

We are IntechOpen, the world's leading publisher of Open Access books Built by scientists, for scientists

6,900

Open access books available

185,000

International authors and editors

200M

Downloads

Our authors are among the

154

Countries delivered to

TOP 1%

most cited scientists

12.2%

Contributors from top 500 universities



WEB OF SCIENCE™

Selection of our books indexed in the Book Citation Index
in Web of Science™ Core Collection (BKCI)

Interested in publishing with us?
Contact book.department@intechopen.com

Numbers displayed above are based on latest data collected.
For more information visit www.intechopen.com



The Influence of Ultrasound Equipment Knobology in Abdominal Sonography

Yaw Amo Wiafe and Augustina Badu-Peprah

Abstract

Ultrasonography is a highly operator dependent imaging modality with a number of knobology variables that are under the control of the operator. Knobology is a terminology that describes the manipulation of ultrasound knobs and system controls in order to obtain the best image possible from diagnostic ultrasound. The inadequate use of knobology variables may impair image quality and can result in misdiagnosis. In abdominal sonography, selecting the appropriate application preset for abdominal examination is first step towards achieving an optimum image. The next step is to select an appropriate transducer frequency which must take the size of the patient into account. Transducer frequency is typically in the range of 3–5 MHz, but a lower frequency may achieve better depth penetration in larger patients. While the output power may improve image quality by increasing the intensity of transmitted sound energy, the impact is usually insignificant. The practice of using high output power should therefore be limited because of the risk of biologic effect. Other essential knobs for better image optimization include controlling the overall gain, time gain compensation, focal zone, dynamic range and tissue harmonic imaging. In the assessment of blood flow in abdominal vessels the regulation of the pulse repetition frequency, Doppler gain, imaging angle, and wall filter improves the sensitivity of color and spectral Doppler.

Keywords: knobology, resolution, greyscale imaging, Doppler imaging, ALARA principle

1. Introduction

Ultrasonography is a highly operator dependent imaging modality with a number of knobology variables that are under the control of the operator. Knobology is a terminology that describes the manipulation of ultrasound knobs and system controls in order to obtain the best image possible from diagnostic ultrasound. The inadequate use of knobology variables may impair image quality and can result in misdiagnosis.

This chapter explains the functions of the various ultrasound system controls and knobs and the impact they have on greyscale ultrasound imaging. It demonstrates the effect of transducer selection on image quality, and the role of knobology variables in image optimization. This includes a description of the Application Preset, Output Power, Overall Gain, Time Gain Compensation (TGC), Focus, Depth, Zoom, Dynamic Range and Tissue Harmonics. The influence of these

essential knobs and system controls on spatial resolution (including lateral and axial resolution) and Contrast resolution are explained. In addition, the utility of Doppler knobs for imaging abdominal blood vessels are also explained and demonstrated.

The need to adhere to the principle of As Low As Reasonably Achievable (ALARA) is also explained with emphasis on the imaging of neonates and children. Lastly, the chapter also emphasizes the potential detrimental effect of underutilizing ultrasound knobs and system controls in abdominal sonography.

2. Switching-on the ultrasound machine

Switching on the ultrasound machine is the first knob to press if the machine is switched off. By switching on the machine, the ultrasound system is given access to a source of electricity, which excites the tiny piezoelectric crystals within the connected transducer. These piezoelectric crystals emit sound waves as a result of their exposure to electricity. The sound waves produced by the piezoelectric crystals can then be transmitted into the human body, normally aided by a coupling gel which serves as an acoustic medium for eliminating the air between the surface of the transducer and the skin.

3. Application preset

Modern machines allow the operator to preset an application setting for a certain examination type. Ultrasound imaging is used for a wide range of medical applications. Aside its use in assessing the abdomen, it is also used in obstetrics and gynecology, cardiac and vascular examinations, and other small-part examinations such as breast, thyroid, and musculoskeletal imaging. Different sonographic settings are needed for the various examinations, due to their differences in terms of the depth of region of interest, tissue-type, and the size of organs and structures in that region. Because of the uniqueness of these examinations, adjusting the settings between patients for a different examination can be time consuming, and may compromise the adherence to ALARA principles. In addressing this limitation, the manufacturer makes it easier by allowing the operator to select the type of examination which will activate the pre-defined factory settings for the specific type of examination. By selecting the appropriate 'Application Preset' for abdominal examination, the pre-defined factory settings are activated for abdominal sonography. This automatically adjusts the basic settings for the selected examination, which include an adjustment of the transducer frequency, acoustic Output Power, Overall Gain, Dynamic Range, Depth and other related settings.

Performing an abdominal ultrasound with a different application preset may impair the image quality which could mislead image interpretation. For example, a user performing an obstetric examination may identify a need for including abdominal examination without switching to the abdomen preset. This may impair the image quality of the abdominal examination if careful adjustments of relevant knobology variables are not made. In **Figure 1a**, obstetric preset was used in imaging the kidneys of an obstetric patient who complained of flank pain during an obstetric ultrasound examination. Upon using the basic obstetric preset without further manipulation of essential knobs, there was the tendency of suspecting a focal lesion in the right kidney (see arrow in **Figure 1a**). However, a switch to the basic abdomen preset without further manipulation resulted in an improved image quality which shows a normal kidney (see arrow of **Figure 1b** in the same person).

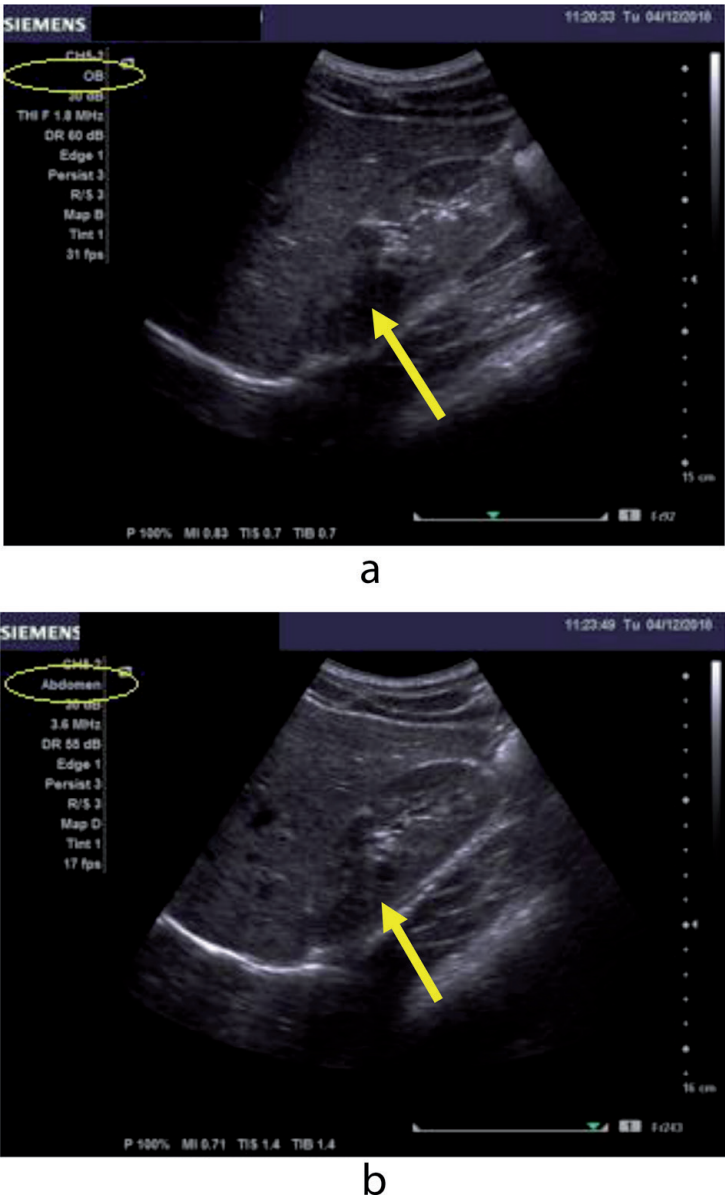


Figure 1.
(a) Image of the right kidney with OB preset suggests a focal change within kidney (see arrow). (b) Image of the right kidney with abdomen preset suggests normal appearance (see arrow).

It therefore suggests that much more manipulation of knobs will be required for selecting the ‘wrong’ application preset which may unduly extend the duration of the examination as a compromise on ALARA principles.

4. The transducer

Ultrasound images are produced from high frequency sound waves that are emitted by the transducer, typically in the range of 1–15 MHz [1, 2]. The frequency of the transducer is determined by the thickness of the piezoelectric crystals and the damping material behind them [3]. In producing a higher frequency, the manufacturer places a damping material behind very thin piezoelectric crystals in order to shorten the pulses of sound waves that are emitted [3]. However, shorter pulses of sound waves are unable to penetrate deeper because of shorter wavelength [3]. Due to this penetration limitation, different types of transducers are designed with different ranges of frequency. Higher frequency transducers offer better resolution at the expense of depth penetration, whilst lower frequency transducers offer better depth penetration for poorer image resolution [2, 3].

Since most abdominal organs such as the liver, spleen, kidneys, pancreas and aorta are relatively deeper, lower frequency transducers are used for this type of examination. Unlike the transducers designed for other examinations, the transducers for abdominal examination (i.e. sector or curvilinear) have a divergent and wider far field. Aside the lower frequency of curvilinear and sector transducers which makes image resolution relatively poorer, there is also an increase in attenuation as the sound beam travels deeper. This may adversely affect the image resolution of abdominal sonography. It is therefore incumbent on the operator to make a careful choice between better image resolution and depth penetration.

The typical frequency range for curvilinear transducers is in the range of 2-5 MHz. In selecting a frequency for an abdominal examination, the operator should consider the size of the patient. If the patient is smaller in size, a higher frequency should be used for better spatial resolution. Particularly in neonates and children, a higher frequency is highly useful, as this is likely to produce better image resolution to shorten the duration of the examination in fulfillment of ALARA principles. Secondly, children are less likely to cooperate during the examination, therefore using a lower frequency such as 3 MHz for abdominal examination may unduly delay the examination because of the lack of patient cooperation and a poorer image resolution. **Figure 2a** and **b** demonstrates two images of the right and left kidneys

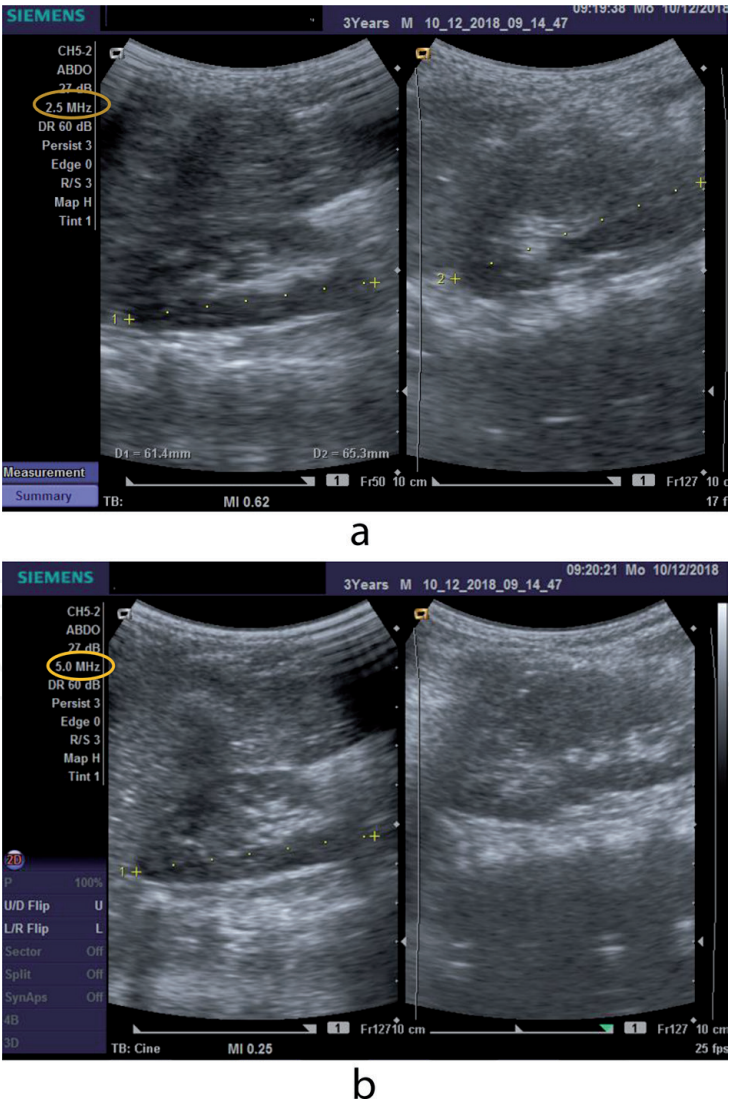


Figure 2.
(a) Image of the right kidney of right and left kidney in a 3-year-old non-cooperating patient showing poorer image resolution because of lower transducer frequency of 2.5 MHz. (b) Image of the right kidney of right and left kidney in the 3-year-old non-cooperating patient showing better visualization of renal margins because of lower transducer frequency of 2.5 MHz.

obtained from a 3-year-old infant with the higher frequency obviously showing more details than the lower frequency. However, a low frequency of 3-4 MHz is often ideal for imaging the average-sized adult, whilst larger or much more obese adults may require as low as 2 MHz of frequency for adequate depth penetration.

In addition, a linear transducer may also be used during abdominal ultrasound. Linear transducers use higher frequencies for imaging structures that are more superficial, such as the anterior abdominal wall and the surface of the liver. They are also used in assessing the appendix.

5. Output power

The acoustic output power of the machine must be considered at all times by the operator. As indicated above, selecting the appropriate preset for abdomen ultrasound will automatically adjust the output power to the recommended level. However, while it is important to observe the ALARA principle by using the minimum output power possible, the operator must not compromise image quality for output power reduction which may lead to misdiagnosis. In essence, there should be a balance between maximizing image quality with the minimum output power possible as a measure for reducing the risk of biological effect. Usually, the ultrasound

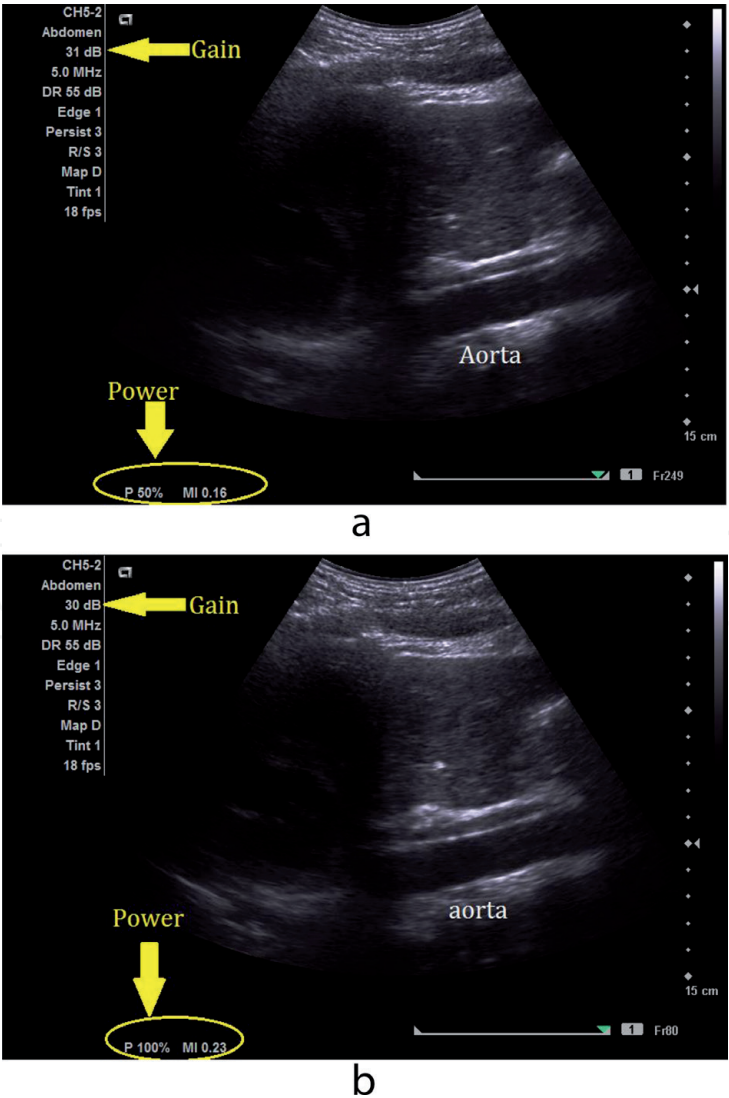


Figure 3.
(a) The appearance of the abdominal aorta at a reduced output power by 50%. (b) The appearance of the abdominal aorta when the output power increased was increased to 100 showed no significant difference %.

machine will display the output power on the screen at all times, allowing the operator to be constantly informed (**Figure 3a and b**). However, while increasing the power output may be useful, it may also be needless in many cases. The over-all Gain can play a better and safer role in image quality optimization than the output power. **Figure 3a and b** demonstrate that there is no significant difference between the appearance the abdominal aorta if the output power is reduced by 50% and the overall gain is about 30 decibels.

6. Overall gain

The overall gain is the recommended option to consider in place of increasing the output power. With the overall gain, image quality can be improved by adjusting the brightness of the entire field of view without increasing the intensity of transmitted sound energy. It achieves this by amplifying the echo-signals returning from the body after transmitting the sound waves. The overall gain can be considered as the ‘microphone’ in ultrasound imaging. The technology is similar to using a microphone to amplify someone’s voice for the listener. Increasing or decreasing

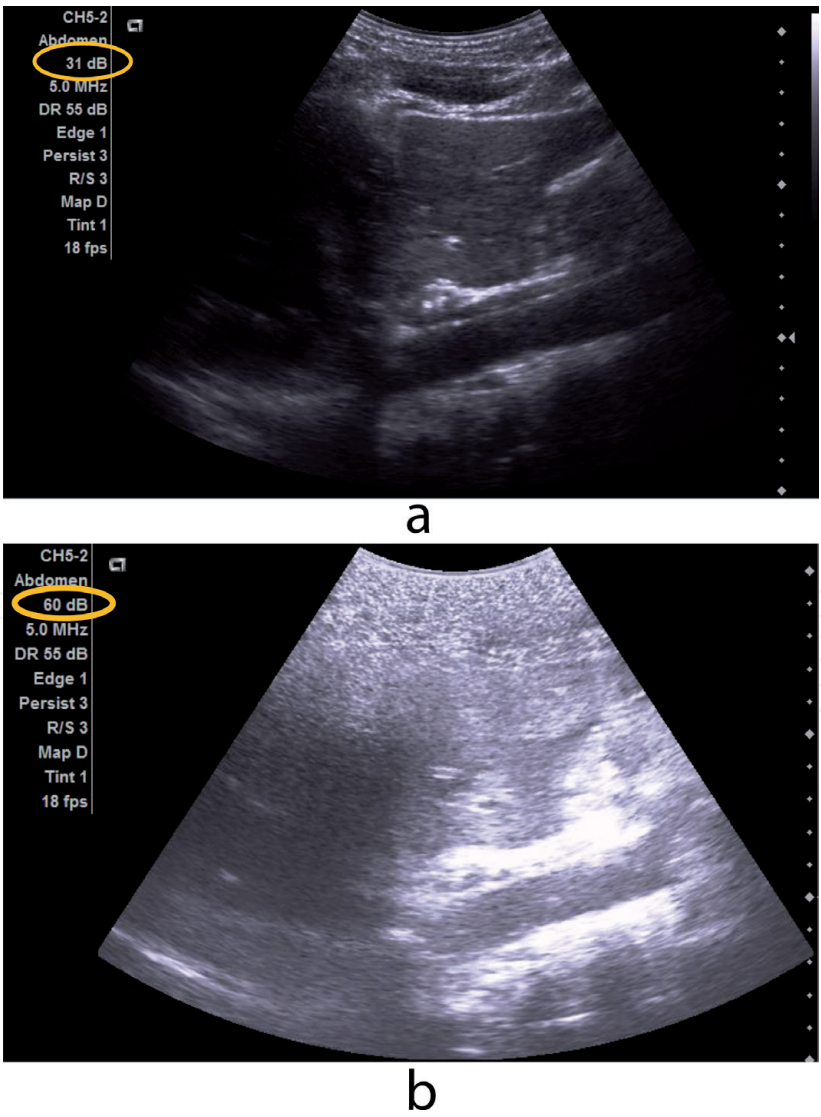


Figure 4.
(a) Adequate overall gain of 31 decibels with liver surface showing. (b) Too high overall gain of 60 decibels with liver surface missing.

the overall gain may improve contrast resolution for adequate visualization of the image. However, just as a microphone can sometimes produce noise and become a nuisance, increasing the overall gain beyond a certain point will affect contrast and spatial resolution by making the image appear too bright. Nonetheless, it is a knob you cannot do without in image optimization. Most modern machines integrate the overall gain in the Bmode or 2D knob, but it is still a separate knob in some machines. Manipulate the overall gain by adjusting it ‘up and down’ and carefully observe the changes that occur as you control the knob. **Figure 4a** and **b** shows images of adequate versus high overall gain and the effect it has on assessing the surface of the liver.

7. Time gain compensation

While the overall gain would adjust the brightness of the entire field of view, it may not address attenuation occurring at specific depths. Some structures in the body are much more affected by attenuation than others and would therefore need additional compensation for the loss of sound energy. For example, an optimum visualization of the left lobe of the liver requires a depth specific gain adjustment that is different from the gain compensation needed for optimum visualization of the right lobe. Hence the Time Gain Compensation (also known as Depth Gain Compensation), is a set of depth-specific slide controls that can be used for echo-signal amplification at different depths (see **Figure 5**). It allows the adjustment of echo-signals in the near-field, mid-field and far field to improve axial resolution. The TGC creates uniformity in the brightness of the echoes when used in conjunction with the overall gain. The best approach is to center all the TGC settings before adjusting the overall gain. After adjusting the overall gain, the TGC can then be adjusted to compensate for attenuation at specific depth.



Figure 5.
TGC slide in the yellow circle.

8. Focal zone(s)

During scanning, the system allows the operator to improve lateral resolution in a region of interest by adjusting the focal zone. This is an additional measure to minimize the effect of attenuation. However, while other controls such as the overall gain and TGC are effective for improving axial resolution, adjusting the focal zone is much more effective for improving lateral resolution. Lateral resolution refers to the ability to identify structures lying side-by-side as separate structures, while axial resolution refers to the ability to identify a structure lying on another structure as separate structures.

The focal zone normally appears at the lateral side of Bmode as a triangular-shaped structure or a dot. It can be moved up or down by the operator and should be placed at the region of interest or posterior to that region. If a single focal zone is set too superficially a poorer image resolution will be observed in the far field (**Figure 6**). However if the focal zone placed below or at the level of region of interest, the resolution improves in the entire field of view (**Figure 6**). To improve lateral resolution in a wider region, more than one focal zones may be selected by the operator. However, increasing the number of focal zones also decreases the frame rate which has the tendency of slowing down the image production time to the detriment of temporal resolution. Thus using more focal zones slows down the scanning time which may not support the principles of ALARA in terms of keeping to a reasonable scanning time.

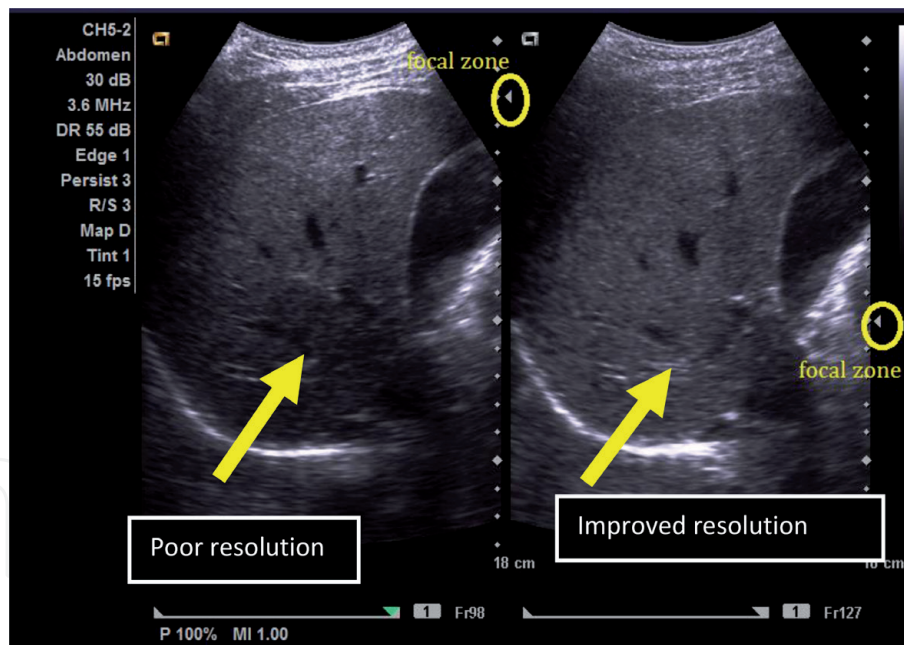
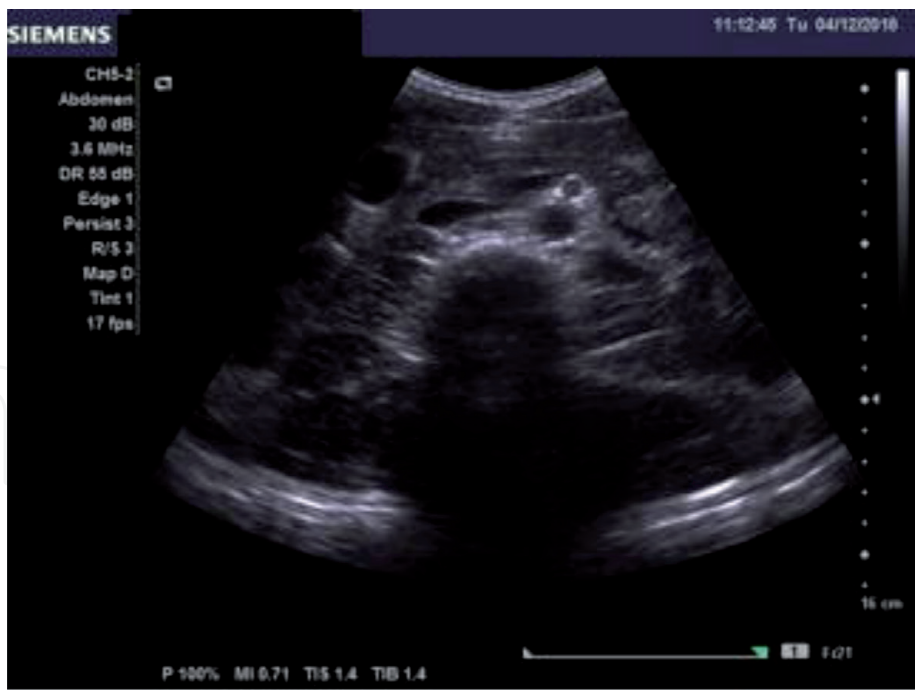


Figure 6.

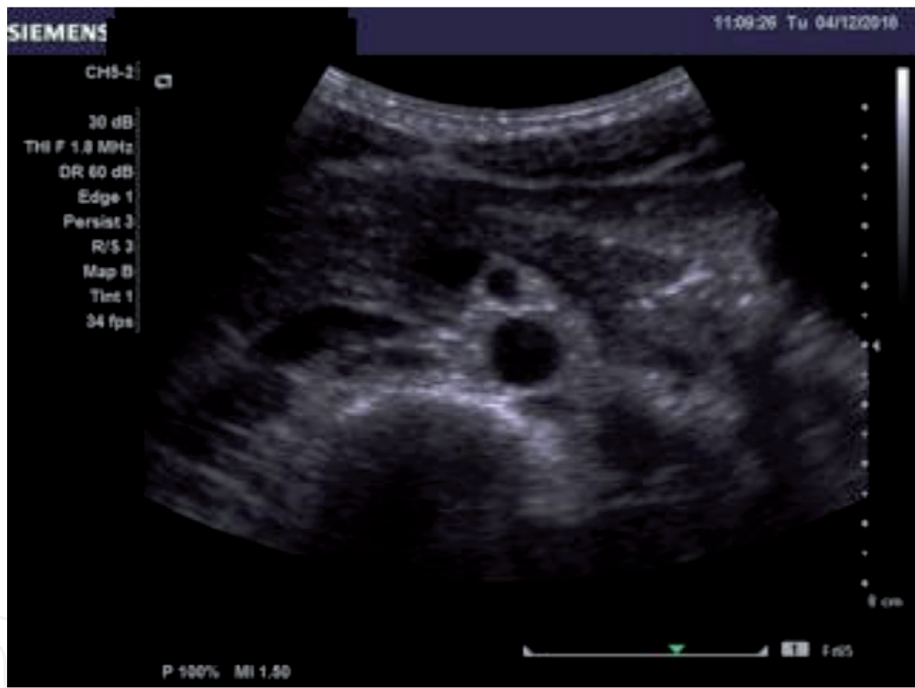
Poorer resolution when focal zone is positioned in the near is compared to focal zone positioned at the level of interest.

9. Depth

The Depth is special a knob for adjusting the distance of the field of view. Structures within the field of view can be moved far or closer by adjusting the Depth. This is to ensure that the region of interest is closer enough for optimum visualization. It is also to avoid showing regions that are not relevant to the area of interest. **Figure 7a** is an example of a far depth image of the pancreas, with a wide irrelevant space showing behind the spine. This irrelevant space can be avoided by adjusting the



a



b

Figure 7.
(a) Far depth. (b) Closer depth.

Depth closer for adequate visualization (**Figure 7b**). The structure of interest should always take the center stage by occupying about two-thirds of the field view. In order to avoid missing a pathology beyond the field of view, the best practice is to adjust the Depth for a far field of view before adjusting for a closer field of view. **Figure 8** is an example of how one can miss a pathology, if the Depth is not adjusted for adequate visualization beyond the field view. It demonstrates how a closer Depth would have missed the pleural effusion if a far depth image was not assessed.

However, while moving the depth closer and far is necessary for evaluating various conditions and ruling out pathologies, moving the Depth closer has the tendency of generating noise which can worsen contrast resolution and may even mimic a pathology.

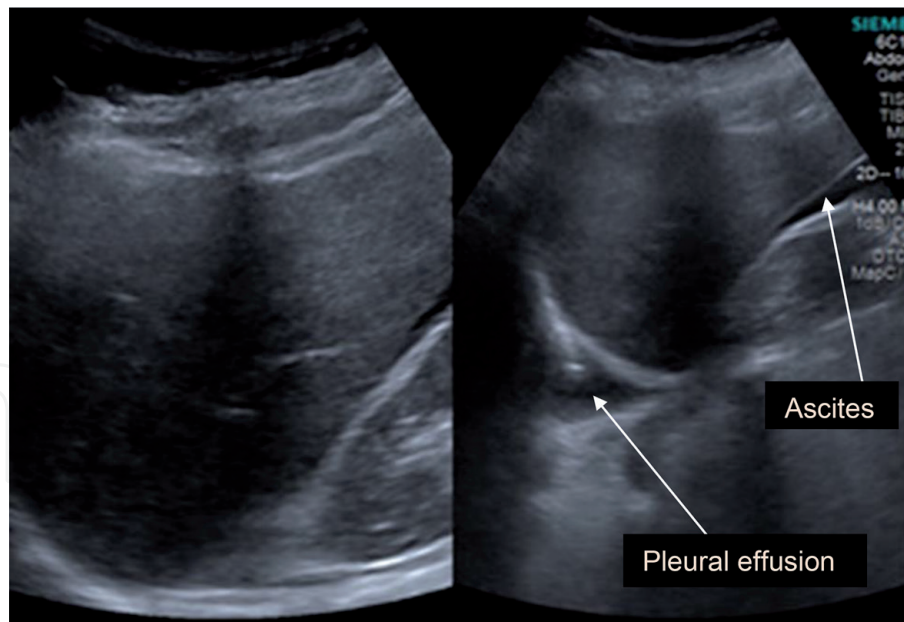
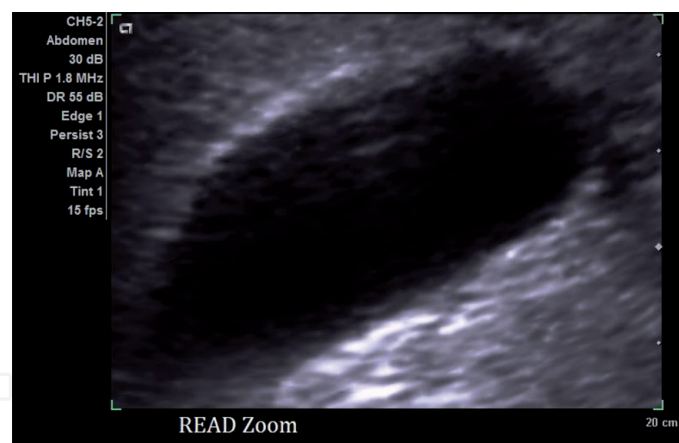


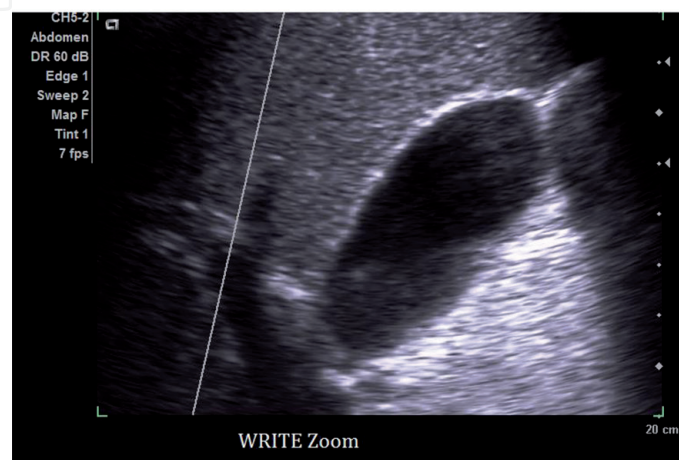
Figure 8.
Missing information on the right-side because of depth adjustment.

10. Zoom

The zoom is used for magnifying the area of interest. Unlike the depth which magnifies by moving the area of interest closer, the zoom actually magnifies by making the region of interest appear bigger. Another limitation of the depth that is



a



b

Figure 9.
(a) Read zoom. (b) Write zoom.

addressed by the zoom is the ability to enlarge a specific region of interest. Without using the zoom, measuring some tiny structures may difficult because of poor spatial resolution. For instance, in measuring the thickness of the gallbladder wall, using the zoom improves the visualization of the wall for an accurate measurement (**Figure 9a and b**).

Some manufacturers use READ zoom for their magnification, while others use WRITE zoom. Both read zoom and write zoom can produce poorer image depending on the size of the area magnified. However, READ zoom produces the worse kind of images because it relies on stored images which enlarges the pixel density in that region (**Figure 9a**). On the other hand, WRITE zoom tries to maintain the pixel density by zooming the image live which produces a better spatial resolution. Operators should check the type of zoom in their machine in order to appreciate how much zooming can be done without compromising the image quality.

11. Dynamic range

The Dynamic Range is a control on the ultrasound system that allows the operator to determine the range of shades of gray to be displayed on the monitor. Broad shades of gray displays a wider range of echo-intensity between bright and

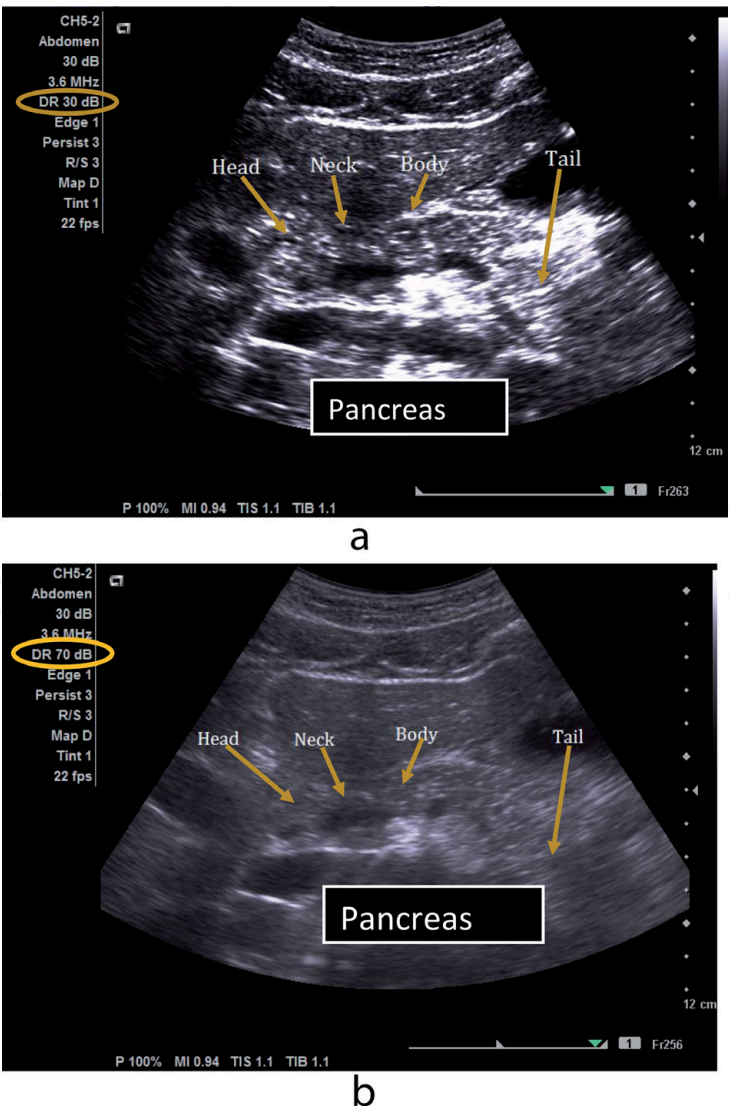


Figure 10.
(a) Narrow dynamic range. (b) Broad dynamic range.

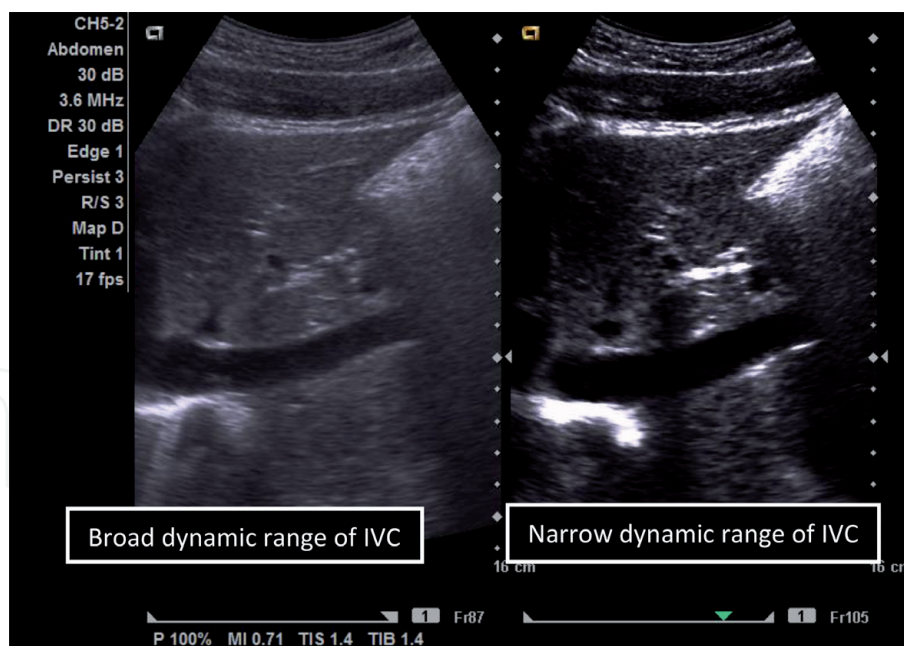


Figure 11.
Broad versus narrow dynamic range of IVC.

dark and produces a smoother image overall, whilst narrow shades of gray displays a narrower range of echo-intensity between bright and dark and produces a higher contrast between two regions of different echogenicity. In abdominal sonography, a broad dynamic range is the most appropriate option for assessing the echotexture of homogeneous soft-tissue structures like the liver, pancreas and spleen. Narrow dynamic range is most appropriate for assessing anechoic structures such as the aorta and IVC. **Figure 10a** shows the effect of narrow dynamic range of the pancreas in comparison to the liver, and **Figure 10b** shows the effect of broad dynamic range on the pancreas which shows poor differentiation in echotexture in comparison to the liver. In **Figure 11** also shows the effect of long and short dynamic range on the appearance of the IVC.

12. Tissue harmonic imaging

Tissue harmonic Imaging (THI) is an additional control for image optimization in most ultrasound machines. It improves image quality by eliminating weak echoes that cloud the image when the fundamental frequency of the transducer is used. It replaces the returning echoes from the fundamental frequency with echoes in the harmonic frequency which improves spatial resolution. This eliminates side lobe artifacts and noticeable noise in the area of interest. It can therefore be used in conjunction with the utilization of other knobs that may generate noise. For example, noise generated by increasing the Depth can be instantly eliminated by activating THI. **Figure 12** also shows an increase in noise as a result of increasing the overall gain and Depth, and how it is instantly eliminated by the activation of THI. The activation of the THI in **Figure 12** instantly changed the settings from the fundamental frequency to the harmonic frequency. In **Figure 13**, you also appreciate the importance of THI, in terms of how it improves visualization of the margins of liver surface in comparison with the adjacent image which did not use THI.

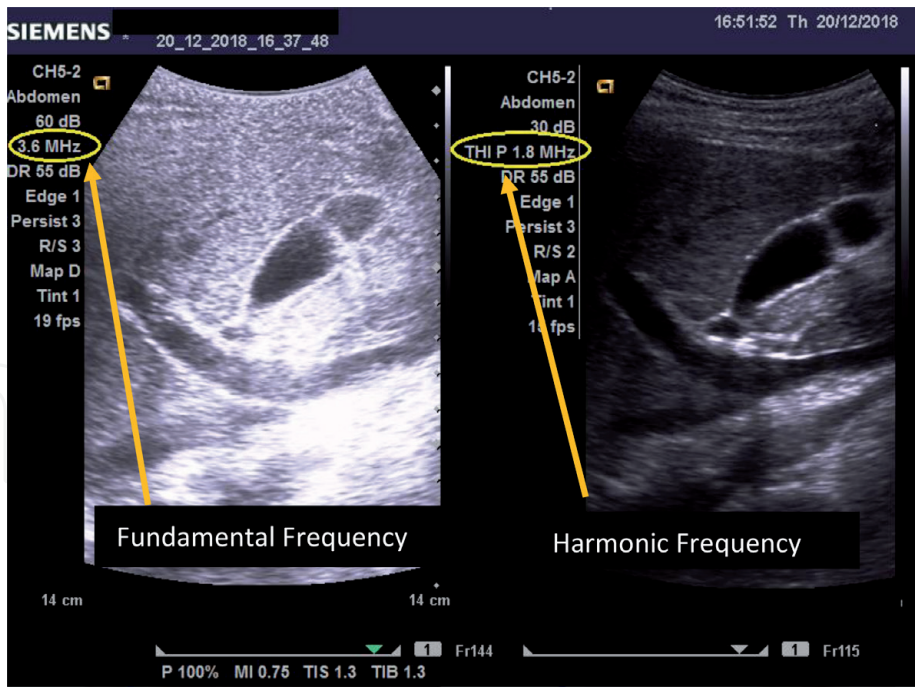


Figure 12.
Noise from increased overall gain and depth is instantly eliminated THI activation.

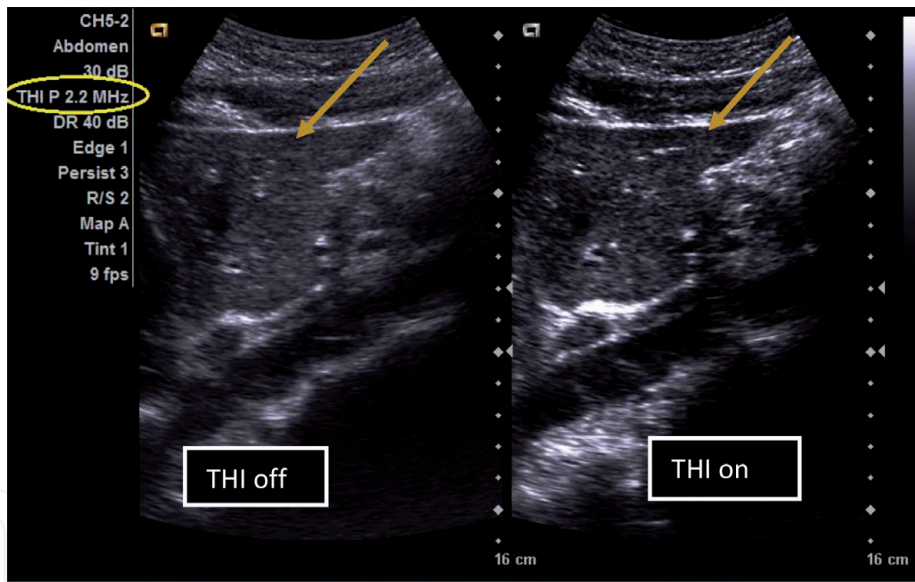


Figure 13.
Improved liver margins with activated THI.

13. Freezing and cineloop

The ultrasound machine also has a freeze button which enables the operator to stop and evaluate the image quality before storage. Saving an image without freezing implies that the image was not evaluated for quality. Freezing the image before storage is therefore recommended.

The cineloop is additional control that helps with selecting the best of the image frozen image. It displays image frames acquired in the last few seconds prior to freezing. The cineloop can be highly useful when scanning children.

14. Additional controls for imaging abdominal blood vessels

An abdominal ultrasound examination may also require the assessment of blood vessels and Doppler evaluation of blood flow. The fundamental knobs that influence both color and spectral Doppler imaging include the Doppler gain, pulse repetition period (PRF), and the wall filter. In assessing the presence of flow in smaller blood vessel, the minimum standard is to adjust the system for a higher Doppler gain, a lower PRF and a lower wall filter [4]. Careful manipulation is used in balancing these knobs, as a slight overlap between them can generate noise artifacts.

Figure 14a shows the poorer flow in the hepatic vein in comparison to the portal vein as a result of higher PRF. This is much improved in **Figure 14b** with decreased PRF.

In larger abdominal blood vessels such as the aorta, additional knob controls that are highly relevant include the imaging angle which must not be parallel to the surface of

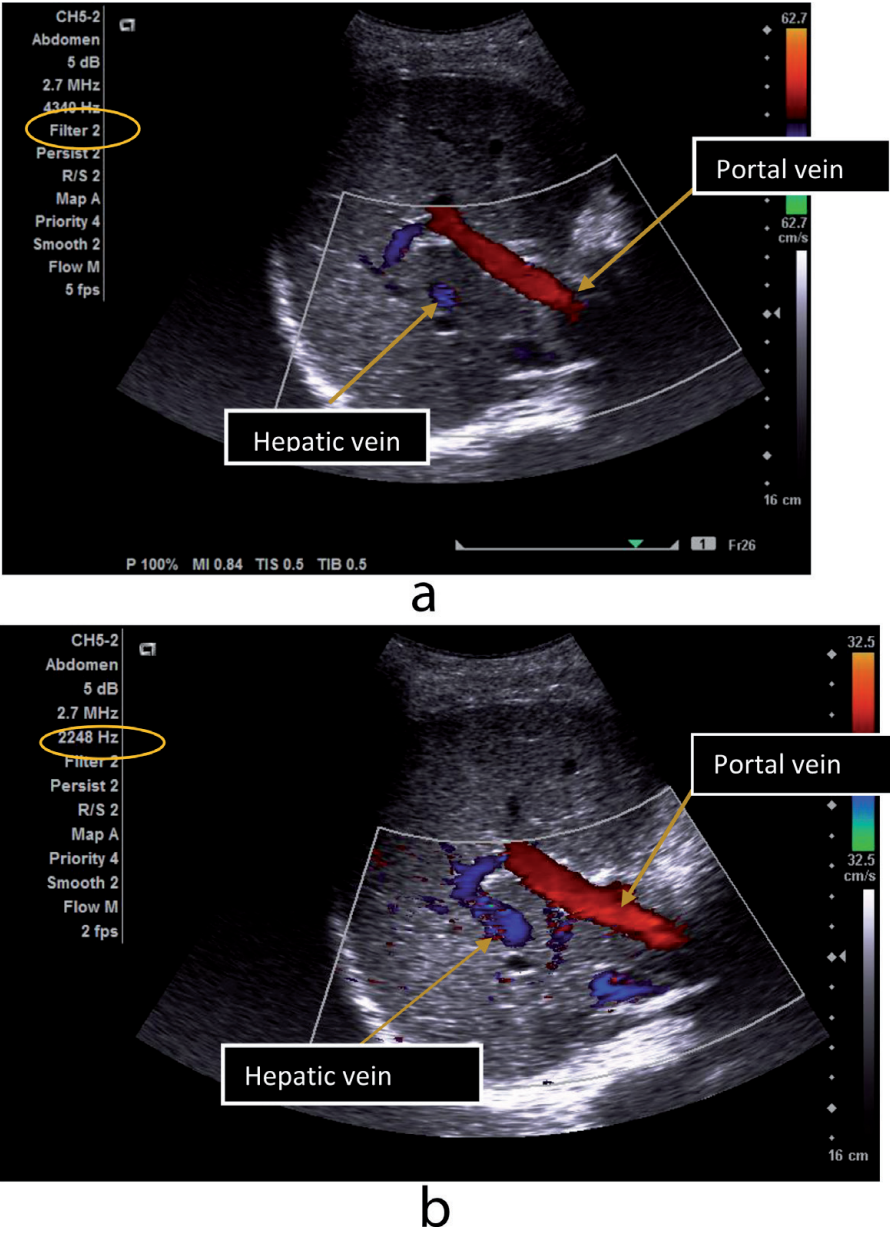
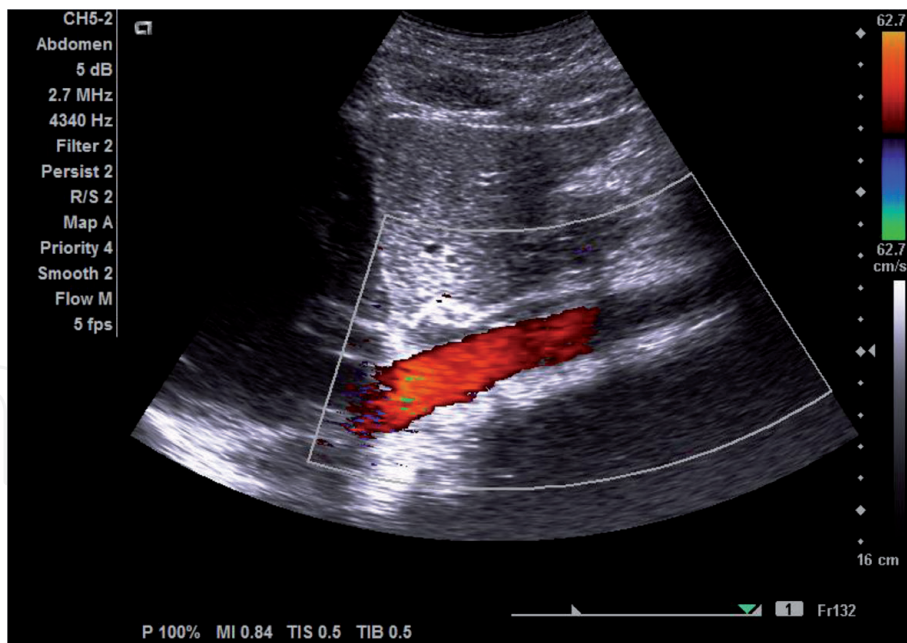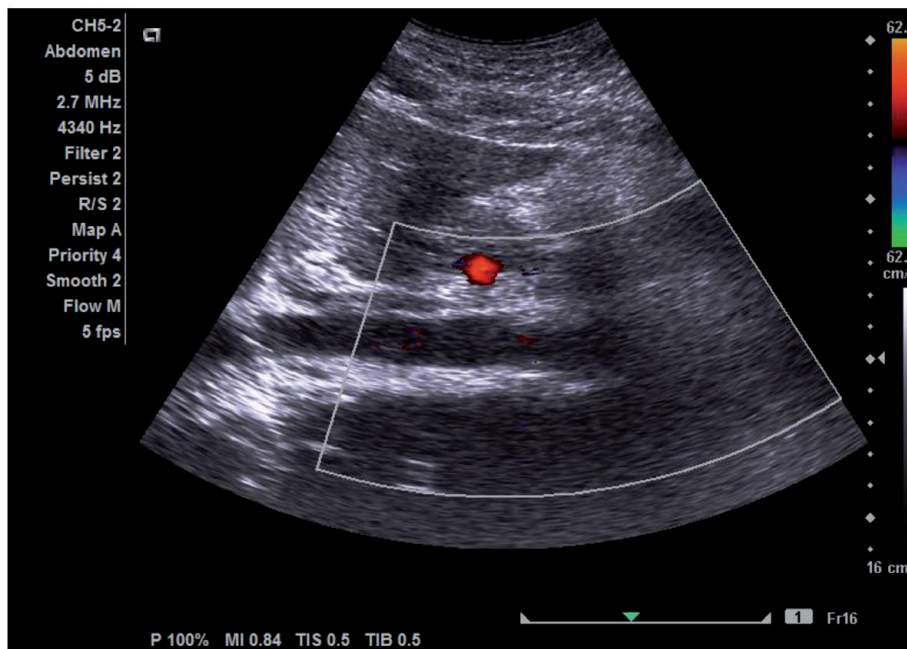


Figure 14.
(a) High PRF with low flow sensitivity in hepatic vein. (b) Low PRF with high flow sensitivity in hepatic vein.



a



b

Figure 15.
(a) Color flow showing in angled vessel. (b) Color flow absent in parallel vessel.

the transducer. **Figure 15a** and **b** shows the effect of imaging angle on color flow in the aorta which is absent when the vessel is parallel to the surface of the transducer.

In spectral Doppler Imaging, however, lower PRF may cause aliasing artifact, especially when the baseline is high [5]. This can be corrected by increasing the PRF of the spectral waveform and lowering the baseline. **Figure 16a** shows aliasing artifact of the Superior Mesenteric Artery (SMA) which was as a result of a lower PRF and a higher baseline. By increasing the PRF and lowering the baseline, a normal waveform of the SMA was obtained in **Figure 16b**. Other essential knobology settings which improves spectral waveform in the assessment of peak systolic velocity include using a smaller sample gate and ensuring an angle correct setting that aligns with the vessel wall as demonstrated in **Figure 16a** and **b**.

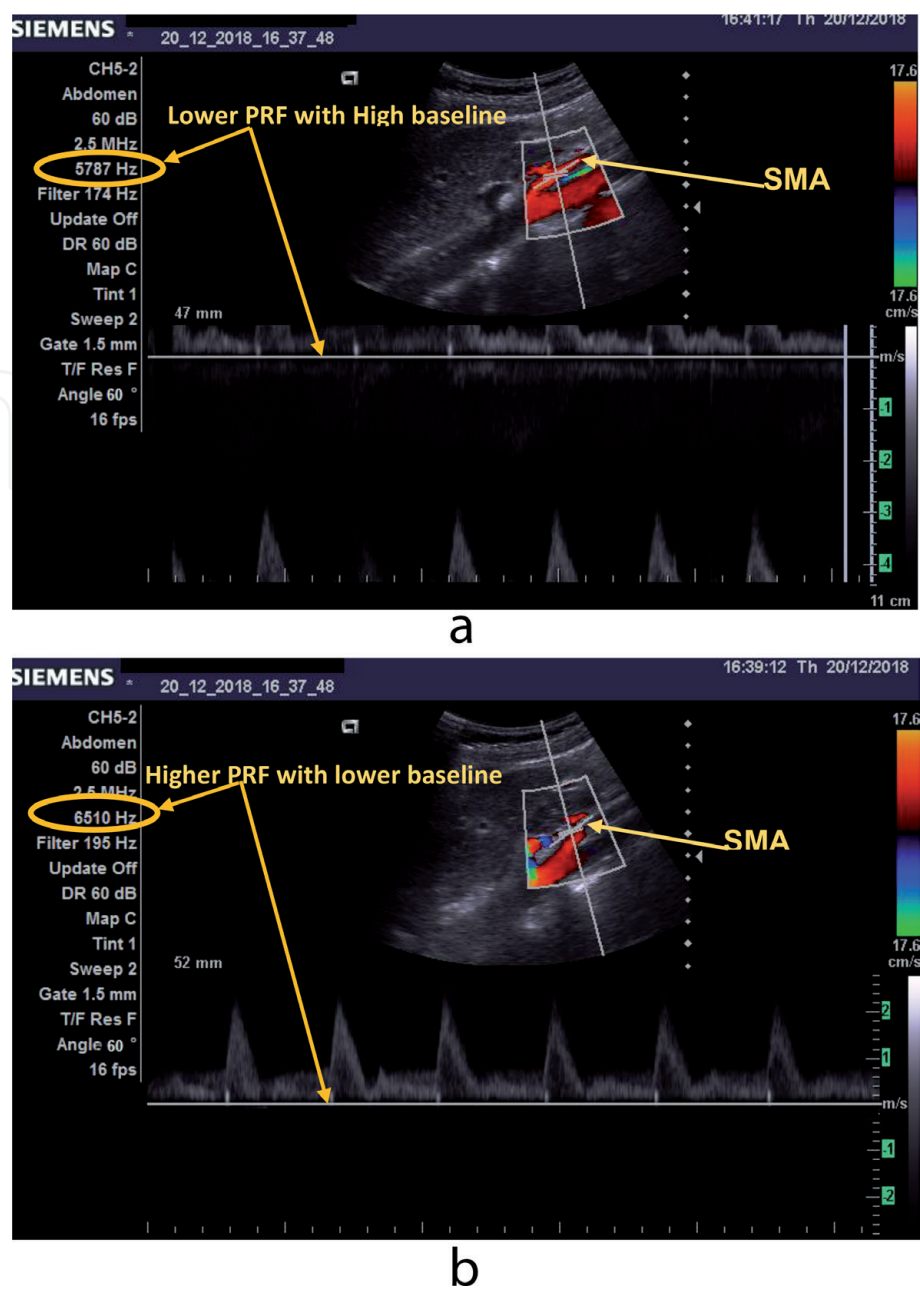


Figure 16.
(a) Aliasing artifact in the superior mesenteric artery as a result of lower PRF and higher baseline. (b) Adequate waveform for assessing peak systolic velocity in the superior mesenteric artery, after increasing the PRF and lowering the baseline.

15. Conclusion

Understanding the influence of knobology in ultrasound imaging is essential in abdominal sonography. The image quality can be optimized by selecting the appropriate application preset and transducer frequency. While using the highest output power may be useful, it is not necessary in many instances. The various knobology variables with direct influence on greyscale and color Doppler should be regularly manipulated by the operator for the best image possible in abdominal sonography.

IntechOpen

Author details

Yaw Amo Wiafe^{1*} and Augustina Badu-Peprah²

¹ Medical Imaging Section, Department of Medical Diagnostics, Kwame Nkrumah University of Science and Technology, Kumasi, Ghana

² Department of Radiology, Komfo Anokye Teaching Hospital, Kumasi, Ghana

*Address all correspondence to: wadart1@gmail.com

IntechOpen

© 2019 The Author(s). Licensee IntechOpen. This chapter is distributed under the terms of the Creative Commons Attribution License (<http://creativecommons.org/licenses/by/3.0>), which permits unrestricted use, distribution, and reproduction in any medium, provided the original work is properly cited. 

References

- [1] Merritt C. In: Rumack CM, Wilson SR, Charboeau JW, Levine D, editors. Diagnostic Ultrasound. 4th ed. Mosby: Elsevier; 2011. p. 3. Ch. 1
- [2] Venables H. How does ultrasound work? Ultrasound. 2011;**19**(1):44-49. DOI: 10.1258/ult.2010.010051
- [3] Kremkau FW. Diagnostic Ultrasound: Principles and Instruments. Philadelphia, USA: WB Saunders Company; 2005
- [4] Kim MJ, Kim KW, Kim SY, Kim JK, Won HJ, Shin YM, Kim PN, Lee MG. Technical essentials of hepatic doppler sonography. Current Problems in Diagnostic Radiology. 1 Mar 2009;**38**(2):53-60. Available from: <https://doi.org/10.1067/j.cpradiol.2007.08.008>
- [5] Kruskal JB, Newman PA, Sammons LG, Kane RA. Optimizing doppler and color flow US: Application to hepatic sonography. Radiographics. May 2004;**24**(3):657-675. Available from: <https://doi.org/10.1148/rg.243035139>