

We are IntechOpen, the world's leading publisher of Open Access books Built by scientists, for scientists

6,900

Open access books available

186,000

International authors and editors

200M

Downloads

Our authors are among the

154

Countries delivered to

TOP 1%

most cited scientists

12.2%

Contributors from top 500 universities



WEB OF SCIENCE™

Selection of our books indexed in the Book Citation Index
in Web of Science™ Core Collection (BKCI)

Interested in publishing with us?
Contact book.department@intechopen.com

Numbers displayed above are based on latest data collected.
For more information visit www.intechopen.com



Keloids and Hypertrophic Scars Can Now Be Treated Completely by Multimodal Therapy, Including Surgery, Followed by Radiation and Corticosteroid Tape/Plaster

Rei Ogawa

Abstract

Keloids and hypertrophic scars are fibroproliferative disorders of the skin. Research over the last decade has markedly improved our understanding of the pathogenesis of these scars, in particular, the fact that both disorders are caused by prolonged inflammation that prevents the orderly healing of injured or irritated skin. This protracted inflammatory response is due to genetic, systemic, and local risk factors. Genetic factors include single nucleotide polymorphisms, while systemic factors include hypertension, pregnancy-related and other hormones, and aberrant cytokine levels. An important local factor is the mechanical force (tension) on the scar. These observations have greatly aided the development of therapies for these once-intractable scars. As a result, these scars are now regarded as being completely treatable. At present, we believe that the following combination of three therapies most reliably achieves a complete cure: surgery followed by radiation and the prolonged daily use of corticosteroid tape/plaster.

Keywords: keloid, hypertrophic scar, scar, scar contracture, fibroproliferative disorder, fibrosis, surgery, radiotherapy, corticosteroid, tape, plaster

1. Introduction

While keloids and hypertrophic scars have some tumor-like properties, they are actually inflammatory conditions that drive the excessive proliferation of dermal fibroblasts and the aberrant accumulation of dermal matrix [1]. These fibroproliferative disorders of the skin are caused by abnormal healing of injured or irritated skin. Common causes of injury and irritation are trauma, burn, surgery, vaccination, skin piercing, acne, and herpes zoster. The risk of developing keloids and hypertrophic scars is particularly high if the wound is deep enough to damage the reticular layer of the dermis and if various genetic, systemic, and/or local risk factors that prolong the inflammatory stage of wound healing are present. The protracted inflammation accelerates angiogenesis and induces the excessive accumulation of collagen. As a result, red and elevated scars that have an unappealing appearance arise. These scars also associate with intermittent pain, persistent itching, and a sensation of contraction. Moreover, if the wounds are located on

the joints or mobile regions, including the neck, the resulting scars can develop into scar contractures. Thus, the primary end-points of treatments for keloids and hypertrophic scars should be functional improvement and relief from pain and itch. Another important goal is the esthetic improvement.

2. Causes of keloids and hypertrophic scars

A number of genetic, systemic, and local factors that influence the characteristics and quantity of keloids and hypertrophic scars have been identified [2]. The genetic causes of pathological scar development include single nucleotide polymorphisms [3, 4]. Moreover, our study showed that one of these polymorphisms associates significantly with clinically severe keloids [4]. It has been suggested that keloids are more influenced by genetic background than hypertrophic scars. This notion remains to be tested. To test it, it will be necessary to have a critical biomarker that reliably distinguishes keloids from hypertrophic scars. One possibility is keloidal collagen: it seems that this histological feature is only present in lesions that bear other classical hallmarks of keloids, including growth over the edges of the original wound. However, identification of other, nonpathology, biomarkers would be highly useful for addressing questions about the differences between keloids and hypertrophic scars in terms of their etiology, growth characteristics, and treatment responses.

In terms of systemic factors, adolescence and pregnancy appear to associate with a higher risk of developing pathological scars [5, 6]. Our recent study also showed that hypertension associates with the development of severe keloids [7, 8]. I believe that while these factors are not primary causes of keloid and hypertrophic scars, they do worsen the inflammation in the scar tissue, thereby accelerating and increasing angiogenesis and matrix production.

Of the many factors that contribute to pathological scar development is local mechanical forces, I believe that they play a particularly important role [9–11]. Keloids commonly adopt distinct site-specific shapes, namely, the typical butterfly, crab's claw, and dumbbell shapes on the shoulder, anterior chest, and upper arm, respectively. These shapes reflect the region-specific distribution of skin tension that then tugs repetitively or constantly on the wounds/scars. Moreover, keloids are rare on the upper eyelid. This reflects the fact that eyelid skin is always relaxed regardless of whether the eyes are open or closed. An exception may be earlobe keloids: the contribution of mechanical factors to the development of these keloids may be minor. Instead, the most likely local cause of these keloids is the repeated attaching and detaching of the piercing, which repeatedly injures the skin and heightens the risk of infection. Both the skin tension and repeated injury/infection trigger inflammation and the downstream fibroproliferative events. In summary, while skin tension itself may not be a primary cause of keloids and hypertrophic scars, it is likely to be an important local risk factor that worsens and prolongs the inflammation that drives the formation and/or progression of these fibroproliferative scars.

3. Standard treatment of keloids and hypertrophic scars

These findings have markedly improved our understanding of the pathogenesis of keloids and hypertrophic scars, which in turn has promoted the development of highly effective treatments for these once-intractable scars. At present, I believe that the most reliable approach is a combination of three therapies, namely, surgery, followed by radiation, and prolonged daily use of steroid tape/plaster. The addition

of radiation and steroid tape/plaster to surgery reflects the point made above, namely, that keloids and hypertrophic scars are inflammatory disorders, and not tumors. Consequently, anti-inflammatory treatments are most effective for these lesions. Indeed, as will be described below, steroid tapes/plasters/injections on their own work well to reduce the volume of accumulated collagen in keloids and hypertrophic scars, thereby causing their mass to shrink. However, steroid treatments take a long time to achieve mass reduction. Consequently, with large lesions, they are best performed after surgery that rapidly removes the lesion mass. Radiation on its own also has mass-reducing effects because it appears to suppress angiogenesis, and therefore dampens the influx of inflammatory cells and factors into the scar. These anti-inflammatory properties of steroid and radiation mean that their application after mass-reducing surgery (which by itself provokes inflammatory responses) will prevent the recurrence of excised keloids and hypertrophic scars.

Below, we will describe each of the three modalities separately. Thereafter, we will describe the three modalities when used in our combination therapeutic protocol.

3.1 Surgery

Since surgical treatment itself induces inflammation, surgery alone associates with high rates of keloid and hypertrophic scar recurrence. Worse, the recurrent scars are often much bigger than the original lesions. Thus, unless the scar is a minor hypertrophic scar, the decision to surgically remove a pathological scar should be made very carefully and postoperative radiation therapy should always be performed. However, if keloids and hypertrophic scars have infected areas, such as inclusion cysts, these should be removed surgically. Another key indication for surgery is keloids and hypertrophic scars that result in scar contracture of the joints or mobile areas such as the neck. In this case, the contractures should be released by a combination of subcutaneous/fascial tensile reduction sutures, z-plasties, and regional/local flap transfer.

The main objective of surgery for keloids and hypertrophic scars is not only mass reduction, but it is also to reduce the mechanical tension on the scar or the wound that is left after surgical removal of the scar. This is due to the important role of mechanical tension in the development and progression of keloids and hypertrophic scars. This is reflected by the fact that the most effective surgical method for releasing scar contractures is to use a regional or local flap, especially skin-pedicled local flaps: these flaps are particularly useful because they expand naturally after surgery and are therefore not prone to postsurgical contractures [12]. In contrast, skin grafts do not expand, which means that skin grafting tends to generate secondary contractures that result in circular pathological scars around the grafted skin.

3.2 Radiation

Interestingly, keloids respond very well to primary radiation therapy (i.e., radiation monotherapy). This reflects the fact that radiotherapy has a strong anti-inflammatory effect. Primary radiation therapy is suitable for older patients or patients with severe (huge) keloids (**Figure 1**). Since the total radiation dose in these cases is relatively high (e.g., 5 Gy administered once a week for 5 weeks by superficial brachytherapy), it is necessary to apply the radiation carefully to prevent secondary radiation carcinogenesis. However, the risks of primary radiation therapy should be weighed against its tremendous benefits; in particular, the fact that it immediately alleviates the subjective symptoms of keloids such as pain and itching. Moreover, over the following year, it causes the color and thickness of the scars to progressively normalize.

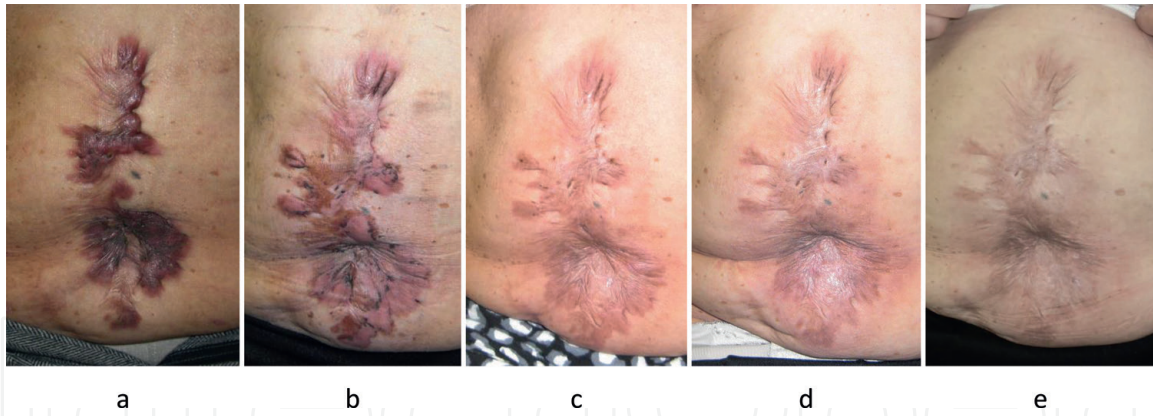


Figure 1.

A patient with severe abdominal keloids was effectively treated by radiation monotherapy. (a) View before treatment. (b) 4 months post-treatment. (c) 9 months post-treatment. (d) 14 months post-treatment. (e) 18 months post-treatment. A 68-year-old female was treated with high-dose-rate superficial brachytherapy. A total of 25 Gy was administered in five fractions over 5 days (i.e., 5 Gy was delivered once a week for 5 weeks). After 4 months of treatment, both the subjective and objective symptoms had improved dramatically. The keloids became mature scars 18 months after the treatment.

Radiation is also useful in the treatment of keloids and hypertrophic scars as a postsurgical modality [13–21]. As mentioned above, the main problem of surgery for pathological scars is recurrence. However, postsurgical radiation therapy can dramatically reduce these rates of recurrence. Use of the linear-quadratic model to calculate the biologically effective doses (BEDs) for various therapeutic radiation regimens after surgical excision of keloids showed that when the BED exceeds 30 Gy, the recurrence rate is less than 10%. Indeed, our review of the literature showed that to ensure maximum efficacy and safety, postoperative radiation for keloids in adults should involve the application of 10–20 Gy *via* daily fractions of 5 Gy.

Currently, we propose that the maximum dose of postoperative radiation therapy for surgically excised keloids is a BED of 30 Gy. A BED of 30 Gy can be obtained in several ways: a single fraction dose of 13 Gy, two fractions of 8 Gy, three fractions of 6 Gy, or four fractions of 5 Gy. In addition, recommended site-dependent dose protocols for the treatment of keloids are as follows: 18 Gy in three fractions over 3 days for the anterior chest wall, shoulder-scapular region, and suprapubic region; 8 Gy in a fraction over a day for the ear lobe; and 15 Gy in two fractions over 2 days for other sites.

It should be noted that the calculated BED of 30 Gy assumes that the α/β ratio for keloids is 10 (the α/β ratio is a measure of the radiosensitivity of a specific tissue). However, when Flickinger [21] investigated the α/β ratio of keloids, they found that it was as low as 2, which suggests that high doses with limited numbers of fractions is the best strategy to achieve low recurrence rates. At present, there is no widely accepted radiation regimen for keloid treatment. Further research on regimens that effectively prevent recurrence without elevating the risk of secondary carcinogenesis is welcome.

3.3 Corticosteroid tapes/plasters

Corticosteroid injections rapidly reduce the volume of a scar [22]. However, the downsides of corticosteroid injections include pain (caused by the injection itself) and difficulties associated with contraindications such as pregnancy, glaucoma, or Cushing's disease. This problem can be overcome by using steroid tapes/plasters. Most pediatric and older patients can be treated by steroid tapes/plaster alone because they have much thinner skin, which means that the steroids are easily absorbed (**Figure 2**). Corticosteroid tape/plasters on their own or in combination

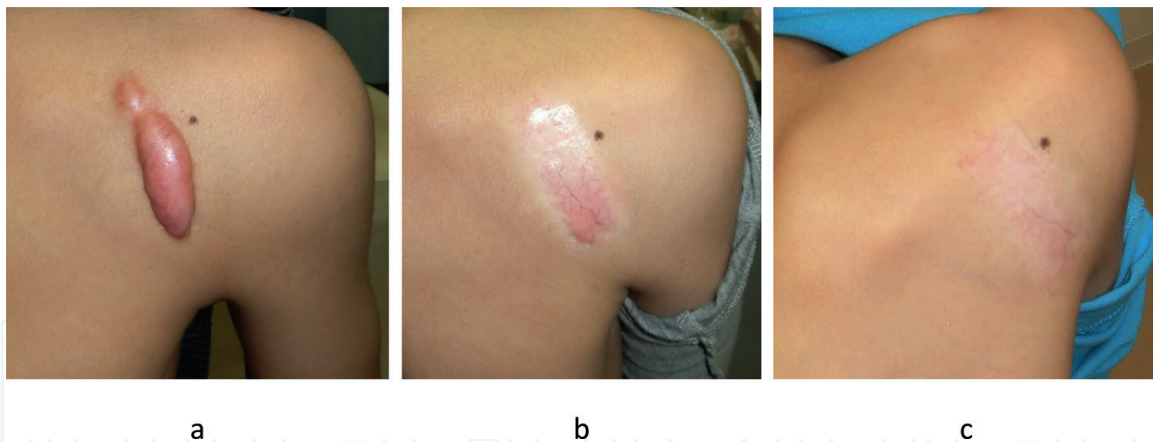


Figure 2.
 A child with a mild keloid was effectively treated with steroid tape alone. (a) View before treatment. (b) After 16 months of treatment. (c) After 26 months of treatment. This 9-year-old boy had a mild right scapular keloid and was treated by fludroxycortide tape (Drenison® tape). The tape was placed on the keloid 24 h a day and was changed daily. The inflammation resolved completely. After 26 months of treatment, both the subjective and objective symptoms of the patient had improved dramatically (the case was cited from the article: Ogawa R, Akaishi S, Kuribayashi S, Miyashita T. Keloids and Hypertrophic Scars Can Now Be Cured Completely: Recent Progress in Our Understanding of the Pathogenesis of Keloids and Hypertrophic Scars and the Most Promising Current Therapeutic Strategy. *J Nippon Med Sch.* 2016;83(2):46–53).

with other therapies such as corticosteroid injection are also suitable for adults with minor keloids. Notably, postoperative application of corticosteroid tape/plasters significantly prevents the development of keloids and hypertrophic scars after surgery.

Steroid tape/plasters should be changed every day. Important tips regarding the treatment of keloids and hypertrophic scars with steroid tapes/plasters are as follows. First, the patient should continue to use the tapes/plasters until the elevated mass becomes flat and soft. Second, once the mass has become flat and soft, steroid tape/plaster use should be stopped, even if the scar is still red. This reflects the fact that if the patient continues to use the tape just because the scar is still red, capillarectasia will occur. This is because the steroid treatment thins the supporting structure of the blood vessels.

Steroid tape is available in the following three countries in slightly different preparations [22]. In the UK, the commercially available formulation comprises a fludroxycortide-impregnated tape ($4 \mu\text{g}/\text{cm}^2$). In the USA, a preparation containing $4 \mu\text{g}/\text{cm}^2$ flurandrenolide (a medium-strength steroid) is available. In Japan, two steroid tape formulations are available, namely, a $4 \mu\text{g}/\text{cm}^2$ fludroxycortide tape (medium-strength) and a $20 \mu\text{g}/\text{cm}^2$ deprodone propionate tape (higher potency steroid). In our experience, deprodone propionate tape is the most effective tape for the treatment and prevention of keloids.

4. Combination treatment for severe keloids and hypertrophic scars

If a patient has severe keloids with infected areas or scar contractures, surgery should be performed (**Figure 3**). If the keloids are too large to be removed in their entirety, the surgeon can resect the region of contracture or infection. The resulting defects can then be covered by a regional/local flap. Surgery should also be performed if the keloid growth causes significant deformity and the keloid does not respond to nonsurgical therapies. An example of severely deforming earlobe keloids is shown in **Figure 4**. Such keloids can be treated by the core excision method, where the fibrous reticular layer of the keloid (i.e., the core of the earlobe keloid) is extirpated and the epidermis and papillary layer of the dermis is preserved as a thin flap.

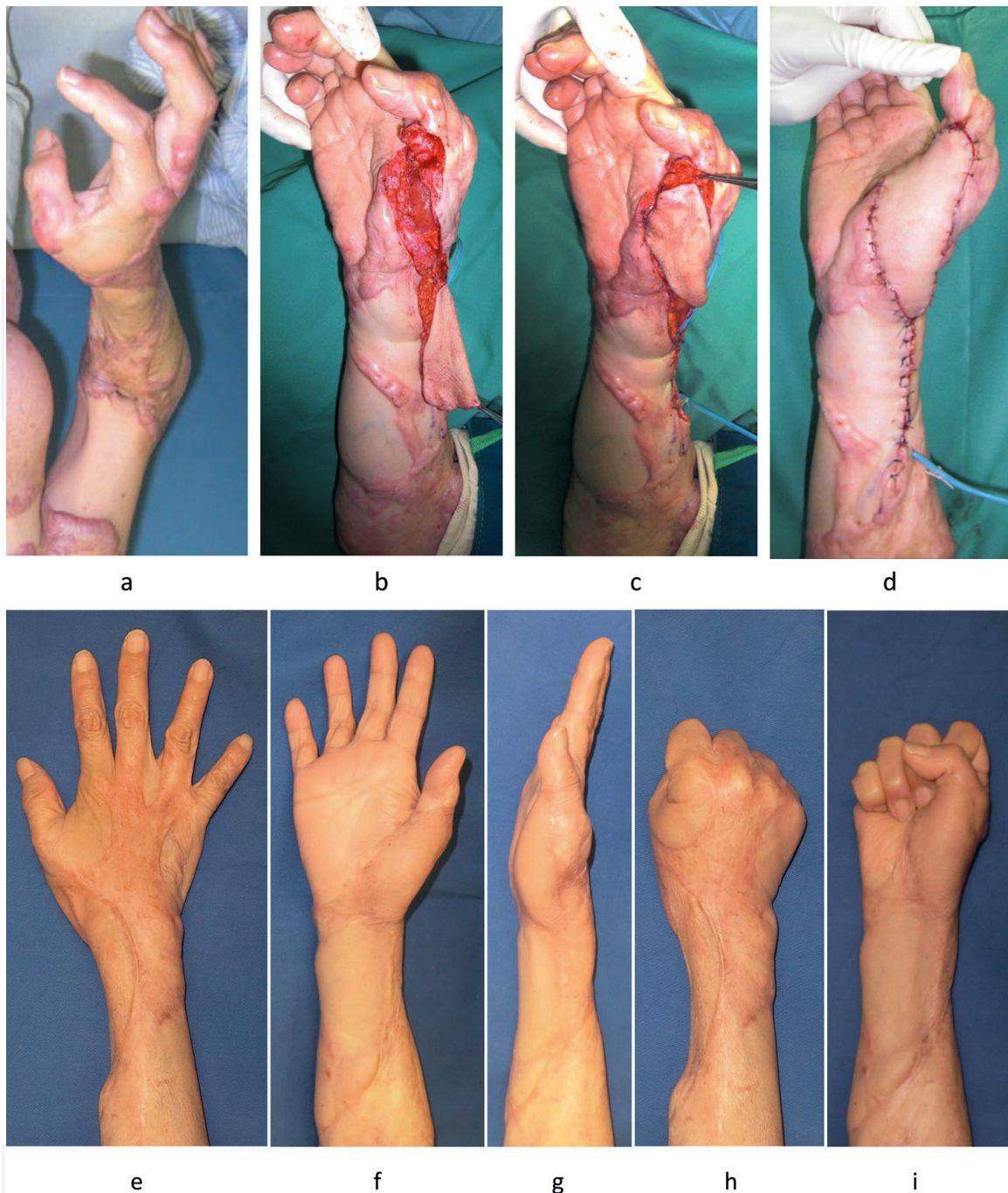


Figure 3.

A patient with an upper limb keloid was effectively treated by surgery and postoperative radiotherapy. (a) Preoperative view. (b) Removal of the hand and wrist keloids and harvest of the flap. (c) Flap rotation. (d) The recipient site immediately after surgery. (e–i) 5 years after the operation. This 63-year-old female had hypertension together with severe keloids of an unknown origin (folliculitis was suspected) that covered her right elbow, wrist joint, and thumb and made it difficult for her to use her right hand. The contractures were released by surgery with a distally based radial forearm flap followed by adjuvant 4-MeV electron beam irradiation therapy (15 Gy/three fractions for 3 days) (the case was cited from the article: Ogawa R, Arima J, Ono S, Hyakusoku H. CASE REPORT Total Management of a Severe Case of Systemic Keloids Associated With High Blood Pressure (Hypertension): Clinical Symptoms of Keloids May Be Aggravated by Hypertension. *Eplasty*. 2013 Jun 3;13:e25).

While these surgical approaches on their own associate with a relatively high risk of recurrence, this risk can be significantly reduced by combining surgery with postoperative radiotherapy and prolonged corticosteroid tape/plaster application. Thus, after the operation, both the donor and recipient sites of the flap should be irradiated to prevent the new formation of keloids. Notably, when partial resection or core extirpation is followed by postoperative radiotherapy, any remaining keloids around the flap (which do not undergo radiotherapy) also improve (**Figure 3**). This

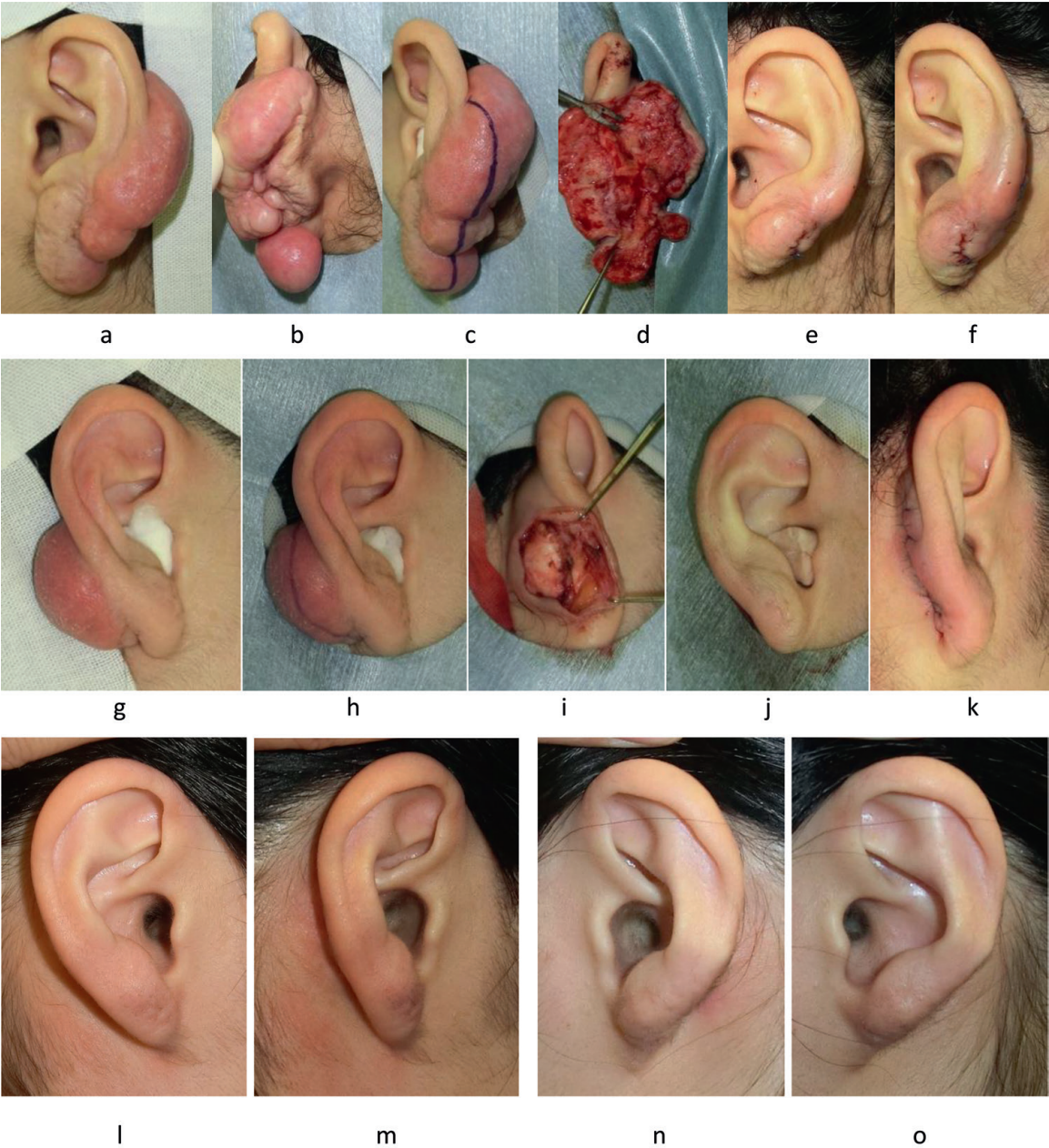


Figure 4.
A patient with bilateral ear keloids was effectively treated by surgery and postoperative radiotherapy. (a, b) Preoperative view of the left ear. (c) Design of the incision on the left ear. (d) Intraoperative view of the left ear. (e, f) The left ear immediately after surgery. (g) Preoperative view of the right ear. (h) Design of the incision on the right ear. (i) Intraoperative view (the right ear). (j, k) The right ear immediately after surgery. (l, m) The right ear 14 months after surgery. (n, o) The left ear 14 months after surgery. A 37-year-old Japanese woman with multiple keloids was diagnosed with multicentric type Castleman's disease. She was treated with systemic administration of steroid for Castleman's disease but the treatment did not improve her keloids. We removed both auricular keloids by using the core excision method. On postoperative days 1, 2, and 3, the patient received a total radiation dose of 15 Gy in three fractions over 3 days. The radiation was delivered by a 4 MeV electron beam. Histopathological examination of the resected tissues showed the absence of abnormal lymphocytes or plasma cell infiltration. Consequently, the auricular lesions were diagnosed definitively as keloids (the case was cited from the article: Quong WL, Kozai Y, Ogawa R. A Case of Keloids Complicated by Castleman's Disease: Interleukin-6 as a Keloid Risk Factor. *Plast Reconstr Surg Glob Open*. 2017 May 16;5(5):e1336).

reflects the fact that the flap releases tension, which in turn decreases the inflammation in the remnant keloids. The high risk of recurrence in these severe cases can be further reduced by the routine application of corticosteroid tape/plasters on the operated area that are changed daily. In general, we recommend patients to use tape/plasters for at least 6 months after the surgery and radiotherapy, or until the scar becomes soft. Long-term follow-up is necessary because if the scars start to stiffen again, corticosteroid tape/plasters should be re-applied. In general, it will

Keloids			
Pediatric patients	Middle-age patients	Elderly patients	Pregnant patients
Treatment at hospital <ul style="list-style-type: none">✓ Surgery and post-operative radiation therapy✓ Surgery and post-operative steroid tape/plaster✓ Steroid injection✓ Radiation monotherapy	Treatment at hospital <ul style="list-style-type: none">✓ Surgery and post-operative radiation therapy✓ Surgery and post-operative steroid tape/plaster✓ Steroid injection✓ Radiation monotherapy	Treatment at hospital <ul style="list-style-type: none">✓ Surgery and post-operative radiation therapy✓ Surgery and post-operative steroid tape/plaster✓ Steroid injection✓ Radiation monotherapy	Treatment at hospital <ul style="list-style-type: none">✓ Surgery and post-operative radiation therapy✓ Surgery and post-operative steroid tape/plaster✓ Steroid injection✓ Radiation monotherapy
Patient self-treatment <ul style="list-style-type: none">✓ Steroid tape/plaster✓ Stabilization/compression therapy	Patient self-treatment <ul style="list-style-type: none">✓ Steroid tape/plaster✓ Stabilization/compression therapy	Patient self-treatment <ul style="list-style-type: none">✓ Steroid tape/plaster✓ Stabilization/compression therapy	Patient self-treatment <ul style="list-style-type: none">✓ Steroid tape/plaster✓ Stabilization/compression therapy

Keloids			
Patients with huge / thick keloids	Patients with small / thin keloids	Patients with multiple keloids	Patients with single keloids
Treatment at hospital <ul style="list-style-type: none">✓ Surgery and post-operative radiation therapy✓ Surgery and post-operative steroid tape/plaster✓ Steroid injection✓ Radiation monotherapy	Treatment at hospital <ul style="list-style-type: none">✓ Surgery and post-operative radiation therapy✓ Surgery and post-operative steroid tape/plaster✓ Steroid injection✓ Radiation monotherapy	Treatment at hospital <ul style="list-style-type: none">✓ Surgery and post-operative radiation therapy✓ Surgery and post-operative steroid tape/plaster✓ Steroid injection✓ Radiation monotherapy	Treatment at hospital <ul style="list-style-type: none">✓ Surgery and post-operative radiation therapy✓ Surgery and post-operative steroid tape/plaster✓ Steroid injection✓ Radiation monotherapy
Patient self-treatment <ul style="list-style-type: none">✓ Steroid tape/plaster✓ Stabilization/compression therapy	Patient self-treatment <ul style="list-style-type: none">✓ Steroid tape/plaster✓ Stabilization/compression therapy	Patient self-treatment <ul style="list-style-type: none">✓ Steroid tape/plaster✓ Stabilization/compression therapy	Patient self-treatment <ul style="list-style-type: none">✓ Steroid tape/plaster✓ Stabilization/compression therapy

Hypertrophic scars		
General Hypertrophic scars	Hypertrophic scars with scar contracture	Recurrent / Intractable Hypertrophic scars
Treatment at hospital <ul style="list-style-type: none">✓ Steroid injection✓ Surgery alone✓ Surgery and post-operative steroid tape/plaster✓ Surgery and post-operative radiation therapy	Treatment at hospital <ul style="list-style-type: none">✓ Steroid injection✓ Surgery alone✓ Surgery and post-operative steroid tape/plaster✓ Surgery and post-operative radiation therapy	Treatment at hospital <ul style="list-style-type: none">✓ Steroid injection✓ Surgery alone✓ Surgery and post-operative steroid tape/plaster✓ Surgery and post-operative radiation therapy
Patient self-treatment <ul style="list-style-type: none">✓ Steroid tape/plaster✓ Stabilization/compression therapy	Patient self-treatment <ul style="list-style-type: none">✓ Steroid tape/plaster✓ Stabilization/compression therapy	Patient self-treatment <ul style="list-style-type: none">✓ Steroid tape/plaster✓ Stabilization/compression therapy

Figure 5. Algorithm for selecting keloid and hypertrophic scar treatment modalities. Particular care should be taken when selecting the treatment for growing children and pregnant women with keloids and hypertrophic scars. In our facility, pediatric patients (<20 years of age) and pregnant women are not treated with radiation. Invasive surgery in pregnant women is also avoided. In these cases, the primary treatment choice should be steroid tape/plaster together with stabilization/compression therapy that reduces the tension on the scar.

take at least 2 years before combination therapy-treated keloids and hypertrophic scars mature. It is important to make clear to the patient before this therapy starts that the protocol has a long duration. Nevertheless, close monitoring and assiduous re-application of steroid tape/plasters have an excellent chance of converting postoperative keloid sites into mature scars.

It should be noted that our combination therapy is not suitable for growing children and pregnant women. In our facility, we do not treat pediatric patients (<20 years of age) or pregnant women with radiation. Moreover, invasive treatments such as surgery are not performed during pregnancy. The primary choice of treatment for children and pregnant women with keloids and hypertrophic scars should be steroid tape/plaster on its own (**Figure 5**).

Author details

Rei Ogawa
Department of Plastic, Reconstructive and Aesthetic Surgery, Nippon Medical
School Hospital, Tokyo, Japan

*Address all correspondence to: r.ogawa@nms.ac.jp

IntechOpen

© 2019 The Author(s). Licensee IntechOpen. This chapter is distributed under the terms of the Creative Commons Attribution License (<http://creativecommons.org/licenses/by/3.0>), which permits unrestricted use, distribution, and reproduction in any medium, provided the original work is properly cited. 

References

- [1] Ogawa R. Keloid and hypertrophic scars are the result of chronic inflammation in the reticular dermis. *International Journal of Molecular Sciences*. 2017;**18**(3):E606
- [2] Huang C, Murphy GF, Akaishi S, Ogawa R. Keloids and hypertrophic scars: Update and future directions. *Plastic and Reconstructive Surgery*. Global Open. 2013;**1**(4):e25
- [3] Nakashima M, Chung S, Takahashi A, Kamatani N, Kawaguchi T, Tsunoda T, et al. A genome-wide association study identifies four susceptibility loci for keloid in the Japanese population. *Nature Genetics*. 2010;**42**(9):768-771
- [4] Ogawa R, Watanabe A, Than Naing B, Sasaki M, Fujita A, Akaishi S, et al. Associations between keloid severity and single-nucleotide polymorphisms: Importance of rs8032158 as a biomarker of keloid severity. *The Journal of Investigative Dermatology*. 2014;**134**(7):2041-2043
- [5] Moustafa MF, Abdel-Fattah MA, Abdel-Fattah DC. Presumptive evidence of the effect of pregnancy estrogens on keloid growth. Case report. *Plastic and Reconstructive Surgery*. 1975;**56**(4):450-453
- [6] Mendelsohn ME, Karas RH. Estrogen and the blood vessel wall. *Current Opinion in Cardiology*. 1994;**9**(5):619-626
- [7] Arima J, Huang C, Rosner B, Akaishi S, Ogawa R. Hypertension: A systemic key to understanding local keloid severity. *Wound Repair and Regeneration*. 2015;**23**(2):213-221
- [8] Huang C, Ogawa R. The link between hypertension and pathological scarring: Does hypertension cause or promote keloid and hypertrophic scar pathogenesis? *Wound Repair and Regeneration*. 2014;**22**(4):462-466
- [9] Ogawa R, Okai K, Tokumura F, Mori K, Ohmori Y, Huang C, et al. The relationship between skin stretching/contraction and pathologic scarring: The important role of mechanical forces in keloid generation. *Wound Repair and Regeneration*. 2012;**20**(2):149-157
- [10] Ogawa R, Akaishi S, Huang C, Dohi T, Aoki M, Omori Y, et al. Clinical applications of basic research that shows reducing skin tension could prevent and treat abnormal scarring: The importance of fascial/subcutaneous tensile reduction sutures and flap surgery for keloid and hypertrophic scar reconstruction. *Journal of Nippon Medical School*. 2011;**78**(2):68-76
- [11] Akaishi S, Akimoto M, Ogawa R, Hyakusoku H. The relationship between keloid growth pattern and stretching tension: Visual analysis using the finite element method. *Annals of Plastic Surgery*. 2008;**60**(4):445-451
- [12] Yoshino Y, Kubomura K, Ueda H, Tsuge T, Ogawa R. Extension of flaps associated with burn scar reconstruction: A key difference between island and skin-pedicled flaps. *Burns*. 2018;**44**(3):683-691
- [13] Ogawa R. The most current algorithms for the treatment and prevention of hypertrophic scars and keloids. *Plastic and Reconstructive Surgery*. 2010;**125**(2):557-568
- [14] Norris JE. Superficial x-ray therapy in keloid management: A retrospective study of 24 cases and literature review. *Plastic and Reconstructive Surgery*. 1995;**95**(6):1051-1055
- [15] Enhamre A, Hammar H. Treatment of keloids with excision and postoperative X-ray irradiation. *Dermatologica*. 1983;**167**(2):90-93
- [16] Guix B, Henríquez I, Andrés A, Finestres F, Tello JI, Martínez A.

Treatment of keloids by high-dose-rate brachytherapy: A seven-year study. International Journal of Radiation Oncology, Biology, Physics. 2001;**50**(1, 1): 167-172

[17] Kuribayashi S, Miyashita T, Ozawa Y, Iwano M, Ogawa R, Akaishi S, et al. Post-keloidectomy irradiation using high-dose-rate superficial brachytherapy. Journal of Radiation Research. 2011;**52**(3):365-368

[18] Ogawa R, Miyashita T, Hyakusoku H, Akaishi S, Kuribayashi S, Tatenos A. Postoperative radiation protocol for keloids and hypertrophic scars: Statistical analysis of 370 sites followed for over 18 months. Annals of Plastic Surgery. 2007;**59**(6):688-691

[19] Ogawa R, Mitsuhashi K, Hyakusoku H, Miyashita T. Postoperative electron-beam irradiation therapy for keloids and hypertrophic scars: Retrospective study of 147 cases followed for more than 18 months. Plastic and Reconstructive Surgery. 2003;**111**(2):547-553

[20] Lo TC, Seckel BR, Salzman FA, Wright KA. Single-dose electron beam irradiation in treatment and prevention of keloids and hypertrophic scars. Radiotherapy and Oncology. 1990;**19**(3):267-272

[21] Flickinger JC. A radiobiological analysis of multicenter data for postoperative keloid radiotherapy. International Journal of Radiation Oncology, Biology, Physics. 2011;**79**(4):1164-1170

[22] Goutos I, Ogawa R. Steroid tape: A promising adjunct to scar management. Scars, Burns & Healing. 2017;**3**:2059513117690937