

We are IntechOpen, the world's leading publisher of Open Access books Built by scientists, for scientists

6,900

Open access books available

186,000

International authors and editors

200M

Downloads

Our authors are among the

154

Countries delivered to

TOP 1%

most cited scientists

12.2%

Contributors from top 500 universities



WEB OF SCIENCE™

Selection of our books indexed in the Book Citation Index
in Web of Science™ Core Collection (BKCI)

Interested in publishing with us?
Contact book.department@intechopen.com

Numbers displayed above are based on latest data collected.
For more information visit www.intechopen.com



Hydrops Fetalis

Renuka Sekar

Abstract

The abnormal accumulation of fluid in two or more fetal space and in some cases is associated with placental edema and polyhydramnios. This can be seen in all trimesters. It is classified as immune and nonimmune fetal hydrops. Immune hydrops fetalis-rhesus alloimmunization and other blood group antibodies cause hemolytic disease of the newborn. Nonimmune hydrops fetalis can be largely divided as fetal, maternal, placental and idiopathic. Pathophysiology, investigations, treatment and counseling are outlined.

Keywords: fetal hydrops, hydrops fetalis, immune hydrops, nonimmune fetal hydrops, pathophysiology

1. Introduction

Hydrops fetalis or fetal hydrops is an abnormal fluid collection in two or more fetal compartments. This includes skin edema (>5 mm), ascites, pleural, and pericardial effusion. In some, this may be associated with the placental edema (placental thickness > 4 cm in the second trimester and >6 mm in the third trimester) [1] and polyhydramnios [2].

Hydrops fetalis is a serious fetal condition usually identified by ultrasound examination. Very rarely, subtle collection of fluid may be missed on ultrasound scan. Historically, hydrops fetalis was due to rhesus alloimmunisation, especially prior to prophylactic anti-D administration in the developed countries, although this may not be the case in many developing countries.

1.1 Terminologies

Hydrops fetalis is the abnormal accumulation of fluid within the fetal skin, abdomen, pleural space, and or pericardium [1, 3].

Edema/anasarca is the term for fluid accumulation in the subcutaneous tissues of the skin.

Excess fluid accumulation within the peritoneal cavity is frequently referred to as ascites.

1.2 Epidemiology

The precise incidence of hydrops fetalis is difficult as some cases spontaneously resolve or diagnosis is not seen until fetal demise or miscarriage. The overall incidence of fetal hydrops reported in the literature is between 1 in 1500 and 1 in 3000 pregnancies [4].

With the advent of anti-D immunoglobulin, the incidence and mortality due to immune hydrops fetalis have reduced with an increase in nonimmune fetal hydrops in about 90% of cases [5–8].

The diagnosis of hydrops fetalis is usually made antenatally and is a challenging condition to counsel and is usually a preterminal manifestation of many different pathophysiological conditions.

A recent publication from a single centre in Australia showed that the overall survival from diagnosis was 27%. The perinatal mortality risk is high when infants are born with hydrops fetalis and is dependent on the underlying diagnosis.

2. Classification

Hydrops fetalis is broadly classified into immune and nonimmune.

2.1 Immune fetal hydrops

Immune hydrops fetalis is due to red cell antibodies. There are many red cell antibodies of which rhesus D, c, and E are the commonest. The incidence of Rh D antibodies is reducing secondary due to the widespread use of anti-D at least in the developed countries. There appears to be an increase in other red cell antibodies that are now commonly associated with immune hydrops fetalis that can cause hemolytic disease of the newborn. These are kell antibodies, Duffy, and other red cell antibodies. Lewis and p antibodies rarely cause hemolytic disease of the newborn. The mechanism of fetal hydrops is secondary to fetal anemia. Fetal anemia is due to direct red cell destruction by the red cell antibodies that cross the placenta, especially if the baby has a different blood group and type to the mother. Anemia causes high output cardiac failure and fetal hydrops.

In the Caucasian population, about 85% are rhesus (Rh) positive, which leaves about 15% Rh negative. When the mother is Rh negative and has never been sensitized before (no previous pregnancy, miscarriage, termination of pregnancy, or ectopic pregnancy), the sensitization event happens with the first pregnancy if the partner is positive. A sensitization event can happen spontaneously during pregnancy (feto maternal hemorrhage) and in labour or during an event such as maternal trauma, abruption, invasive procedures, antepartum hemorrhage, and external cephalic version. During these events, anti-D must be administered in Rh-negative women with an Rh positive partner. When possible, partner testing for both phenotype and genotype of his blood group must be requested. Currently, the widespread use of free fetal DNA in the detection of fetal D gene is helpful in identifying the Rh status of the fetus from maternal blood sample performed after 10 weeks of gestation. Amniocentesis can be performed to assess the fetal Rh D status as well; this will again increase the sensitization during pregnancy.

Hydrops fetalis that develop in the absence of red cell hemolysis is termed as nonimmune fetal hydrops (NIFH) and was first described by Dr. Potter in 1943. The reported incidence of nonimmune fetal hydrops (NIFH) is 1 in 2000–3000 pregnancies [4, 5]. These result in about 3% of perinatal mortality and 50% diagnosed in utero will result in fetal demise and 50% of live born will not survive the neonatal period.

2.2 Nonimmune fetal hydrops (NIFH)

There are many causes for nonimmune fetal hydrops. In the past, many were thought to be idiopathic. Recent literature review shows that a cause can be identified prenatally in 65% of cases and up to 85% postnatally [9]. They are broadly divided as maternal, fetal, placental, and idiopathic causes.

2.2.1 Maternal

Hemoglobinopathies (both alpha and beta thalassemia) are caused especially when both parents are carriers. Alpha thalassemia can cause severe fetal hydrops early in pregnancy, especially Barts [10] hemoglobinopathy (4 gene deletion)—hemolysis is the cause of fetal hydrops, fetomaternal hemorrhage (abruption), and maternal hemolytic anemia.

Infection—some maternal infections can cause fetal infection and affect neural development, e.g., cytomegalovirus, toxoplasmosis, parvovirus [11] (erythrocytic), syphilis, and Zika virus.

Maternal antibodies—anti-Ro and La antibodies can be positive in mothers with autoimmune disorders such as systemic lupus erythematosus, rheumatoid arthritis. These mothers are tested for other antibodies including antiphospholipid and extractable nuclear antibodies (Ro and La). These antibodies cross the placenta and in 6% of cases can cause congenital heart block in the fetus as they affect the purkinje fibers of the heart. With a very low heart rate, the fetus is at increased risk of developing hydrops [12, 13] (low cardiac output and heart failure).

Neonatal alloimmune thrombocytopenia and idiopathic thrombocytopenia—in neonatal alloimmune thrombocytopenia (NAIT), due to incompatible platelet antibodies (human platelet antibody A1A and 5A) between maternal and paternal platelets, there is production of antibodies against maternal platelets. The risk of neonatal thrombocytopenia is very high, 85–100%. These IgG antibodies cross the placenta and destroy fetal platelets causing anemia and fetal hydrops. Unlike rhesus alloimmunisation where the first pregnancy is less likely to be affected when there was no preceding sensitizing event, NAIT affects the first pregnancy (diagnosis is made after the affected pregnancy) and increases the risk for subsequent pregnancies.

When there is maternal idiopathic thrombocytopenia, the risk of fetal thrombocytopenia is low 1–2%, fetal monitoring is recommended both antenatally and intrapartum. The risk of fetal thrombocytopenia is high when maternal platelets fall below 20×10^6 .

2.2.2 Placental

Placental chorioangiomas are tumors of the placenta and is usually a pathological diagnosis. When the size of the chorioangiomas is over 5 cms and the cord insertion is close to the chorioangioma, there is an increased vascular turbulence leading to microangiopathic anemia leading to fetal hydrops and polyhydramnios.

Monochorionic twin pregnancies—especially in 15% of monochorionic diamniotic twin gestations, there is unbalanced vascular communication between the twins leading to unbalanced transfusion where one of the twins can be hydropic (recipient) or polycythemic, while the other can be anemic. Untreated twin-to-twin transfusion [14] leads to fetal hydrops in the recipient and fetal demise in one twin, which can in turn result in the death of the other twin as well.

2.2.3 Fetal

There are many fetal conditions that can give rise to fetal hydrops, which can be broadly classified as:

1. chromosomal—trisomy and 45XO (Turner's syndrome) [15]
2. structural

- fetal tumors of the face (epignathus) and neck
- cardiac (cardiomyopathies, tumors-rhabdomyomas, myocarditis, and abnormal fetal heart rates such as both fetal tachy and bradyarrhythmias)
- thoracic—pulmonary airway malformations [16] (microcystic or macrocystic) especially with mediastinal shift, bronchopulmonary sequestration, congenital hyperinflation obstructive airway syndrome, and primary lymphatic anomaly
- congenital diaphragmatic hernias—especially with mediastinal shift
- abdomen—tumors or large cysts in fetal abdomen, bowel dilatation, or obstruction/volvulus, meconium peritonitis
- sacrococcygeal teratomas—these tumors cause anemia secondary to high-output cardiac failure
- dental hemangiomas, arteriovenous malformations (AVM's), absent ductus venosus, and umbilical cord varix
- skeletal dysplasias
- cystic hygromas and lymphatic obstruction

3. fetal infections

- toxoplasma, rubella, cytomegalovirus, herpes virus, syphilis, and parvovirus are the common fetal infections. Parvovirus is highly erythrogenic, and the resulting fetal anemia is due to failed erythropoiesis. There is an estimated 1–2% risk of seroconversion in pregnancy that increases to 10% during epidemics. There is still a fetal loss rate of 3–10% depending on gestational age of exposure

4. hematological—secondary to congenital leukemia or red cell erythrogenic abnormalities (Blackfan-Diamond syndrome and congenital dyserythropoiesis)

5. fetal metabolic abnormalities, most of them are autosomal recessive—G6PD deficiencies

6. fetal genetic or neurologic syndromes

7. miscellaneous—severe fetal growth restriction, fetal akinesia, or hypomobility syndromes

8. idiopathic—30–50% of fetal hydrops

Fetal tachyarrhythmia includes supraventricular tachycardia, fetal atrial fibrillation, or flutter. In total, 90% of fetal tachyarrhythmia is due to fetal supraventricular tachyarrhythmia. Atrial flutter (FHR > 300 bpm) and fibrillation are less common. When fetal heart rates are above 220 bpm, there is reduced diastolic filling with reduced ejection fraction and cardiac output. This in turn results in poor perfusion, reduced oxygenation, and elevated CVP and hepatic congestion. The risk of fetal hydrops is inversely related to gestational age, and this could be related to immaturity of fetal myocardium [17].

Fetal bradyarrhythmias are due to congenital heart block, and fetal hydrops is secondary to low cardiac output and inadequate oxygen perfusion and also to venous congestion. The risk is higher when FHR is less than 95 bpm and often when <65 bpm.

Congenital structural anomalies of the heart may predispose to high output failure and may be associated with other chromosomal or structural anomalies [18].

Heritable hemoglobinopathies are usually autosomal recessive, and testing for this is done either pre or antenatally. Fetal anemia causes high output cardiac failure and increased central venous pressure, leading to fetal hydrops. Antiplatelet antibodies cross the placenta and destroy fetal platelets similar to rhesus alloimmunisation, resulting in fetal anemia and hydrops.

Fetal infection that crosses the placenta usually causes myocarditis, suppresses erythropoiesis, causes hemolysis, and hepatitis. Examples of fetal infection are toxoplasma, cytomegalovirus, rubella, herpes virus, syphilis, parvovirus and others include coxsackie virus, *Listeria monocytogenes*.

Hydrops fetalis is associated with more than 75 inborn errors of metabolism, genetic syndromes, and chromosomal abnormalities. The inheritance is usually autosomal recessive with some conditions that could be X linked.

Cystic hygromas are usually associated with aberration in lymphatic drainage. They are usually seen as cystic spaces in the fetal neck, but can also be seen in fetal thorax or abdomen. These findings can be associated with 45XO (Turner's syndrome) [6] and are usually seen in aborted fetuses. There are some cases of spontaneous resolution of cystic hygromas, but prognosis is usually poor (90–95% mortality) especially when associated with hydrops fetalis even with normal karyotype. The differential diagnoses include Noonan syndrome and multiple pterygium syndrome.

Thoracic and abdominal tumors, by way of their size and location, obstruct both venous and lymphatic return to the fetal heart, causing fetal hydrops.

In some tumors such as sacrococcygeal teratomas [19] or chorioangiomas, the resulting fetal hydrops is not only due to the size of the tumor but also due to the increased vascularity in them behaving like an arteriovenous malformation, leading to high output cardiac failure, and microangiopathic fetal anemia.

Isolated pleural effusion, unilateral or bilateral, is seen without progression to fetal hydrops, especially with abnormal lymphatic development [20].

3. Pathophysiology

There have been many hypotheses for fetal hydrops. Distribution of body water is between the intracellular (blood and tissues) and extracellular (plasma, interstitial space, and transcellular) space.

The basic mechanism is an abnormal fluid movement between plasma and tissues and the imbalance between the interstitial production and lymphatic return [21].

Four main theories have been postulated:

1. heart failure or obstruction to venous return causes increase in hydrostatic capillary pressure,
2. hepatic congestion causing reduced production of albumin causing reduced plasma oncotic pressure,
3. lymphatic flow obstruction,
4. damage to peripheral capillary integrity.

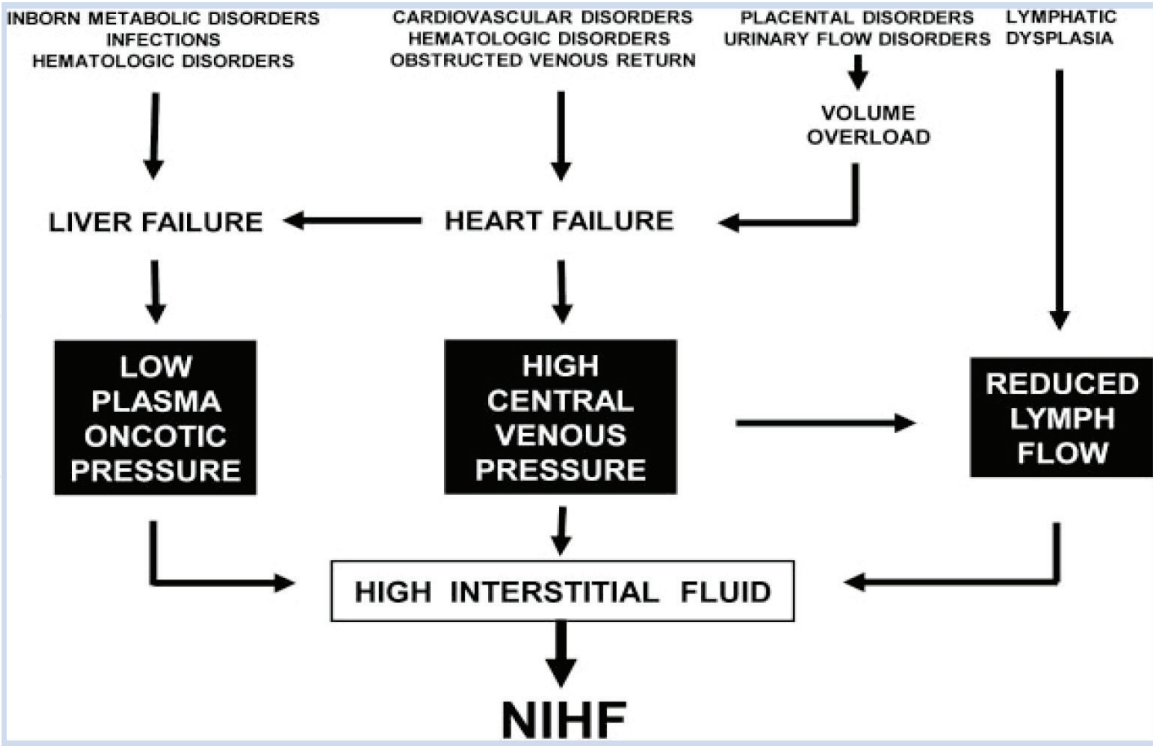


Figure 1.
Flow chart of possible pathophysiology in NIFH [6].

Fluid accumulation may be due to congestive cardiac failure, obstruction to the lymphatic flow, or reduced oncotic pressure. The fetus has greater capillary permeability and an interstitial compartment that can accommodate extra fluid.

When there is fetal hypoxia, there is redistribution to the vital organs such as brain, heart, and adrenals. There is reduced blood flow to fetal kidneys and gut. The reduced renal blood flow activates the renin angiotensin system (RAS) to enhance cardiac output. This also increases the venous pressure and thereby increases in interstitial fluid accumulation.

Due to reduced hepatic blood flow and increase in extramedullary hematopoiesis, there is reduction in albumin production causing hypoalbuminemia, thereby reducing the oncotic pressure and causing fluid shift. Many animal models have been studied in order to understand hydrops. The largest systematic review by Bellini et al. [6] also illustrated the possible pathophysiological causes of NIFH (**Figure 1**).

With fetal hydrops, there is a risk of maternal mirror syndrome (Ballantyne’s syndrome) in some patients, where the mother develops edema similar to the hydropic fetus.

Mirror syndrome represents a form of preeclampsia characterized by edema (90%), high blood pressure (60%), and proteinuria (40%) of cases [22–25]. The incidence is unclear and may not be reported. Review of literature shows a maternal mortality of about 20% secondary to pulmonary edema. With treatment for fetal hydrops, maternal symptoms have noted to resolve.

The imbalance between the angiogenic and antiangiogenic factors that are implicated in severe preeclampsia is also thought to be the underlying pathogenesis of this condition. When the underlying NIFH cannot be treated and when there are ongoing symptoms of maternal mirror syndrome, delivery is indicated.

4. Investigations

Maternal blood tests—the first line of investigation would be to rule out immune hydrops fetalis.

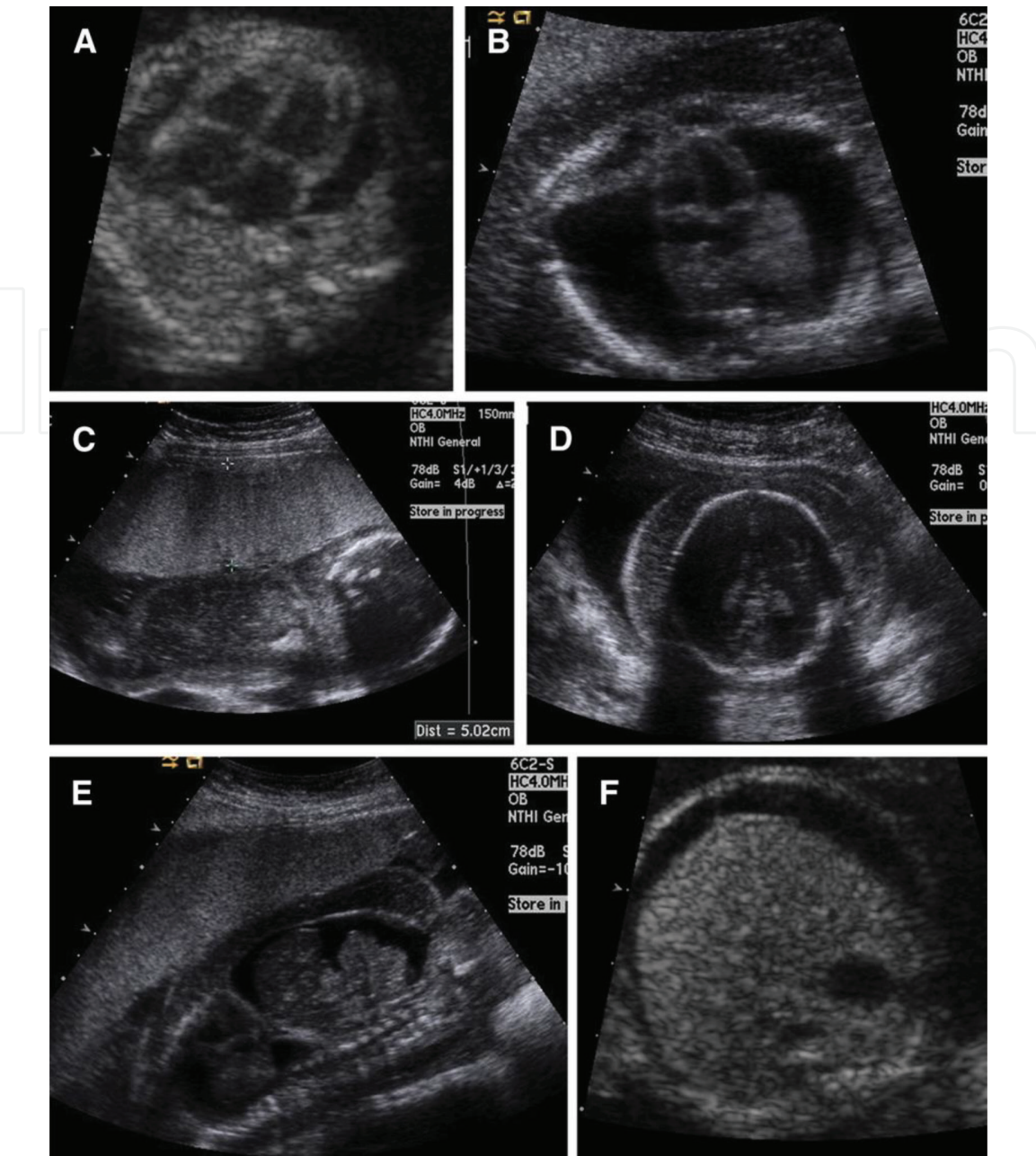


Figure 2.
Ultrasound findings fetal hydrops [1]. (A) Pericardial effusions, (B) pleural effusions; note: midline heart anterior to small lungs with bilateral effusions, (C) placental thickening, with placenta measuring >4 mm in thickness, (D) skin thickening at level of fetal skull, (E) ascites, sagittal, with free-floating loops of bowel surrounded by ascites, and (F) ascites in upper abdomen, at level of fetal liver and stomach [1].

Maternal rhesus status, antibodies, full blood count, Kleihauer-Betke test, and indirect Coombs test are requested.

The other blood tests are for nonimmune hydrops fetalis.

Hemoglobin electrophoresis is requested to rule out thalassemia, both alpha and beta. This screen is especially important in Mediterranean, Indian, and Asian ethnic groups.

TORCHS+P serology (toxoplasma, rubella, cytomegalovirus, herpes, syphilis, and parvovirus).

If fetal heart rate is lower than 100 bpm, anti-Ro and La antibodies to be requested.

Maternal serum electrolytes and liver function tests, including urinary PCR, are recommended to rule out maternal mirror syndrome. When fetal hydrops is associated with abnormal placenta, triploidy or partial molar pregnancy cannot be ruled out; hence, serum beta-HCG and thyroid function tests are performed in this situation.

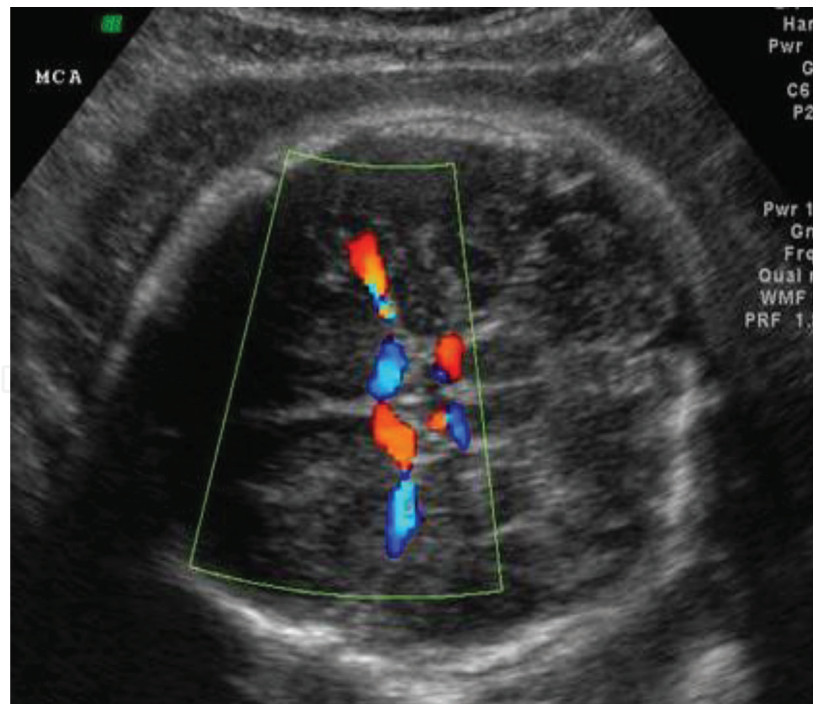


Figure 3.
Transverse section of fetal head showing middle cerebral artery—Google images.

A detailed tertiary ultrasound of the fetus/fetuses is recommended including amniotic fluid volume and Doppler studies looking for fetal anemia.

Fetal tertiary ultrasound is the key to diagnose most of the above-mentioned fetal structural abnormalities. A thorough assessment including fetal weight, morphology, amniotic fluid volume, and placental morphology are recommended.

Fetal heart rate documentation is vital to rule out both tachy and brady arrhythmias.

Fetal dopplers including umbilical artery, vein, ductus venosus, tricuspid regurgitation, and middle cerebral artery peak systolic velocity (MCA PSV) measurements are very helpful in the investigation of hydrops fetalis.

The middle cerebral artery Doppler known as MCA peak systolic velocity is a good noninvasive measure of fetal anemia. With fetal anemia and possible hypoxia, velocity of blood flow to the fetal brain increases. When the MCA PSV is above 1.5 multiples of the median (MoM), there is a high risk of fetal anemia. The false-positive rate of this measurement is around 10% and increases after 35 weeks of gestation (**Figures 2 and 3**).

Invasive testing such as amniocentesis and amniodrainage [26] is discussed and performed under ultrasound guidance. Maternal rhesus status is checked so that the patient is given anti-D when not sensitized.

The amniotic fluid is sent for chromosome tests—fluorescent in situ hybridization (FISH), chromosomal microarray, rasopathy, or hydrops panel including Noonan's syndrome, lysosomal storage disease and in some centres whole exome sequencing. Polymerase chain reaction (PCR) from the amniotic fluid is sent for fetal infection such as TORCHS+parvovirus' DNA for specific conditions if known.

When there is evidence of fetal pleural effusion, either a pleural tap or insertion of a pleuroamniotic shunt is inserted to drain the pleural effusion/effusions [27]. The sample is also sent for lymphocytes apart from infection and karyotype.

The presence of fetal sacrococcygeal teratoma is confirmed, and fetal magnetic resonance imaging (MRI) may be required to identify the intrapelvic extension.

5. Management of NIFH

Transfer to maternal and fetal medicine unit is recommended. The outcome for most cases of NIFH is poor unless there is a treatable cause. Women are not only extensively counseled [28] regarding outcomes with NIFH, but also for risks such as polyhydramnios (29%) and preterm labour (66%). When there is an ongoing maternal symptom with severe polyhydramnios, amniodrainage is recommended.

The outcome usually falls into

1. Treatable cause of NIFH—fetal tachyarrhythmia's (antiarrhythmic medications), fetal anemia secondary to parvovirus B19 infection (in utero fetal transfusion), large macrocystic congenital pulmonary airway malformation (CPAM) (shunt or antenatal corticosteroids), twin-twin transfusion syndrome (TTTS) (laser photocoagulation), and twin-reversed arterial perfusion (TRAP) (selective radiofrequency ablation), fetal sacrococcygeal teratoma's with an identified fetal vessel may benefit from radiofrequency or laser ablation.
2. Lethal prognosis—termination of pregnancy or palliative care should be offered.
3. Idiopathic—with uncertain to poor prognosis.

When NIFH is identified before viability with no identifiable cause, pregnancy termination should be discussed and offered. Termination of pregnancy should be considered when associated with maternal complications such as maternal mirror syndrome. Antepartum surveillance is usually recommended depending on gestational age at diagnosis and the underlying cause of NIFH. Once the underlying cause of fetal hydrops is treated, ongoing surveillance is important to plan delivery. Mode of delivery depends on underlying etiology, gestational age, and maternal well-being. Vaginal delivery is considered when there is a lethal condition with no fetal monitoring. Cesarean delivery is recommended in all other conditions. When there is moderate to severe pleural effusion, drainage prior to delivery may help in the neonatal period. Elective preterm delivery is not recommended unless indicated, as this does not improve neonatal outcomes.

In a recent review of a 12-year retrospective cohort from a single centre [9], the overall survival from diagnosis was 27% increasing to 55% if born alive.

The long-term prognosis of survivors of NIFH also depends on underlying etiology. Following parvovirus B19 infection with fetal anemia and transfusion, there appears to be some neurological sequelae in about 30% of babies [29]. This could be a direct consequence of parvovirus infection with fetal anemia or transfusion.

Fetuses with supraventricular tachycardia, some babies may develop Wolf Parkinson White syndrome later in life [30].

6. Conclusion

Ultrasound is the diagnostic tool for antenatal diagnosis of hydrops fetalis including all fetal Doppler studies. A detailed history and examination of the mother is very important. Serological testing for perinatal fetal infections and maternal antibodies helps in the workup of fetal hydrops. Tertiary referral to a maternal and fetal medicine unit is highly recommended. Outcome for babies with no antenatal diagnosis is very guarded to poor with increased neonatal morbidity and mortality.

IntechOpen

IntechOpen

Author details

Renuka Sekar

Royal Brisbane and Women's Hospital Brisbane, Queensland, Australia

*Address all correspondence to: renuka.sekar@health.qld.gov.au

IntechOpen

© 2019 The Author(s). Licensee IntechOpen. This chapter is distributed under the terms of the Creative Commons Attribution License (<http://creativecommons.org/licenses/by/3.0>), which permits unrestricted use, distribution, and reproduction in any medium, provided the original work is properly cited. 

References

- [1] Norton ME, Chauhan SP, Dashe JS, Society for Maternal-Fetal Medicine (SMFM). Society for maternal-fetal medicine (SMFM) clinical guideline #7: Nonimmune hydrops fetalis. *American Journal of Obstetrics and Gynecology*. 2015;**212**:127-139
- [2] Skoll MA, Sharland GK, Allan LD. Is the ultrasound definition of fluid collections in non-immune hydrops fetalis helpful in defining the underlying cause or predicting outcome? *Ultrasound in Obstetrics & Gynecology*. 1991;**1**:309-312
- [3] Désilets V, Audibert F, Society of Obstetrician and Gynaecologists of Canada. Investigation and management of non-immune fetal hydrops. *Journal of Obstetrics and Gynaecology Canada*. 2013;**35**:923-936
- [4] Hutchison AA, Drew JH, Yu VY, et al. Nonimmunologic hydrops fetalis: A review of 61 cases. *Obstetrics and Gynecology*. 1982;**59**:347-352
- [5] Graves GR, Baskett TF. Nonimmune hydrops fetalis: Antenatal diagnosis and management. *American Journal of Obstetrics and Gynecology*. 1984;**148**:563-565
- [6] Bellini C, Hennekam RC, Fulcheri E, et al. Etiology of nonimmune hydrops fetalis: A systematic review. *American Journal of Medical Genetics Part A*. 2009;**149A**:844-851
- [7] Steurer MA, Peyvandi S, Baer RJ, et al. Epidemiology of live born infants with nonimmune hydrops fetalis- insights from a population-based dataset. *The Journal of Pediatrics*. 2017;**1**(87):182-188
- [8] Pasman SA, Oepkes D, et al. Hypoalbuminemia: A cause of fetal hydrops? *American Journal of Obstetrics and Gynecology*. 2006;**194**(4):972-975
- [9] Gilby DM et al. Outcomes following antenatal identification of hydrops fetalis: A single-center experience from 2001 to 2002. *Archives of Disease in Childhood-Fetal and Neonatal Edition*. 2018;**0**:F1-F6
- [10] Jomoui W, Sanchaisuriya K, et al. Genetic origin of $\alpha 0$ -thalassemia (SEA deletion) in Southeast Asian populations and application to accurate prenatal diagnosis of Hb Bart's hydrops fetalis syndrome. *Journal of Human Genetics*. 2017;**62**(8):747-754
- [11] Onroy A et al. Parvovirus B10 infection during pregnancy and risks to the fetus. *Birth Defects Research*. 2017;**109**(5):311-323
- [12] Friedman DM et al. Prospective evaluation of fetuses with autoimmune associated congenital heart block followed in the PR interval and dexamethasone evaluation study (PRIDE) study. *The American Journal of Cardiology*. 2009;**103**:1102-1106
- [13] Ciardulli A et al. Maternal steroid therapy for fetuses with immune-mediated complete atrioventricular block: A systematic review and meta-analysis. *The Journal of Maternal-Fetal & Neonatal Medicine*. 2017:1419182
- [14] Van Den Wijngaard JP et al. Twin to twin transfusion syndrome modeling. *Annals of the New York Academy of Sciences*. 2017;**1101**:215-234
- [15] Alpman A et al. Prenatally diagnosed turner syndrome and cystic hygroma: Incidence and reasons for referrals. *Fetal Diagnosis and Therapy*. 2009;**25**:58-61
- [16] Lee FL et al. Treatment of congenital pulmonary airway malformation induced hydrops fetalis via percutaneous sclerotherapy. *Fetal Diagnosis and Therapy*. 2012;**31**(4):264-268

- [17] Moodley S et al. Postnatal outcome in patients with fetal tachycardia. *Pediatric Cardiology*. 2013;**34**:81-87
- [18] Yuan SM. Cardiac etiologies of hydrops fetalis. *Zeitschrift für Geburtshilfe und Neonatologie*. 2017;**221**(2):67-72
- [19] Van Mieghem T. Minimally invasive therapy for fetal sacrococcygeal teratoma: Case series and systematic review of the literature. *Ultrasound in Obstetrics & Gynecology*. 2014;**43**(6):611-619
- [20] Williams IA et al. Is hydrops fetalis a manifestation of pulmonary edema caused by impaired lymphatic drainage? *Ultrasound in Obstetrics & Gynecology*. 2018;**31**(1):96-99
- [21] Bellini C, Hennekam RC. Non-immune hydrops fetalis: A short review of etiology and pathophysiology. *American Journal of Medical Genetics Part A*. 2012;**158A**:597
- [22] Braun T et al. Mirror syndrome: A systematic review of fetal associated conditions, maternal presentation and perinatal outcome. *Fetal Diagnosis and Therapy*. 2010;**27**:191-203
- [23] Gedikbasi A et al. Preeclampsia due to fetal non-immune hydrops: Mirror syndrome and review of literature. *Hypertension in Pregnancy*. 2011;**30**:322-330
- [24] Goa S et al. Normalization of angiogenic imbalance after intra-uterine transfusion for mirror syndrome caused by parvovirus B19. *Fetal Diagnosis and Therapy*. 2013;**34**:176-179
- [25] Llurba E et al. Angiogenic and antiangiogenic factors before and after resolution of maternal mirror syndrome. *Ultrasound in Obstetrics & Gynecology*. 2012;**40**:367-369
- [26] Sandlin AT et al. Clinical relevance of sonographically estimated amniotic fluid volume: Polyhydramnios. *Journal of Ultrasound in Medicine*. 2013;**32**:851-863
- [27] Nakayama A et al. The prognostic factors of hydrops fetalis with pleural effusion. *Pediatrics International*. 2017;**59**(10):1053-1057
- [28] Santo S, Thilaganathan B, et al. Prenatal diagnosis of non-immune hydrops fetalis: What do we tell the parents? *Prenatal Diagnosis*. 2011;**31**(2):186-195
- [29] Nassr AA et al. Outcome and treatment of antenatally diagnosed nonimmune hydrops fetalis. *Fetal Diagnosis and Therapy*. 2018;**43**(2):123-128
- [30] Hahurij ND et al. Perinatal management and long-term cardiac outcome in fetal arrhythmia. *Early Human Development*. 2011;**87**:83-87