

# We are IntechOpen, the world's leading publisher of Open Access books Built by scientists, for scientists

6,900

Open access books available

186,000

International authors and editors

200M

Downloads

Our authors are among the

154

Countries delivered to

TOP 1%

most cited scientists

12.2%

Contributors from top 500 universities



WEB OF SCIENCE™

Selection of our books indexed in the Book Citation Index  
in Web of Science™ Core Collection (BKCI)

Interested in publishing with us?  
Contact [book.department@intechopen.com](mailto:book.department@intechopen.com)

Numbers displayed above are based on latest data collected.  
For more information visit [www.intechopen.com](http://www.intechopen.com)



# The Specificities of Electrical Burn Healing

*Iyadh Ghorbel, Slim Moalla, Amal Abid, Amir Karra and Khalil Ennouri*

## Abstract

Electrical burns are a major cause of bodily harm due to the mechanism and effect of the lesions. This prompts us to study these lesions and their management in order to reduce the morbidity caused by this type of accident. In the event of an electric shock accident, the treatment is medico-surgical and is composed of two main phases: acute phase when general treatment is essential and subacute phase when local treatment is implemented. The study shows that conventional emergency decompression does not appear to reduce the amputation rate, the use of local and locoregional flaps in the initial phase (<21 days) carries a significant risk of suffering and necrosis, and also antithrombotic prevention or the use of flaps does not seem to have an impact on healing delays.

**Keywords:** burns, electrical, fasciotomy, antithrombotic, flap, healing time

## 1. Introduction

Electric burns are known for its devastating effects, leading to significant morbidity and mortality, especially as it often affects young adults of working age [1–7]. The lesions are often due to direct contact with the current, which during its passage through the body will cause tissue damage of varying severity depending on the voltage, the exposure time, and the tissue resistance [3, 8]. Low voltage burns (<1000 V) often cause local lesions, whereas high voltage burns (>1000 V) lead to extensive destruction of deep structures and systemic effects [9]. Advances in medical resuscitation have made it possible to increase the survival rate of electrified patients. However, the surgical management of electrical burns is controversial. Opinions are still discussed between early and wide excision with immediate reconstruction and late iterative excision and subsequent reconstruction based on several plastic surgery procedures [10].

## 2. Injury mechanism

### 2.1 The characteristics of electricity

The electric current is defined by:

1. Its intensity that corresponds to the electric charge carried by the electrons crossing a section of circuit during a second. It is measured in amperes denoted as A

2. Its voltage that corresponds to the circulation of the electric field along an electrical circuit measured in volts and denoted as V.

The injuries induced by the electric current thus depend on the voltage, the intensity, the contact time (T), and the resistance encountered expressed in R.

Four main mechanisms are evoked before any electric shock accident:

1. Depolarization lesions: they are due to the direct action of the current on the human cell whatever its type. It can induce a direct lesion of the nervous, cardiac, or muscular cells, which can cause cardio-respiratory arrest. In this case, we speak of an electrocution accident. The depolarization effect is a function of the current intensity.
2. Heat-induced lesions: produced by the passage of the current according to the resistance of the tissues governed by the Joule law:  $J = I^2.R.t$  or  $U.I.R.t$ .

Thus, the higher the tissue resistance is, the more heat will be emitted and the more serious the lesions will be. Note that fluid environments, nerves, blood, and vessels are low resistance tissues that emit little heat during the passage of electric current and lesions will be minimal. However, the skin (mainly the stratum corneum) and the bone tissues are of high resistance and emit a lot of heat, which will cause lesions in the tissue cells in addition to a devastating action on the surrounding tissues like the muscles [11].

On the other hand, depending on the voltage, we can distinguish two types of lesions:

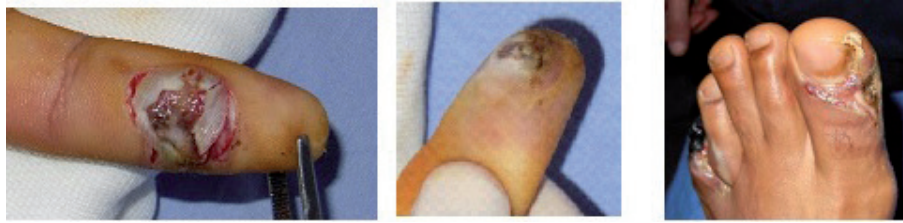
Low voltage burns, when the voltage is less than 1000 V. In this case, the lesions are often less serious but where the intensity can sometimes cause significant lesions.

- High voltage burns, when the voltage is over 1000 V. In this case, the lesions are most often serious.
  - Finally, the contact time contributes to the severity of the lesions: the longer it is prolonged, the more serious the lesions will be.
3. Electric flash: these are thermal burns that can be observed during an electric shock accident and are secondary to the spark that can occur during contact with the electricity [11, 12]
  4. Electric arc: it is a rare phenomenon but which must not be neglected. Thus in some cases when the voltage is very high, there can be an attack without direct contact with the current. The electric jump distance is 2–3 m per 10,000 V [11]. This high voltage generated remotely can cause real skin and muscle damage. It has been calculated that the heat produced can vary from 2000 to 20,000°C [11].

## 2.2 Anatomopathology

In front of an electric burn, practitioner has always to look for the entry point and the exit point, which will make it possible to imagine the path of the current and thus evaluate the severity of the damage and lesions.

The skin is the first organ affected, and then the current follows through variable and unpredictable paths depending on the degree of resistance encountered.



**Figure 1.**  
*Entry point in fingers. Exit point in toes.*

Finally, it will go out of the body through the skin at a zone in contact with the ground or another external element.

At the entry point is a marble colored or whitish area, charred, insensitive and does not bleed when scarification is done (**Figure 1**). Its size is very small in area ranging from a few millimeters to centimeters. The most serious damage is deep. In fact under a dry skin, a high voltage current can generate a heat of more than 1000°C [11]. At the exit point, there is a small area of white and gray necrosis.

The hands and the feet constitute, respectively, the sites of predilections of entry and the exit of the electricity. The dominant side is most often reached during electrical burns [13–15]. Moreover, in the electric burn, the cutaneous lesion is not the accurate reflection of the extent of the underlying lesions related to the passage of the current. Burnt body surface is often small with percentages not exceeding 20% [16, 17].

The different tissues and organs can undergo lesions of variable severity that may be due to the direct action of electricity on the human cell or indirect by the effect of heat released depending on the tissue resistance.

On the other hand, the lesions can be giving extensive necrosis of the tissues, immediately or in the upcoming days as a result of the complications caused by the passage of the current such that:

1. The progressive devascularization of muscles and skin by thrombosis due to the direct action of the current on the vascular wall [18, 19] more or less associated with hypercoagulability.
2. Compartment syndrome: increase of the intra compartmental pressure > 28 mmHg.
3. Multi-resistant bacterial infections aggravating the lesions.

### 3. Epidemiological profile

Most series have reported an average age of 30.2 years [3, 12, 20, 21]. The prevalence of injury in the third decade may be due to occupation [12, 22, 23]. Mashreky et al. [21] have shown that the relative risk of having an electric burn is higher in men than in women. According to Dega et al. [24], 91% of electric burn victims are manual workers. In addition, the lesion most often affects the upper part of the trunk and the upper limb.

Most frequently, it is a domestic accident [21, 22, 25]. This is often due to inexcusable negligence of security measures [21]. Many authors [2, 10, 21] reported the association of household accidents with low-voltage burns, while work and public road accidents are linked with high-voltage burns.

## 4. Patient management

In the event of an electric shock accident, the treatment is medico-surgical and is composed of two main phases.

### 4.1 Acute phase

#### 4.1.1 General treatment

The patient must be conditioned and a solute infusion must be started. It is necessary first of all to eliminate a lesion which can be lethal: essentially cardiac depolarization disorders as it can lead to cardiac arrest (electrocution) and/or head trauma by falling from height or projection during electrification accident. In the case of polytrauma, a body scan must be performed urgently.

About 10–20% of patients arriving at hospital show electrocardiographic disturbances such as supraventricular tachycardia (SVT), right bundle-branch block, arrhythmia, and nonspecific ST segment disturbances at the ECG [11]. On the other hand, the electrified patient is vulnerable to having a myocardial infarction given the lesions created by the current at the level of the vessel wall and the formation of thrombosis. The dosage of cardiac enzymes (troponin) must be systematic and recontrolled. Thus, most authors agree on the need to introduce initial heparin therapy, in order to minimize these thromboembolic risks [26].

An evaluation of renal function by serum creatinine determination and hourly diuresis monitoring as well as the determination of muscle enzymes (CPK and LDH) can detect possible acute functional or organic renal failure by tubular necrosis [7].

#### 4.1.2 Local treatment

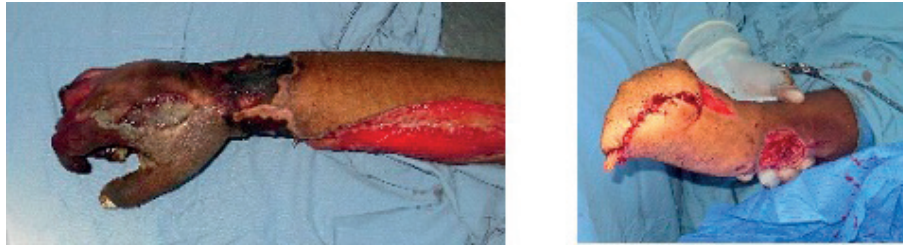In electric shock accidents, depending on the series, 9.2–54% of the victims may require the urgent realization of a fasciotomy and/or escharotomy [10, 16, 27]. This could be explained by the localization of the entry wound as well as the aggressiveness of the electric passage.

The realization of a fasciotomy in emergency is guided by the presence or not of a compartment syndrome and the monitoring of the intra-compartmental pressure which must not exceed 28 mmHg. Fasciotomy timing (immediate or secondary) and technique (total or selective) are subject to controversy. Previously, it was recommended to perform systematically a total fasciotomy in front of any electrical burn of the limbs. Recent studies, however, advocate selective and nonimmediate decompression to preserve the tissues and reduce the rate of amputations [10].

Moreover, during electrical burns, 20–30% of patients undergo amputation [16, 20, 24] with a statistically significant relationship between “the type of voltage and amputation” and “the high voltage and the comorbidity” [16, 28, 29]. It is often an amputation of a limb or limb segment [29]. It is necessary to respect the rules of amputation (suitable level, burial of the nerves) and a stump of good quality guaranteeing an adequate prosthesis without complications (**Figure 2**). Amputation is rarely done urgently, except in case of irreversible distal ischemia or massive necrosis by direct attack with hemodynamic repercussions that can be life threatening.

### 4.2 Subacute phase

Once the hemodynamic state is stabilized and the critical course is surpassed, the management is focused on the prevention of any complications and their



**Figure 2.**  
*Hand necrosis. Amputation.*

treatment, and on the healing of various lesions, modality and deadlines remain controversial.

Some authors believe that tissue damage is fully established immediately and that there is no change in necrosis and thus advocates early and wide excision with immediate free flap reconstruction [10, 13, 25]. This attitude reduces the rate of infectious complications, the time to heal, and the length of hospital stay [30].

Other authors believe that the damage is done in two stages in which the initial trauma is followed by progressive tissue necrosis essentially at the level of the deep muscular compartments [3, 10, 14], and thus that the evolutionary nature of these lesions requires iterative debridement with secondary reconstruction [31, 32].

In our practice, the first excision is performed on an average of 8 days after burns. Reconstruction will be immediate by autoplasty if there is exposure of bone, joint, nerve, or vascular element [7].

#### *4.2.1 Healing modalities*

Healing by secondary intention is the method of choice for many authors [11, 16]. The use of flaps, especially free flaps, is frequent compared to other etiologies of burns [20] and this which aims reducing morbidity. However, their vitality can be disrupted which questions the optimal moment of the reconstruction.

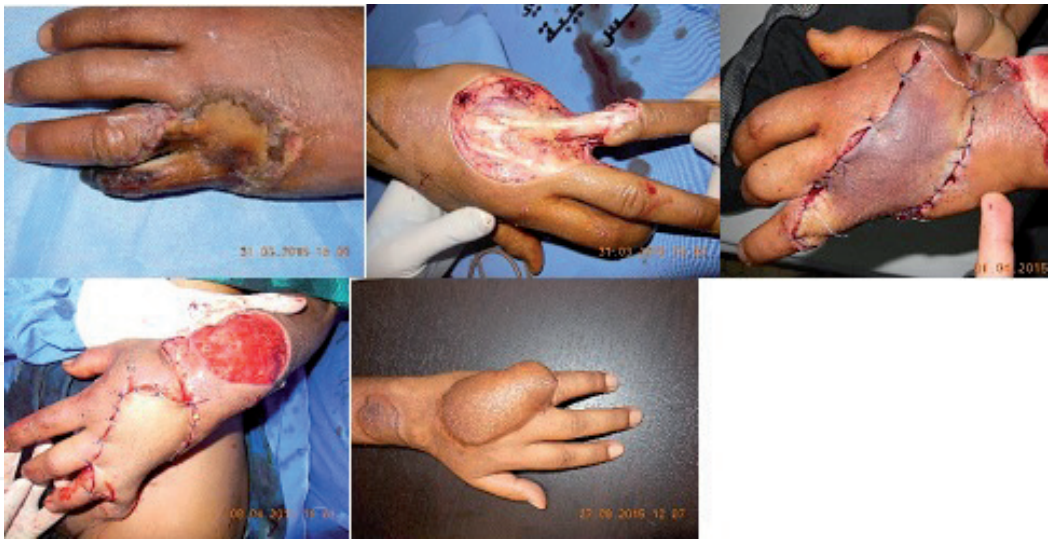During the primary phase, the risk of necrosis is amplified and can reach up to 24% according to Sauerbier et al. [10, 33]. This phase has been described as a phase of vulnerability that lasts about 21 days and during which there is vascular instability that can compromise the vitality of the flap [10, 34]. Therefore, it is recommended to use the flap as far as possible from the electrified area [18] such as the groin flap and the latissimus dorsi flap [10].

Regional and local flaps are often used as an excellent means of coverage with lower morbidity and a similar success rate to free flaps [7, 24]. Moreover, the free flaps are used secondarily in case of necrosis or immediately in case of a large skin defect. We recommend using autoplasty during the secondary phase after delimitation of necrosis and stability of vascular lesions (**Figure 3**).

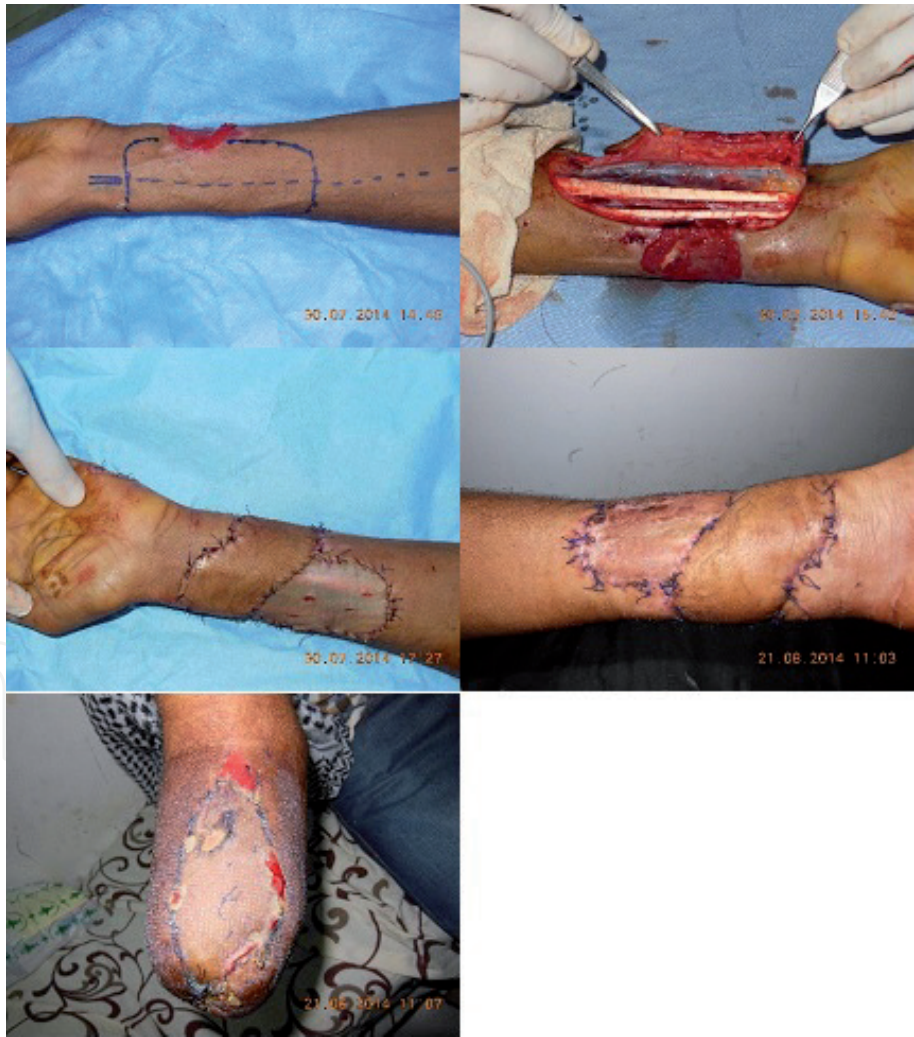Perforator pedicled flaps are an important tool for reconstruction especially in small and average size skin defects. This kind of flaps permits “like by like” reconstruction using microsurgical nonmicrovascular flaps [35]. The main advantages of these flaps could be summarized as: no microsurgical sutures, no main vascular pedicles sacrifice, same surgical field, and shorter hospitalization time (**Figure 4**).

In deep burns with complete destruction of the dermis, the use of definitive skin substitutes (artificial dermis) aims at reconstructing a neodermis, in particular at the level of the functional zones, but it can also be used at limited tendon or osteoarticular exposures, subject to a well vascularized environment [31]. However, given their considerable cost, their use remains limited to burn centers that have such means.

The use of the vacuum-assisted closure (VAC) therapy after debridement has been described by some authors [36–38] who reported that this technique can

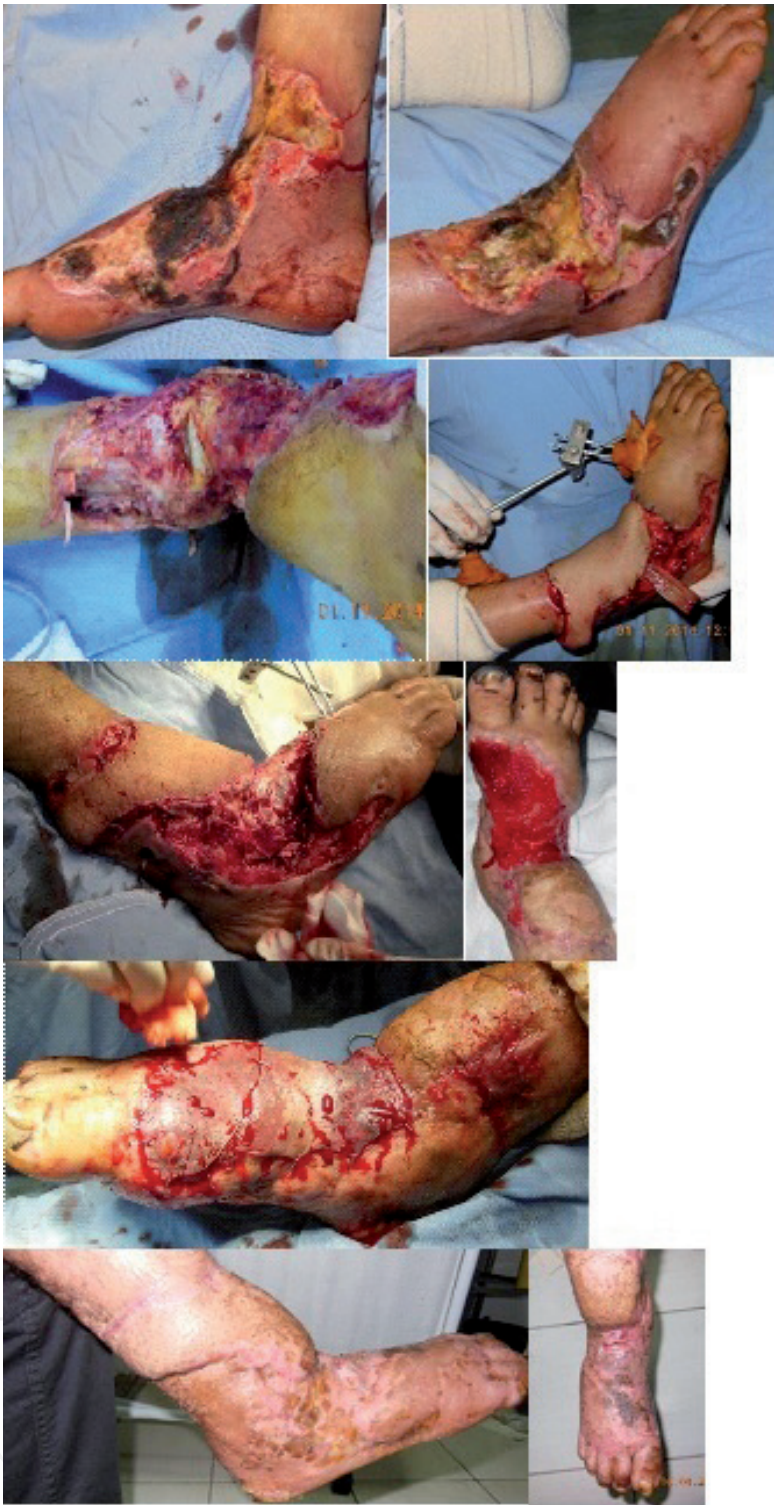

**Figure 3.**  
*Low voltage electric burn. Necrosis of the fifth finger. Excision 6 days after burn. Immediate coverage by local flap. Partial necrosis of the flap. Groin flap.*



**Figure 4.**  
*High voltage electric burn. Radial artery perforator flap for the left upper limb. Right upper limb amputation.*

reduce the frequency of dressing changes and the exposure time. The application of a VAC system requires that the debridement phase should be completed. It accelerates the granulation phase and shortens the duration of hospitalization. In addition, we preserve this technique with deep and small skin defects (**Figure 5**).



**Figure 5.**  
*High voltage electric burn. Excision 7 days after burn with osteoarticular exposition. Use of sural flap, vacuum-assisted closure therapy and skin grafting.*

*4.2.2 Healing time*

The healing time does not depend on the total burn surface area (TBSA) or the healing modality (second intention or first intention). In our practice, it was found that, first, most patients who had flap cover healed beyond 1 month, and second, the flap cover in electrical burns, and despite its efficient functional and esthetic results, it prolongs the healing time. This is largely related to the severity of the initial lesions, lesions localization (joints and periorificial area), terrain, and infectious complications [7].

The mean healing time in our series was  $48.91 \pm 23.16$  days with a median of 45 days [7]. However, most series reports the time of hospitalization during electric burns [2, 3, 39] which is  $53.43 \pm 31.73$  days according to Lipovy et al. According to us, we think that the management of a burnt, electrical, or other, is not reduced to the period of hospitalization but extends to the healing of the various lesions. In most cases, this cannot be done entirely in hospital and, thus, many patients benefit from an external follow-up phase.

Most authors admit that high-voltage electrical burns heal late, compared with low-voltage burns, given the large amount of energy emitted by the tissue and the depth of the lesions [3].

However, there was no statistically significant relationship between the type of voltage and healing time or between the introduction of preventive, anti-thrombotic therapy, and the healing time. This can be explained by the small number of our patients' sample. In addition, as a specialized service, there has been a selection bias in our series since hospitalized patients are those with the most severe lesions even with low voltage current and require sophisticated healing processes [7].

### 4.3 Sequela

The majority of patients who have suffered an electric shock accident have more or less disabling sequela [20, 24, 40]. In fact, the voltage would predict neither the rate of the return to work nor the rate of neuropsychiatric sequela, and that the patients evolve in the same way in terms of sequela independently of the voltage of the causal current [41].

#### 4.3.1 Cutaneous sequela

They are often described as keloid and hypertrophic scars, dyschromia, and skin retractions [7, 40]. In the initial phase, the treatment is medical (pressotherapy and silicone gel). Surgery will only be indicated after scar maturation except in cases of major functional repercussions.

#### 4.3.2 Neurological sequela

Peripheral post-burn neurologic sequela are well documented nowadays and are both troublesome and disabling sequela for patients who have suffered from electrical burns [8, 24, 40, 42].

These sequela ranges from simple paresis with sensitivity disorder to total paralysis. They may appear early or late [43]. In all cases, it is necessary to wait for the delay of 1 year before drawing up the definitive state.

#### 4.3.3 Osteoarticular sequela

The rate of osteoarticular sequela is around 30% according to most series [7, 24, 40]. In addition to the more or less extensive amputations, joint stiffness, dysplasia, and ankylosis can also be described.

### 4.4 Socio-economic impact

Electrical burns, whether high or low voltage, can have a significant socio-economic impact due to absenteeism and inability to work [41]. However, a comparative study showed that although electric burn patients remained more in hospital

and had a higher rate of amputations, there was no difference in terms of return to work compared to thermal burns [44].

#### 4.5 Psychological impact

Psychological impacts following an electrical burn are not as rare as one might think and add psychological morbidity associated with physical morbidity in these patients. Psychiatric morbidity is present in 28–78% of burns. However, the type of voltage and the initial pain do not appear to be related to psychological sequela [8, 43, 45].

### 5. Conclusion

Electrical burns are serious trauma that should be properly managed to avoid serious functional and life-threatening consequences. However, this management continues to be hampered by the lack of established guidelines unifying treatment and improving the prognosis.

#### Conflict of interest

The authors declare no “conflict of interest.”

#### Author details

Iyadh Ghorbel\*, Slim Moalla, Amal Abid, Amir Karra and Khalil Ennouri  
Plastic, Aesthetic and Reconstructive Surgery Department, Habib Bourguiba  
Hospital, Sfax, Tunisia

\*Address all correspondence to: [iadh\\_ghorbel@medecinesfax.org](mailto:iadh_ghorbel@medecinesfax.org)

#### IntechOpen

© 2019 The Author(s). Licensee IntechOpen. This chapter is distributed under the terms of the Creative Commons Attribution License (<http://creativecommons.org/licenses/by/3.0>), which permits unrestricted use, distribution, and reproduction in any medium, provided the original work is properly cited. 

## References

- [1] Costagliola M. Principes généraux de la chirurgie reconstructrice des séquelles de brûlures. *Annales de Chirurgie Plastique Esthétique*. 2011;**56**(5):354-357
- [2] Lipový B, Kaloudová Y, Ríhová H, Chaloupková Z, Kempný T, Suchanek I, et al. High voltage electrical injury: An 11-year single center epidemiological study. *Annals of Burns and Fire Disasters*. 2014;**27**(2):82-86
- [3] Yagmur C. Electrical burns: Highlights from a 5-year retrospective analysis. *Turkish Journal of Trauma and Emergency Surgery*. 2015. Available from: <http://www.tjtes.org/eng/jvi.aspx?pdire=travma&plng=eng&un=UTD-55491&look4=>
- [4] Haddad SY. Electrical burn—A four-year study. *Annals of Burns and Fire Disasters*. 2008;**21**(2):78-80
- [5] Luz DP, Millan LS, Alessi MS, Uguetto WF, Paggiaro A, Gomez DS, et al. Electrical burns: A retrospective analysis across a 5-year period. *Burns*. 2009;**35**(7):1015-1019
- [6] Vierhapper MF, Lumenta DB, Beck H, Keck M, Kamolz LP, Frey M. Electrical injury: A long-term analysis with review of regional differences. *Annals of Plastic Surgery*. 2011;**66**(1):43-46
- [7] Ghorbel I, Abid A, Moalla S, Karra A, Nouri K. La particularité de cicatrisation des pertes de substance cutanées dans les brûlures électriques: Notre expérience. *Annals of Burns and Fire Disasters*. 2018;**31**(2):122-126
- [8] Singerman J, Gomez M, Fish JS. Long-term sequelae of low-voltage electrical injury. *Journal of Burn Care & Research*. 2008;**29**(5):773-777
- [9] Lee RC. Injury by electrical forces: Pathophysiology, manifestations, and therapy. *Current Problems in Surgery*. 1997;**34**(9):677-764
- [10] Handschin AE, Vetter S, Jung FJ, Guggenheim M, Künzi W, Giovanoli P. A case-matched controlled study on high-voltage electrical injuries vs thermal burns. *Journal of Burn Care & Research*. 2009;**30**(3):400-407
- [11] Échinard C, Latarjet J. *Les brûlures*. Issy-Les-Moulineaux: Masson; 2010
- [12] El Bouyousfi J, Fejjal N, Belkacem R. Les brûlures électriques de la main chez l'enfant. *Journal de Pédiatrie et de Puériculture*. 2015;**28**(4):173-176
- [13] Mazzetto-Betti KC, Amâncio ACG, Farina JA, Barros MEPM, Fonseca MCR. High-voltage electrical burn injuries: Functional upper extremity assessment. *Burns*. 2009;**35**(5):707-713
- [14] Noble J, Gomez M, Fish JS. Quality of life and return to work following electrical burns. *Burns*. 2006;**32**(2):159-164
- [15] Brych SB, Engrav LH, Rivara FP, Ptacek JT, Lezotte DC, Esselman PC, et al. Time off work and return to work rates after burns: Systematic review of the literature and a large two-center series. *The Journal of Burn Care & Rehabilitation*. 2001;**22**(6):401-405
- [16] Salehi SH, Fatemi MJ, Asadi K, Shoar S, Ghazarian AD, Samimi R. Electrical injury in construction workers: A special focus on injury with electrical power. *Burns*. 2014;**40**(2):300-304
- [17] Kym D, Seo DK, Hur GY, Lee JW. Epidemiology of electrical injury: Differences between low- and high-voltage electrical injuries during a 7-year study period in South Korea. *Scandinavian Journal of Surgery*. 2015;**104**(2):108-114

- [18] Voulliaume D, Mojallal A, Comparin JP, Foyatier JL. Brûlures graves de la main et lambeaux: choix thérapeutiques et revue de la littérature. *Annales de Chirurgie Plastique Esthétique*. 2005;**50**(4):314-319
- [19] DeBono R. A histological analysis of a high voltage electric current injury to an upper limb. *Burns*. 1999;**25**(6):541-547
- [20] Karimi H, Momeni M, Vasigh M. Long term outcome and follow up of electrical injury. *Journal of Acute Disease*. 2015;**4**(2):107-111
- [21] Mashreky SR, Hossain MJ, Rahman A, Biswas A, Khan TF, Rahman F. Epidemiology of electrical injury: Findings from a community based national survey in Bangladesh. *Injury*. 2012;**43**(1):113-116
- [22] Maghsoudi H, Adyani Y, Ahmadian N. Electrical and lightning injuries. *Journal of Burn Care & Research*. 2007;**28**(2):255-261
- [23] Carloni R, Pechevy L, Quignon R, Yassine A-H, Forme N, Zakine G. Electrical flash burns, about 33 cases. A 10-year retrospective study. Epidemiology, treatment and prevention. *Annales de Chirurgie Plastique et Esthétique*. 2015;**60**(2):123-130
- [24] Dega S, Gnaneswar SG, Rao PR, Ramani P, Krishna DM. Electrical burn injuries. *Burns*. 2007;**33**(5):653-665
- [25] Akçan R, Hilal A, Gülmen M, Çekin N. Childhood deaths due to electrocution in Adana, Turkey. *Acta Paediatrica*. 2007;**96**(3):443-445
- [26] Bargues L, Leclerc T, Donat N, Jault P. Conséquences systémiques des brûlures étendues. *Réanimation*. 2009;**18**(8):687-693
- [27] Pannucci CJ, Osborne NH, Jaber RM, Cederna PS, Wahl WL. Early fasciotomy in electrically injured patients as a marker for injury severity and deep venous thrombosis risk: An analysis of the national burn repository. *Journal of Burn Care & Research*. 2010;**31**(6):882-887
- [28] Sahin I, Ozturk S, Alhan D, Açikel C, Isik S. Cost analysis of acute burn patients treated in a burn centre: The gulhane experience. *Annals of Burns and Fire Disasters*. 2011;**24**(1):9-13
- [29] Tarim A, Ezer A. Electrical burn is still a major risk factor for amputations. *Burns*. 2013;**39**(2):354-357
- [30] Chaouat M, Zakine G, Mimoun M. Principes de la prise en charge locale: Traitements chirurgicaux. *Pathologie et Biologie*. 2011;**59**(3):e57-e61
- [31] Duhamel P, Rem K, Hounkpevi M, Brachet M, Duhoux A, Giraud O, et al. La chirurgie aiguë des brûlés: Etat actuel, voies de recherche et perspectives médecine et armées. 2015;**43**(2):165-174
- [32] Lakhel A, Pradier J-P, Brachet M, Duhoux A, Duhamel P, Fossat S, et al. Chirurgie des brûlures graves au stade aigu. EMC–Techniques chirurgicales–Chirurgie plastique reconstructrice et esthétique. 2008;**3**(3):1-36
- [33] Sauerbier M, Ofer N, Germann G, Baumeister S. Microvascular reconstruction in burn and electrical burn injuries of the severely traumatized upper extremity. *Plastic and Reconstructive Surgery*. 2007;**119**(2):605-615
- [34] Ofer N, Baumeister S, Megerle K, Germann G, Sauerbier M. Current concepts of microvascular reconstruction for limb salvage in electrical burn injuries. *Journal of Plastic, Reconstructive & Aesthetic Surgery*. 2007;**60**(7):724-730

- [35] Georgescu AV, Matei I, Ardelean F, Capota I. Microsurgical nonmicrovascular flaps in forearm and hand reconstruction. *Microsurgery*. 2007;**27**(5):384-394
- [36] Chong SJ, Liang WH, Tan B-K. Use of multiple VAC devices in the management of extensive burns: The total body wrap concept. *Burns*. 2010;**36**(7):e127-e129
- [37] Fette A. Children and their burned limbs. *Burns*. 2007;**33**(1):S20
- [38] Hakkarainen AJ, Kukko H, Vuola J. Vacuum-assisted closure in deep extremity burns. *Burns*. 2009;**35**:S23-S24
- [39] Ghavami Y, Mobayen MR, Vaghardoost R. Electrical burn injury: A five-year survey of 682 patients. *Trauma Monthly*. 2014;**19**(4). Available from: [http://www.traumamon.com/?page=article&article\\_id=18748](http://www.traumamon.com/?page=article&article_id=18748)
- [40] Piotrowski A, Fillet A-M, Perez P, Walkowiak P, Simon D, Corniere M-J, et al. Outcome of occupational electrical injuries among French electric company workers: A retrospective report of 311 cases, 1996-2005. *Burns*. 2014;**40**(3):480-488
- [41] Chudasama S, Goverman J, Donaldson JH, van Aalst J, Cairns BA, Hultman CS. Does voltage predict return to work and neuropsychiatric sequelae following electrical burn injury? *Annals of Plastic Surgery*. 2010;**64**(5):522-525
- [42] Tamam Y, Tamam C, Tamam B, Ustundag M, Orak M, Tasdemir N. Peripheral neuropathy after burn injury. *European Review for Medical and Pharmacological Sciences*. 2013;**17**(Suppl 1):107-111
- [43] Bailey B, Gaudreault P, Thivierge RL. Neurologic and neuropsychological symptoms during the first year after an electric shock: Results of a prospective multicenter study. *The American Journal of Emergency Medicine*. 2008;**26**(4):413-418
- [44] Cochran AJ, Essner R, Rose DM, Glass EC. Principles of sentinel lymph node identification: Background and clinical implications. *Langenbeck's Archives of Surgery*. 2000;**385**(4):252-260
- [45] Ramati A, Rubin LH, Wicklund A, Pliskin NH, Ammar AN, Fink JW, et al. Psychiatric morbidity following electrical injury and its effects on cognitive functioning. *General Hospital Psychiatry*. 2009;**31**(4):360-366