

# We are IntechOpen, the world's leading publisher of Open Access books Built by scientists, for scientists

6,900

Open access books available

185,000

International authors and editors

200M

Downloads

Our authors are among the

154

Countries delivered to

TOP 1%

most cited scientists

12.2%

Contributors from top 500 universities



WEB OF SCIENCE™

Selection of our books indexed in the Book Citation Index  
in Web of Science™ Core Collection (BKCI)

Interested in publishing with us?  
Contact [book.department@intechopen.com](mailto:book.department@intechopen.com)

Numbers displayed above are based on latest data collected.  
For more information visit [www.intechopen.com](http://www.intechopen.com)



# Evaluation and Management of Mandibular Fracture

*Guhan Dergin, Yusuf Emes and Buket Aybar*

## Abstract

The mandibular bone is an important component of the facial bone, which has a unique role in digestive system, speech, and facial esthetics. For these important functions of mandibular bone, it is vital that surgeons should not only treat function but also consider the esthetics together. Mandibular fractures are among the most common traumatic injuries of the maxillofacial region. Even though treatment modalities are well established and being practiced for a long time, untreated and postoperative complications still decrease the patient's quality of life. This chapter aims to describe the cause, clinical presentations, diagnoses, and current treatment methods on the basis of recent literature.

**Keywords:** mandibular fracture, open reduction, rigid fixation, trauma

## 1. Introduction

The mandibular bone, which is an important anatomical and functional structure, constitutes the lower height and width of the facial skeleton. The mandible is a complex bony structure and has a vital anatomical articulation with other cranio-maxillofacial components. It has a fundamental function in digestive system and also plays an important role in speech and facial expression. The mandible is a v-shaped bone articulating with the temporal bone at the temporomandibular joint (TMJ). Mandibular bone has a horizontal and vertical portion.

The cartilaginous mandibular bone is a v-shaped bone articulating with the temporal bone at the temporomandibular joint (TMJ) [1]. Mandibular bone has a horizontal and vertical portion. The horizontal portion of mandible has two main structures, the basal and alveolar (tooth bearing) bones. Symphysis, parasymphysis, the body, and the alveolar bone compose the horizontal section of the mandible. The vertical mandible consists of the angle, ramus, condylar, and coronoid processes [2].

## 2. Brief historical overview

The first description of a mandibular fracture diagnosis and treatment goes back to the Egyptians in 1650 BC. Hippocrates described the reapproximation of fracture fragments and immobilization of the fractured mandible using circumdental wires and external bandaging.

Since then, many effective treatment methods and devices have been introduced to maxillofacial traumatology for the treatment of mandibular fracture including the facial bandage, extra oral fixation apparatus, intraoral acrylic, and metal splints, wires, arch bars, and stainless steel and titanium plate osteosynthesis. More recently resorbable screws and plates have been used for fracture management [3].

### **3. Etiology (epidemiology)**

Mandible fractures have many different etiologies such as interpersonal violence, traffic accidents, gunshot wounds, sport accidents, work accidents, and falls [3]. The etiology of mandibular fractures varies from time to time, culture to culture. Students in different periods demonstrate differences in etiology depending on the age, demographic pattern of countries, and environmental conditions and social, socioeconomic, and cultural configurations. In developed countries, vehicle and sport accidents are main causes of mandibular fractures, while in developing countries and rural areas, inter personal violence, gunshot wounds, and falls in foregrounds [3–7].

### **4. Clinical and radiological assessment**

#### **4.1 Clinical**

Complete history trauma should be obtained after cardiopulmonary and vital neurological functions of the patient are stabilized. Checking the airway by securing cervical spine is vital before assessment. Depending on the consciousness or neurologic status of the patient, history can be obtained from the patient or accompanying family members. Assessments including time, cause of trauma, pain, function of cranial nerves and altered sensation, visual changes, malocclusion, and general systemic conditions should be noted. Some mandibular fractures accompanying multiple injuries, as in traffic accidents, frequently require trauma team evaluation and consultation.

A neurologic examination is a vital point in the assessment of maxillofacial trauma. Functions of cranial nerves such as altered sensation, pupillary reflex, visual changes, and extraocular movements should be evaluated. Motor function of facial expression (nerve VII), symmetrical tongue movements, and mastication muscle (nerve V) should be checked. Sensation of the face should be also noted.

The mandible should be carefully evaluated by extraoral palpation. Mandibular contours such as ramus, lateral and inferior borders, and symphysis and parasymphysis area should be checked, and continuity of the mandibular bone should be noted. Movements of fragments can be evaluated by bidigital palpation. Ecchymosis and crepitation should be assessed. Check mandibular movements. Deviations and restriction of movements should be evaluated considering condylar trauma. Also the condylar head should be evaluated by palpation to check if it is in the articular fossa or not.

Mucosal laceration, oral bleeding, ecchymosis, and sublingual hematomas should be checked by the intraoral inspection. Rule out fresh oral bleeding in the sublingual space or bilateral symphysis fracture to secure airway, especially for anticoagulant drug users. Examination of the occlusion including loose, fractured, or missing teeth should be performed carefully.

## **4.2 Radiological**

In most cases clinical examination cannot be sufficient to intensively evaluate the entire fractures lines, displaced small fragments, root fractures of teeth, and neighboring anatomical structures [8]. Plain films, OPTG, and computed tomography (CT) can provide additional data about the fracture for better evaluation of the patient. Periapical or occlusal radiographs are useful and practical imagining techniques for viewing specific areas of concern [9].

Although it is expensive, computed tomography (CT) is the most comprehensive imagining technique for evaluation of maxillofacial traumas. Detailed 0.5 mm thick slices provide excellent axial, coronal, and sagittal assessments of fracture lines, neighboring anatomical structures such as nerves. Also high velocity impaction traumas with multiple injuries require extensive stabilization of the patient. Additionally, 3D evaluations help to provide models for reconstruction and they are essential for proper approximations of fracture fragments with prepended titanium plates. Nowadays the use of cone-beam computed tomography (CBCT) in maxillofacial surgery has been providing less radiation and an accurate and reliable imagining alternative to conventional CT [10, 11].

Rarely, angiography and embolization can be used in the treatment of displaced TMJ fracture. Also MRI imagining can be helpful to evaluate soft tissue injuries such as TMJ disc.

## **4.3 Classification of mandibular fractures**

Mandible fractures have a unique property within the maxillofacial traumas considering their history and treatment approach. The cornerstone of understanding the mandibular fractures is the classification of mandibular fractures. There are many fracture classifications in literature based on the type of fracture, cause of the fracture, reducibility, anatomic site, condition and inter-fragmental situation, and the presence of dentate or edentate segments. Some of these classifications are more widely accepted and used, and some of them are mostly seen in books but not used practically. Mandibular fractures are most commonly described as their anatomic location [3].

### **4.4 Fracture classifications based on anatomic site**

1. Angle
2. Alveolar process
3. Body
4. Condyle
5. Coronoid
6. Ramus
7. Symphysis/parasymphysis

Fractures can be also classified as pathologic Fractures and traumatic fractures. Pathological fractures occur due to the failure of the bone which has lost its mechanical strength as a result of a pathological condition such as tumors, cysts, infections, etc. Traumatic fractures occur due to an impact which disrupts the continuity of the osseous tissue.

5. Biomechanics

The mandibular bone is exposed to many kinds of linear and angular forces underload such as compression and tension, shear, torsion, and bending [12]. External forces cause mandibular bone to undergo plastic and elastic deformation. On the other hand, muscles have some vertical and horizontal forces on fragments. These forces may cause displacement of fragments or may act as a stabilizer for fragments. The temporalis, masseter, and medial pterygoid muscle pull are responsible for vertical displacements of fragments. Horizontal displacements are mainly caused by lateral and medial pterygoid muscle pull. Some muscles have complex force on fragments such as mylohyoid, digastric, and geniohyoid which have a torsion effect on fragments.

Champy and co-workers described a zone of tension in the alveolar part of the mandible and a zone of compression on the lower border. This information allowed ideal lines for mandibular internal fixation to be identified along the physiological tension lines [3].

5.1 Muscle forces

Muscles have pull direction, and this pull effect may compress fragments to each other and prevent displacement. Fractures under the effect of these kinds of muscle pull vector are called favorable fractures.

On the other hand, some muscle pulls cause displacements of fragment. Fractures at these kinds of disadvantageous situations are called unfavorable

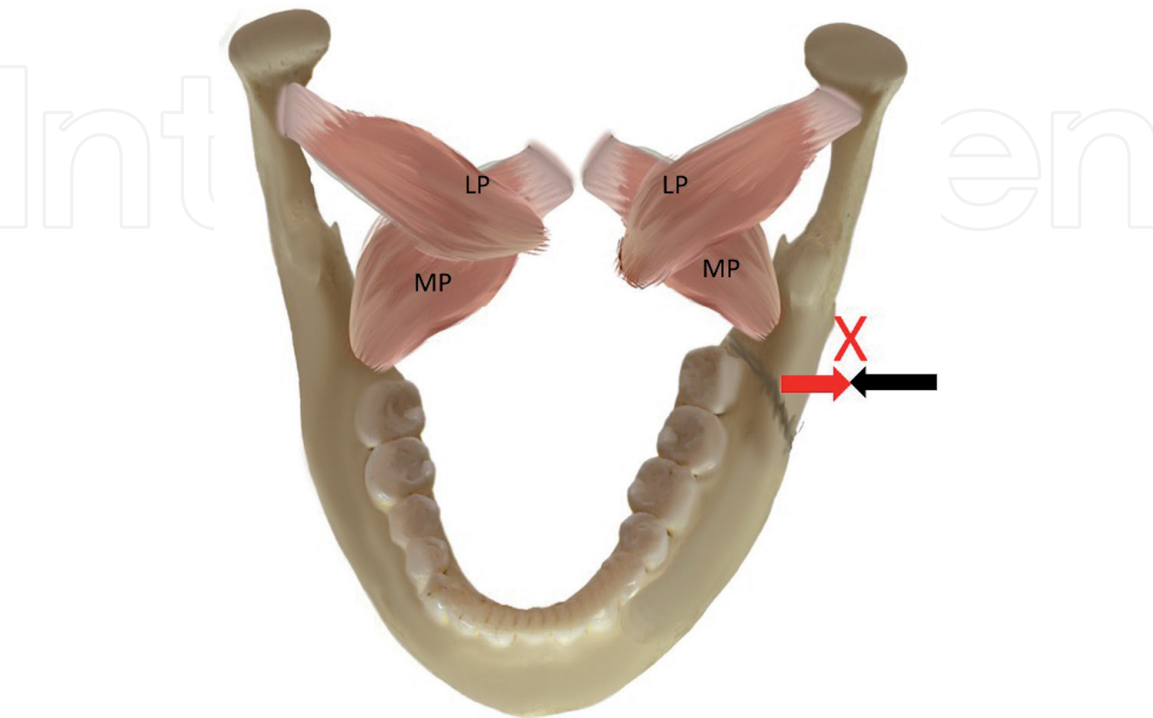


Figure 1.  
Horizontally favorable fractures.

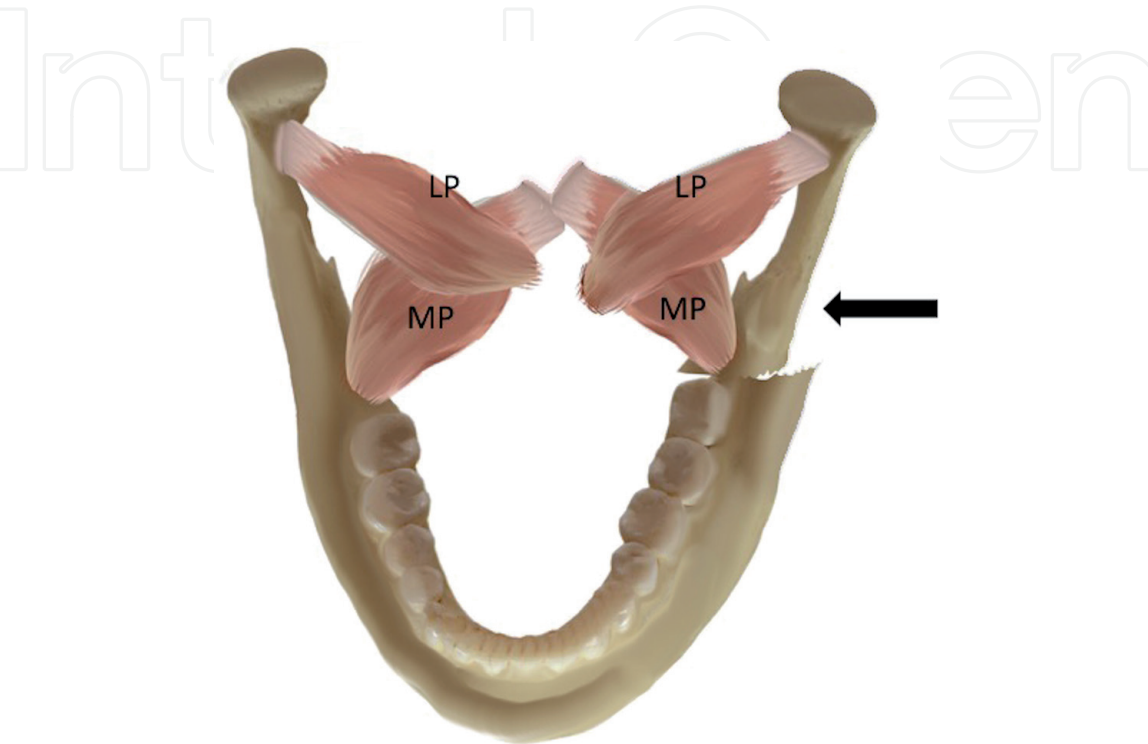


fractures. Favorable/unfavorable fracture concept is essential for mandibular fracture treatment decision which will be discussed later in this chapter.

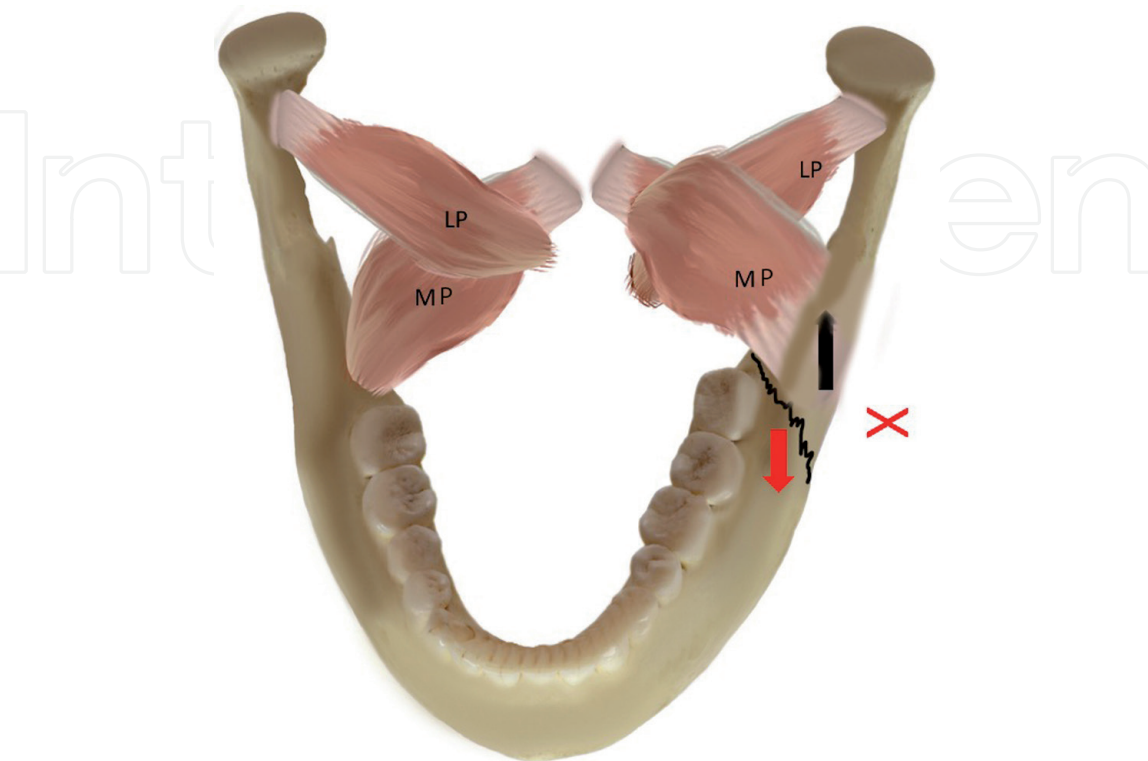
**Horizontally favorable fractures:** reduced biomechanically by the masseter and temporalis muscle pull (**Figure 1**).

**Horizontally unfavorable fractures:** Displacement of fracture fragments increased or is provoked by the masseter and temporalis muscle pull (**Figure 2**).

**Vertically favorable fractures:** The pull vector of the pterygoid muscle promotes the reduction of the fracture segments (**Figure 3**).



**Figure 2.**  
*Horizontally unfavorable fractures.*

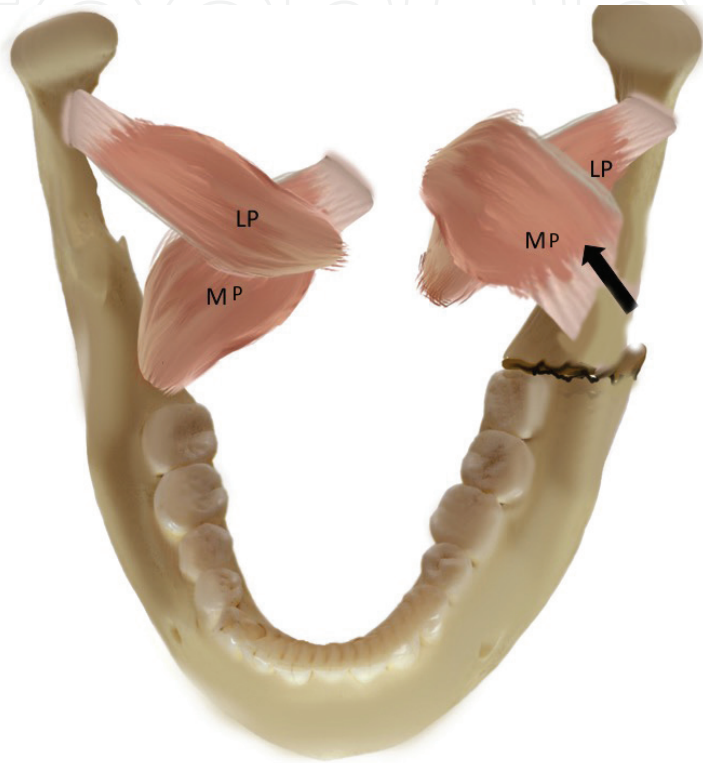


**Figure 3.**  
*Vertically favorable fractures.*

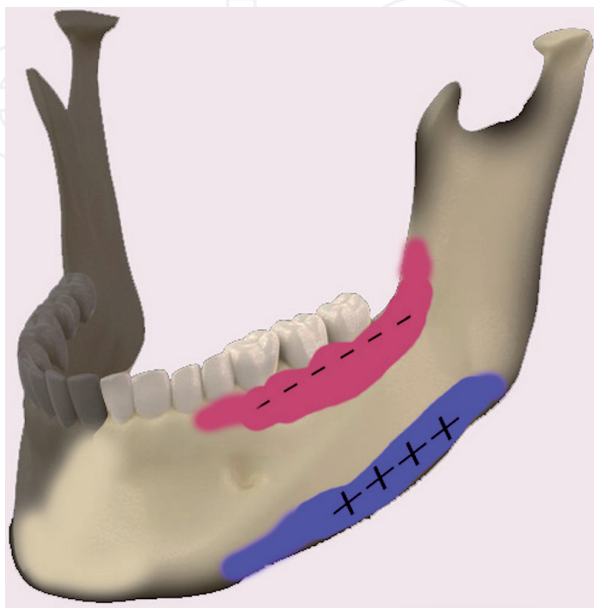
**Vertically unfavorable:** The actions of the pterygoids tend to displace the fracture (Figures 3 and 4).

5.2 Tension and compression zones

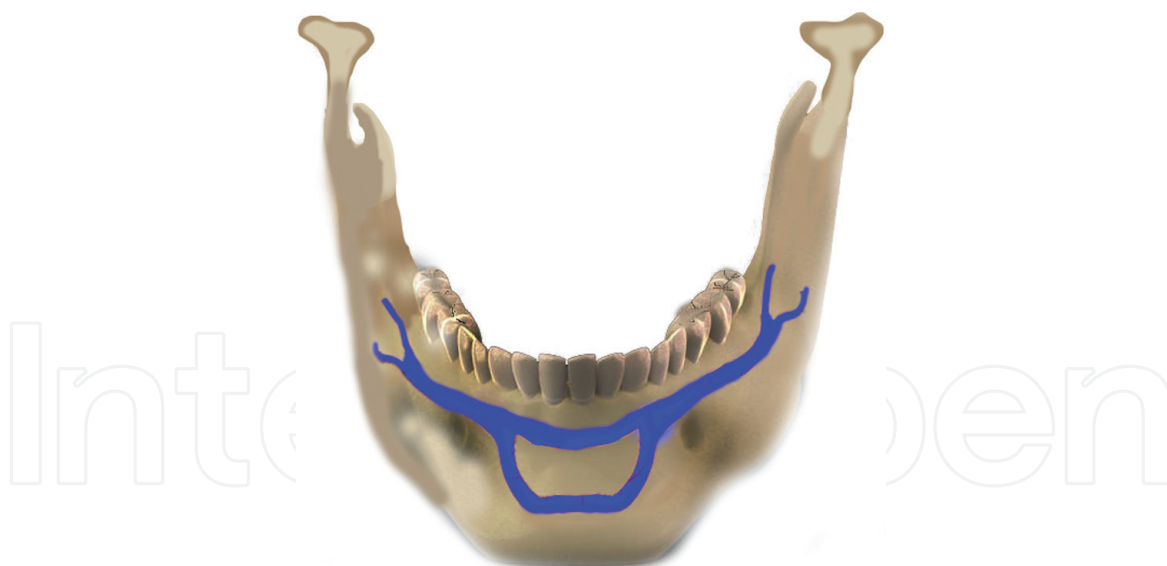
Pulling force applied by muscles of oro-maxillofacial region creates zone of compression and tension within the mandible. The superior portion of the mandible is termed as the tension zone, and the inferior portion is termed as the compression zone (Figure 5). Champy's principle of osteosynthesis lines is based on these tension



**Figure 4.**  
*Vertically unfavorable fractures.*



**Figure 5.**  
*Tension zone marked in red (-) and compression zones marked in blue (+).*



**Figure 6.**  
*Champy's principle of osteosynthesis lines.*

and compressions zones which has been proven to be the guiding line to establish effective treatment for open reduction of mandibular fracture (**Figure 6**) [3, 13].

## 6. Principle of mandibular fracture treatment

The trauma patient should first be provided with airway clearance. In a patient lying in the supine position, foreign bodies such as missed pieces of broken teeth and intraoral bleedings may create a danger of closing the airway. Although the blood in the mouth may be swallowed by the unconscious patient at first, it may cause vomiting as time passes. Breathing can be provided by pulling the mandible forward with a properly positioned cervical collar. It must be kept in mind that in patients with compound fractures, it may be difficult to position the lower jaw with the help of a cervical collar.

Antibiotics are preferred especially in open fractures and delayed healing. The patient should be given anti-inflammatory drugs, and if there are no clean wounds, the necessity of tetanus vaccine should be considered.

### 6.1 Prognosis of the teeth in the fracture line

Fractures of the fracture line, excessively displaced, and teeth which have their cement exposed, if they are not to be temporarily held in the mouth to maintain occlusion, must be extracted [14].

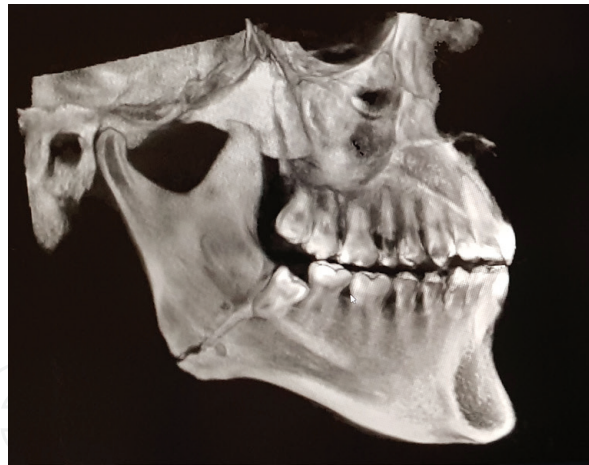The teeth with apical infection and teeth with excessive periodontal defects, teeth with root fractures, and teeth that prevent the reduction of fracture segments should be extracted [15] (**Figure 7**).

### 6.2 Aim of fracture treatment

The purpose of fracture treatment is to return the mechanical strength of the fracture site to its healthy state and to achieve an improvement in the masticatory muscles' normal functions.

The first stage of treatment is to return the fracture parts to their normal anatomic position (reduction). The second stage is the fixation of the parts in their





**Figure 7.**  
*Teeth that prevent the reduction of fracture segments.*

normal anatomical position (fixation). If the history of the trauma does not exceed 8–10 days, the fixation of the fractures can be done manually. In order to control the pain, local anesthesia can be applied. Mobile dentoalveolar structures must be fixed using wires or similar methods [16].

### 6.3 Closed versus open treatment

Fractures of the mandible can be treated either with open method or closed method.

#### 6.3.1 Closed reduction

Anatomically restoration of the fragments without visualization the fracture line is called closed reduction. In closed reduction both tooth-borne and bone-borne stabilization can be used to immobilize fracture to obtain correct maxilla-mandibular relation which is called intermaxillary fixation (IMF). Intermaxillary fixation (IMF) which is also called maxillomandibular fixation (MMF) is usually the basis of closed methods. Intermaxillary fixation is fixing the mandible and maxilla together when the teeth are occluded so that the patient cannot open his/her mouth for a certain period to allow secondary healing. The patient should be prescribed analgesics. One week of antibiotic use is required if there is an open fracture. The treatment continues until the hard callus is formed (4–6 weeks). Optimum bony union can be established in 4–6 weeks, but in complicated fractures, or compromised patients longer treatment periods can be required for healing. Closed method is still used today due to the advantage of elastic traction which helps successful repositioning of the fragments and its low cost. Arch bars, IVY loops, and intermaxillary fixation screws are all well-known appliances for closed reduction methods [17].

The use of vacuum-formed splints has also been recommended in the past for closed reduction.

In the closed methods, arch bars are often used with ligature wires. The wire is passed through the interdental gap. One end of the wire is passed under the arch bar, and the other end is passed over the arch bar. With a fine-tipped tool, the wire is placed under the cingulum of the tooth, and the wire is bent to secure the arch bar to the tooth.

Intermaxillary fixation screws are also used to obtain the occlusion in open reduction. However iatrogenic root injury is a major concern for this method. Also loosening of the screw and covering of the screw head with oral mucosa and screw fractures have been reported as complications regarding the use of IMF screws.

The most important disadvantage of closed therapy is the continuation of intermaxillary fixation for 4 weeks. This may lead to undernourishment of the patient and weight loss. Also the patient must be informed about oral hygiene due to difficulty in cleaning the teeth under IMF. Non-displaced favorable fractures and grossly comminuted fractures with soft tissue lost can be the candidate of closed reduction. Edentulous mandibular fractures are also controversial cases which mostly require periosteal blood supply. Some authors suggest closed reduction with gunning splints and circummandibular wires. On the other hand, some other authors claim that open reduction with minimum periosteal stripping can be a good alternative for such cases [18].

### 6.3.2 Open reduction

Open reduction is preferred when closed treatment is not possible or has failed. In open reduction, there is a surgical approach to the fracture, and the fracture segments are repositioned to their anatomical positions. This stage is called reduction. This is followed by the fixation step. Fixation can be either rigid or semirigid in open reduction. Compression plates and bicortical screws are used in rigid fixation.

While this is a reliable method and allows the patient to quickly return to daily functions, this technique has some disadvantages [19].

Semirigid fixation is performed using mini-plates. These smaller plates are placed on the stress areas in the fracture area. It is thought that micromovements caused by semirigid fixation have a positive effect on the callus formation. Monocortical screws are used so that anatomical structures are preserved. It may be possible to perform even under local anesthesia and with an intraoral approach. Occasionally occlusion can be obtained using intermaxillary fixation and elasticity.

The patient is given a soft diet during semirigid fixation. It is not mandatory to remove the plates after healing [20].

#### 6.3.2.1 Indications for closed reduction

- -No or little displacement.
- Little or no fracture mobility.
- Possibility of regaining pre-injury occlusion.
- The absence of infection.
- The patient's cooperation can be maintained and the follow-up is possible.
- Closed reduction can also be preferred in patients whom a surgical approach is not recommended, such as patients having fractures due to medicine-related osteonecrosis of the jaws.

#### 6.3.2.2 Disadvantages of rigid fixation

- External approach may be required (requires skin incision and scar risks).
- The risk of damage to the alveolar is inferior and tooth roots.
- The need for a second surgical procedure to remove the plates.

### 6.3.2.3 Condyle fractures

When closed reduction is delayed in condyle fracture patients, open reduction may be required. The delaying of closed reduction causes muscles to spasm and prevent a successful repositioning of the fragments. Also medial pterygoid and temporalis muscles may get fibrotic when the treatment is delayed. As more time passes, the risk of ankylosis increases in the untreated condyle fracture patient.

When an open reduction of the condyle fracture is planned, usually an extraoral approach is required. The most common incision for this procedure is the preauricular incision which directly leads to the temporomandibular joint. Another approach is the submandibular incision which does not involve the temporal mandibular joint directly.

Sometimes, to obtain reduction of the fragments, an intraoral incision at the sigmoid notch region may be used [21, 22].

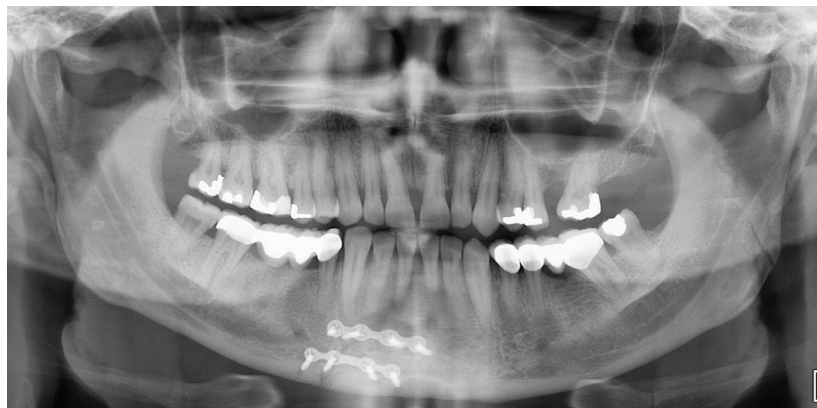### 6.3.2.4 Ramus fractures

Ramus fractures rarely require reduction. Chewing muscles adhering to the area effectively splint fractures. Elastic IMF is applied if occlusion is affected (**Figure 8**).

### 6.3.2.5 Angulus fractures

Triangular in shape, mandibular angle is the anatomic region between anterior border of masseter ligaments attachments and the most posterior superior attachment of masseter muscle. Angle fractures are anatomically unique regions that are developed laterally by the masseter and medially by medial pterygoid muscles which may stabilize the fracture in some situations. Vertical and horizontal fracture lines of this kind of fracture are essential for the reduction of choice. Also the presence of unerupted third molars in this region is the weak point of this anatomical region. Unfavorable fractures of angle fracture may displace medially. Accompanying fractures such as condyle may alter the displacement of angle fractures.

Access to the site is provided through various incisions, and incisions are made along the external oblique line. The plates should be placed so that they will not be directly under the incision line. Sometimes a transbuccal approach using a trocar may be required. Extraoral approaches may also be rarely used for angulus comminuted or pathological fracture reduction with Risdon incision just 1 cm below the angulus. Open reduction or closed reduction both can be used for this kind of fractures considering the complexity, age, displacement, and accompanying fractures to the angulus fracture. In open reduction monocortical single plate at the superior border of angulus as Champy's method or bicortical two mini-plates



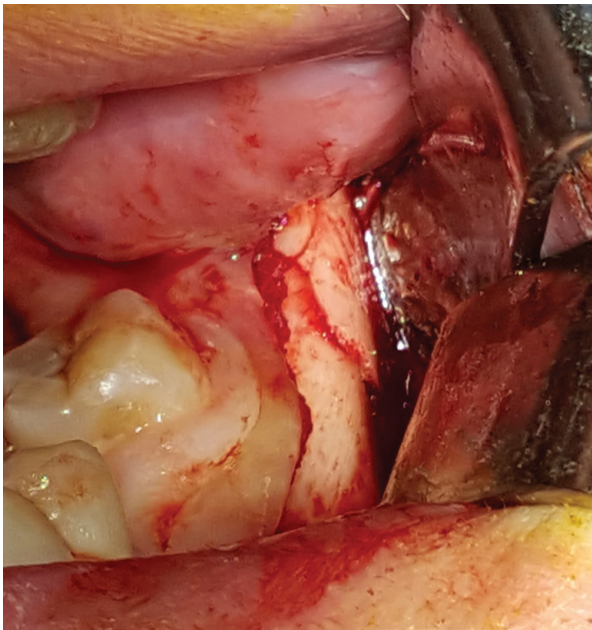**Figure 8.**  
*Parasymphysis fractures accompanying ramus fractures, rarely require reduction.*



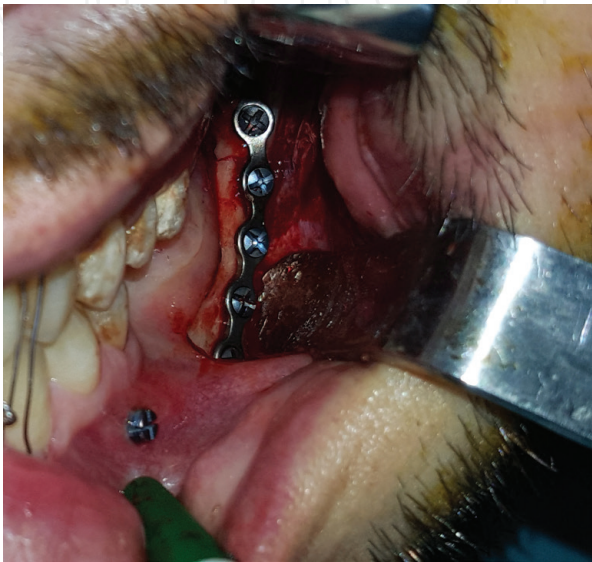can be selected as treatment method. Also the presence of uncontinuity defect or pathological fracture reconstruction plates should be consider fort the fracture managements. Load-sharing and load-bearing principles of fracture treatment must be the main guide as in all mandibular fractures [23] (**Figures 9 and 10**).

6.3.2.6. *Symphysis/parasymphysis fractures*

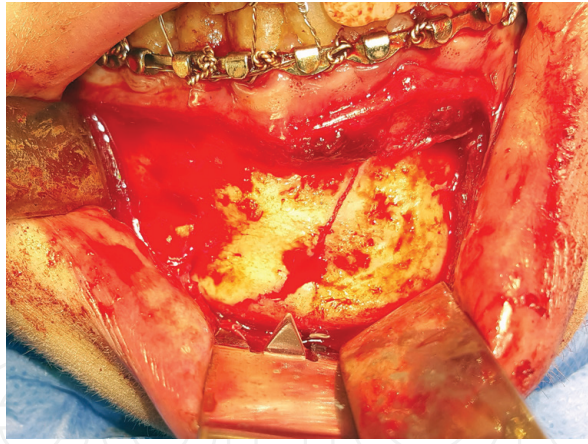Considering the treatment plan, it should be noted that this region is under the influence of torsion forces. Open reduction, especially for unfavorable displaced fractures, is mostly preferred because of the easy access and complex forces upon symphysis/parasymphysis region. Also closed reduction can be used for favorable and non-displaced fracture. Champy’s two-plate technique, one on tension and another on compression zone, is ideal for open reduction (**Figures 11–13**). Arch bar with one mini-plate at compression zone is also acceptable for fracture management. Anterior mandibular traumas should be evaluated very carefully.



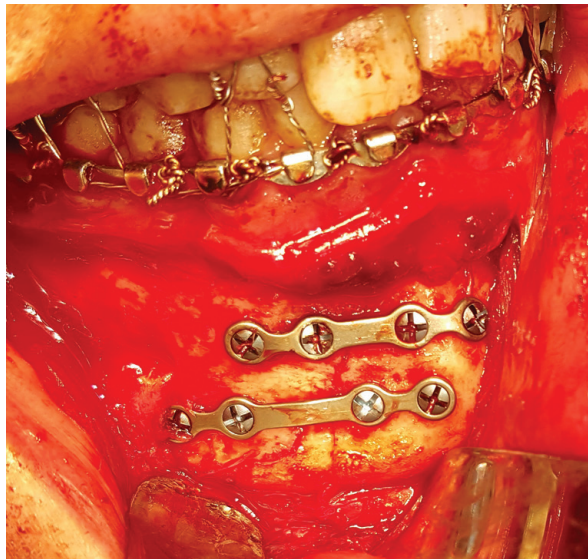**Figure 9.**  
*Angulus fracture.*



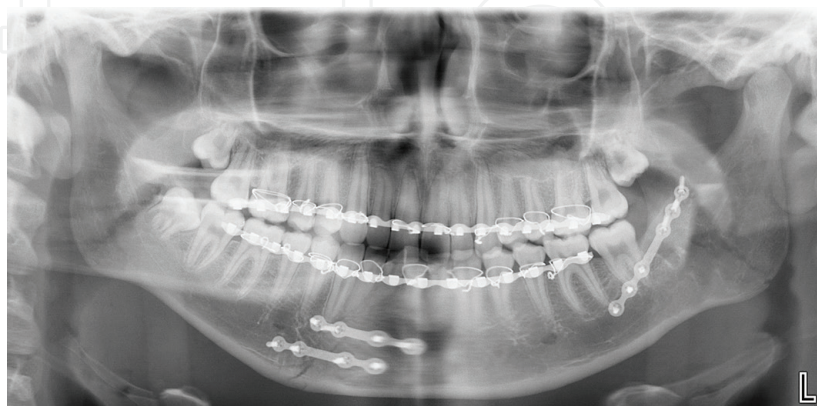**Figure 10.**  
*Open reduction with monocortical single plate at the superior border of angulus as Champy’s method.*



**Figure 11.**  
*Open reduction with monocortical with double plate, one at the superior border and the other at compression zone, as Champy's principle.*



**Figure 12.**  
*Open reduction with mini plates.*



**Figure 13.**  
*Radiological view of open reduction of right parasymphysis fractures accompanying left angulus fracture.*

Accompanying uni- or bilateral condyle fracture to symphysis/parasymphysis fractures is not rare.

Symphysis fractures can be treated either with closed or open reduction. Even though mini-plates are successful in the management of symphyseal fractures,



some clinicians prefer lag screws for rigid fixation. Lag screws have the advantage of needing minimal time and a minimal intraoral incision similar to the incision for genioplasty, which has cosmetic advantages [24].

In the 1990s the use of 3D plates for the management of mandibular fractures has started to be recommended. Unlike compression plates and mini-plates, these 3D plates are placed on the weak parts of the bone.

Even though not conclusive, recent studies show that 3D plates have better results in the condyle region with relatively poorer results in the body of the mandible, especially if the body is dentate.

#### *6.3.2.7. Mandibular body fractures*

Treatment principles of mandibular body fractures are based on Champy's line of osteosynthesis especially for simple fractures of the body. Intraoral access to this fracture is not difficult. One mini-plate at tension zone is sufficient for load-sharing fixation. Comminuted fractures may require additional mini-plates and screws. Also continuity defects such as pathological fractures need further load-bearing fixation systems such as reconplates. Mandibular continuity defects are defined as loss of the continuity of mandibular bone through a bone gap. Fractures close to mental foramen require additional care not to injure the mental nerve [17].

## **7. Timing of the surgical management**

Just like other anatomical regions, all fractures involving the mandible should be treated as soon as possible. However, an immediate intervention is rarely applicable.

In patients who do not have airway problems and who do not have severe painful fractures, treatment can be delayed to the next day even though in cases of open fractures, the risk of infection increases as the time passes.

## **8. Complications**

Infection is the most common complication within fracture management, especially in comminuted fractures and gunshots. Infection rates of authors vary between 0.4 and 32% [17, 25]. Postoperative infection increases the risks of the ununion and fibrous union of the fractures. Infection is not only the cause of the ununion or fibrous union of fractures, mobility and unstable fixation techniques also enhance ununion and fibrous unions in fractures. Fractures because of high-impact traumas, gunshot, or pathological fractures may cause hard and soft tissue lost which can result in esthetical and functional problems. In such cases extraoral surgical approaches may cause facial nerve damages. Inferior alveolar nerve injuries can be rarely seen in open reduction of parasymphysis and mandibular body fracture repairs. Hardware-related postoperative complications are hardware fails, screws and plate fractures, and tooth roots jeopardized by fixation screws.

## **9. Conclusion**

Mandibula is one of the the main skeletal component of the face and their fractures are among the most common traumatic injuries of the maxillofacial region which jeopardize both esthetic and function patients. The occlusion, form, and function should be all considered in the managements of mandibular fractures.

IntechOpen

### Author details

Guhan Dergin<sup>1\*</sup>, Yusuf Emes<sup>2</sup> and Buket Aybar<sup>2</sup>

1 Department of Oral and Maxillofacial Surgery, Faculty of Dentistry, Marmara University, Turkey

2 Department of Oral and Maxillofacial Surgery, Faculty of Dentistry, Istanbul University, Turkey

\*Address all correspondence to: guhandergin@yahoo.com

### IntechOpen

© 2019 The Author(s). Licensee IntechOpen. This chapter is distributed under the terms of the Creative Commons Attribution License (<http://creativecommons.org/licenses/by/3.0>), which permits unrestricted use, distribution, and reproduction in any medium, provided the original work is properly cited. 

## References

- [1] Stacey DH, Doyle JF, Mount DL, Snyder MC, Gutowski KA. Management of mandible fractures. *Plastic and Reconstructive Surgery*. 2006 Mar;**117**(3):48e-60e. DOI: 10.1097/01.prs.0000209392.85221.0b
- [2] Abotaleb BM, Al-Moraissi E, Zhiqiang W, Ping C, Yongjie K, Alkebsi K, et al. A detailed analysis of mandibular fractures epidemiology, treatment and outcomes: A 5-year retrospective study, Gansu Province-China. *Journal of Oral and Maxillofacial Surgery, Medicine, and Pathology*. 2018;**30**:197-205. DOI: 10.1016/J.AJOMS.2017.12.001
- [3] Fonseca RJ. *Oral and Maxillofacial Surgery*. Vol. 2. Saunders; 2017. pp. 146-172
- [4] Lee K. Global trends in maxillofacial fractures. *Craniofacial Trauma & Reconstruction*. 2012 Dec;**5**(4): 213-222. DOI: 10.1055/s-0032-1322535
- [5] Edwards TJ, David JD, Simpson DA, et al. Patterns of mandibular fractures in Adelaide, South Australia. *Australian and New Zealand Journal of Surgery*. 1994;**64**:307-311. DOI: 10.1111/j.1445-2197.1994.tb02216.x
- [6] Ellis E, Moos KF, El-Attar A. Ten years of mandibular fractures: An analysis of 2,137 cases. *Oral Medicine, Oral Pathology, Oral Surgery*. 1985;**59**:120-129. DOI: 10.1016/0030-4220(85)90002-7
- [7] Sakr K, Farag IA, Zeitoun IM. Review of 509 mandibular fractures treated at the University Hospital, Alexandria, Egypt. *The British Journal of Oral & Maxillofacial Surgery*. 2006;**44**:107-111. DOI: 10.1016/j.bjoms.2005.03.014
- [8] Escott EJ, Branstetter BF. Incidence and characterization of unifocal mandible fractures on CT. *American Journal of Neuroradiology*. 2008;**29**:890-894. DOI: 10.3174/ajnr.A0973
- [9] Romeo A, Pinto A, Cappabianca S, et al. Role of multidetector row computed tomography in the management of mandible traumatic lesions. *Seminars in Ultrasound, CT, and MR*. 2009;**30**:174-180. DOI: 10.1053/j.sult.2009.02.008
- [10] Schuknecht B, Graetz K. Radiologic assessment of maxillofacial, mandibular, and skull base trauma. *European Radiology*. 2005 Mar;**15**(3):560-568. Epub 2005 Jan 21. DOI: 10.1007/s00330-004-2631-7
- [11] Pickrell BB, Hollier LH. Evidence-based medicine: Mandible fractures. *Plastic and Reconstructive Surgery*. 2017 Jul;**140**(1):192e-200e. DOI: 10.1097/PRS.00000000000003469
- [12] Draper ERC. Basic biomechanics. In: SPF H, ID MC, editors. *Sciences Basic to Orthopaedics*. WB Saunders Company Limited; 1998. Chapter 14. pp. 201-212
- [13] Champy M, Loddé JP, Schmitt R, Jaeger JH, Muster D. Mandibular osteosynthesis by miniature screwed plates via a buccal approach. *Journal of Maxillofacial Surgery*. 1978;**6**(1):14e21. DOI: 10.1016/S0301-0503(78)80062-9
- [14] Andreasen JO. Etiology and pathogenesis of traumatic dental injuries: A clinical study of 1298 cases. *Scandinavian Journal of Dental Research*. 1970;**78**:329-342. DOI: 10.1111/j.1600-0722.1970.tb02080.x
- [15] Parameters of care. Clinical practice guidelines for oral and maxillofacial surgery (AAOMS ParCare 07); Version 4.0. *Journal of Oral and Maxillofacial Surgery*. 2007;238-24. (Suppl)

- [16] Brandt MT, Haug RH. Open versus closed reduction of adult mandibular condyle fractures: A review of the literature regarding the evolution of current thoughts on management. *Journal of Oral and Maxillofacial Surgery*. 2003;**61**:1324-1332. DOI: 10.1016/S0278-2391(03)00735-3
- [17] Omeje KU, Rana M, Adebola AR, Efunkoya AA, Olasoji HO, Purcz N, et al. Quality of life in treatment of mandibular fractures using closed reduction and maxillomandibular fixation in comparison with open reduction and internal fixation—A randomized prospective study. *Journal of Cranio-Maxillo-Facial Surgery*. 2014;**42**(8):1821-1826. DOI: 10.1016/j.jcms.2014.06.021
- [18] Smith BR, Teenier TJ. Treatment of comminuted mandibular fractures by open reduction and rigid internal fixation. *Journal of Oral and Maxillofacial Surgery*. 1996;**54**:328-331
- [19] Alpert B, Tiwana PS, Kushner GM. Management of comminuted fractures of the mandible. *Oral and Maxillofacial Surgery Clinics of North America*. 2009;**21**:185-192. DOI: 10.1016/j.coms.2008.12.002
- [20] Chrcanovic BR. Open versus closed reduction: Comminuted mandibular fractures. *Oral and Maxillofacial Surgery*. 2013 Jun;**17**(2):95-104. Epub 2012 Jul 29. DOI: 10.1007/s10006-012-0349-2
- [21] Zachariades N, Meztis M, Mourouzis C, et al. Fractures of the mandibular condyle: A review of 466 cases. Literature review and reflections on treatment and proposals. *Journal of Cranio-Maxillofacial Surgery*. 2006;**34**:421-432. DOI: 10.1016/j.jcms.2006.07.854
- [22] Khelemsky R, Moubayed SP, Buchbinder D. What is the evidence for open versus closed treatment of mandibular condylar fractures in adults? *The Laryngoscope*. 2016 Nov;**126**(11):2423-2425. DOI: 10.1002/lary.26076
- [23] Ellis E, Walker LR. Treatment of mandibular angle fractures using one non-compression miniplate. *Journal of Oral and Maxillofacial Surgery*. 1996;**54**:864-867. DOI: 10.1016/S0278-2391(96)90538-8
- [24] Kushner GM, Alpert B. Open reduction and internal fixation of acute mandibular fractures in adults. *Facial Plastic Surgery*. 1998;**14**(1):11-21. DOI: 10.1055/s-0028-1085298
- [25] Koury M. Complications of mandibular fractures. In: Kaban LB, Pogrel AAH, Perrot D, editors. *Complications in Oral and Maxillofacial Surgery*. Philadelphia: WB Saunders; 1997. pp. 121-146