

We are IntechOpen, the world's leading publisher of Open Access books Built by scientists, for scientists

6,900

Open access books available

186,000

International authors and editors

200M

Downloads

Our authors are among the

154

Countries delivered to

TOP 1%

most cited scientists

12.2%

Contributors from top 500 universities



WEB OF SCIENCE™

Selection of our books indexed in the Book Citation Index
in Web of Science™ Core Collection (BKCI)

Interested in publishing with us?
Contact book.department@intechopen.com

Numbers displayed above are based on latest data collected.
For more information visit www.intechopen.com



Introductory Chapter: Orofacial Sarcoidosis and Noncaseating Granulomatosis

*Sharareh Kamfar, Taghi Azizi and
Mohammad Hosein Kalantar Motamedi*

1. Introduction

Sarcoidosis is a multi-organ, granulomatous disease of unknown etiology characterized by T-cell dysfunction and B-cell hyperactivity with increased local immune activity and inflammation that leads to the formation of noncaseating granulomas in the organs involved [1]. The lung and lymphatic system are the most commonly affected organs, but virtually any organ may be affected [2]. Other common sites of involvement include the skin, eye, central nervous system (CNS), and the heart [3]. Patients may present with different symptoms related to the disease stage and the specific organ involved [4]. Sarcoidosis is a global disease, and its prevalence has increased twofold over the past years [5]. Due to the clinical heterogeneity and variable diagnostic criteria in different countries, it is difficult to calculate the exact prevalence and incidence of sarcoidosis. Age, sex, race, and geographic origin significantly influence the incidence rate of sarcoidosis [6]. A definite diagnosis of the disease when an identifiable etiology and definitive diagnostic criteria is lacking remains challenging [3].

2. Types

2.1 Head and neck sarcoidosis

This may occur in combination with, or independent of, CNS sarcoidosis; this has been found in 10–15% of patients with systemic disease [7].

2.2 Orofacial sarcoidosis

Although orofacial presentations of sarcoidosis are uncommon, it is important because of the fact that sarcoidosis in the orofacial region may indicate the development of systemic involvement [4]. Generally, in the case of orofacial sarcoidosis, swelling of the salivary glands is observed. Xerostomia may or may not be present; and bilateral enlargement of the parotid glands may be affected in 4–6% of the cases [8].

2.3 Orofacial granulomatosis

Orofacial granulomatosis (OFG), defined by Wiesenfeld in 1985, encompasses conditions characterized by non-necrotizing granulomatous inflammation of soft

tissues in the oral and maxillofacial region that present clinically with labial enlargement, perioral and/or mucosal swelling, oral ulcerations, gingivitis, and a variety of other orofacial features [9]. The clinical manifestations can be highly variable, and this variability makes it difficult to diagnose. OFG is a disease that encompasses a broad range of presentations, which may include oral manifestations of a systemic condition such as Crohn's disease (CD), sarcoidosis, granulomatosis with polyangiitis, and Melkersson-Rosenthal syndrome [10]. On the other hand, some studies say that OFG displays a spectrum of diseases ranging from granulomatous cheilitis to patients with granulomas involving other orofacial tissues, with or without facial nerve palsy and plicated tongue (Melkersson-Rosenthal syndrome) [11]. According to recent evidence, OFG can also be classified into three categories [12, 13], namely:

- OFG alone
- OFG with intestinal CD
- OFG with gastrointestinal granulomata but no symptoms of intestinal CD.

3. Etiology

The exact cause of OFG is yet to be elucidated, although various etiological agents have been proposed such as genetic predisposition, contact allergies, various microbiological agents, and immunologic causes [9]. The role of genetic predisposition has been evaluated in different studies, but there is a lack of conclusive evidence between HLA and pathogenesis of orofacial granulomatosis [14–16]; there is no evidence to support genetics causes for OFG [16]. Because of involvement of OFG in CD and sarcoidosis, the possible role of infections in the pathogenesis of OFG has been suggested [17]. Several studies have suggested that there is no conclusive evidence to support the role for allergy in OFG [18]. Recently, a monoclonal lymphocytic expansion in OFG lesion has been identified that may be responsible for the granuloma formation through cytokine production in lesions [19, 20].

4. Presentation

The diagnosis of OFG is based on clinical presentation, but it can be highly variable. The clinical features of OFG are mainly similar to orofacial manifestations of CD without apparent lesions in the bowels and may also mimic orofacial manifestations of sarcoidosis [21] labial enlargement, and sometimes oral ulcers are the main clinical features of OFG [22].

4.1 Lips

The lips are the most common sites of involvement in OFG. Labial swelling can involve the lower or upper lip or both. This feature of OFG is persistent but may eventually become recurrent. Each episode in this inflammatory process usually lasts several weeks to months [23]. The swelling varies in consistency from soft to rubbery [24].

4.2 Oral lesions

Three types of oral ulcers may occur in OFG as follows [25]:

- Chronic and deep ulcers in the buccal or labial vestibules with surrounding raised borders (most common).
- Superficial aphthous-like ulcers on any oral mucosal surface (less common).
- Pustules on the anterior gingivae and/or labial vestibules or soft palate (the least common).

4.3 Salivary gland

In asymptomatic patients, enlargement of the salivary glands is the first identifiable sign of the disease [8]. Involvement of salivary glands has been reported in the maxillofacial region that xerostomia or bilateral parotid swelling is the result of this involvement [26, 27]. Inflammation of salivary glands differentiates OFG from other granulomatous diseases such as cheilitis glandularis, Wegener's granulomatosis, sarcoidosis, and deep fungal infections [28].

5. Diagnosis

Since sarcoidosis is a multi-organ disorder, it can be difficult to diagnose with a single specific diagnostic test; and also, the presence of noncaseating granulomas alone does not confirm the presence of the disease because many other diseases can cause granulomas. On the other hand, these structures can be formed in various disorders [29]. In as much as in most cases of sarcoidosis, oral involvement often appears as the first manifestation of the disease; in diagnosis, the following criteria are considered [30]:

- Symptomatic oral manifestations
- Clinical and radiological findings compatible with a diagnosis of systemic sarcoidosis
- Pathologic evidence of noncaseating granulomas in the soft tissues of the oral cavity
- Exclusion of other causes of oral granulomatosis by histology of oral tissue biopsy negative for fungus
- No clinical evidence of other granulomatous diseases.

5.1 Differential diagnosis

As mentioned above, because of the same clinical features of orofacial lesions in granulomatous diseases, differential diagnoses must be considered for such diseases and other conditions including [31]:

- **Infections**, including tuberculosis, syphilis, leprosy, cat-scratch disease, and mycosis.
- **Crohn's disease** with the development of ulcers in the GI tract as the main manifestation.

- **Wegener's disease**, an uncommon necrotizing granulomatosis condition with a set of clinical manifestations with a different immunopathogenesis [32].
- **Foreign body granulomas**, formation of noncaseating granulomas and also labial and mucosal swellings with foreign bodies as the main characteristics of the disease [28].
- **OFG**, a condition that is restricted to the orofacial region (some diseases such as Crohn's disease, sarcoidosis, cheilitis granulomatosa, Wegener's granulomatosis, granulomatous infections, etc. can mimic its features), specifically lip swelling [33].

5.2 Diagnostic tests

Due to the ambiguity and difficulty in the exact diagnosis of granulomatous diseases and OFG, appropriate clinical and laboratory tests as well as radiographic and endoscopic investigations and also staining techniques and biopsy can be helpful to differentiate between such diseases.

Useful evaluations for differentiating granulomatous diseases include, as follows [28]:

- Biopsy: useful for the correct diagnosis.
- Microscopic investigations: for detection of granulomatous inflammation.
- Special stains: used to rule out deep fungal infections and bacterial infections.
- Polarized light microscopy: for identification of foreign bodies in the tissues.
- Chest radiography and assessment of serum levels of angiotensin-converting enzyme (ACE); complete blood count, erythrocyte sedimentation rate (ESR), and serum levels of folic acid, iron, and vitamin B12; and tuberculin skin test are done to assess whether a systemic disease is responsible for the granulomatous inflammation or not.
- Gastrointestinal evaluation is essential, especially in the presence of signs of anemia and intestinal malabsorption.

OFG: Blood tests, hemoglobin, C-1 esterase inhibitor, serum iron and transferrin, chest X-ray, and GI endoscopy/histopathology should be normal, and tuberculin skin test, PAS reaction and Ziehl-Neelsen stain, and polarized light microscopy for identification of foreign body materials should be negative. Also, noncaseating inflammation as well as elevated IgG and serum angiotensin-converting enzyme (ACE) levels are seen in this disease.

Crohn's disease: There are GI symptoms, decreased vitamin B12 and ferritin and increased CRP. Blood test, abdominal radiography, endoscopy, and colonoscopy should be considered.

Sarcoidosis: There are clinical symptoms, anemia, and also increased ESR, CPR, serum ACE, serum, and urinary calcium in sarcoidosis patients. Chest radiograph as well as negative microbial culture and negative staining are also helpful in diagnosis.

Wegener's granulomatosis: Clinical symptoms, vasculitis, and necrotizing granulomatosis are seen in this disease. Chest and sinus radiography as well as kidney function test anti-neutrophil cytoplasmic antibody (ANCA) and ESR should be done.

Tuberculosis: Caseating granuloma is seen in the disease. Ziehl-Neelsen staining, chest X-ray, PPD, and PAS test are used for diagnosis.

Leprosy: Granulomatous inflammation is present in this disease, and for more accurate diagnosis, PAS and acid-fast staining are done.

Foreign body granulomas: Noncaseating granulomatosis and foreign bodies are evident in this disease.

Cheilitis granulomatosa (CG): There is no evidence of GI involvement. Blood tests, chest radiography, and acid-fast staining should be done. Serum calcium and ACE and ESR are checked.

5.3 Histopathology

Histopathologic evaluation is one of the useful methods in OFG diagnosis. Several studies have demonstrated that OFG and Crohn's disease are similar with regard to their orofacial features and histopathology or may be similar to other granulomatous diseases; so it can be said that OFG is a diagnosis of exclusion [22]. Therefore, other complementary techniques like special stains for fungal infections or Ziehl-Neelsen for bacterial infections, negative microbial culture for sarcoidosis, etc. should be done to exclude other causes of granulomatous conditions.

Histopathological evidences indicate that in OFG lesions, noncaseating granulomas may not be present in all cases (from 43 to 82%) [11, 34–37] (**Figures 1** and **2**). Dilated lymphatics, edema of corium, slight fibrosis, with/without multiple noncaseating granulomas with Langerhans giant cells, and lymphocytes may be seen in OFG lesions [11] (**Figures 3** and **4**).

5.4 Treatment of OFG

The definite treatment of the disease in the lack of a causative factor remains to be elucidated. The first line in treatment is the use of local or systemic corticosteroids or both. Corticosteroids are effective in reducing facial swelling and preventing recurrence. Patients with mild swelling are treated locally [35]. Atrophy and hypopigmentation are the only side effects of local treatment, but side effects in the use of corticosteroids systemically are more important and must be avoided because of chronicity and recurrence of the disease and long-term nature of complications [38]. The use of triamcinolone 10 mg/ml is also often suggested in the treatment of local swellings of the lips [39].

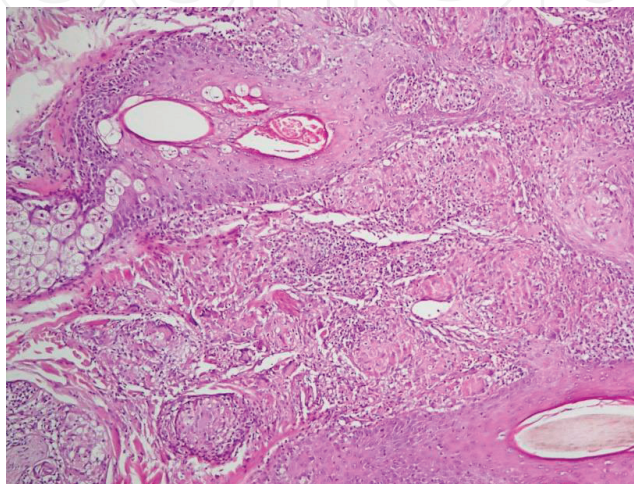


Figure 1.
Noncaseating granulomas of sarcoidosis in skin (H&E low power).

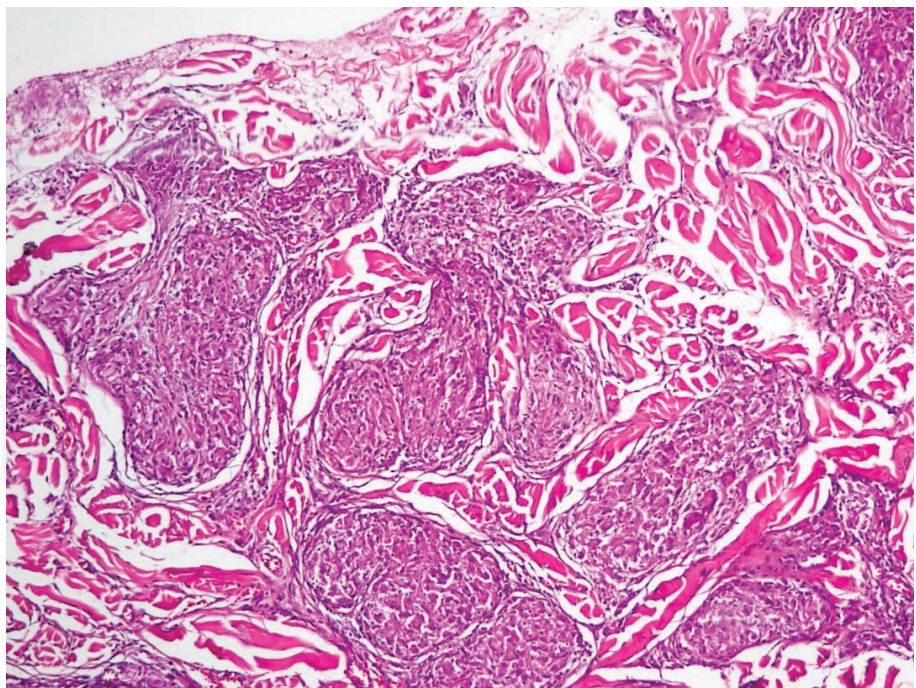


Figure 2.
Confluent noncaseating granulomatosis of sarcoidosis.

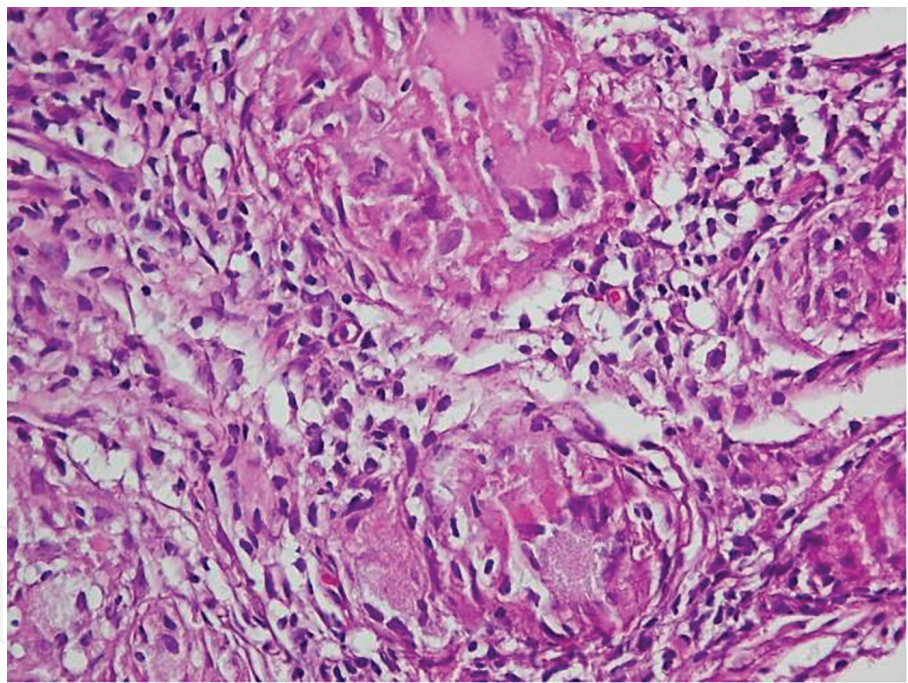


Figure 3.
Asteroid bodies and multinucleated giant cells in sarcoidosis.

Other suggested treatments for OFG in the literature include hydroxychloroquine [35, 40], methotrexate, clofazimine [35], metronidazole, minocycline [41] alone or in combination with oral prednisone, thalidomide [42, 43], dapsone, and danazol. Surgery may be used in cases that do not respond to medical treatment. Altogether, a good prognosis is predicted for OFG.

5.5 Prognosis

The pattern of onset in orofacial sarcoidosis in patients determines the course and prognosis of the disease and also therapeutic effects after treatment [44],

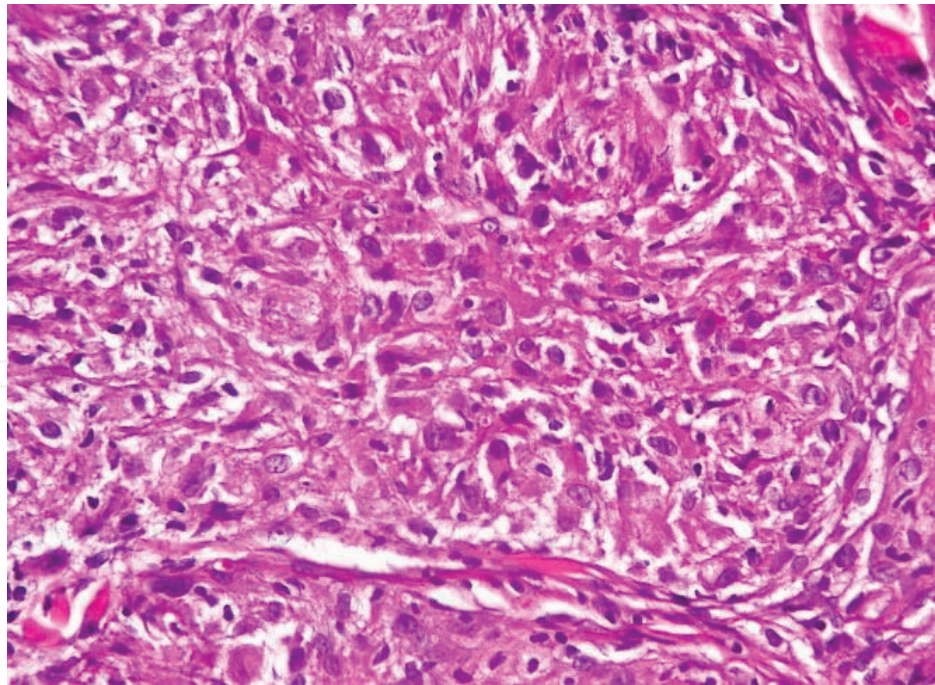


Figure 4.
Asteroid bodies and multinucleated giant cells in sarcoidosis (High-power view).

although affected patients may have a variety of nonspecific symptoms or may be asymptomatic. Oral involvement has been considered as the initial feature of the disease [45]. Although orofacial features in this disease are rare, a wide range of presentations indicates development of systemic involvement in present or future, so it must be considered. This disorder usually appears in the second and third decades of life [46] with no known racial predilection. In addition, it should be taken into consideration that women are more susceptible than men in this disease [47]. Moreover, death from sarcoidosis is a rare phenomenon except in special circumstances such as terminal fibrosis in the lungs, heart, or CNS [48]. Many patients with sarcoidosis (two-thirds) generally have a remission within a decade after diagnosis, with or without consequences.

6. Discussion

OFG is a rare disorder with unknown etiology. As mentioned, there are a variety of causative agents for OFG; but according to the accumulating data, there is no conclusive scientific evidence for the role of genetic susceptibility to the disease in the literature; so in this context, further studies are necessary [49]. Because of histopathological and clinical overlap in oral lesions of granulomatous diseases such as Crohn's disease, sarcoidosis, CG, foreign body granulomas, tuberculosis, etc. [50, 51], there is a controversial question between clinicians and pathologists that whether the formation of granulomas in the oral lesions is a distinct disease or just a feature of a systemic disease. OFG patients should be monitored for all of the symptoms in order to strengthen the possibility of OFG by exclusion of additional symptoms [28].

6.1 Organ involvement

Sarcoidosis is a multisystem disorder that may affect any organ system such as the lungs, lymph nodes, skin, eyes, liver, heart, and nervous, musculoskeletal, renal, and endocrine systems [52]. The lungs are the site of involvement and

granuloma formation [52]; 90% of patients have clinical manifestation of sarcoidosis in the lungs [53]. Oral involvement has been considered as the first feature of the disease although intraoral presentations of sarcoidosis and also tongue sarcoidosis are particularly rare and uncommon [54]. Sarcoidosis signs and symptoms vary depending on which organs are affected and also the stage of the disease [4].

6.2 Disease course

Disease course of sarcoidosis is usually favorable. Patients with asymptomatic organ involvement have a high rate of spontaneous resolution that often happens within 6 months of onset [3, 55]. Every 3 months in the first year after diagnosis, follow-up visits need to be carried out and after that once a year for 3–5 years in patients without problems [3, 56, 57]. In patients having a disease course that is progressive, immunosuppressive treatment is recommended. Long-term corticosteroids in patients must be limited because of major problems such as obesity and development of complicated metabolic syndrome [56, 58]. Mortality in sarcoidosis is low [59].

6.3 Diagnosis of exclusion

Without definitive diagnostic criteria, diagnosis of sarcoidosis requires exclusion of other granulomatous diseases such as tuberculosis, Crohn's disease, etc. [3]; therefore systemic disease evidence as well as compatible clinical and radiological abnormality, histological confirmation of noncaseating granulomas, and exclusion of other granulomatous diseases (that are able to present similar histological and clinical features) can be useful in the diagnosis [60].

6.4 Laboratory markers

Serum angiotensin-converting enzyme (ACE) is the first widely used marker that has been used as diagnostic and prognostic marker of sarcoidosis but has low specificity as a marker because of its poor predictive value [61–63]. In sarcoidosis, ACE is released by pulmonary endothelial cells into blood vessels to perform its functions. ACE is elevated in affected patients [64]. Serum ACE levels are currently considered as a marker of granuloma formation with limited sensitivity and specificity, and because of its limitation, it must be investigated with other markers in sarcoidosis. As mentioned before, ACE can be used for diagnosis and follow-up, but it must be correlated with clinical phenotypes and radiological findings [65]. In addition, several markers of inflammation that can be involved in the pathogenesis of the sarcoidosis have also been reported, which include lysozyme, cytokines, chemokines, and various molecules produced by activated macrophages or lymphocytes [66–68].

6.5 Pattern of onset

Sarcoidosis have been known as a time-limited disease with disease course of 1–3 years in half of the patients, less than 5 years in most remaining cases, and rarely for decades [69].

Abrupt onset is the characteristics of acute sarcoidosis, while chronic sarcoidosis has a progressive onset. According to the annual organ screening tests, most types of organ involvement in sarcoidosis occur within 2 years of the onset of disease [70]. For treatment and prognosis of sarcoidosis, mode of onset is one of the most valid factors [71].

6.6 Treatment outcome

Appropriate decision for treatment in sarcoidosis is difficult especially in the absence of a causative agent. Sarcoidosis treatment is proposed on the basis of prevalence of asymptomatic organ involvement, rate of spontaneous resolution, and complications of long-term corticosteroids therapy [3, 56]. There is a general rule that if only organ function is threatened, organ involvement should be treated [56, 57, 69]. Laboratory testing, biopsy, imaging studies, physical examination, and any other diagnostic tests are required before any treatment. For example, pulmonary function tests and stress testing are required before any treatment for pulmonary sarcoidosis [56]. Corticosteroid therapy is considered the first line in treatment for acute and chronic sarcoidosis and may be used alone or with other medications [57, 72]. Treatment of sarcoidosis is variable between asymptomatic cases and severe cases with systemic corticosteroid therapy [4]. For patients with neurological or ocular involvement or progressive respiratory disease, systemic therapy is prescribed [4]. Immunosuppressive combination therapy is the second line in treatment of sarcoidosis in order to limit the corticosteroid dose [55]. Accumulating evidence suggests that systemic corticosteroids should be used for at least 6 months and then should be reduced gradually [57].

7. Conclusion

OFG is an uncommon immunologically mediated disorder with unknown etiology that affects the soft tissues of the oral and maxillofacial region. Although the precise cause of OFG is still unknown, allergy, infection, and genetic predisposition as well as immunological reaction have been suggested as probable causes that can be effective in pathogenesis of OFG. Clinical features of OFG are nonspecific, and various presentations in disease make it difficult to diagnose, so a comprehensive clinical, laboratory, and microscopic evaluation is required for exact diagnosis and treatment [28]. A number of granulomatous disorders, such as deep fungal infections, tuberculosis, angioedema, leprosy, Wegener's granuloma, Crohn's disease, and sarcoidosis, are similar to OFG in clinical features specifically persistent lip swelling, so differential tests are needed for diagnosis of OFG [33]. Because of similarity between OFG and some of the granulomatous diseases, this point arises that whether or not OFG is a distinct clinical disorder [12]. In this context, further studies are needed to differentiate OFG from this group of disorders.

IntechOpen

Author details

Sharareh Kamfar¹, Taghi Azizi² and Mohammad Hosein Kalantar Motamedi^{3,4*}

1 Hamedan University of Medical Sciences, Hamedan, Iran

2 Baqiyatallah University of Medical Sciences, Tehran, Iran

3 Baqiyatallah University of Medical Sciences, Trauma Research Center, Tehran, Iran

4 Islamic Azad University of Medical Sciences, College of Dentistry, Craniomaxillofacial Research Center, Tehran, Iran

*Address all correspondence to: motamedical@yahoo.com

IntechOpen

© 2018 The Author(s). Licensee IntechOpen. This chapter is distributed under the terms of the Creative Commons Attribution License (<http://creativecommons.org/licenses/by/3.0>), which permits unrestricted use, distribution, and reproduction in any medium, provided the original work is properly cited. 

References

- [1] Patterson KC, Strek ME. Pulmonary fibrosis in sarcoidosis. Clinical features and outcomes. *Annals of the American Thoracic Society*. 2013;**10**(4):362-370
- [2] Iannuzzi MC, Fontana JR. Sarcoidosis: Clinical presentation, immunopathogenesis, and therapeutics. *Journal of the American Medical Association*. 2011;**305**(4):391-399
- [3] Baughman RP, Culver DA, Judson MA. A concise review of pulmonary sarcoidosis. *American Journal of Respiratory and Critical Care Medicine*. 2011;**183**(5):573-581
- [4] Poate T, Sharma R, Moutasim KA, Escudier M, Warnakulasuriya S. Orofacial presentations of sarcoidosis—A case series and review of the literature. *British Dental Journal*. 2008;**205**(8):437
- [5] Erdal BS, Clymer BD, Yildiz VO, Julian MW, Crouser ED. Unexpectedly high prevalence of sarcoidosis in a representative US metropolitan population. *Respiratory Medicine*. 2012;**106**(6):893-899
- [6] Nunes H, Soler P, Valeyre D. Pulmonary sarcoidosis. *Allergy*. 2005;**60**(5):565-582
- [7] Dash GI, Kimmelman CP. Head and neck manifestations of sarcoidosis. *The Laryngoscope*. 1988;**98**(1):50-53
- [8] Mandel L, Kaynar A. Sialadenopathy: A clinical herald of sarcoidosis: Report of two cases. *Journal of Oral and Maxillofacial Surgery*. 1994;**52**(11):1208-1210
- [9] Rana AP. Orofacial granulomatosis: A case report with review of literature. *Journal of Indian Society of Periodontology*. 2012;**16**(3):469
- [10] Mignogna MD, Fedele S, Lo Russo L, Lo Muzio L. Orofacial granulomatosis with gingival onset. *Journal of Clinical Periodontology*. 2001;**28**(7):692-696
- [11] Al Johani KA, Moles DR, Hodgson TA, Porter SR, Fedele S. Orofacial granulomatosis: Clinical features and long-term outcome of therapy. *Journal of the American Academy of Dermatology*. 2010;**62**(4):611-620
- [12] Sanderson J, Nunes C, Escudier M, Barnard K, Shirlaw P, Odell E, et al. Oro-facial granulomatosis: Crohn's disease or a new inflammatory bowel disease? *Inflammatory Bowel Diseases*. 2005;**11**(9):840-846
- [13] White A, Nunes C, Escudier M, Lomer MC, Barnard K, Shirlaw P, et al. Improvement in orofacial granulomatosis on a cinnamon- and benzoate-free diet. *Inflammatory Bowel Diseases*. 2006;**12**(6):508-514
- [14] Satsangi J, Jewell D, Rosenberg W, Bell J. Genetics of inflammatory bowel disease. *Gut*. 1994;**35**(5):696
- [15] Gibson J, Wray D. Human leucocyte antigen typing in orofacial granulomatosis. *British Journal of Dermatology*. 2000;**143**(5):1119-1121
- [16] Meisel-Stosiek M, Hornstein O, Stosiek N. Family study on Melkersson-Rosenthal syndrome. Some hereditary aspects of the disease and review of literature. *Acta Dermato-Venereologica*. 1990;**70**(3):221-226
- [17] O'Neill R, Penman R. 'Sarcoidosis' complicated with nocardiosis. *Journal of the Irish Medical Association*. 1969;**62**(386):287
- [18] Troiano G, Dioguardi M, Giannatempo G, Laino L, Testa NF, Cocchi R, et al. Orofacial granulomatosis: Clinical signs of different pathologies. *Medical Principles and Practice*. 2015;**24**(2):117-122

- [19] Lim S, Stephens P, Cao Q, Coleman S, Thomas D. Molecular analysis of T cell receptor beta variability in a patient with orofacial granulomatosis. *Gut*. 1997;**40**(5):683-686
- [20] De JQ, Cordel N, Bravard P, Lenormand B, Joly P, editors. Miescher's cheilitis and lymphocytic clonal expansion: 2 cases. *Annales de Dermatologie et de Vénéréologie*; Jan 2004. **131**(1 Pt 1):7-55
- [21] Wiesenfeld D, Ferguson M, Mitchell D, MacDonald D, Scully C, Cochran K, et al. Oro-facial granulomatosis—A clinical and pathological analysis. *QJM: An International Journal of Medicine*. 1985;**54**(1):101-113
- [22] Leao J, Hodgson T, Scully C, Porter S. Orofacial granulomatosis. *Alimentary Pharmacology & Therapeutics*. 2004;**20**(10):1019-1027
- [23] Odukoya O. Orofacial granulomatosis: Report of two Nigerian cases. *The Journal of Tropical Medicine and Hygiene*. 1994;**97**(6):362-366
- [24] Mignogna MD, Fedele S, Lo Russo L, Lo Muzio L. The multiform and variable patterns of onset of orofacial granulomatosis. *Journal of Oral Pathology & Medicine*. 2003;**32**(4):200-205
- [25] Clayden AM, Bleys CM, Jones SF, Saage NW, Aldred MJ. Orofacial granulomatosis: A diagnostic problem for the unwary and a management dilemma. Case reports. *Australian Dental Journal*. 1997;**42**(4):228-232
- [26] Clayman L, MacLennan M, Dolan RL. Nonpainful swelling of the palate and loosening of the maxillary incisors. *Journal of Oral and Maxillofacial Surgery*. 1998;**56**(11):1327-1335
- [27] Abul A, Onadeko B, Khadadah M, Behbehani N, Cerna M, Cherian J, et al. Clinical patterns of diffuse parenchymal lung disease in Kuwait: A prospective study. *Medical Principles and Practice*. 2004;**13**(2):78-83
- [28] Javadzadeh A, Pakfetrat A, Falaki F, Seyyedi S. Approach to orofacial granulomatosis and review of literature. *Journal of Islamic Dental Association of IRAN (JIDAI)*. 2012;**24**(3):3
- [29] Costabel U, Guzman J, Drent M. Diagnostic approach to sarcoidosis. *European Respiratory Monograph*. 2005;**32**:259
- [30] Bouaziz A, Le Scanff J, Chapelon-Abric C, Varron L, Khenifer S, Gleizal A, et al. Oral involvement in sarcoidosis: Report of 12 cases. *QJM: An International Journal of Medicine*. 2012;**105**(8):755-767
- [31] Islam NM, Bhattacharyya I, Cohen DM. Common oral manifestations of systemic disease. *Otolaryngologic Clinics of North America*. 2011;**44**(1):161-182
- [32] Swain S, Ray R. Wegener's granulomatosis of nose: A case report. *Indian Journal of Otolaryngology and Head & Neck Surgery*. 2011;**63**(4):402-404
- [33] Neville BW, Damm DD, Chi AC, Allen CM. Oral and Maxillofacial Pathology. *Oral Manifestations of Systemic Diseases*. Elsevier Health Sciences; 2015:566-570
- [34] Greene RM, Rogers RS III. Melkersson-Rosenthal syndrome: A review of 36 patients. *Journal of the American Academy of Dermatology*. 1989;**21**(6):1263-1270
- [35] Van Der Waal RI, Schulten EA, Van Der Meij EH, Van De Scheur MR, Starink TM, Van Der Waal I. Cheilitis granulomatosa: Overview of 13 patients with long-term follow-up—Results of management. *International Journal of Dermatology*. 2002;**41**(4):225-229

- [36] Kanerva M, Moilanen K, Virolainen S, Vaheri A, Pitkäranta A. Melkersson-Rosenthal syndrome. *Otolaryngology-Head and Neck Surgery*. 2008;**138**(2):246-251
- [37] McCartan B, Healy C, McCreary C, Flint S, Rogers S, Toner M. Characteristics of patients with orofacial granulomatosis. *Oral Diseases*. 2011;**17**(7):696-704
- [38] Mignogna M, Fedele S, Russo LL, Adamo D, Satriano R. Effectiveness of small-volume, intralesional, delayed-release triamcinolone injections in orofacial granulomatosis: A pilot study. *Journal of the American Academy of Dermatology*. 2004;**51**(2):265-268
- [39] Sakuntabhai A, MacLeod RI, Lawrence CM. Intralesional steroid injection after nerve block anesthesia in the treatment of orofacial granulomatosis. *Archives of Dermatology*. 1993;**129**(4):477-480
- [40] Allen CM, Camisa C, Hamzeh S, Stephens L. Cheilitis granulomatosa: Report of six cases and review of the literature. *Journal of the American Academy of Dermatology*. 1990;**23**(3):444-450
- [41] Olivier V, Lacour J, Castanet J, Perrin C, Ortonne J. Chéilite granulomateuse chez une enfant. *Archives de Pédiatrie*. 2000;**7**(3):274-277
- [42] Medeiros M, Araujo MI, Guimarães NS, Freitas LAR, Silva TMC, Carvalho EM. Therapeutic response to thalidomide in Melkersson-Rosenthal syndrome: A case report. *Annals of Allergy, Asthma & Immunology*. 2002;**88**(4):421-424
- [43] Hegarty A, Hodgson T, Porter S. Thalidomide for the treatment of recalcitrant oral Crohn's disease and orofacial granulomatosis. *Oral Surgery, Oral Medicine, Oral Pathology, Oral Radiology, and Endodontology*. 2003;**95**(5):576-585
- [44] James DG. Sarcoidosis 2001. *Postgraduate Medical Journal*. 2001;**77**(905):177-180
- [45] Jackowski J, Dragisic D, Arnold G, Dirschka T. Primary oral sarcoidosis preceding Lofgren's syndrome. *Oral Surgery, Oral Medicine, Oral Pathology, Oral Radiology, and Endodontics*. 2005;**100**(2):183-185
- [46] Lourenço SV, Lobo AZ, Boggio P, Fezzi F, Sebastiao A, Nico MMS. Gingival manifestations of orofacial granulomatosis. *Archives of Dermatology*. 2008;**144**(12):1627-1630
- [47] Marcoval J, Viñas M, Bordas X, Jucglà A, Servitje O. Orofacial granulomatosis: Clinical study of 20 patients. *Oral Surgery, Oral Medicine, Oral Pathology, and Oral Radiology*. Apr 2012;**113**(4):e12-e17. DOI: 10.1016/j.oooo.2011.10.011
- [48] Steinberg MJ, Mueller DP. Treating oral sarcoidosis. *Journal of the American Dental Association* (1939). 1994;**125**(1):76-79
- [49] Tilakaratne W, Freysdottir J, Fortune F. Orofacial granulomatosis: Review on aetiology and pathogenesis. *Journal of Oral Pathology & Medicine*. 2008;**37**(4):191-195
- [50] Garnuszewski Z. A case of tuberculosis of the tongue treated with streptomycin. *Gruzlica (Warsaw Poland: 1926)*. 1949;**17**(3-4):306-308
- [51] Crohn BB, Ginzburg L, Oppenheimer GD. Regional ileitis: A pathologic and clinical entity. *Journal of the American Medical Association*. 1932;**99**(16):1323-1329
- [52] Soumithran C, Bindu R, Shahi AK, Shaikh SF. Orofacial sarcoidosis. *Asian Journal of Oral and Maxillofacial Surgery*. 2005;**17**(4):280-283

- [53] Rotsinger J, Drake W. Sarcoidosis: Unknown etiology and genetic predisposition provides therapeutic challenges. *Journal of Pulmonary and Respiratory Medicine*. 2014;**4**(190):2
- [54] Mendelsohn S, Field E, Woolgar J. Sarcoidosis of the tongue. *Clinical and Experimental Dermatology*. 1992;**17**(1):47-48
- [55] Baughman RP, Judson MA. Relapses of sarcoidosis: What are they and can we predict who will get them? *European Respiratory Journal*. Feb 2014;**43**(2):337-339. DOI: 10.1183/09031936.00138913
- [56] Valeyre D, Prasse A, Nunes H, Uzunhan Y, Brillet P, Muller-Quernheim J. *Lancet*. 2014;**383**:1155-1167
- [57] Judson MA. The treatment of pulmonary sarcoidosis. *Respiratory Medicine*. 2012;**106**(10):1351-1361
- [58] Grutters J, Van den Bosch J. Corticosteroid treatment in sarcoidosis. *European Respiratory Journal*. 2006;**28**(3):627-636
- [59] Gerke AK. Morbidity and mortality in sarcoidosis. *Current Opinion in Pulmonary Medicine*. 2014;**20**(5):472
- [60] Costabel U, Bonella F, Ohshimo S, Guzman J, editors. Diagnostic modalities in sarcoidosis: BAL, EBUS, and PET. In: *Seminars in Respiratory and Critical Care Medicine*. © Thieme Medical Publishers; 2010
- [61] Sharma P, Smith I, Maguire G, Stewart S, Shneerson J, Brown MJ. Clinical value of ACE genotyping in diagnosis of sarcoidosis. *The Lancet*. 1997;**349**(9065):1602-1603
- [62] Stokes G, Monaghan J, Schrader A, Glenn C, Ryan M, Morris B. Influence of angiotensin converting enzyme (ACE) genotype on interpretation of diagnostic tests for serum ACE activity. *Australian and New Zealand Journal of Medicine*. 1999;**29**(3):315-318
- [63] Lieberman J. Elevation of serum angiotensin-converting-enzyme (ACE) level in sarcoidosis. *The American Journal of Medicine*. 1975;**59**(3):365-372
- [64] Studdy PR, Lapworth R, Bird R. Angiotensin-converting enzyme and its clinical significance—A review. *Journal of Clinical Pathology*. 1983;**36**(8):938-947
- [65] Schürmann M. Angiotensin-converting enzyme gene polymorphisms in patients with pulmonary sarcoidosis. *American Journal of Pharmacogenomics*. 2003;**3**(4):233-243
- [66] Rothkrantz-Kos S, van Dieijen-Visser MP, Mulder PG, Drent M. Potential usefulness of inflammatory markers to monitor respiratory functional impairment in sarcoidosis. *Clinical Chemistry*. 2003;**49**(9):1510-1517
- [67] Ziegenhagen M, Rothe M, Schlaak M, Müller-Quernheim J. Bronchoalveolar and serological parameters reflecting the severity of sarcoidosis. *European Respiratory Journal*. 2003;**21**(3):407-413
- [68] Rottoli P, Bargagli E. Is bronchoalveolar lavage obsolete in the diagnosis of interstitial lung disease? *Current Opinion in Pulmonary Medicine*. 2003;**9**(5):418-425
- [69] Hunninghake G. Statement on sarcoidosis. Joint Statement of the American Thoracic Society (ATS), the European Respiratory Society (ERS) and the World Association of Sarcoidosis and Other Granulomatous Disorders (WASOG) adopted by the ATS Board of Directors and by the ERS Executive Committee, February 1999. *American Journal of Respiratory and Critical Care Medicine*. 1999;**160**:736-755

[70] Prasse A. The diagnosis, differential diagnosis, and treatment of sarcoidosis. *Deutsches Ärzteblatt International*. 2016;**113**(33-34):565

[71] Siltzbach L, James DG, Neville E, Turiaf J, Battesti J, Sharma OP, et al. Course and prognosis of sarcoidosis around the world. *The American Journal of Medicine*. 1974;**57**(6):847-852

[72] Judson MA. An approach to the treatment of pulmonary sarcoidosis with corticosteroids: The six phases of treatment. *Chest*. 1999;**115**(4):1158-1165