

# We are IntechOpen, the world's leading publisher of Open Access books Built by scientists, for scientists

6,900

Open access books available

186,000

International authors and editors

200M

Downloads

Our authors are among the

154

Countries delivered to

TOP 1%

most cited scientists

12.2%

Contributors from top 500 universities



WEB OF SCIENCE™

Selection of our books indexed in the Book Citation Index  
in Web of Science™ Core Collection (BKCI)

Interested in publishing with us?  
Contact [book.department@intechopen.com](mailto:book.department@intechopen.com)

Numbers displayed above are based on latest data collected.  
For more information visit [www.intechopen.com](http://www.intechopen.com)



# Neurologic Complications of Varicella-Zoster Virus Infection

*Hideto Nakajima, Makoto Hara, Akihiko Morita  
and Satoshi Kamei*

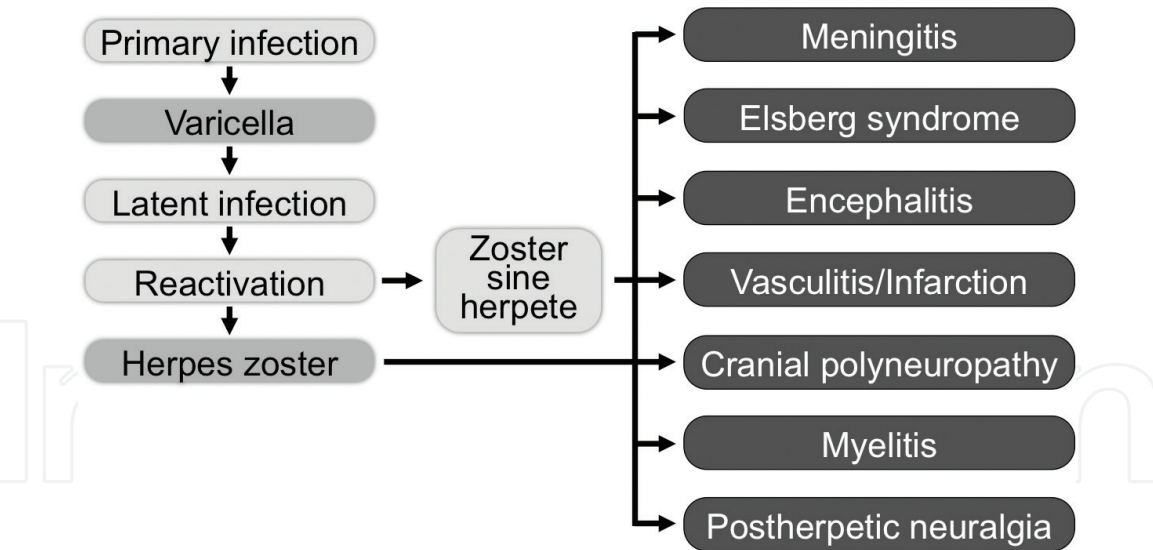
## Abstract

Varicella-zoster virus (VZV) causes a diverse spectrum of neurologic complications: aseptic meningitis, encephalitis, cerebral infarction associated with granulomatous vasculitis, myelitis, and cranial polyneuropathy. These VZV-associated central nervous system (CNS) diseases usually result from reactivation of latent infection in immunosuppressive conditions, such as old age, diabetes mellitus, cancer, human immunodeficiency virus (HIV) infection, and the use of immunosuppressive drugs. However, they also occur in immunocompetent subjects. Since VZV antigen or DNA is often detected in the cerebrospinal fluid of these patients, it is thought that reactivated VZV reaches the central nervous system by direct spread from latently infected sensory ganglia. Analysis of cerebrospinal fluid by PCR is important for the diagnosis of VZV-associated CNS diseases particularly in the absence of exanthema/herpes zoster. Clinicians should be aware of the neurologic complications of VZV infection, because early acyclovir therapy is necessary for these disorders.

**Keywords:** varicella-zoster virus (VZV), neurologic infections, central nervous system (CNS), encephalitis, meningitis

## 1. Introduction

The clinical manifestations of varicella-zoster virus (VZV) infections of the central nervous system (CNS) include aseptic meningitis, encephalitis, cerebral infarction associated with granulomatous vasculitis, myelitis, and multiple cranial neuropathies (**Figure 1**) [1–4]. In these patients, viral antigens or DNA are often detected in the cerebrospinal fluid (CSF) or the sites of pathology. Thus, those neurological disorders reflect reactivation of latent VZV in the trigeminal ganglia and dorsal root ganglion, with subsequent spread of the infection into the CNS [1]. In addition, the incidence of CNS complications caused by VZV is more likely higher in elderly individuals; those with underlying diseases, such as malignant tumors and HIV; and those who are immunosuppressed due to the use of steroids or immunosuppressive drugs [5–8]. However, it can also affect healthy individuals; therefore, these CNS VZV infections may be suspected even in patients without underlying diseases. Among CNS infections caused by VZV, diseases other than meningitis are rare; however, clinicians should be aware of the various clinical features of CNS infections caused by VZV to start early and accurate antiviral drugs for treatment.



**Figure 1.**  
*Neurological complications associated with VZV reactivation.*

**2. Zoster sine herpete**

If neurological symptoms occur simultaneously or around the same time as the onset of herpes zoster infection, they can be considered complications of VZV infections. However, if lesions such as rashes, shingles, or blisters are not observed, VZV as a causative agent is likely to be missed. In fact, because VZV can cause CNS complications in the absence of skin lesions, such cases are referred to as zoster sine herpete [9]; clinicians have to consider the possibility of VZV as a causative virus in patients with neurological infections, such as meningitis or encephalitis (**Figure 1**).

**3. Aseptic meningitis**

Meningitis is inflammation of the pia mater and the arachnoid that cover the surface of the brain. Its clinical signs include fever, headache, nausea, vomiting, and meningeal irritation symptoms, such as nuchal rigidity and Kernig’s sign. Furthermore, jolt accentuation and neck flexion tests are often positive. However, these are common symptoms and findings of meningitis regardless of the cause. The CSF examination shows monocyte-dominant pleocytosis and elevated protein levels with normal glucose levels. Patients with meningitis wherein bacteria are not detected via the CSF test are generally diagnosed as having aseptic meningitis. Most cases of aseptic meningitis involve viral meningitis. The most common virus that causes viral meningitis is enterovirus. In adults, enterovirus is followed by herpes simplex virus type 2 (HSV-2) and VZV [10], and VZV infection accounts for 8% of the total meningitis cases [11].

VZV meningitis can sometimes cause cranial polyneuropathy or dysuria due to sacral radiculopathy, and dysuria due to sacral radiculopathy is known as Elsberg syndrome. Meningitis caused by VZV is also frequently observed among healthy young individuals. Such a condition generally has a good prognosis and rarely causes any sequelae.

**4. Elsberg syndrome**

Elsberg syndrome is caused by bilateral sacral radiculopathy, which is characterized by urinary retention, sensory disturbance, and neuralgia of the perineum

and lower limbs. Although Elsberg syndrome was originally characterized by urinary retention due to sacral radiculopathy associated with genital herpes, it is now defined as aseptic meningitis-associated sacral radiculopathy. As the causative virus, HSV, particularly HSV-2, is the most common cause, followed by VZV [12, 13]. When urinary retention occurs, urethral catheterization is required. However, this condition resolves as meningitis improves.

#### **4.1 Case 1: Elsberg syndrome**

A 32-year-old man was admitted to our hospital because of high fever, headache, nausea, acute urinary retention, and dysesthesia in a lumbosacral dermatome distribution. There were no motor symptoms and no rash. CSF analysis showed 249 leukocytes/mm<sup>3</sup>, 70 mg/dl protein, and positive of VZV DNA by PCR. Gadolinium-enhanced MRI revealed the meningeal lesions of the conus medullaris and the swollen radicular fibers in the upper lumbar spinal canal. Treatment of acyclovir and dexamethasone for 2 weeks led to complete resolution of meningitis and urinary retention.

### **5. Encephalitis and cerebral infarction associated with granulomatous vasculitis**

The symptoms of encephalitis include acute disturbance of consciousness, headache, fever, and convulsions. Neurological findings of encephalitis include meningeal irritation symptoms, such as nuchal rigidity; however, patients with encephalitis sometimes present with motor paralysis and sensory disturbance due to parenchymal brain damage.

Among the pathogens that cause viral encephalitis, VZV is the second most common cause following HSV, accounting for 5% of the total encephalitis cases [14]. According to a recent analysis that used PCR, though, the risk of VZV encephalitis increases in elderly individuals, those with herpes zoster ophthalmicus, and those with disseminated herpes zoster, and this result indicates that the incidence of VZV encephalitis might have increased [15].

The clinical manifestations of VZV encephalitis include meningoencephalitis and vasculopathy [16]. The meningoencephalitis form shows no detectable lesions on MRI. In contrast, the vasculopathy form is characterized by non-specific ischemia, hemorrhagic lesions, and multiple white matter lesions on MRI [16]. Pathological studies suggested that VZV encephalitis develops based on vasculopathy in the large and small vessels. Therefore, MRI typically demonstrates ischemic or hemorrhagic infarction in both gray and white matter and particularly at gray-white matter junctions as characteristic imaging findings of VZV encephalitis [16]. In VZV encephalitis, lesions in the temporal lobe and limbic system, which are often observed in patients with herpes simplex encephalitis, are rare. Moreover, hemorrhagic lesions and necrosis, which are characteristics of herpes simplex encephalitis, are not commonly observed. Because VZV DNA is generally detected in the CSF of adult patients with VZV encephalitis, direct viral invasion to the CNS is believed to be the pathology of VZV encephalitis. In contrast, in varicella encephalitis in children who develop acute cerebellar ataxia associated with varicella infection, VZV is not detected in the CSF. Therefore, a secondary immunological allergic mechanism is considered as the pathology of varicella encephalitis.

Cerebral infarction caused by granulomatous vasculitis is a complication of herpes zoster infection [1, 17]. A typical patient presents with herpes zoster ophthalmicus, followed by postherpetic contralateral hemiplegia, and develops cerebral infarction between the eighth day and sixth month after herpes zoster infection

(average of 7 weeks) [18, 19]. Patients with cerebral infarction often present with stenosis or obstruction in the anterior cerebral artery or middle cerebral artery. Because VZV DNA and antigens are detected in the walls of cerebral arteries, this evidence should provide an anatomic pathway for transaxonal spread of VZV after reactivation from trigeminal ganglia as a mechanism of intracerebral VZV vasculopathy [20–22]. The incidence of stroke increases 6 months after the onset of herpes zoster infection [23], and VZV vaccine and antiviral drug therapy may help reduce the risk of stroke after herpes zoster infection [24]. Cerebral infarction can also develop after varicella infection in children [25]. Although it is rare, it occurs within 6 months after varicella infection, and a similar mechanism as cerebral infarction after varicella zoster infection is considered [25]. In these conditions, VZV, which causes latent infection in the trigeminal ganglion after varicella infection, reactivates and directly invades the vessels in the CNS.

5.1 Case 2: meningoencephalitis

The patient was a 77-year-old woman who was admitted to our hospital due to convulsions and impaired consciousness. She presented with a Glasgow Coma Scale score of E1V1M4, and positive nuchal rigidity was observed. The convulsions were treated with the intravenous injection (IV) of diazepam and intramuscular injection of phenobarbital. However, the patient had high fever after admission at the hospital. CSF examination showed increased cell count (125.0 mg/dl), elevated protein level (125.0 mg/dl), and positivity for VZV DNA, and she was then diagnosed with VZV infection. The patient was treated with acyclovir and dexamethasone, and she regained consciousness and was able to talk on the second day of hospitalization. On the seventh day, she recovered with lucid consciousness without sequelae (Figure 2). Her MRI showed no abnormal lesions in the brain parenchyma, and she was diagnosed with meningoencephalitis.

5.2 Case 3: cerebral infarction associated with granulomatous vasculitis

The patient was a 76-year-old man who developed infarction in the right medial hypothalamus 34 days after the onset of right ophthalmic herpes zoster. He further

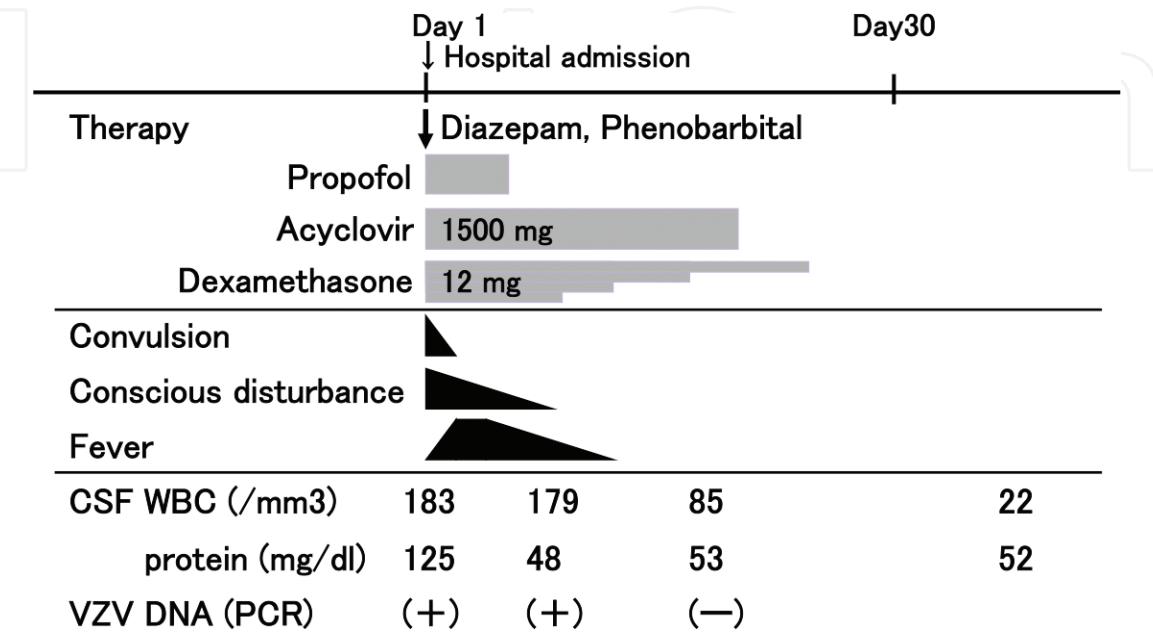


Figure 2.  
Clinical course (Case 1).



developed an infarction in the right occipital lobe 73 days after the onset of herpes zoster infection. Although the MRI obtained while the patient presented with herpes zoster rash did not show any abnormal findings, the MRI performed 73 days later showed severe stenosis of the posterior communicating artery.

### **5.3 Case 4: cerebral infarction associated with granulomatous vasculitis**

The patient was a 52-year-old woman with systemic lupus erythematosus (SLE) who exhibited altered levels of consciousness during immunotherapy for SLE. The CSF test showed pleocytosis, an elevated protein level, and positivity for VZV DNA, and the patient was then diagnosed with VZV meningoencephalitis. Brain MRI showed cerebral infarction in the left cerebral white matter, and MR angiogram showed stenosis of the left middle cerebral artery.

## **6. Cranial polyneuropathy**

Cranial nerve palsy can sometimes develop in patients with herpes zoster of face or neck regions. Facial nerve palsy accompanying herpes zoster infection is known as Ramsay Hunt syndrome, and those patients often exhibit cranial polyneuropathy [26, 27]. Lower cranial polyneuropathy causes dysphagia, dysarthria, and hoarseness. Furthermore, there was no elevation or constriction in the unilateral soft palate, and tongue deviation and muscular weakness of the sternocleidomastoid and trapezius muscles were observed due to unilateral glossopharyngeal, vagus, accessory, and hypoglossal nerve paralyzes. Cranial polyneuropathy is often accompanied by meningitis, and CSF examination showed pleocytosis and elevated protein levels. In most cases, brain MRI shows no abnormalities. However, contrast MRI sometimes shows enhancement in the affected cranial nerves. As a mechanism of this condition, reactivation of VZV from the geniculate ganglion could result in inflammatory process, circulatory disturbance, or edema to involve cranial nerves [28].

### **6.1 Case 5: lower cranial polyneuropathy**

A 64-year-old woman developed acute paralysis of the IX, X, XI, and XII nerves on the left side after experiencing pain in the left ear and throat. CSF examination revealed lymphocytic pleocytosis and elevated protein levels. VZV DNA was detected with PCR using CSF. She was diagnosed with cranial polyneuropathy due to VZV reactivation. After the oral administration of antiviral agent and steroid, all signs and symptoms dramatically improved. Notably, there was no evidence of cutaneous or mucosal rash during the entire course of the disease. VZV reactivation should be included in the differential diagnosis of multiple cranial nerve palsies, particularly with pain and even without rash.

### **6.2 Case 6: lower cranial polyneuropathy**

The patient was a 66-year-old man who presented with dysphagia and hoarseness 2 days after the onset of pain in the left occipital region to the shoulder. At an otorhinolaryngology clinic, recurrent nerve paralysis was observed, and lesions of herpes zoster were noted in the left side of the neck. Left glossopharyngeal, vagal, accessory, and hypoglossal nerve paralyzes were observed during neurological examination. CSF examination showed increased cell count and positivity for VZV DNA, and the patient was diagnosed with multiple lower cranial polyneuropathy.

## **7. Myelitis**

VZV myelitis is a rare clinical manifestation. However, Brown-Séquard syndrome and transverse myelopathy may occur as a complication of herpes zoster infection [6, 7, 29–31]. Previous reports revealed that myelitis occurred in elderly or immunocompromised patients, such as those with HIV infection, and this condition often had severe sequelae such as motor paralysis [6, 7]. MRI shows low to equal signal intensity on T1-weighted images and high signal intensity on T2-weighted images, and sometimes, contrast enhancement can be observed as spinal cord lesions. In addition, MRI enhancement may be observed not only in the lesions in the spinal cord but also in the meninges around the spinal cord as well as in the dorsal root nerve, and these findings indicate myeloradiculitis.

Myelitis is often characterized by myelopathy at a level consistent with the spinal segment affected by herpes zoster. As a pathogenesis of this condition, reactivated VZV in the dorsal root ganglion of the spinal cord directly invades the spinal cord from the dorsal root nerve, resulting in myelitis [6, 7]. Moreover, spinal cord lesions are caused by vasculopathy, such as damage to the anterior spinal artery due to vasculitis, similar to cerebral infarction after herpes zoster infection, and this may be considered another mechanism.

### **7.1 Case 7: myelitis**

The patient was a 60-year-old man with right lower extremity paralysis and sensory disturbance of the right trunk and lower extremity who was diagnosed with VZV myelitis based on CSF examination. MRI of the spinal cord showed a high-signal lesion in the right posterior funiculus at the thoracic vertebral level of Th6 and Th7, which should indicate that VZV directly invaded the spinal cord from the dorsal root.

### **7.2 Case 8: myelitis**

An 87-year-old woman developed weakness of the right lower limb 2 days after developing herpes zoster lesions in the right side of the chest. Neurological examination revealed a spastic palsy in the right lower limb and loss of pain and temperature sensation in the left side to T6. However, vibration and position senses were not impaired in both sides. Thus, the patient presented with incomplete Brown-Séquard syndrome. Spinal T2-weighted MRI images showed a high-intensity lesion in the right side of the spinal cord except at the posterior funiculus at the Th2 level. CSF analysis showed the following results: leukocyte count,  $109/\text{mm}^3$ , and protein level, 79 mg/dl, as well as negativity for VZV PCR, elevated titer levels for anti-VZV IgM and IgG, and increased IgG index. Although she was treated with a combination of acyclovir and steroid pulse therapy, her weakness in the right lower limb did not improve. In this case, because the posterior funiculus circulating from the posterior spinal artery was not involved, the incomplete Brown-Séquard syndrome may have been caused by spinal cord infarction due to VZV vasculitis of the anterior spinal artery.

## **8. Postherpetic neuralgia**

Although most cases of acute herpes zoster are self-limited, about 10–15% of patients with herpes zoster will develop postherpetic neuralgia (PHN) [32], particularly in older adults [33]. Immunosuppressed patients have a higher incidence of PHN. PHN refers to pain persisting for months to years after the resolution of the

rash. Sensory symptoms can include pain, numbness, dysesthesias, and allodynia (pain precipitated by movement) in the affected dermatome. And these symptoms may be severe enough to restrict sleep, appetite, or daily activities. The diagnosis of PHN is clear-cut and could be made if those sensory symptoms including pain persist beyond 4 months in the same distribution as a preceding episode of acute herpes zoster [34]. Gabapentin, pregabalin, tricyclic antidepressants, and opioids are generally the first-line drugs for the treatment of PHN [35–37]. Vaccines are also available for prevention of acute zoster and PHN [38, 39].

## 9. Diagnosis

For the diagnosis of CNS infection caused by VZV, the detection of VZV DNA with PCR using CSF is necessary [40–42]. However, a negative VZV DNA result does not rule out VZV infection, and particularly, PCR examination after the initiation of antiviral treatment will likely turn out negative. Thus, testing should be conducted using CSF before the antiviral treatment. When measuring anti-VZV antibodies, a significant increase of the anti-VZV antibody titer in CSF over the course of the illness or findings suggesting the production of intrathecal antibody [serum/CSF antibody ratio  $\leq 20$  or antibody titer index = (CSF antibody/serum antibody)/(CSF albumin/serum albumin  $\geq 2$ )] should be confirmed.

## 10. Therapy

Antiviral therapy with intravenous acyclovir (10 mg/kg intravenous every 8 hours) should be initiated as soon as the diagnosis is considered [43]. Although the prognosis of meningitis is good, encephalitis and myelitis often result in sequelae, and a delay in the initiation of acyclovir treatment leads to poor prognosis. Therefore, if CNS infection caused by VZV is suspected based on clinical symptoms as well as CSF examination and imaging findings, the administration of acyclovir must be immediately initiated. According to a recent study from the UK, some causative pathogens were identified in 42% of acute encephalitis cases, of which HSV or VZV was identified in one-fourth of the cases. Thus, the administration of acyclovir should be immediately initiated if encephalitis is clinically suspected, and then, acyclovir should be administered for 2 weeks in an immunocompetent host and for 3 weeks in an immunosuppressive host if encephalitis caused by HSV or VZV is confirmed [5]. In CNS infection caused by VZV, the standard administration period is similar. There is no evidence showing the therapeutic effect of adjunctive corticosteroid use. However, corticosteroids suppress the inflammatory response accompanied by cytotoxicity due to the host immune response to viral infection, and in cases of encephalitis/vasculitis, myelitis, and cranial polyneuropathy, the adjunctive administration of dexamethasone or steroid pulse therapy with acyclovir is recommended.

## 11. Conclusions

VZV causes the diverse spectrum of neurologic complications: aseptic meningitis, encephalitis, cerebral infarction associated with granulomatous vasculitis, myelitis, and cranial polyneuropathy. Clinicians should be aware of the neurologic complications of VZV, because early acyclovir therapy is necessary for these disorders.



## Acknowledgements

The authors would like to express their gratitude to Dr. Mitsuru Matsuki (Radiology, Kindai University), Dr. Takafumi Hosokawa (Neurology, Osaka Medical College), Dr. Shinichi Haginomori (Otorhinolaryngology, Osaka Medical College), Dr. Hiroshi Yamamoto (Radiology, Sumitomo Hospital), and Dr. Mitsuyosi Ayabe and Dr. Kazuhito Noda (Neurology, Kurume University) for providing the information of the cases.

This work was supported by JSPS KAKENHI, Grant Number 16 K09704, from the Ministry of Education, Culture, Sports, Science and Technology, Japan.

## Conflict of interest

The authors declare no conflicts of interest.

## Author details

Hideto Nakajima\*, Makoto Hara, Akihiko Morita and Satoshi Kamei  
Division of Neurology, Department of Internal Medicine, Nihon University School of Medicine, Tokyo, Japan

\*Address all correspondence to: nakajima.hideto@nihon-u.ac.jp

## IntechOpen

© 2019 The Author(s). Licensee IntechOpen. This chapter is distributed under the terms of the Creative Commons Attribution License (<http://creativecommons.org/licenses/by/3.0>), which permits unrestricted use, distribution, and reproduction in any medium, provided the original work is properly cited. 

## References

- [1] Echevarría JM, Casas I, Martínez-Martín P. Infections of the nervous system caused by varicella-zoster virus: A review. *Intervirology*. 1997;**40**:72-84. DOI: 10.1159/000150535
- [2] Straus SE, Ostrove JM, Inchauspé G, Felser JM, Freifeld A, Croen KD, et al. NIH conference. Varicella-zoster virus infections. Biology, natural history, treatment, and prevention. *Annals of Internal Medicine*. 1988;**108**(2):221-237
- [3] Oxman MN. Immunization to reduce the frequency and severity of herpes zoster and its complications. *Neurology*. 1995;**45**(12 Suppl 8):S41-S46
- [4] Galil K, Choo PW, Donahue JG, Platt R. The sequelae of herpes zoster. *Archives of Internal Medicine*. 1997;**157**(11):1209-1213
- [5] Gnann JW Jr. Varicella-zoster virus: Atypical presentations and unusual complications. *The Journal of Infectious Diseases*. 2002;**186**(Suppl 1):S91-S98. DOI: 10.1086/342963
- [6] Manian FA, Kindred M, Fulling KH. Chronic varicella-zoster virus myelitis without cutaneous eruption in a patient with AIDS: Report of a fatal case. *Clinical Infectious Diseases*. 1995;**21**(4):986-988
- [7] Chrétien F, Gray F, Lescs MC, Geny C, Dubreuil-Lemaire ML, Ricolfi F, et al. Acute varicella-zoster virus ventriculitis and meningo-myelo-radiculitis in acquired immunodeficiency syndrome. *Acta Neuropathologica*. 1993;**86**(6):659-665
- [8] Glesby MJ, Moore RD, Chaisson RE. Clinical spectrum of herpes zoster in adults infected with human immunodeficiency virus. *Clinical Infectious Diseases*. 1995;**21**(2):370-375
- [9] Gilden DH, Kleinschmidt-DeMasters BK, LaGuardia JJ, Mahalingam R, Cohrs RJ. Neurologic complications of the reactivation of varicella-zoster virus. *The New England Journal of Medicine*. 2000;**342**(9):635-645. DOI: 10.1056/NEJM200003023420906
- [10] Ihekweba UK, Kudesia G, McKendrick MW. Clinical features of viral meningitis in adults: Significant differences in cerebrospinal fluid findings among herpes simplex virus, varicella zoster virus, and enterovirus infections. *Clinical Infectious Diseases*. 2008;**47**(6):783-789. DOI: 10.1086/591129
- [11] Kupila L, Vuorinen T, Vainionpää R, Hukkanen V, Marttila RJ, Kotilainen P. Etiology of aseptic meningitis and encephalitis in an adult population. *Neurology*. 2006;**66**:75-80. DOI: 10.1212/01.wnl.0000191407.81333.00
- [12] Eberhardt O, Küker W, Dichgans J, Weller M. HSV-2 sacral radiculitis (Elsberg syndrome). *Neurology*. 2004;**63**(4):758-759
- [13] Abe M, Araoka H, Kimura M, Yoneyama A. Varicella zoster virus meningoencephalitis presenting with Elsberg syndrome without a rash in an immunocompetent patient. *Internal Medicine*. 2015;**54**(16):2065-2067. DOI: 10.2169/internalmedicine.54.4341
- [14] Granerod J, Ambrose HE, Davies NW, Clewley JP, Walsh AL, Morgan D, et al. Causes of encephalitis and differences in their clinical presentations in England: A multicentre, population-based prospective study. *The Lancet Infectious Diseases*. 2010;**10**:835-844. DOI: 10.1016/S1473-3099(10)70222-X
- [15] Braun-Falco M, Hoffmann M. Herpes zoster with progression to acute varicella zoster virus-meningoencephalitis. *International*

Journal of Dermatology.  
2009;**48**(8):834-839

[16] Gilden D, Cohrs RJ, Mahalingam R, Nagel MA. Varicella zoster virus vasculopathies: Diverse clinical manifestations, laboratory features, pathogenesis, and treatment. *Lancet Neurology*. 2009;**8**:731-740. DOI: 10.1016/S1474-4422(09)70134-6

[17] McKelvie PA, Collins S, Thyagarajan D, Trost N, Sheorey H, Byrne E. Meningoencephalomyelitis with vasculitis due to varicella zoster virus: A case report and review of the literature. *Pathology*. 2002;**34**:88-93

[18] Reshef E, Greenberg SB, Jankovic J. Herpes zoster ophthalmicus followed by contralateral hemiparesis: Report of two cases and review of literature. *Journal of Neurology, Neurosurgery, and Psychiatry*. 1985;**48**:122-127

[19] Ahmad NM, Boruchoff SE. Multiple cerebral infarcts due to varicella-zoster virus large-vessel vasculopathy in an immunocompetent adult without skin involvement. *Clinical Infectious Diseases*. 2003;**37**:e16-e18

[20] Melanson M, Chalk C, Georgevich L, Fett K, Lapierre Y, Duong H, et al. Varicella-zoster virus DNA in CSF and arteries in delayed contralateral hemiplegia: Evidence for viral invasion of cerebral arteries. *Neurology*. 1996;**47**(2):569-570

[21] Gilden DH, Kleinschmidt-DeMasters BK, Wellish M, Hedley-Whyte ET, Rentier B, Mahalingam R. Varicella zoster virus, a cause of waxing and waning vasculitis: The New England Journal of Medicine case 5-1995 revisited. *Neurology*. 1996;**47**(6):1441-1446

[22] Linnemann CC Jr, Alvira MM. Pathogenesis of varicella-zoster angiitis in the CNS. *Archives of Neurology*. 1980;**37**(4):239-240

[23] Sreenivasan N, Basit S, Wohlfahrt J, Pasternak B, Munch TN, Nielsen LP, et al. The short- and long-term risk of stroke after herpes zoster - a nationwide population-based cohort study. *PLoS One*. 2013;**8**(7):e69156. DOI: 10.1371/journal.pone.0069156

[24] Langan SM, Minassian C, Smeeth L, Thomas SL. Risk of stroke following herpes zoster: A self-controlled case-series study. *Clinical Infectious Diseases*. 2014;**58**:1497-1503. DOI: 10.1093/cid/ciu098

[25] Askalan R, Laughlin S, Mayank S, Chan A, MacGregor D, Andrew M, et al. Chickenpox and stroke in childhood: A study of frequency and causation. *Stroke*. 2001;**32**:1257-1262

[26] Mishell JH, Applebaum EL. Ramsay-Hunt syndrome in a patient with HIV infection. *Otolaryngology and Head and Neck Surgery*. 1990;**102**(2):177-179. DOI: 10.1177/019459989010200215

[27] Adour KK. Otological complications of herpes zoster. *Annals of Neurology*. 1994;**35**(Suppl):S62-S64

[28] Furuta Y, Takasu T, Fukuda S, Sato-Matsumura KC, Inuyama Y, Hondo R, et al. Detection of varicella-zoster virus DNA in human geniculate ganglia by polymerase chain reaction. *The Journal of Infectious Diseases*. 1992;**166**(5):1157-1159

[29] Young-Barbee C, Hall DA, LoPresti JJ, Schmid DS, Gilden DH. Brown-Séquard syndrome after herpes zoster. *Neurology*. 2009;**72**:670-671. DOI: 10.1212/01.wnl.0000343737.79883.5c

[30] Steiner I, Kennedy PG, Pachner AR. The neurotropic herpes viruses: Herpes simplex and varicella-zoster. *Lancet Neurology*. 2007;**6**(11):1015-1028. DOI: 10.1016/S1474-4422(07)70267-3

- [31] Gilden DH, Beinlich BR, Rubinstien EM, Stommel E, Swenson R, Rubinstein D, et al. Varicella-zoster virus myelitis: An expanding spectrum. *Neurology*. 1994;**44**:1818-1823
- [32] Rowbotham M, Harden N, Stacey B, Bernstein P, Magnus-Miller L. Gabapentin for the treatment of postherpetic neuralgia: A randomized controlled trial. *Journal of the American Medical Association*. 1998;**280**(21):1837-1842
- [33] Choo PW, Galil K, Donahue JG, Walker AM, Spiegelman D, Platt R. Risk factors for postherpetic neuralgia. *Archives of Internal Medicine*. 1997;**157**(11):1217-1224
- [34] Nalamachu S, Morley-Forster P. Diagnosing and managing postherpetic neuralgia. *Drugs & Aging*. 2012;**29**(11):863-869. DOI: 10.1007/s40266-012-0014-3
- [35] Hempenstall K, Nurmikko TJ, Johnson RW, A'Hern RP, Rice AS. Analgesic therapy in postherpetic neuralgia: A quantitative systematic review. *PLoS Medicine*. 2005;**2**(7):e164. DOI: 10.1371/journal.pmed.0020164
- [36] Edelsberg JS, Lord C, Oster G. Systematic review and meta-analysis of efficacy, safety, and tolerability data from randomized controlled trials of drugs used to treat postherpetic neuralgia. *The Annals of Pharmacotherapy*. 2011;**45**(12):1483-1490. DOI: 10.1345/aph.1P777
- [37] Attal N, Cruccu G, Baron R, Haanpää M, Hansson P, Jensen TS, et al. European Federation of Neurological Societies. EFNS guidelines on the pharmacological treatment of neuropathic pain: 2010 revision. *European Journal of Neurology*. 2010;**17**(9):1113-e88. DOI: 10.1111/j.1468-1331.2010.02999.x
- [38] Levin MJ, Oxman MN, Zhang JH, Johnson GR, Stanley H, Hayward AR, et al. Varicella-zoster virus-specific immune responses in elderly recipients of a herpes zoster vaccine. *The Journal of Infectious Diseases*. 2008;**197**(6):825-835. DOI: 10.1086/528696
- [39] Oxman MN, Levin MJ, Johnson GR, Schmader KE, Straus SE, Gelb LD, et al. A vaccine to prevent herpes zoster and postherpetic neuralgia in older adults. *The New England Journal of Medicine*. 2005;**352**(22):2271-2284. DOI: 10.1056/NEJMoa051016
- [40] Nagel MA, Cohrs RJ, Mahalingam R, Wellish MC, Forghani B, Schiller A, et al. The varicella zoster virus vasculopathies: Clinical, CSF, imaging, and virologic features. *Neurology*. 2008;**70**(11):853-860. DOI: 10.1212/01.wnl.0000304747.38502.e8
- [41] Schubert J, Weissbrich B. Detection of virus-specific intrathecally synthesised immunoglobulin G with a fully automated enzyme immunoassay system. *BMC Neurology*. 2007;**7**:12. DOI: 10.1186/1471-2377-7-12
- [42] Nagel MA, Forghani B, Mahalingam R, Wellish MC, Cohrs RJ, Russman AN, et al. The value of detecting anti-VZV IgG antibody in CSF to diagnose VZV vasculopathy. *Neurology*. 2008;**68**(13):1069-1073. DOI: 10.1212/01.wnl.0000258549.13334.16
- [43] Solomon T, Michael BD, Smith PE, Sanderson F, Davies NW, Hart IJ, et al. Management of suspected viral encephalitis in adults: Association of British Neurologists and British Infection Association National Guidelines. *The Journal of Infection*. 2012;**64**:347-373. DOI: 10.1016/j.jinf.2011.11.014