

# We are IntechOpen, the world's leading publisher of Open Access books Built by scientists, for scientists

6,900

Open access books available

186,000

International authors and editors

200M

Downloads

Our authors are among the

154

Countries delivered to

TOP 1%

most cited scientists

12.2%

Contributors from top 500 universities



WEB OF SCIENCE™

Selection of our books indexed in the Book Citation Index  
in Web of Science™ Core Collection (BKCI)

Interested in publishing with us?  
Contact [book.department@intechopen.com](mailto:book.department@intechopen.com)

Numbers displayed above are based on latest data collected.  
For more information visit [www.intechopen.com](http://www.intechopen.com)



# ZIKV Diagnostics: Current Scenario and Future Directions

*Zilton Vasconcelos, Renata Campos Azevedo, Andrea Zin, Luiza Neves and Daniela Prado Cunha*

## Abstract

Since the discovery of the Zika virus in Uganda in 1947, diagnostic challenges remain, especially when we take into account the epidemiological context of the surveyed population. Genetic similarities with other flavivirus are responsible for cross-reactivity during serological evaluation that would often be the only resources to confirm the infection in asymptomatic cases or samples collected after the short window of viral RNA detection. The importance of Zika virus infection diagnosis is undoubtedly useful for pregnant women. This statement became evident after 2015 Brazil's Zika outbreak when a significant increase in cases of newborn with microcephaly was observed. Reverse transcriptase real-time PCR is the most reliable tool for Zika virus infection diagnosis. It detects viral RNA in both biological fluids and tissues and contributes to clinical case classification for initial description of developmental changes observed in neonates exposed congenitally to Zika virus. In conclusion, advances in serological diagnostic are urgent. The safest pathway for these studies requires laborious, subjective, and low throughput PRNT evaluations. Consequently, critical public health questions remain unanswered: how serum prevalent is the general population and pregnant women; can we define risk for congenital Zika syndrome (CZS) and Guillain-Barré syndrome; and how to assess vaccine efficacy and long-term protection.

**Keywords:** congenital Zika syndrome, real-time RT-PCR, PRNT, serum prevalence

## 1. Introduction

The Zika virus (ZIKV) belongs to the family *Flaviviridae*, genus *Flavivirus*, phylogenetically related to the dengue, yellow fever, and West Nile virus [1]. The main vector is the *Aedes aegypti*, hematophagous arthropod well adapted to urban living conditions, and for this reason, they are considered as emergent arboviruses, transmitted mainly by mosquitoes of the genus *Aedes*.

Clinically, the infection produces a self-limited febrile disease, whose symptoms of the acute phase are fever, headache, myalgia, and cutaneous rash. The virus incubation period in humans can range from 3 to 12 days, very similar to other arboviruses such as dengue and chikungunya virus. Thus, in regions where there is co-infection of these viruses, ZIKV can be sub-notified [2].

The ZIKV is transmitted to humans by the bite of infected female mosquitoes. However, other mechanisms of transmission have been described such as sexual

transmission, blood transfusion, and through breastfeeding [3–6]. In addition, the presence of ZIKV RNA has been identified already in body fluids such as endocervical or nasopharyngeal swab, saliva, and urine, which highlights other possible routes of transmission [7–11]. For example, ZIKV RNA detection in amniotic fluid was essential to define fetal infection during vertical transmission [12].

During 1947, ZIKV was originally isolated from the serum of a febrile rhesus monkey female, which was used as a sentinel to detect wild yellow fever virus in the Zika forest, localized at Uganda [13]. At the same site, the ZIKV was also isolated from a mosquito genus *Aedes Africanus* sample. More than one decade later, the first case of ZIKV infection in humans was reported in Uganda, with a detailed clinical description performed by a doctor who described his own infection. He described symptoms such as a mild headache, diffuse maculopapular rash, fever, and malaise [14].

Despite this report, ZIKA infections remained relatively unknown until 2007, when it occurred as a major outbreak in Micronesia, representing the first evidence of virus circulation outside the African continent [15].

The disease spread rapidly across the islands of the Pacific Ocean, and in October 2013, initial cases were diagnosed in French Polynesia that culminates with a major epidemic [16]. In February 2014, for the first time, ZIKV was detected in the Americas, and those cases were reported on Easter Island (Chilean territory in the Pacific Ocean), probably related to the outbreak in Micronesia and French Polynesia [17].

In Brazil, the first autochthonous transmission was observed in April 2015 in patients from Rio Grande do Norte, where the sequence of a fragment of viral envelope protein revealed high identity with ZIKV sequences of the Asian lineage [2]. The Ministry of Health of Brazil confirmed the circulation of ZIKV in the country, after identifying the viral RNA in 16 serum samples (8 cases from Bahia and the others from Rio Grande do Norte). The main symptoms described were arthralgia, edema of the extremities, low fever, headache, and retro-orbital pain, conjunctival hyperemia, and maculopapular rashes, besides pruritus, dizziness, myalgia, and digestive disorder [18]. Approximately 80% of ZIKV infections are asymptomatic or display mild-to-moderate symptoms that are self-limited and last between 5 and 7 days [19].

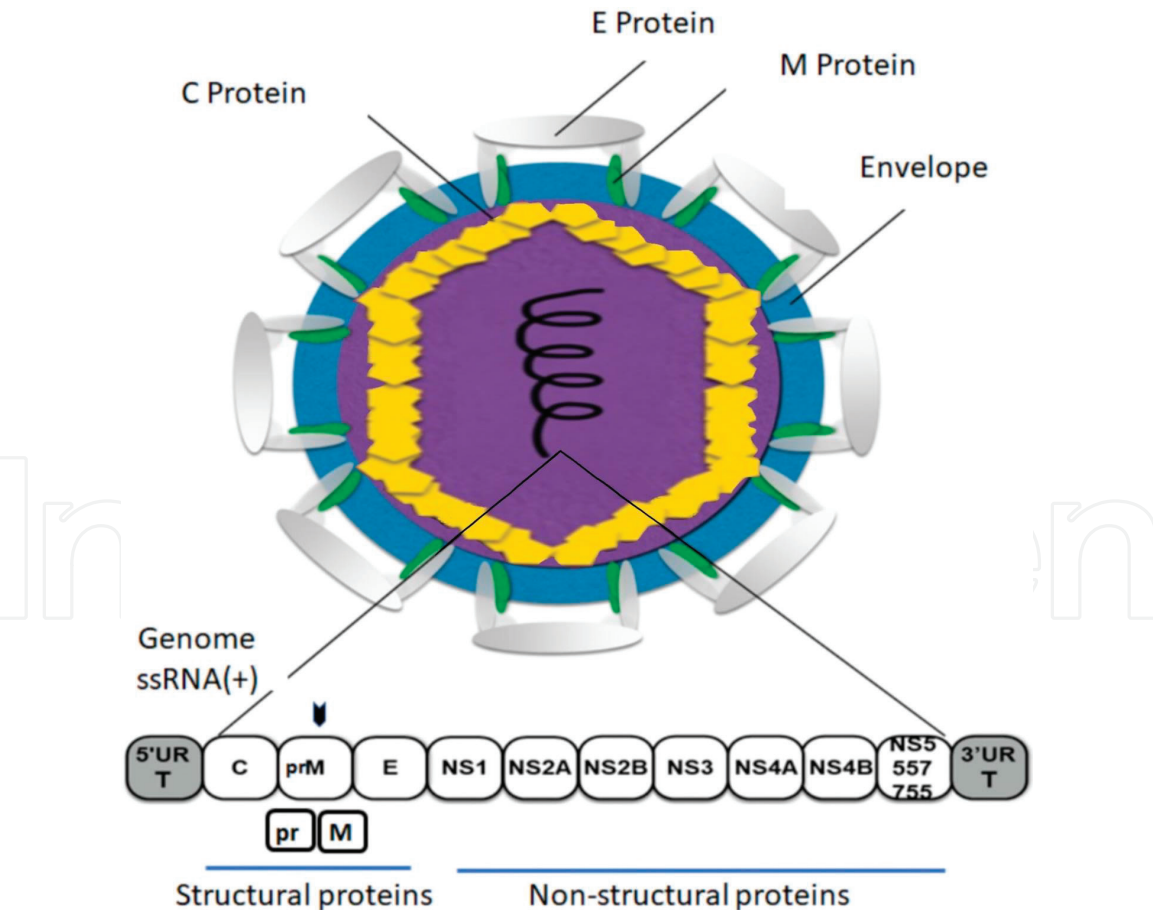
However, before ZIKV outbreak detection, the number of infants born with microcephaly in the second half of 2015 increased tremendously, when compared with historical reports. This observation was done in the Northeast region of the country, and Recife and Salvador and their surroundings were the most severely affected cities [18]. Retrospectively, the anamnesis of most parturients revealed episodes of febrile illness and exanthematous skin lesions during pregnancy [20]. Considering the epidemiological situation, in November 2015, the World Health Organization confirmed the relationship between ZIKV infection and congenital malformations in neonates, with most cases developing microcephaly and/or ventriculomegaly [21, 22].

In addition to CNS malformations due to congenital infections, ZIKV outbreak was also associated with increased number of cases of Guillain-Barré Syndrome (GBS) in French Polynesia, indicating another CNS-related complication resulting from ZIKV infection [23, 24]. In Brazil, severe manifestations associated with ZIKV infections were also described such as GBS, transverse myelitis, and meningitis in adults [23, 25].

## 2. Structural properties, genetic context, and evolution

ZIKV particle is composed of a positive-sense, single-stranded RNA about 10,794 bp in length involved by a protein capsid and surrounding a lipid

membrane. The RNA genome presents 5' and 3' untranslated regions (UTR), flanking a single long open reading frame (ORF) that translates one polyprotein (5'-C-prM-E-NS1-NS2A-NS2BNS3-NS4A-NS4B-NS5-3'). After cleavage, the polyprotein originates three structural proteins: capsid (C), membrane (M), and envelope (E), which are virus particle components, and seven nonstructural proteins: NS1, NS2A, NS2B, NS3, NS4A, NS4B, and NS5, which are involved in genome replication, polyprotein cleavage, and evasion of immunologic response (**Figure 1**) [26, 27]. The genome region, encoding flavivirus structural proteins, is more susceptible to genome variation when compared to nonstructural coding regions. Envelope protein (E), the major virion surface protein, is responsible for virus-cell interaction and membrane fusion, therefore being the major target for neutralizing antibodies [28]. Three domains were identified in E protein EDI, EDII, and EDIII. Karin Stettler and colleagues demonstrated that monoclonal antibodies (mAbs) directed to EDIII domain presented a potent and specific neutralizing activity to ZIKV, whereas mAbs directed to EDI/EDII domains partially neutralized ZIKV. Additionally, EDI/EDII-specific mAbs displayed higher cross-reactivity with dengue virus and enhanced *in vitro* viral infection, the phenomena described as antibody-dependent enhancement (ADE) [29]. This information should be considered in the development of ZIKV-specific diagnostic tool using antibody-based detection.



**Figure 1.** Flavivirus particle diagram. Flavivirus are small spherical enveloped particles. Envelope protein (E), responsible for virus-cell interaction and membrane fusion, is the main target for neutralizing antibodies. The membrane-associated protein (M) results from the cleavage of the precursor to membrane protein (PrM) during virus maturation. Capsid proteins (C) assemble into an icosahedral structure (capsid) and involve the virus genomic material (ssRNA+). The genomic RNA coding region is flanked by two untranslated regions (5' UTR and 3' UTR) and produces a polyprotein that after proteolytic cleavage generates all functional virus proteins. Adapted from de Vasconcelos et al. [32].



Regarding the nonstructural proteins, NS1 glycoprotein is a multifunctional virulence factor that intracellularly co-localizes with the virus replication complex. In addition, an infected cell secretes NS1 as a hexameric lipoprotein, and several immunomodulatory functions are proposed for this particular protein [27]. The secretion of NS1 during acute dengue infection culminates in high serum levels of this protein. It occurs mainly during viremic period and encourages the development of NS1-based serologic diagnostic tests during previous dengue outbreaks [30]. Recently, one serologic test for ZIKV based on NS1 reinforces the use of this protein as an acute phase biomarker for flavivirus infection [31]. The NS5 protein is the largest viral protein whose C-terminal portion has RNA-dependent RNA polymerase (RdRP) activity. The polymerase region of the protein is generally conserved and can be used for the design of a broad range of primers.

Genetic studies using nucleotide sequences derived from the NS5 gene indicated three ZIKV lineages: East African, West African, and Asian [1]. However, after genome-based phylogenetic analysis, Asian and African strains remained as the only two genetic lineages for ZIKV [1]. ZIKV was associated with sporadic human infections in Africa and Southeast Asia by the end of the last century and was described as a zoonotic pathogen [33]. Due to the first isolation in monkeys and mosquitoes, the maintenance of the enzootic ZIKV was first attributed to those two groups of animals. However, antibodies have been detected in other animal species [26]. The ZIKV ability to switch species can play a special role in virus evolution. Especially in virus presenting RNA genome, nucleotide polymorphisms have long been noted as an evolutionary mechanism and indicate viral adaptation to the host [34, 35]. The mutation rate of ZIKV was demonstrated to be between 12 and 25 bases per year and corresponds to 0.2% of total ZIKV genome [36]. On top of the mutation rate, recombination events also play an important role in virus evolution. Fay et al. studying the molecular evolution of ZIKV reported a possible event of recombination in E and NS5 genes affecting African samples [28]. Han et al. propose a recombinant event within Brazilian strain (ZikaSPH2015), French Polynesia strain (H/PF/2013), and strain Z1106033 from Suriname [37]. Noteworthy, the recombination within Asian strains was not supported by Jun and colleagues when 196 ZIKV genomes were analyzed [38]. Therefore, further investigation is needed in order to accurately correlate genome changes and virulence.

### **3. Molecular tests (virus detection)**

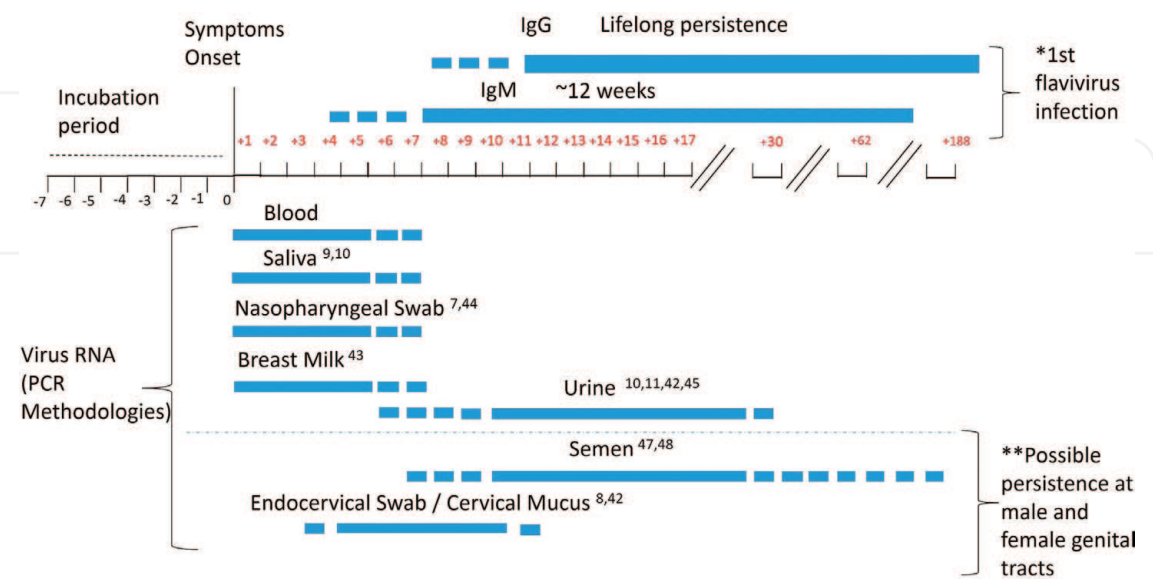
#### **3.1 Quantitative polymerase chain reaction (qPCR)**

Quantitative polymerase chain reaction amplification (qPCR) assays have been used for laboratory diagnosis of viral infectious diseases, since the sensitivity, specificity, and speed of the method allow the rapid detection of viruses in the host, human clinical samples, biopsies, and autopsy tissue. Since ZIKV is an RNA virus, running an initial reverse transcriptase step followed by a qPCR (RT-qPCR) is recommended. This method has been proved to be the most reliable one to confirm ZIKV infection during acute phase. Then, the first step for molecular ZIKV detection is the RNA isolation from different patient biological samples. When one is dealing with tissue samples, it is necessary to mechanically dissociate the freshly isolated tissue fragment to further conduct the nucleic acid extraction process. Other body fluid samples could be directly processed by an RNA isolation kit before viral genome reverse transcriptase reaction followed by amplification using ZIKV-specific primers and probes.

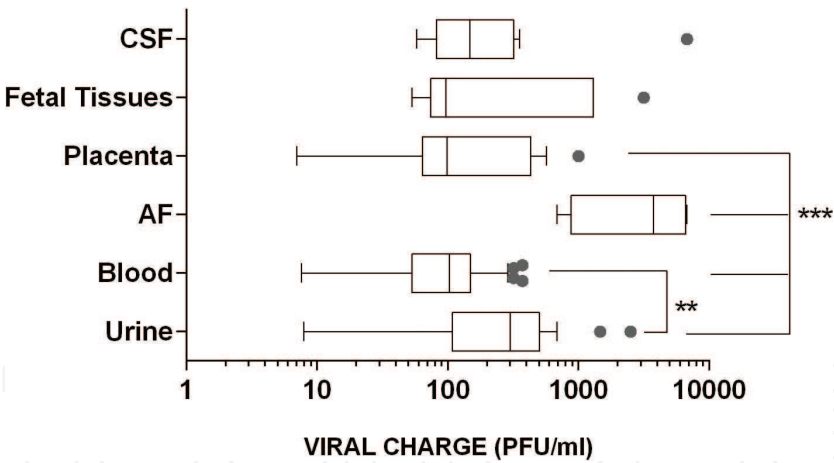
One of the limitations of the PCR technique is related to the presence of inhibitory substances, such as IgG, hemoglobin, lactoferrin in blood samples, and anticoagulants as heparin, that have already been described as PCR inhibitors [39]. In urine samples, the most critical component described as PCR inhibitors is urea, which can lead to degradation of the polymerase. However, its direct effect is dependent on urea concentration in the sample [40]. One way to monitor an inhibitory effect performed by PCR inhibitors is to carry out PCR positive control reactions. Spike-in experiments where an exogenous microorganism is added to your patient sample, to be co-extracted and amplified by another pair of primers and probe, could demonstrate inhibitors' presence when no amplification occurs [41].

Other limitations of the technique are related to both the time of infection (acute phase) and the type of sample chosen. This relationship is directly associated with the success of the laboratory confirmation. It is known that the presence of the virus in the plasma, saliva, breast milk, and nasopharyngeal swab is short, which allows the detection of viral RNA for a limited time, and during the acute phase of the disease, it is calculated on average 3–7 days after the occurrence of the symptoms. On the other hand, urine and saliva biological samples are optimal in the context of infant and newborn diagnosis due to low invasiveness and easy sample access [7, 10, 42–44]. In term of RNA detection, urine samples are described to present positivity from the fourth day until 29 days after the onset of symptoms [45], another time this sample opens the possibility of virus detection in longer times, even after the period of viremia. In adults, the biological sample that displays an increased period of viral persistence was semen, with cases where RNA detection occurred months after ZIKV infection. This raises the possibility that viral persistence could exist in both female and male genital tract (Figure 2) [8, 42, 46–48].

Apart of a positive RT-qPCR result for ZIKV, quantitative PCR offers the opportunity to deliver viral copies relative to tissue milligrams or fluid milliliters. To calculate viral load is imperative to construct a standard curve, from a serial dilution from a



**Figure 2.** Literature evidence on the average period of virus RNA positivity in different body fluids and serum immunoglobulins levels after symptoms onset. Bars following the timeline indicate sample and proper molecular test that should be used to investigate infection after viral exposition, and dashes represent virus load decrease. Immunoglobulins development expected for a primary flavivirus infected patient. A secondary exposition should promote earlier and higher IgG serum titles with short and reduced IgM levels. ZIKV detection in genital fluids without viremia suggests viral tropism and persistence in those organs.



**Figure 3.** ZIKV RNA viral load in different biological samples. Noninvasive biological samples urine presents a higher viral load than blood samples (\*\*  $p$ -value < 0.001). AF viral load is the highest when compared with other maternal samples (\*\*\*  $p$ -value < 0.0001). AF, amniotic fluid. CSF, cerebrospinal fluid. Data generated from 13 placentas, 12 CSF, 6 fetal tissues, 4 AF, 24 urine, and 49 blood samples.

reference sample that was previously determined RNA copies or plaque forming units (PFU). Then, the sample result will be possible to extrapolate from a relative measurement to an absolute quantification applied to a patient sample. This quantitative molecular diagnosis, in some pathologies (e.g., Hepatitis B and C, HIV, and herpes), has been already described as important indicators of health status and guide treatment choices. In the case of ZIKV infection, viral load does not appear to be related with clinical adverse events in congenital infections [49] or general population [50], but it was important to demonstrate viral load in different biological samples. As shown in **Figure 3**, the amniotic fluid has the highest viral load when compared with other biological fluids (urine or blood). However, in the context of an epidemiological outbreak, blood and urine are the more accessible samples with a significantly higher amount of virus and prolonged RNA detection (**Figure 2**) in urine than blood. The placenta did not present a significant difference when compared to blood and urine.

However, as discussed before, potential ZIKV RNA viral mutation turns RT-qPCR methods not infallible. Viral genetic evolution raises the possibility that polymorphisms inside primer annealing site may generate false negative amplification reactions of the ZIKV genome targeted region. During 2015 ZIKV outbreak, there was six widely used *in-house* RT-qPCR methods for diagnostic [1, 51–53], and their suitability for detection of ZIKV Asian strain was reported by Corman et al. with clear differences in sensitivity between them [54]. Poor PCR sensitivity and low RNA viral load observed in patient samples can be one of the explanations for the reduced number of laboratory-confirmed cases during the last epidemics. Few RT-qPCR kits for ZIKV detection were commercially available, and high costs also limited their use and could be the other reason for lower confirmed cases, especially in most of the endemic countries [55]. Besides the small amount of proficient clinical laboratories, performance control of *in-house* methodologies continues to be a challenging task; therefore, constant interlaboratory control should be stimulated, and standardized reagents, suitable probes, and primers should be used whenever possible.

### 3.2 Immunoenzymatic assays for virus detection

#### 3.2.1 NS1 tests

Another flavivirus laboratory test that has gained prominence is the detection of NS1 viral protein in the serum, which in turn reflects a viral infection during the acute

phase [56]. Largely used during DENV outbreaks, it is based on NS1 protein secretion by infected cells that reach high serum concentrations during periods of viral replication during flaviviruses and is considered an important acute phase biomarker for dengue fever. The assay format is suitable for use in routine laboratories around the world, allowing high-throughput testing in epidemic regions [31, 56]. Serological identification of ZIKV infections could also be maximized by parallel testing for IgM/IgG and NS1. The limitation of this assay is related to cross-reactivity between Zika and other flaviviruses, once they display a high degree of homology around their viral proteins, especially with dengue [1]. However, serological tests are constantly improving in order to increase the specificity through the use NS1-based anti-ZIKV, and it has been recently shown to be more sensitive and highly specific for the serodiagnosis of ZIKV infections but has not yet been commercially available [31].

### 3.2.2 Immunohistochemistry

Immunohistochemistry is an important tool to evaluate vertical transmission (placenta infection). Through this, viral particles of ZIKV have already been detected in placental defense cells, known as Hofbauer cells. These cells are of fetal origin and have the ability to migrate, in areas that have contact with trophoblastic epithelium and vessels of the fetus. It is believed that ZIKV has an immune system evasion mechanism and Hofbauer cells are responsible for viral dissemination, facilitating their access to the fetal compartment besides being a viral reservoir [57]. Due to access to the fetal compartment, ZIKV gains open access to fetal layer where no more immunological barrier could arrest their access to fetal central nervous system (CNS) [58].

ZIKV neuronal tropism was observed and described in affected fetus through necropsy studies. It was clearly demonstrated ZIKV antigens being expressed in large amounts in the brain with sporadic amounts of ZIKV antigens found in other fetal tissues, like liver, kidney, heart, and lung [59]. The opportunity to demonstrate CNS prolonged viral persistence was showed in a necropsy study conducted in a 5-month infant deceased after ZIKV congenital infection, which occurred in the first trimester of pregnancy. In this case report, ZIKV was still present in the brain tissue with no evidence of inflammation or brain damage evolution [60].

## 3.3 Virus isolation

Virus isolation using cell culture or animals remains as an option for virus detection. Vertebrate or invertebrate cells (e.g., *Aedes albopictus* clone C6/36) can be used for ZIKV propagation from the biological sample. This methodology allows the identification of infectious particles and was used to evaluate the body fluid potential to transmit the virus, such as saliva, breast milk, and urine. Additionally, cellular propagation increases the sensitivity in low viral load samples; however, the condition of sample transport and storage can impact the test result. This seems to be even more important for ZIKV, which demonstrates reduced stability in fluids and tissues [61]. Due to the time required for virus propagation and the cell culture structure need, viral isolation is not used in the diagnostic routine.

## 4. Serology tests

### 4.1 ELISA tests

The considerable cross-reactivity between flavivirus antibodies is the major challenge for serological test development. In endemic areas, where dengue and



Zika viruses cocirculate besides several proposed ELISA tests, individuals previously exposed to other flaviviruses are not prevented to be misclassified. Another complication for patients experiencing a second flavivirus infection is a shortened IgM antibody response that could misdiagnose the time for acute infection [1].

This presents a diagnostic dilemma for patients living in regions in which flaviviruses are endemic, and reliable diagnostic tools that are able to discriminate between primary and secondary ZIKV or DENV infections are urgently needed [1, 62, 63].

Although the precise period of onset and duration IgM class antibodies in response to ZIKV is not well defined, data known by other flaviviruses suggest that IgM for ZIKV should start to be detectable 7 days following infection, in the majority of symptomatic patients (**Figure 2**). However, it has been recently reported in the literature that seroconversion may occur earlier for one-third of patients [1, 42]. While anti-ZIKV antibody titers decrease, IgM to ZIKV has a window of detection more than 12 weeks following infection for over 80% of individuals [42]. According to the modeling studies with other flaviviruses, including West Nile virus (WNV) and dengue (DENV), this serum persistence is consistent with the antibody responses following infection, suggesting that the mean time to IgM seronegativity ranges from 5 to 6 months [64, 65].

Apart from initial antibody response, IgG neutralizing antibodies (NA) normally develop after IgM response and should persist for years to decades following primary infection. It is believed that NA to ZIKV directed to a key epitope after infection should be highly specific in patients without prior exposure to flaviviruses; however, NA specificity, in the setting of past exposure to a closely related flavivirus, such as DENV, once shares diverse antigenic determinants, decrease specificity to ZIKV epitopes [1].

Another tool that is being proposed in the context of outbreaks is rapid point of care (POC) tests which are based on the IgM/IgG immunochromatography assay. They should be used carefully and are normally interpreted as qualitative screening tests, and further serological investigations are needed. When they present a positive result, the patient samples should be sent for plaque reduction neutralization test (PRNT), or in the case of pregnant women, RT-qPCR is recommended [66, 67].

Special attention should be given to the risk group composed of newborns, where the immunoenzymatic serological test is extremely important to define congenital infection. ZIKV IgG antibody detection in a newborn may reflect maternal infection due to the passive transfer of this class of immunoglobulins. Based on other congenital infections, uninfected newborns display IgG levels that decline gradually in the first months of life, and this corresponds to the time of elimination of the antibody transmitted by the mother [68]. For this reason, tests to detect IgM are commonly used to confirm infection in the child, and in the context of flavivirus infection, only ZIKV was demonstrated to cross the placental and fetal immunological barriers [69, 70]. ZIKV IgM positivity in CSF, after congenital infection, was described as a reliable tool to discriminate fetal infection, and it characterized high risk for neuroinvasive disease [71].

## 4.2 Plaque reduction neutralization test (PRNT)

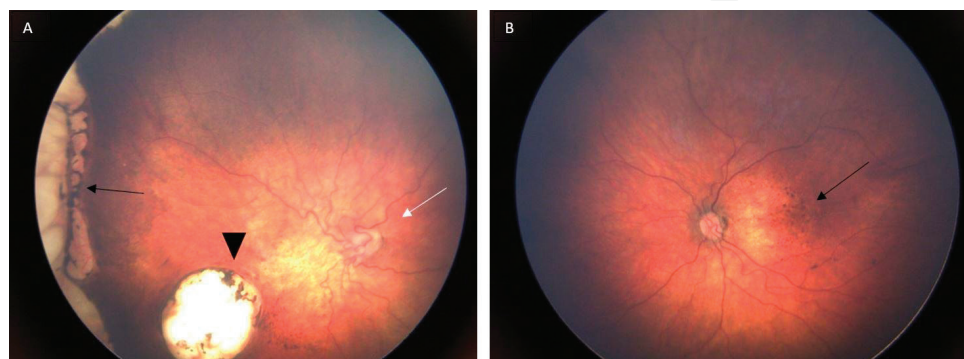
Until now, the unique reference standard for NA detection related to flaviviruses remains the plaque reduction neutralization test (PRNT). Although technically cumbersome, with several challenges: (1) long turnaround time of days to weeks; (2) requirement for live viral cultures; (3) technical-experience dependence; and (4) high degree of subjectivity, it offers the highest achievable level of specificity. This test initiates with a serial dilution of patient serum that is preincubated with live ZIKV or other closely related viruses (e.g., DENV), followed by deposition

onto a virus-susceptible cell monolayer. After proper incubation time, any resulting plaques suggest nonneutralized live virus and absence of specific antibodies. Those plaques are quantified and compared to plaques number obtained in culture wells containing virus-only in order to establish which serum dilution promotes 90% reduction in plaques occurrence in this patient sample (PRNT90). ZIKV and DENV PRNT90 titers are subsequently compared to define the specificity of the NAs [72]. Although the PRNT assay has a higher sensitivity than other tests such as hemagglutination and enzyme immunoassay and is more specific than other serological methods for the diagnosis, the limitation of this test is not discriminate between antibody classes and, especially in secondary flavivirus infections, cross-reactive neutralizing antibodies may contribute to virus neutralization [73]. In addition, PRNTs are time-consuming and laborious and are to be restricted to reference laboratories and research centers because they require the technical capacity to carry them out, as well as a complex laboratory structure [46].

## 5. Clinical context

Zika virus (ZIKV) infection is usually an asymptomatic or a mild symptomatic disease in adults, with maculopapular and pruritic rash, fever, conjunctivitis, joint pain, headache, and muscle pain [74]. However, infection during pregnancy may be transmitted to the fetus and causes severe systemic fetuses' malformations, comprising the congenital Zika syndrome (CZS).

The clinical features of CZS have been described since 2015 Zika's outbreak in Brazil. They can be divided into structural and functional components [75]. The structural components are cranial morphology, brain, and ocular anomalies, as well as congenital contractures [75]. The functional component is related to neurologic sequelae [75]. Therefore, CZS may consist of (A) cranial morphology: severe microcephaly, overlapping cranial sutures, prominent occipital bone, redundant scalp skin, and neurologic impairment; (B) brain anomalies: thin cerebral cortices, abnormal gyral patterns, increased fluid spaces, subcortical calcifications, corpus callosum abnormalities, decreased white matter, and cerebellar hypoplasia; (C) ocular anomalies: macular scarring (**Figure 4A**), focal pigmentary retinal mottling (**Figure 4B**), and optic nerve hypoplasia or atrophy (**Figure 4A**); (D) congenital contractures: arthrogryposis and club feet; and (E) neurologic sequelae: marked early hypertonia, symptoms of extrapyramidal involvement, epilepsy, and irritability [75–77]. Early recognition and referral to multidisciplinary care may result in a better outcome for each one of the abnormalities described.



**Figure 4.**  
 (A) Right eye retinography showing macular (black arrowhead) and peripheral (black arrow) scarring and optic nerve hypoplasia (white arrow); (B) left eye retinography showing focal pigmentary retinal mottling (black arrow).

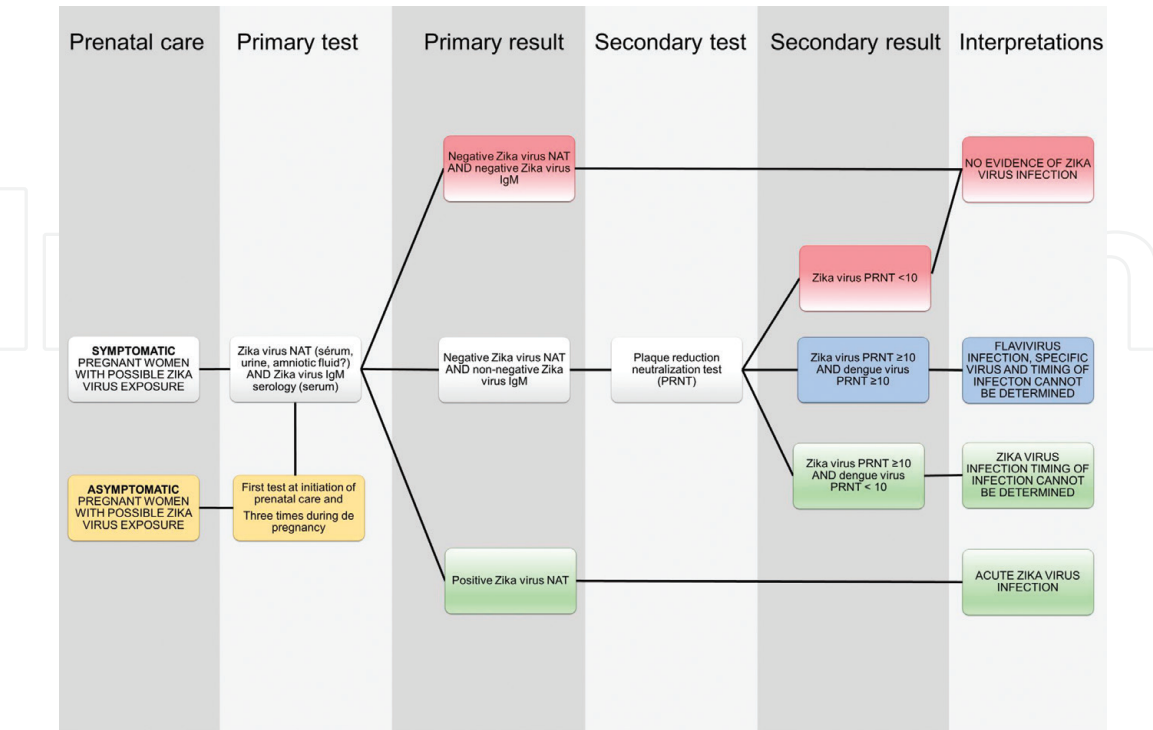
The diagnostic approach during prenatal care should be different in an endemic area and in a nonendemic area. Endemic area means residence in or travels to the affected area. In addition, in each of these two scenarios, the diagnosis is divided into symptomatic and asymptomatic pregnant women.

5.1 Endemic area (residence or travel)

5.1.1 Symptomatic pregnant women

The ZIKV infection is divided into acute and convalescent phases. The acute phase is within the first 7 days of the symptoms, and the convalescent phase is 2–12 weeks after [78]. As shown in **Figure 5**, during the acute phase, the possible primary tests are the ZIKV RT-qPCR and the Immunoglobulin (Ig) M. The first one can be obtained from serum, saliva, urine, or amniotic fluid. When it is detected in the serum or saliva, it is confined to 5–7 days after onset of symptoms, and when it is detected in urine, it lasts up to 3 weeks after onset of illness. The evidence is lacking on the diagnostic accuracy of RT-qPCR of amniotic fluid and on the optimal time to perform amniocentesis [74]. The IgM is detectable  $\geq 4$  days after onset of illness [78]. In the convalescent phase, the primary test is IgM and the second test is plaque reduction neutralization test (PRNT). However, the Zika virus RT-qPCR can also be performed during this phase.

If the primary results are **negative ZIKV RT-qPCR and negative ZIKV IgM** (red flowchart in **Figure 5**), there is no evidence of virus detection, but an intra-uterine ultrasound scan (US) should be done. If there are any fetal development abnormalities, serological tests for others congenital infections could be done and the pregnant woman should be referred to a specialized care. The possible congenital infections are toxoplasmosis, rubella, cytomegalovirus (CMV), herpes virus, parvo-virus B19, varicella, and syphilis, known by the acronym TORCH's syndrome (Sd).



**Figure 5.** Flowchart showing initially two clinical scenarios (symptomatic and asymptomatic pregnant women) and the different primary and secondary tests and results for Zika virus diagnosis during pregnancy. NAT: RT-qPCR nucleic acid test. IgM: Immunoglobulin M. US: Intrauterine ultrasound. PRNT: Plaques reduction neutralization test.



The possible fetal abnormalities are microcephaly, intracranial calcifications, ocular lesions and calcifications, ventriculomegaly, abnormal sulcation and gyration, abnormal cortical development (lissencephaly), cerebral atrophy, callosal dysgenesis, cerebellar atrophy, brainstem hypoplasia, microphthalmia and arthrogryposis, intrauterine growth restriction, and evidence of placental insufficiency [74]. If there is absence of fetal abnormalities, the pregnant can follow routine antenatal care and it should be considered to repeat the US at 28–30 weeks [74].

If the primary results are **negative ZIKV RT-qPCR and non-negative ZIKV IgM**, the secondary test PRNT should be performed. It can be done for any other flavivirus that might be found in that geographic area [74]. If ZIKV PRNT  $\leq 10$  (white flowchart in **Figure 5**), there is no evidence of Zika virus infection. If ZIKV PRNT  $\geq 10$  and dengue virus PRNT  $\geq 10$  (blue flowchart in **Figure 5**), there is evidence of a flavivirus infection but no confirmation of a specific virus. Finally, if ZIKV PRNT  $\geq 10$  and dengue virus PRNT  $< 10$  (green flowchart in **Figure 5**), there is evidence of ZIKV infection. In any of the last two scenarios, the timing of infection cannot be determined.

If the primary result is **positive ZIKV RT-qPCR** (green flowchart in **Figure 5**), acute ZIKV infection is confirmed and US should be done. If there is any fetal abnormality, the pregnant woman should be referred to a specialized care, and if there is no abnormality, routine antenatal care should be done, as well as a US follow-up every 4 weeks until birth [74, 79].

### 5.1.2 Asymptomatic pregnant women

In endemic area of residence or traveling, the pregnant woman with possible ZIKV exposure should be first tested at initiation of prenatal care and three times during pregnancy [67]. The primary tests should be ZIKV RT-qPCR and ZIKV IgM serology. If available, US should be considered for fetal morphology assessment. The possible results of the laboratory tests and US are described above.

## 5.2 Nonendemic area

The asymptomatic woman should follow the routine antenatal care. The symptomatic woman should do the primary tests ZIKV RT-qPCR and ZIKV IgM serology. If available, US for fetal morphology assessment should be considered.

Additionally, the differential diagnosis is also crucial for the correct assessment and management of the disease. Signs of maternal disease, as well as intrauterine and neonatal findings, are similar in most of the TORCH's congenital infections [75, 80]. Moreover, some genetic syndromes (Sd), such as Aicardi-Goutières Sd, pseudo-TORCH Sd, and mutations in the JAM3, NDE1, and ANKLE2 genes can also be in the differential diagnosis [75].

The main clinical findings in maternal TORCH infections include nonspecific signs, like fever, fatigue, malaise, headache, myalgia, arthralgia, lymphadenopathy, conjunctivitis, and making the ability to recognize the specific etiological agent difficult. Moreover, there are typical findings in some of these infections that can lead to the diagnosis. In herpes simplex virus infection, there is also painful genital ulcer, pruritus, and dysuria [80]. In primary syphilis infection, there is a firm, round, and painless chancre on external genitals and vagina, lasting 3–6 weeks [81]. In rubella, parvovirus B19, varicella, and ZIKV, cutaneous rash is an additional important sign [80, 82, 83]. The rash in rubella is maculopapular and usually progresses from the face to the body, fading within 2–4 days [80, 82, 83]. In parvovirus B19, the rash is also maculopapular, persisting until the 6th day and disappearing on the 7–9th day after the first appearance [80, 82, 83]. First, it occurs on the face, sparing nasal, and periorbital zones and second, on the trunk and extremities [83]. In varicella, it



is initially pruritic and maculopapular, following a vesicular phase until crushing occurs, usually about 5 days later [84]. Finally, the rash in ZIKV infection is pruritic, descending, and maculopapular, beginning proximally and spreading to the extremities with resolution occurring within 1–4 days of onset [14, 74].

Nonspecific intrauterine US findings in TORCH infections are intrauterine growth restriction, abnormal fluid imbalance (ascites, hydrops, pericardial effusion, pleural effusion, and oligo-polyhydramnios), hepatosplenomegaly and hepatic calcifications, echogenic bowel, echogenic kidneys, and limb deformities [80, 85]. Cerebral brain calcification, although relatively common in most of these infections, can be an important distinguishing factor due to its location [80, 85]. In congenital toxoplasmosis, the calcifications are diffuse and widely distributed, and in rubella, they are at basal ganglia [80, 85]. In CMV congenital infection, the calcifications are usually punctate and periventricular or cortical [80, 85]. Conversely, in ZIKV, the calcifications are larger and denser, usually appearing at the gray and white matter junction [80, 86].

As well as seen with maternal clinical signs and intrauterine US findings, TORCH congenital infection can also produce a similar neonatal clinical presentation, although the features rarely occur simultaneously [87, 88]. The common clinical features include growth retardation, prematurity, jaundice, anemia, hepatosplenomegaly, microcephaly, cerebral calcifications, chorioretinitis, cataracts, microphthalmia, and others [87, 88]. However, clinical findings are more associated, although not exclusively, with a determined etiological agent. Cardiac lesions and deafness have been described in CMV and rubella congenital infections. Cicatricial skin lesions and limb hypoplasia are seen in varicella virus congenital infection [87]. Petechial or purpuric form exanthema (blueberry muffin spot) is typical of CMV infection [80, 82]. Chorioretinitis, hydrocephalus, and cerebral calcifications comprise the characteristic triad of congenital toxoplasmosis [89].

Finally, clinical signs of CZS can also be found in other TORCH infections. Cranial ZIKV morphology and brain anomalies can occur in congenital CMV infection [75]. Congenital contractures can appear in congenital rubella, varicella, and Coxsackie B infections [75]. Neurologic sequelae are seen in most TORCH infections [75]. Ocular anomalies, such as pigmentary mottling and chorioretinal scars, can manifest differently in each of these congenital infections. In rubella, the pigment mottling is usually diffused compared with the focal pigment mottling seen in Zika virus infection (**Figure 4B**) [77]. Chorioretinal lesions in toxoplasmosis can present with active exudative retinitis or regressed macular or peripapillary retinal scar [77]. In ZIKV congenital infection, chorioretinal lesions are atrophic and colobomatous-like and are found in the macula or retinal periphery (**Figure 4A**) [77]. Optic nerve hypoplasia, commonly seen in ZIKV congenital infection, is seldom seen in rubella, toxoplasmosis, herpes, and CMV congenital infections [77].

## 6. Conclusions

Human clinical diagnosis of ZIKV infection in regions where other arboviruses circulate, mainly DENV and CHIKV, has become a daunting task; therefore, laboratory confirmation is crucial for conclusive diagnosis. Detection of virus genome by RT-qPCR is helpful and demonstrated to be a reliable tool; however, the limited window for virus detection, low viral load, and stability restricted the use of these methodologies. Antibody screening is also hampered by cross-reactivity among other flaviviruses.

Due to impact of ZIKV infection, especially for pregnant women, a confident ZIKV serology test is urgently needed, and this will promote a better prenatal

follow-up, especially in endemic areas. Nonetheless, as mentioned above, there are typical findings to aid the correct diagnosis and, thus, the appropriate management and counseling of the disease.

## Acknowledgements

We thank Fernandes Figueira Institute Pediatric Infectious Disease Team for helpful discussions during this work and field expertise from ZIKVIRUSIFF Cohort study registered on [clinicaltrials.gov](http://clinicaltrials.gov) with identifier NCT03255369.

This work was partially supported by Fernandes Figueira Institute Research Program (Programa de Incentivo à Pesquisa II), Rio de Janeiro State Research Grant (Fundação de Amparo à Pesquisa do Estado do Rio de Janeiro—grant E-26/201.840/2017), National Research Grant (Conselho Nacional de Desenvolvimento Científico e Tecnológico—grant 441098/2016-9), and the Coordenação de Aperfeiçoamento de Pessoal de Nível Superior—Brasil (CAPES)—Finance Code 001.

## Conflict of interest

The authors declare no conflict of interest.

## Author details

Zilton Vasconcelos<sup>1\*</sup>, Renata Campos Azevedo<sup>2</sup>, Andrea Zin<sup>1</sup>, Luiza Neves<sup>1</sup> and Daniela Prado Cunha<sup>1</sup>

<sup>1</sup> Fernandes Figueira Institute, Fiocruz, Rio de Janeiro, Brazil

<sup>2</sup> Institute of Microbiology Paulo de Góes, Federal University of Rio de Janeiro, Rio de Janeiro, Brazil

\*Address all correspondence to: [zvasconcelos@iff.fiocruz.br](mailto:zvasconcelos@iff.fiocruz.br)

## IntechOpen

© 2018 The Author(s). Licensee IntechOpen. This chapter is distributed under the terms of the Creative Commons Attribution License (<http://creativecommons.org/licenses/by/3.0>), which permits unrestricted use, distribution, and reproduction in any medium, provided the original work is properly cited. 

## References

- [1] Lanciotti RS, Kosoy OL, Laven JJ, Velez JO, Lambert AJ, Johnson AJ, et al. Genetic and serologic properties of Zika virus associated with an epidemic, Yap State, Micronesia, 2007. *Emerging Infectious Diseases* [Internet]. 2008;**14**(8):1232-1239. DOI: 10.3201/eid1408.080287
- [2] Zanluca C, Melo VCA de, Mosimann ALP, Santos GIV dos, Santos CND dos, Luz K. First report of autochthonous transmission of Zika virus in Brazil. *The Memórias do Instituto Oswaldo Cruz* [Internet]. 2015;**110**(4):569-572. Available from: [http://www.scielo.br/scielo.php?script=sci\\_abstract&pid=S0074-02762015000400569&lng=en&nrm=iso&tlng=en](http://www.scielo.br/scielo.php?script=sci_abstract&pid=S0074-02762015000400569&lng=en&nrm=iso&tlng=en) [cited: 27 August 2018]
- [3] Atkinson B, Graham V, Miles RW, Lewandowski K, Dowall SD, Pullan ST, et al. Complete genome sequence of Zika virus isolated from semen. *Genome Announcements* [Internet]. 2016;**4**(5):1-2. DOI: 10.1128/genomeA.01116-16
- [4] Musso D, Nhan T, Robin E, Roche C, Bierlaire D, Zisou K, et al. Potential for Zika virus transmission through blood transfusion demonstrated during an outbreak in French Polynesia, November 2013 to February 2014. *Euro Surveillance* [Internet]. 2014;**19**(14):1-3. Available from: <https://www.ncbi.nlm.nih.gov/pubmed/24739982>
- [5] De Carvalho NS, De Carvalho BF, Fugaça CA, Dóris B, Biscaia ES. Zika virus infection during pregnancy and microcephaly occurrence: A review of literature and Brazilian data. *The Brazilian Journal of Infectious Diseases* [Internet]. 2016;**20**(3):282-289. DOI: 10.1016/j.bjid.2016.02.006
- [6] Mann TZ, Haddad LB, Williams TR, Hills SL, Read JS, Dee DL, et al. Breast milk transmission of flaviviruses in the context of Zika virus: A systematic review. *Paediatric and Perinatal Epidemiology* [Internet]. 2018;**32**(4):358-368. DOI: 10.1111/ppe.12478
- [7] Fonseca K, Drebot M, MacDonald J, Lindsay R, Pabbaraju K, Tellier R, et al. First case of Zika virus infection in a returning Canadian traveler. *The American Journal of Tropical Medicine and Hygiene* [Internet]. 2014;**91**(5):1035-1038. DOI: 10.4269/ajtmh.14-0151
- [8] Visseaux B, Mortier E, Houhou-Fidouh N, Brichler S, Collin G, Larrouy L, et al. Zika virus in the female genital tract. *Lancet Infectious Diseases* [Internet]. 2016;**16**(11):1220. DOI: 10.1016/s1473-3099(16)30387-5
- [9] Barzon L, Pacenti M, Berto A, Sinigaglia A, Franchin E, Lavezzo E, et al. Isolation of infectious Zika virus from saliva and prolonged viral RNA shedding in a traveller returning from the Dominican Republic to Italy, January 2016. *Euro Surveillance* [Internet]. 2016;**21**(10):1-5. DOI: 10.2807/1560-7917.es.2016.21.10.30159
- [10] Bonaldo MC, Ribeiro IP, Lima NS, Dos Santos AAC, Menezes LSR, da Cruz SOD, et al. Isolation of infective Zika virus from urine and saliva of patients in Brazil. *PLoS Neglected Tropical Diseases* [Internet]. 2016;**10**(6):e0004816. DOI: 10.1371/journal.pntd.0004816
- [11] Gourinat A-C, O'Connor O, Calvez E, Goarant C, Dupont-Rouzeyrol M. Detection of Zika virus in urine. *Emerging Infectious Diseases* [Internet]. 2015;**21**(1):84-86. DOI: 10.3201/eid2101.140894
- [12] da Silva SR, Cheng F, Gao S-J. *Zika Virus and Diseases: From Molecular Biology to Epidemiology* [Internet]. New Jersey, United States: John

Wiley & Sons; 2018. 264 p. Available from: <https://market.android.com/details?id=book-EWxODwAAQBAJ>

[13] Dick GWA, Kitchen SF, Haddow AJ. Zika virus. I. Isolations and serological specificity. *Transactions of the Royal Society of Tropical Medicine and Hygiene* [Internet]. 1952;**46**(5):509-520. Available from: <https://www.ncbi.nlm.nih.gov/pubmed/12995440>

[14] Simpson DIH. Zika virus infection in man. *Transactions of the Royal Society of Tropical Medicine and Hygiene* [Internet]. 1964;**58**(4):339-348. DOI: 10.1016/0035-9203(64)90201-9

[15] Duffy MR, Chen T-H, Hancock WT, Powers AM, Kool JL, Lanciotti RS, et al. Zika virus outbreak on Yap Island, Federated States of Micronesia. *New England Journal of Medicine* [Internet]. 2009;**360**(24):2536-2543. DOI: 10.1056/NEJMoa0805715

[16] Cao-Lormeau V-M, Roche C, Teissier A, Robin E, Berry A-L, Mallet H-P, et al. Zika virus, French polynesia, South pacific, 2013. *Emerging Infectious Diseases* [Internet]. 2014;**20**(6):1085-1086. DOI: 10.3201/eid2006.140138

[17] Musso D, Nilles EJ, Cao-Lormeau V-M. Rapid spread of emerging Zika virus in the Pacific area. *Clinical Microbiology and Infection* [Internet]. 2014;**20**(10):O595-O596. DOI: 10.1111/1469-0691.12707

[18] Mlakar J, Korva M, Tul N, Popović M, Poljšak-Prijatelj M, Mraz J, et al. Zika virus associated with microcephaly. *New England Journal of Medicine* [Internet]. 2016;**374**(10):951-958. DOI: 10.1056/NEJMoa1600651

[19] Plourde AR, Bloch EM. A literature review of Zika virus. *Emerging Infectious Diseases* [Internet]. 2016;**22**(7):1185-1192. DOI: 10.3201/eid2207.151990

[20] Calvet G, Aguiar RS, Melo ASO, Sampaio SA, de Filippis I, Fabri A, et al. Detection and sequencing of Zika virus from amniotic fluid of fetuses with microcephaly in Brazil: A case study. *Lancet Infectious Diseases* [Internet]. 2016;**16**(6):653-660. DOI: 10.1016/s1473-3099(16)00095-5

[21] Štrafela P, Vizjak A, Mraz J, Mlakar J, Pižem J, Tul N, et al. Zika virus-associated micrencephaly: A thorough description of neuropathologic findings in the fetal central nervous system. *Archives of Pathology & Laboratory Medicine* [Internet]. 2017;**141**(1):73-81. DOI: 10.5858/arpa.2016-0341-SA

[22] Del Campo M, Feitosa IML, Ribeiro EM, Horovitz DDG, Pessoa ALS, França GVA, et al. Zika Embryopathy task force-Brazilian Society of Medical Genetics ZETF-SBGM. The phenotypic spectrum of congenital Zika syndrome. *American Journal of Medical Genetics. Part A* [Internet]. 2017;**173**(4):841-857. DOI: 10.1002/ajmg.a.38170

[23] Oehler E, Watrin L, Larre P, Leparac-Goffart I, Lastère S, Valour F, et al. Zika virus infection complicated by Guillain-Barré syndrome—Case report, French Polynesia, December 2013. *Euro Surveillance* [Internet]. 2014;**19**(9):1-3. DOI: 10.2807/1560-7917.es2014.19.9.20720

[24] Avelino-Silva VI, Martin JN. Association between Guillain-Barré syndrome and Zika virus infection. *Lancet* [Internet]. 2016;**387**(10038):2599. DOI: 10.1016/s0140-6736(16)30843-1

[25] Vasconcelos PF da C, da Costa Vasconcelos PF. Doença pelo vírus Zika: um novo problema emergente nas Américas? *Revista Pan-Amazônica de Saúde* [Internet]. 2015;**6**(2):9-10. DOI: 10.5123/s2176-62232015000200001

[26] Haddow AD, Schuh AJ, Yasuda CY, Kasper MR, Heang V, Huy R, et al.



Genetic characterization of Zika virus strains: Geographic expansion of the Asian lineage. *PLoS Neglected Tropical Diseases* [Internet]. 2012;**6**(2):e1477. DOI: 10.1371/journal.pntd.0001477

[27] Freire MCLC, Pol-Fachin L, Coêlho DF, Viana IFT, Magalhães T, Cordeiro MT, et al. Mapping putative B-cell Zika virus NS1 epitopes provides molecular basis for anti-NS1 antibody discrimination between Zika and dengue viruses. *ACS Omega* [Internet]. 2017;**2**(7):3913-3920. DOI: 10.1021/acsomega.7b00608

[28] Faye O, Freire CCM, Faye O, de Oliveira JV, Zanutto PMA, Diallo M, et al. Molecular evolution of Zika virus during its emergence in the 20th century. *International Journal of Infectious Diseases* [Internet]. 2014;**21**:2-3. DOI: 10.1016/j.ijid.2014.03.411

[29] Stettler K, Beltramello M, Espinosa DA, Graham V, Cassotta A, Bianchi S, et al. Specificity, cross-reactivity, and function of antibodies elicited by Zika virus infection. *Science* [Internet]. 2016;**353**(6301):823-826. DOI: 10.1126/science.aaf8505

[30] Zhang H, Li W, Wang J, Peng H, Che X, Chen X, et al. NS1-based tests with diagnostic utility for confirming dengue infection: A meta-analysis. *International Journal of Infectious Diseases* [Internet]. 2014;**26**:57-66. DOI: 10.1016/j.ijid.2014.02.002

[31] Balmaseda A, Stettler K, Medialdea-Carrera R, Collado D, Jin X, Zambrana JV, et al. Antibody-based assay discriminates Zika virus infection from other flaviviruses. *Proceedings of the National Academy of Sciences of the United States of America* [Internet]. 2017;**114**(31):8384-8389. DOI: 10.1073/pnas.1704984114

[32] de Vasconcelos ZFM, Azevedo RC, Thompson N, Gomes L, Guida L,

Moreira MEL. Challenges for molecular and serological ZIKV infection confirmation. *Child's Nervous System* [Internet]. 2018;**34**(1):79-84. DOI: 10.1007/s00381-017-3641-5

[33] Hayes EB. Zika virus outside Africa. *Emerging Infectious Diseases* [Internet]. 2009;**15**(9):1347-1350. DOI: 10.3201/eid1509.090442

[34] Longdon B, Brockhurst MA, Russell CA, Welch JJ, Jiggins FM. The evolution and genetics of virus host shifts. *PLoS Pathogens* [Internet]. 2014;**10**(11):e1004395. DOI: 10.1371/journal.ppat.1004395

[35] Plotkin JB, Kudla G. Synonymous but not the same: The causes and consequences of codon bias. *Nature Reviews. Genetics* [Internet]. 2011;**12**(1):32-42. DOI: 10.1038/nrg2899

[36] Logan IS. ZIKA—How fast does this virus mutate? *Dongwuxue Yanjiu* [Internet]. 2016;**37**(2):110-115. DOI: 10.13918/j.issn.2095-8137.2016.2.110

[37] Han J-F, Jiang T, Ye Q, Li X-F, Liu Z-Y, Qin C-F. Homologous recombination of Zika viruses in the Americas. *The Journal of Infection* [Internet]. 2016;**73**(1):87-88. DOI: 10.1016/j.jinf.2016.04.011

[38] Jun S-R, Wassenaar TM, Wanchai V, Patumcharoenpol P, Nookaew I, Ussery DW. Suggested mechanisms for Zika virus causing microcephaly: What do the genomes tell us? *BMC Bioinformatics* [Internet]. 2017;**18**(S14):81-92. DOI: 10.1186/s12859-017-1894-3

[39] Al-Soud WA, Rådström P. Purification and characterization of PCR-inhibitory components in blood cells. *Journal of Clinical Microbiology* [Internet]. 2001;**39**(2):485-493. DOI: 10.1128/JCM.39.2.485-493.2001

[40] Wilson IG. Inhibition and facilitation of nucleic acid

amplification. *Applied and Environmental Microbiology* [Internet]. 1997;**63**(10):3741-3751. Available from: <https://www.ncbi.nlm.nih.gov/pubmed/9327537>

[41] Rådström P, Knutsson R, Wolffs P, Lövenklev M, Löfström C. Pre-PCR processing: Strategies to generate PCR-compatible samples. *MBio Journal* [Internet]. 2004;**26**(2):133-146. Available from: <http://link.springer.com/10.1385/MB:26:2:133>

[42] Paz-Bailey G, Rosenberg ES, Doyle K, Munoz-Jordan J, Santiago GA, Klein L, et al. Persistence of Zika virus in body fluids—Preliminary report. *The New England Journal of Medicine* [Internet]. 14 Feb 2017;**379**(13):1234-1243. DOI: 10.1056/NEJMoa1613108

[43] Colt S, Garcia-Casal MN, Peña-Rosas JP, Finkelstein JL, Rayco-Solon P, Weise Prinzo ZC, et al. Transmission of Zika virus through breast milk and other breastfeeding-related bodily-fluids: A systematic review [Internet]. In: Horstick O, editor. *PLOS Neglected Tropical Diseases*. 10 Apr 2017;**11**(4):e0005528. DOI: 10.1371/journal.pntd.0005528. eCollection 2017 Apr

[44] Leung GHY, Baird RW, Druce J, Anstey NM. ZIKA virus infection in Australia following a monkey bite in Indonesia. *The Southeast Asian Journal of Tropical Medicine and Public Health* [Internet]. 2015;**46**(3):460-464. Available from: <https://www.ncbi.nlm.nih.gov/pubmed/26521519>

[45] Campos R de M, Cirne-Santos C, Meira GLS, Santos LLR, de Meneses MD, Friedrich J, et al. Prolonged detection of Zika virus RNA in urine samples during the ongoing Zika virus epidemic in Brazil. *Journal of Clinical Virology* [Internet]. 2016;**77**: 69-70. DOI: 10.1016/j.jcv.2016.02.009

[46] Landry ML, St George K. Laboratory diagnosis of Zika virus

infection. *Archives of Pathology & Laboratory Medicine* [Internet]. 2017;**141**(1):60-67. DOI: 10.5858/arpa.2016-0406-SA

[47] Nicastri E, Castilletti C, Liuzzi G, Iannetta M, Capobianchi MR, Ippolito G. Persistent detection of Zika virus RNA in semen for six months after symptom onset in a traveller returning from Haiti to Italy, February 2016. *Euro Surveillance* [Internet]. 2016;**21**(32):1-4. DOI: 10.2807/1560-7917.ES.2016.21.32.30314

[48] Atkinson B, Hearn P, Afrough B, Lumley S, Carter D, Aarons EJ, et al. Detection of Zika virus in semen. *Emerging Infectious Diseases* [Internet]. 2016;**22**(5):940. DOI: 10.3201/eid2205.160107

[49] Halai U-A, Nielsen-Saines K, Moreira ML, de Sequeira PC, Junior JPP, de Araujo Zin A, et al. Maternal Zika virus disease severity, virus load, prior dengue antibodies, and their relationship to birth outcomes. *Clinical Infectious Diseases* [Internet]. 2017;**65**(6):877-883. DOI: 10.1093/cid/cix472

[50] Musso D, Rouault E, Teissier A, Lanteri MC, Zisou K, Broult J, et al. Molecular detection of Zika virus in blood and RNA load determination during the French Polynesian outbreak. *Journal of Medical Virology* [Internet]. 2017;**89**(9):1505-1510. DOI: 10.1002/jmv.24735

[51] Faye O, Faye O, Diallo D, Diallo M, Weidmann M, Sall A. Quantitative real-time PCR detection of Zika virus and evaluation with field-caught mosquitoes. *Virology Journal* [Internet]. 2013;**10**(1):311. DOI: 10.1186/1743-422x-10-311

[52] Pyke AT, Daly MT, Cameron JN, Moore PR, Taylor CT, Hewitson GR, et al. Imported Zika virus infection from the Cook Islands into Australia, 2014. *PLOS Currents* [Internet]. 2014;**2**:6.

DOI: 10.1371/currents.outbreaks.4635a54dbffba2156fb2fd76dc49f65e

[53] Tappe D, Nachtigall S, Kapaun A, Schnitzler P, Günther S, Schmidt-Chanasit J. Acute Zika virus infection after travel to Malaysian Borneo, September 2014. *Emerging Infectious Diseases* [Internet]. 2015;**21**(5):911-913. DOI: 10.3201/eid2105.141960

[54] Corman VM, Rasche A, Baronti C, Aldabbagh S, Cadar D, Reusken CB, et al. Assay optimization for molecular detection of Zika virus. *Bulletin of the World Health Organization* [Internet]. 2016;**94**(12):880-892. DOI: 10.2471/BLT.16.175950

[55] Waggoner JJ, Pinsky BA. Zika virus: Diagnostics for an emerging pandemic threat. *Journal of Clinical Microbiology* [Internet]. 2016;**54**(4):860-867. DOI: 10.1128/JCM.00279-16

[56] Balmaseda A, Zambrana JV, Collado D, García N, Saborío S, Elizondo D, et al. Comparison of four serological methods and two reverse transcription-PCR assays for diagnosis and surveillance of Zika virus infection. *Journal of Clinical Microbiology* [Internet]. 2018;**56**(3):1-13. DOI: 10.1128/JCM.01785-17

[57] Rosenberg AZ, Yu W, Hill DA, Reyes CA, Schwartz DA. Placental pathology of Zika virus: Viral infection of the placenta induces villous stromal macrophage (Hofbauer cell) proliferation and hyperplasia. *Archives of Pathology & Laboratory Medicine* [Internet]. 2017;**141**(1):43-48. DOI: 10.5858/arpa.2016-0401-OA

[58] Bhatnagar J, Rabeneck DB, Martinez RB, Reagan-Steiner S, Ermias Y, Estetter LBC, et al. Zika virus RNA replication and persistence in brain and placental tissue. *Emerging Infectious Diseases* [Internet]. 2017;**23**(3):405-414. DOI: 10.3201/eid2303.161499

[59] Azevedo RSS, Araujo MT, Martins Filho AJ, Oliveira CS, Nunes BTD,

Cruz ACR, et al. Zika virus epidemic in Brazil. I. Fatal disease in adults: Clinical and laboratorial aspects. *Journal of Clinical Virology* [Internet]. 2016;**85**: 56-64. DOI: 10.1016/j.jcv.2016.10.024

[60] Chimelli L, Pone SM, Avvad-Portari E, Vasconcelos ZFM, Zin AA, Cunha DP, et al. Persistence of Zika virus after birth: Clinical, virological, neuroimaging, and neuropathological documentation in a 5-month infant with congenital Zika syndrome. *Journal of Neuropathology and Experimental Neurology* [Internet]. 2018;**77**(3): 193-198. DOI: 10.1093/jnen/nlx116

[61] Tan SK, Sahoo MK, Milligan SB, Taylor N, Pinsky BA. Stability of Zika virus in urine: Specimen processing considerations and implications for the detection of RNA targets in urine. *Journal of Virological Methods* [Internet]. 2017;**248**:66-70. DOI: 10.1016/j.jviromet.2017.04.018

[62] Johnson BW, Kosoy O, Martin DA, Noga AJ, Russell BJ, Johnson AA, et al. West Nile virus infection and serologic response among persons previously vaccinated against yellow fever and Japanese encephalitis viruses. *Vectorborne and Zoonotic Diseases* [Internet]. 2005;**5**(2):137-145. DOI: 10.1089/vbz.2005.5.137

[63] Mohammed H, Tomashek KM, Stramer SL, Hunsperger E. Prevalence of anti-dengue immunoglobulin G antibodies among American Red Cross blood donors in Puerto Rico, 2006. *Transfusion* [Internet]. 2012;**52**(8):1652-1656. DOI: 10.1111/j.1537-2995.2011.03492.x

[64] Prince HE, Matud JL. Estimation of dengue virus IgM persistence using regression analysis. *Clinical and Vaccine Immunology* [Internet]. 2011;**18**(12): 2183-2185. DOI: 10.1128/cvi.05425-11

[65] Busch MP, Kleinman SH, Tobler LH, Kamel HT, Norris PJ, Walsh I, et al. Virus and antibody dynamics in



acute west nile virus infection.

The Journal of Infectious Diseases [Internet]. 2008;**198**(7):984-993. DOI: 10.1086/591467

[66] Theel ES, Hata DJ. Diagnostic testing for Zika virus: A postoutbreak update. Journal of Clinical Microbiology [Internet]. 2018 Apr;**56**(4). DOI: 10.1128/JCM.01972-17

[67] Oduyebo T, Igbiosa I, Petersen EE, Polen KND, Pillai SK, Ailes EC, et al. Update: Interim guidance for health care providers caring for pregnant women with possible Zika virus exposure—United States, July 2016. Morbidity and Mortality Weekly Report [Internet]. 2016;**65**(29):739-744. DOI: 10.15585/mmwr.mm6529e1

[68] Montoya JG. Laboratory diagnosis of *Toxoplasma gondii* infection and toxoplasmosis. The Journal of Infectious Diseases [Internet]. 2002;**185**(Suppl 1):S73-S82. DOI: 10.1086/338827

[69] Dale Carroll I, Toovey S, Van Gompel A. Dengue fever and pregnancy—A review and comment. Travel Medicine and Infectious Disease [Internet]. 2007;**5**(3):183-188. DOI: 10.1016/j.tmaid.2006.11.002

[70] Tunkel AR, Glaser CA, Bloch KC, Sejvar JJ, Marra CM, Roos KL, et al. The management of encephalitis: Clinical practice guidelines by the Infectious Diseases Society of America. Clinical Infectious Diseases [Internet]. 2008;**47**(3):303-327. DOI: 10.1086/589747

[71] Cordeiro MT, Pena LJ, Brito CA, Gil LH, Marques ET. Positive IgM for Zika virus in the cerebrospinal fluid of 30 neonates with microcephaly in Brazil. Lancet [Internet]. 2016;**387**(10030):1811-1812. DOI: 10.1016/s0140-6736(16)30253-7

[72] Roehrig JT, Hombach J, Barrett ADT. Guidelines for

plaque-reduction neutralization testing of human antibodies to dengue viruses. Viral Immunology [Internet]. 2008;**21**(2):123-132. DOI: 10.1089/vim.2008.0007

[73] Puschnik A, Lau L, Cromwell EA, Balmaseda A, Zompi S, Harris E. Correlation between dengue-specific neutralizing antibodies and serum avidity in primary and secondary dengue virus 3 natural infections in humans. PLoS Neglected Tropical Diseases [Internet]. 2013;**7**(6):e2274. DOI: 10.1371/journal.pntd.0002274

[74] Oladapo OT, Souza JP, De Mucio B, de León RGP, Perea W, Gülmezoglu AM, et al. WHO interim guidance on pregnancy management in the context of Zika virus infection. Lancet glob. Health [Internet]. 2016;**4**(8):e510-e511. DOI: 10.1016/S2214-109X(16)30098-5

[75] Moore CA, Erin Staples J, Dobyns WB, Pessoa A, Ventura CV, da Fonseca EB, et al. Characterizing the pattern of anomalies in congenital Zika syndrome for pediatric clinicians. JAMA Pediatrics [Internet]. 2017;**171**(3):288. DOI: 10.1001/jamapediatrics.2016.3982

[76] Brasil P, Pereira JP Jr, Moreira ME, Ribeiro Nogueira RM, Damasceno L, Wakimoto M, et al. Zika virus infection in pregnant women in Rio de Janeiro. New England Journal of Medicine [Internet]. 2016;**375**(24):2321-2334. DOI: 10.1056/NEJMoa1602412

[77] Zin AA, Tsui I, Rossetto J, Vasconcelos Z, Adachi K, Valderramos S, et al. Screening criteria for ophthalmic manifestations of congenital Zika virus infection. JAMA Pediatrics [Internet]. 2017;**171**(9):847. DOI: 10.1001/jamapediatrics.2017.1474

[78] Website [Internet]. Division of vector-borne diseases. Revised diagnostic testing for Zika, chikungunya, and dengue viruses in US Public Health Laboratories. Cdc



- [Internet]. 2014;1:1-5. Available from: <http://stacks.cdc.gov/view/cdc/38149> [cited: 09 September 2018]
- [79] Website [Internet]. Oladapo OT, Souza JP, De Mucio B, de León RGP, Perea W, Gülmezoglu AM, WHO Guideline Development Group. WHO interim guidance on pregnancy management in the context of Zika virus infection. *Lancet Global Health* [Internet]. 2016;4(8):e510-e511. DOI: 10.1016/S2214-109X(16)30098-5 [cited: 09 September 2018]
- [80] Levine D, Jani JC, Castro-Aragon I, Cannie M. How does imaging of congenital Zika compare with imaging of other TORCH infections? *Radiology* [Internet]. 2017;285(3):744-761. DOI: 10.1148/radiol.2017171238
- [81] De Santis M, De Luca C, Mappa I, Spagnuolo T, Licameli A, Straface G, et al. Syphilis infection during pregnancy: Fetal risks and clinical management. *Infectious Diseases in Obstetrics and Gynecology* [Internet]. 2012;2012:1-5. DOI: 10.1155/2012/430585
- [82] Kang JH. Febrile illness with skin rashes. *Infection & Chemotherapy* [Internet]. 2015;47(3):155. DOI: 10.3947/ic.2015.47.3.155
- [83] Al-Khan A, Caligiuri A, Apuzzio J. Parvovirus B-19 infection during pregnancy. *Infectious Diseases in Obstetrics and Gynecology* [Internet]. 2003;11(3):175-179. DOI: 10.1080/10647440300025518
- [84] Lamont RF, Sobel JD, Carrington D, Mazaki-Tovi S, Kusanovic JP, Vaisbuch E, et al. Varicella-zoster virus (chickenpox) infection in pregnancy. *BJOG: An International Journal of Obstetrics & Gynaecology* [Internet]. 2011;118(10):1155-1162. DOI: 10.1111/j.1471-0528.2011.02983.x
- [85] Picone O, Simon I, Benachi A, Brunelle F, Sonigo P. Comparison between ultrasound and magnetic resonance imaging in assessment of fetal cytomegalovirus infection. *Prenatal Diagnosis* [Internet]. 2008;28(8):753-758. DOI: 10.1002/pd.2037
- [86] Soares de Oliveira-Szejnfeld P, Levine D, Melo AS de O, Amorim MMR, Batista AGM, Chimelli L, et al. Congenital brain abnormalities and Zika virus: What the radiologist can expect to see prenatally and postnatally. *Radiology* [Internet]. 2016;281(1):203-218. DOI: 10.1148/radiol.2016161584
- [87] Website [Internet]. TORCH syndrome. *Lancet* [Internet]. 1998;351(9123):194-203. Available from: <http://eurheartj.oxfordjournals.org/cgi/doi/10.1053/euhj.1997.0817> [cited: 23 September 2018]
- [88] Nahmias AJ, Walls KW, Stewart JA, Herrmann KL, Flynt WJ. The ToRCH complex-perinatal infections associated with toxoplasma and rubella, cytomegal- and herpes simplex viruses. *Pediatric Research* [Internet]. 1971;5(8):405-406. DOI: 10.1203/00006450-197108000-00144
- [89] Hampton MM. Congenital toxoplasmosis: A review. *Neonatal Network* [Internet]. 2015;34(5):274-278. DOI: 10.1891/0730-0832.34.5.274