

We are IntechOpen, the world's leading publisher of Open Access books Built by scientists, for scientists

6,900

Open access books available

186,000

International authors and editors

200M

Downloads

Our authors are among the

154

Countries delivered to

TOP 1%

most cited scientists

12.2%

Contributors from top 500 universities



WEB OF SCIENCE™

Selection of our books indexed in the Book Citation Index
in Web of Science™ Core Collection (BKCI)

Interested in publishing with us?
Contact book.department@intechopen.com

Numbers displayed above are based on latest data collected.
For more information visit www.intechopen.com



Vestibular Schwannomas: Diagnosis and Surgical Treatment

Gustavo Jung and Ricardo Ramina

Abstract

Over the last decades, significant advances in skull base surgery have enabled many neurosurgical centers around the world to perform surgical resection of vestibular schwannomas; otherwise, clinical observation and radiotherapy/radio-surgery can be possible management options. Auditory pattern, the presence of bilateral tumors, tumor size, and neurological symptoms are deeply considered in the decision-making process. In this chapter, we expanded the general discussion of vestibular schwannomas, discussing bases for an accurate diagnose and the technical aspects for the surgical approaches, drilling of internal auditory canal, and its reconstruction as well as the technical nuances when handling very small and large/residual tumors.

Keywords: vestibular schwannoma, acoustic neuroma, acoustic tumor, cerebellopontine angle

1. Introduction

Vestibular schwannomas (VS) account for 6–8% of all intracranial neoplasms and around 90% of cerebellopontine angle tumors (CPA) [1]. It is usually a sporadic tumor but can be bilateral in cases of neurofibromatosis type 2, when larger tumors are common.

Over the last decades, significant advances in skull base surgery have enabled many neurosurgical centers around the world to perform surgical resection of VS with good functional outcomes (facial nerve and hearing preservation). Deeper observation about the natural history of these lesions and the development of radiosurgery have increased the options to manage VS. The rates of surgical morbidity and mortality have also declined dramatically, and functional preservation of the facial nerve has been possible even in larger tumors.

2. Natural history

The natural history of VS is highly unpredictable. Some tumors exhibit continuous growth, while others remain stable or even decrease in size, and its reason is not known. In the literature, a mean growth rate of 2.9 mm per year is reported, and a growth rate of 2.5 mm/year is associated with worse hearing function.

3. Management options

Clinical observation, microsurgical removal, and radiotherapy/radiosurgery are the management options. Different factors make treatment decision highly variable. Small tumors may be followed with regular MRI examinations and audiograms. Patients harboring small tumors and presenting progressive hearing loss, microsurgical removal, or radiosurgery should be considered. Preoperative hearing level is a prognostic factor for postoperative hearing preservation. Tumors up to 3 cm in diameter may be treated either by microsurgical removal or radiosurgery, and larger tumors will require surgical resection. Cystic VS may present sudden growth and surgical removal is the best option. The management of bilateral tumors in NF2 patients is complex, and the quality of hearing in both ears and size of the tumors will be the main factors to decide how to treat these patients.

4. Diagnosis

VS commonly arise from the vestibular division of the eighth cranial nerve. Dizziness, vertigo, and progressive hearing loss (earliest symptom) are the most frequent complaints. Dizziness is routinely transient and episodic, and the patient can neglect it for a variable period of time. Dizziness is a frequent complaint in daily ENT practice, and patients complaining of unilateral hearing loss associated or not to vestibular symptoms are frequently seen by ENT surgeons. Very often these symptoms are not adequately investigated, and it is a common cause to miss the diagnosis.

Facial nerve weakness is observed in only 6% of the patients [2]. In larger and mainly cystic tumors that present fast growth, facial numbness (due to trigeminal nerve compression) and gait ataxia (due to brain stem displacement) can appear [3, 4].

Hydrocephalus is relatively common in VS patients. In larger tumors it is caused by IV ventricle displacement, leading to obstructive hydrocephalus. In smaller tumors, degenerative changes on the tumor content can increase the protein rates on CSF, causing CSF malabsorption and consequent hydrocephalus [5]. When hydrocephalus is present, a preoperative external ventricular CSF drainage is required. Ventriculoperitoneal shunt is done especially in patients without major CSF obstruction when the tumor removal is less probable to relieve.

5. Audiological evaluation

Hearing function is evaluated with audiograms with sound discrimination. There are different classifications to preoperatively grade the hearing function. Brain stem evoked response audiometry (BERA) provides reliable information on the hearing function from the ear to the brain stem, and to determine the nerve of origin in vestibular schwannomas, the video Head Impulse Test (vHIT) is usually performed.

6. Radiological diagnosis

CT scan is useful to demonstrate the bony anatomy, the position of the jugular bulb, and the semicircular canals. Vestibular schwannomas often expand the internal auditory canal [10].

Magnetic resonance imaging (MRI) is the eligible test to diagnose and evaluate patients with a vestibular schwannomas. T1, T2, FLAIR, and DWI images are usually sufficient for the diagnosis. Over 50% of vestibular schwannomas are isointense in T1-weighted images; hypointensities usually represent a cystic component (**Figure 1**). VS present usually intense homogeneous gadolinium enhancement on T1-weighted images, but cystic lesions can present a heterogenous pattern. A hyperintense signal inside of the IAC in FLAIR images and nodular hyperintense signal in the vestibular nuclei on the dorsal pons in T2-weighted images can additionally differentiate vestibular schwannomas from other cerebellopontine angle tumors (**Figure 2**). T2-weighted images and tractography may demonstrate the position of the facial nerve and its relation to the tumor capsule [5, 6]. When a watchful waiting is decided, MRI volumetric studies have an excellent accuracy to follow tumor growth [7]. 3D T2 CISS or post-contrast 3D T1 MPRAGE MRI (evidence class II) provides best images to monitor tumor growth [8, 9].

After surgical resection, a thin not-nodular enhancement is often visualized in surgical resection field. It can persist for years but usually reduces over the time [11]. Fat grafts, fibrin glue, and muscle grafts, used to reconstruct the IAC, can generate a nodular enhancement which usually appear within the first 3 days after surgery. New nodular enhancement appearing in the postoperative follow-up highly suggests tumor recurrence [12].

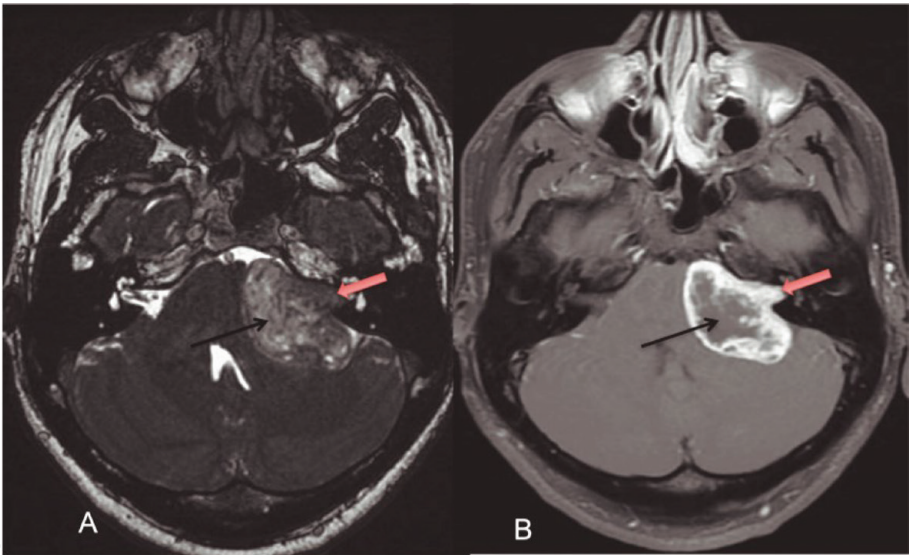


Figure 1.
Large vestibular schwannoma. (A) T2-weighted image showing a solid (red arrow) and cystic tumor (black arrow). (B) Post-contrast-weighted image exhibiting intense contrast enhancement in the solid portion (red arrow) and heterogeneous pattern in the cystic component (black arrow).

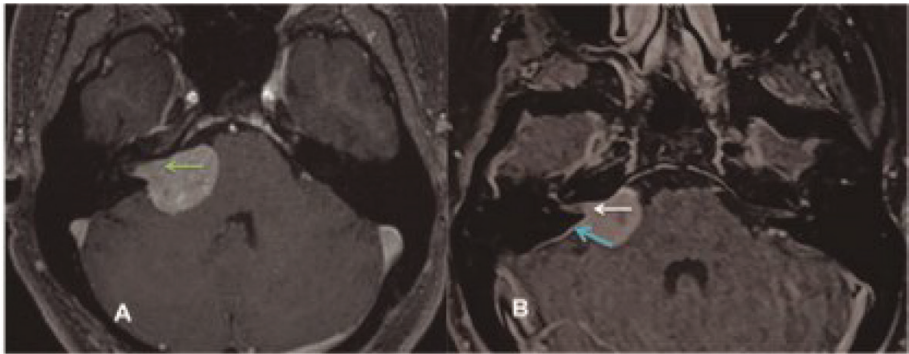


Figure 2.
T2-weighted image with a small vestibular schwannoma (green arrow) with hyperintensity in the dorsal pons (blue arrow).

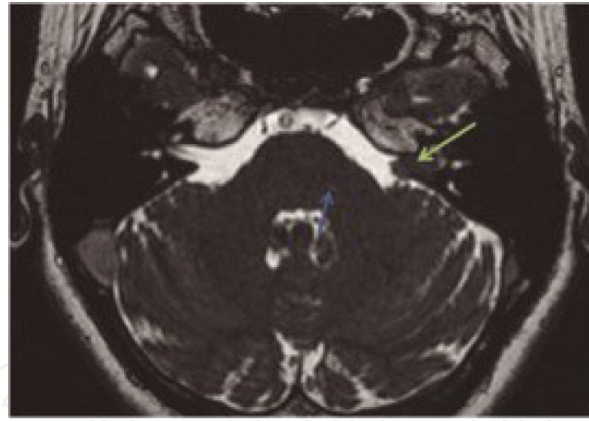


Figure 3. (A) Expansion of IAC caused by vestibular schwannoma (green arrow). (B) Normal width of IAC in a patient with CPA meningioma and IAC involvement (white arrow). Dural enhancement (blue arrow) strongly suggests its diagnosis.

Meningiomas are the most frequent differential diagnosis between non-schwannomatous lesions that arise or protrude into the IAC. Meningiomas usually present a dural enhancement and display calcification, and hyperostosis in the adjacent bone is usually seen (**Figure 3**).

7. Treatment

Vestibular schwannoma is a benign intracranial nerve sheath tumor, usually sporadic but that may be bilateral in the context of neurofibromatosis type 2. Wait and scan strategy, microsurgical resection, and radiotherapy/radiosurgery are the options. Presenting symptoms, hearing status, growth rate, size and characteristic of tumor, and surgeon preference will interfere in these treatment decisions [13].

8. Microsurgical resection

The goals of the treatment are radical resection with zero mortality and complete anatomical and functional preservation of the involved cranial nerves. Some authors propose partial resection followed, or not, by radiotherapy/radiosurgery to preserve cranial nerve function [14]. However, the only treatment that offers cure is radical microsurgical removal.

VS might be approached through translabyrinthine, retrosigmoid, or middle fossa craniotomy. The main advantage of the translabyrinthine approach is to minimize brain retraction. The difficulty to resect larger tumor damage to hearing structures is the limitation of this surgical approach. Fat grafts are needed to close the dura and avoid CSF fistula. In small tumors, best suited to translabyrinthine approach, commonly serviceable hearing is present, which ultimately turns this surgical option unfeasible.

The middle fossa approach (MFA) is a lateral access to the IAC and was popularized by House in 1961. The exposition of the IAC through its superior wall makes it a good option for small lateral tumors restricted to the internal auditory canal and brings the lowest risk to the labyrinth structures.

The retrosigmoid (RS) approach is the most used access by the majority of neurosurgeons offering an excellent exposition of all anatomical structures of the posterior fossa. The IAC is opened through the RS, and injury to the inner ear structures (labyrinth) and jugular bulb are avoidable complications [15]. This is the approach of choice to VS, regardless of its size, in our department. The dorsal

decubitus is preferred by the authors due to the lower risk of air embolism and to provide a more comfortable work position for the surgeon.

A 4 cm diameter craniotomy is cut laterally bordering the sigmoid sinus to avoid cerebellar retraction. In most cases, in the dorsal position, a cerebellar retractor is only used to protect the cerebellum during the drilling of internal auditory canal.

After the dura opening, CSF is released from the cerebellomedullary cisterna to relax the pressure in the posterior fossa. The inspection of the bridging veins over the tentorial surface of the cerebellum is highly recommended as it can be a potential source of bleeding.

The IAC is drilled as the first step in most cases. It reduces the pressure over the cochlear and the facial nerves. Piecemeal resection with ultrasound aspirator is useful to debulk the cisternal component and reduces the traction over the tumor capsule. The facial nerve is usually very attached to the tumor capsule at its entrance in the IAC, and careful microsurgical dissection should be performed under continuous electrophysiologic monitoring. Preservation of the cochlear nerve is also attempted under continuous BERA monitoring. If an alteration of the waves is observed, the surgical field is irrigated with papaverine solution awaiting until recovery is recorded. Cystic and larger tumors usually present more difficulty to dissect the facial nerve from tumor capsule. Hearing preservation is a challenge in tumors larger than 3 cm in diameter. In NF2 patients with bilateral tumor, preservation of hearing should be attempted even if residual tumor must be left. Brain stem decompression with hearing preservation is the goal of treatment in these cases.

Reconstruction of the IAC is extremely important to avoid CSF fistula and infection. To identify the mastoid air cells inside the IAC, the use of the endoscope can be opportune, and small pieces of muscle or fat graft should be used to seal these cells.

9. Residual tumor

In our series of 541 VS surgically resected between 1987 and 2016, 31 patients had residual/recurrent tumors. Twenty-seven patients had been operated elsewhere. From the 4 patients in our own casuistry, two cases were recurrences and two were residual lesions. One of the residual cases was a patient with neurofibromatosis type 2 and showing large bilateral VS who underwent radical resection in one side and subtotal removal of the contralateral tumor for hearing preservation. The other case was a 75-year-old patient with large cystic VS who underwent stereotactic aspiration of the cyst to alleviate mass effect, since surgical resection was not advised for medical reasons.

The causes for subtotal removal, as reported by the patient, were extensive intraoperative bleeding, adherence to the brain stem or facial nerve, and intraoperative cerebellar edema. All patients were reoperated at our institution through the retrosigmoid/transmeatal approach. The surgical procedure proved to be significantly more difficult than in non-operated cases. Fibrosis from previous procedure(s) altered the anatomical location of the transverse and sigmoid sinus, as well as the dissection and opening of the dura mater. Intracranially, the arachnoid plane usually found between the tumor and the brain stem and cranial nerves was lost; thus, dissection of the tumor required more manipulation of those structures. This was especially significant in irradiated patients. We observed that in cases in which the IAC had not been previously opened, identification and dissection of the facial nerve and subsequent dissection were less difficult. Postoperative anatomical preservation of the facial nerve was possible in 13 (76%) of 17 patients with preoperative facial nerve function. There was no permanent morbidity or mortality. All cases were histologically confirmed as WHO grade I schwannomas [16].

10. Intralabyrinthine tumors

Intralabyrinthine VS are by definition tumors arising at the terminal end of the eighth cranial nerve within the vestibule, cochlea, or semicircular canal [17]. According to its location, intralabyrinthine schwannomas may be anatomically divided in six major types: intravestibular, vestibulocochlear, modiolar, transotic, intracochlear, and transmacular schwannomas (Figures 4–7).

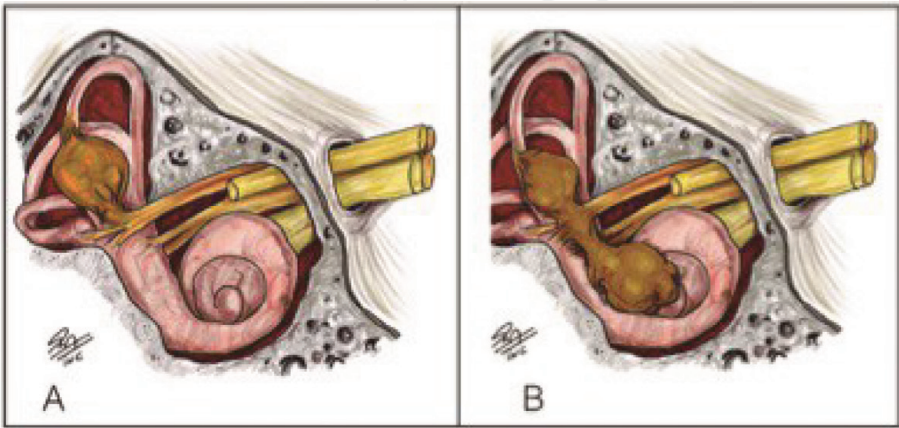


Figure 4.
(A) Intravestibular schwannoma. (B) Vestibulocochlear schwannoma. Intravestibular schwannomas are located in the labyrinth. Vestibulocochlear schwannomas grow in the labyrinth and cochlea.

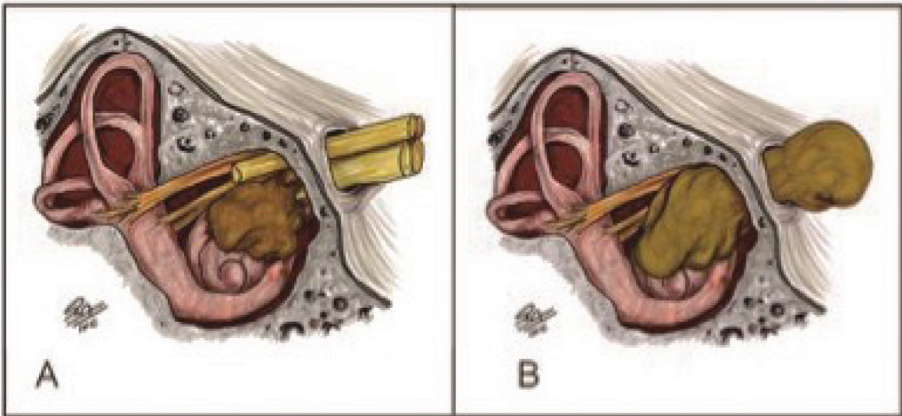


Figure 5.
(A) Modiolar schwannoma. (B) Transotic schwannoma.

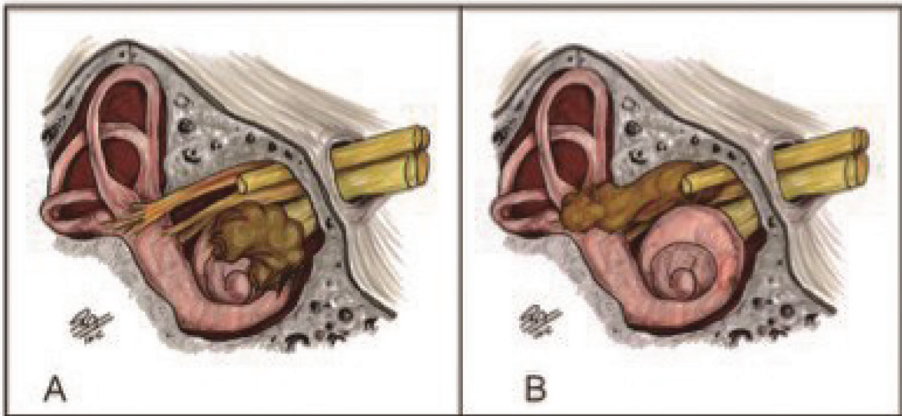


Figure 6.
(A) Intracochlear schwannoma. (B) Transmacular schwannoma.

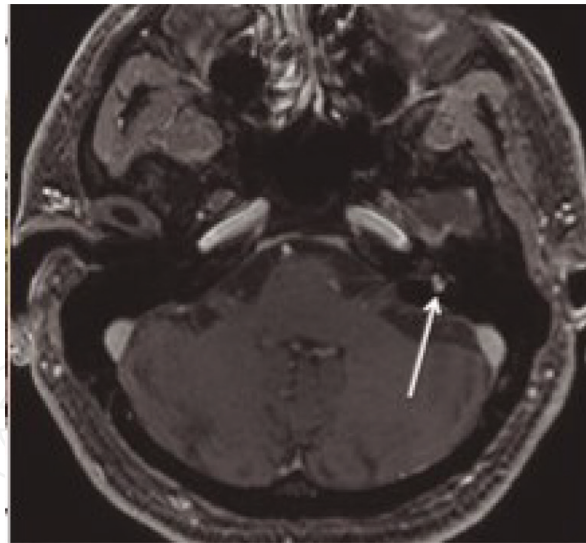


Figure 7.
Post-contrast T1-weighted image demonstrating a transmacular schwannoma (white arrow).

Modiolar schwannomas arise at the cochlea and extend in the modiolus and the IAC. Transotic schwannomas grow from the labyrinth into the IAC and middle ear.

Intracochlear schwannomas are located in the cochlea. Transmacular schwannomas arise in the vestibule and extend into the internal auditory canal through the macula cribrosa.

These tumors have been frequently observed on MRI examinations, but their management was rarely reported in the literature [18].

Labyrinthitis and otitis may also cause gadolinium enhancement of the vestibular nerves and mimic intralabyrinthine tumors. However, in these pathologies the enhancement is less sharp, and the cochlea, as well as the entire vestibular system, may exhibit contrast enhancement [19].

Clinical observation is recommended in patients already deaf and if the vestibular symptoms are slight and treatable. Microsurgical removal is curative, but hearing preservation is very challenging since these tumors often affect the cochlea and the semicircular canals. The retrosigmoid-transmeatal endoscopic-assisted approach is very useful and provides an excellent view of the lateral portion of IAC. A wide and deep opening of the IAC (about 1 cm in length) is required to resect those lesions. Symptoms of intractable vertigo usually disappear after microsurgical removal of the lesion [20, 21].

Author details

Gustavo Jung* and Ricardo Ramina
Skull Base Division, Department of Neurosurgery, Neurological Institute of
Curitiba, Curitiba, Brazil

*Address all correspondence to: gustavosjung@gmail.com

IntechOpen

© 2019 The Author(s). Licensee IntechOpen. This chapter is distributed under the terms of the Creative Commons Attribution License (<http://creativecommons.org/licenses/by/3.0>), which permits unrestricted use, distribution, and reproduction in any medium, provided the original work is properly cited. 

References

- [1] Machinis TG, Fountas KN, Dimomopolos V, Robinson JS. History of acoustic neurinoma surgery. *Neurosurgical Focus*. 2005;**18**(4):1-4
- [2] Matthies C, Samii M. Management of 1000 vestibular schwannomas (acoustic neuromas): Clinical presentation. *Neurosurgery*. 1997;**40**(1):1-10
- [3] Piccirillo E, Wiet MR, Flanagan S, Dispenza F, Giannuzzi A, Mancini F, et al. Cystic vestibular schwannoma: Classification, management, and facial nerve outcomes. *Otology & Neurotology*. 2009;**30**(6):826-834
- [4] Thakur JD, Khan IS, Shorter CD, Sonig A, Gardner GL, Guthikonda B, et al. Do cystic vestibular schwannomas have worse surgical outcomes: Systematic analysis of the literature. *Neurosurgical Focus*. 2012;**33**(3):E12
- [5] Taniguchi M, Nakai T, Kohta M, Kimura H, Kohmura E. Communicating hydrocephalus associated with small- to medium-sized vestibular schwannomas: Clinical significance of the tumor apparent diffusion coefficient map. *World Neurosurgery*. 2016;**94**:261-267
- [6] Liang C, Zhang B, Wu L, Du Y, Wang X, Liu C, et al. The superiority of 3D-CISS sequence in displaying the cisternal segment of facial, vestibulocochlear nerves and their abnormal changes. *European Journal of Radiology*. 2010;**74**(3):437-440
- [7] Choi KS, Kim MS, Kwon HG, Jang SH, Kim OL. Preoperative identification of facial nerve in vestibular schwannomas surgery using diffusion tensor tractography. *Journal of Korean Neurosurgical Association*. 2014;**56**(1):11-15
- [8] Tan TY. Non-contrast high resolution fast spin echo magnetic resonance imaging of acoustic schwannoma. *Singapore Medical Journal*. 1999;**40**(1):27-31
- [9] Held P, Fellner C, Seitz J, Graf S, Fellner F, Strutz J. The value of T2(*)-weighted MR images for the diagnosis of acoustic neuromas. *European Journal of Radiology*. 1999;**30**(3):237-244
- [10] Held P, Fellner C, Fellner F, Seitz J, Graf S, Hilbert M, et al. MRI of inner ear and facial nerve pathology using 3D MP-RAGE and 3D CISS sequences. *The British Journal of Radiology*. 1997;**70**(834):558-566
- [11] Tomogane Y, Mori K, Izumoto S, Kaba K, Ishikura R, Ando K, et al. Usefulness of PRESTO magnetic resonance imaging for the differentiation of schwannoma and meningioma in the cerebellopontine angle. *Neurologia Medico-Chirurgica (Tokyo)*. 2013;**53**(7):482-489
- [12] Carlson ML, Van Abel KM, Driscoll CL, Neff BA, Beatty CW, Lane JI, et al. Magnetic resonance imaging surveillance following vestibular schwannoma resection. *Laryngoscope*. 2012;**122**(2):378-388
- [13] Bennett ML, Jackson CG, Kaufmann R, Warren F. Postoperative imaging of vestibular schwannomas. *Otolaryngology and Head and Neck Surgery*. 2008;**138**(5):667-671
- [14] Taylor RL, Kong J, Flanagan S, Pogson J, Croxson G, Pohl D, et al. Prevalence of vestibular dysfunction in patients with vestibular schwannoma using video head-impulses and vestibular-evoked potentials. *Journal of Neurology*. 2015;**262**(5):1228-1237
- [15] Samii M, Gerganov VM, Samii A. Functional outcome after complete surgical removal of giant vestibular

schwannomas. *Journal of Neurosurgery*.
2010;**112**(4):860-867

[16] Tatagiba M, Samii M, Matthies C, El Azm M, Schönmayr R. The significance for postoperative hearing of preserving the labyrinth in acoustic neurinoma surgery. *Journal of Neurosurgery*. 1992;**77**(5):677-684

[17] Kennedy RJ, Shelton C, Salzman KL, Davidson HC, Harnsberger HR. Intralabyrinthine schwannomas: Diagnosis, management, and a new classification system. *Otology & Neurotology*. 2004;**25**(2):160-167

[18] Magliulo G, Colicchio G, Romana AF, Stasolla A. Intracochlear schwannoma. *Skull Base*. 2010;**20**(2):115-118

[19] Harnsberger R, Glastonbury CM, Michel MA, Harnsberger HR, Glastonbury CM, Michel MA, et al. *Diagnostic Imaging: Head and Neck*. 2nd ed. Baltimore: Lippincott, Williams & Wilkins; 2010. https://www.amazon.co.uk/s/ref=dp_byline_sr_book_4?ie=UTF8&text=Bernadette+L.+Koch&search-alias=books-uk&field-author=Bernadette+L.+Koch&sort=relevancerank

[20] Samii M, Matthies C, Tatagiba M. Intracanalicular acoustic neurinomas. *Neurosurgery*. 1991;**29**(2):189-199

[21] Samii M, Metwali H, Gerganov V. Efficacy of microsurgical tumor removal for treatment of patients with intracanalicular vestibular schwannoma presenting with disabling vestibular symptoms. *Journal of Neurosurgery*. 2017;**126**(5):1514-1519