

We are IntechOpen, the world's leading publisher of Open Access books Built by scientists, for scientists

6,900

Open access books available

185,000

International authors and editors

200M

Downloads

Our authors are among the

154

Countries delivered to

TOP 1%

most cited scientists

12.2%

Contributors from top 500 universities



WEB OF SCIENCE™

Selection of our books indexed in the Book Citation Index
in Web of Science™ Core Collection (BKCI)

Interested in publishing with us?
Contact book.department@intechopen.com

Numbers displayed above are based on latest data collected.
For more information visit www.intechopen.com



Current Noninvasive MR-Based Imaging Methods in Assessing NAFLD Patients

Diana Feier, Delia Muntean, Nina Bastati and Ahmed Ba-Ssalamah

Abstract

The chapter will focus on the different aspects of nonalcoholic fatty liver disease (NAFLD). An update in noninvasive MR-based imaging will be offered in detail, pointing mainly to fat, iron, and fibrosis deposition and the accuracy of quantitative methods in disease grading and severity assessment. NAFLD is the most common cause of chronic liver disease (CLD) in Western countries. MRI is used to evaluate the disease, to assess the severity, and to quantify the amount of fat deposition, being also the method of choice to evaluate and quantify iron overload. Diagnosis and staging of liver fibrosis is one of the most challenging aspects of non-invasive imaging. “Virtual biopsy” refers to the possibility of imaging techniques to depict, map, and measure fibrosis minimizing the need for invasive liver biopsies in CLD. MRI allows an accurate determination of steatosis, iron overload, and fibrosis, even if they coexist.

Keywords: steatosis, fibrosis, iron overload, contrast-enhanced MRI, chemical shift sequences

1. Introduction

1.1 The importance of noninvasive evaluation of liver steatosis and fibrosis in NAFLD patients

NAFLD is currently the most common cause of CLD worldwide. It is defined by lipid droplet accumulation within hepatocytes in the absence of substantial alcohol intake. NAFLD comprises a disease spectrum ranging from simple steatosis to nonalcoholic steatohepatitis (NASH), which may progress into liver fibrosis and even end-stage cirrhosis [1]. NAFLD is becoming a major concern with the increasing incidence of obesity in Europe. Available data suggest that the global prevalence of NAFLD is estimated at 24%, being the leading cause of CLD in the USA and Europe [2].

The differentiation of simple steatosis from NASH has a great clinical importance. Additionally to liver steatosis, NASH presents inflammation and hepatocellular injury [3]. The differentiation between both entities is routinely made by histopathological analysis after liver biopsy. However, it is an invasive method, with inherent risks that include sampling error and serious complications [4].

Currently, there is an urgent need for a noninvasive method to accurately assess liver fibrosis and liver steatosis. Ultrasonography (US)-based and computer tomography (CT)-based modalities can demonstrate the morphologic alterations of cirrhosis, but they are limited in evaluating patients with earlier stages of liver disease [5].

Advancements in magnetic resonance imaging (MRI), with its unique and intrinsic imaging features, have provided the opportunity to revolutionize how we image and evaluate patients with diffuse liver diseases. In addition, with the development of new antifibrotic therapeutic agents, MRI-based techniques may play a central role in monitoring treatment response and in the clinical management of patients with NAFLD [6, 7].

The recent technical developments in MRI hardware and software, including the use of three Tesla MR devices in daily routine work, have significantly improved the temporal and spatial resolutions, especially in the case of contrast-enhanced T1-weighted 3D sequences. The use of various liver-specific hepatobiliary contrast agents enables not only morphological characterization but also a functional assessment of all liver lesions and also characterization of diffuse parenchymal changes [8].

2. Liver biopsy: the available but imperfect gold standard

Currently, liver biopsy is the reference standard for the diagnosis and staging of liver fibrosis [4]. However, this procedure has several major limitations, including its invasive nature, risk for potential complications, poor patient acceptance, interobserver variability, and possible sampling errors [4, 9].

Liver biopsy captures only a tiny fraction of the liver (roughly 1/50.000), leading to sampling errors [10]. In an attempt to reduce sampling variability, it is recommended that liver biopsy specimens be at least 2.0 cm long and contain at least 11 portal triads. Biopsy specimens that do not meet these criteria are associated with a high risk of under staging (false negative) [11].

In contrast to fibrosis in chronic viral hepatitis, fibrosis in alcoholic hepatitis and in the adult form of NAFLD begins adjacent to the central veins. The fibrosis is laid down in a perisinusoidal manner, and the scar tissue surrounds individual hepatocytes. As the disease advances, perisinusoidal fibrosis accumulates adjacent to portal tracts, and the fibrotic tissue eventually coalesces into fibrous bridges connecting portal triads and central veins, ultimately culminating in cirrhosis [3]. As cirrhosis develops, the characteristic histologic features of fatty liver disease may be lost. The perisinusoidal may no longer be apparent, and other features (e.g., inflammatory cells, ballooned hepatocytes, and steatosis) may subside. Thus, cirrhosis due to fatty liver disease may be indistinguishable from cirrhosis due to viral hepatitis or other causes [12].

3. MRI-based methods for the noninvasive diagnosis of NAFLD

The search for the best diagnostic technique in terms of noninvasiveness and accuracy is still a major concern in recent research activity. In the recent literature, the role of several imaging diagnosis tools and specific contrast agents is reported in the evaluation of diffuse liver diseases such as steatosis, fibrosis, and cirrhosis.

The differentiation of prognostically relatively benign simple steatosis from potentially progressive NASH is a crucial issue [13, 14]. Moreover, NAFLD is a reversible condition, especially during the early onset of the disease; therefore diagnosing and correct staging of patients with NAFLD are essential in order to prevent the development of an irreversible advanced liver disease.

Routine biochemical laboratory tests and conventional imaging, including US, CT, and non-specific gadolinium-enhanced MRI, cannot distinguish between these entities with sufficient confidence [15, 16]. Therefore, the differentiation between both entities is routinely made by histopathological analysis after liver biopsy. Liver biopsy is still considered the reference standard for the diagnosis of NASH [4]. There are several histological scoring systems to grade NASH, and the most commonly used is the so-called NAFLD activity score (NAS) [17]. The steatosis activity and fibrosis score (SAF) are a newly developed system for categorizing liver histology in NAFLD patients [18]. The lack of reliable, noninvasive methods for the diagnosis of disease severity and prediction of prognosis is one of the major drawbacks in the clinical management of patients with NAFLD [19].

3.1 The diagnostic value of MR imaging techniques in assessing NAFLD

3.1.1 Magnetic resonance elastography

Magnetic resonance elastography (MRE) assesses viscoelastic properties of soft tissues [20], offering a direct insight into the liver parenchymal stiffness. First step in the MRE technique is generating mechanical waves in the liver tissue. Then gradient-echo sequences are used to image wave motion, while a specialized software utilizing inversion algorithms transforms the images obtained into elastograms, revealing the tissues' stiffness quantitative map, expressed in kilopascals [21].

Studies comparing healthy volunteers and patients with CLD established that the shear viscoelastic parameters of the liver increased according to the stage of liver fibrosis, and a statistically significant difference between the patients with Metavir scores F0–F1 fibrosis versus F2–F3, F2–F3 versus F4, and F0–F1 versus F4 was found [20, 22]. MRE also proved to be superior to biochemical testing using the aspartate aminotransferase-to-platelet ratio index [22]. Most importantly the authors could clearly separate the intermediate fibrosis stages, using MRE elasticity measurements.

Chen et al. [23] demonstrated that MRE-based assessments of liver stiffness in patients with NAFLD may have a high diagnostic accuracy (AUC 0.93) for discriminating NASH from simple steatosis, with a cutoff value of 2.74 kPa reaching 94% sensitivity and 73% specificity. However, a more recent study suggested that the performance of MRE for diagnosis of NASH versus simple steatosis was rather modest and did not provide a high level of accuracy. Using 2D-MRE (60 Hz), 3D-MRE (60 Hz), and 3D-MRE (40 Hz), the AUROC for diagnosing definite NASH was 0.754, 0.757, and 0.736, respectively [24].

In a prospective study, Cui et al. [25] proved that the diagnostic accuracy of 2D-MRE for the noninvasive evaluation of advanced fibrosis in patients with biopsy-proven NAFLD was significantly higher than five clinical prediction rules, widely validated for the assessment of fibrosis in patients with NAFLD, such as the NAFLD fibrosis score, the BARD score, the AST-to-ALT ratio, FIB-4, and AST-to-platelet ratio index. Using the cutoff value for 2D-MRE of 3.64 kPa, the AUROC of 2D-MRE for predicting advanced fibrosis was 0.957. This proved to be significantly higher than FIB-4 score with AUROC of 0.861, the best-of-all analyzed clinical prediction rules. Therefore, 2D-MRE is a promising noninvasive imaging-based biomarker for the diagnosis of advanced fibrosis in NAFLD patients used additionally to clinical prediction rules, especially when the latter have indeterminate values.

The cutoff values proposed by Loomba et al. [26] for the prediction of each fibrosis stage using 2D-SWE in patients with NAFLD were 3.02 kPa for early fibrosis, 3.58 kPa for significant fibrosis, 3.64 kPa for advanced fibrosis, and 4.67 kPa for the prediction of cirrhosis, with areas under the ROC curve of 0.838,

0.856, 0.924, and 0.894, respectively. The most promising results were obtained for discriminating advanced fibrosis (F3–F4) from fibrosis stages 0–2 with a sensitivity of 0.86 (95% confidence interval [CI]: 0.65–0.97) and a specificity of 0.91 (95% CI, 0.83–0.96).

Kim et al. showed, however, that the best cutoff for detecting advanced fibrosis value was 4.15 kPa (AUROC = 0.954, sensitivity = 85%, specificity = 92%). The performance of this technique for discriminating between other fibrosis stages was also satisfactory [27].

Nevertheless, this ability to stage pre-cirrhotic disease could make MRE very useful for the assessment of therapeutic success and disease progression [28].

More advanced versions of the imaging modality such as 3D-MRE allow the evaluation of a larger volume of liver parenchyma than 2D-MRE, being significantly more accurate for diagnosis of advanced fibrosis in NAFLD patients [24].

As it is not affected by the absence of an ultrasound window, MRE is more precise than ultrasonographic elastographic techniques. In patients with obesity to morbid obesity, MRE proved to have a better success rate than vibrant-controlled transient elastography (95.8 versus 81.3%) and a higher interobserver agreement than liver biopsy (intraclass correlation coefficient, 0.95 versus 0.89) [29].

Acute inflammation, passive liver congestion caused by cardiac insufficiency, or obstructive cholestasis leads to a false increase of liver stiffness values [30]. Moreover, on a gradient-echo MRE sequence, certain conditions such as iron overload states may lead to a lower MRI signal intensity, which does not allow shear wave recognition. This leads to a decrease in MRE diagnostic accuracy. Thus, using spin-echo or echo-planar sequences with lower T2* effect susceptibility can alleviate this problem [30].

The technique has the advantage of not being influenced by the patient's weight or the presence of ascites. MRE remains expensive and not widely accessible in the everyday imaging routine of patients with NAFLD.

3.1.2 Magnetic resonance spectroscopy

MR spectroscopy (MRS) enables the noninvasive measurement of concentrations of different chemical components within tissues, which are displayed as a 1D spectrum with peaks consistent with the various chemicals detected. The major problem in obtaining MRS signals from abdominal organs is sensitivity to physiologic movement during the scan time usually exceeding several minutes [31]. Usually, the measurement is performed by manually placing a single voxel into the liver parenchyma far from the liver capsule, in an area free of large vessels or bile ducts [32].

While proton MRS is a very useful technique for the quantification of hepatic fat, its use for the estimation of hepatic fibrosis appears to be limited [33, 34].

According to Abrigo et al. [34], phosphorus-MRS (31P-MRS) shows distinct biochemical changes in different NAFLD states and has fair diagnostic accuracy for NASH. However, this technique requires considerable operator skills (sequence programming, shimming, analysis of spectra) and access to special equipment (scanner, 31P coil) [28].

31P-MRS permits in vivo evaluation of energy metabolism and intracellular compartment division through different signals and provides metabolic information, which is useful when assessing fibrogenesis [28]. A significant correlation between phosphodiester concentration and the stage of fibrosis and a correlation between “anabolic charge” (phosphomonoester/[phosphomonoester + phosphodiester]) and the stage of fibrosis were found in a study comparing a group of patients

with steatosis and no to moderate inflammation to a group of patients with severe fibrosis or cirrhosis [35].

Hydrogen 1 MRS (1H-MRS) has proven its efficiency in quantifying liver steatosis, by measuring lipid peaks, identified in the liver at 0.9, 1.3, 2.0, 2.2, and 5.3 parts per million. The dominant lipid peaks are caused by the resonance of methyl (-CH₃) protons and methylene (-CH₂) in the triglyceride molecule [36].

The absolute fat concentration can be therefore calculated using the following formula:

$$\text{Triglyceride content} = \frac{\text{total lipid peak area}}{(\text{total lipid resonance peak} + \text{water resonance peak})} \quad (1)$$

As the steatosis grade increases, the size of the lipid peaks relative to the water peak increases as well [36].

The advantages of ¹H-MRS are the very high sensitivity, a good correlation with histological analysis, and the method's independency of confounders such as fibrosis and iron or glycogen depositions. On the other side, MRS has currently a limited clinical availability, and it is prone to sampling error, when a single-voxel liver spectroscopy is performed [36].

Furthermore, authors assessed the diagnostic accuracy of a novel magnetic resonance protocol for liver tissue characterization, using T1 mapping, 1H spectroscopy, and T2* mapping, which quantified liver fibrosis, steatosis, and hemosiderosis, respectively [37]. According to their results, the novel scanning method provides high diagnostic accuracy for the assessment of all three histology variables.

In a recent study, Idilman et al. [38] analyzed the efficiency of MRI-proton density fat fraction (MRI-PDFF) and MRS-determined liver fat content in patients with NAFLD in comparison with liver biopsy-determined steatosis.

No superiority between the two imaging methods was observed. This study emphasized that the estimation of fat liver content using both MR imaging techniques was more accurate in the absence of liver fibrosis. MRS showed promising results for discriminating moderate/severe steatosis from none/mild steatosis with an AUROC of 0.857. A cutoff value of 9% provided a sensitivity of 92%, negative predictive value of 83.3%, specificity of 71%, and positive predictive value of 84.6%.

The accurate assessment of liver fat content in patients with NAFLD is essential in identifying those who are at greater risk of progressing into advanced fibrosis stages, being also of great value in evaluating the response to therapy. Liver steatosis also influences the successful rate of liver transplantation (LT); one of the necessary requirements in many centers is that the living donor liver must not exceed 5% steatosis, as greater values are associated with increased recipient liver dysfunction [38].

MRS proves to be a highly accurate noninvasive technique, which allows us to distinguish between individuals with simple steatosis and steatohepatitis who may benefit from early intervention and more aggressive therapy.

3.1.3 Diffusion-weighted MR imaging

Diffusion-weighted imaging (DWI) is a noninvasive method that allows measurement of the microscopic motion of water in tissue and generates representative apparent diffusion coefficient (ADC) values. DWI uses very fast scans with an additional series of (diffusion) gradients rapidly turned on and off [28].

Within tissues with highly cellular component and therefore a narrowed extracellular space, the water molecule motion is impeded leading to restricted water diffusion in such tissues. In contrast, fluid-rich or necrotic structures are associated

with a greater freedom of motion of water molecules, and the water diffusion in such tissues is considered to be “free.” Therefore, on DWI sequences, the signal intensity reflects the tissue diffusion characteristics, which is influenced by cellular-ity and the integrity of cell membranes [39].

In a prospective study, Guiu et al. [40] demonstrated that both pure molecular diffusion and perfusion-related diffusion were significantly lower in the steatotic liver than in the normal liver. On a group of 89 NAFLD patients who underwent liver biopsy, Murphy et al. [41] also found a good correlation between histologic features of NAFLD liver and DWI-derived quantitative measures. Molecular diffusivity was significantly decreased with steatosis, while perfusion fraction decreased with fibrosis degree. Same associations were found between pediatric NAFLD histologic features and DWI parameters, with a high interobserver reproducibility [42]. As far as the apparent diffusion coefficient is concerned, studies show inconsistent results. One study in adults with NAFLD found that ADC decreased with steatosis, while others found no significant relationship [40, 41].

Several studies have evaluated the use of DWI and ADC values for the diagnosis of hepatic fibrosis or cirrhosis in patients with diffuse hepatopathies. The complex assembly of collagen fibers, glycosaminoglycan, and proteoglycans that constitutes liver fibrosis may restrict the molecular diffusion measured by DWI [43].

DWI has been successfully applied to differentiate cirrhotic from healthy tissue. Girometti et al. reported a positive predictive value of 100%, a negative predictive value of 99.9%, and an overall accuracy of 96.4% in cirrhotic patients compared to healthy controls [44].

A recent meta-analysis suggests that DWI parameters can reliably stage hepatic fibrosis, having a good diagnostic accuracy with areas under the SROC curve between 80 and 90%. A high b value for liver fibrosis imaging (between 800 and 1000 s/mm²) could significantly increase the diagnostic accuracy of diffusion imaging in differentiating between significant and severe fibroses (>F2). For diagnosing liver cirrhosis (F4), the use of 3T MRI equipment has also proved to optimize the DWI diagnostic accuracy, compared to 2T MRI [45].

Lewin et al. found a significant relationship between the ADC values and necro-inflammatory scores and suspected an influence of steatosis on apparent diffusion coefficient values [46]. In addition, the ADC of fibrotic livers was decreased as the fibrosis scores increased in some studies [46], but not in others [43].

However, differences in MR equipment and sequence parameters make it difficult to compare studies. Clearly, more research is needed to create a standard setup for DWI sequence acquisition to make studies comparable and to determine whether or not DWI can be a useful tool for the diagnosis and staging of diffuse liver diseases.

Furthermore, DWI imaging is susceptible to artifacts (e.g., blurring, ghosting, and distortions) and offers a limited image quality; therefore, DWI is currently used as complementary and not as a replacement to conventional sequences in the evaluation of NAFLD [47].

DWI does not require administration of intravenous contrast; consequently the technique might represent a reasonable option for patients with kidney failure, where gadolinium-based contrast substances represent a contraindication due to the increased risk of developing nephrogenic systemic fibrosis, while iodinated CT contrast might lead to an even greater impairment of renal function, being also contraindicated [47].

3.1.4 Susceptibility-weighted MR imaging

It is known that, among other factors, increased iron content of the liver and secondary changes manifesting in progressive collagen deposition are important background alterations in the development of liver fibrosis [48].

Susceptibility-weighted imaging (SWI) is well known as a three-dimensional (3D) gradient-echo (GRE) technique utilizing phase information to increase sensitivity for detecting susceptibility changes that result from, for example, iron, hemoglobin, and calcification. Initially used for neuroimaging [49, 50], recent technical advances allow for possible abdominal applications.

SWI is based on T2*-weighted GRE sequences and exploits both magnitude and phase information. Traditionally SWI sequences are high-resolution 3D sequences. Employing 3D sequences for abdominal imaging is not feasible because of long acquisition times and the large B0 variations encountered in this body area. With the advent of a multi-breath-hold GRE-sequence-based SWI, a two-dimensional (2D) sequence was developed for abdominal imaging [51]. SWI utilizes the differences in the magnetic susceptibilities of different tissues and produces a contrast superior to conventional T1- and T2-weighted MR imaging in the detection of structures that cause susceptibility artifacts [52].

The superiority of SWI over the T2*-weighted sequence has been shown, both in the detection and conspicuity of increased liver iron deposition and siderotic nodules [51] and in the detection of intratumoral hemorrhage in hepatocellular carcinoma (HCC) [53].

The liver-to-muscle signal intensity ratio on SWI proved to be a reliable measurement in grading liver fibrosis in patient with diffuse liver disease, with a high-diagnostic accuracy for the differentiation of moderate to advanced (F2 and F3) liver fibrosis from liver cirrhosis (F4) (AUROC = 0.93). The multiple regression analysis showed that liver fibrosis independently influenced SWI measurements, being a main contributor to the decreasing liver-to-muscle SI ratio, followed by iron overload and necroinflammatory activity, when compared with histopathologic findings [52].

The relationship between iron load and fibrogenesis has multiple considerations. The increased iron content in the liver, either diffusely distributed or in the form of numerous siderotic nodules, does not represent the entire transformation of liver fibrosis. In the process of fibrogenesis, hepatic stellate cells are also activated by other factors such as inflammation, genetic determinants, and the immune system [52].

Using a multiparametric approach, a recent study proved that liver SWI signal intensity enhanced the diagnostic performance in diagnosing and staging liver fibrosis, when used together with the apparent diffusion coefficient of the liver parenchyma on DWI and the degree of liver enhancement on the hepatobiliary phase of dynamic contrast-enhanced MRI. The three MRI techniques used together were able to assess the severity of liver fibrosis with an AUC ranging from 0.90 to 0.95, and the best performance was obtained in predicting moderate fibrosis (F2 or greater), with a sensitivity of 86% and a specificity of 94%. This reflects the clinical significance of this diagnostic tool, as F2 or greater is the stage in which therapeutic action should be taken [54].

3.1.5 Proton density fat fraction

Proton density fat fraction (PDFF) measurement is a multi-echo chemical shift-encoded MRI method for quantitatively assessing hepatic steatosis, being available as an option from several manufacturers of MRI scanners. PDFF is defined as the ratio of the density of mobile protons from triglycerides and the total density of protons from mobile triglycerides and mobile water. It is expressed as an absolute percentage (%) and ranges from 0 to 100% [7].

This sequence allows the measurement of fat fraction in any segment of the liver, generating a fat mapping of the entire hepatic parenchyma. This is of great value, as several studies proved the heterogeneous intrahepatic fat distribution [55].

The advantages of PDFF calculation are its ability to be completely obtained during a short breath-hold (in less than 25 s) and the fact that it minimizes the errors from confounders of fat quantification encountered using conventional MRI methods (Dixon and fat saturation) such as T1 bias, T2* decay, or spectral complexity of lipid [38].

Emerging data support the use of MRI-PDFF in evaluating the response to treatment in the setting of early-phase clinical trials in NASH, using drugs with an anti-steatotic mechanism of action [7].

In a recent study, the mean fat fraction was significantly lower in the left lobe than it was in the right, while liver segments 4 and 5 proved to be the most adequate to estimate the entire hepatic lipid content [55].

Regarding technical parameters, using a six-echo map proved to have a higher diagnostic accuracy than three, four, or five echoes [56].

Permutt et al. showed a good correlation between MRI-PDFF and histology-determined steatosis grade in adults with NAFLD. They observed an increasing average value of MRI-determined PDFF with increasing steatosis grade (8.9% for grade 1, 16.3% for grade 2, and 25% for grade 3 steatoses) [57]. PDFF was effective in differentiating moderate or severe hepatic steatosis from mild or no hepatic steatosis, with area under the curve of 0.95 and 93% sensitivity and 85% specificity. However, the correlation between biopsy and PDFF-determined steatosis was less pronounced when fibrosis was present ($r = 0.60$) than when fibrosis was absent [58].

When comparing the efficiency of MRI-PDFF to magnetic resonance spectroscopy, both techniques proved to strongly correlate with the histology-determined steatosis, with no superiority between them [38]. But the PDFF maps have the advantage of being automatically reconstructed without user input or post-processing, unlike MR spectroscopy-based methods.

Therefore, MR-PDFF represents another novel, noninvasive, and practical imaging tool in assessing patients with NAFLD, as the entire liver can be covered in assessment with a great accuracy in quantifying total hepatic fat amount [38, 55].

3.1.6 Contrast-enhanced MRI

In the liver, contrast agents are categorized into non-specific agents that distribute into the vascular and extravascular extracellular spaces (such as the linear gadopentetate dimeglumine (Gd-DTPA) and the macrocyclic gadobutrol (Gd-DO3A-butrol) and gadoterate dimeglumine (Gd-DOTA)) and liver-specific agents taken up by liver cells. These liver-specific agents are either taken up by Kupffer cells (such as the super paramagnetic iron oxide particles ferumoxides and ferucarbotran) or by hepatocytes (such as gadolinium ethoxybenzyl dimeglumine or gadoxetic acid (Gd-EOB-DTPA) and gadobenate dimeglumine (Gd-BOPTA)) [8].

3.1.6.1 Hepato-specific contrast-enhanced MRI

Gadoxetic acid (Gd-EOB-DTPA, Eovist® in the USA, Primovist® in Europe) is a liver-specific MRI contrast agent which provides both morphological and functional information and can be used as an imaging biomarker in the diagnostic workup of liver fibrosis [8].

After intravenous injection, the gadoxetic acid (GA) distributes into the vascular and extravascular spaces during the arterial, portal venous, and late dynamic phases and progressively into the hepatocytes and bile ducts during the hepatobiliary phase. GA enhancement depends mainly on liver perfusion, vascular permeability, extracellular diffusion, and hepatocyte transporter expression [8, 59].

All these functions are disturbed in diffuse liver diseases, and there may be a decrease in the balance between uptake and excretion of the contrast media by the impaired hepatocytes.

The transport of GA in the hepatocytes is mediated by two different transport systems located at the sinusoidal and canalicular membranes of the cell [60]. The contrast agent enters the hepatocytes through two organic anion-transporting polypeptide transporters (OATP1B1 and OATP1B3) [61], and it is excreted into the bile via the multidrug resistance protein 2 (MRP2) [62].

In patients with liver cirrhosis, the upregulation of MRP2 is associated with significant signal loss on gadoxetic acid-enhanced MR images [63]. Organic acid efflux from hepatocytes may also occur through the sinusoidal membrane because the transport through OATP is bidirectional and because the sinusoidal membrane also contains multidrug resistance proteins (MRP3 and MRP4), as it is illustrated in **Figure 1**. These efflux pumps are normally expressed at low levels in normal hepatocytes but can be upregulated in pathologic conditions, such as cholestasis. GA is not metabolized within hepatocytes [64].

With GA, approximately 50% of the administered dose in the normal human liver is transported through the hepatocytes and excreted into the bile, and the percentage of the contrast agent that is not cleared by the hepatobiliary system is excreted by glomerular filtration in the kidneys [65].

Hepatobiliary MR contrast agents can be used to characterize liver functional properties, and the relative enhancement quantification is a reflection of hepatocyte malfunction as a result of liver fibrosis accumulation and increased necroinflammatory activity [66].

Several MR-derived parameters can be used to estimate the amount of GA uptake, such as the relative liver enhancement, hepatic uptake index, and T1 mapping during hepatobiliary phase—on static images or the hepatic extraction fraction and liver blood flow—by using dynamic assessment [67]. Importantly, there is currently no clear consensus as to which of these MR-derived parameters is the most suitable for assessing liver dysfunction.

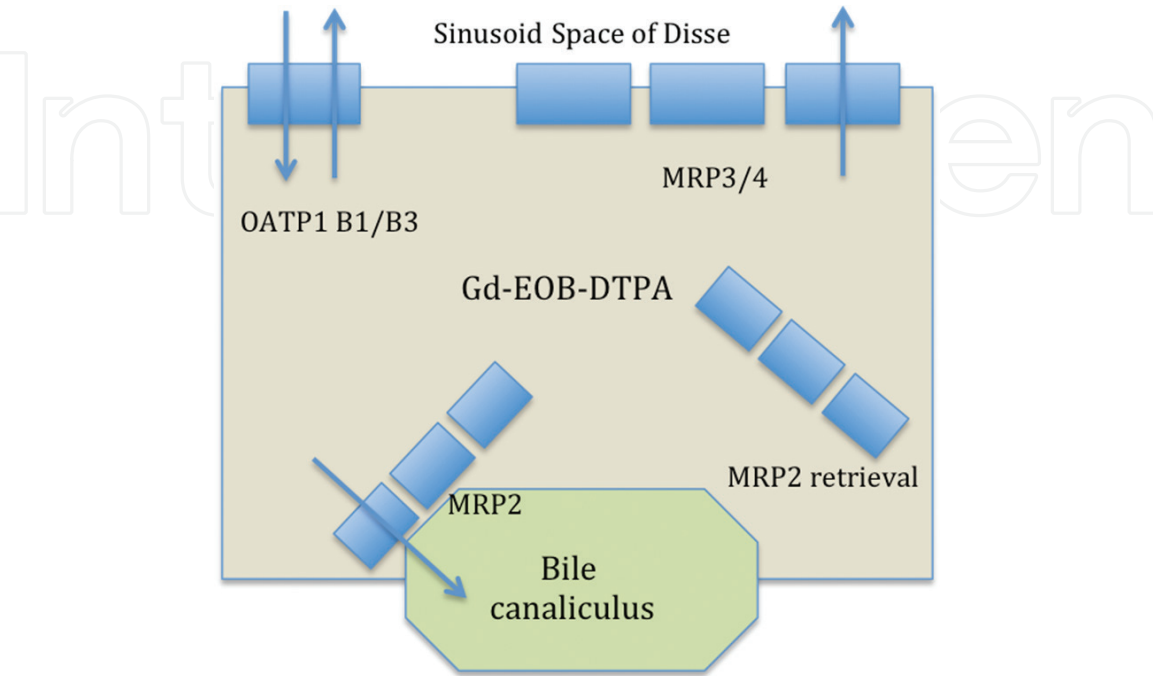


Figure 1.
Cellular pharmacology of Gd-EOB-DTPA—figure adapted after Van Beers et al. [8].

The relative liver enhancement (RLE), the most commonly used parameter, is calculated by subtracting the signal intensity (SI) on the unenhanced images from the SI in the HBP, and dividing the difference by the SI of the unenhanced images, using the following formula [67]:

Relative enhancement (RE) = (SI 20 minutes post – contrast – SI pre – contrast)/SI pre – contrast (2)

In order to avoid bias due to liver parenchyma inhomogeneity, several regions of interest (ROI) are placed in different segments of both liver lobes.

Indeed, reports on animal models also proved that gadoxetic acid-enhanced MRI could differentiate simple steatosis from NASH by comparing the signal profile or the time of maximum relative enhancement [68]. Furthermore, several recent

| Imaging technique | Advantages | Disadvantages |
|-----------------------------|------------------------------------------------------------------------------------------------------------------------------------------------------------------------------------------------------------------------------------------|-------------------------------------------------------------------------------------------------------------------------------------------------------------------------------------------------------------------------------------------------------------------------|
| MRE | <ul style="list-style-type: none">• Excellent diagnostic accuracy for staging liver fibrosis and cirrhosis• Uninfluenced by obesity or ascites | <ul style="list-style-type: none">• Increased failure rate in iron overload states• Not widely available |
| MRS | <ul style="list-style-type: none">• Excellent sensitivity for detecting mild steatosis• Good correlation with histological analysis• Independent of confounders (e.g., fibrosis, iron, glycogen) | <ul style="list-style-type: none">• Requires specialized post-processing data, expensive• Sensitive to field inhomogeneity• Technical limitations: low signal-to-noise ratio, motion• Evaluation of small portion of the liver |
| DWI | <ul style="list-style-type: none">• Functional information in the absence of intravenous contrast• Successfully applied to differentiate cirrhotic from healthy tissue | <ul style="list-style-type: none">• Limited image quality• Susceptible to artifacts (e.g., blurring, ghosting, and distortions)• Needs further research |
| SWI | <ul style="list-style-type: none">• Iron overload quantification• Enhances the diagnostic performance of other MRI techniques in diagnosing liver fibrosis | <ul style="list-style-type: none">• Susceptibility artifacts |
| PDFF | <ul style="list-style-type: none">• The most accurate and precise imaging biomarker to quantify liver steatosis• Not influenced by iron overload• Short acquisition time• Volumetric assessment | <ul style="list-style-type: none">• Accuracy could be affected by fibrosis, severe steatosis |
| Liver-specific contrast MRI | <ul style="list-style-type: none">• Allows evaluation of both liver morphology and function• High sensitivity in differentiating between simple steatosis and NASH | <ul style="list-style-type: none">• Low specificity in differentiating between simple steatosis and NASH• Confounders: increased liver function parameters |

MRE, magnetic resonance elastography; MRS, magnetic resonance spectroscopy; DWI, diffusion-weighted MR imaging; SWI, susceptibility-weighted MR imaging; PDFF, proton density fat fraction.

Table 1.
Summary of main advantages and disadvantages of different MRI techniques in evaluating patients with NAFLD.

studies have shown the ability of gadoxetic acid-enhanced MRI to evaluate patients with CLD, particularly for the staging of hepatic fibrosis, and to obtain global and territorial liver function information [69].

In a retrospective, proof-of-concept study, the mean relative enhancement of the whole liver after GA administration was significantly lower in patients with NASH (0.82 ± 0.22), compared to those with simple steatosis (1.39 ± 0.52) [70]. Therefore, the relative enhancement measurements could potentially be used to differentiate between simple steatosis and NASH [AUC = 0.85 (95% CI 0.75–0.91)], providing a high sensitivity of 97% but a low specificity of 63% [70].

Histology parameters used to stage NASH, such as lobular inflammation, hepatocellular ballooning, and the degree of liver fibrosis, proved to be independent factors that negatively correlated with RLE. On the other side, fatty liver infiltration did not correlate with the relative enhancement. Due to its low specificity, GA-MRI cannot be used at this moment as the only criterion by which to differentiate simple steatosis and NASH. However, GA-MRI can be used as a valuable screening tool in identifying which NAFLD patients need to perform liver biopsy and which do not [70].

With regard to liver fibrosis staging, the contrast enhancement index (method that uses the paraspinal muscles' signal intensity as a reference for liver) proved to be an efficient biomarker, with higher diagnostic accuracy than other enhancement parameters or hematologic markers [71]. RLE is best suited for detecting moderate to advanced fibrosis, but the interpretation of results should consider laboratory parameters, with special attention to liver function. Elevated levels of aspartate aminotransferase, gammaglutamyl transpeptidase, and alkaline phosphatase levels were independent predictors of false-negative results [69].

The main advantages and disadvantages of each magnetic resonance imaging technique currently used in the noninvasive assessment of NAFLD are briefly synthesized in **Table 1**.

4. Conclusion

MRI is currently increasingly used in the assessment of NAFLD. Although all methods have their own advantages and disadvantages, the noninvasive diagnosis of NAFLD using innovative applications of MRI-based methods presents a promising future. Liver fibrosis can be accurately assessed using MRI methods that do not require contrast media administration, such as MRE, diffusion-weighted MRI, and susceptibility-weighted MRI, while quantitative detection of liver steatosis is better performed using MRS or chemical shift-based MRI techniques such as proton density fat fraction. Moreover, GA-enhanced MRI provides both morphological and functional information and can be used as an imaging biomarker in the diagnostic workup of liver fibrosis and may help to distinguish between the two subgroups of NAFLD, simple steatosis and nonalcoholic steatohepatitis.

List of abbreviations

| | |
|-----|--------------------------------|
| ADC | Apparent diffusion coefficient |
| CLD | Chronic liver disease |
| CT | Computer tomography |
| DWI | Diffusion-weighted imaging |
| GA | Gadoxetic acid |
| GRE | Gradient echo |
| LT | Liver transplantation |

| | |
|-------|----------------------------------|
| MRE | Magnetic resonance elastography |
| PDFF | Proton density fat fraction |
| MRI | Magnetic resonance imaging |
| MRP2 | Multidrug resistance protein 2 |
| MRS | Magnetic resonance spectroscopy |
| NAFLD | Nonalcoholic fatty liver disease |
| NASH | Nonalcoholic steatohepatitis |
| RLE | Relative liver enhancement |
| ROI | Region of interest |
| SI | Signal intensity |
| SWI | Susceptibility-weighted imaging |
| US | Ultrasonography |

Conflict of interest

There is none to declare.

Author details

Diana Feier^{1*}, Delia Muntean², Nina Bastati³ and Ahmed Ba-Ssalamah³

1 Department of Radiology, Medical University of Cluj-Napoca, Cluj-Napoca, Romania

2 Department of Radiology, “Leon Daniello” Pneumology Clinical Hospital, Cluj-Napoca, Romania

3 Department of Biomedical Imaging and Image-guided Therapy, Medical University of Vienna, Austria

*Address all correspondence to: diana.feier@gmail.com

IntechOpen

© 2019 The Author(s). Licensee IntechOpen. This chapter is distributed under the terms of the Creative Commons Attribution License (<http://creativecommons.org/licenses/by/3.0>), which permits unrestricted use, distribution, and reproduction in any medium, provided the original work is properly cited. 

References

- [1] Adams LA, Lindor KD. Nonalcoholic fatty liver disease. *Annals of Epidemiology*. 2007;**17**(11):863-869
- [2] Younossi ZM, Koenig AB, Abdelatif D, Fazel Y, Henry L, Wymer M. Global epidemiology of nonalcoholic fatty liver disease-meta-analytic assessment of prevalence, incidence, and outcomes. *Hepatology*. 2016;**64**(1):73-84
- [3] Yeh MM, Brunt EM. Pathology of nonalcoholic fatty liver disease. *American Journal of Clinical Pathology*. 2007;**128**(5):837-847
- [4] Bravo AA, Sheth SG, Chopra S. Liver biopsy. *New England Journal of Medicine*. 2001;**344**(7):495-500
- [5] van Werven JR, Marsman HA, Nederveen AJ, Smits NJ, ten Kate FJ, van Gulik TM, et al. Assessment of hepatic steatosis in patients undergoing liver resection: Comparison of US, CT, T1-weighted dual-echo MR imaging, and point-resolved 1H MR spectroscopy. *Radiology*. 2010;**256**:159-168
- [6] Hardy T, McPherson S. Imaging-based assessment of steatosis, inflammation and fibrosis in NAFLD. *Current Hepatology Reports*. 2017;**16**:298-307
- [7] Caussy C, Reeder SB, Sirlin CB, Loomba R. Non-invasive, quantitative assessment of liver fat by MRI-PDFF as an endpoint in NASH trials. *Hepatology*. 2018;**68**(2):763-772
- [8] Van Beers BE, Pastor CM, Hussain HK. Primovist, eovist: What to expect? *Journal of Hepatology*. 2012;**57**(2):421-429
- [9] Cadranel JF, Rufat P, Degos F. Practices of liver biopsy in France: Results of a prospective nationwide survey. For the Group of Epidemiology of the French Association for the Study of the Liver (AFEFL). *Hepatology*. 2000;**32**(3):477-481
- [10] Regev A, Berho M, Jeffers LJ, Milikowski C, Molina EG, Pyrsopoulos NT, et al. Sampling error and intraobserver variation in liver biopsy in patients with chronic HCV infection. *The American Journal of Gastroenterology*. 2002;**97**(10):2614-2618
- [11] Colloredo G, Guido M, Sonzogni A, Leandro G. Impact of liver biopsy size on histological evaluation of chronic viral hepatitis: The smaller the sample, the milder the disease. *Journal of Hepatology*. 2003;**39**(2):239-244
- [12] Faria SC, Ganesan K, Mwangi I, Shieh Morteza M, Viamonte B, Mazhar S, et al. MR imaging of liver fibrosis: Current state of the art. *Radiographics*. 2009;**29**(6):1615-1635. A review publication of the Radiological Society of North America, Inc
- [13] Nascimbeni F, Pais R, Bellentani S, Day CP, Ratzliff V, Loria P, et al. From NAFLD in clinical practice to answers from guidelines. *Journal of Hepatology*. 2013;**59**(4):859-871
- [14] Reid AE. Nonalcoholic steatohepatitis. *Gastroenterology*. 2001;**121**(3):710-723
- [15] Lall CG, Aisen AM, Bansal N, Sandrasegaran K. Nonalcoholic fatty liver disease. *American Journal of Roentgenology*. 2008;**190**(4):993-1002
- [16] Afdhal NH, Curry M. Technology evaluation: A critical step in the clinical utilization of novel diagnostic tests for liver fibrosis. *Journal of Hepatology*. 2007;**46**(4):543-545
- [17] Brunt EM, Kleiner DE, Wilson LA, Belt P, Neuschwander-Tetri BA. Nonalcoholic fatty liver disease

(NAFLD) activity score and the histopathologic diagnosis in NAFLD: Distinct clinicopathologic meanings. *Hepatology*. 2011;**53**(3):810-820

[18] Bedossa P, Poitou C, Veyrie N, Bouillot JL, Basdevant A, Paradis V, et al. Histopathological algorithm and scoring system for evaluation of liver lesions in morbidly obese patients. *Hepatology*. 2012;**56**(5):1751-1759

[19] Dowman JK, Tomlinson JW, Newsome PN. Systematic review: The diagnosis and staging of non-alcoholic fatty liver disease and non-alcoholic steatohepatitis. *Alimentary Pharmacology & Therapeutics*. 2011;**33**(5):525-540

[20] Wang Y, Ganger DR, Levitsky J, Sternick LA, McCarthy RJ, Chen ZE, et al. Assessment of chronic hepatitis and fibrosis: Comparison of MR elastography and diffusion-weighted imaging. *American Journal of Roentgenology*. 2011;**196**(3):553-561

[21] Venkatesh SK, Yin M, Ehman RL. Magnetic resonance elastography of liver: Technique, analysis, and clinical applications. *Journal of Magnetic Resonance Imaging*. 2013;**37**:544-555

[22] Huwart L, Sempoux C, Salameh N, Jamart J, Annet L, Sinkus R, et al. Liver fibrosis: Noninvasive assessment with MR elastography versus aspartate aminotransferase-to-platelet ratio index. *Radiology*. 2007;**245**(2):458-466

[23] Chen J, Talwalkar JA, Yin M, Glaser KJ, Sanderson SO, Ehman RL. Early detection of nonalcoholic steatohepatitis in patients with nonalcoholic fatty liver disease by using MR elastography. *Radiology*. 2011;**259**(3):749-756

[24] Loomba R, Cui J, Wolfson T, Haufe W, Hooker J, Szeverenyi N, et al. Novel 3D magnetic resonance elastography for the noninvasive diagnosis of advanced

fibrosis in NAFLD: A prospective study. *The American Journal of Gastroenterology*. 2016;**111**(7):986-994

[25] Cui J, Ang B, Haufe W, Hernandez C, Verna EC, Sirlin CB, et al. Comparative diagnostic accuracy of magnetic resonance elastography vs. eight clinical prediction rules for non-invasive diagnosis of advanced fibrosis in biopsy-proven nonalcoholic fatty liver disease: A prospective study. *Alimentary Pharmacology & Therapeutics*. 2015;**41**:1271-1280

[26] Loomba R, Wolfson T, Ang B, Hooker J, Behling C, Peterson M, et al. Magnetic resonance elastography predicts advanced fibrosis in patients with nonalcoholic fatty liver disease: A prospective study. *Hepatology*. 2014;**60**(6):1920-1928

[27] Kim D, Kim WR, Talwalkar JA, Kim HJ, Ehman RL. Advanced fibrosis in nonalcoholic fatty liver disease: Noninvasive assessment with MR elastography. *Radiology*. 2013;**268**(2):411-419

[28] Bonekamp S, Kamel I, Solga S, Clark J. Can imaging modalities diagnose and stage hepatic fibrosis and cirrhosis accurately? *Journal of Hepatology*. 2009;**50**(1):17-35

[29] Chen J, Yin M, Talwalkar JA, Oudry J, Glaser KJ, Smyrk TC, et al. Assessment of diagnostic performance of MR elastography (MRE) and vibration-controlled transient elastography (VCTE) for detecting hepatic fibrosis in patients with severe to morbid obesity. *Radiology*. 2017;**283**:418-428

[30] Low G, Kruse SA, Lomas DJ. General review of magnetic resonance elastography. *World Journal of Radiology*. 2016;**8**:59-72

[31] Irwan R, Sijens PE, Potze JH, Oudkerk M. Correlation of proton

MR spectroscopy and diffusion tensor imaging. *Magnetic Resonance Imaging*. 2005;**23**(8):851-858

[32] Karlas T, Petroff D, Garnov N, Böhm S, Tenckhoff H, Wittekind C, et al. Non-invasive assessment of hepatic steatosis in patients with NAFLD using controlled attenuation parameter and 1H-MR spectroscopy. *PLoS One*. 2014;**9**(3):e91987

[33] Cho SG, Kim MY, Kim HJ, Kim YS, Choi W, Shin SH, et al. Chronic hepatitis: In vivo proton MR spectroscopic evaluation of the liver and correlation with histopathologic findings. *Radiology*. 2001;**221**(3):740-746

[34] Abrigo JM, Shen J, Wong VW, Yeung DK, Wong GL, Chim AM, et al. Non-alcoholic fatty liver disease: Spectral patterns observed from an in vivo phosphorus magnetic resonance spectroscopy study. *Journal of Hepatology*. 2014;**60**(4):809-815

[35] Noren B, Lundberg P, Ressner M, Wirell S, Almer S, Smedby O. Absolute quantification of human liver metabolite concentrations by localized in vivo 31P NMR spectroscopy in diffuse liver disease. *European Radiology*. 2005;**15**(1):148-157

[36] Qayyum A. MR spectroscopy of the liver: Principles and clinical applications. *Radiographics*. 2009;**29**(6):1653-1664

[37] Banerjee R, Pavlides M, Tunnicliffe EM, Piechnik SK, Sarania N, Philips R, et al. Multiparametric magnetic resonance for the non-invasive diagnosis of liver disease. *Journal of Hepatology*. 2014;**60**(1):69-77

[38] Idilman IS, Keskin O, Celik A, Savas B, Elhan AH, Idilman R, et al. A comparison of liver fat content as determined by magnetic resonance imaging-proton density fat fraction

and MRS versus liver histology in non-alcoholic fatty liver disease. *Acta Radiologica*. 2016;**57**:271-278

[39] Taouli B, Koh DM. Diffusion-weighted MR imaging of the liver. *Radiology*. 2010;**254**:47-66

[40] Guiu B, Petit JM, Capitan V, Aho S, Masson D, Lefevre PH, et al. Intravoxel incoherent motion diffusion-weighted imaging in nonalcoholic fatty liver disease: A 3.0-T MR study. *Radiology*. 2012;**265**:96-103

[41] Murphy P, Hooker J, Ang B, Wolfson T, Gamst A, Bydder M, et al. Associations between histologic features of nonalcoholic fatty liver disease (NAFLD) and quantitative diffusion-weighted MRI measurements in adults. *Journal of Magnetic Resonance Imaging*. 2015;**41**:1629-1638

[42] Manning P, Murphy P, Wang K, Hooker J, Wolfson T, Middleton MS, et al. Liver histology and diffusion-weighted MRI in children with nonalcoholic fatty liver disease: A MAGNET study. *Journal of Magnetic Resonance Imaging*. 2017;**46**(4):1149-1158

[43] Aube C, Racineux PX, Lebigot J, Oberti F, Croquet V, Argaud C, et al. Diagnosis and quantification of hepatic fibrosis with diffusion weighted MR imaging: Preliminary results. *Journal de Radiologie*. 2004;**85**(3):301-306

[44] Girometti R, Furlan A, Bazzocchi M, Soldano F, Isola M, Toniutto P, et al. Diffusion-weighted MRI in evaluating liver fibrosis: A feasibility study in cirrhotic patients. *La Radiologia Medica*. 2007;**112**(3):394-408

[45] Jiang H, Chen J, Gao R, Huang Z, Wu M, Song B. Liver fibrosis staging with diffusion-weighted imaging: A systematic review and meta-analysis. *Abdominal Radiology*. 2017;**42**:490-501

- [46] Lewin M, Poujol-Robert A, Boelle PY, Wendum D, Lasnier E, Viallon M, et al. Diffusion-weighted magnetic resonance imaging for the assessment of fibrosis in chronic hepatitis C. *Hepatology*. 2007;**46**(3):658-665
- [47] Shenoy-Bhangle A, Baliyan V, Kordbacheh H, Guimaraes AR, Kambadakone A. Diffusion weighted magnetic resonance imaging of liver: Principles, clinical applications and recent updates. *World Journal of Hepatology*. 2017;**9**(26):1081-1091
- [48] Schmeltzer PA, Talwalkar JA. Noninvasive tools to assess hepatic fibrosis: Ready for prime time? *Gastroenterology Clinics of North America*. 2011;**40**(3):507-521
- [49] Haacke EM, Mittal S, Wu Z, Neelavalli J, Cheng YC. Susceptibility-weighted imaging: Technical aspects and clinical applications, part 1. *American Journal of Neuroradiology*. 2009;**30**(1):19-30
- [50] Mittal S, Wu Z, Neelavalli J, Haacke EM. Susceptibility-weighted imaging: Technical aspects and clinical applications, part 2. *American Journal of Neuroradiology*. 2009;**30**(2):232-252
- [51] Chen W, DelProposto Z, Wu D, Wang J, Jiang Q, Xuan S, et al. Improved siderotic nodule detection in cirrhosis with susceptibility-weighted magnetic resonance imaging: A prospective study. *PLoS One*. 2012;**7**(5):e36454
- [52] Balassy C, Feier D, Peck-Radosavljevic M, Wrba F, Witoszynskyj S, Kiefer B, et al. Susceptibility-weighted MR imaging in the grading of liver fibrosis: A feasibility study. *Radiology*. 2014;**270**(1):149-158
- [53] Li RK, Zeng MS, Rao SX, Qiang JW, Dai YM, Ji Y, et al. Using a 2D multibreath-hold susceptibility-weighted imaging to visualize intratumoral hemorrhage of hepatocellular carcinoma at 3T MRI: Correlation with pathology. *Journal of Magnetic Resonance Imaging*. 2012;**36**(4):900-906
- [54] Feier D, Balassy C, Bastati N, Fragner R, Wrba F, Ba-Ssalamah A. The diagnostic efficacy of quantitative liver MR imaging with diffusion-weighted, SWI, and hepato-specific contrast-enhanced sequences in staging liver fibrosis—A multiparametric approach. *European Radiology*. 2016;**26**(2):539-546
- [55] Lee H, Jun DW, Kang B-K, Nam E, Chang M, Kim M, et al. Estimating of hepatic fat amount using MRI proton density fat fraction in a real practice setting. *Medicine*. 2017;**96**(33):e7778
- [56] Heba ER, Desai A, Zand KA, Hamilton G, Wolfson T, Schlein AN, et al. Accuracy and the effect of possible subject-based confounders of magnitudebased MRI for estimating hepatic proton density fat fraction in adults, using MR spectroscopy as reference. *Journal of Magnetic Resonance Imaging*. 2016;**43**:398-406
- [57] Permutt Z, Le T-A, Peterson MR, Seki E, Brenner DA, Sirlin C, et al. Correlation between liver histology and novel magnetic resonance imaging in adult patients with non-alcoholic fatty liver disease—MRI accurately quantifies hepatic steatosis in NAFLD. *Alimentary Pharmacology & Therapeutics*. 2012;**36**(1):22-29
- [58] Idilman IS, Aniktar H, Idilman R, Kabacam G, Savas B, Elhan A, et al. Hepatic steatosis: Quantification by proton density fat fraction with MR imaging versus liver biopsy. *Radiology*. 2013;**267**:767-775
- [59] Geier A, Dietrich CG, Voigt S, Kim SK, Gerloff T, Kullak-Ublick GA, et al. Effects of proinflammatory cytokines on rat organic anion transporters

during toxic liver injury and cholestasis. *Hepatology*. 2003;**38**(2):345-354

[60] Weinmann HJ, Bauer H, Frenzel T, Muhler A, Ebert W. Mechanism of hepatic uptake of gadoxetate disodium. *Academic Radiology*. 1996;**3**(Suppl 2): S232-S234

[61] Leonhardt M, Keiser M, Oswald S, Kuhn J, Jia J, Grube M, et al. Hepatic uptake of the magnetic resonance imaging contrast agent Gd-EOB-DTPA: Role of human organic anion transporters. *Drug Metabolism and Disposition*. 2010;**38**(7):1024-1028

[62] International Transporter C, Giacomini KM, Huang SM, Tweedie DJ, Benet LZ, Brouwer KL, et al. Membrane transporters in drug development. *Nature Reviews. Drug Discovery*. 2010;**9**(3):215-236

[63] Motosugi U, Ichikawa T, Muhi A, Sano K, Morisaka H, Ichikawa S, et al. Magnetic resonance elastography as a predictor of insufficient liver enhancement on gadoxetic acid-enhanced hepatocyte-phase magnetic resonance imaging in patients with type C hepatitis and Child-Pugh class A disease. *Investigative Radiology*. 2012;**47**(10):566-570

[64] Kullak-Ublick GA, Stieger B, Meier PJ. Enterohepatic bile salt transporters in normal physiology and liver disease. *Gastroenterology*. 2004;**126**(1):322-342

[65] Reimer P, Schneider G, Schima W. Hepatobiliary contrast agents for contrast-enhanced MRI of the liver: Properties, clinical development and applications. *European Radiology*. 2004;**14**(4):559-578

[66] Tsuda N, Matsui O. Cirrhotic rat liver: Reference to transporter activity and morphologic changes in bile canaliculi–gadoxetic acid-enhanced MR imaging. *Radiology*. 2010;**256**(3):767-773

[67] Ba-Ssalamah A, Bastati N, Wibmer A, Fragner R, Hodge JC, Trauner M, et al. Hepatic gadoxetic acid uptake as a measure of diffuse liver disease: Where are we? *Journal of Magnetic Resonance Imaging*. 2017;**45**(3):646-659

[68] Tsuda N, Okada M, Murakami T. New proposal for the staging of nonalcoholic steatohepatitis: Evaluation of liver fibrosis on Gd-EOB-DTPA-enhanced MRI. *European Journal of Radiology*. 2010;**73**(1):137-142

[69] Feier D, Balassy C, Bastati N, Stift J, Badea R, Ba-Ssalamah A. Liver fibrosis: Histopathologic and biochemical influences on diagnostic efficacy of hepatobiliary contrast-enhanced MR imaging in staging. *Radiology*. 2013;**269**(2):460-468

[70] Bastati N, Feier D, Wibmer A, Traussnigg S, Balassy C, Tamandl D, et al. Noninvasive differentiation of simple steatosis and steatohepatitis by using gadoxetic acid-enhanced MR imaging in patients with nonalcoholic fatty liver disease: A proof-of-concept study. *Radiology*. 2014;**271**:739-747

[71] Watanabe H, Kanematsu M, Goshima S, Kondo H, Onozuka M, Moriyama N, et al. Staging hepatic fibrosis: Comparison of gadoxetate disodium-enhanced and diffusionweighted MR imaging—Preliminary observations. *Radiology*. 2011;**259**:142-150