

# We are IntechOpen, the world's leading publisher of Open Access books Built by scientists, for scientists

6,900

Open access books available

186,000

International authors and editors

200M

Downloads

Our authors are among the

154

Countries delivered to

TOP 1%

most cited scientists

12.2%

Contributors from top 500 universities



WEB OF SCIENCE™

Selection of our books indexed in the Book Citation Index  
in Web of Science™ Core Collection (BKCI)

Interested in publishing with us?  
Contact [book.department@intechopen.com](mailto:book.department@intechopen.com)

Numbers displayed above are based on latest data collected.  
For more information visit [www.intechopen.com](http://www.intechopen.com)



# Viral Retinitis: Diagnosis and Management Update

*Abhinav Dhami and Ravinder Kaur Malhi*

## Abstract

Cytomegalovirus, herpes simplex, and herpes zoster are responsible for the majority of cases of viral retinitis and can occur in both healthy and immunocompromised or immunodeficient individuals. Herpes zoster has been strongly incriminated as a causal agent in acute retinal necrosis in immunocompetent patients. Epstein Barr virus has been described in various ocular inflammatory diseases including multifocal choroiditis in healthy patients. In immunocompromised or immunodeficient patients, various opportunistic viral infections can occur; the most common being cytomegalovirus (CMV) infection. Other less common viruses causing retinal infections include herpes simplex virus (HSV) and varicella zoster virus (VZV). The vision-threatening complications associated with infectious viral disease are disastrous in nature due to rapid progression. The inability to control this viral retinitis requires early detection by the clinician with prompt and aggressive initiation of the drug therapy to prevent complications.

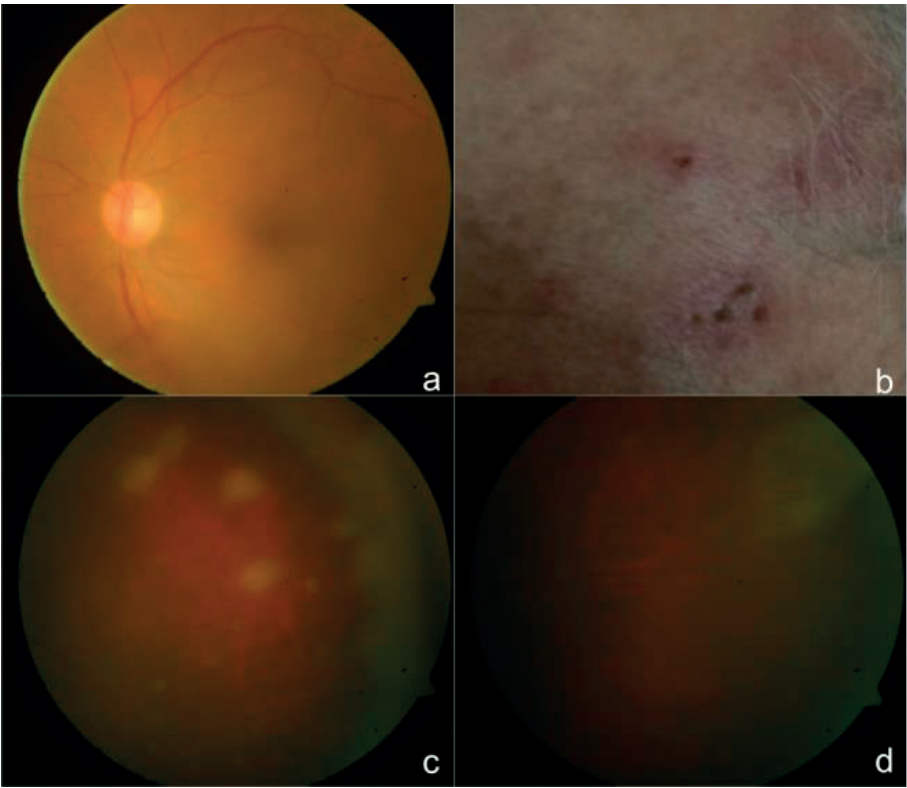
**Keywords:** acute retinal necrosis, herpes zoster, herpes simplex, cytomegalovirus

## 1. Introduction

Viral retinitis is an important vision threatening infectious disease of the retina which can occur in both immunocompetent and immunocompromised or immunodeficient acquired immunodeficiency syndrome (AIDS) individuals. In immunocompetent patients, acute retinal necrosis (ARN) has been recognized as a vision threatening inflammation caused primarily by herpes group of viruses while Epstein Barr virus (EBV) is associated with various ocular inflammatory diseases including multifocal choroiditis in healthy patients [1]. The immunocompromised or immunodeficient patients are predisposed to a higher risk for viral infections with the most common being cytomegalovirus (CMV) infection and the less commonly affecting viruses include herpes simplex virus (HSV) and varicella zoster virus (VZV) [1].

## 2. Acute retinal necrosis

It is characterized by the initial onset of episcleritis or scleritis, periorbital pain, and anterior uveitis, which may be granulomatous or stellate in appearance and lead to decreased vision resulting from vitreous opacification (**Figure 1a**), necrotizing retinitis, and, in some cases, optic neuritis or neuropathy. The American Uveitis Society released its criteria for diagnosis of acute retinal necrosis syndrome in 1994 (**Table 1**) [2]. Takase et al. [3] described a newer diagnostic criteria which includes: six ocular findings in the early stage, five clinical courses, and the virologic tests of intraocular fluids.



**Figure 1.**  
(a) Fundus photo of left eye showing media haze with vitritis, (b) herpes zoster lesions on the scalp, (c) peripheral fundus pictures showing deep yellowish white patches, in the peripheral retina and spreading concentrically with adjoining active vasculitis, and (d) resolution of the whitish lesion with valacyclovir 1 g TDS after 6 weeks.

Required clinical criteria	Supporting clinical criteria
One or more foci of retinal necrosis with discrete borders, located in peripheral retina	Optic neuropathy/atrophy
Rapid progression of disease in the absence of therapy	Scleritis
Circumferential spread of disease	Pain
Evidence of occlusive vasculopathy and arteriolar involvement	
A prominent inflammatory reaction in the vitreous and anterior chamber	

**Table 1.**  
American uveitis society criteria for diagnosis of acute retinal necrosis.

**2.1 The six ocular findings include**

- (1a) Presence of anterior chamber cells or mutton-fat keratic precipitates.
- (1b) Presence of yellow-white lesion in the peripheral retina (granular or patchy in the early stage, then gradually merging.
- (1c) Associated retinal arteritis.
- (1d) Presence of hyperemic optic disc.

(1e) Presence of inflammatory vitreous opacities.

(1f) Associated elevated intraocular pressure (IOP).

## 2.2 The five clinical courses include

(2a) Rapid expansion of retinal lesion circumferentially.

(2b) Development of retinal breaks or retinal detachment.

(2c) Associated retinal vascular occlusion.

(2d) Associated optic atrophy.

(2e) Response to antiviral agents.

## 2.3 Virologic testing

It consists of the intraocular fluid analysis by using PCR or the Goldmann-Witmer (GW) coefficient for HSV-1, HSV-2, or VZV. A “virus-confirmed ARN” was defined as the presence of ocular findings in stage 1a and 1b, the presence of any one of the five clinical courses, and a positive virologic test result. A “virus-unconfirmed ARN” was defined by them as the presence of four of six early stage ocular findings including 1a and 1b, presence of any two of the five clinical courses, a negative virologic test result, or when virologic testing had not been performed [3].

Clinical appearance of retinitis is deep yellowish white patches, typically beginning in the peripheral retina and spreading concentrically and towards the posterior pole (**Figure 1c** and **d**). An active vasculitis (**Figure 1a**) is present, with perivascular hemorrhages, sheathing, and terminal obliteration of arterioles by thrombi lasting about 4–6 weeks [4, 5].

Frequently the necrotic and normal retinal edge acts a site for developing fresh retinal breaks, with a 75% risk for developing rhegmatogenous retinal detachment (RRD) in untreated eyes [6]. Systemically these patients have a risk for developing meningoencephalitis and a neurologic symptoms should be borne in mind while treating such patients [7, 8].

## 3. Etiology

Considerable evidence points to multiple members of the herpesvirus family in the etiology of ARN syndrome with VZV (**Figure 1b**) [7] being the leading cause followed HSV [9] and rarely by CMV and EBV [10].

### 3.1 Histopathology

Studies of blind eyes enucleated early in the course of ARN have demonstrated retinal necrosis with eosinophilic intranuclear inclusions within cells of all layers of retina and retinal pigment epithelium. Immune complex deposition for VZV and HSV antigen can be noted in the retinal vessels [11].

The differential diagnosis that need to be rules out include CMV retinopathy, syphilitic retinitis, toxoplasmosis, large cell lymphoma, hemorrhagic vasculitis and Progressive outer retinal necrosis [10].

ARN is a syndrome whose clinical diagnosis is established on the basis of the evolving signs and symptoms, which may be pathognomonic in many cases, but in atypical cases ancillary clinical history or laboratory tests help in supporting and identifying the diagnosis [1, 2]. The patient's level of immunocompetence has to be determined, as this adds knowledge of the seropositivity to HIV and syphilis and may help to establish an appropriate and specific diagnosis. The most sensitive and specific method for the detection of herpes viruses in vitreous specimens is the polymerase chain reaction (PCR) [3–7]. Genomic DNA of human herpes virus (HHV), toxoplasma, bacteria, and fungi can be measured in the aqueous humor and vitreous fluids using of two independent PCR assays either a qualitative multiplex PCR or a quantitative real-time PCR and secondly a broad-range real-time PCR. The multiplex PCR can qualitatively measures the genomic DNA of eight different types of HHVs: (HSV) type 1 (HHV-1), HSV-2 (HHV-2), (VZV; HHV-3), Epstein-Barr virus (EBV; HHV-4), CMV (HHV-5), HHV-6, HHV-7, HHV-8, and toxoplasma [3]. PCR is now capable of detecting a single varicella zoster with a positivity of 86.4% and it was noted that aqueous sample yields a lesser chance for detection of virion in comparison to vitreous biopsy [12, 13].

Takase et al. [3] observed the overall rate of positive results of PCR for HSV-1, HSV-2, or VZV was 95% for ARN and 8% for control uveitis, a difference that was statistically significant [3]. In cases in which PCR is negative but a high clinical suspicion, endoretinal biopsy and a central spinal fluid tap has been deemed more appropriate. Taking the biopsy from the transition zone between normal and necrotic retina during the acute phase of the disease greatly increases its diagnostic yield [12]. Another method for detection of intraocular viral infection can be achieved by measuring the viral antibody titers (FA) in serum and intraocular fluids and then calculating the quotient ratio (Q value or Goldmann-Witmer coefficient). If the Goldmann-Witmer coefficient of 1 or above is obtained, it establishes proof of intraocular specific antibody production, hence intraocular infection should be suspected. However, the positivity of the Goldmann-Witmer coefficient can vary with time and from onset of ARN syndrome [3, 14].

#### **4. Prognosis and treatment**

Literature states that a generally poor prognosis in untreated eyes is expected in eyes with classic ARN syndrome and only 28% of affected eyes end up obtaining a final vision better than 20/200 as there are coexistent risks of RRD (75% of affected eyes), optic nerve dysfunction, or macular abnormality [6].

In the recent era of antiviral therapy and vitrectomy techniques have enabled in decreasing the level of vision loss associated with ARN to less than one-third of cases in recent years [15]. However, the use of prophylactic laser photocoagulation has become more controversial than it was in the past [16]. The comparison of lasered and non-lasered eyes as analyzed by Roy et al. [17], concluded that many eyes with severe ARN with the presence of vitreous inflammatory opacification usually preclude the application of laser, whereas eyes with mild ARN with relatively clear media allows the application of laser. They noted that prophylactic laser retinopexy failed to prevent secondary RD and found no protective role in preventing RRD's even after laser retinopexy, because the involved retinal area continues to extend posteriorly beyond the demarcation of the laser burns. It was concluded that eyes in which laser treatment was possible, obviously had less retinitis and hence vitritis, which ultimately gave them a better final visual prognosis [17].



## 5. Treatment

(1g) Acyclovir is given intravenously for 5–10 days of 1500 mg/m<sup>2</sup>/day in three divided doses with normal renal function tests. This is followed by oral acyclovir dose 800 mg (orally) 5 times daily for 6 weeks. The side-effects which close monitoring include decreased renal function, gastrointestinal irritation, phlebitis, central nervous system dysfunction, and hypersensitivity reactions. The most potent antiviral action is against VZV, HSV types 1 and 2, EBV, but a low activity has been noted in various studies against CMV [17].

(1h) Valacyclovir [L-valyl ester of acyclovir], has better bioavailability and is used in the doses of 1 g three times a day for 6–8 weeks. Treatment algorithms as cited in literature used oral valacyclovir 1 g 3 times daily, oral famciclovir 500 mg 3 times daily, or valganciclovir 450–900 mg 2 times daily until complete resolution of retinitis was observed [17, 18]. Renal function need to be monitored for all antivirals are administered on a long-term basis, especially in extremes of age.

(1i) Adjunctive role for intravitreal antiviral medication in the treatment of ARN syndrome has been explored in early remission of the retinitis. The original dose of ganciclovir used was 200 or 400 mcg in 0.1 ml, but nowadays the dose is 2 mg in 0.05–0.1 ml. The injections are given on a weekly basis. Intravitreal foscarnet in humans at a dose of 2.4 mg in 0.1 ml has also been reported to be safe and effective in treating retinitis caused by cytomegalovirus followed with a maintenance dose once a week, with a close monitoring for optic and retinal toxicity. Intravitreal therapy forms a part of palliation therapy for patients who are unable to tolerate or refuse systemic treatment, or as an adjunct in severe disease. However, studies have demonstrated efficacy as good as or better than intravenous treatment [18, 19].

(1j) Systemic corticosteroids also may limit intraocular inflammation and the vitreous reaction, but are generally begun only after 24–48 h of intravenous acyclovir/oral valacyclovir [20].

(1k) The combination of systemic and intravitreal therapy has been reported as new a treatment paradigm for patients with ARN. Flaxel et al. conducted a comparative case series and analyzed in 24 patients with ARN treated over a 20-year period. They had 12 patients in the study who received combination systemic and intravitreal antiviral therapy while 12 patients received only systemic therapy alone. Patients receiving combination therapy showed a higher incidence of two-line-or-greater visual acuity and decreased incidence of RD and severe visual acuity loss to 20/200 or poorer when compared to patients who received systemic antiviral alone and similar results were obtained by Wong et al. and Megphara et al. They concluded that patients that with moderate disease (i.e., 25–50% retina involved) usually showed better results. However, Tibbetts et al. found no statistically significant difference in the visual acuity and prevalence of retinal detachment with combination therapy [21].

In recent years the use of adjunctive intravitreal antivirals has increased as it enables a high concentration of antiviral agent to reach where it is needed most. Intravitreal foscarnet was used in 46.7% of patients by TF Cochrane et al. in their study and linked its use with a no specific reduction in the rate of retinal detachment versus eyes treated without intravitreal therapy. No specific guidelines have been outlined with the use and number of injections required for controlling the viral retinitis [13, 17, 18].

Kawaguchi et al. described an algorithm where they used combination of antiviral, anti-inflammatory and antithrombotic treatment depending on virus isolated. They suggested that higher doses of systemic acyclovir (10 vs. 15 mg/kg), oral prednisolone (30 vs. 40–60 mg/d) and aspirin (100 vs. 200–300 mg/d) should be given to those with VZV ARN [13]. Till date no specific trial has validated the efficacy of virus specific.

Treatment and all current treatment options available for ARN are based on anecdotal evidence.

Before the antiviral management the reported incidence of second eye involvement was 36% in ARN patients, usually within 6 weeks. However with better management, most of the recent studies conclude a fellow-eye involvement rate of around 3% with appropriate antiviral treatment [6, 18]. The duration for which the systemic treatment should be continued to prevent fellow-eye involvement is not well established in literature. The risk is believed to be decrease if therapy is continued for 6–12 weeks. The incidence of bilateral ARN reported in literature has been as late as 34 years after the first eye became affected [18]. The syndrome of ARN is a potentially visually devastating disorder with multifactorial pathogenesis. Its successful management depends on further advances in antiviral chemotherapy, control of the ischemic vasculopathy, and prevention of proliferative vitreoretinopathy [1, 5, 22].

To conclude ARN is a rare but potentially visually devastating condition and both qualitative and quantitative real-time PCR testing may be used both to ascertain the etiology of ARN and to assess the response to therapy. During the last few years the first-line of therapy has been the use of oral prodrugs valacyclovir, famciclovir and valganciclovir which has gained popularity because the patients do not have to be hospitalized with oral therapy in contrast to intravenous therapy and thus preventing the devastating complications. It is still a matter of debate from most of the studies whether and where all prophylactic laser is deemed beneficial in preventing RRD. Intravitreal antiviral therapy acts in supportive role in combination with the oral antiviral therapy for better visual outcomes.

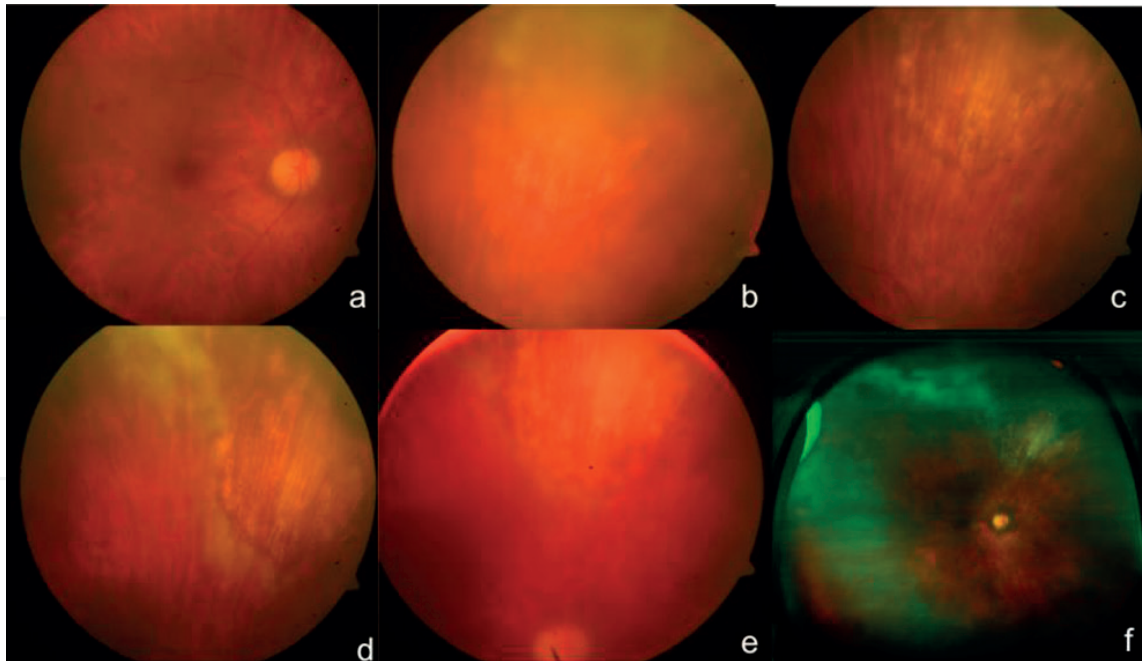
## **6. Cytomegalovirus retinitis**

CMV is ubiquitous entity and its seroprevalence rises from nearly 60% in patients 6 years or older to greater than 90% in individuals more than 80 year of age [23].

In immunocompetent individuals the initial infection with CMV causes minimal symptoms, although an associated mononucleosis-like syndrome can be a presentation. Cell-mediated immunity helps to control the virus and prevents specific organ disease in all, but may affect a few patients [24]. However, in the presence of advanced immunosuppression, such as AIDS, history of organ transplantation with iatrogenic immunosuppression, autoimmune disease, or malignancy are a higher risk of developing specific end-organ CMV disease (e.g., encephalitis, esophagitis, colitis, and retinitis), thus increasing the risk of morbidity and mortality [23–25].

## **7. Ophthalmoscopic findings**

The diagnosis of CMV is based on clinical appearance and correlating it with a supportive history of an immunocompromised state. The retinal lesions appear peripherally in a perivascular distribution as a creamy white infiltrate and associated



**Figure 2.**

(a) Fundus picture of right eye of a female patient presented with diminution of vision after renal transplant, with posterior active vasculitis with presence of hemorrhages, (b) (superior retina just above the arcade) a mid-peripheral perivascular vitritis with a creamy white infiltrate, with a more granular border, (c) the area of resolution of the whitish lesion after treatment with 450 mg B.D of valganciclovir after 3 months, (d) recurrence at the edge of the lesion 2 months post tapering dose of valganciclovir, (e) resolution of the recurrence at the edge with initiation of 450 mg B.D of valganciclovir, and (f) an wide field image at last follow up where patient underwent intravitreal ganciclovir injection 2 mg/0.5 ml with oral valganciclovir, showing resolution of the retinitis with peripheral scarring and gliosis.

granular borders surrounded with smaller satellite lesions (**Figure 2a** and **b**). There is a space of “clear” retina separating in between the granular foci. Progression of active retinitis causes scarring (**Figure 2c**), suggesting the virus involvement from the beginning. The active border progresses posteriorly, at a rate of 250–350  $\mu\text{m}$ /week, causing scarring and adjoining necrosis of retina (**Figure 2f**) with mottled pigmentation of the RPE. The term “pizza pie” appearance is associated with CMV if the retinitis lesions are presenting more posteriorly thus involving the retinal vessels and causing retinal hemorrhages (**Figure 2a**) [25, 26].

A second pattern of CMV retinitis has as describes includes a “granular” or “brushfire border.” The focal granular infiltrates enlarge slowly and advancement is associated with destruction of the retina and leaving a atrophic retinal pigment epithelium behind. Hemorrhages and vitreous cells are less prominent seen. This is attributed to be direct cell-to cell transfer of infected virions in this pattern of infection. The brushfire border is commonly seen in the anterior to the equator [24–27].

The clinical appearance of newly diagnosed CMV retinitis has not altered appreciably from the pre-highly antiretroviral therapy (HAART) era to the HAART era [26]. A delay in diagnosis increases the risk of vision loss either due to fulminant retinitis (foveal or optic nerve involvement), or it may induce immune recovery uveitis (IRU) and its associated sequelae increase with the severity of CMV retinitis in elderly, healthy patients with CMV retinitis. The delayed diagnosis causes retinal arteriolar occlusions, with poor visual outcomes [27].

Histopathologically there is presence of extensive areas of necrosis with diffuse or full thickness retinal involvement. In the areas of necrosis intracytoplasmic as well intranuclear inclusions resembling ‘Owl eyes’ can be noted. The majority of the enlarged cells are in the range of 20–30  $\mu\text{m}$  with intranuclear basophilic inclusion and numerous eosinophilic intracytoplasmic inclusions [28].



## **8. Clinical findings of CMV retinitis in non-HIV-positive patients**

In elderly immune-competent patients (other than the natural waning of immunity and increased prevalence of typical comorbidities that come with age), CMV retinitis tends to have an increased association with retinal arteriolar occlusions, even with minimal retinitis. In patients with limited immune dysfunction (due to old age, diabetes, or noncytotoxic immunosuppression), CMV retinitis can present with typical peripheral, granular, and slowly progressive retinitis and an atypical panretinal occlusive vasculitis, mimicking ARN [29].

### **8.1 Biochemical testing**

In cases of diagnostic dilemma, especially in the absence of an identifiable source of host immunosuppression, polymerase chain reaction (PCR) of aqueous or vitreous samples can amplify CMV DNA and secure a diagnosis. Recently, a loop-mediated isothermal amplification (LAMP) assay has demonstrated 100% concordance with PCR in detecting CMV DNA in vitreous samples of patients suspected or diagnosed as CMV retinitis at a fraction of the cost, potentially increasing the diagnostic capabilities of clinicians in [30, 31].

### **8.2 Screening**

All HIV individuals with CD4+ T cell counts <50 cells/ $\mu$ L, need a screening by a uveitis or retinal specialist using dilated fundus exams every 3 months [27].

In patients undergoing allogeneic hematopoietic stem cell transplantation (HSCT) after conditioning with an alemtuzumab (Campath, Genzyme, Cambridge, MA)-based regimen, the frequency of CMV retinitis can approach 24% and similarly, post-HSCT patients with a significant CMV viral load (peak CMV DNA level  $>7.64 \times 10^4$  copies/mL) are at increased risk of developing CMV retinitis and require periodic screening for ruling out retinitis [32].

### **8.3 Management**

Because no currently available agent is virucidal, the goal of therapy is to arrest viral replication/assembly until the host's immune system has recovered sufficiently to assume this function. Factors to be considered in selecting the mode of therapy include the patient's potential for immunologic improvement, the location and severity of CMV retinitis, and the risks, costs, and convenience associated with various therapies [32].

In the setting of HIV/AIDS, initiation of HAART is the most critical step in planning for long-term suppression of CMV retinitis. In the event that immune system recovery is unexpected (i.e., transplant recipients requiring lifelong immunosuppression), the physician should provide indefinite virostatic treatment [32].

The treatment for CMV retinitis includes three intravenous drugs: oral or intravenous ganciclovir, intravenous foscarnet and intravenous cidofovir. The role of systemic therapy is by starting at a higher induction dose for 2–3 weeks, followed by lower maintenance doses as it helps in preventing relapses of the retinitis. The purposed mechanism of action is specific selective inhibition of viral DNA polymerase [32].

The treatment of choice includes intravenous ganciclovir in two divided doses for 2 weeks of initial induction therapy (5–7 mg/kg/day), followed by a once-daily maintenance dose. It is continued until the lesions begin to resolve and the patient's immune status shows improvement. Oral valganciclovir 900 mg twice daily as

induction therapy followed by 900 mg once daily as maintenance dose as it serves an additional advantage of being a non-parenteral mode of treatment and avoiding complications relating to indwelling catheters, especially in immunocompromised patients. Foscarnet is administered as 90 mg/kg, twice daily for 14–21 days, as induction therapy, followed by once-daily administration as maintenance therapy. It is the preferred treatment of choice in Ganciclovir resistant cases [19, 32–34].

Recently the use of oral valganciclovir (Valcyte, Roche), an L-valyl ester prodrug of ganciclovir, is preferred as it obviates the risks due to intravenous therapy, but the cost of therapy and its related myelosuppression remain an issue. The bioavailability of 60% is obtained by the drug, which is comparable to intravenous ganciclovir and far greater than with oral ganciclovir (5%). Several newer antiviral agents are in various stages of preclinical experiments to phase 2 clinical trials include: Cidofovir, Maribavir (GlaxoSmithKline, Philadelphia, PA), BAY 38-4766 (Bayer, Pittsburgh, PA), and AIC246 (AiCuris, Wuppertal, Germany), inhibit viral activity through pathways other than the inhibition of viral DNA polymerase [33].

#### 8.4 Intravitreal therapy

The preferred intravitreal injections consist of either ganciclovir or foscarnet, with or without systemic medication, to control sight-threatening retinitis. Induction dosing with intravitreal medications requires injections two to three times weekly, while once weekly generally is sufficient for maintenance.

1. Ganciclovir: the original dose used was 200 or 400 mcg in 0.1 ml, but almost all injections given today are 2 mg in 0.05–0.1 ml. The injections are given on a weekly basis. It is also available as an intraocular ganciclovir implant (Vitrasert, Bausch + Lomb, Rochester, NY) and demonstrated superiority over intravenous ganciclovir in terms of median time to the progression of retinitis (221 days for the 1 µg/h implant vs. 71 days for intravenous ganciclovir). Complication rates associated with the ganciclovir implant, most commonly for cataract, vitreous hemorrhage, and retinal detachment [20].
2. Foscarnet: it is used in the dose of 2.4 mg per 0.1 ml. It is used as twice weekly injections for induction period and once a week for maintenance therapy. They may be more effective in cases of resistant CMV disease. Combinations of high-dose intravitreal ganciclovir (3.0 mg twice a week) and foscarnet (2.4 mg twice a week) may be effective in patients who fail to respond or are intolerant to conventional therapy for ARN and HSV-1 retinitis. The most commonly reported complications include cataract, vitreous hemorrhage, and retinal detachment [34].
3. Cidofovir: the long half-life and potent anti-CMV activity of Cidofovir make it an attractive candidate for intravitreal injection. Studies in rabbits suggested that 100 mcg was a safe dose. Increased proteinuria and elevations in serum creatinine are the major dose limiting toxicities [19, 34, 35].
4. Fomivirsen: Vitravene, (Isis Pharmaceuticals Inc., Carlsbad, CA, USA) has also been studied for intravitreal use in patients with CMV retinitis, especially in situations where conventional therapy such as systemic and intravitreal ganciclovir, foscarnet, or cidofovir have failed or are contraindicated. Induction doses of fomivirsen are administered intravitreally at a dose of 330 mcg once every 2 weeks for 2 doses followed by maintenance therapy at same dose every 4 weeks [19, 34].

## **9. Treatment options in resistance**

The treatment of CMV retinitis in the setting of drug resistance remains a particular challenge as newer antivirals take time to reach the level of commercial availability. Oral leflunomide (Arava, Sanofi-Aventis, Bridgewater, NJ), an immunosuppressive agent with anti-CMV activity, has demonstrated efficacy in transplant patients with systemic CMV infection and also in multi-drug-resistant CMV retinitis [36].

## **10. Conclusion**

The evident benefits of HAART have helped in decreasing incidence and severity in immune compromised patients but still CMV retinitis remains the most common ocular opportunistic infection. Patients with a CD4+ T cell count <50 are at increased risk of CMV retinitis, and frequent screening of these patients is the need of the hour to detect the disease before it becomes sight-threatening [36].

### **10.1 Progressive outer retinal necrosis**

Progressive outer retinal necrosis (PORN, also known as VZV retinitis or rapidly progressive herpetic retinal necrosis) was described and cited most by Engstrom and colleagues in 1994. They established about its devastating nature, in which two-thirds of eyes progressed to no light perception (NLP) within 4 weeks of onset. They concluded that most patients with this syndrome have had low CD4 cell counts (i.e., below 50/ml). It is mostly found in immunocompromised patients and diagnosis is based on the presence of:

1. Multifocal lesions with deep retinal opacification without granular borders with some areas of confluent opacification.
2. Peripheral retina location, with or without macular involvement.
3. Rapid progression.
4. Absence of vascular inflammation.
5. Minimal or no intraocular inflammation.
6. Perivascular clearing of the retinal opacification (hallmark of PORN syndrome).
7. Immunocompromised or patients with immunosuppression [37, 38].

Therapy of PORN often requires immediate high-dose anti-zoster or -HSV therapy. The earliest reports of treatment of PORN with single intravenous antivirals, primarily acyclovir, showed poor visual results. Recently the studies have shown an improvement in the visual outcomes with the combination use of intravenous and intravitreal antiviral treatment [38].

Scott et al. have reported that final vision of 20/80 or better in 5 of 11 eyes (45%) and only two of 11 eyes (18%) progressing to NLP vision. This was achieved utilizing a regimen of intravitreal ganciclovir and foscarnet plus IV foscarnet and IV ganciclovir or oral valganciclovir [39].

Gore et al. have the largest published series of patients with PORN treated with intravitreal ganciclovir antiviral therapy, found an improvement in final vision, with only 9 (13%) eyes losing perception of light. They observed that the retinas in patients receiving HAART when first evaluated were significantly less likely to detach and had a bimodal distribution to retinal detachment, the vast majority of retinas detaching within the first few weeks (i.e., during the active necrotic phase) and a few detaching many months later (i.e., during the inactive phase). The early group can be explained by full-thickness necrosis, leading to holes through both the inner and outer retina, as a prelude to RRD. For delayed RRD's they proposed that some retina's are associated with one or more sieve-like holes that can occasionally self-seal with the ensuing scarring process, allowing a functioning retinal pigment epithelium to pump the detachment flat [39].

Despite some patients being able to retain workable good vision, the overall functional outcomes remain alarming as a result of the catastrophic loss of vision PORN can lead to. The most encouraging results are achieved with improved visual outcomes when associated with early response to intravitreal ganciclovir injections. The best outcomes are limited to be seen in patients who begin intravitreal (and systemic) therapy within a few days of symptom onset, before macular involvement is apparent [39].

## Sources of support

Nil. No proprietary interest or conflict. No financial funding disclosure.

## Author details

Abhinav Dhama\* and Ravinder Kaur Malhi  
Vitreo-Retina Department, Dhama Eye Care Hospital, Punjab, India

\*Address all correspondence to: [drabhinavdhama@gmail.com](mailto:drabhinavdhama@gmail.com)

## IntechOpen

© 2019 The Author(s). Licensee IntechOpen. This chapter is distributed under the terms of the Creative Commons Attribution License (<http://creativecommons.org/licenses/by/3.0>), which permits unrestricted use, distribution, and reproduction in any medium, provided the original work is properly cited. 



## References

- [1] Biswas J, Madhavan HN, Gopal L, Badrinath SS. Clinical features and virologic studies in viral retinitis. *Indian Journal of Ophthalmology*. 1995;**43**:6368
- [2] Holland GN. Standard diagnostic criteria for the acute retinal necrosis syndrome. Executive Committee of the American Uveitis Society. *American Journal of Ophthalmology*. 1994;**117**(5):663-667
- [3] Takase H, Okada AA, Goto H, Mizuki N, Namba K, Ohguro N, et al. Development and validation of new diagnostic criteria for acute retinal necrosis. *Japanese Journal of Ophthalmology*. 2015;**59**(1):14-20
- [4] Duker JS, Nielsen JC, Eagle RC Jr, et al. Rapidly progressive acute retinal necrosis secondary to herpes simplex virus, type 1. *Ophthalmology*. 1990;**97**(12):1638-1643
- [5] Margolis T, Irvine AR, Hoyt WF, et al. Acute retinal necrosis syndrome presenting with papillitis and arcuate neuroretinitis. *Ophthalmology*. 1988;**95**(7):937-940
- [6] Fox GM, Blumenkranz M. Giant retinal pigment epithelial tears in acute retinal necrosis. *American Journal of Ophthalmology*. 1993;**116**(3):302-306
- [7] Cardine S, Chaze PA, Bourcier F, et al. Bilateral acute retinal necrosis syndrome associated with meningoencephalitis caused by herpes simplex virus 2. A case report. *Journal Français d'Ophtalmologie*. 2004;**27**(7):795-800
- [8] Soushi S, Ozawa H, Matsuhashi M, et al. Demonstration of varicella-zoster virus antigens in the vitreous aspirates of patients with acute retinal necrosis syndrome. *Ophthalmology*. 1988;**95**(10):1394-1398
- [9] Ludwig IH, Zegarra H, Zakov ZN. The acute retinal necrosis syndrome. Possible herpes simplex retinitis. *Ophthalmology*. 1984;**91**(12):1659-1664
- [10] Kramer S, Brummer C, Zierhut M. Epstein-Barr virus associated acute retinal necrosis. *The British Journal of Ophthalmology*. 2001;**85**(1):114
- [11] Culbertson WW, Blumenkranz MS, Haines H, et al. The acute retinal necrosis syndrome. Part 2: Histopathology and etiology. *Ophthalmology*. 1982;**89**(12):1317-1325
- [12] Short GA, Margolis TP, Kuppermann BD, et al. A polymerase chain reaction-based assay for diagnosing varicella-zoster virus retinitis in patients with acquired immunodeficiency syndrome. *American Journal of Ophthalmology*. 1997;**123**(2):157-164
- [13] Cochrane TF, Silvestri G, McDowell C, Foot B, McAvoy CE. Acute retinal necrosis in the United Kingdom: Results of a prospective surveillance study. *Eye*. 2012;**26**(3):370
- [14] Usui Y, Goto H. Overview and diagnosis of acute retinal necrosis syndrome. *Seminars in Ophthalmology*. 2008;**23**(4):275-283
- [15] Pepose JS, Flowers B, Stewart JA, et al. Herpesvirus antibody levels in the etiologic diagnosis of the acute retinal necrosis syndrome. *American Journal of Ophthalmology*. 1992;**113**(3):248-256
- [16] Litoff D, Catalano RA. Herpes zoster optic neuritis in human immunodeficiency virus infection. *Archives of Ophthalmology*. 1990;**108**(6):782-783

- [17] Roy R, Pal BP, Mathur G, Rao C, Das D, Biswas J. Acute retinal necrosis: Clinical features, management and outcomes—a 10 year consecutive case series. *Ocular Immunology and Inflammation*. 2014;**22**(3):170-174
- [18] Tibbetts MD, Shah CP, Young LH, et al. Treatment of acute retinal necrosis. *Ophthalmology*. 2010;**117**(4):818-824
- [19] Wong R, Pavesio CE, Laidlaw DA, Williamson TH, Graham EM, Stanford MR. Acute retinal necrosis: The effects of intravitreal foscarnet and virus type on outcome. *Ophthalmology*. 2010;**117**(3):556-560
- [20] Teoh SC, Ou X, Lim TH. Intravitreal ganciclovir maintenance injection for cytomegalovirus retinitis: Efficacy of a low-volume, intermediate-dose regimen. *Ophthalmology*. 2012;**119**(3):588-595
- [21] Shantha JG, Weissman HM, Debiec MR, Albin TA, Yeh S. Advances in the management of acute retinal necrosis. *International Ophthalmology Clinics*. 2015;**55**(3):1
- [22] Hillenkamp J, N'le B, Bruns C, et al. Acute retinal necrosis: Clinical features, early vitrectomy, and outcomes. *Ophthalmology*. 2009;**116**(10):1971-1975
- [23] Staras SA, Dollard SC, Radford KW, et al. Seroprevalence of cytomegalovirus infection in the United States, 1988-1994. *Clinical Infectious Diseases*. 2006;**43**:1143-1151
- [24] Gallant JE, Moore RD, Richman DD, et al. Incidence and natural history of cytomegalovirus disease in patients with advanced human immunodeficiency virus disease treated with zidovudine. The Zidovudine Epidemiology Study Group. *The Journal of Infectious Diseases*. 1992;**166**:1223-1227
- [25] Holland GN, Sison RF, Jatulis DE, et al. Survival of patients with the acquired immune deficiency syndrome after development of cytomegalovirus retinopathy. UCLA CMV Retinopathy Study Group. *Ophthalmology*. 1990;**97**:204-211
- [26] Jabs DA, Van Natta ML, Holbrook JT, et al. Longitudinal study of the ocular complications of AIDS: 2. Ocular examination results at enrollment. *Ophthalmology*. 2007;**114**:787-793
- [27] Kempen JH, Min YI, Freeman WR, et al. Studies of Ocular Complications of AIDS Research Group. Risk of immune recovery uveitis in patients with AIDS and cytomegalovirus retinitis. *Ophthalmology*. 2006;**113**:684-694
- [28] Chiotan C, Radu L, Serban R, Cornăcel C, Cioboata M, Anghel A. Cytomegalovirus retinitis in HIV/AIDS patients. *Journal of Medicine and Life*. 15 Jun 2014;**7**(2):237
- [29] Schneider EW, Elner SG, van Kuijk FJ, et al. Chronic retinal necrosis: Cytomegalovirus necrotizing retinitis associated with panretinal vasculopathy in non-HIV patients. *Retina*. 2013;**33**:1791-1799
- [30] Tran TH, Rozenberg F, Cassoux N, et al. Polymerase chain reaction analysis of aqueous humour samples in necrotizing retinitis. *The British Journal of Ophthalmology*. 2003;**87**:79-83
- [31] Reddy AK, Balne PK, Reddy RK, et al. Development and evaluation of loop-mediated isothermal amplification assay for rapid and inexpensive detection of cytomegalovirus DNA in vitreous specimens from suspected cases of viral retinitis. *Journal of Clinical Microbiology*. 2010;**48**:2050-2052
- [32] Song WK, Min YH, Kim YR, et al. Cytomegalovirus retinitis after

hematopoietic stem cell transplantation with alemtuzumab. *Ophthalmology*. 2008;**115**:1766-1770

immunodeficiency syndrome with progressive outer retinal necrosis. *Archives of Ophthalmology*. 2002;**120**:1219-1222

[33] Studies of ocular complications of AIDS Research Group in collaboration with the AIDS Clinical Trials Group. Mortality in patients with the acquired immunodeficiency syndrome treated with either foscarnet or ganciclovir for CMV retinitis. *The New England Journal of Medicine*. 1992;**326**:213-220

[34] Vadlapudi AD, Vadlapatla RK, Mitra AK. Current and emerging antiviral for the treatment of cytomegalovirus (CMV) retinitis: An update on recent patents. *Recent Patents on Anti-Infective Drug Discovery*. 2012;**7**:8-18

[35] Rahhal FM, Arevalo JF, Munguia D, Taskintuna I, de la Paz EC, Azen SP, et al. Intravitreal cidofovir for the maintenance treatment of cytomegalovirus retinitis. *Ophthalmology*. 1996;**103**(7):1078-1083

[36] Thorne JE, Jabs DA, Kempen JH, et al. Incidence of and risk factors for visual acuity loss among patients with AIDS and cytomegalovirus retinitis in the era of highly active antiretroviral therapy. *Ophthalmology*. 2006;**113**:1432-1440

[37] Gore DM, Gore SK, Visser L. Progressive outer retinal necrosis: Outcomes in the intravitreal era. *Archives of Ophthalmology*. 2012;**130**(6):700-706

[38] Galindez OA, Sabates NR, Whitacre MM, Sabates FN. Rapidly progressive outer retinal necrosis caused by varicella zoster virus in a patient infected with human immunodeficiency virus. *Clinical Infectious Diseases*. 1996;**22**(1):149-151

[39] Scott IU, Luu KM, Davis JL. Intravitreal antivirals in the management of patients with acquired