

# We are IntechOpen, the world's leading publisher of Open Access books Built by scientists, for scientists

6,900

Open access books available

186,000

International authors and editors

200M

Downloads

Our authors are among the

154

Countries delivered to

TOP 1%

most cited scientists

12.2%

Contributors from top 500 universities



WEB OF SCIENCE™

Selection of our books indexed in the Book Citation Index  
in Web of Science™ Core Collection (BKCI)

Interested in publishing with us?  
Contact [book.department@intechopen.com](mailto:book.department@intechopen.com)

Numbers displayed above are based on latest data collected.  
For more information visit [www.intechopen.com](http://www.intechopen.com)





---

# Hip Surgery in Cerebral Palsy

---

João Lameiras-Campagnolo

Additional information is available at the end of the chapter

<http://dx.doi.org/10.5772/intechopen.80442>

---

## Abstract

Hip pathology is one of the main orthopedic concerns in cerebral palsy (CP) patients. It has been demonstrated that correctly applied hip screening programs could significantly diminish the incidence of hip pathology. Unfortunately, in several countries, hip dislocation is significantly prevalent and is still a major concern in these patients. Depending on the age, the disability grade, the rehabilitation support, and the surgical strategies, results of hip treatment are variable. The ideal outcome of a stable, reduced, and long-lasting pain-free hip are not always achieved. In this chapter, we discuss theoretical and practical strategies used to treat specific CP hip dislocation. In younger children, simple femoral reorientation procedures (tenotomies with or without femoral osteotomies) promote correct acetabular remodeling. Later, surgical hip reduction can be an option even in late adolescents, and the use of capsuloplasty can lead to greater hip stability, in spite of eventual pelvis obliquity caused by associated spine pathology. Several technical tips for hip surgery are presented. It is essential that patients with CP hip problems receive proper follow-up, including rehabilitation medicine, physiotherapy, anti-spastic medication, on-time orthosis availability, and real teamwork concerned with this kind of pathology.

**Keywords:** cerebral palsy, hip, surgery, technical tips, children, adolescents

---

## 1. Introduction

In recent years, the cerebral palsy (CP) definition has evolved from Bobath's concept [1] of a group of non-progressive disorders of movement and posture caused by abnormal development of, or damage to, motor control centers of the brain. Nowadays, CP is also considered "a disorder of the development of movement and posture, causing activity limitations attributed to non-progressive disturbances of the fetal or infant brain that may also affect sensation,



perception, cognition, communication, and behavior. Motor control during reaching, grasping, and walking are disturbed by spasticity, dyskinesia, hyperreflexia, excessive coactivation of antagonist muscles, retained developmental reactions, and secondary musculo-skeletal malformations, together with paresis and defective programming" [2]. This concept expands the definition significantly: weakness and hypo-extensibility of the muscles are due not only to inadequate recruitment of motor units, but also to changes in mechanical stresses and hormonal factors. The notion of functional classification has become a major criterion in diagnosis, prognosis, and therapeutic strategy, particularly, the Gross Motor Function Measure (GMFM), has made it possible to evaluate the change over time and the effects of clinical interventions.

This means that a multi-disability, and not only a motor one, is present in CP patients in most cases. All of these factors must be taken into account to reach better clinical/functional results. The goals for each patient must be clear, "reachable" (technique, clinical team, drug therapy, and orthosis), and shared between the patient/family and the respective supporting team.

Several studies show that a correct screening program (Australia, Scandinavia, WHO [3–6]) can almost "eradicate" hip dislocation in CP patients, but the reality is that a large number of patients still have hip symptoms and disability, all around the world.

In this chapter, hip problems and their surgical treatment are discussed.

Most of the clinical studies that support our treatment options are widely documented in CP manuals and papers; some are cited in the "References" chapter.

Combining methods for hip evaluation and treatment with remarks and surgical tips, this chapter aims to enhance the efficacy and duration of positive results in CP patients.

## 2. Evaluation

The question of evaluation concerns more than just the patient. We must consider several factors:

- Type of CP and GMFCS grade
- Co-morbidities
- Health support
- Clinical exam and complementary diagnosis exams

### 2.1. Type of CP and GMFCS grade

Nowadays, the GMFCS grade is a fundamental tool in CP patient evaluation and treatment planning:

Milder forms have fewer hip problems—hemiplegic type is less prone to hip dislocation than either diplegic type or quadriplegic type.



Lesser GMFCS grades are also less prone to hip dislocation; walking patients can also have hip problems but it is relatively rare. Most hip dislocations are observed, crescently, in GMFCS Type III, IV, or V.

Spastic types are more prone to hip dislocation than athetotic and dyskinetic types, with involuntary movements; however, when these kinds of patients have hip symptomatology, they are much more difficult to treat (post-surgery care is very difficult; there are more cases of pressure sores within plasters, casts, or splints, and patient agitation tends to be greater).

Clinical evaluation is fluctuant in these patients. Even with careful and systematic observation and testing, there are some incongruities between different observations (consecutive or by different observers), due to the level of momentaneous spasticity, possibility of relaxation, expertise of the medical staff, or even imaging interpretation. For this reason, it is critical to take into account all of the data for each patient because clinical evolution is one of the key factors in the treatment strategy. In rare cases, the condition does not deteriorate as anticipated and abnormal findings can be surprisingly stable over time. This may permit the postponement of an initially planned surgery.

## **2.2. Co-morbidities**

There is some association between GMFCS grade and the amount of co-morbidities: mental retardation, impaired deglutition, drooling, gastro-intestinal hernia, seizures, respiratory, bowel or bladder problems, deafness, and others [7]. All of these co-morbidities influence not only the health status of patients, but also treatment strategies and patient compliance, and increase the risks of the different interventions. The problem of low weight in more disabled patients is a major concern for anesthetic and surgical teams. Sometimes a period of “fattening” is needed, and a gastric button for feeding may be considered.

## **2.3. Health support**

It is important to be aware of the scarcity of sufficient CP reference centers that address the needs of these kinds of patients. Another common shortfall is in the follow-up in the period of child to adult transition. Depending on where in the world treatment is taking place, the quality of the health care system and related organizational problems can vary dramatically. Unfortunately, these are issues without short-term solutions. It can be very frustrating for patients, respective family, and medical and social staff, to know that the most successful expected results will not be reached for a certain kind of patient, due to the lack of sufficient support.

There are a number of critical links in the treatment process, all of which impact the success of the outcome, among them are: correct patient screening and diagnosis; adequate medical and physical therapy (sometimes psychological and learning therapies); adequate and on-time adapted orthoses, social support to caregivers, transportation to and from medical/physical departments, access to movement quantitative analysis, and so on.

In many countries and/or regions (even in developed countries), all of the optimal needs are not available simultaneously. So, the reality is that patients are usually treated in sub-optimal or, sometimes, in incomplete conditions. Adaptations must be made and patients and family expectations should be adjusted accordingly.



That said, we must have the courage to refuse some interventions when the conditions to assure the possibility of a positive result are inadequate and pain and suffering outweigh the potential benefits.

## 2.4. Clinical exam and complementary diagnosis exams

Most of the data needed for treatment decisions is provided by a good history and a correct clinical exam, and by a succession of observations that demonstrate the progression of the disability.

After clinical evaluation, radiographic parameters become the key points for therapeutic decisions. Primary among these are the anteroposterior (AP) and frog lateral images. Obtaining standardized radiographs can be challenging. Pelvic obliquity, lumbar lordosis, and contractures interfere with proper positioning and measurements. The hips should be flexed to overcome the lumbar lordosis. We can observe evident asymmetry and femoral head coverage insufficiency (**Figure 1a**).

Several radiographic measurements have been reported, but the most widely used are the acetabular index and Reimer's migration index. The acetabular index is a helpful predictor of instability. It corresponds to the angle between a line uniting the two triradiate cartilages (horizontal, when the pelvis is leveled) and the line between medial and lateral edges of acetabulum (**Figure 1b**). Cooke and colleagues [8] identified an acetabular index of greater than  $30^\circ$  as a predictor of future instability in children more than the 4-year-old. The acetabular index varies with pelvic orientation. It decreases with lordosis and increases with flexion, and also varies with rotational malposition. The Reimer's migration index measures the degree of subluxation on the AP view. It is a simple, reliable, and reproducible measurement, comparing width of femoral head and percentage of head not covered by acetabulum (see **Figure 1c**). In a healthy child, the 90th percentile for migration percentile is 10%. The upper limit of normal is 25% in a 4-year-old. A migration index of 30% is considered abnormal. In a normal child, the spontaneous progression is less than 1%. In children with cerebral palsy, an annual increase of 7.7% was observed in those unlikely to walk, and 4% in those with walking potential. Spontaneous stabilization and correction without treatment were observed in some children with a migration index of 33% [8].

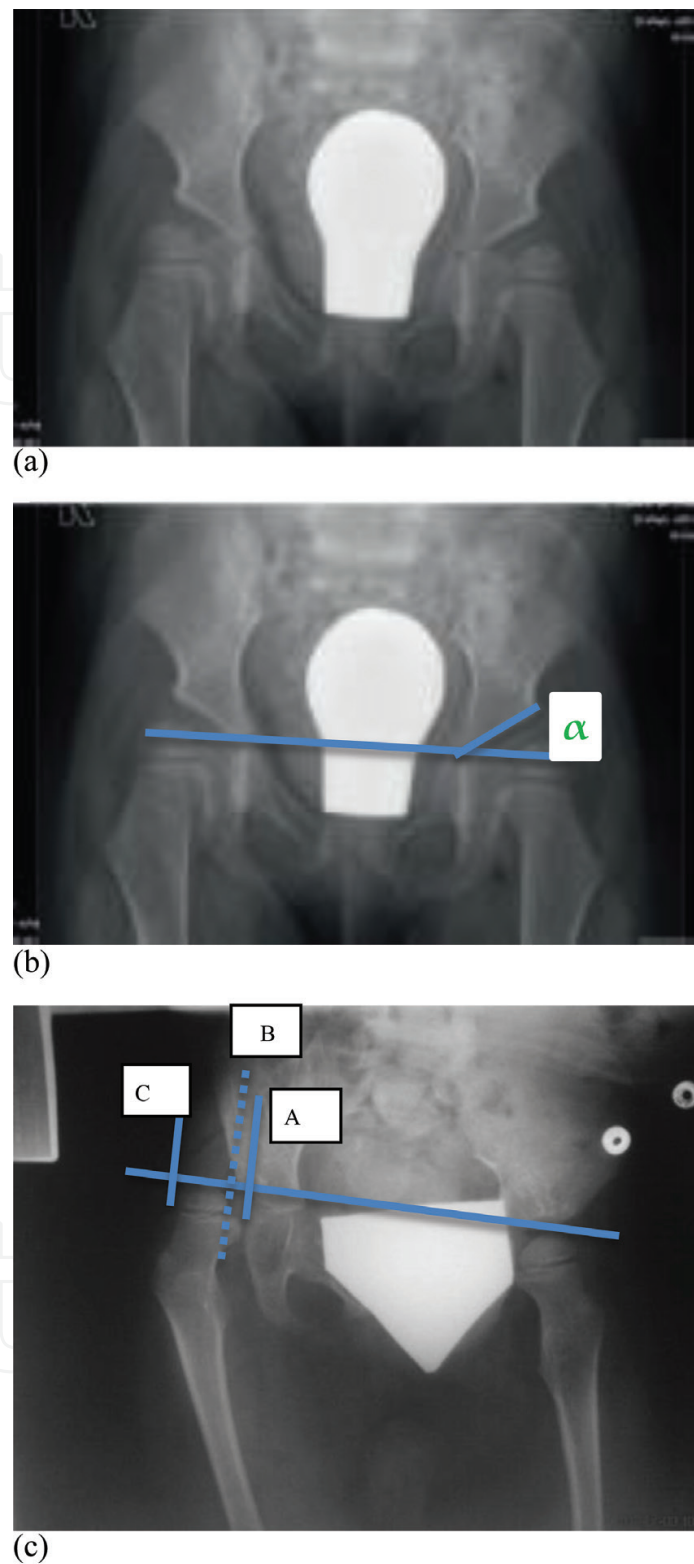
We can separate walkers and non-walkers in our exam.

For the first group, generally, the major concern is the asymmetry of the child, when walking, or the so-called femoral anteversion with a marked "in-toeing", or the progressive "crouch-gait" (primary or "iatrogenic"). These are the usual clinical figures we have to evaluate, and are often candidates for a movement analysis.

We can describe the highlights in *ambulatory/walking patients*:

- The incidence of hip abnormalities is of 7% in independent ambulators [8].
- The presence of asymmetry of range of motion (ROM) of both hips is common; tests for distinguishing adductors or ischio tibialis (Phelps' test), to detect rectus femoris shortening (Duncan-Ely's test), to detect retraction of hip flexors (Thomas' test), are important in





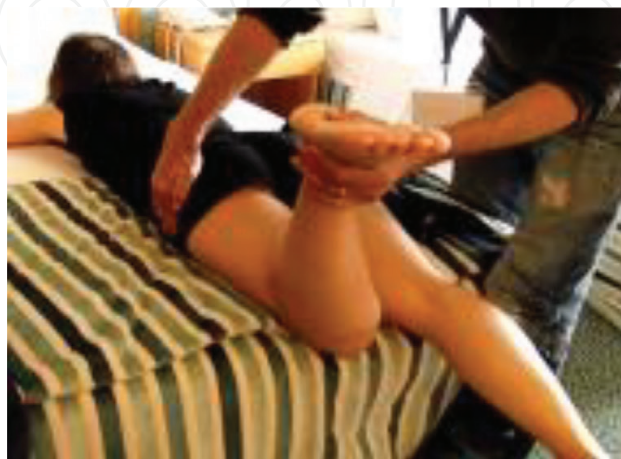**Figure 1.** (a) Bilateral head coverage insufficiency, (b) acetabular index— $\alpha$ , (c) Reimer's Index:  $\frac{BC}{AC} \times 100 = X\%$ .

these patients; some knowledge is needed to make tests at different speeds, countering the spasticity of the limb, and trying to evaluate real articular ROM or making a differential diagnosis between muscle contracture and muscle shortening.



- Diagnosis of a true anatomic anteversion can be prone to confusion; there are two major clinical tests to evaluate the femoral anteversion (1) palpation of great trochanter in prone position—the angle between vertical plane and plane of tibia when trochanter is more palpable, gives us the anteversion of femoral neck (**Figure 2**); (2) difference between hip internal rotation and external rotation angles), but some errors occur because of muscle shortening/retraction, or anomalies of acetabular orientation, or unusual pelvis positioning can give a “false” clinical diagnose of anatomic anteversion; there are studies with 3D CT scan and more recently with EOS® imaging (“this system takes simultaneous anteroposterior and lateral 2D images of the whole body and can be utilized to perform 3D reconstruction based on statistical models”) [9], which confirm some cases of incongruity between clinical exam and true anatomy. A final exam under anesthesia can confirm (or modify) our pre-determined strategy and surgical planning for each case
- Dealing with patient and family expectations is generally more difficult with walkers. Among the factors that may affect this are: greater awareness of the concept of self-esteem and social difference among less disabled patients; an unrealistic focus on minor, “almost esthetical” details; or “border” cases. Additionally, expectations change dramatically in some type III GMFCS cases where the patient may lose the ability to walk when they reach adolescence (because of a gain of body weight and loss of relative strength, and simultaneously, because a wheelchair can free their hands when they abandon crutches). It is important to distinguish between anatomic bony deformities (femoral anteversion, tibial torsion, and foot equinus versus cavus and/or adductus) and major muscle imbalance, which can be reducible clinically by slow counteracting of affected muscles, or even under anesthesia. It is critical to locate precisely the true causes of clinical status, because of child/family expectations and also for surgical reasons (correct indications). Despite the best intentions, an incomplete and incautious evaluation can be responsible for severe unplanned complications.

For the group of *non-ambulatory/non-walking patients*, the orthopedic goals are simpler: it must be clear that the main purposes are to treat pain, to permit hygiene and sitting in the best conditions and, sometimes, to permit positioning in a standing-frame. A proper screening program and adapted interventions should avoid hip dislocation and subluxation, but,



**Figure 2.** Palpation of greater trochanter, to evaluate femoral anteversion.



unfortunately, these diagnoses are still usual, at different degrees. So, evaluation must be directed, with the cited clear goals in mind:

- The incidence of hip abnormalities is of up to 60% in non-independent sitters [8].
- Passive abduction of less than 40° with the hips in flexion should raise a suspicion of hip instability. Dislocation can be suspected by leg-length discrepancy, but early subluxation is difficult to assess by physical examination [10].
- The clinical exam follows the usual steps; in these very disabled patients, there is an association between hip dislocation, spine deformities, and pelvic obliquity. We have particularly challenging clinical tests to try to understand the main concerns of each situation and their close inter-relationship warrants continuing analysis [10]. Sometimes, the pelvis obliquity is so important (due to spine deformity) that it promotes hip hyper adduction and, then, dislocation. Sometimes the problem begins in hip hyper adduction that promotes pelvic obliquity and scoliosis that turns structural, with progressive aggravation. There is some discussion about this concern [10, 11] but we do not have clear guidelines to predict the evolution for each case, even though we know that about 75% grade IV-V GMFCS patients will develop a scoliosis during their lives [7].
- The discussion still remains about whether or not to treat a contralateral hip apparently normal at the time of the dislocated hip reduction. So, much care should be taken during exam: once more, relations between both hips, pelvis and spine are evaluated and noted, muscular tests are also done, and close follow-up is mandatory to have a clear sense of the progression/evolution of the clinical status over time.
- The information provided by caregivers is fundamental. It can help to decide the priority between spine and hip treatment.
- In certain cases solving pelvic obliquity does not mean a sure hip protection [7], as demonstrated by cases of secondary hip dislocation after spine surgery.
- Clinically, cases that cause the greatest concern present a frank hip asymmetry (with cases of a “wind-swept” appearance of lower limbs); there are also a number of cases of “scissors” positioning of lower limbs (with a simultaneous adductus of hips, which obliges a crossing of legs). The malpositioning for sitting becomes disabling and pain becomes a major concern, as well as difficulties in carrying out hygiene tasks because of a “lack of space”. We must try to relax the patient and, with gentle but firm testing, we should try to understand if spasticity is the greater problem, or if the hip is stiff, with reduced ROM, and if there are bony deformities that are insurmountable.

### 3. Planning—treatment strategy

When we plan our therapeutic approach, a wide range of data must be present: clinical (orthopedic concerns and also globally medical ones), radiographical, eventual gait laboratory analysis data, if available, time progression, and patient care (feeding, medication, orthoses, transports, and physiotherapy).



In this particular field of CP patients, one of the primary challenges for surgeons is the uniqueness of each case. There are very tiny nuances that can change the expected outcomes for a certain kind of disability or abnormality. Therefore, we must be very systematic and cautious in our analysis and treatment decisions.

There is generally a crescent therapeutical approach to these patients: first non-surgical (physiotherapy, occupational therapy, splints, orthoses, positioning, botulinum injections, and oral anti-spastic medication), and later surgical (orthopedic, neuro-surgical, and oro-gastro-intestinal). Several times, the interventions are mixed to optimize results.

When a hip surgery is indicated (unbearable pain, progressive subluxation with Reimer's Index >40%, or dislocation), we differentiate three levels of intervention, depending on age and anatomical structures to correct. The first level consists of soft tissue releases intended to prevent or halt subluxation. The second level incorporates bony osteotomies and is addressed to advanced hip subluxation or dislocation, associated with acetabular and/or femoral dysplasia. In the last level, palliative measures ("salvage procedures") are indicated for the treatment of painful, arthritic, and/or dislocated hips [8].

In the first level, and in children younger than 6 years-old (Y-O), it is astonishing how acetabulum can remodel some months/years after surgery in which femoral heads were "pointed" correctly into the central acetabulum in the end of procedure. The same occurs in second level of surgery, with simple varus proximal femoral osteotomies, when optimal reduction and abduction is obtained, in younger ages (before 6–7 Y-O).

In older children, soft tissues releases have, unfortunately, inconsistent results. Sometimes, after a short period of pain relief, there are, paradoxically, cases of increasing pain; this is observed more frequently when additional treatments are not correctly followed. In rare cases, where hips are on external rotation, even wide external rotators tenotomies have a high rate of recurrence, and are very difficult to deal with. Positioning, orthosis, and anti-spastic medication are fundamental, in association with physiotherapy to obtain better results.

In walking patients, incidence of hip subluxation or luxation is very low but, when it happens, reduction should be "perfect" with acetabular and femoral osteotomies and concentric reduction, with a good global pelvic balance.

In non-ambulatory patients, generally with huge asymmetry of pelvis, we can discuss what kind of intervention should be done in children between 6 and 12 years (sometimes older, if really immature).

It is generally accepted that, when it is not reducible under anesthesia with simple procedures (tenotomies), we have to reduce the hip with "heavier" techniques; the standard procedure is the so-called varus derotation osteotomy (VDRO) of the proximal femur; it consists in varus osteotomy (nowadays we try to reach a final cervico-diaphyseal angle of ~120°) combined to a derotation of excessive femoral anteversion (the final angle depends on the grade of GMFCS; in very disabled children, we can hyper-rotate externally distal femur, so that the weight of the lower limb counteract the internal rotational spasticity torque).

But, of critical importance is the simultaneous shortening of femur, allowing a hip reduction in abduction without any stress, during the procedure; if this criterion is not fulfilled, the risk of recurrence is much higher and a rather early clinical deterioration can occur.



There is also some discussion about simultaneously performing acetabuloplasty to correct the usual and particular development hip dysplasia in this neuro-muscular context.

There are several anatomic situations: sometimes you find a long shallow acetabulum, with a high acetabular index ( $>30\%$ ), without any depth to stably receive the reduced femoral head; sometimes, there is a "neo-acetabulum" separated from the original by a kind of smooth crest, but the original acetabulum has enough depth to achieve a certain intrinsic stability, after reduction. In this last situation, the acetabuloplasty is not necessarily required.

We must remember that the addition of one more invasive intervention (pelvic osteotomy) with its immediate and late complications should be established for solid reasons. Complications of the combined single-stage reconstruction include infection, avascular necrosis, femoral fractures, and premature closure of the triradiate cartilage. The avascular necrosis can occur from injury to the femoral head circulation during the open reduction, injury to the medial circumflex artery with iliopsoas release, or increased pressure between femoral head and acetabulum [8]. Theoretically, the acetabuloplasty is meant to "normalize" acetabular index and only can be done while the triradiate cartilage is still open ( $<11\text{--}12$  Y-O maximum, for some authors). Some authors advocate adding this procedure in a one-stage procedure with VDRO, to achieve better hip stability. According to these authors, from patients who had VDRO alone, 25% needed revision procedures and none of the combined group needed other procedures [11], and they conclude that "the clinical and radiologic results obtained by the one-stage procedure were far better than doing VDRO alone justifying a more extensive approach".

One type of associated procedure is rarely discussed in literature: it is the shortening capsuloplasty. This technical point could make a significant difference in the hip stability outcome in severe patients with highly dysplastic acetabula. The technique consists of, after totally freeing the acetabulum (transverse ligament, ligamentum teres, inferior excision of joint capsule and of pulvinar) and confirming that the femoral head can be lowered completely in anatomic position, shortening of the superior joint capsule with a mattress Mayo type suture, sometimes through the labrum or even the superior bony acetabulum, in order to make an obstacle to head re-dislocation (**Figure 3**) [12]. The inferior flap will occupy space inside the articulation, lowering the femoral head more; the hip capsule is used as the interposition material between the femoral head and the deformed acetabulum. In time, the capsule undergoes metaplasia and fibrocartilage mimics the function of articular cartilage. Intrinsic stability can be confirmed with an intra-operative hip radiograph in full adduction.

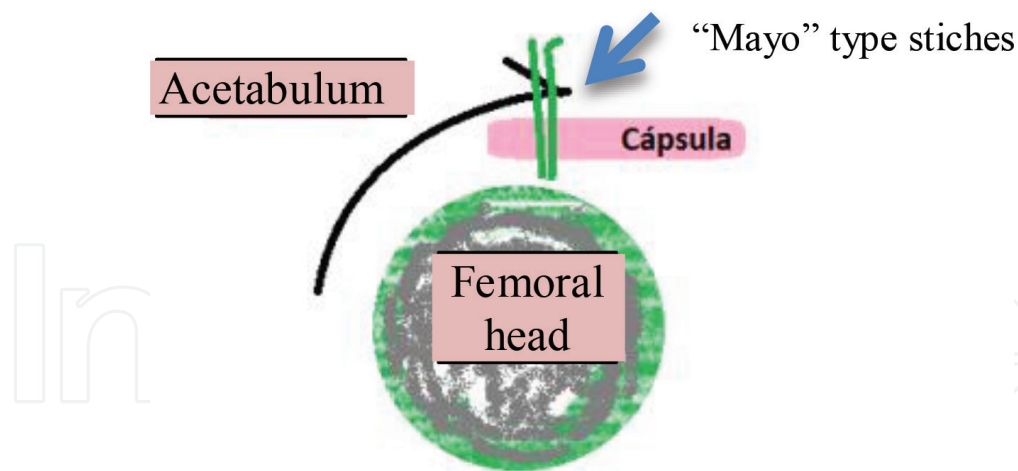
This is an important matter; in practice, the purpose is to correctly reduce the hip so that it will remain stable and painless throughout the years, with a minimum of complications.

In our practice, if we can avoid acetabular gesture with capsulorrhaphy and a VDRO with enough shortening, that is our preference; but if the stability is not sufficient and the triradiate is still open, we join a Dega osteotomy.

It is important to level both hips as best we can, and, sometimes, we have to perform tenotomies (or even reorientation osteotomies) of the contralateral side.

Another associated procedure is the neurectomy of the obturator nerve. Although we do not perform this technique, Valencia describes the technique: "the anterior branch of the obturator nerve lies on the anterior surface of the adductor brevis. Historically, division of the nerve





**Figure 3.** Mayo type capsulorrhaphy double “matress” stitches; capsula is shortened and occupies the “void” of deformed superior acetabulum.

had been used as an adjunct to reduce the recurrence of an adduction contracture, but has been associated with creation of an abduction contracture after surgery. It is difficult to delineate whether the neurectomy, overly aggressive tenotomies, or prolonged abduction splinting is the cause of this complication. Although a neurectomy is no longer advocated, the author has used temporary interruption of the signal with a crush neurectomy in non-ambulatory settings without leading to an abduction-posture complication. Phenol can also be placed directly on the nerve at the time of surgery” [7].

Discussing treatment options for children with major disabilities at the end of their growth, the primary criterion is pain; only ~50% of dislocated hips will be painful, and those should be treated. In these older children (>12 Y-O, with closed triradiate cartilage), we have to face several arthritic changes of the femoral head, an almost absent remodeling ability, and frequent low weight and skin problems. At times, we must choose between a hip reduction strategy and a “salvage procedure”.

In the first option, hip reduction (our preferred course of treatment), we use the procedures described previously (VDRO with femoral shortening, with or without acetabuloplasty, capsulorrhaphy, adductor, iliopsoas, and hamstrings tenotomies), and, sometimes, we have to burr osteophytes of the severely deformed femoral head (queilectomy). Robb and Brunner have shown that it is feasible to perform a peri-acetabular osteotomy (Dega type) after triradiate cartilage closure in this type of patient using the same surgical principle as when the cartilage is open [13].

Unfortunately, we usually have to face 6–12 months of a difficult post-operative period that is sometimes still painful, until a steady-state is reached where daily activities can be achieved, such as sitting and hygiene.

The second option is the “salvage procedure”: the options available are valgus redirectional osteotomy, hip arthrodesis, femoral head resection, interposition arthroplasty, and total joint arthroplasty [8]. These options may be recommended after a failed attempt of hip reduction with uncontrolled pain.



The advantage of the first option is to avoid an uncertain evolution of “salvage procedures” that can evolve to an almost fixed adduction and non-wished femur uprising, with a painful and “unfunctional” outcome. Alternatively, we have to accept the risks and difficulties of a total hip prosthesis in a spastic and “uncontrollable” patient. But, sometimes, this can be the last solution.

In summary, a fluxogram is proposed, trying to integrate some different nuances of these complex questions.

### 3.1. Proposed algorithm

#### 1. For hip subluxation, dislocation

- <6 Y-O sub-luxated hip(s) Reimer’s Index between **40** and **60%**, **reducible** after adductor tenotomy alone → adductor tenotomy alone + > 1 month abduction cast/splint.
- <6 Y-O sub-luxated hip(s) Reimer’s Index between **40** and **60%**, **NOT reducible** after adductor tenotomy alone → adductor tenotomy + medial hamstrings tenotomy + varus proximal femoral osteotomy (centralizing head in acetabulum) + > 1 month abduction cast/splint.
- <6 Y-O sub-luxated hip(s) Reimer’s Index >**70%**, **NOT reducible** after adductor tenotomy alone → adductor tenotomy + varus and shortening proximal femoral osteotomy (centralizing head in acetabulum or, if not possible, open reduction + capsuloplasty) + > 1 month abduction cast/splint.
- 6 Y-O sub-luxated hip(s) Reimer’s Index between **40** and **60%**, **reducible** (rare cases) after adductor tenotomy alone → adductor tenotomy alone + (thinking about shrinking capsuloplasty) + > 1 month abduction cast/splint.
- 6 Y-O sub-luxated hip(s) Reimer’s Index between **40** and **60%**, **NOT reducible** after adductor tenotomy alone → adductor tenotomy + iliopsoas tenotomy + medial hamstrings tenotomy + varus, derotation proximal femoral osteotomy (centralizing head in acetabulum) + Dega Osteotomy if triradiate cartilage open and very shallow acetabulum + > 1 month abduction cast/splint (try to operate at 8 Y-O or more, to reduce recurrence rate).
- 6 Y-O sub-luxated/dislocated hip(s) Reimer’s Index >**70%**, **NOT reducible** after adductor tenotomy alone → adductor tenotomy + medial hamstrings tenotomy + iliopsoas tenotomy + open reduction + varus, derotation and shortening proximal femoral osteotomy + Dega Osteotomy if open triradiate cartilage and very shallow acetabulum + reduction capsuloplasty + > 1 month abduction cast/splint (try to operate at 8 Y-O or more, to reduce recurrence rate).
- 10 Y-O sub-luxated/dislocated hip(s) Reimer’s Index >**70%**, **NOT reducible** after adductor tenotomy alone and sometimes with arthritic deformity → adductor tenotomy + medial hamstrings tenotomy + open reduction (queiloplasty) + varus, derotation and shortening proximal femoral osteotomy + reduction capsuloplasty + > 1 month abduction



cast/splint—NB—Dega Osteotomy is to consider, even with closed triradiate cartilage [14], if very shallow acetabulum and reduction is not enough after capsuloplasty, when you accept higher risk of complications.

- 12–14 Y-O (completely mature) sub-luxated/dislocated hip(s), with Reimer's Index >70%, **NOT reducible** after adductor tenotomy alone and with arthritic deformity.
  - (First option) adductor tenotomy + medial hamstrings tenotomy + iliopsoas tenotomy + open reduction (queiloplasty) + varus and shortening proximal femoral osteotomy + reduction capsuloplasty + > 1 month abduction cast/splint—NB—you can also consider Dega Osteotomy even with closed triradiate cartilage if very shallow acetabulum and reduction is not enough after capsuloplasty OR
  - (Second option, after painful failure of previous attempt of hip reduction) “salvage procedure”, per example, Mc Hale procedure: it is a 90° proximal femoral valgus osteotomy with suture of distal ligamentum teres to lesser trochanter to avoid subsequent femoral uprising.
- 2. For hip internal rotation (sometimes associated to knee flexed and foot equinus varus, in diplegic patients)
  - Concerning only the hip, in this chapter: sub-trochanteric external rotation osteotomy with plate (leaving ~30° passive internal rotation) in children or diaphyseal external rotation osteotomy with a nail in adolescents, in order to permit early standing. Usually, intertrochanteric osteotomy is proposed [7, 8], but, in walking patients, there is a risk of an further femoral head subluxation because of the continuous action of hip rotators muscles, and namely iliopsoas; after post-operative healing, its spastic action continues, forcing hip internal rotation, contributing for further dislocation. I believe that immediate sub-trochanter osteotomy (instead of intertrochanteric) is safer in the long-term evolution.

#### 4. Technical tips

The purpose of this chapter is to summarize tips used to face some technical challenges in CP hip surgery.

First, we cannot plan a procedure correctly without an accurate previous evaluation. There are several moments (in CP cases) where we can easily have a false perception of reality, and some of those points are discussed below.

Second, the surgery planning is the moment where we try to imagine the surgical approaches and the technical steps we will have to fulfill and what eventual orthopedic materials and respective ancillary equipment we will need to achieve our osteosynthesis. Sometimes, even the enterprises who sell orthopedic material have their own technique manuals not adapted to the specificity of this kind of “extreme” deformities. This is also the reason for the following explanations.



Third, the main goal in hip surgery, is a correct and, if possible, concentric hip reduction; as so, a good femoral osteosynthesis is not, *per se*, enough if final hip reduction is not satisfying. Taking care to shorten femur and to stabilize the femoral head in correct position (acetabulum “cleansing”, iliopsoas distal section, acetabuloplasty, and/or capsulorrhaphy), without any residual stress in abduction, are mandatory to have a successful procedure.

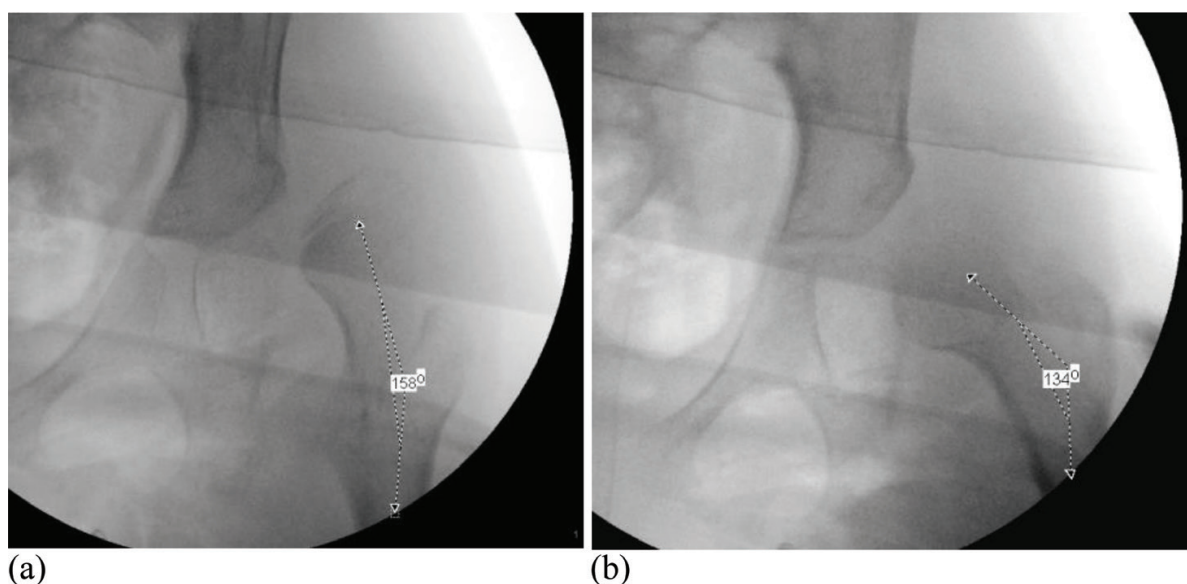
These are the technical highlights that usually can raise some theoretical and practical discussion.

#### 4.1. Correct evaluation of hip deformities

After clinical evaluation, X-ray is fundamental. However, generally the patient is awake and information is biased by malposition of patient and spasticity. Or, if we do not have access to EOS® technology [9] or an eventual 3D CT scan, a correct understanding of real bony deformities, will be achieved only by X-ray evaluation under anesthesia. After this, we can have a clear idea of the real initial state, and we can adapt our planning to reach the final state desired.

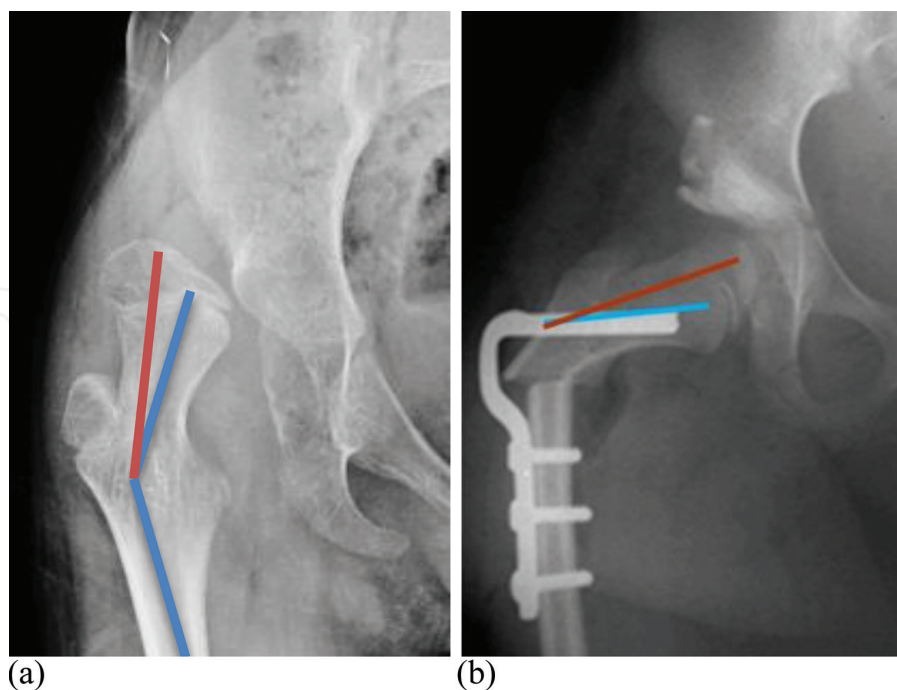
A hyper-lordosis can preclude correct evaluation of acetabulum parameters, or an excessive femur rotation can increase an impression of femoral valgus (**Figure 4a** and **b**).

Another practical and important question is the real evaluation of valgus deformity when the physis have a long period of progressive deformation. Instead of being in the continuity of the femoral neck, it is deformed in valgus, sometimes adding about 10° more in evaluation (**Figure 5a** and **b**). This notion will be important for the amount of needed correction and for the correct perception of hip reduction.



**Figure 4.** (a, b) In AP view, the cervico-diaphyseal angle is measured as a 158° valgus, but if we correct rotation of the thigh, achieving a true femoral neck AP view (the great trochanter physis is clearly viewed), we find a 134° real angle—the proximal femoral varization will be less important than planned.





**Figure 5.** (a) dislocated hip; the cervical line doesn't correspond to "head cervical" line, because of head progressive deformity in valgus, (b) post-operative reduced hip; when head is correctly reduced, we observe a bigger "true" cervico-diaphyseal angle than classically measured and an "infra leveling" of the Shenton's line.

#### 4.2. Calculation of the final angle in femoral osteotomy and bone osteosynthesis

As mentioned previously, when we plan a proximal femoral osteotomy, the goal for the inner question of the femur is to reach a final state where the cervico-diaphyseal angle (or head-cervico-diaphyseal angle, when femoral head is in valgus) is about  $120^\circ$  in the AP view, with a correction of rotation that permits about  $30^\circ$  of hip internal rotation and an eventual femur shortening, depending on the previous amount of femur uprising associated with dislocation. Sometimes, when we have a flexed hip, we can incorporate a "deflexion" procedure, adding an extension component at the osteotomy site (with a corresponding slope for the plate positioning).

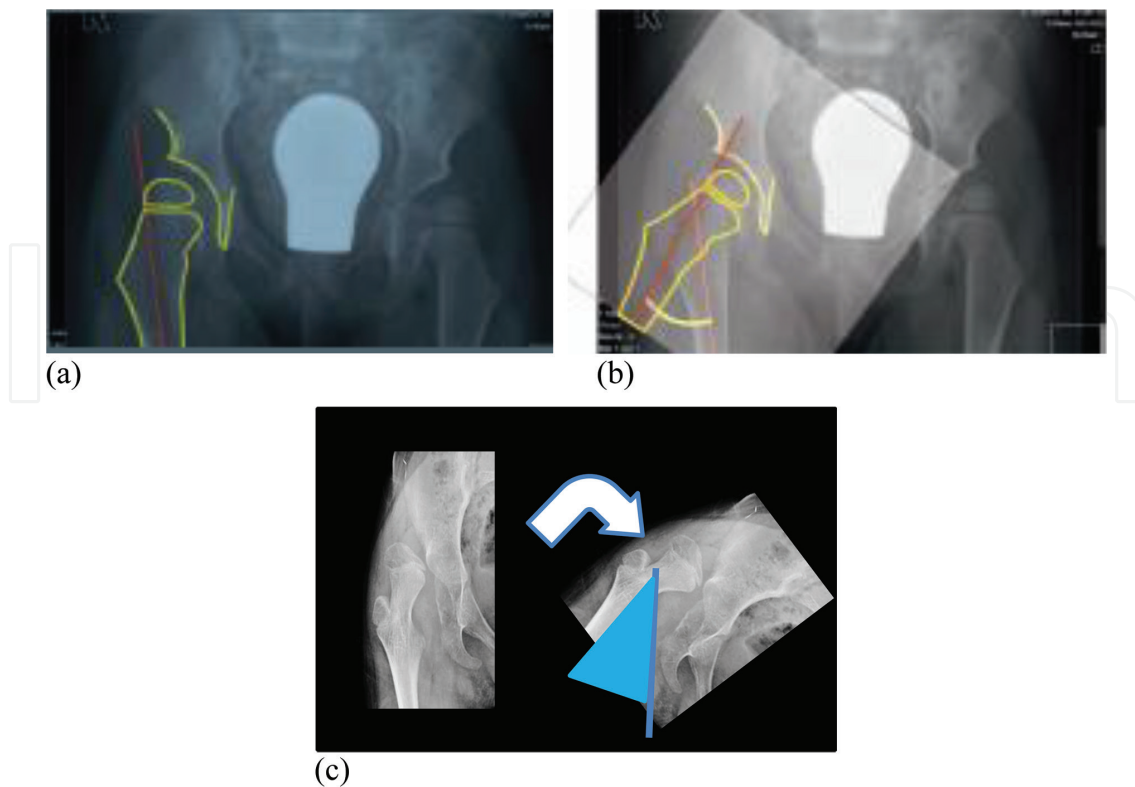
There are several materials we use to achieve a correct osteosynthesis—straight plates, angled blade plates, angled screw plates, Altdorf plates, and others. Age, weight, bone density, need of external contention (splints, casts), and surgeon experience, impact the implant choice for each patient.

For the correction of femoral proximal valgus, we have to calculate the amount of varization we need. There are several ways to calculate it: we can use a goniometer and an X-ray transfer (always remembering that correction is made more accurately after evaluation under anesthesia), measuring the angle between initial valgus and final planned position, just rotating image/transfer (**Figure 6a–c**). We can also plan the angle of entrance of our guide wire (when we use an angled plate for our osteosynthesis), using the following formula:

$$\text{initial angle} - \text{final (pretended) angle} + \text{plate angle} = \text{guide wire angle}$$

In this formula, the *initial angle* is the real valgus of the patient, the *final angle* is about  $120^\circ$ , the *plate angle* depends on angle availability in the equipment we are using (and decision





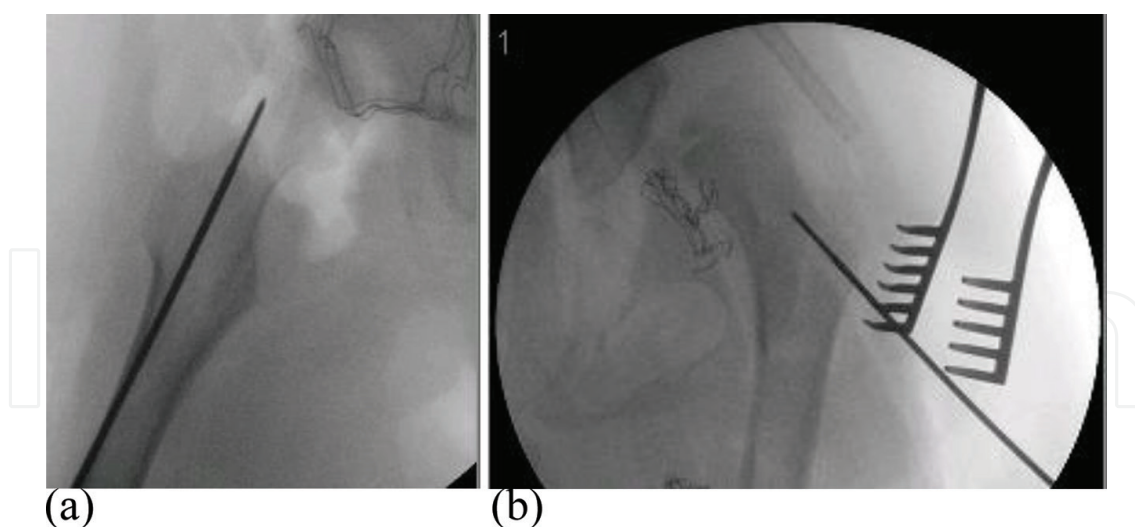
**Figure 6.** Planning varus osteotomy with a transfer; we measure the angle between initial (a) and the final (b) correct position we pretend, and it corresponds to the amount of varus needed, (c) planning varus osteotomy with a simple rotation of the X ray: we measure also the angle between initial and final correct position we pretend; it corresponds to the amount of varus.

regarding the point of entrance on lateral femur), and *guide wire angle* is the angle of entrance in femur which should be adjusted using the equipment pointer.

A third strategy can be employed to insert the guide wire and is based on the following technical assumptions: when we use the equipment pointer to insert the guide wire in cases of significant valgus ( $>140^{\circ}$ – $150^{\circ}$ ), the off-set provoked by the thickness of the metal piece gives us a worse result than planned (the osteotomy will be too far, causing the plate to be too lateral); another assumption is that soft tissues can interfere in the guide wire and pointer orientation when we have very “vertical” orientation of the guide wire and a huge femoral internal rotation; even so, if we know that we want a final head-cervico-diaphyseal of about  $120^{\circ}$ , and that there is an angle of about  $10^{\circ}$  between cervical line and real head cervical line (when femoral head is deformed in valgus). So, if we insert the guide wire by free hand, parallel with the femoral neck, and if we use a  $110^{\circ}$  plate, we will reach a final angle of  $120^{\circ}$ . Given the real constraints of soft tissue during surgery, it is easier to find the correct point of entrance for the wire using this technique (**Figure 7a** and **b**).

Before we make the osteotomy, we have to make marks on the femur, so that we can have clear indicators when we achieve the final state after osteosynthesis. To avoid rotation errors, we can mark the bone, inserting Kirschner wires, above and distally to the osteotomy line (sufficiently far to not interfere with the plate placement), or marking the bone, for example, with a vertical superficial line made with a chisel or a saw, long enough, because of eventual femur shortening at the osteotomy site, once more, far from the location where the plate is

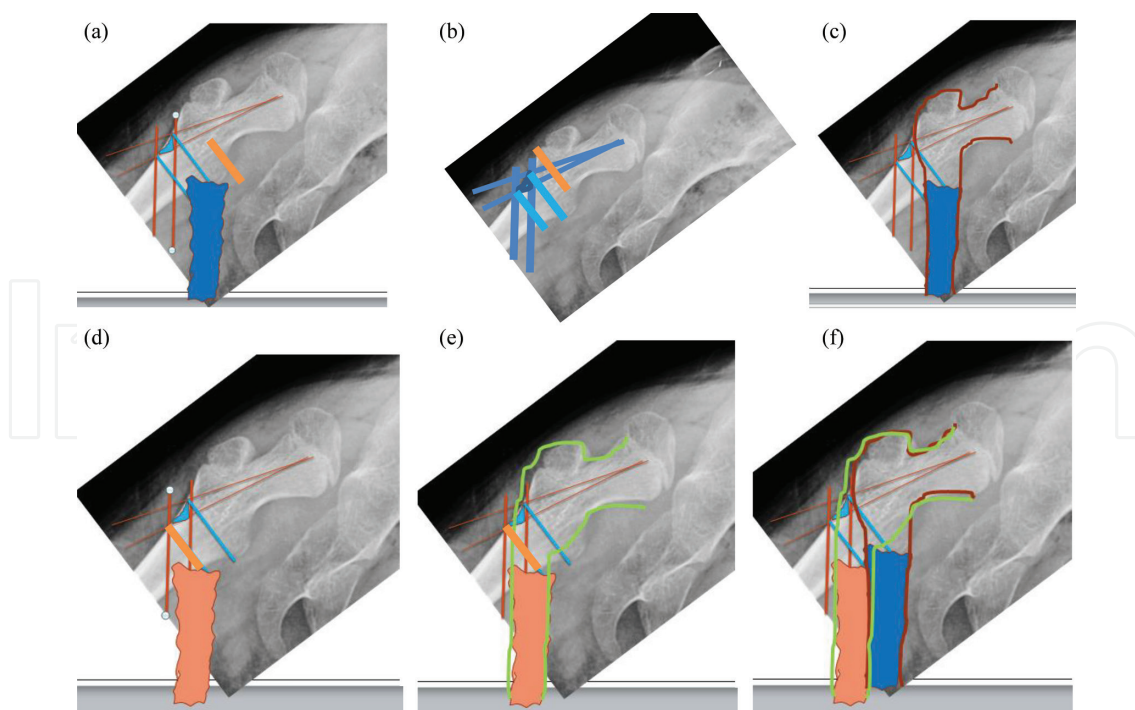




**Figure 7.** (a, b) Profile and front guide wire correct insertion.

going to be screwed. At the site of the osteotomy, we try to detach and preserve periosteum so that it contributes to a good consolidation, in particular when the initial valgus is very important and respective correction implies some significant off-set of the proximal femur and risk of late pseudarthrosis. In these cases, the adjunction of an auto graft seems wise.

Now we discuss the entry point for the plate; as we can see in **Figure 8a**, we can imagine different entry points in function of the angulation of the plate. For example, we have planned

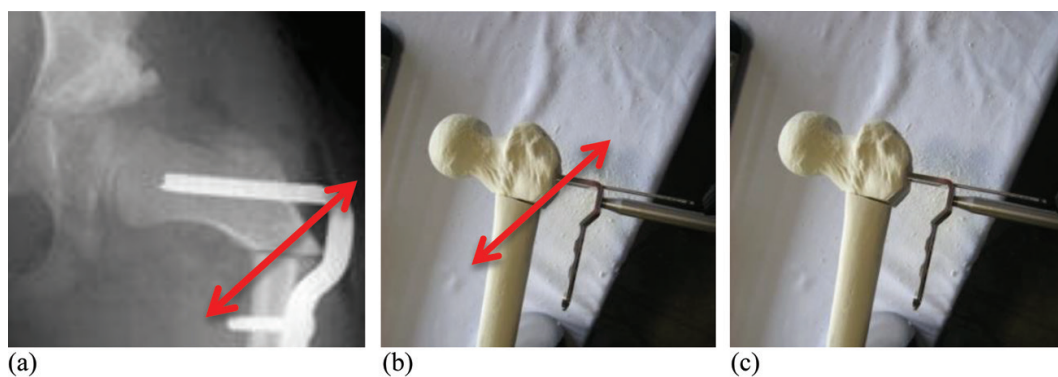


**Figure 8.** (a) Different entry points of the guide-wire, in function of the angulation of the plate, (b, c) more proximal femur osteotomy and achievement of a final balanced result, (d, e) slight more distal osteotomy and achievement of a final "Shepherd's crook", (f) comparison of anatomic final results in function of the osteotomy level.

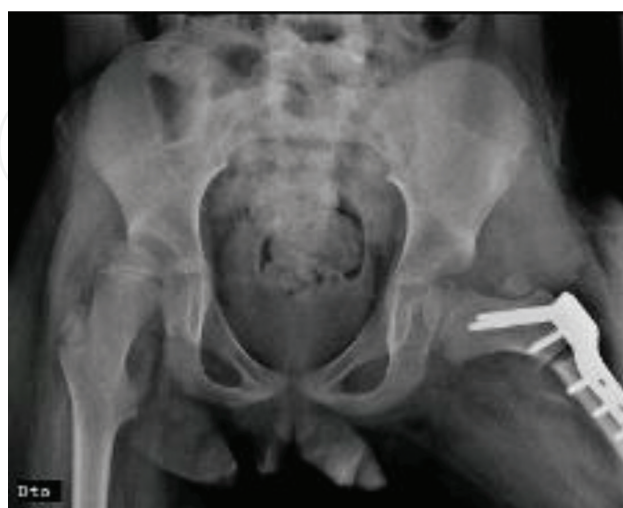

a 100° [upper line (**Figure 8a–c, f**)] or a 110° [lower line (**Figure 8a, d–f**)] angled plate. The difference of the two entry points implies an osteotomy almost 1 cm more distal in the second option. If we are not aware of this issue, it is easy to make an osteotomy that is too distal which negatively affects hip's Pauwels' balance [15]. In the latter option, we risk obtaining a "Shepherd's crook"-like femur instead of a balanced hip (**Figure 8d–f**). It is not a rule to choose plates with lower angles because, sometimes, they reach the lower femoral neck or even the calcar and that is not our goal. In consequence, it is important to choose the best angulation on a case by case basis.

When we face a situation where the proximal femur lateral cortex prevents correct apposition of the plate, provoking the cited femur "shepherd's crook"-like deformity, we can cut the lateral beak, so that the plate can join completely its osseous "bed". The problem is that we will have less bone apposition between proximal and distal fragments (**Figure 9a–c**). It is advisable to preserve periosteum and to join autograft, if possible.

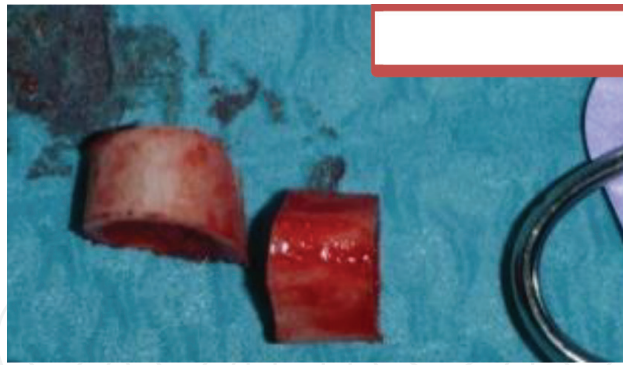


**Figure 9.** The proximal femur lateral cortex prevents correct apposition of the plate (a), provoking a femur "shepherd's crook"-like deformity; we can cut the lateral beak (b), so that the plate can join completely its osseous "bed" (c).



**Figure 10.** Femur shortening is regulated until null tension on the femoral head remains on abduction, after hip reduction; if some tension remains, the proximal femur should be more shortened.





**Figure 11.** Femur shortening, resection pieces—They can be used as auto-graft in supra-acetabular pelvic osteotomy or in the femur osteotomy site.

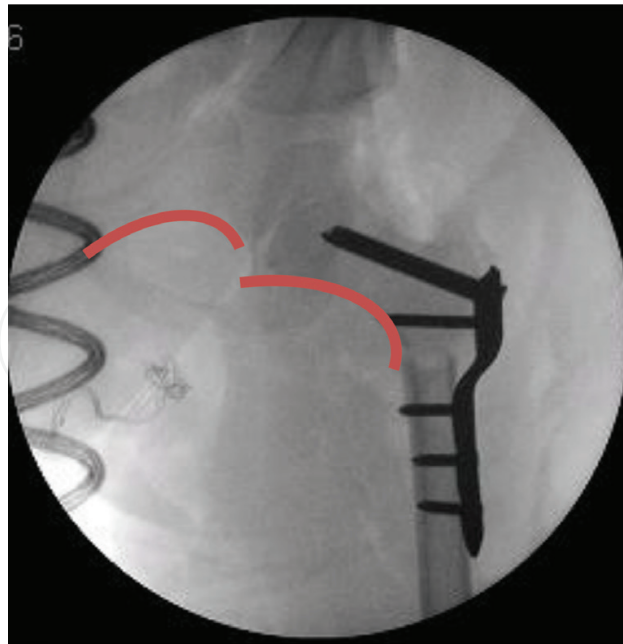
Before final screwing of the plate to distal fragment, we must be sure that hip muscle tension does not stress hip reduction during abduction. The shortening is made until null tension on the femoral head remains on abduction (**Figure 10**). If some stress remains, the femoral head has a tendency to upraise in acetabulum, or even dislocate. Sometimes we can make an important shortening, as much as 2–3 cm (**Figure 11**).

#### 4.3. Correct concentric hip reduction

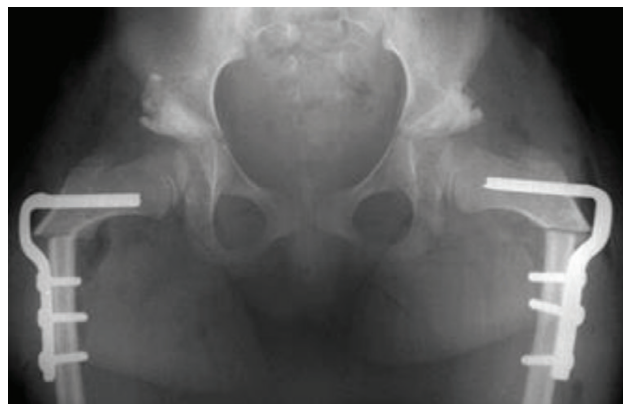
The steps used for hip reduction depend on reducibility of the femoral head; in classic spastic cases, we make an adductor (and ischio tibialis) tenotomy, and after iliopsoas tenotomy we can test if the femoral head is reducible or not; if it is difficult, we begin the proximal femoral osteotomy step of the procedure, so that we can free at maximum all of the proximal femur. With forceps, we can handle the femoral neck and trochanter and we can test reducibility and eventual stability of the head in acetabulum. We must be aware of a false sensations of reducibility, for example, in cases of head valgus deformity, which can fool us (we tend to follow the neck alignment visually and not the head location in R-ray). In these situations, to be sure that reduction is achieved, we have an “infra-leveling” of Shenton’s line (**Figure 12**) because the femoral head is well centered and the neck is below the head level, and not in continuity with it. If the head is not totally reduced, we have to open the joint capsule and cleanse all the obstacles to total reduction with special care to transverse ligament excision and freeing of lower joint capsule, permitting complete lowering of the femoral head.

As mentioned before, and depending on age (presence or not of the triradiate cartilage), depending also on anatomic profile of acetabulum, and of femoral head reducibility, we decide if we add an acetabular step [acetabuloplasty, (**Figure 13**)], reorientation procedure, shelf) or a capsulorrhaphy (cf. Section 3). A dynamic X-ray can be made at the end of the procedure to test the stability of hip reduction. The external immobilization depends on age and osteosynthesis stability. In younger children, we use pelvi-podalic casts and in older children and adolescents we use bi-cruro-podalic casts, for a period of 4–6 weeks.





**Figure 12.** When femoral head is deformed in valgus, and when hip reduction is correctly achieved, we verify a discontinuity of the Shenton's line(that is "infra-leveled").



**Figure 13.** In this case, a bilateral Dega pelvic osteotomy was added to a femoral VDR osteotomy.

## 5. Conclusions

Cerebral palsy is a particularly complex field of medical knowledge, where clinical experience is probably more important than in other fields. For that reason, trying to teach and to share some "shortcuts" about CP "thinking" with new generations of health professionals is an important and challenging concern.

The goal of this chapter is to facilitate hip evaluation and decision making for surgeons who deal with these complex problems in CP patients. Practical clinical situations were presented with a wide array of comprehensive solutions.



I hope this summary of experience and reflections about the subject will be useful for interested readers.

## Acknowledgements

This chapter has benefited from the experience and teaching of Professor José Salis Amaral. I would also like to express my gratitude to my surgical team at Hospital Dona Estefânia. A special thanks to my wife, Camille, who shares this commitment to science and to patients, and finally, my thoughts to all my family.

## Conflict of interest

The author has no disclosures.

## Author details

João Lameiras-Campagnolo

Address all correspondence to: campas64@gmail.com

Pediatric Orthopedic Department, Hospital de Dona Estefânia, Lisbon, Portugal

## References

- [1] Graham H. The orthopaedic management of cerebral palsy. In: Broughton NS, editor. A Textbook of Paediatric Orthopaedics. London, Toronto: WB Saunders Company Limited, Harcourt Brace & Company; 1997. p. 102-112. ISBN 0-7020-1962-3
- [2] Richards C, Malouin F. Cerebral palsy: Definition, assessment and rehabilitation. Handbook of Clinical Neurology. 2013;**111**:183-195
- [3] Robby J, Hägglund G. Surveillance and management of the displaced hip in cerebral palsy. The Journal of Children's Orthopaedics. 2013;**7**(5):407-413. Published Online 2013 Aug 18. DOI: 10.1007/s11832-013-0515-6
- [4] Wynter M, Gibson N, Willoughby K, et al. Australian hip surveillance guidelines for children with cerebral palsy: 5-year review. Developmental Medicine and Child Neurology. 2015;**57**(9):808-820
- [5] Gibson N. CEREBRAL PALSY The Importance of Monitoring Hips in Cerebral Palsy. Princess Margaret Hospital, Perth; July 2012



- [6] Hägglund SA, Pedersen H, Rodby-Bousquet E, Wagner P, Westbom L. Prevention of dislocation of the hip in children with cerebral palsy–20-year results of a population-based prevention program. *The Bone and Joint Journal*. 2014;**96-B**:1546-1552
- [7] Canavese F, Deslandes J, editors. *Orthopedic Management of Children with Cerebral Palsy: A Comprehensive Approach*. New York: Nova Science Publishers Inc; 2015. ISBN 978-1-63483-349-3 (E-book)
- [8] Valencia F. Management of hip deformities in cerebral palsy. *Orthopedic Clinics of North America*. 2010;**41**:549-559. DOI: 10.1016/j.ocl.2010.07.002
- [9] Melhem E, Assi A, El Rachkidi A, Ghanem I. EOS® biplanar X-ray imaging: Concept, developments, benefits, and limitations. *The Journal of Children's Orthopaedics*. 2016;**10**:1-14. DOI: 10.1007/s11832-016-0713-0
- [10] Patel J, Shapiro F. Simultaneous progression patterns of scoliosis, pelvic obliquity, and hip subluxation/dislocation in non-ambulatory neuromuscular patients: An approach to deformity documentation. *The Journal of Children's Orthopaedics*. 2015;**9**:345-356. DOI: 10.1007/s11832-015-0683-7
- [11] Senaran H, Shah SA, Glutting JJ, Dabney KW, Miller F. The associated effects of untreated unilateral hip dislocation in cerebral palsy scoliosis. *Journal of Pediatric Orthopaedics*. 2006;**26**(6):769-772
- [12] Campagnolo J, Ovidio J, Carvalho M, Jerónimo R, Guarda E. Faut-il opérer la hanche controlatérale réduite chez l'enfant paralysé cérébral à hanche luxée? Révision d'une série de 9 cas. Conférence abstract, *Revue de Chirurgie Orthopédique et Traumatologique* 2013;**99**(7):320. SOFCOT 2013, Paris
- [13] Robb J, Brunner R. A Dega-type osteotomy after closure of the triradiate cartilage in non-walking patients with severe cerebral palsy. *The Journal of Bone and Joint Surgery [British]*. 2006;**88-B**:933-937
- [14] Al-Ghadir M, Masquijo JJ, Guerra LA, Willis B. Combined femoral and pelvic osteotomies versus femoral osteotomy alone in the treatment of hip dysplasia in children with cerebral palsy. *Journal of Pediatric Orthopaedics*. 2009;**29**(7):779-783. DOI: 10.1097/BPO.0b013e3181b76968
- [15] Erceg M. The influence of femoral head shift on hip biomechanics: Additional parameters accounted. *International Orthopaedics (SICOT)*. 2009;**33**:95-100. DOI: 10.1007/s00264-008-0544-9



