

We are IntechOpen, the world's leading publisher of Open Access books Built by scientists, for scientists

6,900

Open access books available

185,000

International authors and editors

200M

Downloads

Our authors are among the

154

Countries delivered to

TOP 1%

most cited scientists

12.2%

Contributors from top 500 universities



WEB OF SCIENCE™

Selection of our books indexed in the Book Citation Index
in Web of Science™ Core Collection (BKCI)

Interested in publishing with us?
Contact book.department@intechopen.com

Numbers displayed above are based on latest data collected.
For more information visit www.intechopen.com



Early Pregnancy Ultrasound Assessment of Multiple Pregnancy

Panagiotis Antsaklis, Maria Papamichail,
Marianna Theodora, Michael Syndos and
George Daskalakis

Additional information is available at the end of the chapter

<http://dx.doi.org/10.5772/intechopen.81498>

Abstract

As the frequency of multiple pregnancies is increasing, every obstetrician has to know that the correct, accurate, and timely determination of gestational age, chorionicity, and amnionicity has significant importance in the management of a multiple pregnancy. Surveillance, complications, outcome, morbidity, and mortality are totally different in a monochorionic and a dichorionic pregnancy. In this chapter, we will present the sonographic figures that are visualized in the first trimester in a multiple pregnancy and help us define the gestational age, chorionicity, and amnionicity. We will classify them into two periods: the early first trimester, including the 10 first weeks of gestation and the late first trimester including the period between the 10th and 14th week of gestation. Finally, we will review some interesting, although infrequent, cases from the literature, showing that pitfalls in the determination of both chorionicity and amnionicity exist and highlighting the importance of being aware of their subsistence.

Keywords: multiple pregnancy, early ultrasound assessment, gestational age, chorionicity, amnionicity

1. Introduction

It is a well-established fact that multiple pregnancies occur more commonly nowadays than a few decades ago. The progress of reproductive technologies and *in vitro* fertilization has played a major role in this increase. In fact, twins comprise about 3% of all live births in the United States [1]. As we speak about history, the vast majority of multiple pregnancies that occurred

in the past were diagnosed during the intrapartum period [2]. Today, as the use of ultrasound has become a routine in daily medical practice, multiple pregnancies are diagnosed in the initial ultrasound scan [3]. Beyond the diagnosis of early multiple pregnancy, ultrasound scan is more than necessary to define chorionicity, amnionicity, and gestational age [4].

In this chapter, we will present the ultrasound figures that help us determine gestational age, chorionicity, and amnionicity, focused on the 14 first weeks of gestation in multiple pregnancies. We will also focalize the discussion on twin pregnancies, as they comprise >98% of multiple pregnancies and the vast majority of studies today include twin pregnancies [4]. Nonetheless, we will review some cases from the literature that show that situations can be a little more complicated and may lead to a false diagnosis of chorionicity and amnionicity, in order to highlight that when we manage multiple pregnancies, we have to be alert about exceptions despite being infrequent [5].

A twin pregnancy can be either dizygotic (two-third of twin pregnancies), in which two different eggs are fertilized by two different sperms, and in this case, the pregnancy is always dichorionic-diamniotic or monozygotic. A monozygotic pregnancy occurs when an egg is fertilized by one sperm, producing one embryo, which can split any time, more commonly between day 2 and day 13 after fertilization. Chorionicity and amnionicity are differentiated by the timing of embryo splitting. **Table 1** presents this differentiation and the frequency of each type of a monozygotic pregnancy [3].

2. Defining gestational age

The accurate determination of gestational age is critical for pregnancy management as it shows wherever the measurements of the fetus are in line for the estimate gestational age [4]. In addition, a correct pregnancy dating is necessary not only for the appropriate timing for screening and diagnostic testing but also for optimal scheduling of delivery [6]. For women with regular cycles, the date of the last menstrual period is used to estimate gestational age, taking into account the biological variability and correct the cycle length. For IVF pregnancies, the date of the embryo transfer has been used to define pregnancy dating. The vast majority of authors embraced with multiple pregnancies agree that during the second trimester the evaluation of gestational age is more accurate and it is statistically superior to the second trimester [4]. Moreover, there is an agreement that the parameters and formulas that have been used for dating singleton pregnancies are also accurate for dating multiple pregnancies, since studies in this area include a combination of singleton and multiple pregnancies [7–9].

Time of embryo splitting (in days)	Chorionicity	Amnionicity	Frequency (%)
2–3	Dichorionic	Diamniotic	30
3–8	Monochorionic	Diamniotic	70
8–13	Monochorionic	Monoamniotic	<1

Table 1. How the chorionicity and amnionicity are differentiated by the timing of the embryo splitting in monozygotic twins (Table is modified from Simpson L, 2015 [6]).

In the first trimester—before the 14th week of gestation—crown-rump length (CRL) is the parameter that is used in order to estimate gestational age with 5–7 days of deviation [7–9]. If there is a doubt about the reliability of the menstrual cycle or if the woman is administered late for care, a repeat scan in 3–4 weeks can be helpful to determine pregnancy dating [10].

Modest size discordance is very common in multiple pregnancies [4]. Some studies suggest that pregnancy dating must be defined by using the mean of the fetuses [11]. However, more recent studies agreed that if the gestational age is based on the CRL of the larger twin, the possibility of missing a fetus that might develop intrauterine fetal growth restriction (IUGR) is decreased [12]. Salomon et al. [13] suggested that the CRL of the smallest fetus can estimate more accurately the gestational age, if the intertwin CRL discrepancy is less than the 95th percentile, using charts from studies. An interesting finding is that if the intertwin discordance in CRL is higher than 10%, the possibility of pregnancy loss, aneuploidy, or congenital anomalies is increased [3, 14, 15].

In the second trimester, a combination of parameters is used to define pregnancy dating such as abdominal circumference, femur length, and biparietal diameter [8]. Further discussion about calculating gestational age in second trimester is beyond the scope of this chapter.

3. Defining chorionicity and amnionicity

Early and accurate definition of chorionicity and amnionicity has an undeniably determinant role in the management of multiple pregnancies, since chorionicity plays a key role in the appearance of complications: monochorionic-monoamniotic twins present the highest mortality and morbidity. There is no doubt that the continuous surveillance and the timely intervention can optimize the outcome of the pregnancy [4].

The determination of chorionicity and amnionicity is better to be done in the first trimester [4]. If chorionicity is defined in the first trimester, accuracy is extremely close to 100% and if the definition is carried out in the second trimester, correct assignment decreases to 90% [16, 17].

At this point, we will classify the determination based on gestational age, separated in two periods: the first before the 10th week of gestation and the second that includes the period from week 10 to week 14.

3.1. Before 10 weeks of gestation

Three ultrasound findings can help in the detection of chorionicity: These are (1) the number of observable gestational sacs, (2) the number of amniotic sacs within the chorionic cavity, and (3) the number of yolk sacs [4].

3.1.1. Number of observable gestational sacs

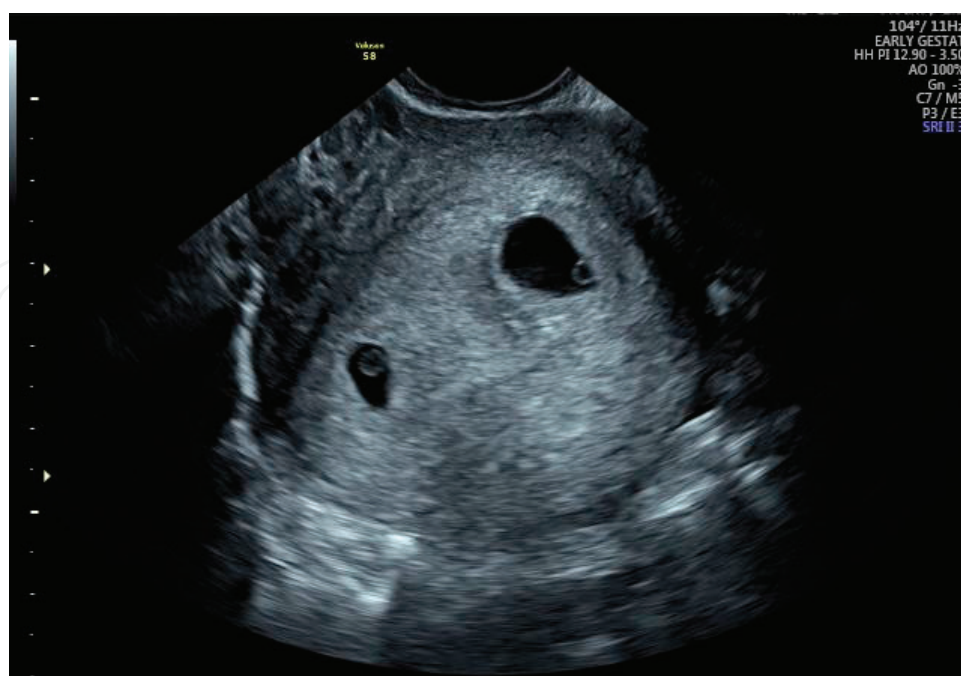The number of the gestational sacs and the number of fetal heartbeats in early multiple pregnancy scan are strongly related with chorionicity: each gestational sac will form a distinct placenta and chorion. Therefore, visualization of a single gestational sac with two visible heart beats indicates a monochorionic twin pregnancy, while the presentation of two distinctive

gestational sacs implies a dichorionic pregnancy (**Picture 1**) [18]. The number of gestational sacs is the parameter with the highest accuracy to define chorionicity which is extremely close to 100% [16].

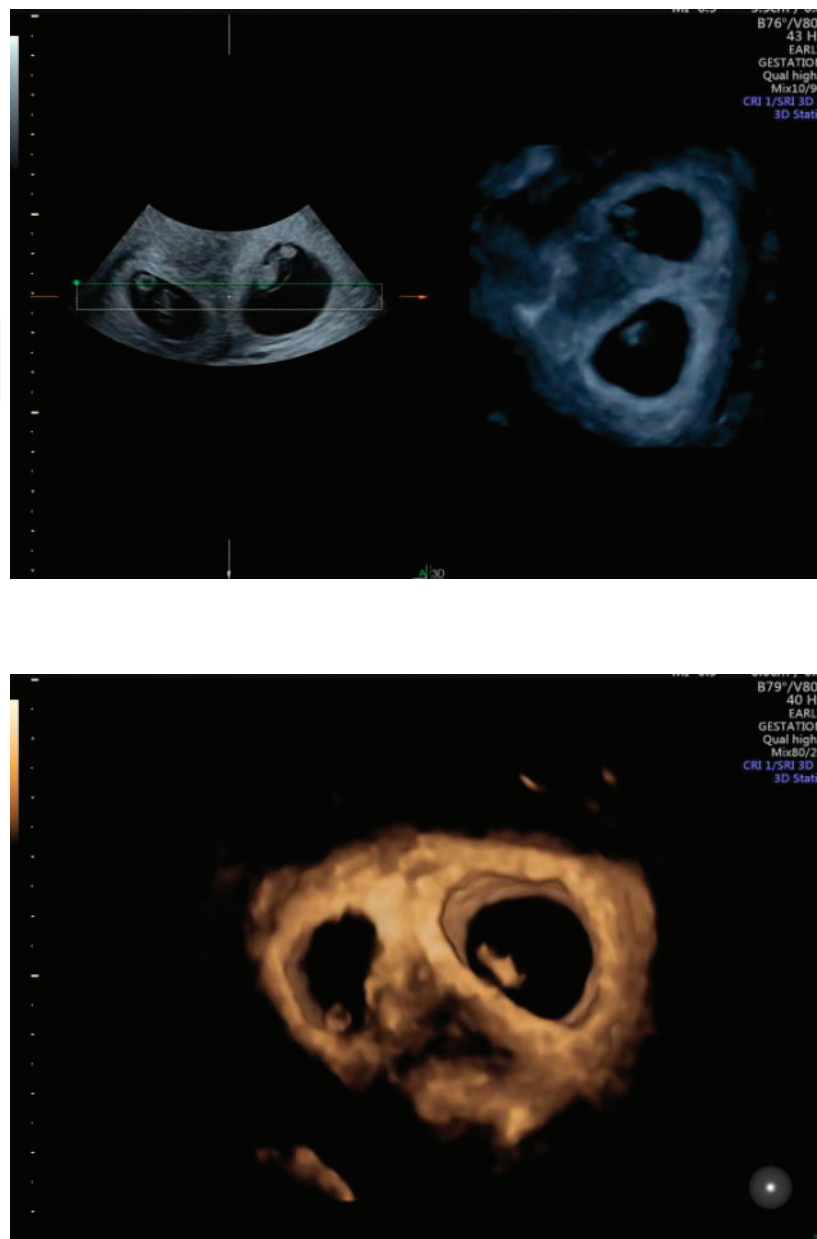
3.1.2. Number of amniotic sacs within the chorionic cavity

Identification of the number of amniotic sacs present in a single gestational sac helps define amnionicity in a monochorionic pregnancy. Prior to the 10th week of gestation, the amnions grow outward from the embryonic disk and at that age are not big enough to contact each other and create the intertwin septum [4]. As a result, separate and distinct amnions indicate a diamniotic twin pregnancy (**Pictures 2a, b and 3a, b**). The evaluation of the amnion should be done diligently via transvaginal ultrasound since the intertwin membrane is extremely thin and it may be invisible via transabdominal ultrasound. Even when the separate amnions cannot be visualized via the transvaginal ultrasound, their absence can be confirmed by demonstrating umbilical cord enlargement by using pulsed wave Doppler and identifying two distinct heart rates [3]. In addition, the impossible visualization of the intertwin membrane may be technical: if the membrane is parallel to the ultrasound beam or because the ultrasound gain is low, the membrane may be hard to evaluate. This problem can be solved by changing the angle of insonation and increasing gain facilitates visualization [5]. Another way to confirm amnionicity, wherever there is any doubt about the presence of the intertwin membrane, is to suggest a small chain of repeat scans [4].

However, is evaluation of intertwin membrane always that simple? There are two rare yet important situations that may lead to a false diagnosis of monoamniotic twins. The first case

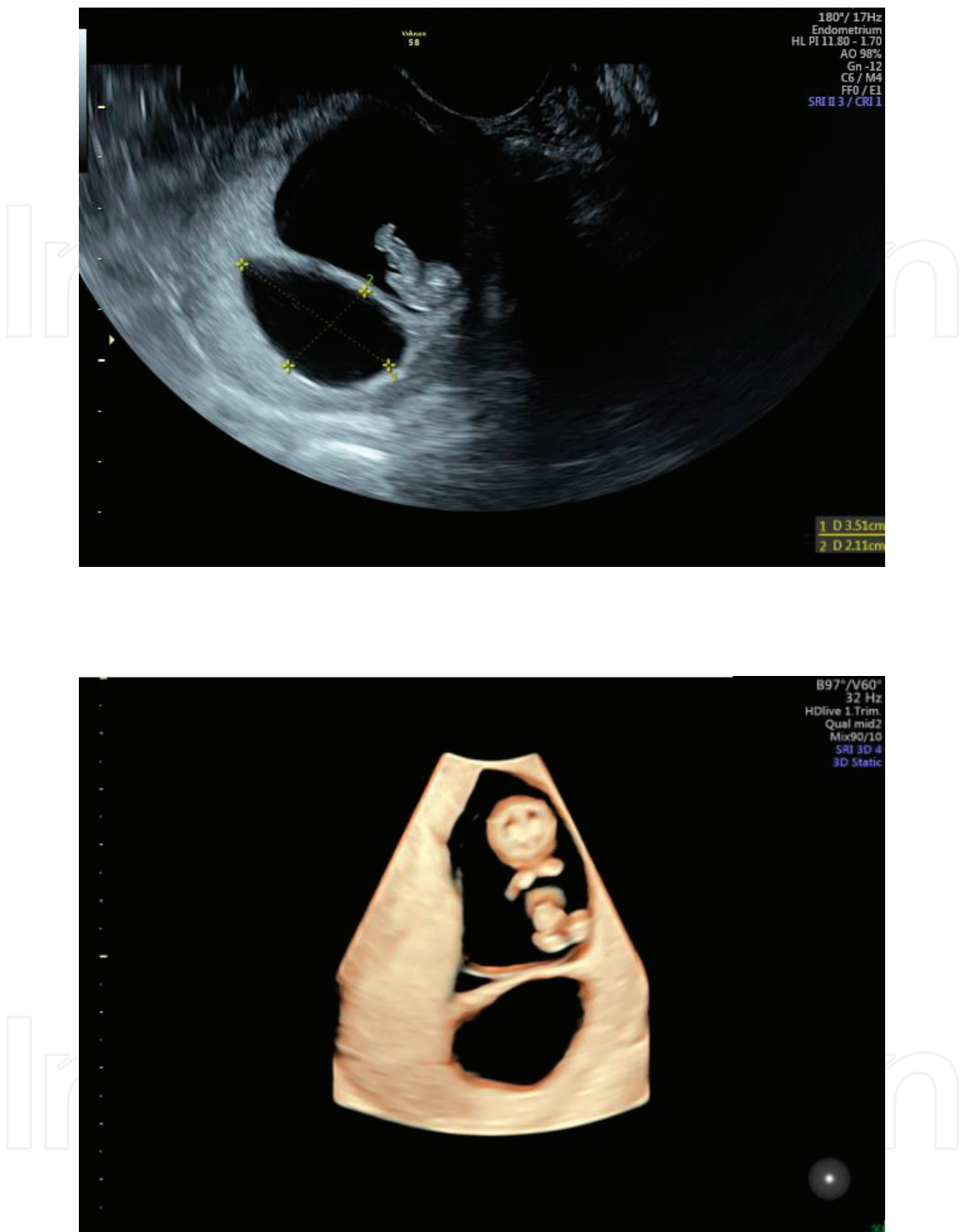


Picture 1. Dichorionic diamniotic pregnancy at 5 weeks of gestation. The two separate gestational sacs with one yolk sac each are visible and a thick septum separates them.



Picture 2. (a) 3D imaging of dichorionic diamniotic pregnancy at 6 weeks of gestation. (b) 3D imaging of dichorionic diamniotic pregnancy at 6 weeks of gestation.

is when the monochorionic-diamniotic twins are complicated with twin-to-twin transfusion syndrome (TTTS) the donor twin has severe oligohydramnios or anhydramnios, and the intertwin membrane collapses resulting in wrapping the donor twin. The collapse of the membrane can be overtaken if we evaluate extremely carefully the wrapping membrane around the limbs of the donor twin. A possible rupture of the intertwin membrane is another case that may lead to “pseudo-MA” twins. Rupture of the membrane may occur spontaneously, but more often is a complication of invasive *in utero* procedures. Discontinuity of the membrane and cord enlargement can be visualized on the ultrasound scan. Other facts helping



Picture 3. (a) Dichorionic diamniotic pregnancy with one of the pregnancies having miscarried. The size of the empty sac has been measured. (b) 3D imaging of DCDA pregnancy in which one of the sacs appears “empty” due to miscarriage.

in the identification of the membrane rupture are the location of the fetuses in the same side of the warped membrane, the equal quantity of amniotic fluid in both sides of the dividing membrane in a pregnancy, which was complicated with TTTS, and of course a previous diagnosis of a monochorionic-diamniotic twin pregnancy [5].

3.1.3. Number of yolk sacs

Over the past few years, there is an uncertainty regarding the relation between the number of yolk sacs and amnionicity. If there are two yolk sacs present in the extraembryonic coelom, the pregnancy will be regarded as diamniotic. However, a single yolk sac cannot set the definitive diagnosis of a monoamniotic pregnancy. This is well-established since it is known that the differentiation of a yolk sac and an amnion occur very close to each other in time, around 6–8 days after fertilization [5]. If a single yolk sac is detected, a repeat first trimester scan is undertaken, or a refer to a tertiary center with advanced experience in multiple pregnancies can be helpful [3, 4].

3.2. 10th–14th week of gestation

As the pregnancy continues, the ultrasound signs that help in the determination of chorionicity and amnionicity are changing: gestational sacs are now fused and the intertwin membrane is formed. As a result, four other ultrasound figures set the diagnosis of chorionicity and amnionicity. These are: (1) sex discordance, (2) distinct placentas number, (3) intertwin membrane characteristics and (4) chorionic peak sign—‘λ’ sign.

3.2.1. Sex discordance

If a male and a female fetus are identified in the late first or early second trimester, a dichorionic twin pregnancy is the rule. However, gender discordance is the biggest pitfall for the diagnosis of chorionicity. Discordant fetal sex phenotype can be present in monochorionic twins, leading to a false diagnosis of dichorionic twins.

A false diagnosis of dichorionic twins might be the result of a postzygotic sex chromosome aneuploidy. For instance, there is a 46,XY zygote which splits, but a postzygotic anaphase lag can cause the loss of the Y chromosome in one of the twins. The karyotype of one of the fetuses will be 46,XY which corresponds to a normal male fetus, while the other karyotype will be 45,XO which is a female fetus with Turner syndrome (**Figure 1**). If we want to take our example a step forward, postzygotic nondisjunction after the anaphase lag can lead to mosaicism in the monozygotic twins leading to two embryos with a variety of proportion of 45,XO and 46,XY cells. The phenotype of this individual will correspond to the amount of cells having the abnormal karyotype (**Figure 2**) [19, 20].

A sex discordance in monozygotic twins can also be caused by a trisomic 47,XXY zygote. A process known as trisomy rescue can lead to either the production of a normal 46,XY male fetus (loss of X chromosome) or a normal 46,XX female fetus (loss of Y chromosome). Hence, this mechanism causes the production of two euploids fetuses from a trisomic zygote (**Figure 3**) [21]. In addition, confusion might be caused if a 46,XY zygote splits with nondisjunction of the Y chromosome, producing a male fetus with a 47,XYX karyotype and a female fetus with a 45,XO karyotype, Turner syndrome, and female sex phenotype (**Figure 4**) [22].

Beyond sex chromosome abnormalities, sex discordance may be the result of epigenetic single gene defects in only one of the monozygotic twins, effecting testis-determining genes such as SOX9 which inhibits the expression of SRY gene [23, 24].

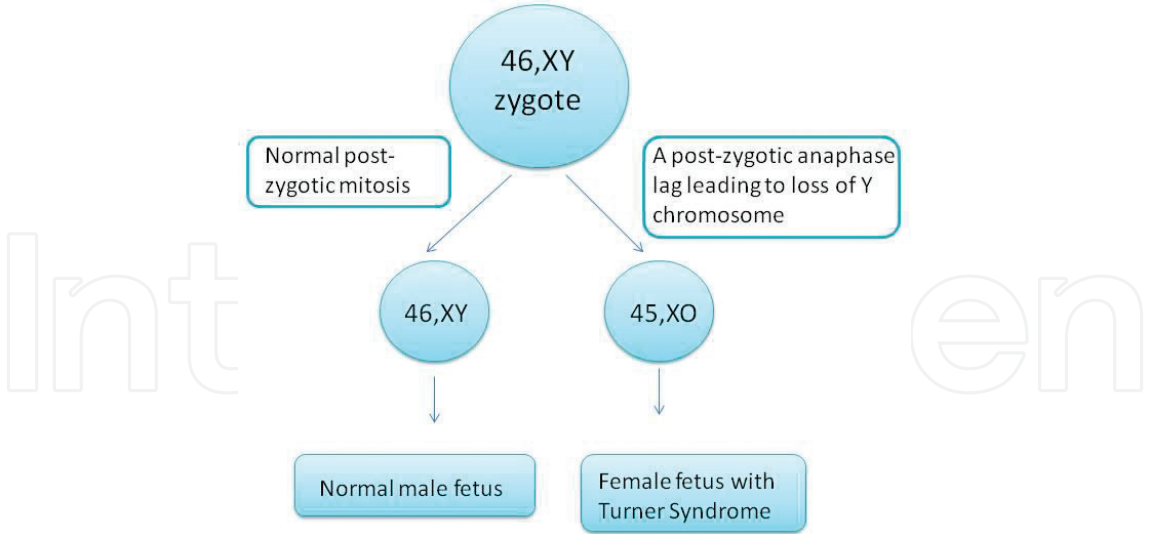


Figure 1. Postzygotic anaphase lag causing sex discordance due to loss of Y chromosome in one of the fetuses.

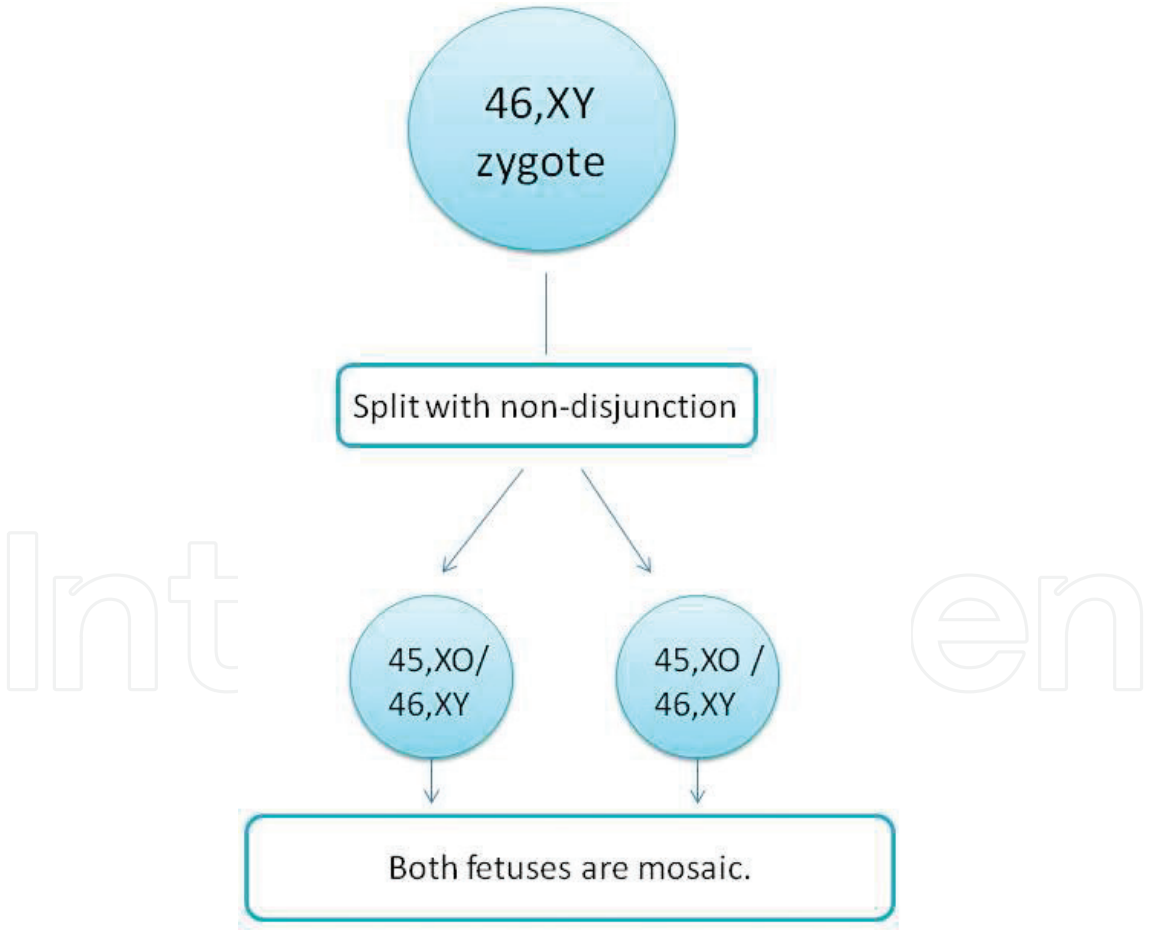


Figure 2. Postzygotic nondisjunction leading to both fetuses with gonadal mosaicism.

Nonetheless, sex discordance may be caused by malformed genitalia unrelated to chromosomal or genetic disorders. It is well established that a monochorionic twin pregnancy is complicated frequently with selective growth restriction [25], and hypospadias is a known complication of

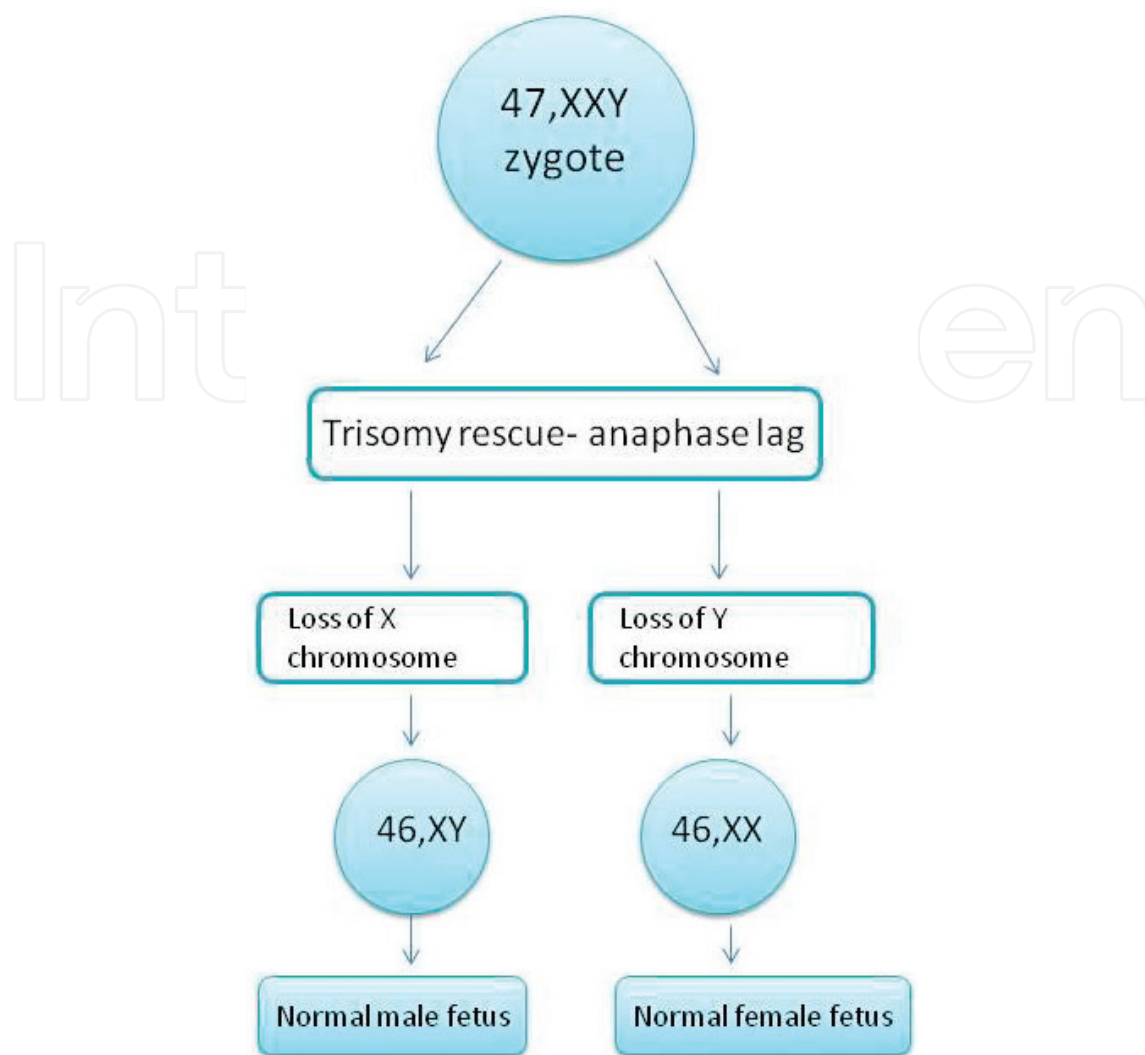


Figure 3. Trisomy rescue.

IUGR [26, 27]. As hypospadias might lead to female sex phenotype, confusion about chorionicity is expected, as the IUGR male fetus will present with female external genitalia, while the normally developing twin will be present as a normal male fetus. Cloacal malformation in one of the female fetuses (karyotype 46,XX) leads to phallus-like structure, causing phenotypically male external genitalia. The outcome is again confusion of chorionicity [28].

A very rare mechanism can cause the transverse situation: a dizygotic twin pregnancy is been diagnosed as monochorionic because of the fusion of the trophoblasts. Two distinct blastocysts produce two distinctive trophoblasts. If these trophoblasts fuse before the implantation, the result is the creation of a placental mass. The fused placenta will form vascular anastomoses, and the twins can exchange blood cells. As a result, blood chimerism of two populations of blood cells will be present in both fetuses [29, 30]. This mechanism is present more frequently in pregnancies carried out from ART because of the disruption of the zona pellucida and spatial proximity of multiple embryos [29, 31]. Dizygotic twins forming a monochorionic placenta have significant importance because these twins are genetically and phenotypically normal and they have to be distinguished from the pathological sex discordance [5].

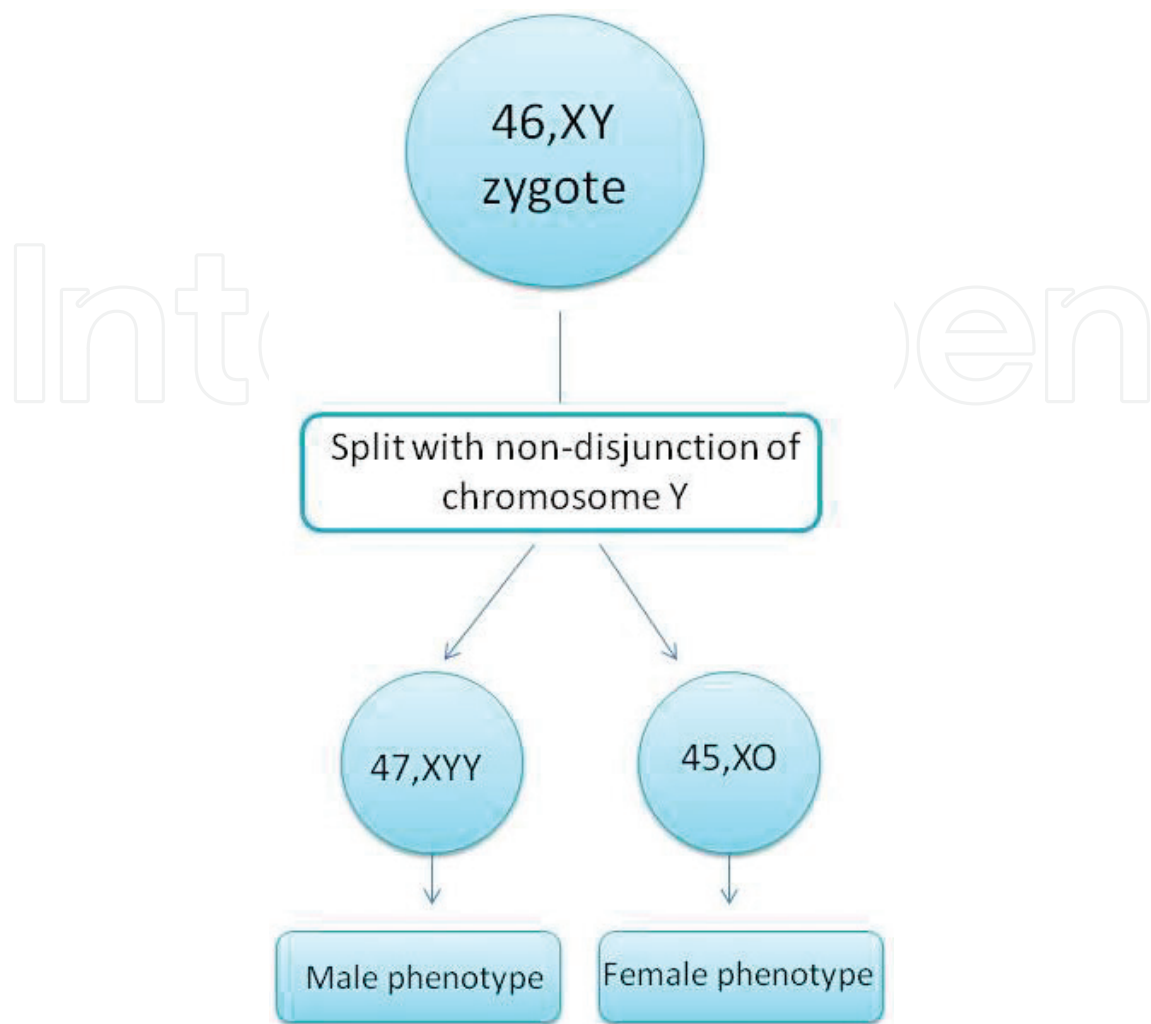


Figure 4. Nondisjunction of chromosome Y.

3.2.2. Number of distinct placentas

It is logical that the visualization of two separate placental masses confirms dichorionicity as a single placenta identifies monochorionicity [4]. Careful ultrasound evaluation has to be done in order to define the presence of a single placenta or two placentas in abutment.

As the pattern above, monochorionic twins may form a bipartite placenta. This sonographic finding is visible in 3% of monochorionic twin pregnancies. As a result, two separated placental masses are present with two nearly equal-sized placental lobes, which can be totally separated or connected by chorion laeve. Things can be more complicated when each placental mass has its own umbilical cord connection. Bipartite placenta can be distinguished from the dichorionic placental masses by using color Doppler and identifying vascular anastomoses that are present between the two lobes. Thus, this leads to the conclusion that if an ostensibly dichorionic pregnancy is complicated with TTTS, the diagnosis of a monochorionic pregnancy with bipartite placenta has to be considered [32–35].

3.2.3. Intertwin membrane characteristics

The intertwin membrane of a dichorionic pregnancy comprises three layers of three membranes: amnion-chorion-amnion, as the monochorionic pregnancy consists only two layers of amnion. Therefore, intertwin membrane in a dichorionic pregnancy is thicker and more echogenic than the intertwin membrane in monochorionic pregnancies. Measuring the thickness of the membrane can help us define chorionicity: a membrane thicker than 2 mm indicates dichorionicity (positive predictive value: 95%), and if the membrane is thinner than 2 mm, the possibility of monochorionic pregnancy is about 90% [4].

The intertwin membrane has to be carefully detected and if it cannot be visualized, a transvaginal ultrasound scan has to be performed, to set the definitive diagnosis of monoamniotic pregnancy [4]. When a single placental mass is visualized and chorionicity is identified as monochorionic, evaluation of the intertwin membrane characteristics is the key to determine amnionicity. The most significant sonographic figure that demonstrates monoamniocity is the demonstration of cord enlargement from the placental or umbilical origin and it is identified easier via color Doppler. Other important findings intimating monoamniocity are the entanglement of limbs or observation of a limb circumscribing the other, the failure to find the membrane between the two cord insertions in the placenta [4], and the short intercord distance [5].

However, intertwin membrane thickness difference between monochorionic and dichorionic pregnancy decreases during gestation [36]. In addition, the measurement of the thickness of the membrane is not widely accepted since this parameter can be affected by many factors such as the position and the quality of the probe, and as a result, it has poor reproducibility [37]. A rare but significant pitfall may lead to a wrong determination of a monochorionic pregnancy as dichorionic is the intrauterine synechiae in twin pregnancy with a fetus with anencephaly. Intrauterine synechiae can mimic the thick dichorionic membrane [38]. This septum is not the intertwin membrane and does not include the layer of chorion between the layers of amnion.

3.2.4. The chorionic peak sign—the “λ” sign

The chorionic peak sign or the “λ” sign supports strongly dichorionicity, with an accuracy of 99% [5]. It shows a projecting zone of tissue which is as echogenic as the placenta; it has a triangular shape in cross-section; and it is wider at the chorionic surface of the placenta, extending into, and tapering to a point within, the intertwin membrane [39, 40]. The absence of the “λ” sign or the presence of “T” sign indicates monochorionicity. The “T” sign represents the two opposing amnions “standing” at the base of the intertwin membrane [10].

The chorionic peak sign is ideally evaluated during the late first trimester or the very early second trimester, as in second trimester, it is more difficult to be visualized and it might be disappeared at 16–20 weeks of gestation, leading to a false negative “λ” sign. As a result, the impossible depiction of the “λ” sign in late second trimester cannot exclude dichorionicity [41, 42]. Nonetheless, a false positive “λ” sign might also exist. This can be due to umbilical cord insertion into the intertwin membrane or because of the visualization of a hematoma presented along the insertion of the membrane. Another interesting reason that may lead to

a false positive “λ” sign is the presence of an echogenic retrograded yolk sac of the placental junction of the intertwin membrane in a monochorionic-diamniotic twin gestation. The sonographic finding that succors determinate the true “λ” sign is that the true “λ” has been seen along with the whole insertion area, in contrast to the false “λ” sign, which appears in only a small region of the intertwin membrane [43, 44]. Finally, in very rare instances, the placentation may be both monochorionic and dichorionic, and each chorionicity is presented in different regions of the intertwin membrane. Therefore, the same intertwin membrane has parts with two layers of amnions and parts with three layers: amnion-chorion-amnion [45–47]. This situation shows the importance of scanning the whole insertion of the intertwin membrane in early ultrasound assessment of multiple pregnancy.

In some cases and despite the best possible ultrasound assessment, chorionicity is impossible to be defined. In these situations, the pregnancy has to be considered as monochorionic. Therefore, surveillance has to be as close as in monochorionic pregnancies [45], and this is discussed below.

4. Surveillance

Surveillance in multiple pregnancies has a significant importance, as it plays the major role in the detection of complications that are associated with a high-risk pregnancy, and it is well known that multiple pregnancy is a classic example of a high-risk pregnancy. However, the appropriate frequency of the ultrasound assessment in both dichorionic and monochorionic pregnancies, which provides the best balance between cost and effectiveness, is not be established and worldwide accepted [3].

4.1. Dichorionic pregnancies

Finberg et al. [46] suggested repeat scans every 4–6 weeks for noncomplicated dichorionic pregnancies. However, in current daily medical routine, surveillance is closer: follow-up ultrasound assessments are performed every 3–4 weeks [4, 47]. But, if a complication is suspected, and more specifically when CRL, estimated fetal weight or amniotic fluid volume are different between the two fetuses, routine scans have to be repeated every 2 weeks, or within a week [48].

4.2. Monochorionic pregnancies

It is a well-established fact that surveillance in monochorionic pregnancies has to be closer in relation to a dichorionic pregnancy. Finberg et al. [46] recommended ultrasound monitoring for noncomplicated monochorionic twins every 3–4 weeks. As the pattern mentioned previously, nowadays, routine scans are performed more frequently: they are performed every 2–3 weeks, starting from the gestational age of 16 weeks. Finally, in some cases, surveillance is even closer: a follow-up scan can be repeated every 2 weeks.

The parameters that are necessary to be evaluated in these follow-up scans are estimated fetal weight and fetal biometry, amniotic fluid volume, and Doppler assessment of the umbilical artery [49].

5. Conclusion

There is no doubt that multiple pregnancies are now more frequent than a few years before, due to the spreading of artificial reproductive technologies. Determination of gestational age, chorionicity, and amnionicity has to be done as soon as possible and ideally in the first trimester of the pregnancy, as the accuracy of the determining sonographic figures is extremely close to 100%, in contrast to the definition in the second trimester whose accuracy is slightly decreased. Last but not least, timely determination of both chorionicity and amnionicity can optimize the outcome of the pregnancy, as the correct and early intervention or a refer to a tertiary center could be really valuable.

Acknowledgements

We would like to thank Kyriaki Savva, PhD student of Cyprus Institute of Neurology and Genetics, for her comments that greatly improved the manuscript.

Author details

Panagiotis Antsaklis^{1*}, Maria Papamichail², Marianna Theodora¹, Michael Syndos³ and George Daskalakis¹

*Address all correspondence to: panosant@gmail.com

1 Alexandra Maternity Hospital, University of Athens, Athens, Greece

2 University of Athens, Athens, Greece

3 Obstetrics and Gynecology, Alexandra Maternity Hospital, Athens, Greece

References

- [1] Martin JA, Hamilton BE, Osterman MJ. Three decades of twin births in the United States, 1980-2009. NCHS Data Brief. 2012;**80**:1-8
- [2] Kurtz GR, Keating WJ, Loftus JB. Twin pregnancy and delivery: Analysis of 500 twin pregnancies. Obstetrics and Gynecology. 1995;**6**:370-378
- [3] Glanc P, Nyberg DA, Khati NJ, Deshmukh SP, Dudiak KM, Henrichsen TL, Poder L, Shipp TD, Simpson L, Weber TM, Zelop CM. ACR Appropriateness Criteria® Multiple Gestations. Journal of American College of Radiology. 2017;**14**(11):S476-S489
- [4] Morin L, Lim K. Ultrasound in twin pregnancies. Journal of Obstetrics and Gynaecology Canada. 2011;**33**(6):643-656

- [5] Lu J, Cheng YKY, Ting YH, Law KM, Leung TY. Pitfalls in assessing chorioamnionicity: Novel observations and literature review. *American Journal of Obstetrics and Gynecology*. 2018;**219**(3):242-254. DOI: 10.1016/j.ajog.2018.02.010
- [6] Simpson L. What you need to know when managing twins: 10 key facts. *Obstetrics and Gynecology Clinics of North America*. 2015;**42**(2):225-239
- [7] Kalish RB, Thaler HT, Chasen ST, Gupta M, Berman SJ, Rosenwaks Z, et al. First- and second-trimester ultrasound assessment of gestational age. *American Journal of Obstetrics and Gynecology*. 2004;**191**:975-978
- [8] Tunón K, Eik-Nes SH, Grøttum P, Von Düring V, Kahn JA. Gestational age in pregnancies conceived after in vitro fertilization: A comparison between age assessed from oocyte retrieval, crown-rump length and biparietal diameter. *Ultrasound in Obstetrics & Gynecology*. 2000;**15**:41-46
- [9] Wisser J, Dirschedl P, Krone S. Estimation of gestational age by transvaginal sonographic measurement of greatest embryonic length in dated human embryos. *Ultrasound in Obstetrics & Gynecology*. 1994;**4**:457-462
- [10] Simpson L. Ultrasound in Twins: Dichorionic and Monochorionic. *Seminars in Perinatology*; 2013;**37**(5):348-358
- [11] Chervenak FA, Skupski DW, Romero R, Myers MK, Smith-Levitin M, Rosenwaks Z, et al. How accurate is fetal biometry in the assessment of fetal age? *American Journal of Obstetrics and Gynecology*. 1998;**178**:678-687
- [12] Sebire NJ, D'Ercole C, Soares W, Nayar R, Nicolaides KH. Intertwin disparity in fetal size in monochorionic and dichorionic pregnancies. *Obstetrics and Gynecology*. 1998;**91**:82-85
- [13] Salomon LJ, Cavicchioni O, Bernard JP, Duyme M, Ville Y. Growth discrepancy in twins in the first trimester of pregnancy. *Ultrasound in Obstetrics & Gynecology*. 2005;**26**: 512-516
- [14] D'Antonio F, Khalil A, Pagani G, Papageorgiou AT, Bhide A, Thilaganathan B. Crown-rump length discordance and adverse perinatal outcome in twin pregnancies: Systematic review and metaanalysis. *Ultrasound in Obstetrics & Gynecology*. 2014;**44**:138-146
- [15] Kalish RB, Gupta M, Perni SC, Berman S, Chasen ST. Clinical significance of first trimester crown-rump length disparity in dichorionic twin gestations. *American Journal of Obstetrics and Gynecology*. 2004;**191**:1437-1440
- [16] Carroll SG, Soothill PW, Abdel-Fattah SA, et al. Prediction of chorionicity in twin pregnancies at 10-14 weeks gestation. *BJOG*. 2002;**109**:182-186
- [17] Lee YM, Cleary-Goldman J, Thanker HM, et al. Antenatal sonographic prediction of twin chorionicity. *American Journal of Obstetrics and Gynecology*. 2006;**195**:863-867
- [18] Monteagudo A, Roman AS. Ultrasound in multiple gestations: Twins and other multifetal pregnancies. *Clinics in Perinatology*. 2005;**32**:329-354, vi
- [19] Perlman EJ, Stetten G, Tuck-müller CM, et al. Sexual discordance in monozygotic twins. *American Journal of Medical Genetics*. 1990;**37**:551-557

- [20] Nieuwint A, Zalen-Sprock R Van, Hummel P, et al. Identical twins with discordant karyotypes. *Prenatal Diagnosis*. 1999;**19**:72-76
- [21] Zech NH, Wisser J, Natalucci G, Riegel M, Baumer A, Schinzel A. Monochorionic-diamniotic twins discordant in gender from a naturally conceived pregnancy through postzygotic sex chromosome loss in a 47,XXY zygote. *Prenatal Diagnosis*. 2008;**28**:759-763
- [22] Bohec C, Douet-Guilbert N, Basinko A, et al. Difficult diagnosis and management of an heterokaryotypic monochorionic twin pregnancy with discordant fetal sex and 45,X/47,XXY karyotypes. *Fetal and Pediatric Pathology*. 2010;**29**:424-430
- [23] Prior HM, Walter MA. SOX genes: Architects of development. *Molecular Medicine*. 1996;**2**: 405-412
- [24] Wolf U. Reorganization of the sex-determining pathway with the evolution of placentation. *Human Genetics*. 1999;**105**:288-292
- [25] De Paepe ME, Shapiro S, Young L, Luks FI. Placental characteristics of selective birth weight discordance in diamniotic-monochorionic twin gestations. *Placenta*. 2010;**31**: 380-386
- [26] Chen M, Macias CG, Gunn SK, Dietrich JE, Roth DR, Schlomer BJ. Intrauterine growth restriction and hypospadias: Is there a connection? *International Journal of Pediatric Endocrinology*. 2014;**2014**:20
- [27] Toufaily MH, Roberts DJ, Westgate M, Hunt A, Holmes LB. Hypospadias, intrauterine growth restriction, and abnormalities of the placenta. *Birth Defects Research Journal*. 2017;**29**:1-6
- [28] Chitrit Y, Vuillard E, Khung S, et al. Cloaca in discordant monoamniotic twins: Prenatal diagnosis and consequence for fetal lung development. *American Journal of Perinatology*. 2014;**4**:33-36
- [29] Mcnamara HC, Kane SC, Craig JM, Short RV, Umstad MP. A review of 21 the mechanisms and evidence for typical and atypical twinning. *American Journal of Obstetrics and Gynecology*. 2016;**214**:172-191
- [30] Souter VL, Kapur RP, Nyholt DR, et al. A report of dizygous monochorionic twins. *The New England Journal of Medicine*. 2003;**349**:154-158
- [31] Miura KNN. Do monochorionic dizygotic twins increase after pregnancy by assisted reproductive technology? *Journal of Human Genetics*. 2005;**50**:1-6
- [32] Lopriore E, Sueters M, Middeldorp JM, Klumper F, Oepkes D, Vandenbussche FP. Twin pregnancies with two separate placental masses can still be monochorionic and have vascular anastomoses. *American Journal of Obstetrics and Gynaecology*. 2006;**194**:804-808
- [33] Kim K, Lage JM. Bipartite diamniotic monochorionic twin placenta with 6 superficial vascular anastomoses: Report of a case. *Human Pathology*. 1991;**22**:501-503
- [34] Altshuler G, Hyde S. Placental pathology casebook: A bidiscoid, monochorionic placenta. *Journal of Perinatology*. 1993;**13**:492-493

- [35] Walsh CA, Wilkinson M, Downey P, Mooney EE, Carroll S. "False" lambda sign in monochorionic twin pregnancy. *Ultrasound in Obstetrics & Gynecology*. 2015;**46**:376-377
- [36] Townsend RR, Simpson GF, Filly RA. Membrane thickness in ultrasound prediction of chorionicity of twin gestations. *Journal of Ultrasound in Medicine*. 1988;**7**:327-332
- [37] Stagiannis KD, Sepulveda W, Southwell D, Price DA, Fisk NM. Ultrasonographic measurement of the dividing membrane in twin pregnancy during the second and third trimesters: A reproducibility study. *American Journal of Obstetrics and Gynecology*. 1995;**173**:1546-1550
- [38] Machin G. Non-identical monozygotic twins, intermediate twin types, zygosity testing, and the non-random nature of monozygotic twinning: A review. *American Journal of Medical Genetics. Part C, Seminars in Medical Genetics*. 2009;**151C**:110-127
- [39] Stenhouse E, Hardwick C, Maharaj S, Webb J, Kelly T, Mackenzie FM. Chorionicity determination in twin pregnancies: How accurate are we? *Ultrasound in Obstetrics & Gynecology*. 2002;**19**:350-352
- [40] Wood SL, St. Onge R, Connors G, Elliot PD. Evaluation of the twin peak or lambda sign in determining chorionicity in multiple pregnancy. *Obstetrics and Gynecology*. 1996;**88**:6-9
- [41] Scardo JA, Ellings JM, Newman RB. Prospective determination of chorionicity, amnion-icity, and zygosity in twin gestations. *American Journal of Obstetrics and Gynecology*. 1995;**173**:1376-1380
- [42] Sepulveda W. Chorionicity determination in twin pregnancies: Double trouble. *Ultrasound in Obstetrics & Gynecology*. 1997;**10**:79-81
- [43] Dias T, Arcangeli T, Bhide A, Napolitano R, Mahsud-Dornan S, Thilaganathan B. First-trimester ultrasound determination of chorionicity in twin pregnancy. *Ultrasound in Obstetrics & Gynecology*. 2011;**38**:530-532
- [44] Gueneuc A, Spaggiari E, Bonniere M, Hajal NJ, Ville Y, Salomon LJ. Pitfall in the diagnosis of chorionicity in twin pregnancy at first trimester. *Ultrasound in Obstetrics & Gynecology*. 2017;**49**:277-278
- [45] D'Antonio F, Bhide A. Early pregnancy assessment in multiple pregnancies. *Best Practice & Research. Clinical Obstetrics & Gynaecology*. 2014;**28**(2):201-214
- [46] Finberg H, Mendelson E, Bohm-Velez M, et al. Evaluation of Multiple Gestations. *American College of Radiology*. 2000;**215**(Suppl):903-914
- [47] Vayssiere C, Favre R, Audibert F, et al. Cervical length and funneling at 22 and 27 weeks to predict spontaneous birth before 32 weeks in twin pregnancies: A French prospective multicenter study. *American Journal of Obstetrics and Gynecology*. 2002;**187**:1596-1604
- [48] Modena AB, Berghella V. Antepartum management of multifetal pregnancies. *Clinics in Perinatology*. 2005;**32**:443-454, vii
- [49] Lodeiro JG, Vintzileos AM, Feinstein SJ, Campbell WA, Nochimson DJ. Fetal biophysical profile in twin gestations. *Obstetrics and Gynecology*. 1986;**67**:824-827