

# We are IntechOpen, the world's leading publisher of Open Access books Built by scientists, for scientists

6,900

Open access books available

185,000

International authors and editors

200M

Downloads

Our authors are among the

154

Countries delivered to

TOP 1%

most cited scientists

12.2%

Contributors from top 500 universities



WEB OF SCIENCE™

Selection of our books indexed in the Book Citation Index  
in Web of Science™ Core Collection (BKCI)

Interested in publishing with us?  
Contact [book.department@intechopen.com](mailto:book.department@intechopen.com)

Numbers displayed above are based on latest data collected.  
For more information visit [www.intechopen.com](http://www.intechopen.com)



# Use of Intraoperative Ultrasound (IOUS) in Liver Surgery

*Ali I. Yahya*

## Abstract

Over the last many years, diagnostic imaging has grown from a state of infancy to a high level of maturity. The various imaging modalities were developed over the last 50 years. Ultrasonography is one of the valuable tools in diagnosis of many diseases for a long time. It replaced X-ray in the diagnosis of many different diseases. It is noninvasive and has no complications if used many times in the day even if it is safe during pregnancy. The use of ultrasonography was spread over the years in all branches of medicine. It is promptly used in emergency medicine. Its use was introduced during operations. It showed excellent results when used for the assessment of liver tumors either primary or secondary liver tumors during open surgery and laparoscopy. The use of high-frequency ultrasound probe intraoperatively will nullify the abdominal wall and bowel gas effects on the result.

**Keywords:** intra-operative ultrasound, liver surgery

## 1. History of IOUS

In 1942, Neurologist Karl Dussik used ultrasound first time in the medical diagnosis of brain tumors.

In 1948, George D. Ludwig developed the A-mode ultrasound equipment to detect gallstones.

John J. Wild is known as the “father of medical ultrasound” for imaging tissue in 1949. Modern ultrasonic diagnostic medical scans are descendants of the equipment developed by him and his colleagues in the 1950s.

In 1957–1958, Ian Donald, professor of obstetrics and gynecology from Glasgow, invented the ultrasound machine and developed first time the use of ultrasound in obstetrics.

The use of ultrasound during operations which is called intraoperative ultrasound was started in 1960 [3]; however, it was not widely accepted in use because of limited experience and the quality of ultrasound machine. Bernard Sigel is the surgeon who first performed intraoperative ultrasound in biliary surgery; it was in 1979, and later in 1980, he started using IOUS in hepatobiliary surgery.

In 1980, intraoperative ultrasound became more popular and widely used in the field of hepatobiliary and pancreatic, vascular, and neurosurgery.

In 1990, the use of intraoperative ultrasound became widely used, especially in liver surgery. And in the mid-1990s, the use of intraoperative ultrasound became a routine use in hepatic surgery; introduction of probes for open and laparoscopic surgery also added much in addition to the utilization of color Doppler flow ultrasound. IOUS is used for the assessment of pancreatic lesions, blood vessel invasion, lymph node

metastasis, and also biopsy. The use of intraoperative ultrasound adds a lot of information on the anatomy and pathology of the lesion to the surgeon when he is standing at the operation table and can change the decision of the surgical management.

## **2. Use of intraoperative ultrasound for liver diseases**

Ultrasound is used for diagnosis and assessment of liver diseases mainly for tumors, like colonic metastasis since 1990 with the use of a transducer either linear or T-shaped 3.7 MHz.

Intraoperative ultrasound can be used during an open or laparoscopic surgery; each approach has a unique probe. The use of ultrasound where the probe is put directly on the liver with no skin and abdominal wall interferes with the picture of the liver tissue.

*The use of IOUS in different diseases:*

1. Benign liver diseases
2. Malignant liver tumors

### **2.1 Benign liver diseases**

The liver is a very important intra-abdominal organ, which is involved in different diseases that either originate in the liver itself or by a lesion in another part of the body and involves the liver like hepatic metastasis of malignancy. There are benign liver diseases, which are diagnosed by imaging like ultrasound, computed tomography, and magnetic resonance imaging.

#### *2.1.1 Use of IOUS added changes in treatment of different benign liver lesions*

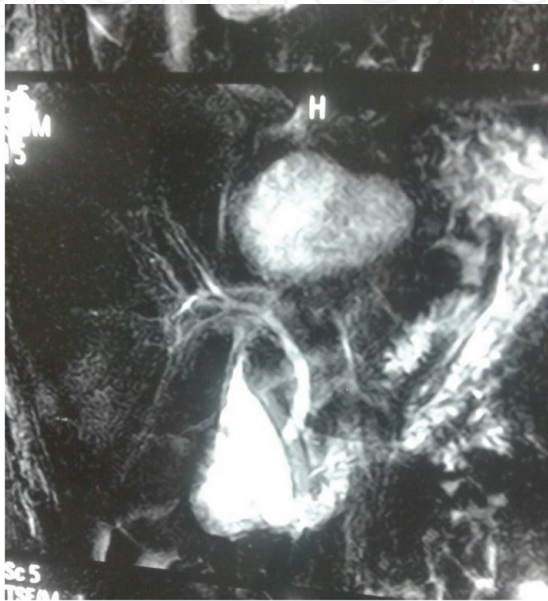##### *2.1.1.1 Hydatid liver disease*

Intraoperative ultrasound is used in surgery for hydatid liver disease. It is used routinely in our hospital.

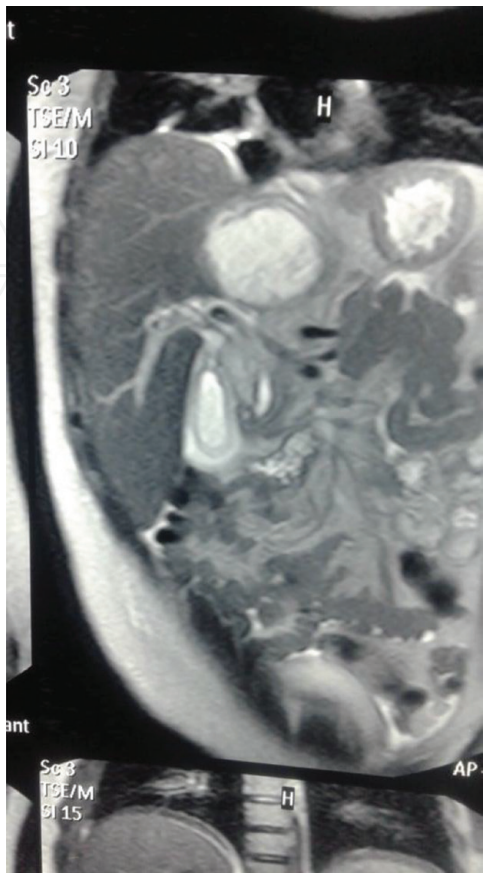
Once the abdomen is opened, we examined the liver manually for localization of the cysts, and defining the number, we use T-shaped ultrasound probe sterilized by glutaraldehyde and examine the liver with the team of our consultant surgeons who perform IOUS and had good training in ultrasound. We examine the number of the cysts and contents in relation to the blood vessels and bile ducts, and visible bile duct communication will be notified if it is visible. Intraoperative ultrasound is more superior and informative than CT and MRI for hepatic hydatid disease, and it is found of value in the following [6–12]:

1. Localization of the cyst in relation to major blood vessels and bile duct.
2. Helping in planning hepatotomy to reach deep-seated cysts.
3. Aspiration and injection of deep-seated cysts—pair technique.
4. Trans-choledochal hydatid cyst evacuation—this is a very rare operation that was done for a 20-year-old female patient admitted to Zliten Teaching Hospital with obstructive jaundice and with percutaneous ultrasound and MRI. The cause of obstructive jaundice was due to the daughter hydatid cyst coming

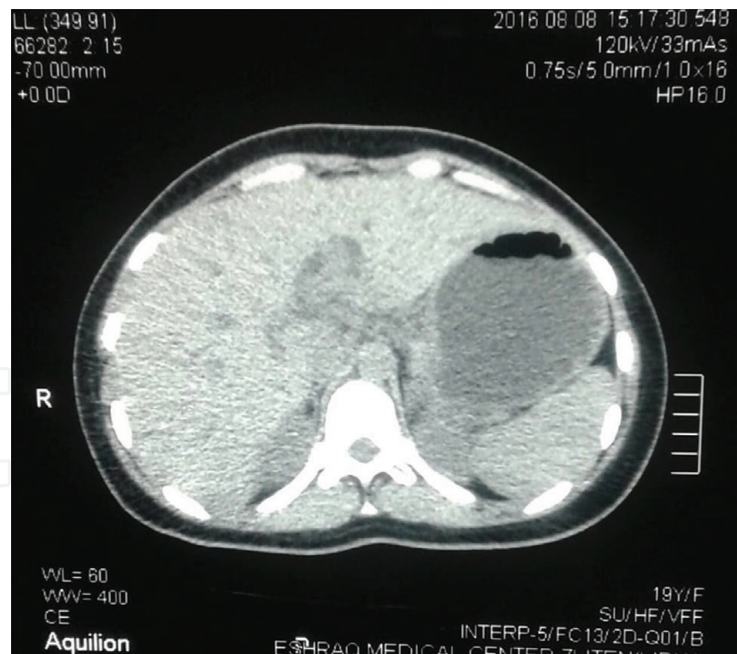
from the mother hydatid cyst which was a deep-seated hepatic hydatid cyst in segment VIII with communication to the bile duct which was cleared by MRCP (**Figures 1** and **2**). The surgery was performed to the patient with the use of IOUS. The common bile duct was opened, and the daughter cysts from the bile duct were removed with the help of IOUS the mother cyst was cleared from daughter cysts by approach through the communication with the bile duct, Endocyst was removed, and the residual cavity collapsed which is clearly seen by IOUS. A T-tube was put inside the common bile duct, and the patient was discharged and after 4 weeks she had a T-tube contrast study. The common bile duct was clear, there was no more cyst in the liver, and the patient was cured from the hepatic hydatid-induced obstructive jaundice (**Figure 3**).



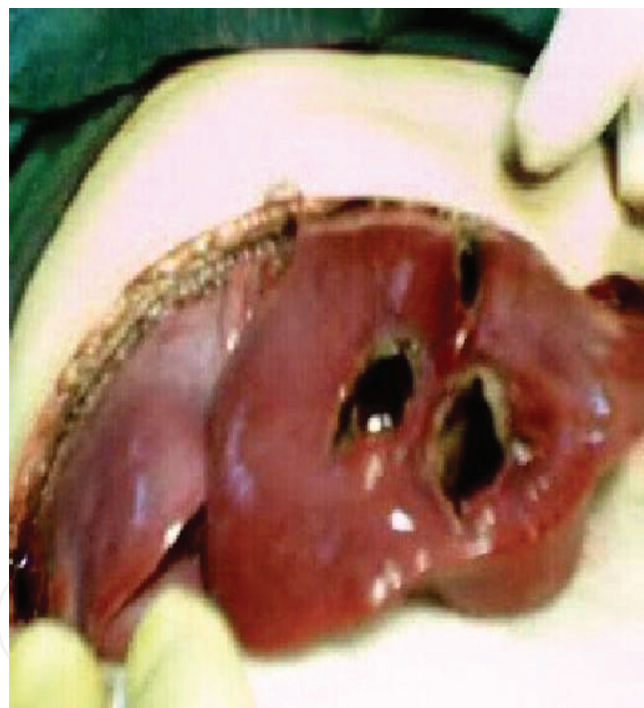Hydatid cyst liver evacuated through bile duct.







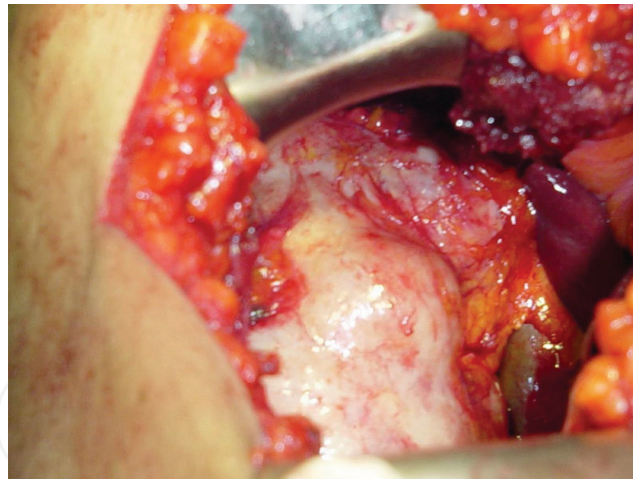
CT scan liver showing residual cyst was done after two months after the surgery



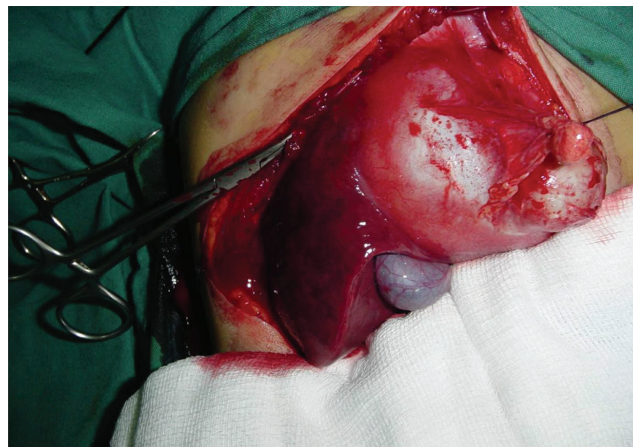
**Figure 1.**  
*Showing the liver with hydatid cysts in a child, aged 9 years, which had preoperative ultrasound which showed few hepatic hydatid cysts, with the use of intraoperative ultrasound; 22 hydatid cysts were removed in spite of the CT scan reporting few cysts.*

#### *2.1.1.2 Liver hemangioma*

Liver hemangioma is not a common liver lesion; it can have a small size or may increase in size and rupture and can be detected by percutaneous ultrasound, CT, and MRI. Intraoperative ultrasound is used for delineation and plans the resection of the hemangioma. Hemangioma can be differentiated from other liver lesions by contrast-enhanced intraoperative ultrasound. It can be compressed under ultrasound and seen by Doppler, which is a feature of the space containing blood.



**Figure 2.**  
*Showing a patient with surgery for huge liver hydatid cyst. IOUS was used to scan the liver for other cysts and used in surgical approach to excise the cyst.*



**Figure 3.**  
*Showing a big hydatid cyst in the liver.*

#### 2.1.1.3 Intraoperative ultrasound study of the gall bladder and the bile duct

With the development of transducers for intraoperative ultrasound, intrahepatic and extrahepatic bile ducts can be visualized with 7.5 MHz probes. We use T-shaped probes sterilized with glutaraldehyde solution or by gas sterilization; the probe can be covered with sterile sheet. Intraoperative laparoscopic ultrasound is used during laparoscopic cholecystectomy to visualize common bile lesions including stones, tumors, and gall bladder suspicious lesions either sludge or tumors.

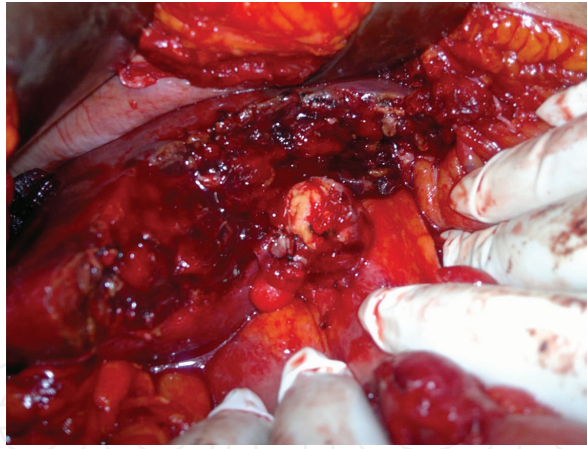
Laparoscopic intraoperative ultrasound can replace intraoperative cholangiogram for the detection of common bile duct stones which costs less and consumes less time [1, 2, 4, 5] (**Figure 4**).

#### 2.1.1.4 Liver cysts

Benign liver cyst, which can be congenital or acquired with the use of intraoperative ultrasound, we can delineate and study the relation of the cysts to the blood vessels and the bile duct.

#### 2.1.1.5 Liver abscess

Liver abscess is not common; once happened it can be localized and aspirated with the help of intraoperative ultrasound.



**Figure 4.**  
*A 60-year-old female patient with carcinoma in the gall bladder; the tumor was resected completely with segment of the liver.*

#### *2.1.1.6 Liver tumors*

For primary liver tumors and hepatocellular carcinoma, IOUS is very helpful in staging the tumor looking for any small lesions. It is very helpful in case of a cirrhotic liver, for looking the extent of the lesion, relation of the blood vessel to the lesion. It is more useful if contrast-enhanced ultrasound is used. IOUS is more superior in detecting liver lesion than preoperative MRI and CT scan with sensitivity of 95–100% in comparison to others, 80% for CT, and 70% for percutaneous ultrasound. It is very helpful in liver resection for liver malignant tumors and will improve patient survival by taking safety liver resection; with the use of IOUS, limited liver tumor resection can be done in a non-segmental way and will improve patient survival especially in a patient with hepatocellular carcinoma with a background of cirrhosis [25–27, 29–33]. IOUS may have difficulty in detecting small liver lesion in a fatty liver; however, the use of contrast-enhanced ultrasound will be more beneficial [22–24, 28].

For cholangiocarcinoma of the hilar region and Klatskin tumor, intraoperative ultrasound makes a difference in staging the disease and resection of the tumor.

*Use of IOUS in malignant hepatic tumors:*

1. IOUS scan for malignant liver lesions adds an outcome of 25–35% more over percutaneous ultrasound in liver resection and helps in defining the extent of the tumor and its relation to big blood vessels and the bile duct [13–21].

#### *2. Helping in biopsy of liver lesions*

The use of IOUS at primary surgery of colonic tumor is as follows: In our hospital it is done when the operation is performed by senior surgeons, and we found it gives more information on the staging of the tumor. It is found more superior than CT scan and percutaneous ultrasound.

#### *2.1.1.7 Hepatic transplantation*

It is used for harvesting the liver and for following the patency of anastomosis of the blood vessels.



### 3. IOUS

IOUS changed the surgical decision when used by hepatobiliary and pancreatic surgeons. The benefit of the use of IOUS in surgical treatment of a liver disease may reach to 41.9% according to documented studies and makes the use of IOUS for liver surgery of a big value.

#### 3.1 IOUS training

1. Ultrasound is performed by the radiologist who had training and knowledge of operating on machines, and the radiologist and radiographer should be ready to perform the procedure in the right time.
2. It is difficult to perform IOUS during emergency operations, if needed.
3. Training of surgeons for the use of ultrasound during surgery needs time for different surgical operations.

#### 3.2 Methods of the use of IOUS

1. Types of the transducer: the transducer can be for open surgery (linear or T-shaped). There are laparoscopic and robotic transducers which are used during laparoscopic surgery.
2. Sterilization: the transducer needs either sterilization or cover with sterile sheet to be used in surgery.

*Sterilization and disinfecting the probes:*

- a. The transducer has to be cleaned after finishing the work and dried with dry tissue paper.
  - b. Use the sterile sheet cover over the transducer, and put sterile gel during the examination inside the cover.
  - c. Use a disinfective solution like CISEx; the time is 12 minutes. Glutaraldehyde and dialdehyde are not used nowadays because they may cause inflammatory contact.
  - d. Hydrogen peroxide.
  - e. Plasma.
3. Cover the ultrasound board with sterile sheet for the surgeon to use the board by himself.
  4. Full mobilization of the liver by the removing of the ligaments before the application of IOUS.
  5. Examining the remaining liver tissue for its blood flow and bile drainage. IOUS is a very crucial tool for modern liver surgery and changes the resection margin and the outcome.



6. When we examine the liver, we follow the portal veins and hepatic veins.
7. Looking for the pattern of the blood vessels: the flow of the blood, clotting in the blood vessels, and the pedicle supply of the resected and remaining segments.



Open surgery ultrasound transducer



Laparoscopic ultrasound transducer



Robotic ultrasound transducer

## 4. Conclusion

Ultrasound is routinely used for the diagnosis of diseases. The use of ultrasound during surgery is applied for a long time, and it is used for surgical treatment of surgical liver diseases. It made a lot of changes in the management of malignant hepatic metastatic colonic tumors. Using IOUS for liver pathology will change the mode of treatment. It also helps in the ablation of liver tumors. IOUS is also used for surgical treatment of benign hepatic pathology like hydatid liver disease, liver cysts, bile duct stones, and bile duct tumors. It can replace intraoperative cholangiography when needed. The advantages of the use of IOUS in liver surgery are the following: it gives better informations about the liver involvement by the lesion than transcutaneous ultrasound, CT scan, or MRI; it will show small lesions which may not be seen by the other modalities; it helps in outlining the resection line when liver resection is planned; it gives informations about the relation of the blood vessels to the lesion; it gives information about the bile duct anatomy; and it can replace intraoperative cholangiogram if needed. Disadvantages of IOUS in liver surgery are the following: it needs special training for the surgeons, it adds more work for the radiologists if it needs to be done by the radiologist, and it is difficult to be used in emergency surgery like where patients are operated on malignant bowel obstruction to check whether the patient has liver metastasis or not. This is because of availability of the trained surgeon or trained radiologist and the availability of the equipment. The use of IOUS in liver surgery will add more cost, and it may not be possible in hospitals where the resources are restricted.

### Author details

Ali I. Yahya  
Zliten Teaching Hospital, Zliten Medical School, Al-Asmaria University,  
Zliten, Libya

\*Address all correspondence to: [aliyahyaz60@hotmail.com](mailto:aliyahyaz60@hotmail.com)

### IntechOpen

© 2019 The Author(s). Licensee IntechOpen. This chapter is distributed under the terms of the Creative Commons Attribution License (<http://creativecommons.org/licenses/by/3.0>), which permits unrestricted use, distribution, and reproduction in any medium, provided the original work is properly cited. 

## References

- [1] Lane RJ, Glazer G. Intra-operative B-mode ultrasound scanning of the extrahepatic biliary system and pancreas. *Lancet*. 1980;**2**:334-337
- [2] Koleccki R, Schirmer B. Intra-operative and laparoscopic ultrasound. *The Surgical Clinics of North America*. 1998;**78**:251-271
- [3] Kane RA. intraoperative ultrasonography: History, current state of the art, and future directions. *Journal of Ultrasound in Medicine*. 2004;**23**:1407-1420
- [4] Sigel B, Machi J, Beitler JC, Donahue PE, Bombeck CT, Baker RJ, et al. Comparative accuracy of operative ultrasonography and cholangiography in detecting common duct calculi. *Surgery*. 1983;**94**(4):715
- [5] Kruskal JB, Robert A. Intraoperative sonography of the biliary system. *American Journal of Roentgenography*. 2001;**177**
- [6] Botea F, Sârbu V, Dima S, Iusuf T, Unc O, Toldişan D, et al. The role of intraoperative ultrasound in the diagnosis and treatment of hydatid liver disease. *Chirurgia (Bucur)*. 2006;**101**(6):593-598
- [7] Ivanov SA, Kotiv BN. Ultrasound examination in the surgery of hepatic echinococcosis. *Vestnik Khirurgii Imeni I. I. Grekova*. 2001;**160**(3):73-77
- [8] Gavrilin AV, Vishnevskii VA, Ikramov RZ, Ambadi V. Intraoperative ultrasonic study in surgery of hepatic echinococcosis. *Khirurgiia (Mosk)*. 1991;**(2)**:78-82
- [9] Picardi N, Annunziata A, Bartolacci M, Di Rienzo M, Bottegoni G, Zuccarini F, et al. The radical treatment of hepatic hydatidosis with deep and multiple locations. The role of new technologies particularly in the case of multiple locations. *Annali Italiani di Chirurgia*. 1999;**70**(4):529-538
- [10] Dervisoglu A, Erzurumlu K, Taç K, Arslan A, Gürsel M, Hökelek M. Should intraoperative ultrasonography be used routinely in hepatic hydatidosis? *Hepato-Gastroenterology*. 2002;**49**(47):1326-1328
- [11] Tasev V, Ionkov A. Intraoperative echography in the diagnosis and treatment of minor intraparenchymal cysts in multiple hepatic echinococcosis—A report on 3 cases. *Khirurgia (Sofia)*. 1998;**51**(3):25-27
- [12] Trotta F, Prati U, Roveda L, Brunetti E, Filice C. Intra-operative PAIR of hepatic echinococcal cyst after cholecystectomy with laparoscopic approach. *Liver International*. 2007;**27**(2):284-286
- [13] Makuuchi M, Takayama T, Kosuge T, et al. The value of ultrasonography for hepatic surgery. *Hepato-Gastroenterology*. 1991;**36**:64
- [14] Machi J, Isomoto H, Kurohiji T, et al. Accuracy of intraoperative ultrasonography in diagnosing liver metastasis from colorectal cancer: Evaluation with postoperative follow-up results. *World Journal of Surgery*. 1991;**15**:551
- [15] Torzilli G, Olivari N, Moroni E, et al. Contrast-enhanced intraoperative ultrasonography in surgery for hepatocellular carcinoma in cirrhosis. *Liver Transplantation*. 2004;**10**(2 Suppl): S34-S38
- [16] Castaing D, Emond J, Bismuth H, Kunstlinger F. Utility of operative ultrasound in the surgical management of liver tumors. *Annals of Surgery*. 1986;**204**:600-605

- [17] Lau WY, Leung KL, Lee TW, Li AKC. Ultrasonography during liver resection for hepatocellular carcinoma. *The British Journal of Surgery*. 1993;**80**:493-494
- [18] Garancini M, Gianotti L, Delitala A, Romano F, Degrate L, Giardini V. Intraoperative ultrasound: A review on its role in liver surgery for primitive and metastatic tumors. *Minerva Chirurgica*. 2016;**71**(3):201-213
- [19] Donadon M, Costa G, Torzilli G. State of the art of intraoperative ultrasound in liver surgery: Current use for staging and resection guidance. *Ultraschall in der Medizin*. 2014;**35**(06):500
- [20] Torzilli G, Makuuchi M. Tricks for ultrasound-guided resection of colorectal liver metastases. *Hepato-Gastroenterology*. 2003;**50**(49):1-3
- [21] Meijer S, Paul MA, Cuesta MA, Blomjous J. Intra-operative ultrasound in detection of liver metastases. *European Journal of Cancer*. 1995;**31A**(7-8):1210-1211
- [22] Mitsunori Y, Tanaka S, Nakamura N, Ban D, Irie T, Noguchi N, et al. Contrast-enhanced intraoperative ultrasound for hepatocellular carcinoma: High sensitivity of diagnosis and therapeutic impact. *Journal of Hepato-Biliary-Pancreatic Sciences*. 2013;**20**(2):234-242
- [23] Arita J, Takahashi M, Hata S, Kokudo N. Usefulness of contrast enhanced intraoperative ultrasound using sonazoid in patients with hepatocellular carcinoma. *Annals of Surgery*. 2011;**254**(6):992-999
- [24] Vazharov IP, Kostov DV. Intraoperative ultrasound examination OF hilar cholangiocarcinoma/tumor of klatskin. *Journal of IMAB-Annual Proceeding (Scientific Papers)*. 2012;**18**. book 3
- [25] Torzilli G, Del Fabbro D, Palmisano A, et al. Contrast-enhanced intraoperative ultrasonography during hepatectomies for colorectal cancer liver metastases. *Journal of Gastrointestinal Surgery*. 2005;**9**(8):1148-1153. discussion 1153-4
- [26] Ferrero A, Langella S, Giuliente F, Viganò L, Vellone M, Zimmitti G, et al. Intraoperative liver ultrasound still affects surgical strategy for patients with colorectal metastases in the modern era. *World Journal of Surgery*. 2013;**37**(11):2655-2663
- [27] van Vledder MG, Pawlik TM, Munireddy S, Hamper U, de Jong MC, Choti MA. Factors determining the sensitivity of intraoperative ultrasonography in detecting colorectal liver metastases in the modern era. *Annals of Surgical Oncology*. 2010;**17**(10):2756-2763
- [28] Schulz A, Dormagen JB, Drolsum A, Bjørnbeth BA, Labori KJ, Kløw NE. Impact of contrast-enhanced intraoperative ultrasound on operation strategy in case of colorectal liver metastasis. *Acta Radiologica*. 2012;**53**(10):1081-1087
- [29] Walker TLJ, Bamford R, Finch-Jones M. Intraoperative ultrasound for the colorectal surgeon: Current trends and barriers. Review article. *ANZ Journal of Surgery*. 2017;**87**(9):671-676
- [30] Grondona P, Meola C, Floris F, Masini R, Brignole E, Quidaciolu F. Ultrasound-guided liver resection: Early experience in a district general hospital. *Journal of Ultrasound*. 2008;**11**(4):162-167
- [31] Röthlin M, Schlumpf R, Bornman P, Krige J, Largiadèr F. Intraoperative



ultrasonography of the liver. Swiss  
Surgery. 1996;(3):105-111

[32] Torzilli G, Takayama T, Hui A-M,  
Kubota K, Harihara Y. A new technical  
aspect of ultrasound-guided liver  
surgery. The American Journal of  
Surgery. 1999;**178**(4):341-343

[33] Solomon MJ, Stephen MS, Gallinger  
S, White GH. Does intraoperative  
hepatic ultrasonography change surgical  
decision making during liver resection.  
The American Journal of Surgery.  
1994;**168**(4):307-310