

We are IntechOpen, the world's leading publisher of Open Access books Built by scientists, for scientists

6,900

Open access books available

186,000

International authors and editors

200M

Downloads

Our authors are among the

154

Countries delivered to

TOP 1%

most cited scientists

12.2%

Contributors from top 500 universities



WEB OF SCIENCE™

Selection of our books indexed in the Book Citation Index
in Web of Science™ Core Collection (BKCI)

Interested in publishing with us?
Contact book.department@intechopen.com

Numbers displayed above are based on latest data collected.
For more information visit www.intechopen.com



Anaplastic Large Cell Lymphoma

Suzanne D. Turner

Abstract

Anaplastic large cell lymphoma (ALCL) describes a distinct group of T cell lymphomas characterised by cell surface expression of CD30. At least three entities of ALCL exist, with similar cellular morphology but varying clinical courses and pathology: systemic ALCL, anaplastic lymphoma kinase (ALK)-positive, systemic ALCL ALK– and primary cutaneous ALCL. A fourth provisional entity associated with breast implants has been proposed, named breast implant-associated (BIA)-ALCL. ALCL have varying clinical outcomes, affect both children and adults, and range from being well-characterised at the genetic level to relatively unknown, predominantly due to the relative rarity of this group of malignancies. Current therapeutic approaches include standard chemotherapeutic agents as well as novel drugs including monoclonal antibodies and kinase inhibitors.

Keywords: anaplastic large cell lymphoma, anaplastic lymphoma kinase, tyrosine kinase inhibitors, peripheral T cell lymphoma, BIA-ALCL

1. Introduction

Anaplastic large cell lymphoma (ALCL) was first described in 1985 as a CD30-positive (or ki-1+) histiocytic lymphoma, later re-classified as a distinct clinical entity, ALCL [1]. The presence of a chromosomal translocation in this malignancy was described independently by several authors in 1989–1990 [2–5]. This was further refined in 1994 on cloning of the t(2;5)(p23;q35) translocation breakpoint product, identified as a fusion protein of Nucleophosmin 1 (NPM) and anaplastic lymphoma kinase (ALK), the latter a previously uncharacterized protein named after the disease from which it was cloned [6]. Sometime later in 2008, systemic (s) ALCL was divided into two provisional entities: ALCL, ALK+ and ALCL, ALK– which were confirmed as distinct entities in the revised 4th edition of the WHO classification of tumours of haemopoietic and lymphoid tissues [7]. The revised 4th edition also includes a new provisional entity of ALCL associated with breast implants, breast implant-associated (BIA)-ALCL which may consist of at least two clinically distinguishable forms, if not a spectrum of disease, ranging from sub-capsular seroma fluid to aggressive, infiltrating masses with good and poor prognoses respectively [8, 9]. As well as systemic forms of the disease, there exists a cutaneous type belonging to the class of primary cutaneous CD30-positive T cell lymphoproliferative disorders—primary cutaneous (pc) ALCL [7]. In this chapter, the clinical and pathological presentations of each of these disease entities will be presented and discussed as will the biology underlying these malignancies.

2. Systemic ALCL

2.1 Clinical course

The large majority of ALCL, ALK+ are diagnosed in a younger patient population with a median age of 10.2–11 and have a relatively good prognosis (>80% overall survival; OS) [10–15]. In contrast ALCL, ALK– more often affects an older demographic (40–65 years of age) and has a poor prognosis (<50% OS) [16–19]. Whether these different clinical outcomes are age-related or due to inherent properties of the malignancies remains to be determined although in support of the latter, ALK– ALCL carrying DUSP22 rearrangements have been reported to have a superior 5-year OS of 90% (compared to 17% for TP63 rearranged cases and 42% for ALK–/DUSP22–/TP63– cases) although if patients are stratified according to age rather than ALK status, the outcome in response to treatment is the same [17, 19, 20]. The relatively high survival rates of patients diagnosed with ALCL, ALK+ may also be attributable to the host immune response whereby cytotoxic T lymphocytes, helper T cells and B cells responding to ALK have been detected in patients [21, 22]. Patients with ALCL, ALK+ mount an immune response to the ALK protein in the form of a humoral antibody response [23]. In fact, the titre of ALK autoantibodies in a patient's serum can be predictive of outcome with an inverse correlation between ALK antibodies and relapse [24]. This prognostic factor can be extended further when combined with the presence or absence of minimal disseminated disease (MDD), with children having low ALK autoantibody titres combined with presence of MDD being of high risk, with the converse indicative of low risk [25].

2.2 Histopathological presentation and immunophenotype

ALCL spans a broad morphological spectrum with sub-types including common (65%), small cell and lymphohistiocytic variants (32% combined) with the latter constituting a poor prognostic variable [26–28]. The unifying feature of ALCL is the presence of CD30 expression on the surface of the tumour cells, particularly the larger ones. CD30 is a marker of activated immune cells but does not distinguish between a T or B cell origin when applied in isolation. Hence, for a diagnosis of a T cell lymphoma, a cell surface protein, or combination of proteins unique to T cells must be detected. In this regard, many ALCL express CD4, CD2 and/or CD5 but often lack CD3. The positive expression of CD4 in the absence of CD8 combined with the presence of cytotoxic proteins such as TIA-1, Granzyme B and/or perforin is at odds with the presumed cytotoxic T cell origin of ALCL [7, 29]. However, in some cases, no T cell specific proteins are detectable and these are categorised as being 'null cell', although the majority demonstrate molecular rearrangements of the T cell receptor (TCR) [30].

2.3 Underlying genetic alterations

2.3.1 ALCL, ALK+

ALCL is, in general, a genetically stable cancer with few common defining genetic alterations besides translocations involving ALK [31, 32]. In this regard, the t(2;5) (p23;q35) generating NPM-ALK at the breakpoint is the most common event with many variants having been published over the years (**Table 1**) [33]. The common expression of NPM-ALK, and its nuclear and cytoplasmic location as opposed to cytoplasmic-alone position as seen with many of the other variants, may account for its predominance in ALCL, ALK+; nuclear location may provide a competitive advantage over cytoplasmic alone. Alternatively, the *NPM1* gene on chromosome 5 may be

Chromosomal alteration	Fusion protein	Cellular location	References
t(2;5)(p23;q35)	NPM-ALK	Nucleus and cytoplasm	[2–6]
t(2;3)(p23;q12.2)	TFG-ALK (short, long and extra-long isoforms)	Cytoplasm	[134, 135]
t(1;2)(q25;p23)	TPM3-ALK	Cytoplasm	[136]
Inv(2)(p23;q35)	ATIC-ALK	Cytoplasm	[137, 138]
t(X;2)(q11–12;p23)	MSN-ALK	Membrane	[139]
t(2;17)(p23;q23)	CLTC-ALK	Cytoplasm (granular)	[140, 141]
t(2;22)(p23;q11.2)	MYH9-ALK	Cytoplasm	[142]
t(2;19)(p23;q13.1)	TPM4-ALK	Cytoplasm	[143]
t(2;17)(p23;q25)	RNF213/ALO17-ALK	Cytoplasm	[144]

Table 1.
Overview of ALK fusion partners identified in ALCL, ALK+.

more prone to breakage and fusion with new partners due to its active transcription at the same time as *ALK*, although there is no evidence to suggest this is the case. What is clear, is that all reported ALK fusion proteins generate a hyperactive tyrosine kinase that is ligand-independent, driving cellular proliferation and survival [33]. Taking the example of NPM-ALK, this fusion protein retains the oligomerisation domains of NPM1 and the entire intracellular portion of ALK encoding the kinase domain, resulting in dimerization, auto-phosphorylation and subsequent hyperactivity initiating a whole plethora of signal transduction pathways (**Figure 1**) [6, 34].

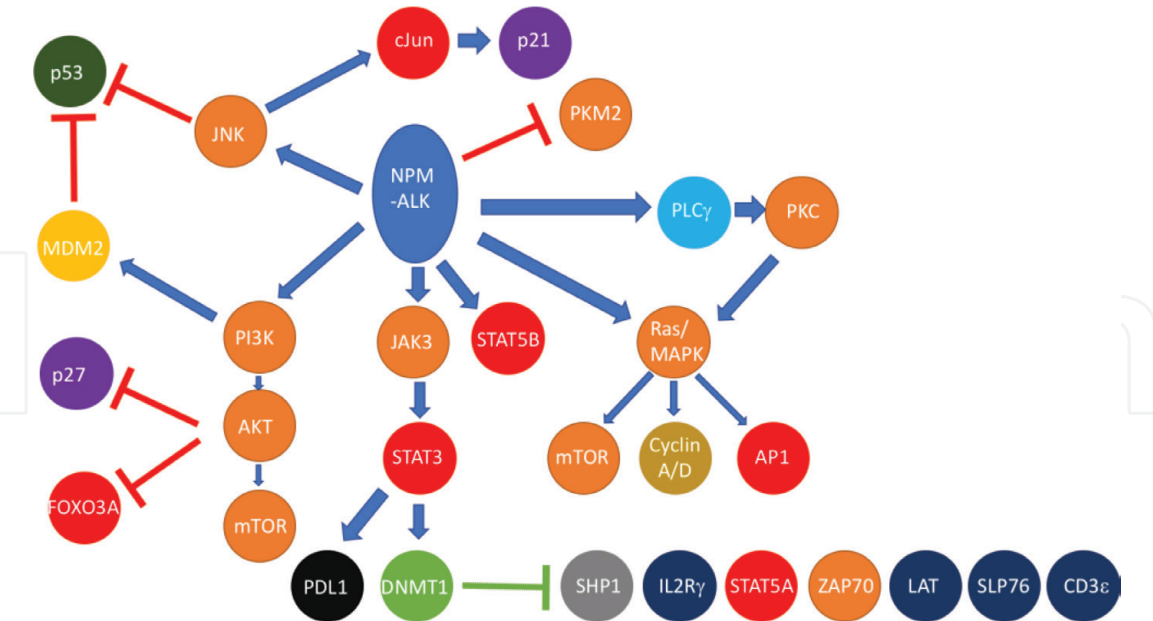


Figure 1.
*NPM-ALK activates a plethora of signalling pathways conferring many of the cancer hallmarks on tumour cells. NPM-ALK autophosphorylates tyrosine residues providing docking sites for SH2 domain-containing proteins and the development of a signalosome consisting of at least 46 proteins [35]. Key pathways involved in cell survival and proliferation include the PI 3-Kinase/Akt, Ras/MAP Kinase and JAK/STAT pathways as well as PLCγ [36–41]. While activation of JNK and PI 3-Kinase by NPM-ALK can drive cell proliferation, they also inactivate p53 by ubiquitin-mediated degradation [42]. NPM-ALK also activates immunomodulatory pathways including up-regulation of PDL1 mediated by STAT3, as well as silencing some proteins by epigenetic means (green arrow, **Figure 1**), including those associated with signalling downstream of a functional TCR [43–47]. In addition, NPM-ALK directs metabolic activity of the cells shifting to aerobic glycolysis with increased lactate and biomass production promoting cell survival [48].*

While ALK translocations are diagnostic of ALCL, ALK⁺ and are central to disease pathogenesis, the role of other contributing mutations is largely unknown as few consistent genetic abnormalities besides those generating ALK translocations have been reported. This may, in part, be due to the plethora of cancer hallmarks that can be driven by NPM-ALK alone (**Figure 1**). However, array comparative genomic hybridization (aCGH) studies have highlighted some commonalities [31, 32]. For example, gains of chromosomes 7, 6q, 17p, 17q24-qter and losses of chromosomes 4q13-q21, 11q14 and 13q although the significance of these is unknown [32]. However, a higher number of genomic imbalances as detected by aCGH at a resolution of 1 MB, has been associated with a worse prognosis [31].

The recognition of NPM-ALK as a driving oncogenic event and the paucity of other reported consistent genomic/genetic abnormalities in ALCL, ALK⁺ has led to studies of the epigenetics of ALCL [31, 49, 50]. Profiling of CpG methylation in ALCL defined a number of genes silenced in these malignancies including the TCR signalling-related proteins Zap70, LAT, CD3 ϵ , SLP76 and the IL2R γ chain [43, 45–47, 49, 51]. Given that NPM-ALK can substitute for signalling normally induced via an engaged TCR, activation of these proximal TCR signalling proteins may be detrimental to cell survival resulting in their evolutionary down-regulation [38, 52]. Furthermore, a number of miRNA have been implicated in tumorigenesis including miR17-92, miR135b, miR29a and miR16 [53–56].

2.3.2 ALCL, ALK[–]

By their very definition, ALCL, ALK[–] lack expression of ALK fusion proteins, but until recently, few studies had found major contributory and consistent mutations. DUSP22 rearrangements leading to loss of expression of DUSP22 have been reported in as many as 30% of cases and activating *JAK1/STAT3* mutations in 20% [19, 57, 58]. In addition, rearrangements leading to *TP63* mutation (8% of cases) and *ERBB4* truncation have been demonstrated as have novel, rare rearrangements leading to the generation of NcoR2-ROS1, NFkB2-ROS1 and NFkB2-TYK2 fusion proteins [19, 57, 59, 60]. In addition, similar to ALK⁺ ALCL, miRNA have been implicated in disease pathogenesis including miR155 as well as others that enable a molecular distinction between ALCL, ALK⁺ and ALK[–] as well as peripheral T cell lymphoma, not otherwise specified (PTCL-NOS) [61–64]. Likewise, genomic classifiers of ALCL, ALK[–] amongst other peripheral T cell lymphomas have been demonstrated using a variety of genomic analysis techniques and includes the differentiating 3-gene signature of *TNFRSF8*, *BATF3* and *TMOD1* [65–68]. SNP arrays have also led to the identification of recurrent losses at 17p13 and/or 6q21 where the *TP53* and *PRDM1* genes are located respectively, in as many as 52% of cases suggestive of a role for the loss of the p53 and BLIMP1 proteins in disease pathogenesis [69].

3. BIA-ALCL

BIA-ALCL is a relatively new addition to the spectrum of ALCL, although the first case was reported in 1997, but did not receive much attention until further cases were identified and published, and the FDA acknowledged an association in 2011 [70, 71]. In March 2015, the French health minister issued a warning following reports of 18 cases in France [72]. A further follow-up report released by the FDA in 2017 described 414 medical device reports and 9 deaths associated with BIA-ALCL [73]. Many case series have been reviewed and reported since, with data from France, Italy,

The Netherlands, UK, Australia and the USA being prevalent [74–80]. Most recently, seven cases have been reported in Latin America [81]. There are approximately 5–10 million women with breast implants worldwide with rates of BIA-ALCL being proportionately rare although difficult to put an exact figure to. Dependent on the study conducted, incidence rates range from 1 to 89 cases per million women with breast implants [82, 83]. This reaches a much higher incidence if one considers women with textured implants alone. Almost all cases reported to date have been associated with a breast implant of a textured surface at some point during the history of the patient; whilst rare cases have been reported in women with smooth implants, the patient had been in receipt of a textured implant at some stage [78, 84]. In addition, both saline and silicone filled implants have been implicated in patients with BIA-ALCL. The tumour cells generally present as a monoclonal expansion of CD30-positive cells, as an effusion within the fibrous capsule surrounding the implant [78].

3.1 Clinical course

BIA-ALCL appears to represent at least two clinical entities if not a spectrum of malignancies; patients present on most occasions with an indolent seroma with rarer incidences of invasive solid masses [77]. Indeed, cases have been reported of tumour growth into the ribs with metastases to distant lymph nodes [85, 86].

3.2 Histopathological presentation and immunophenotype

Like sALCL, BIA-ALCL is characterised by CD30 expression on lymphoid cells, in the latter situation contained within the peri-prosthetic effusion [28, 87]. These cells can be detected by immunohistochemistry, cytology and flow cytometry of seroma fluid or any solid mass [85]. A Th17/Th1 origin has been proposed whereby tumour cells secrete IFN γ , IL6, IL8, IL17 and TGF β although a Th2 derivation has also been put forward [88–90].

3.3 Underlying genetic alterations

Like ALCL, ALK $^{-}$, BIA-ALCL has not to date been associated with genomic events leading to activation of ALK. However, in concert with ALCL, ALK $^{-}$, activating mutations of JAK/STAT proteins have been reported in a very few cases [91, 92]. Given the relative rarity of this disease, larger scale studies are required to elucidate the underlying genetics.

4. Primary cutaneous ALCL

While skin involvement can occur as an extranodal manifestation of sALCL, isolated cutaneous disease can also occur, although this is largely ALK-negative [17]. Primary cutaneous ALCL belongs to the spectrum of CD30 positive lymphoproliferative disorders (LPDs) and like BIA-ALCL is largely indolent in nature. While largely affecting adults who present with isolated, ulcerating nodules, children can also develop pcALCL.

4.1 Clinical course

Like systemic ALCL, ALK $^{-}$, cutaneous ALCL is also a disease of an older demographic with the majority of patients being over 50 years of age, yet is closer

to ALCL, ALK+ in its prognosis, reaching a 5-year OS of over 90% [17]. However, relapse is relatively common in this patient group occurring in as many as 30–40% of patients and some rare cases (12–16%) can progress to systemic disease [93–95]. Spontaneous regression has been reported, although in rare cases with partial regressions being more common [96].

4.2 Histopathological presentation and immunophenotype

Diagnosis can be difficult with other cutaneous T cell lymphomas such as lymphomatoid papulosis (LyP) and transformed mycosis fungoides (MF) providing differential diagnoses [9]. However, like systemic ALCL, CD30 expression is a defining feature of this malignancy as it is for the other CD30-associated LPDs.

4.3 Underlying genetic alterations

Due to its relative rarity, sometimes-difficult diagnosis and indolent course, studies of the underlying genetics are few. However, limited studies have elucidated some of the genetic events that may be driving this disease process some of which are also common to sALCL. For example, as in sALCL, DUSP22-IRF4 rearrangements have been detected in 20–57% of pcALCL and ALK expression is seen in rare cases [19, 97–101]. In addition, aCGH has identified gains of 7q31 and losses of 6q16-21 as well as 13q34, collectively in 45% of examined patient specimens [102]. As well as similarities to ALCL, ALK-negative with regards to DUSP22 translocations, upregulation of miR155 has also been observed in both pcALCL and sALCL, ALK– [61, 103]. The functional and clinical significance of these genetic events is still subject to investigation.

5. Treatment of ALCL

As for most peripheral T cell lymphomas, standard combination chemotherapy has been the mainstay of treatment for many years, specifically in the case of systemic disease [14]. In contrast, the relatively indolent cutaneous and breast implant-associated forms are primarily treated by surgical removal [86]. However, as this spectrum of diseases crosses age boundaries, there are age-specific differences in therapeutic approaches.

5.1 Treatment of children with ALCL

As mentioned before, the large majority of patients diagnosed with ALCL, ALK+ are children and young adults. As such, the therapeutic approach is tuned to this patient population with children receiving a combination of chemotherapeutic agents with survival rates in excess of 90% [10, 13, 14]. The ALCL99 trial, the largest trial ever to be conducted for children diagnosed with ALCL (n = 352) applied a therapeutic regimen consisting of a B cell protocol (based on NHL-BFM-B) with randomisation of vinblastine [13]. The success of this trial has led to most centres adopting the ALCL99 treatment protocol. Additionally, the success of the ALCL99 trial and the plethora of biological data produced suggest that patients might be stratified according to ALK autoantibody titre and the presence of MDD as discussed above. Indeed, vinblastine monotherapy might be more appropriate for low risk patients reducing both acute and chronic side-effects of the combination chemotherapy protocol [104, 105].

5.2 Treatment of adults with ALCL

Adults with ALCL tend to be ALK[−] and are treated with the standard T cell lymphoma regimen CHOP (cyclophosphamide, doxorubicin, vincristine, prednisone) although CHOEP (CHOP + etoposide) has been demonstrated to be superior in the treatment of adult ALCL, ALK⁺ patients [106]. In the case of BIA-ALCL, surgical excision with complete capsulectomy is recommended and is often sufficient to induce remission particularly for patients that present with a contained seroma [85, 86]. However, patients with aggressive BIA-ALCL that has metastasised require radiotherapy if not chemotherapy, and anecdotal evidence suggests that upfront use of brentuximab vedotin (BV) may benefit these patients [107]. In the case of pcALCL, localised excision and/or radiotherapy is largely prescribed due to the obvious skin presentation, although cases with multi-focal lesions may require more aggressive treatment involving chemotherapy [108, 109].

5.3 New and novel treatment options for ALCL

In the post-genomic era, targeted agents have become the mainstay of chemotherapy, largely in addition to standard cytotoxic drugs. In the case of ALCL, ALK⁺, inhibitors of ALK are the obvious choice and many have been developed since the discovery of ALK expression in Non-Small Cell Lung Cancer [14]. The first ALK inhibitor to be developed was Pfizer's PF-2341066, now known as crizotinib, a dual ALK/cMet inhibitor with efficacy in experimental models of ALCL, ALK⁺ [110]. However, these drugs have been slow to make their way into the clinic for the treatment of ALCL, largely due to its relative rarity and paediatric presentation. A phase I study of crizotinib for children with relapsed/refractory ALK⁺ malignancies including ALCL, reported seven out of nine patients to achieve a complete response (CR) [111]. A phase II expansion cohort showed overall response rates of 83 and 90% respectively for those children receiving crizotinib at dosages of 165 and 280 mg/m² respectively [112]. However, discontinuation of therapy has led to rapid relapse of both children and adults with ALCL, ALK⁺ questioning the required window of therapy [113].

Naturally, ALK inhibitors only apply to the therapy of ALCL, ALK⁺. In contrast, the common expression of CD30 on all ALCL sub-types means that targeted agents to this cell surface protein should be broadly applicable [114]. In this vein, BV, an anti-CD30 antibody tethered to the microtubule inhibitor monomethyl auristatin E, has shown promising results in clinical trials, although relapse is again an issue with down-regulation of CD30 expression seen [115–117]. However, results of the Phase 3 ALCANZA trial for pcALCL and MF showed impressive results with an objective response rate of 67% in the BV arm (versus 20% in the standard treatment arm: methotrexate or bexarotene) [118]. However, BV is not without its side-effects with peripheral neuropathy being prominent (affecting 67% of patients in the afore-mentioned trial) [118]. Likewise, results of a Phase 2 trial of relapsed/refractory sALCL showed peripheral neuropathy to be a considerable side-effect in 91% of patients although a 5-year OS of 79% was achieved (69% CR, 80% ORR for ALK⁺ patients and 52% CR, 81% ORR for ALK[−]) [119]. A randomised Phase 3 trial to establish the efficacy of BV in combination with cyclophosphamide, doxorubicin and prednisolone, in comparison to these chemotherapeutic agents given with vincristine in place of BV, is ongoing for the frontline treatment of CD30-positive lymphomas including ALCL (ECHELON 2; NCT01777152). Other potential therapeutic targets for the treatment of ALCL include PDGFR, JAK/STAT, PD-1/PDL1 and reactivation of p53 [42, 44, 120, 121].

Indeed, biological studies have identified a number of potential therapeutic targets, which in some cases, and with time, have been matched to available drugs. However, with relatively few patients, coupled with a good prognosis, at least for children with ALK+ systemic disease, it is difficult to formulate trials to test these agents.

A further approach given the immune response to ALK in patients with ALK-positive disease, is a vaccination strategy [122]. This is especially relevant as ALK expression seems to be limited to tissues of neonatal origin suggesting that side-effects will be limited [123].

6. The origins and pathogenesis of ALCL: a common origin with distinct pathogenesis or different origins converging on a shared histopathology?

6.1 Cell of origin

Systemic ALCL presents in the periphery suggestive of a peripheral T cell origin, although as many as 50% of children show mediastinal involvement [29]. In this latter vein, a thymic origin has been proposed whereby gene expression signatures associated with early thymic progenitors (ETP) are detected in ALCL cancer stem cells, in fitting with the detection of transcripts for the t(2;5)(p23;q35) translocation breakpoint product in 2% of cord blood specimens from healthy babies [124, 125]. In addition, studies of epigenetic signatures are in keeping with an ETP origin [49]. As such, it is not inconceivable that ALCL, ALK+ has a thymic, perhaps *in utero* origin in-line with the pathogenesis of paediatric leukaemias [29]. Additionally, this is in keeping with a paediatric presentation and the early-life involution of the thymus. Furthermore, studies of murine models show that events in the periphery once incipient tumour cells emerge from the thymus contribute to disease pathogenesis as discussed below [30].

While ALCL, ALK+ is proposed to emerge from the thymus, a similar origin likely does not apply to ALK-negative disease, including pcALCL, BIA-ALCL and ALCL, ALK-. In these latter cases, circulating peripheral T cells are most probably the cells of origin given the older age of diagnosis and peripheral location, particularly with regards to BIA-ALCL and pcALCL. If this is the case, if the type of T cell that becomes transformed can be identified, this may give clues as to disease pathogenesis. While histopathology indicating an activated CD30-expressing T cell producing cytotoxic proteins, yet also often retaining CD4 expression, has given rise to a presumed cytotoxic T cell origin, recent data challenges this perception [29, 126]. Specifically, analysis of gene expression data suggests a Th17 origin, a T cell that usually responds to large extracellular infectious agents such as bacteria and is often implicated in autoimmune disease [89, 127]. However, given that ALCL often lack expression of TCR-related signalling proteins as well as a functional cell surface TCR, analogies to innate lymphoid cells (ILC), specifically ILC type 3 cells are also apparent [127]. Naturally, the eventual cell phenotype is not necessarily reflective of the cell of origin with environmental events likely contributing to the final observed identity. In this regard, whether in ALCL, ALK+ this is shaped by ALK-mediated activities (or is the consequence of other induced (epi)genetic events) remains to be fully elucidated as it does for other ALCL sub-types. In evidence, it has been shown that NPM-ALK induces expression of cytotoxic proteins suggesting that their presence reflects the activities of this inherent transforming event rather than a property of the cell of origin, at least for ALCL, ALK+ [128]. This would

partly explain the ‘confused’ T cell phenotype with both helper and cytotoxic T cell properties apparent. Indeed, plasticity amongst helper T cell subsets is immense and is dependent on the relative expression levels of key transcription factors such as T-bet, ROR γ , GATA-3 and Foxp3 as well as cytokines in the microenvironment [129]. Hence, for a T cell aberrantly expressing a variety of genetic changes, embedded in specific inflammatory microenvironments, the resultant cell surface phenotype may no longer reflect the cell of origin.

Another factor to consider is genetic predisposition or health status of the patients whereby some, with for example, autoimmune disease or allergies and a preponderance of Th17 or Th1/Th2 cells respectively may be more at risk, with the resultant tumour phenotype dependent on this. In evidence, at least for BIA-ALCL Th1, Th2 and Th17 origins have been proposed based on the profile of secreted cytokines and expression of specific transcription factors, although of course none of these factors in isolation are necessarily truly indicative of the cell of origin, and as mentioned before, the contribution of the microenvironment cannot be discounted [88–90].

6.2 An infectious aetiology?

The common expression of CD30 on all entities of ALCL is suggestive of an infectious aetiology whereby activation of the underlying T cells triggers expression of this cell surface protein. However, individual cell surface proteins in isolation are not necessarily indicative of the cell of origin of any given cancer, which combined with the propensity of cancer cells to aberrantly up- or down-regulate expression of proteins according to evolutionary fitness necessitates further evidence to draw conclusive decisions. Yet, in evidence of an infectious aetiology,

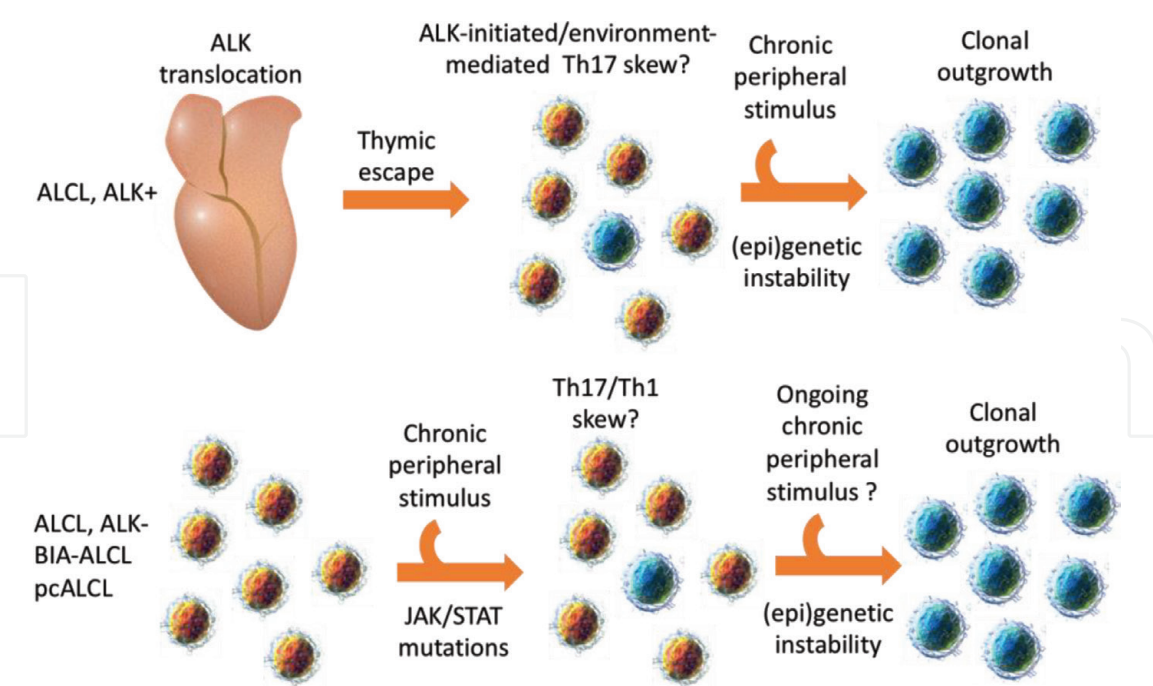


Figure 2.
Proposed mechanisms of tumorigenesis for ALCL. Data suggest that the NPM-ALK generating chromosomal translocation occurs in primitive haemopoietic cells, such as early thymic progenitors, whereby aberrant TCR rearrangements are tolerated [30]. Incipient tumour cells then exit into the periphery where secondary events lead to transformation. Conversely, systemic ALCL, ALK–, pcALCL and BIA-ALCL more likely initiate in circulating peripheral T cells whereby chronic antigenic stimulation mediated by infectious agents, an inflammatory milieu and/or toxic insult leads to the acquisition of malignancy-promoting mutations and cellular transformation.

sALCL have been reported in the context of insect and tick bites, as well as bacterial infections on the surface of breast implants in BIA-ALCL and in association with cutaneous T cell lymphomas whereby TLRs 2, 4 and 7 are expressed by tumour cells [130–132]. Such infectious aetiologies would also produce an inflammatory microenvironment dictated by the infectious agent whereby cytokines, growth factors and many cell types involved in inflammation would be present and may contribute to disease pathogenesis. In this regard, the lymphohistiocytic subtype of sALCL is, as its name suggests, infiltrated with macrophages and many cytokines have been detected at elevated levels in patients diagnosed with ALCL, ALK+ [26, 133] (**Figure 2**).

7. Conclusions

ALCL is a diverse disease entity affecting a range of patients ranging from children to women with breast implants. What is clear, is that all ALCL share some common immunohistopathological features, most prominently CD30 expression, but the clinical courses of these diseases vary considerably from the indolent LPD, pcALCL through to aggressive, poor prognostic malignancies such as sALCL, ALK–. Our understanding of the underlying biology is improving year on year and has had a significant impact on clinical decision making including therapeutic approaches. While for many forms of ALCL, therapy has not altered considerably over the past decade, novel targeted approaches to treatment are entering the clinical arena ranging from monoclonal antibodies to kinase inhibitors. Indeed, we are now in the fortunate position whereby there are a plethora of therapeutic agents, but too few patients to trial them.

Acknowledgements

I would like to acknowledge all authors that have contributed to our understanding of ALCL who could not be cited due to page length restrictions.

Conflict of interest

The author declares no conflicts of interest.

IntechOpen


IntechOpen

Author details

Suzanne D. Turner
Department of Pathology, University of Cambridge, Cambridge, UK

*Address all correspondence to: sdt36@cam.ac.uk

IntechOpen

© 2018 The Author(s). Licensee IntechOpen. This chapter is distributed under the terms of the Creative Commons Attribution License (<http://creativecommons.org/licenses/by/3.0>), which permits unrestricted use, distribution, and reproduction in any medium, provided the original work is properly cited. 

References

- [1] Stein H et al. The expression of the Hodgkin's disease associated antigen Ki-1 in reactive and neoplastic lymphoid tissue: Evidence that Reed-Sternberg cells and histiocytic malignancies are derived from activated lymphoid cells. *Blood*. 1985;**66**(4):848-858
- [2] Kaneko Y et al. A novel translocation, t(2,5)(p23;q35), in childhood phagocytic large T-cell lymphoma mimicking malignant histiocytosis. *Blood*. 1989;**73**(3):806-813
- [3] Le Beau MM et al. The t(2;5)(p23;q35): A recurring chromosomal abnormality in Ki-1-positive anaplastic large cell lymphoma. *Leukemia*. 1989;**3**(12):866-870
- [4] Bitter MA et al. Morphology in Ki-1(CD30)-positive non-Hodgkin's lymphoma is correlated with clinical features and the presence of a unique chromosomal abnormality, t(2;5)(p23;q35). *The American Journal of Surgical Pathology*. 1990;**14**(4):305-316
- [5] Rimokh R et al. A translocation involving a specific breakpoint (q35) on chromosome 5 is characteristic of anaplastic large cell lymphoma ('Ki-1 lymphoma'). *British Journal of Haematology*. 1989;**71**(1):31-36
- [6] Morris SW et al. Fusion of a kinase gene, ALK, to a nucleolar protein gene, NPM, in non-Hodgkin's lymphoma. *Science*. 1994;**263**(5151):1281-1284
- [7] Swerdlow SH. WHO Classification of Tumours of Haematopoietic and Lymphoid Tissues. Lyon: International Agency for Research on Cancer; 2008. 439 p
- [8] Swerdlow SH et al. The 2016 revision of the World Health Organization classification of lymphoid neoplasms. *Blood*. 2016;**127**(20):2375-2390
- [9] Swerdlow SH. World Health Organization, and International Agency for Research on Cancer. In: WHO Classification of Tumours of Haematopoietic and Lymphoid Tissues. Revised 4th ed. World Health Organization Classification of Tumours; 2017. p. 585
- [10] Minard-Colin V et al. Non-Hodgkin lymphoma in children and adolescents: Progress through effective collaboration, current knowledge, and challenges ahead. *Journal of Clinical Oncology*. 2015;**33**(27):2963-2974
- [11] Turner SD et al. Anaplastic large cell lymphoma in paediatric and young adult patients. *British Journal of Haematology*. 2016;**173**(4):560-572
- [12] Le Deley MC et al. Prognostic factors in childhood anaplastic large cell lymphoma: Results of a large European intergroup study. *Blood*. 2008;**111**(3):1560-1566
- [13] Le Deley MC et al. Vinblastine in children and adolescents with high-risk anaplastic large-cell lymphoma: Results of the randomized ALCL99-vinblastine trial. *Journal of Clinical Oncology*. 2010;**28**(25):3987-3993
- [14] Prokoph N et al. Treatment options for paediatric anaplastic large cell lymphoma (ALCL): Current standard and beyond. *Cancers (Basel)*. 2018 Mar 30;**10**(4). pii: E99. DOI: 10.3390/cancers10040099
- [15] d'Amore ES et al. Anaplastic large cell lymphomas: A study of 75 pediatric patients. *Pediatric and Developmental Pathology*. 2007;**10**(3):181-191
- [16] ten Berge RL et al. ALK-negative anaplastic large-cell lymphoma demonstrates similar poor prognosis to peripheral T-cell lymphoma,

unspecified. Histopathology. 2003;**43**(5):462-469

[17] Savage KJ et al. ALK-anaplastic large-cell lymphoma is clinically and immunophenotypically different from both ALK+ ALCL and peripheral T-cell lymphoma, not otherwise specified: Report from the international peripheral T-cell lymphoma project. *Blood*. 2008;**111**(12):5496-5504

[18] Gascoyne RD et al. Prognostic significance of anaplastic lymphoma kinase (ALK) protein expression in adults with anaplastic large cell lymphoma. *Blood*. 1999;**93**(11):3913-3921

[19] Parrilla Castellar ER et al. ALK-negative anaplastic large cell lymphoma is a genetically heterogeneous disease with widely disparate clinical outcomes. *Blood*. 2014;**124**(9):1473-1480

[20] Sibon D et al. Long-term outcome of adults with systemic anaplastic large-cell lymphoma treated within the Groupe d'Etude des Lymphomes de l'Adulte trials. *Journal of Clinical Oncology*. 2012;**30**(32):3939-3946

[21] Ait-Tahar K, Barnardo MC, Pulford K. CD4 T-helper responses to the anaplastic lymphoma kinase (ALK) protein in patients with ALK-positive anaplastic large-cell lymphoma. *Cancer Research*. 2007;**67**(5):1898-1901

[22] Ait-Tahar K et al. B and CTL responses to the ALK protein in patients with ALK-positive ALCL. *International Journal of Cancer*. 2006;**118**(3):688-695

[23] Pulford K et al. Immune response to the ALK oncogenic tyrosine kinase in patients with anaplastic large-cell lymphoma. *Blood*. 2000;**96**(4):1605-1607

[24] Ait-Tahar K et al. Correlation of the autoantibody response to the ALK

oncoantigen in pediatric anaplastic lymphoma kinase-positive anaplastic large cell lymphoma with tumor dissemination and relapse risk. *Blood*. 2010;**115**(16):3314-3319

[25] Mussolin L et al. Kinetics of humoral response to ALK and its relationship with minimal residual disease in pediatric ALCL. *Leukemia*. 2009;**23**(2):400-402

[26] Benharroch D et al. ALK-positive lymphoma: A single disease with a broad spectrum of morphology. *Blood*. 1998;**91**(6):2076-2084

[27] Lamant L et al. Prognostic impact of morphologic and phenotypic features of childhood ALK-positive anaplastic large-cell lymphoma: Results of the ALCL99 study. *Journal of Clinical Oncology*. 2011;**29**(35):4669-4676

[28] Montes-Mojarro IA et al. The pathological Spectrum of systemic anaplastic large cell lymphoma (ALCL). *Cancers (Basel)*. 2018 Apr 4;**10**(4). pii: E107. DOI: 10.3390/cancers10040107

[29] Malcolm TI et al. Challenging perspectives on the cellular origins of lymphoma. *Open Biology*. 2016 Sep;**6**(9). pii: 160232

[30] Malcolm TI et al. Anaplastic large cell lymphoma arises in thymocytes and requires transient TCR expression for thymic egress. *Nature Communications*. 2016;**7**:10087

[31] Youssif C et al. Genomic profiling of pediatric ALK-positive anaplastic large cell lymphoma: A Children's Cancer and Leukaemia Group Study. *Genes, Chromosomes & Cancer*. 2009;**48**(11):1018-1026

[32] Salaverria I et al. Genomic profiling reveals different genetic aberrations in systemic ALK-positive and ALK-negative anaplastic large cell lymphomas. *British Journal of*

Haematology. 2008;**140**(5):516-526

[33] Duyster J, Bai RY, Morris SW. Translocations involving anaplastic lymphoma kinase (ALK). *Oncogene*. 2001;**20**(40):5623-5637

[34] Shiota M, Mori S. Anaplastic large cell lymphomas expressing the novel chimeric protein p80NPM/ALK: A distinct clinicopathologic entity. *Leukemia*. 1997;**11**(Suppl 3):538-540

[35] Crockett DK et al. Identification of NPM-ALK interacting proteins by tandem mass spectrometry. *Oncogene*. 2004;**23**(15):2617-2629

[36] Marzec M et al. Oncogenic tyrosine kinase NPM/ALK induces activation of the rapamycin-sensitive mTOR signaling pathway. *Oncogene*. 2007;**26**(38):5606-5614

[37] Marzec M et al. Oncogenic tyrosine kinase NPM/ALK induces activation of the MEK/ERK signaling pathway independently of c-Raf. *Oncogene*. 2007;**26**(6):813-821

[38] Turner SD et al. The NPM-ALK tyrosine kinase mimics TCR signalling pathways, inducing NFAT and AP-1 by RAS-dependent mechanisms. *Cellular Signalling*. 2007;**19**(4):740-747

[39] Turner SD et al. Vav-promoter regulated oncogenic fusion protein NPM-ALK in transgenic mice causes B-cell lymphomas with hyperactive Jun kinase. *Oncogene*. 2003;**22**(49):7750-7761

[40] Zamo A et al. Anaplastic lymphoma kinase (ALK) activates Stat3 and protects hematopoietic cells from cell death. *Oncogene*. 2002;**21**(7):1038-1047

[41] Bai RY et al. Nucleophosmin-anaplastic lymphoma kinase of large-cell anaplastic lymphoma is a constitutively active tyrosine

kinase that utilizes phospholipase C-gamma to mediate its mitogenicity. *Molecular and Cellular Biology*. 1998;**18**(12):6951-6961

[42] Cui YX et al. NPM-ALK inhibits the p53 tumor suppressor pathway in an MDM2 and JNK-dependent manner. *Blood*. 2009;**113**(21):5217-5227

[43] Ambrogio C et al. NPM-ALK oncogenic tyrosine kinase controls T-cell identity by transcriptional regulation and epigenetic silencing in lymphoma cells. *Cancer Research*. 2009;**69**(22):8611-8619

[44] Marzec M et al. Oncogenic kinase NPM/ALK induces through STAT3 expression of immunosuppressive protein CD274 (PD-L1, B7-H1). *Proceedings of the National Academy of Sciences of the United States of America*. 2008;**105**(52):20852-20857

[45] Zhang Q et al. IL-2R common gamma-chain is epigenetically silenced by nucleophosmin-anaplastic lymphoma kinase (NPM-ALK) and acts as a tumor suppressor by targeting NPM-ALK. *Proceedings of the National Academy of Sciences of the United States of America*. 2011;**108**(29):11977-11982

[46] Zhang Q et al. STAT5A is epigenetically silenced by the tyrosine kinase NPM1-ALK and acts as a tumor suppressor by reciprocally inhibiting NPM1-ALK expression. *Nature Medicine*. 2007;**13**(11):1341-1348

[47] Zhang Q et al. STAT3 induces transcription of the DNA methyltransferase 1 gene (DNMT1) in malignant T lymphocytes. *Blood*. 2006;**108**(3):1058-1064

[48] McDonnell SR et al. Integrated phosphoproteomic and metabolomic profiling reveals NPM-ALK-mediated phosphorylation of PKM2 and metabolic reprogramming in

anaplastic large cell lymphoma. *Blood*. 2013;**122**(6):958-968

[49] Hassler MR et al. Insights into the pathogenesis of anaplastic large-cell lymphoma through genome-wide DNA methylation profiling. *Cell Reports*. 2016;**17**(2):596-608

[50] Merkel O et al. Identification of differential and functionally active miRNAs in both anaplastic lymphoma kinase (ALK)+ and ALK- anaplastic large-cell lymphoma. *Proceedings of the National Academy of Sciences of the United States of America*. 2010;**107**(37):16228-16233

[51] Bonzheim I et al. Anaplastic large cell lymphomas lack the expression of T-cell receptor molecules or molecules of proximal T-cell receptor signaling. *Blood*. 2004;**104**(10):3358-3360

[52] Marzec M et al. Malignant transformation of CD4+ T lymphocytes mediated by oncogenic kinase NPM/ ALK recapitulates IL-2-induced cell signaling and gene expression reprogramming. *Journal of Immunology*. 2013;**191**(12):6200-6207

[53] Matsuyama H et al. miR-135b mediates NPM-ALK-driven oncogenicity and renders IL-17-producing immunophenotype to anaplastic large cell lymphoma. *Blood*. 2011;**118**(26):6881-6892

[54] Desjobert C et al. MiR-29a down-regulation in ALK-positive anaplastic large cell lymphomas contributes to apoptosis blockade through MCL-1 overexpression. *Blood*. 2011;**117**(24):6627-6637

[55] Dejean E et al. Hypoxia-microRNA-16 downregulation induces VEGF expression in anaplastic lymphoma kinase (ALK)-positive anaplastic large-cell lymphomas. *Leukemia*. 2011 Dec;**25**(12):1882-1890. DOI: 10.1038/leu.2011.168. Epub 2011 Jul 22

[56] Spaccarotella E et al. STAT3-mediated activation of microRNA cluster 17~92 promotes proliferation and survival of ALK-positive anaplastic large cell lymphoma. *Haematologica*. 2014;**99**(1):116-124

[57] Crescenzo R et al. Convergent mutations and kinase fusions lead to oncogenic STAT3 activation in anaplastic large cell lymphoma. *Cancer Cell*. 2015;**27**(4):516-532

[58] Feldman AL et al. Discovery of recurrent t(6;7)(p25.3;q32.3) translocations in ALK-negative anaplastic large cell lymphomas by massively parallel genomic sequencing. *Blood*. 2011;**117**(3):915-919

[59] Vasmataz G et al. Genome-wide analysis reveals recurrent structural abnormalities of TP63 and other p53-related genes in peripheral T-cell lymphomas. *Blood*. 2012;**120**(11):2280-2289

[60] Scarfo I et al. Identification of a new subclass of ALK-negative ALCL expressing aberrant levels of ERBB4 transcripts. *Blood*. 2016;**127**(2):221-232

[61] Merkel O et al. Oncogenic role of miR-155 in anaplastic large cell lymphoma lacking the t(2;5) translocation. *The Journal of Pathology*. 2015 Aug;**236**(4):445-456. DOI: 10.1002/path.4539. Epub 2015 Apr 27

[62] Steinhilber J et al. Next-generation sequencing identifies deregulation of microRNAs involved in both innate and adaptive immune response in ALK+ ALCL. *PLoS One*. 2015;**10**(2):e0117780

[63] Laginestra MA et al. Pathogenetic and diagnostic significance of microRNA deregulation in peripheral T-cell lymphoma not otherwise specified. *Blood Cancer Journal*. 2014;**4**:259

- [64] Liu C et al. MicroRNA expression profiling identifies molecular signatures associated with anaplastic large cell lymphoma. *Blood*. 2013;**122**(12):2083-2092
- [65] Piva R et al. Gene expression profiling uncovers molecular classifiers for the recognition of anaplastic large-cell lymphoma within peripheral T-cell neoplasms. *Journal of Clinical Oncology*. 2010;**28**(9):1583-1590
- [66] Piccaluga PP et al. Molecular profiling improves classification and prognostication of nodal peripheral T-cell lymphomas: Results of a phase III diagnostic accuracy study. *Journal of Clinical Oncology*. 2013;**31**(24):3019-3025
- [67] Agnelli L et al. Identification of a 3-gene model as a powerful diagnostic tool for the recognition of ALK-negative anaplastic large-cell lymphoma. *Blood*. 2012;**120**(6):1274-1281
- [68] Iqbal J et al. Molecular signatures to improve diagnosis in peripheral T-cell lymphoma and prognostication in angioimmunoblastic T-cell lymphoma. *Blood*. 2010;**115**(5):1026-1036
- [69] Boi M et al. PRDM1/BLIMP1 is commonly inactivated in anaplastic large T-cell lymphoma. *Blood*. 2013;**122**(15):2683-2693
- [70] Keech JA Jr, Creech BJ. Anaplastic T-cell lymphoma in proximity to a saline-filled breast implant. *Plastic and Reconstructive Surgery*. 1997;**100**(2):554-555
- [71] Administration, U.F.a.D. Anaplastic large cell lymphoma (ALCL) in women with breast implants: Preliminary findings and analyses. 2011. Available from: <http://wayback.archive-it.org/7993/20171115053750/https://www.fda.gov/MedicalDevices/ProductsandMedicalProcedures/ImplantsandProsthetics/BreastImplants/ucm239996.htm>
- [72] Ministere des affaires sociales, d.l.s.e.d.d.f., La France reste vigilante pour detecter rapidement les cas de lymphomes parmi les femmes porteuses d'implants mammaires. 2015
- [73] Administration, U.F.a.D., Breast Implant-Associated Anaplastic Large Cell Lymphoma (BIA-ALCL). 2017
- [74] Antonella C, Rosaria B, Marcella M. 22 cases of BIA-ALCL: Awareness and outcome tracking from the Italian Ministry of Health. *Plastic and Reconstructive Surgery*. 2017
- [75] Johnson L et al. Breast implant associated anaplastic large cell lymphoma: The UK experience. Recommendations on its management and implications for informed consent. *European Journal of Surgical Oncology*. 2017;**43**(8):1393-1401
- [76] de Jong D et al. Anaplastic large-cell lymphoma in women with breast implants. *JAMA*. 2008;**300**(17):2030-2035
- [77] Laurent C et al. Breast implant-associated anaplastic large cell lymphoma: Two distinct clinicopathological variants with different outcomes. *Annals of Oncology*. 2016;**27**(2):306-314
- [78] Clemens MW, Miranda RN. Coming of age: Breast implant-associated anaplastic large cell lymphoma after 18 years of investigation. *Clinics in Plastic Surgery*. 2015;**42**(4):605-613
- [79] Doren EL et al. U.S. epidemiology of breast implant-associated anaplastic large cell lymphoma. *Plastic and Reconstructive Surgery*. 2017;**139**(5):1042-1050

- [80] Srinivasa DR et al. Global adverse event reports of breast implant-associated ALCL: An international review of 40 government authority databases. *Plastic and Reconstructive Surgery*. 2017;**139**(5):1029-1039
- [81] Ramos-Gallardo G et al. Is Latin America Ready to Identify Anaplastic Large Cell Lymphoma in Breast Implants Patients? Regional Encounter during the National Plastic Surgery Meeting in Cancun. Mexico: *Aesthetic Plast Surg*; 2018
- [82] McGuire P, Reisman NR, Murphy DK. Risk factor analysis for capsular contracture, malposition, and late Seroma in subjects receiving Natrelle 410 form-stable silicone breast implants. *Plastic and Reconstructive Surgery*. 2017;**139**(1):1-9
- [83] de Boer M et al. Breast implants and the risk of anaplastic large-cell lymphoma in the breast. *JAMA Oncology*. 2018;**4**:335-341
- [84] Loch-Wilkinson A et al. Breast implant-associated anaplastic large cell lymphoma in Australia and New Zealand: High-surface-area textured implants are associated with increased risk. *Plastic and Reconstructive Surgery*. 2017;**140**(4):645-654
- [85] Clemens MW, Horwitz SM. NCCN consensus guidelines for the diagnosis and management of breast implant-associated anaplastic large cell lymphoma. *Aesthetic Surgery Journal*. 2017;**37**(3):285-289
- [86] Clemens MW et al. Complete surgical excision is essential for the management of patients with breast implant-associated anaplastic large-cell lymphoma. *Journal of Clinical Oncology*. 2016;**34**(2):160-168
- [87] Ye X et al. Anaplastic large cell lymphoma (ALCL) and breast implants: Breaking down the evidence. *Mutation Research, Reviews in Mutation Research*. 2014;**762**:123-132
- [88] Lechner MG et al. Survival signals and targets for therapy in breast implant-associated ALK—Anaplastic large cell lymphoma. *Clinical Cancer Research*. 2012;**18**(17):4549-4559
- [89] Kadin ME et al. Biomarkers provide clues to early events in the pathogenesis of breast implant-associated anaplastic large cell lymphoma. *Aesthetic Surgery Journal*. 2016;**36**(7):773-781
- [90] Kadin ME et al. IL-13 is produced by tumor cells in breast implant associated anaplastic large cell lymphoma: Implications for pathogenesis. *Human Pathology*. 2018 Aug;**78**:54-62. DOI: 10.1016/j.humpath.2018.04.007. Epub 2018 Apr 22
- [91] Blombery P et al. Whole exome sequencing reveals activating JAK1 and STAT3 mutations in breast implant-associated anaplastic large cell lymphoma anaplastic large cell lymphoma. *Haematologica*. 2016;**101**(9):e387-e390
- [92] Di Napoli A et al. Targeted next generation sequencing of breast implant-associated anaplastic large cell lymphoma reveals mutations in JAK/STAT signalling pathway genes, TP53 and DNMT3A. *British Journal of Haematology*. 2018;**180**(5):741-744
- [93] Bekkenk MW et al. Primary and secondary cutaneous CD30(+) lymphoproliferative disorders: A report from the Dutch cutaneous lymphoma group on the long-term follow-up data of 219 patients and guidelines for diagnosis and treatment. *Blood*. 2000;**95**(12):3653-3661
- [94] Liu HL et al. CD30+ cutaneous lymphoproliferative disorders: The Stanford experience in lymphomatoid

papulosis and primary cutaneous anaplastic large cell lymphoma. *Journal of the American Academy of Dermatology*. 2003;**49**(6):1049-1058

[95] Kempf W et al. EORTC, ISCL, and USCLC consensus recommendations for the treatment of primary cutaneous CD30-positive lymphoproliferative disorders: Lymphomatoid papulosis and primary cutaneous anaplastic large-cell lymphoma. *Blood*. 2011;**118**(15):4024-4035

[96] Krishnan J, Tomaszewski MM, Kao GF. Primary cutaneous CD30-positive anaplastic large cell lymphoma. Report of 27 cases. *Journal of Cutaneous Pathology*. 1993;**20**(3):193-202

[97] Kiran T et al. The significance of MUM1/IRF4 protein expression and IRF4 translocation of CD30(+) cutaneous T-cell lymphoproliferative disorders: A study of 53 cases. *Leukemia Research*. 2013;**37**(4):396-400

[98] Geller S et al. ALK-positive primary cutaneous anaplastic large cell lymphoma: A case report and review of the literature. *International Journal of Dermatology*. 2018;**57**(5):515-520

[99] Wada DA et al. Specificity of IRF4 translocations for primary cutaneous anaplastic large cell lymphoma: A multicenter study of 204 skin biopsies. *Modern Pathology*. 2011;**24**(4):596-605

[100] Pham-Ledard A et al. IRF4 gene rearrangements define a subgroup of CD30-positive cutaneous T-cell lymphoma: A study of 54 cases. *The Journal of Investigative Dermatology*. 2010;**130**(3):816-825

[101] Feldman AL et al. Recurrent translocations involving the IRF4 oncogene locus in peripheral T-cell lymphomas. *Leukemia*. 2009;**23**(3):574-580

[102] Szuhai K et al. Array-CGH analysis of cutaneous anaplastic large cell lymphoma. *Methods in Molecular Biology*. 2013;**973**:197-212

[103] Benner MF et al. Primary cutaneous anaplastic large cell lymphoma shows a distinct miRNA expression profile and reveals differences from tumor-stage mycosis fungoides. *Experimental Dermatology*. 2012;**21**(8):632-634

[104] Garner R et al. Long-term disease control of refractory anaplastic large cell lymphoma with vinblastine. *Journal of Pediatric Hematology/Oncology*. 2009;**31**(2):145-147

[105] Brugieres L et al. Single-drug vinblastine as salvage treatment for refractory or relapsed anaplastic large-cell lymphoma: A report from the French Society of Pediatric Oncology. *Journal of Clinical Oncology*. 2009;**27**(30):5056-5061

[106] Cederleuf H et al. The addition of etoposide to CHOP is associated with improved outcome in ALK+ adult anaplastic large cell lymphoma: A Nordic Lymphoma Group study. *British Journal of Haematology*. 2017;**178**(5):739-746

[107] Alderuccio JP et al. Frontline brentuximab vedotin in breast implant-associated anaplastic large-cell lymphoma. *Clinical Case Reports*. 2018;**6**(4):634-637

[108] Melchers RC et al. Evaluation of treatment results in multifocal primary cutaneous anaplastic large cell lymphoma: Report of the Dutch Cutaneous Lymphoma Group. *The British Journal of Dermatology*. 2018 Sep;**179**(3):724-731. DOI: 10.1111/bjd.16501. Epub 2018 Jun 21

[109] Melchers RC et al. Recommendations for the optimal radiation dose in patients with

primary cutaneous anaplastic large cell lymphoma: A report of the Dutch cutaneous lymphoma group. *International Journal of Radiation Oncology, Biology, Physics*. 2017;**99**(5):1279-1285

[110] Christensen JG et al. Cytoreductive antitumor activity of PF-2341066, a novel inhibitor of anaplastic lymphoma kinase and c-Met, in experimental models of anaplastic large-cell lymphoma. *Molecular Cancer Therapeutics*. 2007;**6**(12 Pt 1): 3314-3322

[111] Mosse YP et al. Safety and activity of crizotinib for paediatric patients with refractory solid tumours or anaplastic large-cell lymphoma: A Children's Oncology Group phase 1 consortium study. *The Lancet Oncology*. 2013;**14**(6):472-480

[112] Mosse YP et al. Targeting ALK with Crizotinib in pediatric anaplastic large cell lymphoma and inflammatory myofibroblastic tumor: A Children's oncology group study. *Journal of Clinical Oncology*. 2017;**35**(28):3215-3221

[113] Gambacorti-Passerini C, Mussolin L, Brugieres L. Abrupt relapse of ALK-positive lymphoma after discontinuation of Crizotinib. *The New England Journal of Medicine*. 2016;**374**(1):95-96

[114] Senter PD, Sievers EL. The discovery and development of brentuximab vedotin for use in relapsed Hodgkin lymphoma and systemic anaplastic large cell lymphoma. *Nature Biotechnology*. 2012;**30**(7):631-637

[115] Nielson C et al. Loss of CD30 expression in anaplastic large cell lymphoma following brentuximab therapy. *Journal of Drugs in Dermatology*. 2016;**15**(7): 894-895

[116] Arai H et al. ALK-negative anaplastic large cell lymphoma with loss of CD30 expression during treatment with brentuximab vedotin. *Rinshō Ketsueki*. 2016;**57**(5):634-637

[117] Pro B et al. Brentuximab vedotin (SGN-35) in patients with relapsed or refractory systemic anaplastic large-cell lymphoma: Results of a phase II study. *Journal of Clinical Oncology*. 2012;**30**(18):2190-2196

[118] Prince HM et al. Brentuximab vedotin or physician's choice in CD30-positive cutaneous T-cell lymphoma (ALCANZA): An international, open-label, randomised, phase 3, multicentre trial. *Lancet*. 2017;**390**(10094):555-566

[119] Pro B et al. Five-year results of brentuximab vedotin in patients with relapsed or refractory systemic anaplastic large cell lymphoma. *Blood*. 2017;**130**(25):2709-2717

[120] Laimer D et al. PDGFR blockade is a rational and effective therapy for NPM-ALK-driven lymphomas. *Nature Medicine*. 2012;**18**(11):1699-1704

[121] Chen J et al. Cytokine receptor signaling is required for the survival of ALK– anaplastic large cell lymphoma, even in the presence of JAK1/STAT3 mutations. *Proceedings of the National Academy of Sciences of the United States of America*. 2017;**114**(15):3975-3980

[122] Chiarle R et al. The anaplastic lymphoma kinase is an effective oncoantigen for lymphoma vaccination. *Nature Medicine*. 2008;**14**(6): 676-680

[123] Pulford K et al. Detection of anaplastic lymphoma kinase (ALK) and nucleolar protein nucleophosmin (NPM)-ALK proteins in normal and neoplastic cells with the

monoclonal antibody ALK1. *Blood*. 1997;**89**(4):1394-1404

[124] Moti N et al. Anaplastic large cell lymphoma-propagating cells are detectable by side population analysis and possess an expression profile reflective of a primitive origin. *Oncogene*. 2015 Apr 2;**34**(14):1843-1852. DOI: 10.1038/onc.2014.112. Epub 2014 May 12

[125] Laurent C et al. Circulating t(2;5)-positive cells can be detected in cord blood of healthy newborns. *Leukemia*. 2012;**26**(1):188-190

[126] Kasprzycka M et al. Nucleophosmin/anaplastic lymphoma kinase (NPM/ALK) oncoprotein induces the T regulatory cell phenotype by activating STAT3. *Proceedings of the National Academy of Sciences of the United States of America*. 2006;**103**(26):9964-9969

[127] Schleussner N et al. The AP-1-BATF and -BATF3 module is essential for growth, survival and TH17/ILC3 skewing of anaplastic large cell lymphoma. *Leukemia*. 2018 Sep;**32**(9):1994-2007. DOI: 10.1038/s41375-018-0045-9. Epub 2018 Mar 28

[128] Pearson JD et al. NPM-ALK and the JunB transcription factor regulate the expression of cytotoxic molecules in ALK-positive, anaplastic large cell lymphoma. *International Journal of Clinical and Experimental Pathology*. 2011;**4**(2):124-133

[129] Tripathi SK, Lahesmaa R. Transcriptional and epigenetic regulation of T-helper lineage specification. *Immunological Reviews*. 2014;**261**(1):62-83

[130] Lamant L et al. Cutaneous presentation of ALK-positive anaplastic large cell lymphoma following insect bites: Evidence for an association

in five cases. *Haematologica*. 2010;**95**(3):449-455

[131] Piccaluga PP et al. Anaplastic lymphoma kinase expression as a marker of malignancy. Application to a case of anaplastic large cell lymphoma with huge granulomatous reaction. *Haematologica*. 2000;**85**(9):978-981

[132] Hu H et al. Bacterial biofilm infection detected in breast implant-associated anaplastic large-cell lymphoma. *Plastic and Reconstructive Surgery*. 2016;**137**(6):1659-1669

[133] Knorr F et al. Blood cytokine concentrations in pediatric patients with anaplastic lymphoma kinase-positive anaplastic large cell lymphoma. *Haematologica*. 2018;**103**(3):477-485

[134] Hernandez L et al. Diversity of genomic breakpoints in TFG-ALK translocations in anaplastic large cell lymphomas: Identification of a new TFG-ALK(XL) chimeric gene with transforming activity. *The American Journal of Pathology*. 2002;**160**(4):1487-1494

[135] Hernandez L et al. TRK-fused gene (TFG) is a new partner of ALK in anaplastic large cell lymphoma producing two structurally different TFG-ALK translocations. *Blood*. 1999;**94**(9):3265-3268

[136] Lamant L et al. A new fusion gene TPM3-ALK in anaplastic large cell lymphoma created by a (1;2) (q25;p23) translocation. *Blood*. 1999;**93**(9):3088-3095

[137] Wlodarska I et al. The cryptic inv(2) (p23q35) defines a new molecular genetic subtype of ALK-positive anaplastic large-cell lymphoma. *Blood*. 1998;**92**(8):2688-2695

[138] Ma Z et al. Inv(2) (p23q35) in anaplastic large-cell lymphoma induces

constitutive anaplastic lymphoma kinase (ALK) tyrosine kinase activation by fusion to ATIC, an enzyme involved in purine nucleotide biosynthesis. *Blood*. 2000;**95**(6):2144-2149

[139] Tort F et al. Molecular characterization of a new ALK translocation involving moesin (MSN-ALK) in anaplastic large cell lymphoma. *Laboratory Investigation*. 2001;**81**(3):419-426

[140] Cools J et al. Identification of novel fusion partners of ALK, the anaplastic lymphoma kinase, in anaplastic large-cell lymphoma and inflammatory myofibroblastic tumor. *Genes, Chromosomes & Cancer*. 2002;**34**(4):354-362

[141] Touriol C et al. Further demonstration of the diversity of chromosomal changes involving 2p23 in ALK-positive lymphoma: 2 cases expressing ALK kinase fused to CLTCL (clathrin chain polypeptide-like). *Blood*. 2000;**95**(10):3204-3207

[142] Lamant L et al. Non-muscle myosin heavy chain (MYH9): A new partner fused to ALK in anaplastic large cell lymphoma. *Genes, Chromosomes & Cancer*. 2003;**37**(4):427-432

[143] Lawrence B et al. TPM3-ALK and TPM4-ALK oncogenes in inflammatory myofibroblastic tumors. *The American Journal of Pathology*. 2000;**157**(2):377-384

[144] van, der Krogt JA et al. Anaplastic lymphoma kinase-positive anaplastic large cell lymphoma with the variant RNF213-, ATIC- and TPM3-ALK fusions is characterized by copy number gain of the rearranged ALK gene. *Haematologica*. 2017;**102**(9):1605-1616