

We are IntechOpen, the world's leading publisher of Open Access books Built by scientists, for scientists

6,900

Open access books available

186,000

International authors and editors

200M

Downloads

Our authors are among the

154

Countries delivered to

TOP 1%

most cited scientists

12.2%

Contributors from top 500 universities



WEB OF SCIENCE™

Selection of our books indexed in the Book Citation Index
in Web of Science™ Core Collection (BKCI)

Interested in publishing with us?
Contact book.department@intechopen.com

Numbers displayed above are based on latest data collected.
For more information visit www.intechopen.com



The Role of Catheter Reshaping at the Angiographic Success

Yakup Balaban

Additional information is available at the end of the chapter

<http://dx.doi.org/10.5772/intechopen.79210>

Abstract

In coronary angiography, inability to selectively visualize anomalous coronary arteries is one of the major problems, which a cardiologist encounters during angiography. The process we expect to finish in 15 min can take hours. The angiography times exceeding 1 h are not uncommon. On 2.6% of coronary angiograms, anomalous origin of coronary arteries is encountered. In 0.58% of the cases, the left anterior descending artery (LAD) arises from a separate ostium. The absence of the left main coronary artery (LMCA) can be discerned directly on coronary angiograms obtained using selective visualization of the left circumflex (Cx) or LAD because in most of the cases, the LAD and circumflex artery (Cx) arise from separate ostia. In such situations and where it seems impossible to achieve imaging of anomalous coronary artery, catheter reshaping can be accepted as a solution. This method can be used looking for the carotid and vertebral arteries at the angiography performed via the radial or femoral route also the right and left coronary ostia with anomalous origin, that easily and safely.

Keywords: catheter reshaping, angiographic success, anomalous coronary origins

1. Coronary anomalies and frequency

For arteries that cannot be selectively visualized frequently, the presence of anomalous origins is looked for, and if they cannot be displayed for the second time, diagnosis of single or atresic coronary arteries is made [1–5]. The most common coronary artery abnormalities are follows; the right coronary artery (RCA) arising from a superoanterior position or left coronary sinus (0.65%), the LAD and Cx arising from separate ostia (0.48%), the Cx arising from the right coronary ostium (0.20%), the LAD arising from the right coronary sinus (0.20%), the single coronary artery is the LMCA (0.02%), the single coronary artery is the RCA (0.11%), and the

LAD arising from the pulmonary artery (0.02%, ALPACA syndrome). The LAD originated from the LIMA can also be present rarely in cases (Balaban Syndrome) (**Figures 1** and **2** and **Table 1**). In most of these cases during angiography, standard catheters fail to selectively visualize the anomalous coronary arteries [1–4] (**Figures 1** and **2** and **Table 1**).

In publications on anomalous origins and their incidence rates, detection of anomaly has been made in autopsy or using computed tomography. Currently, there are no encountered

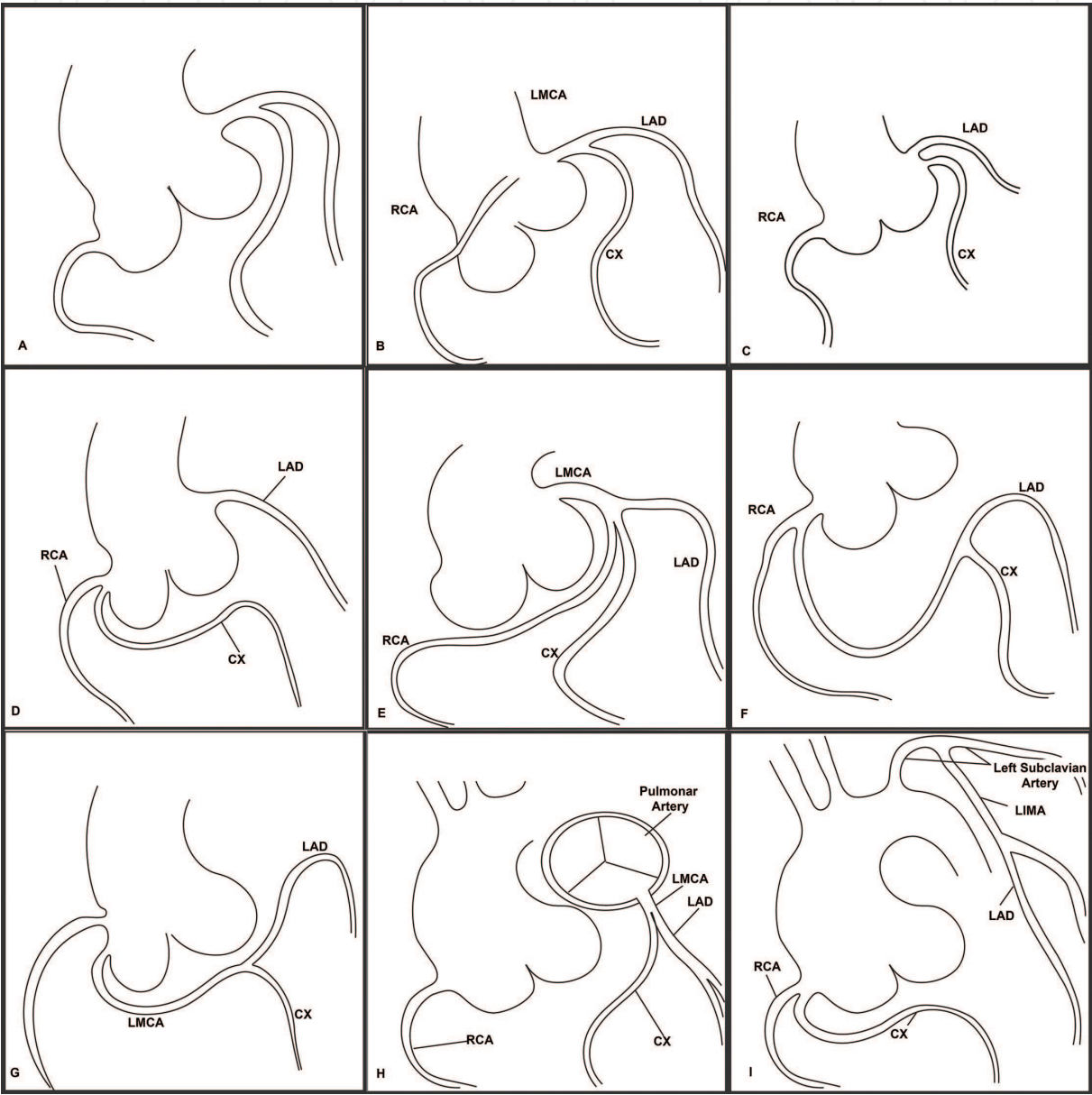


Figure 1. (A) Normal variation is 97.4% of the population. (B) The RCA arising from a superoanterior position or left coronary sinus (0.65%). (C) The LAD and Cx arising from separate ostia (0.48%). (D) The Cx arising from the right coronary ostium (0.20%). (E) The single coronary artery is the LMCA (0.02%). (F) The single coronary artery is the right coronary artery (0.11%). (G) The LAD arising from the right coronary sinus (0.20%). (H) The LAD arising from the pulmonary artery is a very rarely encountered anomaly (0.02% ALPACA syndrome). (I) The LAD is originated from LIMA in the very rarely encountered cases.

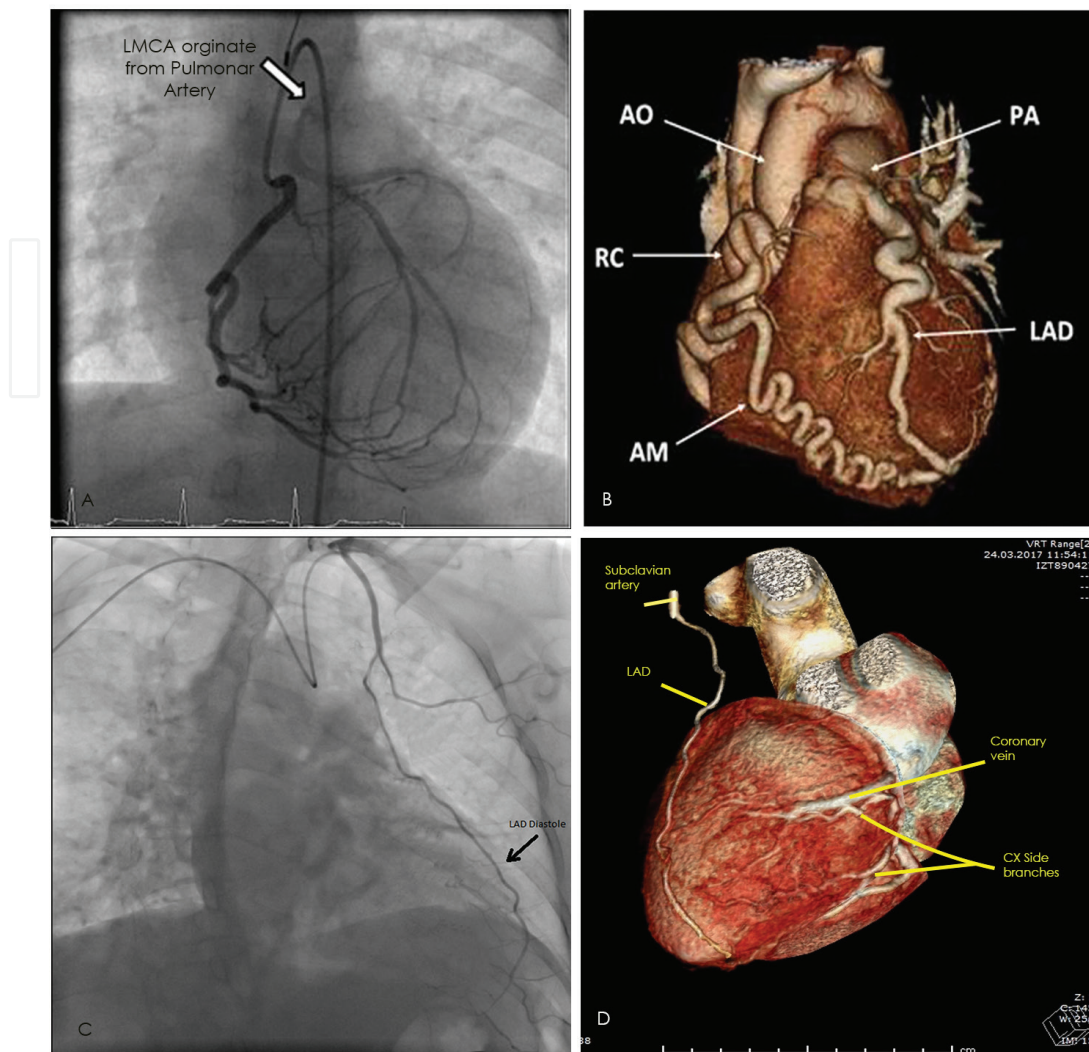


Figure 2. (A, B) The LAD arising from the pulmonary artery is a very rarely encountered anomaly (0.02% ALPACA syndrome). (C, D) The LAD is originated from the LIMA in the very rarely encountered cases (Balaban Syndrome).

comprehensive and detailed publications related to angiographically defined coronary arteries of anomalous origin or their incidence. In patients with anomalous coronary arteries, by shaping catheter, angiographic visualization of anomalous coronary arteries may be enabled within a short time and using lesser amount of opaque material [6–8].

If the physician does not suspect the presence of another coronary artery, this negligence may lead to catastrophic consequences during a potential attack of myocardial infarction in cases with anomalous origin of coronary arteries, inability to visualize the coronary artery [6].

In nearly 97.4% of the patient population, selective visualization of coronary arteries can be achieved with the aid of catheters available in most of the catheterization laboratories. However, in the remaining 2.6% of the cases, these catheters cannot aid in visualization. Otherwise, if an infarction-related coronary artery could not be selectively detected, this condition may lead to fatal consequences for the patient [1–8].

Anomalous origin	Incidence (%)
High take off RCA or from left CS (Figure 1B)	0.65
LAD and CX arising from separate ostia (Figure 1C)	0.48
CX arising from right CS (Figure 1D)	0.20
Single coronary artery RCA (Figure 1E)	0.11
Single coronary artery LMCA(Figure 1F)	0.02
LAD arising from the right coronary sinus (Figure 1G)	0.20
LAD arising from pulmonary artery(Figure 1H)	0.02
LAD arising from LIMA(Figure 1I)	0.001

Coronary arteries of anomalous origin, and their incidence rates. LAD: left anterior descending artery; CX: circumflex artery; RCA: right coronary artery; LMCA: left main coronary artery; CS: coronary sinus.

Table 1. Incidence rates of coronary arteries of anomalous origin.

In these circumstances a physician who is both an explorer and an inventor in cases of MI may save the life of his/her patient.

In cases with coronary arteries with anomalous origin, which are difficult or even impossible to visualize in catheterization laboratory, after determination of approximate origin and angle of exit of the coronary artery, it is possible to design a catheter that can negotiate anomalous origin and angle of exit. Shaping catheter may be an effective, reliable, and in cases with acute MI, life-saving procedure in the achievement of visualization and decreasing the duration of the procedure, radiation dose, and opaque material used [4, 8].

2. The catheter reshaping method

The standard diagnostic catheters that we use in angiography can be reshaped with the standardized methods that we explain as below:

The distal tip of the 0.035 inch guidewire that we use during angiography is inserted through the distal tip of the catheter and advanced for 10 cm. Then, with the aid of the guidewire, the required shaping can be performed. Afterwards, the end of the catheter is held 10 cm away from a heat gun and exposed to hot air (450°C) for 4–6 s. Soon after the tip of the heated and reshaped catheter is immersed in water. Using a plastic injector, the catheter with the guidewire inside is irrigated from the opposite end using a sterile isotonic saline solution. Before completion of the cooling process, the guidewire is removed, and water cooling is continued. When the catheter is completely cooled, the catheter is cannulated with the aid of a 0.38-inch guidewire using rotational movements through the carotid ostium or anomalous coronary ostium to visualize the carotid or coronary arteries (Figures 3 and 4) [4, 8–12].

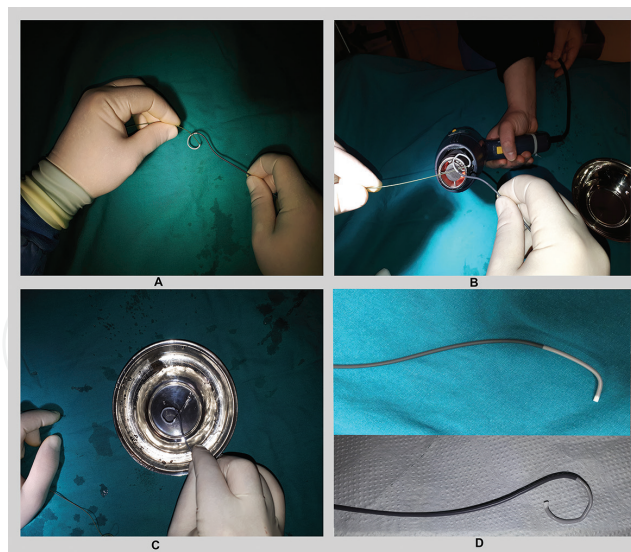


Figure 3. The catheter reshaping method for carotid angiography via transradial approach: (A) the distal tip of the 0.035 inch guidewire we used during angiography was inserted through the distal tip of the catheter and advanced for 10 cm. With the aid of the guidewire, the required shaping was then performed. (B) Afterwards, the end of the catheter was held 10 cm away from a heat gun and exposed to hot air (450°C) for 4–6 s. Soon after the tip of the heated and reshaped catheter was immersed in water. (C) Using a plastic injector, the catheter with the guidewire inside was irrigated from the opposite end using a sterile isotonic saline solution. Before completion of the cooling process, the guidewire was removed, and water cooling was continued. (D) Final viewing of the reshaped catheter.

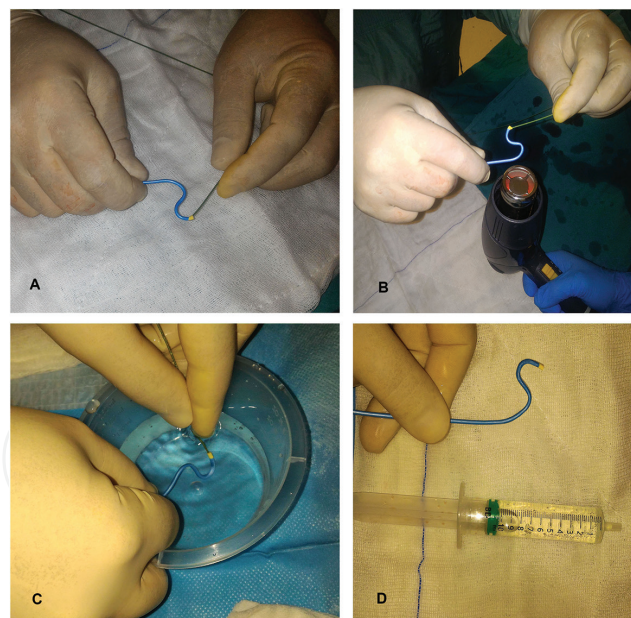


Figure 4. The catheter reshaping for carotid angiography via femoral way: (A) the distal tip of the 0.035 inch guidewire we used during angiography was inserted through the distal tip of the catheter and advanced for 10 cm. With the aid of the guidewire, the required shaping was then performed. (B) Afterwards, the end of the catheter was held 10 cm away from a heat gun and exposed to hot air (450°C) for 4–6 s. Soon after the tip of the heated and reshaped catheter was immersed in water. (C) Using a plastic injector, the catheter with the guidewire inside was irrigated from the opposite end using a sterile isotonic saline solution. Before completion of the cooling process, the guidewire was removed, and water cooling was continued. (D) Final viewing of the reshaped catheter.

3. Types of aortic arches and their incidence rates

In cases where selective angiography is not successful, it is necessary to know the anomaly in order to solve the problem. The identification of aortic type may be helpful to determine the most appropriate shape of catheter. At first, the physician should know and form an estimate aortic arch and coronary origin anatomy.

In some publications, various classifications for various types of aortic arches have been proposed. Most of such classification schemes fail to improve the transradial angiography procedure. We have recently proposed a classification system. Type I aortic arches, also known as normal aortic arches, are the most frequently encountered (86%). In this arch type, the right carotid artery arises from the right brachial trunk, and the left common carotid artery originates from the aortic arch 1–2 cm to the left of the brachiocephalic trunk. In 9% of cases in which a Type II aortic arch is observed, the right and left common carotid arteries originate from the brachial trunk. In Type III aortic arches (2%), the right and left common carotid arteries directly originate from the aortic arch as a one unit or separately. In Type IV aortic arches (3%), which also include arteria lusoria, the right subclavian artery stems from the aorta near the descending aorta after the carotid arteries [9, 10, 13–15] (Figure 5).

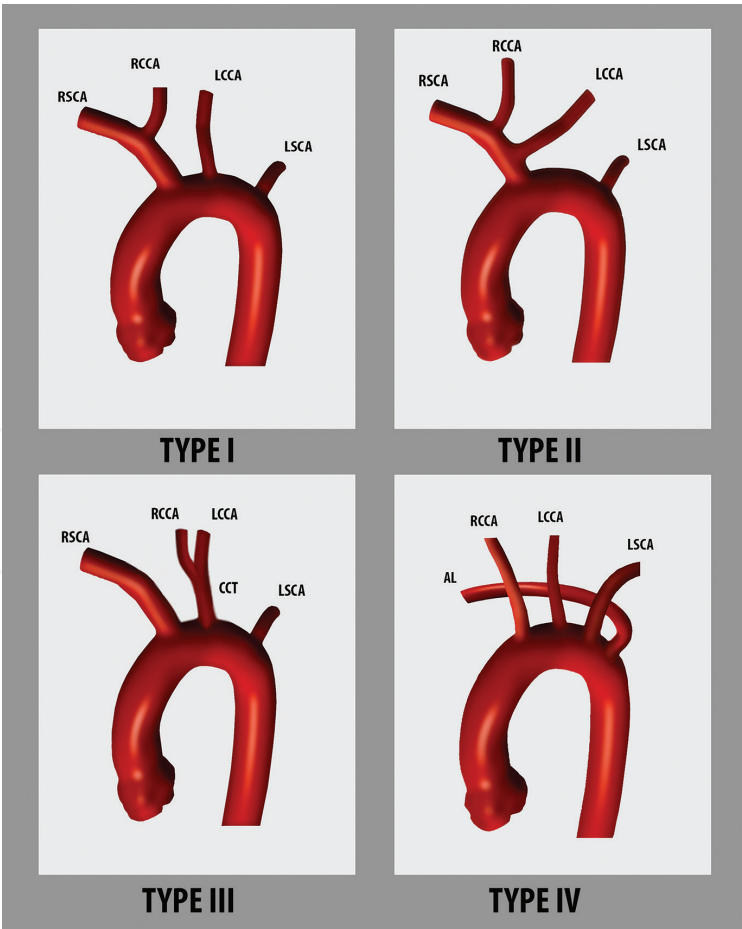


Figure 5. RSCL, right subclavian artery; LCCA, left common carotid artery; RCCA, left common carotid artery; LSCL, left subclavian artery. Types I, II, III, and IV are encountered in 86, 9, 2, and 3% of cases, respectively.

4. The role of catheter reshaping in the success of carotid angiography by radial pathway

It is difficult to perform transradial carotid angiography using conventional multipurpose catheters, which suffer from lower success rates and longer procedural times. Therefore, physicians do not prefer to perform transradial carotid angiography. We thought that among conventional catheters, the Simpson catheter and the 3.5 JL catheter were the most suitable for transradial visualization. To this end, the reshaped catheters can be more effective than available conventional catheters in carotid angiography. There are a few new publications in this regard, reaching 1500 participants. However, one study has examined the use of the modified Simmons catheter in the right transradial route carotid angiography. The Simpson catheter has an angled distal tip, which opens far from the long axis of the catheter. This configuration decreases the right transradial procedural success rate of selective visualization of the left carotid artery in cases where the left carotid artery stems from a point near the brachiocephalic trunk. Therefore, performing selective angiography with a Simpson catheter requires special experience and manual dexterity. The retroflexed tip of the 3.5 JL catheter provides improved cannulation of the left common carotid artery and is one of the most frequently available catheters in every laboratory [9–11, 16].

Even though transradial carotid visualization can be achieved using standard catheters, carotid arteries cannot be selectively cannulated, and the images obtained are far from satisfactory

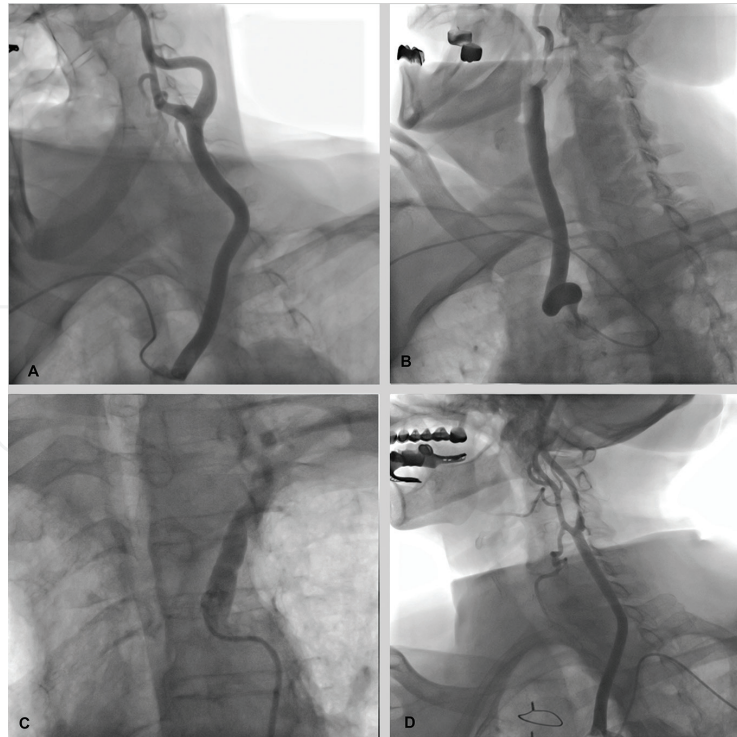


Figure 6. The reshaped catheter types using at the different angiographies: (A) right transradial carotid angiography with hooklike reshaped catheter; (B) the right transradial carotid angiography in the arteria lusoria case (type IV aorta); (C) the “S”-shaped catheter using with femoral access; and (D) the left transradial carotid angiography with the “hooklike” reshaped catheter.

compared with the selective images. The size and track of the plaque, in particular, cannot be clearly evaluated. Only the degree of stenosis may be estimated. However, determining the morphology and fragility of the plaque, and the presence of vascularity or plaque dissection and erosion, is required to predict the probability of experiencing a cerebrovascular event in the future and for planning the appropriate treatment modality and decreasing procedural complications. The new visualization method that is catheter reshaping is more useful to detect the presence of plaque fractures, erosion, and dissection due to good quality images. These satisfactory images aid us in selection of appropriate treatment methods and prediction of complications [10] (**Figure 6**).

The visualization with new reshaped catheter requires a shorter procedural time and less opaque material usage. Since selective engagement of catheters in carotid arteries is achieved with this method, higher-quality images can be obtained. The new catheter greatly contributes to the determination of appropriate treatment [10, 17].

5. Following coronary angiography performed by femoral approach, the carotid angiography, and the contribution of the catheter reshape to success

The relationship between peripheral artery disease and coronary artery disease is a known fact. This relationship is often predictive of stroke, renal insufficiency, and extremity artery disease in patients with coronary artery disease. At the moment of coronary angiography procedure, the visualisable of carotids seems to be advantageous for the patient. The carotids can be displayed noninvasively by MR angiography and CT angiography. But it can only be displayed at low resolution according to invasive angiography. This noninvasive imaging may be the first choice, for isolated cases. However, in patients already undergoing coronary angiography, carotid imaging application following this procedure is a more appropriate choice. The quality of the invasive carotid image is still better than the MR and CT angiography. Invasive imaging is still the gold standard in neck malformations, carotid tumors, neck injuries, and carotid artery stenosis. In still today, cardiovascular surgeons, neurologists, and neurosurgeons, if they see lesions in the carotid artery at the MR and CT angiography, require invasive carotid angiography when they propose an additional intervention for these lesions [9, 10, 12–18].

It is known that physicians who perform coronary angiography use “the right diagnostic catheter” for their desired carotid imaging. Simon catheters and HN4–5, CK1, and MAN catheters can be used, especially if carotid interventional procedures are going to be performed. However, these catheters are not commonly used by cardiologists. They can often be supplied by special order, and they are not available in most coronary angiography laboratories. For these reasons, the reshaping of catheter in the coronary angiography laboratory can be a snapshot solution to the problem of imaging anomalous vascular origins and for carotid and other peripheral arterial imaging [4, 9, 10, 12, 19–21]. There is a strong relationship between carotid artery disease and coronary artery disease. According to recent studies, in patients

with coronary artery stenosis of 50% or more, the likelihood of a significant carotid artery stenosis exceeds 60%. This ratio can be interpreted; if carotid angiography is performed in the patients with a significant coronary stenosis, carotid artery disease can be shown at least among 60% of the patients. Therefore, in patients with planned coronary angiography, it would be useful to look at carotids in the presence of severe coronary atherosclerosis at the same session without preliminary investigation of carotid stenosis. Also the opposite can also be considered. In other words, that is very useful to perform coronary angiography at the same procedure in the patient with carotid stenosis. At least 60% of these patients with carotid artery disease have also significant coronary artery disease [9, 10, 20–22].

In the patients with carotid stenosis by Doppler ultrasonography, invasive angiography may be more advantageous than MR and CT angiography, because if a person has carotid stenosis, there is a high probability of coronary artery disease. If we focus on carotid stenosis and ignore potential coronary artery disease, the patient may become vulnerable to myocardial infarction. Furthermore, the image quality of noninvasive techniques is not as detailed as in the invasive angiography. The conventional angiography can show the character of carotid plaque, the cracks in the plaque, whether the plaque is vulnerable or not. Knowing plaque features give valuable information to physicians for treatment approach [9, 10, 18–27].

Cardiologists who perform carotid angiography followed by coronary angiography perform carotid angiography often with the right Judkins diagnostic catheter. There are no clinical studies conducted to determine which of the HN4-5, CK1, and MAN catheters are more effective and reliable in carotid angiography [21, 22]. The cardiologists performing coronary angiography can make a very successful and reliable carotid angiography by giving the “S” shape to “right diagnostic catheter” at the transfemoral way or by giving “hooklike” shape to right diagnostic catheter at the transradial way, without having an additional catheter in the catheterization laboratory (**Figures 3, 4, and 6**) [9, 10].

Catheter shaping is done as an amateur in many coronary angiography laboratories. There are clinical trials that standardize catheter reshaping. The reliability and success of catheter shaping by hand have been proven with these clinical studies reaching over 1500 participants. Teaching and implementing this method in daily practice may be useful [9, 10, 12, 17].

All experiences and discoveries are creating new percutaneous intervention areas. Twenty years ago, transcatheter aortic valve replacement was a dream. The retrograde chronic total occlusion intervention was almost impossible with techniques and instruments of 15 years ago. All these developments have been made possible by the transformation of new methods into scientific publications [28, 29].

The initial experience of angiography was performed with brachial pathway, but the femoral route was considered safer and simpler at the beginning. Therefore, the development of angiography has been initiated using the femoral route. However, in the last 15 years, radial route has been used again and even has been shown to have advantages, so it is used now all over the world. Today, coronary and peripheral invasive angiography can be performed as fast and reliable as MR and CT angiography. Invasive angiography allows for real-time imaging and immediate intervention allowing physicians to better identify condition of patient

and treatment of the disease. All interventional physicians should strive to publish the useful and practical methods that they have recently discovered. These publications are very important because they can shed light on the development of new techniques and devices [30–32] (Figures 3, 4, and 6).

6. Conclusion

The newly obtained catheter by reshaping of the plastic catheters used in angiography by cooling after reshaping with heat can be more effective at the displaying vessels with anomalous origin than existing catheters. First, the aortography must be performed to determine the location of the coronary artery ostium in the aorta at the anomalous coronary events. Thus, the appropriate catheter shape can be estimated. The selective angiography can be quite easy if the current catheter can be successfully shaped. This method can also be used to image the carotid and vertebral arteries by radial and femoral routes. The carotid and vertebral artery angiography can be performed more easily with the use of reshaped catheters in some cases including anomalous coronary cases.

Author details

Yakup Balaban

Address all correspondence to: yakupbalaban@gmail.com

Department of Cardiology, VM Medical Park Kocaeli Hospital, Turkey

References

- [1] Graidis C, Dimitriadis D, Karasavvidis V, Dimitriadis G, Argyropoulou E, et al. Prevalence and characteristics of coronary artery anomalies in an adult population undergoing multidetector-row computed tomography for the evaluation of coronary artery disease. *BMC Cardiovascular Disorders*. 2015;**15**:112
- [2] Mavi A, Ayalp R, Serçelik A, Peştemalci T, Batyraliev T, Gümüşburun E. Frequency of the anomalous origin of the left main coronary artery with angiography in a Turkish population. *Acta Medica Okayama*. 2004;**58**(1):17-22
- [3] Ayalp R, Mavi A, Serçelik A, Batyraliev T, Gümüşburun E. Frequency of the anomalous origin of the right coronary artery with angiography in a Turkish population. *International Journal of Cardiology*. 2002;**82**(3):253-257
- [4] Balaban YHA, Gümrükçüoğlu D, Güngör SC. Left anterior descending artery of anomalous origin; native LAD arises from left internal mammarian artery. A case report and article review. *Cardiovascular Revascularization Medicine*. 2018;**19**(2):209-214

- [5] Villa AD, Sammut E, Nair A, Rajani R, Bonamini R, Chiribiri A. Coronary artery anomalies overview: The normal and the abnormal. *World Journal of Radiology*. 2016;**8**(6):537-555
- [6] Frescura C, Basso C, Thiene G, Corrado D, Pennelli T, et al. Anomalous origin of coronary arteries and risk of sudden death: A study based on an autopsy population of congenital heart disease. *Human Pathology*. 1998;**29**(7):689-695
- [7] Gräni C, Benz DC, Schmied C, Vontobel J, Possner M, et al. Prevalence and characteristics of coronary artery anomalies detected by coronary computed tomography angiography in 5634 consecutive patients in a single Centre in Switzerland. *Swiss Medical Weekly*. 2016;**146**:w14294
- [8] Kim JY, Yoon GS, Doh HJ, Choe HM, Kwon SU, Namgung J. Two cases of successful primary percutaneous coronary intervention in patients with an anomalous right coronary artery arising from the left coronary cusp. *Korean Circulation Journal*. 2008;**38**(3):179-183
- [9] Balaban Y. New developed femoral-S carotid catheter' is very effective and safe in carotid angiography: A retrospective study OMICS. *Journal of Radiology*. 2017;**6**:6
- [10] Balaban Y. Effectiveness of a handmade "new carotid catheter" in transradial carotid angiography: A comparison with conventional multipurpose catheters. *Journal of Interventional Cardiology*. 2018;**31**(1):94-105. DOI: 10.1111/joic.12454. Epub: October 11, 2017
- [11] Cha KS, Kim MH, Kim YD, Kim JS. Combined right transradial coronary angiography and selective carotid angiography: Safety and feasibility in unselected patients. *Catheterization and Cardiovascular Interventions*. 2001;**53**(3):380-385
- [12] Erden I, Golcuk E, Bozyel S, Erden EC, Balaban Y, Yalın K, et al. Effectiveness of handmade "Jacky-like catheter" As a single multipurpose catheter in transradial coronary angiography: A randomized comparison with conventional two-catheter strategy. *Journal of Interventional Cardiology*. 2017;**30**(1):24-32
- [13] Huapaya JA, Trujillo KC, Trelles M, Carbaja RD, Espadin RF. Anatomic variations of the branches of the aortic arch in a Peruvian population. *Medwave*. 2015;**15**(6):e6194. DOI: 10.5867/medwave.2015.06.6194
- [14] Ergun E, Simsek B, Kosar P, Yilmaz BK, Turgut AT. Anatomical variations in branching patterns of arcus aorta: 64-slice CTA appearance. *Surgical and Radiologic Anatomy*. 2014;**36**(10):1105-1106. DOI: 10.1007/s00276-014-1288-4. Epub: March 27, 2014
- [15] Cummings MS, Kuo BT, Ziada KM. A rare anomaly of the aortic arch: Aberrant right subclavian artery associated with common carotid trunk. *The Journal of Invasive Cardiology*. 2011;**23**(10):E241-E243
- [16] Park JH, Kim DY, Kim JW, Park YS, Seung WB. Efficacy of transradial cerebral angiography in the elderly. *Journal of Korean Neurosurgical Association*. 2013;**53**(4):213-217. DOI: 10.3340/jkns.2013.53.4.213. Epub: April 30, 2013
- [17] Fang Y, Yang C, Wang X, Zhou L, Wang H, Zeng C. Feasibility and application of single 5F multipurpose catheter in coronary and peripheral angiography via a transradial approach. *International Journal of Cardiology*. 2011;**151**:182-118

- [18] Ledwoch J, Staubach S, Segerer M, Strohm H, Mudra H. Incidence and risk factors of embolized particles in carotid artery stenting and association with clinical outcome. *International Journal of Cardiology*. 2017;**227**:550-555. DOI: 10.1016/j.ijcard.2016.10.103. Epub: November 2, 2016
- [19] Rafailidis V, Chrysosgonidis I, Tegos T, Kouskouras K, Charitanti-Kouridou A. Imaging of the ulcerated carotid atherosclerotic plaque: A review of the literature. *Insights into Imaging*. 2017;**8**(2):213-225. DOI: 10.1007/s13244-017-0543-8
- [20] Rigatelli G. Screening angiography of supraaortic vessels performed by invasive cardiologists at the time of cardiac catheterization: Indications and results. *The International Journal of Cardiovascular Imaging*. 2005;**21**(2-3):179-183
- [21] Seo WK, Yong HS, Koh SB, Suh SI, Kim JH, Yu SW, et al. Correlation of coronary artery atherosclerosis with atherosclerosis of the intracranial cerebral artery and the extracranial carotid artery. *European Neurology*. 2008;**59**(6):292-298. DOI: 10.1159/000121418. Epub: April 11, 2008
- [22] Bae HJ, Yoon BW, Kang DW, Koo JS, Lee SH, Kim KB, et al. Correlation of coronary and cerebral atherosclerosis: Difference between extracranial and intracranial arteries. *Cerebrovascular Diseases*. 2006;**21**(1-2):112-119. Epub: December 9, 2005
- [23] Rigatelli G, Gemelli M, Zamboni A, Docali G, Rossi P, Grazio M. Significance of selective carotid angiography during complete cardiac catheterization in patients candidates to combined aortic valve and carotid surgery. *Minerva Cardioangiologica*. 2003;**51**(3):305-309
- [24] Rigatelli G. Diagnosis of carotid artery occlusive disease in patients scheduled for cardiac or vascular surgery: Is this a place for invasive selective carotid angiography? *Stroke*. 2004;**35**(5):e89-e90; Author reply: e89-90. Epub: March 25, 2004
- [25] Korotkikh NG, Ol'shanskiĭ MS, Stepanov IV. Multidisciplinary approach to diagnostics of extensive vascular head and neck malformations. *Stomatologiya (Mosk)*. 2012;**91**(1):40-45
- [26] Korotkikh NG, Ol'shanskiĭ MS, Stepanov IV, Mashkova TA, Nerovnyĭ AI, Panchenko IG. The multidisciplinary approach to diagnostics and treatment of hypervascular masses in ENT structures. *Vestnik Otorinolaringologii*. 2013;**5**:44-47
- [27] Arslan F1, Yılmaz S, Özer F, Andıç C, Canpolat T, Yavuz H. Surgical treatment of carotid body tumors. *Kulak Burun Boğaz İhtisas Dergisi*. 2013;**23**(6):336-340. DOI: 10.5606/kbbihtisas.2013.28159
- [28] Kaneda H, Takahashi S, Saito S. Successful coronary intervention for chronic total occlusion in an anomalous right coronary artery using the retrograde approach via a collateral vessel. *The Journal of Invasive Cardiology*. 2007;**19**(1):E1-E4
- [29] Cribier A, Eltchaninoff H, Tron C, Bauer F, Agatiello C. Early experience with percutaneous transcatheter implantation of heart valve prosthesis for the treatment of end-stage inoperable patients with calcific aortic stenosis. *Journal of the American College of Cardiology*. 2004;**43**(4):698-703

- [30] Morgan JH, Johnson JH, Brown RB, Harvey RL, Rizzoni WE, Tyson CS. Initial experience with routine selective carotid arteriography by vascular surgeons. *The American Surgeon*. 2006;**72**(8):684-686; Discussion 687
- [31] Louvard Y, Lefèvre T, Allain A, Morice M. Coronary angiography through the radial or the femoral approach: The CARAFE study. *Catheterization and Cardiovascular Interventions*. 2001;**52**(2):181-187
- [32] Oren O, Oren M, Turgeman Y. Transradial versus Transfemoral approach in peripheral arterial interventions. *International Journal of Angiology*. 2016;**25**(3):148-152. DOI: 10.1055/s-0035-1563607. Epub: September 7, 2015

