

We are IntechOpen, the world's leading publisher of Open Access books Built by scientists, for scientists

6,900

Open access books available

185,000

International authors and editors

200M

Downloads

Our authors are among the

154

Countries delivered to

TOP 1%

most cited scientists

12.2%

Contributors from top 500 universities



WEB OF SCIENCE™

Selection of our books indexed in the Book Citation Index
in Web of Science™ Core Collection (BKCI)

Interested in publishing with us?
Contact book.department@intechopen.com

Numbers displayed above are based on latest data collected.
For more information visit www.intechopen.com



Abutment Selection for Anterior Implant-Supported Restorations

Pinar Turkoglu, Adnan Kose and Deniz Sen

Additional information is available at the end of the chapter

<http://dx.doi.org/10.5772/intechopen.80965>

Abstract

With the introduction of dental implants to the market, varying restorative options have been successfully added for restoring the function and esthetics of both completely and partially edentulous patients. Accurate prosthodontic rehabilitation is the key factor for providing the long-term success and the survival of osseointegrated implants. Implant-supported restorations can be fabricated with different techniques. The prefabricated abutments provided by the implant companies are accepted as the gold standard because of their biocompatibility and advanced mechanical properties. However, especially for the anterior restorations, they are increasingly being replaced by custom abutments ideally prepared with CAD/CAM techniques; due to disadvantages of prefabricated abutments such as esthetic flaws, mechanical insufficiency resulting from implant placement, unacceptable emergence profile, and unhygienic regions formed under angled abutments. Currently, custom abutments are reported to have functional and esthetic advantages over prefabricated abutments. In this chapter, indications for proper abutment selection, contemporary production techniques, and different abutment materials will be stated, and the current research on the subject will be discussed.

Keywords: abutment, CAD/CAM, emergency profile, hybrid abutment, zirconia

1. Introduction

Implant-supported restorations have become a popular treatment choice for the rehabilitation of the partially edentulous patients with missing teeth particularly in the anterior region, where esthetics has an irreplaceable importance in treatment success [1]. Accurate prosthodontic rehabilitation is the key factor for providing the long-term success and the survival of osseointegrated implants [2]. Implant-supported restorations can be fabricated with several

techniques and materials [1, 2]. This chapter evaluates the historical development of abutment types, their usage, and the studies evaluating the survival rates of abutments used in the anterior restorations.

Abutment-crown complex for single-tooth restorations was first introduced in 1986 [1]. This one-piece complex was primarily composed of acrylic resin crown veneered onto prefabricated machined titanium [1, 2]. Subsequently, for obtaining better esthetics, this complex was changed to a two-piece restoration consisting of a cemented metal-ceramic crown that was supported by a prefabricated titanium abutment [1]. Afterward, the University of California Los Angeles (UCLA) abutment was introduced in 1988, which made it possible to use custom cast metal component that can be screwed into the implant [3]. This abutment type gained popularity in time and still continues to be preferred for both screw- and cement-retained implant-supported restorations.

Until today, a large number of clinical studies have displayed perfect survival rates for metal abutments used in both anterior and posterior regions [4–7]. However, metal abutments have some limitations and disadvantages, predominantly related with the esthetic results. Clinical studies reported that metal abutments caused a blue-grayish color reflection from the peri-implant site gingiva, which threatens the treatment success especially for the patients with a high/gummy smile line [8–11]. To solve the esthetic problems related with metal abutments, Prestipino and Ingber introduced a densely sintered alumina ceramic abutment in 1993 [12–14]. The development of alumina ceramic abutments parallel with the improvements in the CAD/CAM technology was an important breakthrough in implant dentistry that was investigated with a wide range of clinical studies [15]. Then, in 2004, a densely sintered yttrium-stabilized zirconia was described by Glauser et al. as an alternative abutment material to alumina [16]. At first, zirconia abutments were produced manually with copy-milling technique using a customized resin pattern. Since then, fabricating zirconia abutments with CAD/CAM system led to significant improvements in implant dentistry enabling the replacement of a missing anterior tooth with an implant supporting a restoration with ideal esthetics and function. Zirconia abutments were developed offering a large number of biological advantages in comparison with titanium: less bacterial adhesion [17] and more biocompatibility due to lack of corrosion and galvanic coupling [18, 19].

Use of CAD/CAM technology in the dental market allowed the fabrication of custom abutments that can be manufactured from either titanium or ceramics [20]. Currently, preparation of individual custom abutments is also possible in accordance with the patients' anatomic needs and/or with the ideal emergence profile of the missing tooth [21].

2. Classification of implant abutments

Varying types of implant abutments have been reported in the literature for use with the anterior implant-supported restorations [22]. They can be classified according to the connection method to the restoration, fabrication material, fabrication method, type of abutment-implant connection, and color (Table 1).

Category	Options
Method of connection to restoration	<ul style="list-style-type: none"> - Screw-retained abutment-crown complex - Two-piece design with screw-retained crown over the abutment - Two-piece design with cemented crown over the abutment
Abutment connection to implant	<ul style="list-style-type: none"> - External connection - Internal connection
Material	<ul style="list-style-type: none"> - Titanium - Cast metal (noble, high noble, or base metal alloy) - Cast metal with porcelain fused at the base - Alumina - Complete zirconia - Zirconia with a titanium base (zirconia-titanium hybrid abutment)
Method of fabrication	<ul style="list-style-type: none"> - Prefabricated (unmodified or modified) - Customized cast abutment - Customized copy-milled abutment - Customized CAD-CAM abutment
Color	<ul style="list-style-type: none"> - Gold - Silver (metallic finish) - Pure white - Customized white - Customized pink/gingival shade at the cervical region

Table 1. Classification of implant abutment designs [22].

Differing properties of the abutments have varying advantages and disadvantages. Occlusal forces with different vectors are significantly lower in the anterior teeth than the posterior teeth because of Class III lever system of the human jaw [23, 24]. When compared with the incisors, biting forces are almost two times higher for the premolar teeth and three times higher for the molar teeth. Consequently, the clinical results between anterior and posterior abutments should be importantly different. Furthermore, esthetic parameters related to the selection of an anterior abutment may not be applied to the posterior regions. The readers should be aware that studies investigating the clinical outcomes of prosthetic components are classified as anterior and posterior regions due to significantly different complications and survival rates [22].

2.1. Implant-abutment connections

The implant-abutment connections can be classified as either external, which protrudes above the implant platform, or internal, which sets down in the access hole inside the implant body (**Figure 1**). The external hex design was the first to be used in the manufacturing of dental implants. It was originally 0.7 mm in height and was used to help screw the implant fixture into the prepared osteotomy. It was not used as an antirotational device because the rotation of the

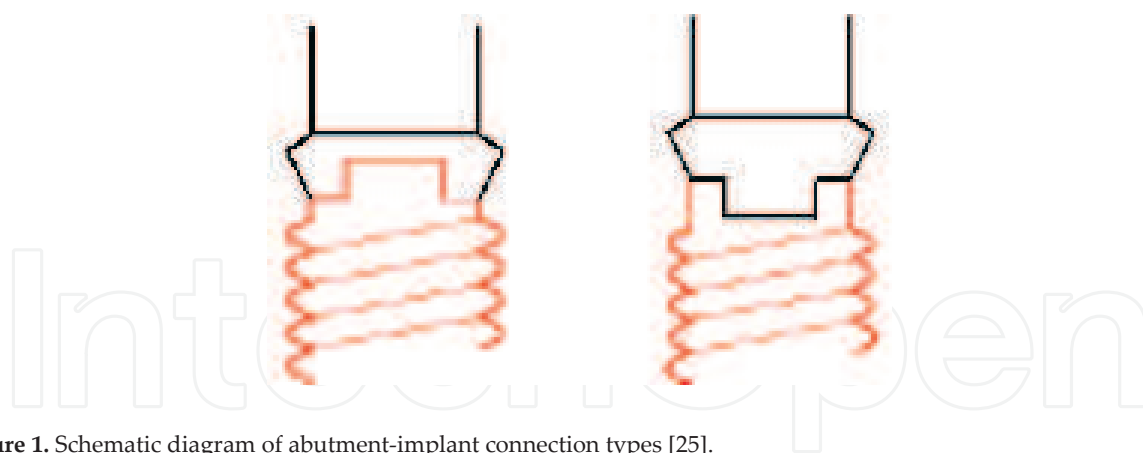


Figure 1. Schematic diagram of abutment-implant connection types [25].

implant-supported restoration was not an issue. However, when the dental implants began to be used in replacing a single-missing tooth, the external hex with some improved quality was used to prevent rotation of the abutment under loading. The external hex connection is still in use as it is suitable for the two-piece implant placement method, has an antirotational mechanism, and is compatible with different implant systems. The external hex also helps the laboratory technician to achieve the best possible emergence profile because the porcelain can be brought closer to the implant-abutment interface. However, it is not without disadvantages, such as low resistance for rotational and lateral movements owing to its high center of rotation. Furthermore, difficulty in seating the abutments in a deep gingival sulcus, increased screw loosening, and component fractures are problems to be considered when the external hex connectors are used [25].

The internal hex connector is widely used. It is a stable connection with a high resistance to lateral forces because of the lower center of rotation and is also suitable for a one-stage implant placement technique. It is also characterized by a good distribution of imposed force. However, weakening of the lateral wall of the implant at the connecting part and compensation for mismatching in the angle between implant fixtures may cause some problems [25].

There is a general consensus that deep internal attachment in which the screw is exposed to little or no load with an intimate contact between mating surfaces will result in good resistance to micromovement. This movement may be associated with crestal bone loss, as mentioned earlier [26]. In order to simplify the technique of placement of the abutments, an audible and tactile “click” feature was incorporated in the internal connection. Thus, the clinician will be able to tell when the abutment is in its intended position on the implant and the need for a radiograph following placement may be reduced. The internal connection when it is long enough may provide lateral stability for the restorative component from off-axis occlusal forces [25].

2.2. Types of abutments

Implant-supported restorations may be classified into two types according to the method by which they are attached to the implant: screw- and cement-retained implant restorations. Screw-retained implant restorations enable the direct attachment of the restoration to the implant or the abutment, whereas a cementing medium is used for the retention of the restoration onto the abutment for cement-retained implant restorations [25]. Comparison of the advantages and disadvantages of cement- and screw-retained techniques is shown in **Table 2** [27].

2.3. Abutment selection

For the single-tooth implant-supported restorations, an antirotational abutment mechanism is necessary. Currently, the most widely used mechanism is a hexagon with an internal connection. Because of the anatomical limitations related with the anterior single-tooth implant, the prosthetic abutment should be planned with an antirotational mechanism requiring a two-piece system. It may also be necessary to use angled abutment in order to compensate the implant insertion, which is not within the contours of the final restoration. This also forces the dentist to use at least two pieces: the abutment that engages the hexagon or antirotational design and an abutment screw that connects the abutment to the implant body [28]. Abutments are basically categorized into two types according to the fabrication technique:

- Prefabricated abutments
- Custom abutments

	Screw type	Cement type
Retrievability	Restorations can be removed/replaced without damage or the need for a new restoration	It is possible if weak cements were used, i.e., soft provisional cement, otherwise restorations have to be cut in order to remove them
Interocclusal space/retention	It can also be used when the interocclusal space is limited, i.e., less than 4 mm	Minimum interocclusal space with minimum converges is needed to achieve an optimal retention
Limitation of mouth opening	The mouth opening should be enough for the use of different tools required for screwing and torquing the screws	A restricted mouth opening is less problematic than with the use of the screw-retained restorations
Occlusal loading	Unlikely to reduce the occlusal load on the restoration and the implant body	The use of soft provisional cement may reduce the occlusal load on the restoration and the implant body
Peri-implant inflammation	The adaptation between the restoration and the underlying implant is significantly better than that in the case of cement-retained counterpart	The difficulty of removing the cement and the inferiority of margin adaptation between the restoration and the abutment, when this margin is placed subgingivally can cause peri-implant soft tissue inflammation
Esthetics and occlusion	The implant needs to be placed in its optimal angulation in the anterior zone. The screw hole may interfere with the creation of an ideal occlusal morphology as well as with esthetics. The screw hole could weaken the porcelain veneer	Even if the implant angulation is not optimal, the restoration could still have good esthetics The ideal occlusal morphology can be created in the laboratory in the normal way as in the conventional restorations
Cost	The cost in terms of laboratory time and materials is much more than that for the cement-retained restorations	The materials and techniques used for the fabrication of the conventional restorations can be used in this situation

Table 2. Comparison of cement- and screw-retained restorations [27].

2.3.1. Prefabricated abutments

The prefabricated abutment is prepared by the manufacturer from different materials and provides a connection between the implant and the restoration, with different platform width, length, and gingival output profile. These abutments can be fabricated from titanium or its alloy, titanium with titanium nitride coating, or ceramic (alumina or zirconia) materials. They may also be angled or straight. The preangled abutment has varied angulations provided by manufacturers, usually 15 and 25 degrees off-axis (**Figure 2**) [29].

2.3.2. Custom abutments

The custom abutments are preferred for the esthetic and function in the anterior restorations. In the posterior region, it has been reported that the use of custom abutments is more successful than prefabricated abutments because of the small diameter implants due to insufficient bone mass, chewing forces in these regions are high and gingivae are wider [30].

Titanium abutments are considered as a 'gold standard' because of their clinical success rates and improved physical properties [31]. However, titanium abutments have been reported to cause reflection and grayish coloration of the mucosa around the implant [32]. Abutments made from full ceramics provide optimum esthetics when used in conjunction with full ceramic crown restorations, reducing shading in soft tissue. Yttrium-stabilized tetragonal zirconia polycrystals (Y-TZPs) have begun to be used as abutment materials due to their durability and biocompatibility in implant-supported fixed dentures. Besides the esthetic qualities of zirconia abutments, they have a high corrosion resistance and a low plaque build-up [33, 34]. Tan et al. studied the zirconia's biocompatibility of abutments and did not encounter any complications that occurred in the soft tissue. Zirconia reported that less bacterial involvement occurred on the abutment surface than titanium [35].

Zirconia has been reported in abutments in the implanted platform, in the neck region of the connection, and in titanium abrasions and fractures [36–38]. It has been reported that the causes of wear and fracture may be due to differences in the hardness values of titanium and zirconia materials. Due to these observable complications, a system is created in which a zirconia abutment is made up of a titanium neck and a neck of the abutment-implant connection,



Figure 2. Different abutment types [29].

and this system is called a “hybrid abutment.” With this system, the durability of titanium and the esthetic qualities of zirconia have been used together to become an alternative treatment for individual abutments [36, 37, 39]. With the understanding that the durability properties of hybrid abutments are higher than that of single-piece zirconia abutments, manufacturers have begun to produce titanium abutments in which they use as “ti-base” for use in accordance with existing implant sizes. Thus, the zirconia abutment on the titanium platform can be prepared and used in one piece, combined with the technique proposed by the firm [39].

Many companies that produce custom abutments for individuals can produce zirconia abutments in various color alternatives prepared beforehand by sintering in different color solutions or in different colors of zirconia blocks [40]. In recent years, monolithic zirconia onto ti-base, which is reported to have a high light transmission, has begun to be used as a hybrid abutment [41].

Different types of implant abutments have been described in the literature for use in the anterior region. The selection of an implant abutment in the anterior region is related to the factors: (1) smile line, (2) thickness of the peri-implant mucosa, (3) implant angulation, (4) restoration material, (5) interocclusal space, (6) type of the restoration related with the retention (screw- or cement-retained), (7) clinician’s selection, and (8) cost of the treatment [22].

Patient’s smile line can be categorized as low, medium, high, and gummy smile. When the smile line of the patient is low, there is no need to use esthetic abutment in no case. When the patient’s smile line is from medium to gummy smile, selection of abutment material depends on the thickness of the buccal peri-implant mucosa. The abutment should be ceramic when the thickness of the buccal gingiva is ≤ 2 mm regardless of the bone thickness. When the buccal mucosa thickness exceeds 2 mm, there will be no esthetic problems due to titanium abutment use. Previous studies reported that 80% of the patients have buccal gingiva thickness less than 1.5 mm in the anterior region that means that zirconia abutment is necessary for most of the anterior restorations [42].

For anterior single-tooth implant-supported restorations, various options of abutments for cement retention are available:

1. A two-piece abutment for cement with minimal flare from the implant body
2. A two-piece abutment wider than the implant body
3. A two-piece anatomical abutment similar in shape to the cross section of a tooth
4. A plastic castable UCLA-type coping
5. UCLA-type machined/plastic cast to cylinder and abutment screw
6. Ceramic
7. Preangled abutment fabricated by the manufacturers with different angulations, usually with 15 and 25 degrees [43].

Manufacturers usually prefer the fabrication of the abutments wider than the implant body. An abutment with a wider cervical region enables obtaining an emergence profile for the

crown, ensures a greater retention area, and provides a greater premade taper of the abutment. The dentist can customize the abutment preparation, condition, and site for each patient. In addition, the wider abutment and chamfer margin facilitate cement retrieval in subgingival margin applications. This is the most popular abutment used for the direct intra-oral technique. The accuracy of the machined implant-abutment interface makes it a popular option. However, the wider abutment design has some disadvantages [29]:

1. The wider abutment is wider all around the implant body. When too close to the adjacent tooth/implant, too buccal, or too lingual, the abutment must be prepared further.
2. The wider abutment creates an undercut where it tapers down to the implant body, with several inherent problems. The crown margin must be placed above the undercut. If the undercut is more than 1 or 2 mm, long-term soft tissue shrinkage is likely to expose a metal band below the crown margin resulting in compromised esthetics.
3. If the implant was placed below the crestal bone, the restoring dentist cannot set the abutment on the implant platform without an osteoplasty around the implant, unless Stage I healing screw was of the same dimension as the wider abutment (in which case the osteoplasty would have been performed by the surgeon at implant insertion) [29].

The anatomical abutments (custom-made or premade) present similar advantages and disadvantages as the wider abutment posts. One more advantage is that because anterior teeth are wider faciolingually than mesiodistally, the abutment can reflect the natural tooth cross section [29].

An abutment with minimum flare presents several advantages:

- One size of abutment may be used for most of the patients.
- The abutment is seated on the implant platform and engages the hexagon without circumferential hard or soft tissue interference, which is beneficial because the abutment-to-implant connection may be several millimeters below the tissue.
- Minimal preparation is required if the implant is not in ideal position.
- The emergence profile of the crown is used to create the gingival contour and may be customized to the specific requirement of each area.
- The margin of the crown may be a knife-edge, chamfer, or shoulder and may be placed anywhere on the abutment.
- A knife-edge margin may be extended or shortened in the laboratory once the tissue model is fabricated.
- The abutment can be used for direct and indirect crown fabrication techniques [29].

The disadvantages of an abutment of similar diameter as the implant crest module include (1) a less tapered abutment, (2) a thinner outer wall of the abutment, (3) less material to prepare

when a chamfer or a shoulder margin is preferred, and (4) no clear marking for the laboratory to determine the desired margin location unless a small chamfer is present on the selected abutment [29].

2.3.2.1. Clinical cases

Case 1: The extraoral picture taken from a patient with an osseointegrated implant on the left upper lateral region can be seen in **Figure 3**. Temporary screw-retained crown restoration was prepared and checked for approximately 3 months in order to obtain the recontouring of the emergence profile and interproximal papilla (**Figure 4**). Optimal emergence profile and soft tissue contouring achieved before fabrication of the final restoration can be seen in **Figure 5**. In **Figure 6**, the final crown restoration applied onto custom abutment, which was screw-retained 7 months after the implant surgery can be seen with satisfactory recontoured peri-implanter soft tissue and interproximal papilla. When the distance from the contact point of the crowns to the crest of bone is ≤ 5 mm, there will be no need for periodontal surgery in order to obtain the interproximal dental papilla (**Figure 7**) [44].

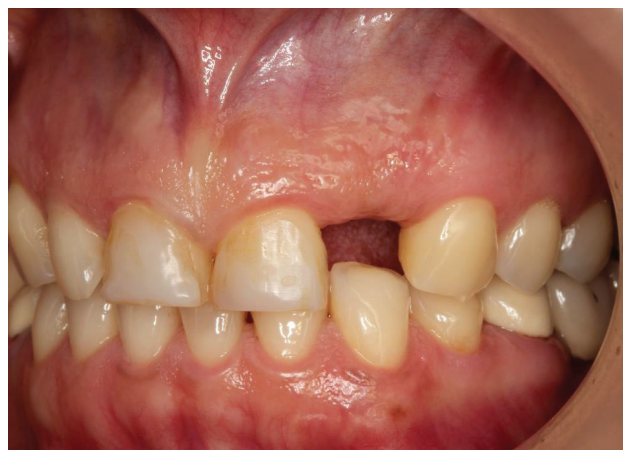

Figure 3. Soft tissue (4 months after implant surgery).

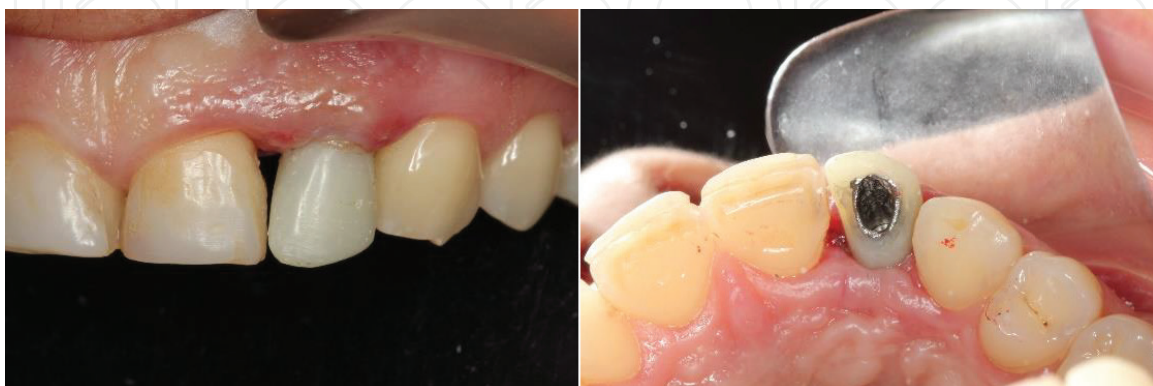

Figure 4. Buccal and palatal view of screw-retained temporary acrylic crown prepared on prefabricated titanium abutment (4 months after implant surgery).

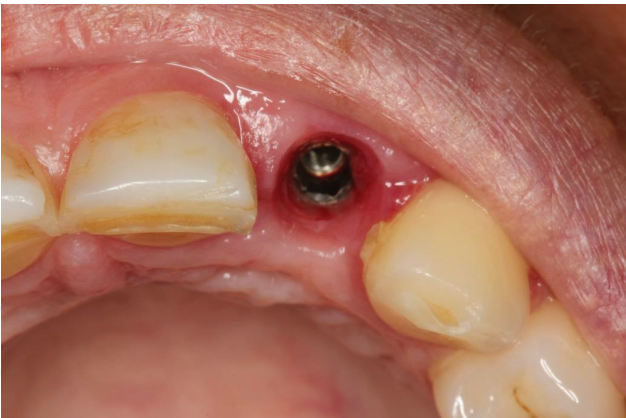

Figure 5. Reshaped emergence profile of the upper lateral incisor tooth.

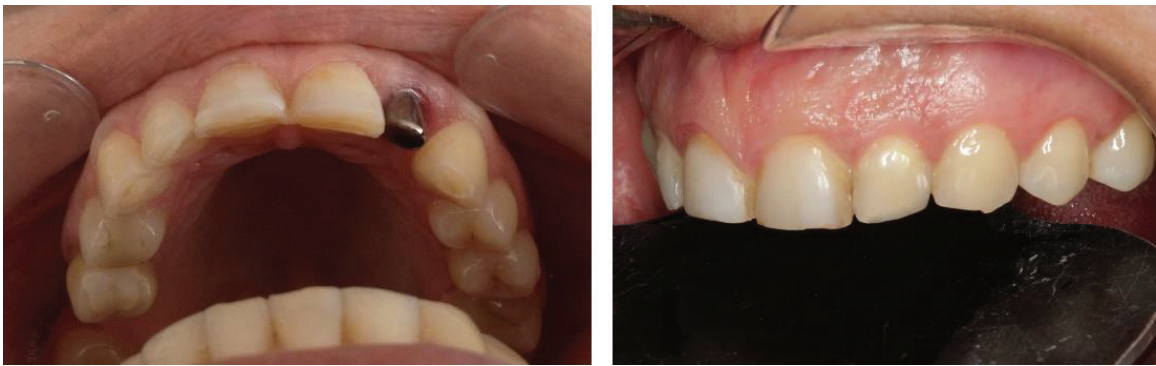

Figure 6. Final crown prepared on custom abutment by the application of veneering porcelain directly on titanium substructure (7 months after implant surgery).

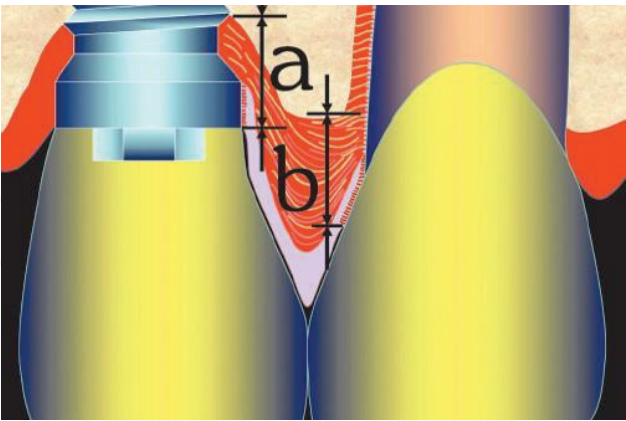


Figure 7. Schematic diagram showing the distance from the contact point of the crowns to the crest of bone.

Case 2: The extraoral picture taken from a patient with an osseointegrated implant on the left upper central incisor region can be seen in **Figures 8 and 9**. Temporary screw-retained crown restoration was prepared and checked for approximately 3 months in order to obtain the recontouring of the emergence profile and interproximal papilla (**Figures 8 and 9**). Following

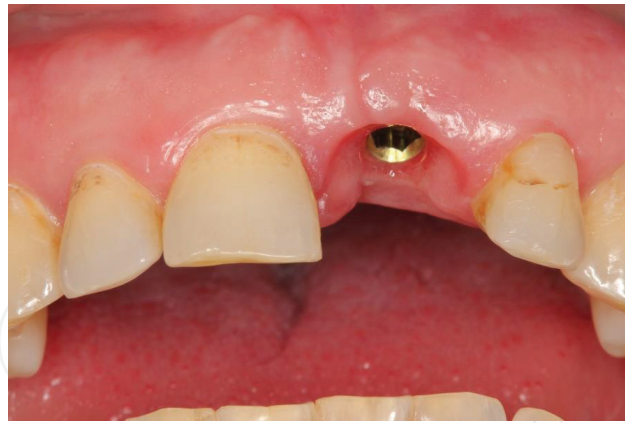

Figure 8. Reshaped emergence profile of the upper left central incisor tooth from buccal view.

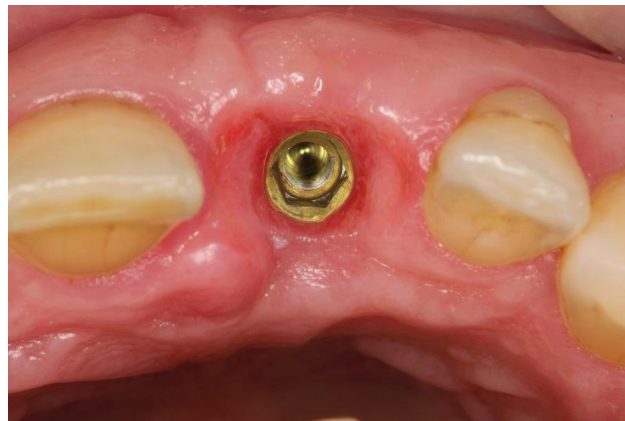

Figure 9. Reshaped emergence profile of upper left central incisor tooth from occlusal view.

the impression of the implant site, custom abutment design was achieved with the aid of a special CAD/CAM software (**Figures 10–12**). In **Figure 13**, custom designed hybrid abutment can be seen following the milling. Following the intraoral check of the custom abutment (**Figure 14**), the feldspathic layering porcelain was applied directly onto the hybrid abutment (**Figure 15**). In **Figures 16 and 17**, the final crown restoration applied onto the custom abutment, which was screw-retained 7 months after the implant surgery can be seen with satisfactory recontoured peri-implanter soft tissue and interproximal papilla.

2.4. Comparison of fracture strength of prefabricated and custom abutments

Most of the studies evaluating the custom abutments in the literature are in-vitro and short-term clinical follow-ups [45–58]. In-vitro studies showed that zirconia-based custom abutments have almost two times higher fracture strength than the alumina-based ones [45, 51]. Although zirconia-based abutments have lower fracture strength than titanium abutments, they were reported to be appropriate for use in clinical practice because of having two times higher strength than biting forces [45, 51]. A recent study reported that fracture strength of custom abutments was higher than prefabricated abutments, which were fabricated with the

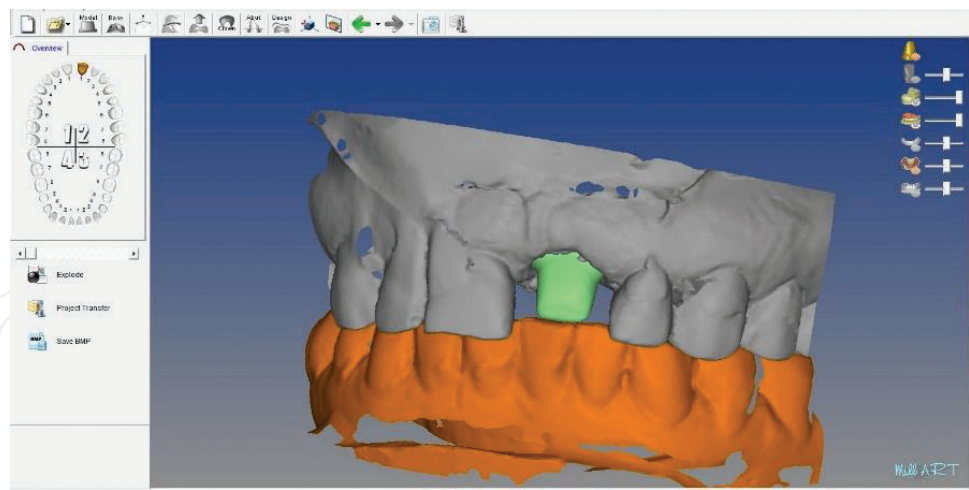


Figure 10. Designing the form of the hybrid abutment according to the occlusion with a CAD/CAM software.

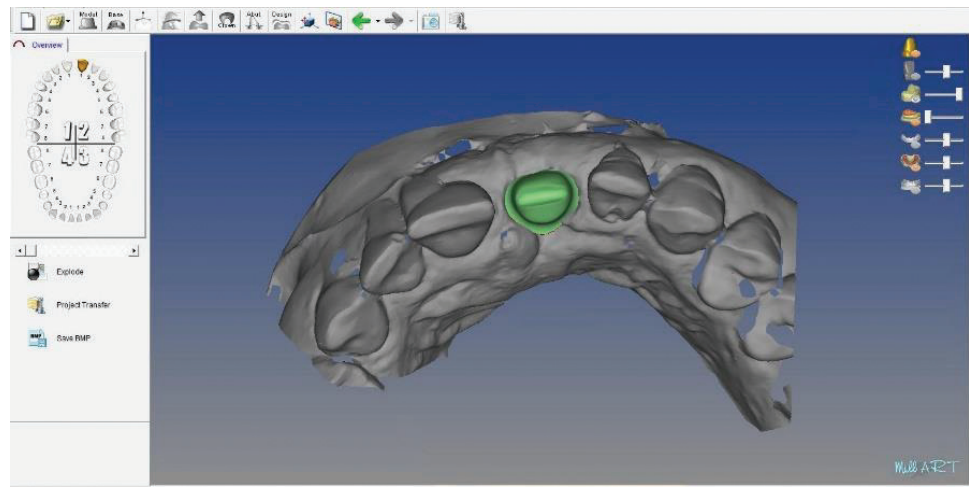


Figure 11. Occlusal view of the designed custom abutment.

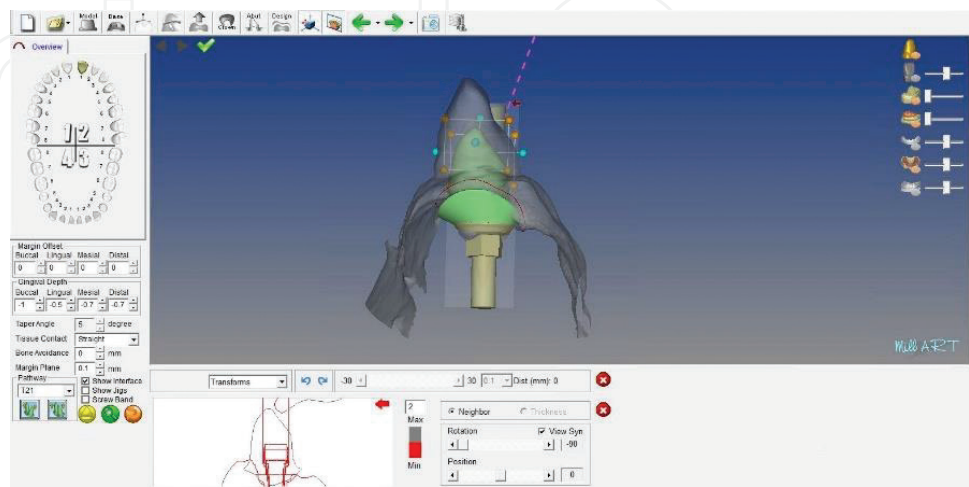


Figure 12. Sectional view of titanium and zirconia parts of the custom designed hybrid abutment.

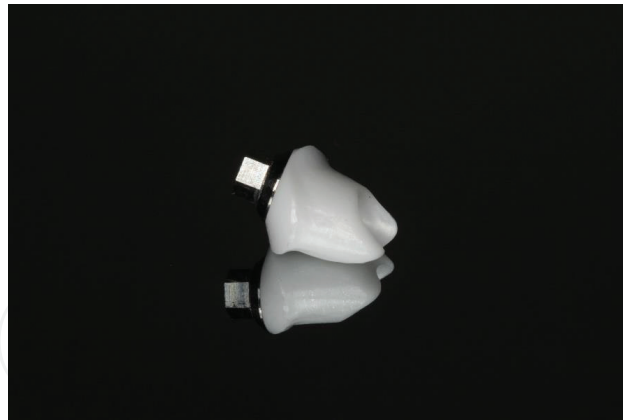


Figure 13. Designed hybrid abutment following milling with a CAM machine.

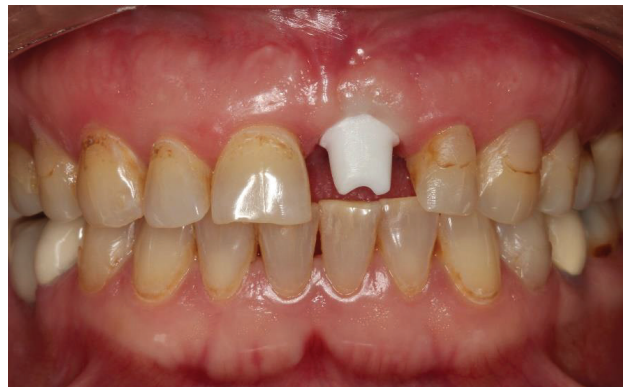

Figure 14. Intraoral check of the abutment.

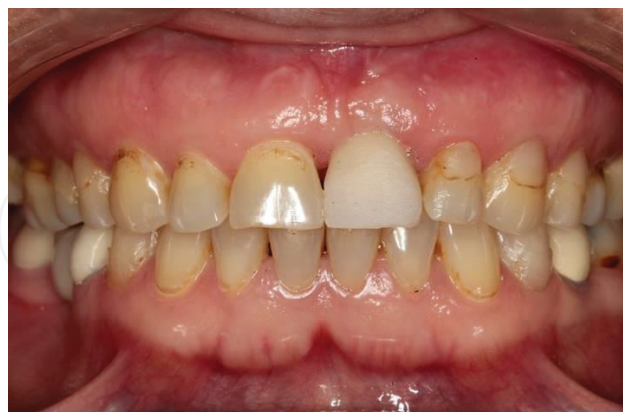

Figure 15. Dentin try-in of screw-retained monolithic implant-supported crown.

same CAD/CAM system [52]. Zembic et al. evaluated titanium- and zirconia-based custom abutments for the anterior single-tooth implant restorations and reported that biological and technical complication rates for both groups were similar at the end of 5 years usage [50]. Vanlioğlu et al. compared prefabricated titanium and custom hybrid abutments applied onto

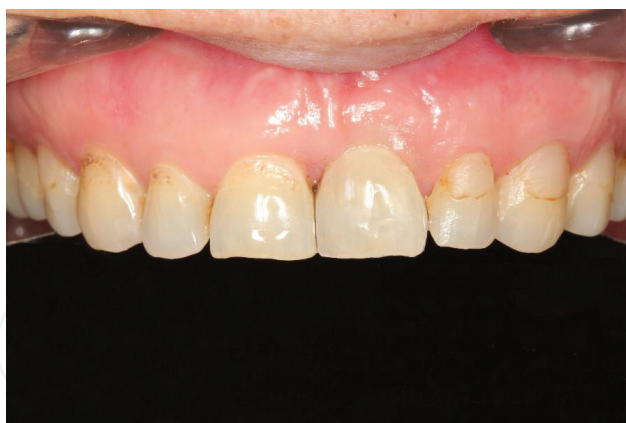

Figure 16. Screw-retained monolithic implant-supported crown.

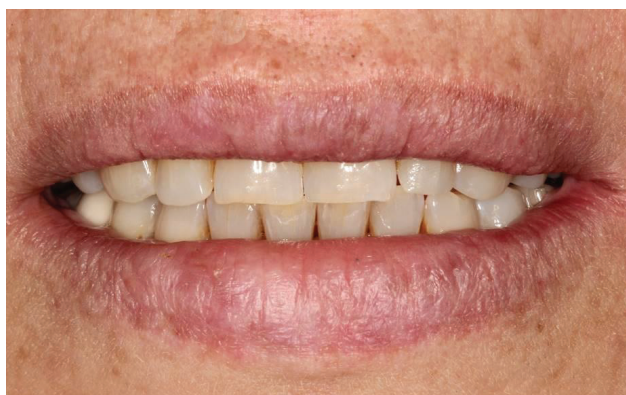

Figure 17. Labial view of the implant-supported crown.

narrow-diameter implants and reported a 100% survival rate at the end of 5 years follow-up [55]. The authors argue that hybrid abutments can be safely used for narrow-diameter implants as well as implants with standard diameters [55]. Prefabricated zirconia-based abutments showed significantly higher fracture strength than the zirconia-based abutments prepared by milling in the laboratory [46]. In-vitro studies showed that for the prefabricated abutments with zirconia neck, fracture occurs mostly at the neck region with varying rates for both the implants with internal and external connections [46]. A study comparing the fracture strength of prefabricated and hybrid abutments applied onto internal and external connected implants revealed that hybrid abutments with internal connection showed significantly higher strength than prefabricated abutments with internal and external connections [58]. Thulasidas et al. compared the fracture strength of angled prefabricated zirconia and custom hybrid abutments and reported that hybrid abutments showed higher strength than angled prefabricated abutments, and both groups showed lower strength values following artificial aging [53]. Similarly, another study evaluating anterior single-tooth restorations revealed that hybrid abutments prepared with 20° angle showed higher strength than straight prefabricated abutments [54]. It was also reported that fractures occurred mostly at implant-abutment interface [54].

3. Conclusions

Custom abutments designed individually with CAD/CAM systems provide optimal esthetics and function while preventing the technician to make possible mistakes during fabrication. In the future, developments in implant dentistry may enable fabrication of stronger abutments in less time and cost, and this will make it possible for the clinicians to make more satisfactory restorations with higher survival rates. Recent studies evaluating the fracture strength of custom and prefabricated abutments mostly report that custom abutments have several advantages and superiority compared to prefabricated ones. However, in-vitro study results related with custom abutment usage must be definitely supported with various long-term clinical follow-up studies in near future before recommending to the clinicians.

Author details

Pinar Turkoglu^{1*}, Adnan Kose² and Deniz Sen¹

*Address all correspondence to: drpturkoglu@yahoo.com

1 Department of Prosthodontics, Faculty of Dentistry, Istanbul University, Istanbul, Turkey

2 Private Practice, Istanbul, Turkey

References

- [1] Jemt T. Modified single and short span restorations supported by osseointegrated fixtures in the partially edentulous jaw. *The Journal of Prosthetic Dentistry*. 1986;**55**:243-246. DOI: 10.1016/0022-3913(86)90352-5
- [2] Avivi-Arber L, Zarb GA. Clinical effectiveness of implant-supported single-tooth replacement: The Toronto study. *The International Journal of Oral & Maxillofacial Implants*. 1996;**11**:311-321
- [3] Lewis S, Beumer J, Hornburg W, Moy P. The "UCLA" abutment. *The International Journal of Oral & Maxillofacial Implants*. 1988;**3**:183-189
- [4] Pjetursson BE, Tan K, Lang NP, Bragger U, Egger M, Zwahlen M. A systematic review of the survival and complication rates of fixed partial dentures (FPDs) after an observation period of at least 5 years. *Clinical Oral Implants Research*. 2004;**15**:625-642. DOI: 10.1111/j.1600-0501.2004.01120.x
- [5] Andersson B. Implants for single-tooth replacement. A clinical and experimental study on the Branemark CeraOne system. *Swedish Dental Journal. Supplement*. 1995;**108**:1-41
- [6] Sailer I, Philipp A, Zembic A, Pjetursson BE, Hammerle CH, Zwahlen M. A systematic review of the performance of ceramic and metal implant abutments supporting fixed

- implant reconstructions. *Clinical Oral Implants Research*. 2009;**20**(suppl 4):4-31. DOI: 10.1111/j.1600-0501.2009.01787.
- [7] Zembic A, Sailer I, Jung RE, Hammerle CH. Randomized-controlled clinical trial of customized zirconia and titanium implant abutments for single-tooth implants in canine and posterior regions: 3-year results. *Clinical Oral Implants Research*. 2009;**20**:802-808. DOI: 10.1111/j.1600-0501.2009.01717.x
 - [8] Jung RE, Holderegger C, Sailer I, Khraisat A, Suter A, Hammerle CH. The effect of all-ceramic and porcelain-fused-to-metal restorations on marginal peri-implant soft tissue color: A randomized controlled clinical trial. *The International Journal of Periodontics & Restorative Dentistry*. 2008;**28**:357-365. DOI: 10.5167/uzh-9284
 - [9] Park SE, Da Silva JD, Weber HP, Ishika-wa-Nagai S. Optical phenomenon of peri-implant soft tissue. Part I. Spectrophotometric assessment of natural tooth gingiva and peri-implant mucosa. *Clinical Oral Implants Research*. 2007;**18**:569-574. DOI: 10.1111/j.1600-0501.2007.01391.x
 - [10] Bressan E, Paniz G, Lops D, Corazza B, Romeo E, Favero G. Influence of abutment material on the gingival color of implant-supported all-ceramic restorations: A prospective multicenter study. *Clinical Oral Implants Research*. 2011;**22**:631-637. DOI: 10.1111/j.1600-0501.2010.02008.x
 - [11] van Brakel R, Noordmans HJ, Frenken J, de Roode R, de Wit GC, Cune MS. The effect of zirconia and titanium implant abutments on light reflection of the supporting soft tissues. *Clinical Oral Implants Research*. 2011;**22**:1172-1178. DOI: 0.1111/j.1600-0501.2010.02082.x
 - [12] Prestipino V, Ingber A. Esthetic high strength implant abutments. Part I. *Journal of Esthetic Dentistry*. 1993;**5**:29-36. DOI: 10.1111/j.1708-8240.1993.tb00741.x
 - [13] Prestipino V, Ingber A. Esthetic high strength implant abutments. Part II. *Journal of Esthetic Dentistry*. 1993;**5**:63-68. DOI: 10.1111/j.1708-8240.1993.tb00750.x
 - [14] Prestipino V, Ingber A. All-ceramic implant abutments. Esthetic indications. *Journal of Esthetic Dentistry*. 1996;**8**:255-262. DOI: 10.1111/j.1708-8240.1996.tb00876.x
 - [15] Henriksson K, Jemt T. Evaluation of custom-made procera ceramic abutments for single-implant tooth replacement: A prospective 1-year follow-up study. *The International Journal of Prosthodontics*. 2003;**16**:626-630
 - [16] Glauser R, Sailer I, Wohlwend A, et al. Experimental zirconia abutments for implant-supported single-tooth restorations in esthetically demanding regions: 4-year results of a prospective clinical study. *The International Journal of Prosthodontics*. 2004;**17**:285-290
 - [17] Scarano A, Piattelli M, Caputi S, Favero GA, Piattelli A. Bacterial adhesion on commercially pure titanium and zirconium oxide disks: An in vivo human study. *Journal of Periodontology*. 2004;**75**:292-296
 - [18] Ichikawa Y, Akagawa Y, Nikai H, Tsuru H. Tissue compatibility and stability of a new zirconia ceramic in vivo. *The Journal of Prosthetic Dentistry*. 1992;**68**:322-326

- [19] Piconi C, Maccauro G. Zirconia as a ceramic biomaterial. *Biomaterials*. 1999;**20**:1-25
- [20] Marchack CB. A custom titanium abutment for the anterior single-tooth implant. *Journal of Prosthetic Dentistry*. 1996;**76**:288-291
- [21] Ekfeldt A, Fürst B, Carlsson GE. Zirconia abutments for single-tooth implant restorations: A retrospective and clinical follow-up study. *Clinical Oral Implants Research*. 2011;**22**(11):1308-1314
- [22] Bidra AS, Rungruanganunt P. Clinical outcomes of implant abutments in the anterior region: A systematic review. *Journal of Esthetic and Restorative Dentistry*. 2013;**25**(3):159-176
- [23] Garner LD, Kotwal NS. Correlation study of incisive biting forces with age, sex, and anterior occlusion. *Journal of Dental Research*. 1973;**52**:698-702
- [24] Kumagai H, Suzuki T, Hamada T, et al. Occlusal force distribution on the dental arch during various levels of clenching. *Journal of Oral Rehabilitation*. 1999;**26**:932-935
- [25] Warreth A et al. An introduction to single implant abutments. *Dental Update*. 2013;**40**(1):7-17
- [26] Hermann JS, Schoolfield JD, Schenk RK, Buser D, Cochran DL. Influence of the size of the microgap on crestal bone changes around titanium implants. A histometric evaluation of unloaded non-submerged implants in the canine mandible. *Journal of Periodontology*. 2001;**72**:1372-1383
- [27] Newsome P, Reaney D, Owen S. Screw-versus cement-retained crowns. *Irish Dentist*. 2011;**3**:22-25
- [28] Kallus T et al. Clinical evaluation of angulated abutments for the Brånemark system: A pilot study. *International Journal of Oral & Maxillofacial Implants*. 1990;**5**:1
- [29] Misch CE. *Dental Implant Prosthetics-E-Book*. St.Louis: Elsevier, Mosby; 2014
- [30] Joda T, Wittneben JG, Brägger U. Digital implant impressions with the "Individualized Scanbody Technique" for emergence profile support. *Clinical Oral Implants Research*. 2014;**25**:395-397
- [31] Osman RB, Swain VB. A critical review of dental implant materials with an emphasis on titanium versus zirconia. *Materials*. 2015;**8**:932-958
- [32] Ormianer Z, Schioli G. Maxillary single-tooth replacement utilizing a novel ceramic restorative system: Results to 30 months. *The Journal of Oral Implantology*. 2006;**32**:190-199
- [33] Firidinoğlu K, Toksavul S, Toman M. İmplant destekli sabit protezlerde seramik abutment kullanımı. *Ege Üniversitesi Dişhekimliği Fakültesi Dergisi*. 2007;**28**:145-150
- [34] Butz F, Heydecke G, Okutan M, Strub JR. Survival rate, fracture strength and failure mode of ceramic implant abutments after chewing simulation. *Journal of Oral Rehabilitation*. 2005;**32**:838-843

- [35] Tan PL, Dunne JT. An esthetic comparison of a metal ceramic crown and cast metal abutment with an all-ceramic crown and zirconia abutment: A clinical report. *The Journal of Prosthetic Dentistry*. 2004;**91**(3):215-218
- [36] Binon PP. Implants and components: Entering the new millennium. *The International Journal of Oral & Maxillofacial Implants*. 2000;**15**:76-94
- [37] Brodbeck U. The ZiReal Post: A new ceramic implant abutment. *Journal of Esthetic and Restorative Dentistry*. 2003;**15**:10-23
- [38] Stimmelmayer M, Edelhoff D, Guth JF, Erdelt K, Happe A, Beuer F. Wear at the titanium-titanium and the titanium-zirconia implant-abutment interface: A comparative in vitro study. *Dental Materials*. 2012;**28**:1215-1220
- [39] Kurbad A, Kurbad S. CAD/CAM-based implant abutments. *International Journal of Computerized Dentistry*. 2013;**16**(2):125-141
- [40] Gehrke P, Johansson D, Fischer C, Stawarczyk B, Beuer F. In vitro fatigue and fracture resistance of one- and two-piece CAD/CAM zirconia implant abutments. *The International Journal of Oral & Maxillofacial Implants*. 2015;**30**(3):546-554
- [41] Martinez-Rus F, Ferreiroa A, Ozcan M, Bartolome JF, Pradies G. Fracture resistance of crowns cemented on titanium and zirconia implant abutments: A comparison of monolithic versus manually veneered all-ceramic systems. *The International Journal of Oral & Maxillofacial Implants*. 2012;**27**:1448-1455
- [42] Jung RE, Sailer I, Hämmerle CH, Attin T, Schmidlin P. In vitro color changes of soft tissues caused by restorative materials. *The International Journal of Periodontics & Restorative Dentistry*. 2007;**27**(3):251-257
- [43] Daftary F, Bahat O. Prosthetically formulated natural aesthetics in implant prostheses. *Practical Periodontics and Aesthetic Dentistry*: Ppad 6. 1994;**9**:75-83
- [44] Tarnow DP, Magner AW, Fletcher P. The effect of the distance from the contact point to the crest of bone on the presence or absence of the interproximal dental papilla. *Journal of Periodontology*. 1992;**63**(12):995-996
- [45] Yildirim M, Fischer H, Marx R, Edelhoff D. In vivo fracture resistance of implant-supported all-ceramic restorations. *The Journal of Prosthetic Dentistry*. 2003;**90**(4):325-331
- [46] Alqahtani F, Flinton R. Postfatigue fracture resistance of modified prefabricated zirconia implant abutments. *The Journal of Prosthetic Dentistry*. 2014;**112**(2):299-305
- [47] Manicone PF, Rossi Iommetti P, Raffaelli L. An overview of zirconia ceramics: Basic properties and clinical applications. *Journal of Dentistry*. 2007;**35**(11):819-826
- [48] Ozkurt Z, Kazazoglu E. Clinical success of zirconia in dental applications. *Journal of Prosthodontics*. 2010;**19**:64-68
- [49] Ardlin BI. Transformation-toughened zirconia for dental inlays, crowns and bridges: Chemical stability and effect of low temperature aging on the flexural strength and surface structure. *Dental Materials*. 2002;**18**(8):590-595

- [50] Zembic A, Bösch A, Jung RE, Hämmerle CH, Sailer I. Five-year results of a randomized controlled clinical trial comparing zirconia and titanium abutments supporting single implant crowns in canine and posterior regions. *Clinical Oral Implants Research*. 2013;**24**(4):384-390
- [51] Mitsias ME, Silva NR, Pines M, Stappert C, Thompson VP. Reliability and fatigue damage modes of zirconia and titanium abutments. *The International Journal of Prosthodontics*. 2010;**23**(1):56-59
- [52] Park JI, Lee Y, Lee JH, Kim YL, Bae JM, Cho HW. Comparison of fracture resistance and fit accuracy of customized zirconia abutments with prefabricated zirconia abutments in internal hexagonal implants. *Clinical Implant Dentistry and Related Research*. 2013;**15**(5):769-778
- [53] Thulasidas S, Givan DA, Lemons JE, O'Neal SJ, Ramp LC, Liu PR. Influence of implant angulation on the fracture resistance of zirconia abutments. *Journal of Prosthodontics*. 2015;**24**(2):127-135
- [54] Nothdurft FP, Doppler KE, Erdelt KJ, Knauber AW, Pospiech PR. Fracture behavior of straight or angulated zirconia implant abutments supporting anterior single crowns. *Clinical Oral Investigations*. 2011;**15**(2):157-163
- [55] Vanlıoglu BA, Özkan Y, Evren B, Özkan YK. Experimental custom-made zirconia abutments for narrow implants in esthetically demanding regions: A 5-year follow-up. *The International Journal of Oral & Maxillofacial Implants*. 2012;**27**(5):1239-1242
- [56] Moon IS, Berglundh T, Abrahamsson I, Linder E, Lindhe J. The barrier between the keratinized mucosa and the dental implant. An experimental study in the dog. *Journal of Clinical Periodontology*. 1999;**26**(10):658-663
- [57] Nascimento C, Pita MS, Pedrazzi V, de Albuquerque Junior RF, Ribeiro RF. In vivo evaluation of *Candida* spp. adhesion on titanium or zirconia abutment surfaces. *Archives of Oral Biology*. 2013;**58**(7):853-861
- [58] Sailer I, Sailer T, Stawarczyk B, Jung RE, Hämmerle CH. In vitro study of the influence of the type of connection on the fracture load of zirconia abutments with internal and external implant-abutment connections. *The International Journal of Oral & Maxillofacial Implants*. 2009;**24**(5):850-858

