

# We are IntechOpen, the world's leading publisher of Open Access books Built by scientists, for scientists

6,900

Open access books available

185,000

International authors and editors

200M

Downloads

Our authors are among the

154

Countries delivered to

TOP 1%

most cited scientists

12.2%

Contributors from top 500 universities



WEB OF SCIENCE™

Selection of our books indexed in the Book Citation Index  
in Web of Science™ Core Collection (BKCI)

Interested in publishing with us?  
Contact [book.department@intechopen.com](mailto:book.department@intechopen.com)

Numbers displayed above are based on latest data collected.  
For more information visit [www.intechopen.com](http://www.intechopen.com)



# Platelet-Rich Plasma for Injured Peripheral Nerves: Biological Repair Process and Clinical Application Guidelines

*Mikel Sánchez, Ane Garate, Ane Miren Bilbao, Jaime Oraa, Fernando Yangüela, Pello Sánchez, Jorge Guadilla, Beatriz Aizpurua, Juan Azofra, Nicolás Fiz and Diego Delgado*

## Abstract

Platelet-rich plasma (PRP) is a biological therapy that uses the patient's own blood to obtain products with a higher platelet concentration than in blood. It provides a transient fibrin scaffold as a controlled drug delivery system of growth factors suitable for regenerative medicine. PRP has been used as medical strategy to treat diverse types of injuries in the field of orthopedics, including peripheral nerve lesions. In vitro and in vivo studies showed the neuroprotective, neurogenic and neuroinflammatory modulator effect of PRP. In addition, it has been demonstrated clinically that PRP infiltrations improve clinical symptoms and enhance the sensory and motor functional nerve muscle unit recovery. Potential effects of PRP could be applied in treatments for neuropathies, as conservative treatment by means of nerve ultrasound-guided infiltrations or as biological adjuvant during surgery.

**Keywords:** platelet-rich plasma, growth factors, neuropathies, intraneural injection, perineural injection, US-guided injection

## 1. Introduction

Diverse health conditions or traumatic injuries such as accidents, stretching or compressions may cause damage on nerves. Some options to treat these damages are oral drugs, steroid injections, physical therapy or surgical interventions. Probably, nerve autografts or direct tension-free microsurgical repairs are the most common treatments aimed to enhance the intrinsic regenerative potential of injured axons. However, they do not recreate the suitable cellular and molecular microenvironment of peripheral nerve repair.

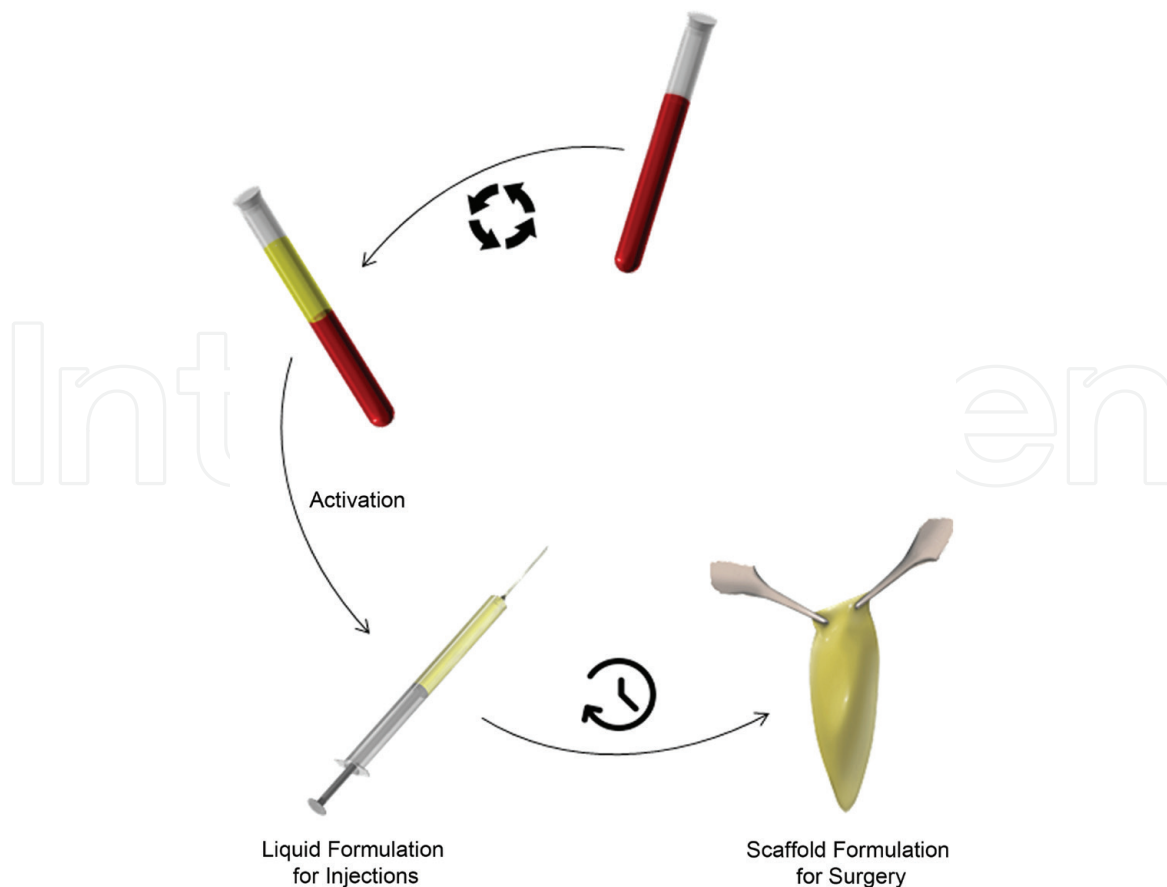
To overcome this drawback, new therapeutic strategies have been developed for these conditions, using various models of nerve injuries. In vitro models of neuronal survival include cell cultures or tissue engineering advances, whereas in vivo models involve lesions in peripheral nerves of many species. These studies lead to

develop new strategies based on tissue engineering approaches through molecular intervention and scaffolding, and platelet-rich plasma (PRP) represents one of these promising biological strategies. Large number of studies provides evidence for PRP application in musculoskeletal disorders and orthopedics. Applications include treatments of chondropathy, osteoarthritis, tendinopathy, muscle or ligament tear, acute and chronic soft tissue injuries, as well as enhancement of healing after bone or tissue reconstruction [1]. In addition to its positive effects on the healing of many types of tissues, recent studies reported the promising effects of PRP on nerve regeneration [2]. Indeed, several preclinical and clinical studies have proved the neuroprotective, neurogenic and neuroinflammatory properties of this therapy. Moreover, pain reduction, function improvement and nerve-muscle unit recovery have been demonstrated after applying diverse PRP formulations including liquid and scaffold form. This chapter is intended to overview the advances made on this specific field, focusing on the concept of PRP, its biological effects on nerve repair and its clinical application.

## **2. Platelet-rich plasma**

PRP is an autologous product with a higher platelet concentration than in blood. It consists of a pool of bioactive mediators including growth factors (GF), cytokines, microparticles and others from patient's own blood. Currently, there are several methods and commercial devices to achieve PRP, obtaining a diversity of products including autologous conditioned plasma, platelet-enriched plasma, platelet-rich concentrate, autogenous platelet gel, platelet releasate, platelet rich in GFs and others [3]. Some parameters and characteristics such as platelet concentration, the presence of leucocytes or the fibrin architecture may vary depending on the method or device employed to obtain these refined products. The processing technique to achieve PRP mostly consists of a blood collection in the presence of an anticoagulant followed by centrifugation. This centrifugation separates the blood components with the aim of discarding substances considered as not usable such as red blood cells and concentrating the elements with therapeutic potential, for instance fibrinogen/fibrin, platelets or GF, with or without leukocytes (**Figure 1**). Before its administration, an activating factor such as thrombin or calcium is added to the platelet concentrate to promote platelet degranulation and exocytosis of the factors stored in the cytoplasmic granules [4].

Indeed, the potential effect of PRP is closely related with the release of bioactive molecules stored in alpha granules of platelets after its activation with the activating factor [5]. Platelet-derived growth factor (PDGF), transforming growth factor (TGF- $\beta$ ), epidermal growth factor (EGF), insulin-like growth factor (IGF-1), hepatocyte growth factor (HGF), basic fibroblasts growth factor (FGF) and vascular endothelial growth factor (VEGF) are some of the key proteins associated with the acceleration of healing process, since they modulate angiogenesis, remodel the extracellular matrix (ECM) and affect the recruitment, proliferation and differentiation of stem cells [6]. The wide variety of elements found in platelet granules act synergistically under normal physiological conditions on local cells to promote wound healing. On the other hand, plasma activation also promotes the polymerization of fibrinogen into a three-dimensional fibrin scaffold (**Figure 1**), maintaining the bioactive mediators trapped through fibrin heparin sulfate-binding domains [1]. This biocompatible and biodegradable scaffold provides plastic-elastic stiffness and generates GF gradients that are essential cues for cell proliferation, differentiation, migration and correct orientation in the nascent tissue [7]. When fibrinolysis begins, a gradual, sustained release of GF and other biomolecules occurs, in contrast to a bolus delivery modality. Thus, this technology provides a fibrin scaffold as a controlled drug delivery system of GF suitable for regenerative medicine [8].



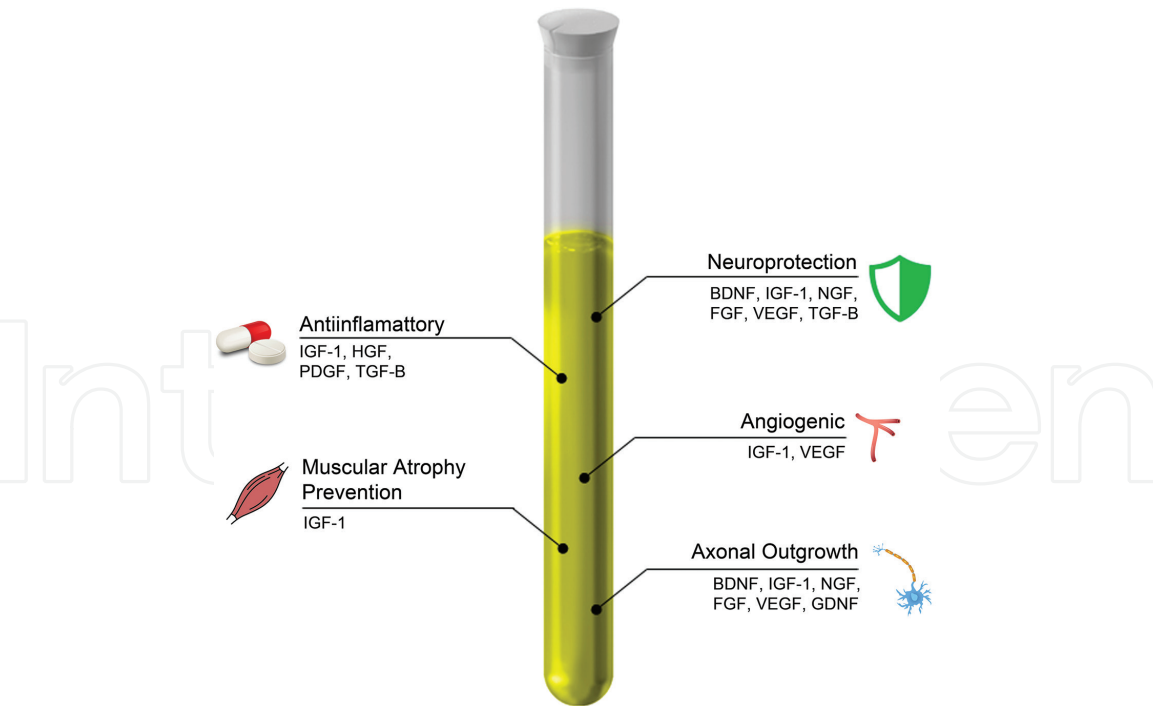
**Figure 1.**

*Platelet-rich plasma formulation. After withdrawing a small volume of venous blood in tubes containing anticoagulant, these are centrifuged in order to separate the blood components. The plasma fraction located just above the red blood cells is collected including or not leukocytes. PRP is activated adding thrombin or calcium to promote platelet degranulation and exocytosis of GF. This liquid formulation is used to conduct PRP injections. If after activation, the waiting time is prolonged, fibrin formation is achieved, obtaining a scaffold for applying in surgery.*

Due to its primarily autologous origin and relatively noninvasive collection technique, the risks of injection or immune rejection associated with PRP are minimized, making this biological therapy a powerful tool for its application on diverse medical fields. Thus, this strategy has been employed as a biological adjuvant in peripheral nerve injuries and neuropathies, enhancing the sensory and motor functional nerve-muscle unit recovery [9]. In cases of nontraumatic peripheral injuries such as compression, adhesion and/or fibrotic postsurgical side effects, PRP may help diminish undesirable consequences such as denervated organ atrophy and fibrotic scars.

### 3. Biological effects of PRP on nerve regeneration

Among therapeutic alternatives to restore damaged nerves, PRP is gaining attention, since it provides the infiltrated environment with a pool of GF inducing healing and regeneration of the tissue. Nerve growth factor (NGF), brain-derived neurotrophic factor (BDNF) and PDGF are some of PRP components that can improve nerve regeneration. However, a sustained delivery of several GFs is not the unique constituent of PRP effect on nerve regeneration. Indeed, in vitro and in vivo evidence suggests that the biomolecules transmitted by PRP are instrumental agents that act as key drivers of full nerve functional recovery, offering a new possibility for nerve regeneration (**Figure 2**).



**Figure 2.**  
*Effects of PRP on nerve repair. Biomolecules and GF participate jointly and synergistically in several biological processes involved in nerve regeneration.*

### 3.1 Neuroprotection and prevention of cell apoptosis

An important factor that plays a critical role in many functions within the nervous system including neurogenesis and neuroprotective function is BDNF. One of the most important benefits that this biomolecule offers is its ability to inhibit neuronal and glial apoptosis after traumatic injury. A work carried out by Koda et al. proved that BDNF suppressed in a dose-dependent manner anoikis of Schwann cells (SC), which are able to promote axonal regeneration and functional recovery [10]. This effect is based on the activation or transdifferentiation of SCs, a drastic modification of the phenotype of this cell type that takes place after the disruption of the regeneration unit by the noxious agent. Macrophages will collaborate with the activated SCs clearing the myelin and other tissue debris. Moreover, these SCs come into direct contact with resident fibroblasts accumulated in large numbers at the site of injury, influencing SC migration and transdifferentiation. In another work, Wang et al. found that mesenchymal stem cells (MSCs) transfected with Ad-BDNF enhance the expression of BDNF, recovering brain damage. They suggest that BDNF-MSCs have a potential protective effect against neuron death by apoptosis [11]. In another study, Zurita et al. enriched PRP fibrin scaffolds with bone marrow stromal cells with BDNF, NGF and retinoic acid, enhancing cell survival and differentiation into the neural phenotype [12]. Another GF related with neuronal and Schwann cell survival is IGF-1. This factor acts as neurotrophic factor for sensory, motor and sympathetic neurons to promote growth cone motility and prevent apoptosis [13]. It has also been proved that neurons express PDGF receptors, and the function related with this GF on nerve injury also involves the survival for Schwann cells with trophic activity on neurons [14]. Other substances such as NGF, FGF, VEGF and TGF- $\beta$  presented in PRP have shown to exert an antiapoptotic and neuroprotective effect on diverse cell types such as MSCs, neurons, Schwann cells and human neural stem cells [15].



### 3.2 Anti-inflammatory effects

Anti-inflammatory action of PRP is associated with an inhibition of nuclear transcription factor- $\kappa$ B (NF- $\kappa$ B) pathway, which was observed after culturing astrocytes with PRP supernatants [16]. Some of the GFs such as HGF, IGF-1, PDGF and TGF- $\beta$  delivered in a sustained way after PRP infiltrations are closely related with these effects [15]. TGF- $\beta$  also affects cellular behavior, the neurite outgrowth and glial scar formation [17]. Outcomes from an in vivo study further suggested that TGF- $\beta$  coordinated with adipose-derived MSCs enhanced nerve regeneration affecting the host's immune response and reducing inflammation [15].

PRP injections have been associated with a decrease of proinflammatory substances such as nitric oxide, cyclooxygenase and tumor necrosis factor expressed in the brain [16]. In addition, PRP is able to block Ab-induced upregulation of proinflammatory cytokine production, and this capacity was correlated with a prevention of the decrease in several synaptic proteins.

### 3.3 Angiogenic properties

Among the substances that PRP contains, VEGF is one of the most angiogenic factors. It stimulates proliferation and migration of endothelial cells, formation of new blood vessels and enhances vascular permeability. This action is conducted by transmembrane receptors found in neural tissue, especially on growth cones of sprouting axons and Schwann cells [18]. VEGF can act as a neurotrophic factor by promoting Schwann cell proliferation and neurite outgrowth and enhance nerve survival [19]. However, despite the evidence that PRP promotes angiogenesis in tendon, muscle and bone and the crucial role that blood vessels play as trackers of the axonal growth cones across the injury site, there is lack of studies assessing angiogenesis in nerve repair. Borselli et al. showed that an injectable scaffold loaded with VEGF and IGF-1 accelerated regeneration of damaged neuromuscular junction innervation together with an enhancement of angiogenesis in an ischemic limb rodent model [20]. Another study demonstrated that vein graft filled with PRP provides an earlier and more prominent neoangiogenesis than sciatic nerve gaps treated with nerve autograft alone [21]. The fibrin obtained after PRP activation provides a permissive and robust 3D matrix for angiogenesis. In fact, autologous fibrin matrix is the best tailored transient scaffold for tissue regeneration where complex morphogenetic processes for tissue regeneration take place, including angiogenesis, cell migration and proliferation [22].

### 3.4 Enhancing axonal outgrowth capacity

Schwann cells provide bioactive substrates for axonal migration and they release neurotrophic factors able to regulate axonal outgrowth. An optimal proliferation and viability may affect the rapid regeneration of injured peripheral nerves. PRP might allow the sprouting of growth cones since they promote survival, proliferation and differentiation of Schwann cells. In that sense, Zheng et al. showed a dose-dependent effect of PRP on the proliferation, migration and neurotrophic function in rat Schwann cells cultured with PRP [23]. The significant role played by GF within the PRP has also been highlighted in a rat brain-spinal cord cocultured system, where the addition of PRP supernatant promoted an increase in the size and number of axons. This positive effect was significantly suppressed by the addition of antibodies against IGF-1 and VEGF [24].

Solid form of PRP also demonstrated its positive effect on both axonal myelination and its density enhancement. Ye et al. fabricated tissue-engineered nerves

based on poly (lactic-co-glycolic acid) conduit using PRP gel for suspension of Schwann cell-like cells. PRP group presented superior functionality in both nerve conduction velocity and compound muscle action potential. They suggest that PRP gel plays a dual role: first, the fibrin network as matrix for regenerative cell incorporation, and second, biomolecules that improve the biological environment stimulating the regenerative processes of nerve fibers [25]. Indeed, the PRP bioactive proteins initiate and control the healing cascade of nerve fibers. Increasing the concentration of these bioactive proteins such as TGF- $\beta$ , PDGF and IGF-1 could accelerate healing of the regenerating nerve fibers [26]. Other studies realized in rabbits after implantation of PRP together with Schwann cells [27] reported beneficial effects on axonal counts, myelination and electrophysiological parameters. Cho et al. observed considerably increased expression of neurotrophic factors such as BDNF, NGF, FGF and Glial cell-derived neurotrophic factor (GDNF) after PRP injection in guinea pigs with facial nerve transection, suggesting that PRP and MSCs act as a source of neurotrophic factors. They also could prove an enhancement of axon counts and myelination in the groups treated with PRP [27]. An inside-out vein autograft filled with PRP was used to bridge a 10-mm-long sciatic nerve defect in rats [21]. The axon diameter, the number of myelinated axons and myelin sheath were significantly superior when vein autograph was filled with PRP. In another rat model, they used platelet-rich fibrin (PRF) as a filler of silicon nerve guidance. Animals treated with PRP improved functional recovery and showed a superior sciatic functional index compared to nontreated animals [28].

### **3.5 Dampening the denervated target muscle atrophy**

The acceleration of axonal growth can prevent muscle atrophy, since it reduces the time to establish a connection between the sprouting axon and target muscle [29]. PRP applications induce an earlier axonal regeneration and functional recovery, which also can have a consequence reducing the target muscle atrophy. In the work carried out by Sánchez et al., they could observe this positive effect since nerves repaired with intraneural infiltrations of PRP were associated with lower muscle atrophy and an earlier electrophysiological recovery [30]. In some peripheral nerve injuries such as carpal tunnel syndrome or fibrotic postsurgical side effects, the main pathological agent is compression, adhesion and/or fibrosis. The use of PRP may additionally avoid or at least diminish denervated organ atrophy and undesirable fibrotic scars, thereby accelerating the functional recovery of the nerve-muscle unit, due to its antifibrotic effects [24, 31]. Intramuscular injection of PRP 24 hours after the induction of limb ischemia in mice mitigated fibrosis and muscle atrophy [32]. These results are in agreement with the reduction of atrophy in denervated muscle reported when muscle was infiltrated with cells [33], effects suggested to be mediated by IGF-1 [34].

## **4. Clinical guidelines for the application of platelet-rich plasma in injured peripheral nerves: from bench to bedside**

Although the biological effects described previously mean a promising therapeutic tool, the success to achieve optimal clinical results lies in several factors such as PRP preparation, dosage and application protocols.

### **4.1 PRP preparation**

Physicians face a large number of systems to obtain PRP and therefore different types of final products. These depend on variables such as platelet

concentration, the presence or absence of leukocytes and the exogenous activation of PRP. Although there is still no consensus on which is the best product to use in orthopedic pathologies, according to preclinical research and our experience, we suggest choosing a product with specific characteristics.

An excessive number of platelets could not only suppress the therapeutic action of PRP but also inhibit the tissue repair process. PRP with excess platelet concentration had negative influence over cellular responses such as proliferation, viability or differentiation [35]. Thus, it seems that a concentration of platelet slightly higher than blood is suitable to achieve an optimal response. The presence of leukocytes in PRP products is more controversial. While in tissues like cartilage the scale tips in favor of the PRP without leukocytes, in other applications, it is not clear. The presence of leukocytes fosters the nuclear NF- $\kappa$ B p65 protein expression, which is key in the activation of cellular inflammation, and oddly enough, it is inhibited by PRP [36]. Finally, and although platelets within PRP can be activated endogenously by tissue collagen, we recommend the previous activation in an exogenous way, which is carried out by adding calcium to PRP. As calcium was chelated during blood extraction to avoid coagulation, we restore the levels of it in PRP preventing hypocalcemia in nerve environment during infiltration. The activation triggers the formation of a fibrin 3D liquid scaffold that spreads over the tissue, delivering GF in a control manner. After activation, PRP must be injected immediately during the following 10 minutes. Without activating, it can be stored for 3–4 hours without losing its efficacy. PRP can be applied also as a fibrin scaffold for using in surgery. This scaffold is obtained in the same way as the liquid formulation, except that after its activation, the waiting time before its use is prolonged until the formation of the fibrin scaffold (**Figure 1**). Despite these recommendations, it is in the hands of the professional who applies PRP to choose the best suitable type, and following the manufacturer's protocol is advisable to obtain an optimal product.

## 4.2 Conducting nerve infiltrations

In order to achieve the biological effects described in Section 3, PRP must be administered in an adequate manner to reach the target tissue and cells that are key elements in nerve repair process such as Schwann cells. However, they are in the innermost compartment of the nerve, inside the fascicles that enclose the axons covered by the myelin sheaths, and getting to them is a major issue. For many years, nerve infiltration has been and still is a controversial point for physicians and medical specialists. Although a possible cause of nerve lesions during an injection is the ischemic damage due to increased pressure inside the nerve, the most likely reason is the neurotoxicity of the injected drug such as corticosteroids or local anesthetics. Several studies demonstrated that the injuries caused to the nerve after infiltrations were because of the injected drug or its dose, and not because of the physical act of infiltrating [37].

The compartment of the nerve where the injection is performed is also a sensitive point to consider. Although some studies recommend avoiding intraneural injection due to high risk of nerve lesion [38], it is necessary to be more precise in this description. We must distinguish between extrafascicular and intrafascicular injection, the former being safe and without any evidence of nerve injury [39]. In contrast, some studies conclude that the main cause of neurologic injury is the intrafascicular injections [40]. Brierley et al. studied the progression of nerve lesions in some diseases like tetanus or poliomyelitis using radioactive phosphorus. He found that the phosphorus reached the blood stream, the cerebrospinal fluid and the nervous system when the needle penetrated into the fasciculus, thus being an intrafascicular injection [41]. Diffusion studies of PRP into the nerve carried out by our group showed that PRP previously stained with methylene blue was



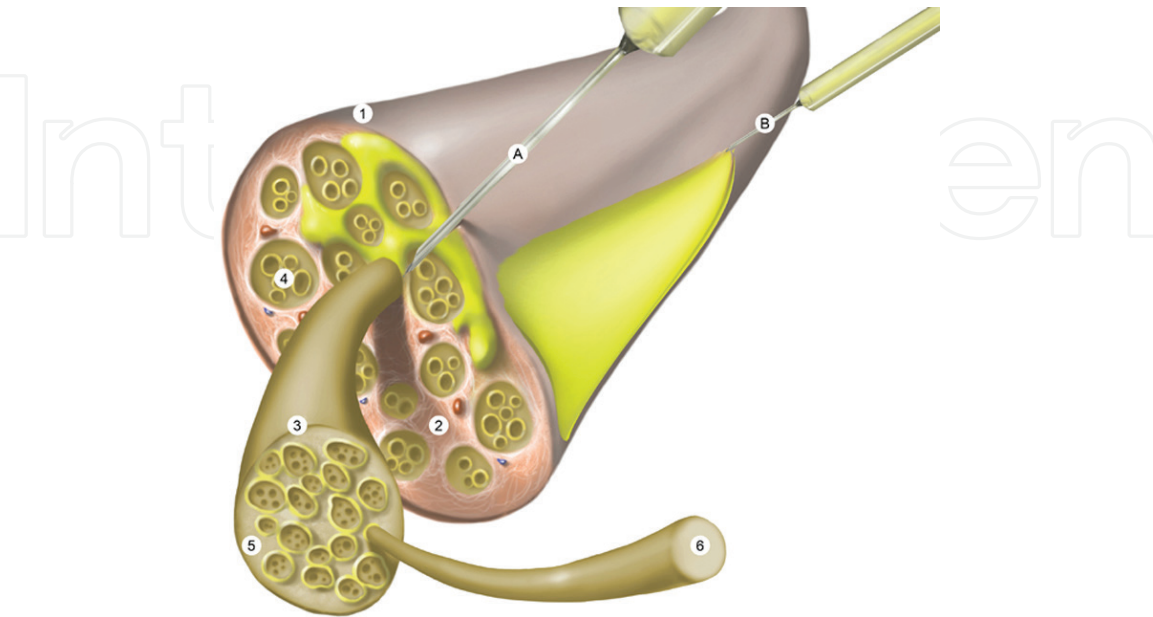
accumulated around the perineurium after intraneural but not intrafascicular injections, without reaching inside the fascicle through the perineurium [2] (**Figure 3**).

4.3 Conservative treatment with US-guided infiltrations of PRP

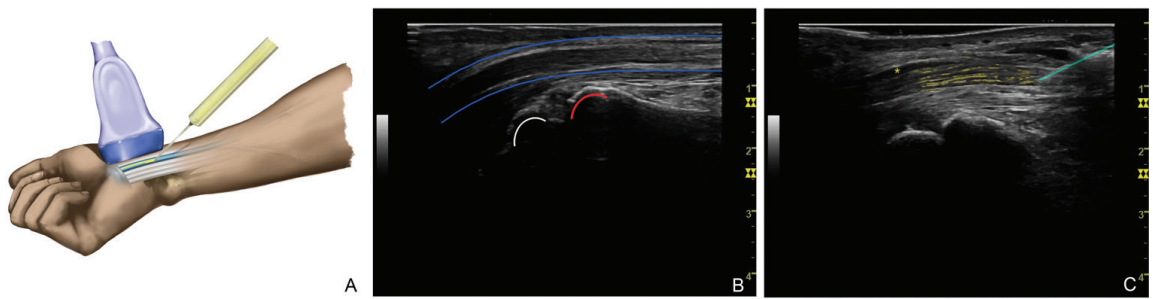
Throughout this section, we will describe the procedures to perform US-guided infiltrations of PRP in some nerves susceptible to peripheral lesions, namely median nerve (**Figure 4**), ulnar nerve (**Figure 5**) and common peroneal nerve (**Figure 6**). The infiltrations of the nerves mentioned in this section share a large number of key points, which are described below. The details of each nerve are shown in **Table 1**.

4.3.1 Key points for common US-guided neural infiltrations

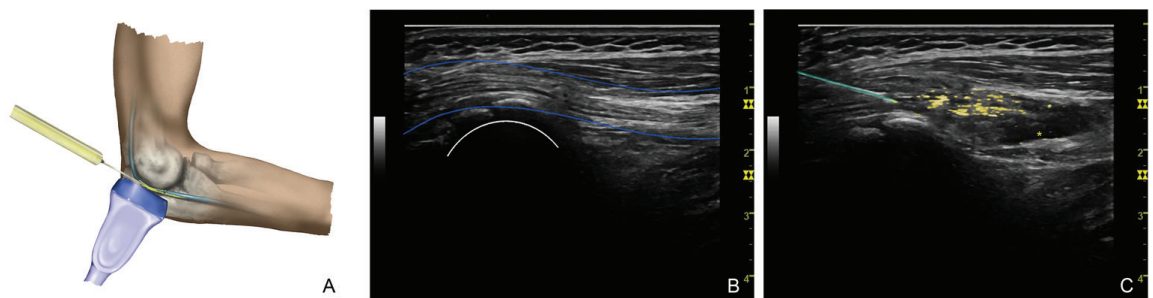
- a. Preparation of the sterile field is required to maintain aseptic conditions throughout the treatment. The skin covering the affected nerve and the transducer of the US machine must be prepared following standard asepsis protocols.
- b. Prior to the infiltrations, the nerve must be located by means of US in the pertinent areas. During this step, the US probe can be used in a long- as well as short-axis in respect to the nerve so that its examination can be as accurate as possible.
- c. In the course of PRP injections, the needle is placed parallel to the US probe, and consequently its orientation in respect to the nerve has influence on the PRP diffusion. With the transducer in the long-axis in respect to the nerve, the needle is introduced almost parallel to it, spreading PRP along the nerve. If the US probe is placed in the short-axis, the needle is inserted at right angles to the nerve increasing the risk of injury axon. The spread is less than in the previous case, especially when the diameter of the nerve is large. However, this approach allows better visualization of the tissue. Therefore, we recommend using the US transducer that achieves a balance between diffusion and nerve visualization.



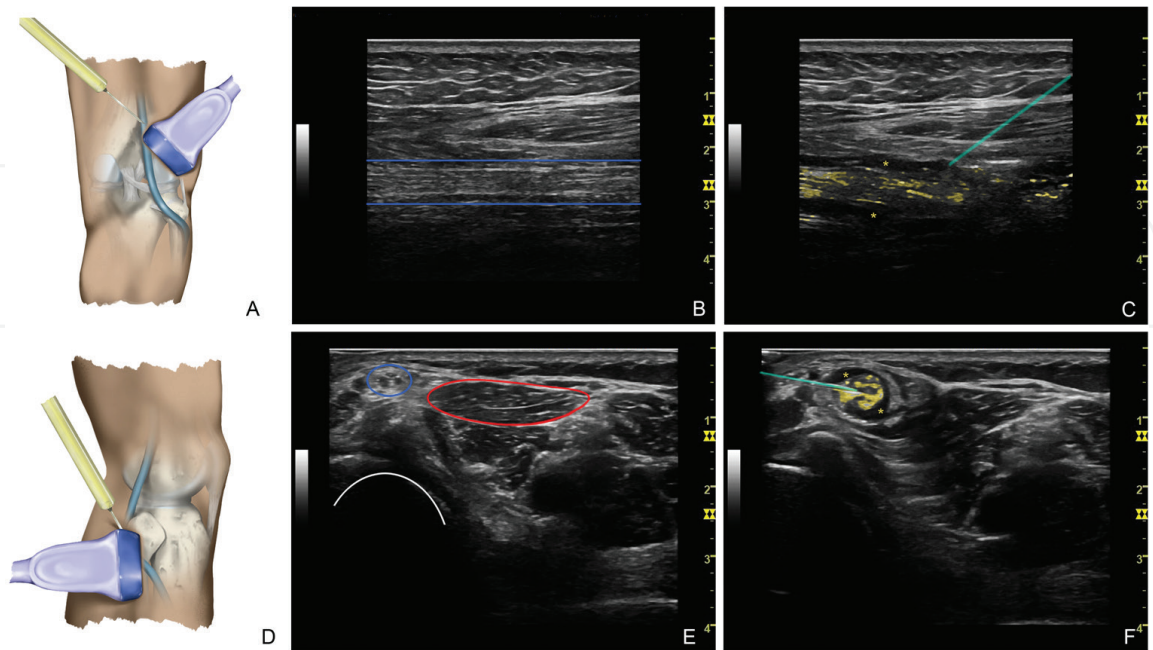
**Figure 3.** Nerve infiltration. During the procedure, two injections are conducted. First, intraneural infiltration (A) reaches the intrafascicular epineurium (2) and next, the perineural infiltration (B) is performed around the nerve. 1 = epineurium; 2 = intrafascicular epineurium; 3 = perineurium; 4 = fascicle; 5 = endoneurium; 6 = axon covered by myelin.



**Figure 4.** Median nerve infiltration. The median nerve is located by means of US in the area of the wrist (A). Under US control with the probe placed in long-axis, the nerve (blue) is observed above the epiphyses of the distal radius (red) and lunate bone (white) (B). The needle (green) is inserted in distal-proximal direction, and PRP is injected in an intraneural (yellow) and perineural way (asterisk) (C).



**Figure 5.** Ulnar nerve infiltration. The ulnar nerve is located by means of US in the area of the elbow (A). Under US control with the probe placed in long-axis, the nerve (blue) is observed above the epicondyle (white) (B). The needle (green) is inserted in distal-proximal direction, and PRP is injected in an intraneural (yellow) and perineural way (asterisk) (C). In this case, the injection could be conducted in proximal-distal direction if the access is difficult.



**Figure 6.** Common peroneal nerve infiltration. Two approaches are possible to infiltrate common peroneal nerve. In the first approach, the nerve (blue) is located by US above the popliteal fossa with the US transducer in the long axis (A and B). In the second approach, the nerve is located in the lateral side of the knee (D). With the probe placed in the short axis, the nerve (blue) is observed above the peroneal head (white) and close to tibialis anterior muscle (red) (E). In both cases, the needle (green) is inserted in proximal-distal direction, injecting PRP in an intraneural (yellow) and perineural way (asterisk) (C and F).

	Median nerve	Ulnar nerve	Common peroneal nerve	
			Approach 1	Approach 2
Indication	Compressive neuropathies such as CTS	Compressive neuropathies such as UTS	Nerve lesions associated to knee injuries	
Patient position	Sitting with the arm flexed and supported on flat surface	Supine position	Prone position	Lateral position over the healthy side
Limb position	Supination, the palm of the hand facing upward	Pronation, with the elbow lightly flexed and on a padded support	Extended leg	Lightly knee flexion and on a padded support
Infiltration area	Wrist, around the distal area of the radius	Behind medial epicondyle, into cubital tunnel	Back of the thigh, around the popliteal fossa above the knee	Lateral knee area around the peroneal head
Syringe	Luer-Lok, 3 mL	Luer-Lok, 3 mL	Luer-Lok, 5 mL	Luer-Lok, 5 mL
Needle	23 G/25 mm	23 G/25 mm	21 G/50 mm	21 G/50 mm
Direction	Proximal-distal	Both	Proximal-distal	Proximal-distal
Intraneural vol.	2 mL	3 mL	3 mL	3 mL
Perineural vol.	4 mL	6 mL	6 mL	6 mL

*CTS, carpal tunnel syndrome; UTS, ulnar tunnel syndrome; Vol, volume.*

**Table 1.**  
*Characteristics of platelet-rich plasma US-guided infiltrations for different nerves.*

- d. The proximal-distal direction is preferable so that PRP spreads through the nerve. In some cases as injections into ulnar nerve, the direction can also be from distal to proximal zone if the injured area is unapproachable.
- e. Both intraneural and perineural injections are performed during the treatment. Activated PRP is injected softly and without rough movements of the needle to prevent nerve damage. As the PRP volume required for both infiltrations can exceed the capacity of the syringe, changes of syringes for loading them with PRP can be done without removing the needle from the injection site, thus avoiding repeated punctures.
- f. Firstly, it is advisable to perform the intraneural infiltration with the needle reaching the intrafascicular epineurium of the nerve. During intraneural injection, PRP shows some hyperechoic signals under US control within the nerve.
- g. Once intraneural injection is accomplished, the needle is gently retreated placing it just above the nerve to conduct the perineural injection around the nerve. The adjacent tissue to the nerve is detached when perineural infiltration is performed, appearing as a hypoechoic signal. This infiltration entails a hydrodissection that reduces nerve entrapment through a mechanical effect [42].
- h. The dosage of these treatments is determined by the nerve size to be infiltrated, which is detailed in each case (**Table 1**). In all cases, it is recommended to carry out two treatments, with an interval of two between both visits.

- i. The follow-up is conducted 4 weeks after finishing the treatment. Clinical examination is required in order to observe improvement in clinical parameters such as pain and paresthesia. Depending on the patient's condition, we will follow different recommendation:
  - If the patient shows a significant improvement, no intervention will be performed. Six weeks after clinical follow-up, an electromyography (EMG) will be conducted to evaluate the state of the nerve and assess possible actions.
  - When the patient evolution has flat-lined or is not enough, neural infiltrations with PRP will be repeated again.
  - In case the patient has not experienced any improvement, infiltrations of PRP will be discarded and other treatment alternatives will be considered. An EMG study should be performed in the third month.

#### *4.3.2 Subgluteal sciatic compression*

- a. PRP infiltrations into this nerve are indicated for compressive neuropathies such as pyramidal syndrome or deep gluteal syndrome.
- b. The patient is placed as in the case of the sciatic nerve approach, namely in prone decubitus on a flat surface.
- c. By means of US control, the nerve is located at the level popliteal fossa, and then the nerve path is followed until gluteal fold, where PRP injection in distal-proximal direction is conducted. If the nerve can be located in a more proximal area, the infiltration can also be performed following the proximal-distal direction.
- d. The injection is conducted with 10 mL in a syringe fitted with an 18 G and 75 mm needle and US probe placed in the long axis.
- e. Four ml of activated PRP is administered during intraneural infiltration and 8 mL of activated PRP is infiltrated around the nerve.

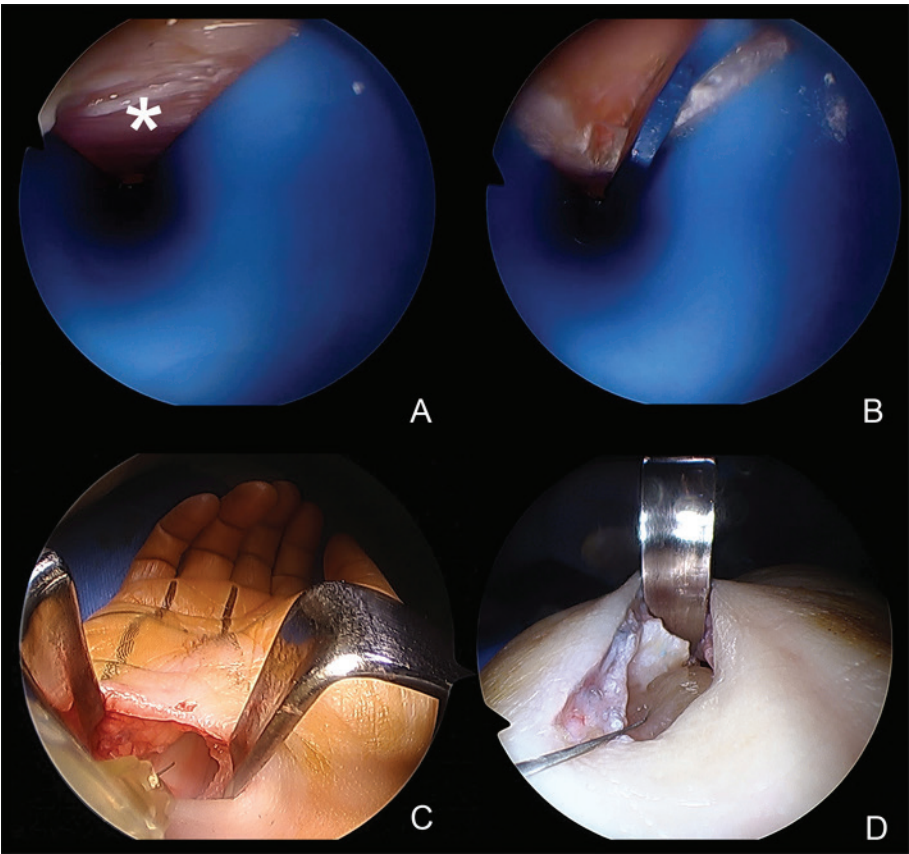
#### *4.3.3 Neuromas*

Traumatic neuroma follows different forms of nerve injury often as a result of surgery. They occur at the end of injured nerve fibers as a form of ineffective, unregulated nerve regeneration. Due to the peculiarities of these neuropathies, the volume of the product, the type of syringes and needles to infiltrate the PRP will largely depend on the nerve where the neuroma is located, which was described above. In addition, not only an intraneural and a perineural injection into neuroma are conducted but also in the proximal nerve close to the neuroma.

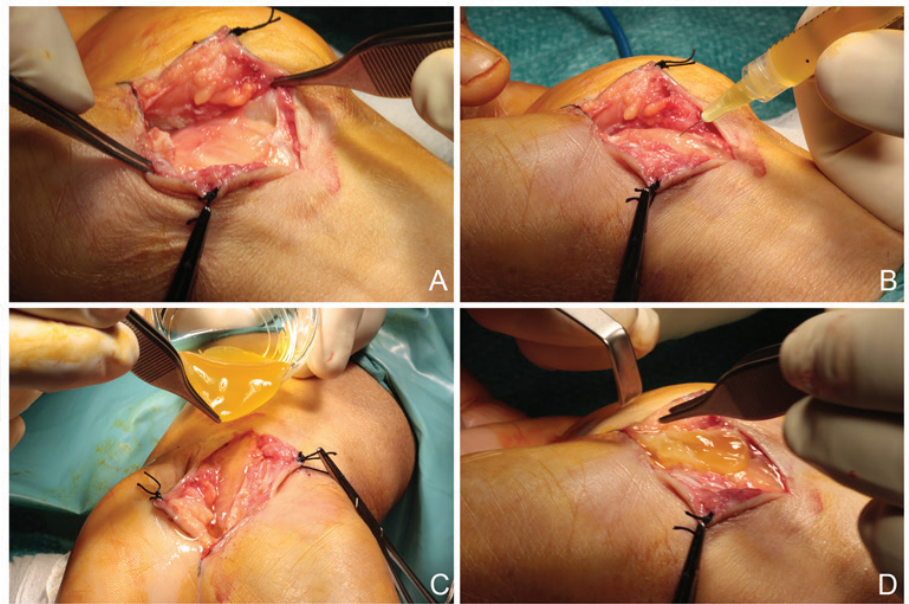
### **4.4 PRP as adjuvant in surgery**

In many cases, surgical interventions are required for the treatment of neuropathies. Among these, the neurolysis is a standard procedure to separate the nerve from the surrounding tissues and try to solve problems related to compression and entrapment. In these cases, the use of PRP as a therapeutic adjuvant during surgery can stimulate and accelerate nerve recovery. Next, both endoscopic (**Figure 7**) and open neurolysis (**Figure 8**) of a median nerve are explained. Neurolysis in other nerves will be done in the same way but adapting to the particularities of each nerve.





**Figure 7.** Endoscopic neurolysis of median nerve. Endoscopic camera and cannula are introduced into the wrist (A). Carpal ligament (asterisk) is dissected and cut (B). PRP is infiltrated into the nerve (C) and a fibrin clot is placed between the nerve and the ligament (D).



**Figure 8.** Open neurolysis of median nerve. Median nerve and the transverse carpal ligament are observed after incision (A). Once median nerve is released, PRP is injected (B). Finally, fibrin membrane (C) is placed between the nerve and the ligament (D).

#### 4.4.1 Endoscopic neurolysis

- a. After performing a small incision at the level of wrist crease, a cannula is introduced in order to observe structures in the wrist as the transverse carpal ligament with an endoscopic camera.

- b. When the transverse carpal ligament is located and dissected, it is cut with endoscopic knife so that the median nerve is released.
- c. Once the ligament is sectioned and nerve released, 2 mL of PRP is infiltrated into the nerve from the incision made for arthroscopy with a 30 G needle. A fibrin clot is placed in the open carpal tunnel before suturing.

#### *4.4.2 Open surgical neurolysis*

- a. An incision at the level of wrist crease is conducted. The incision must be large enough to observe and access to the median nerve and the transverse carpal ligament.
- b. Next, the median nerve and the transverse carpal ligament are located and dissected. During the surgery, the median nerve is released by cutting the transverse carpal ligament and removing all the adhesions present along the nerve.
- c. Finally, intraneural and perineural injections of PRP are performed. In addition, a fibrin membrane is placed between the nerve and the ligament, to later suture the incision.

## **5. Clinical results of PRP application for peripheral nerve injury**

PRP products present a number of features that are quickening the application of this therapy in clinical practice, namely ease of use, reasonable biosafety and great versatility. Therefore, and although the PRP is still a recent technique, several clinical studies have emerging in the last decade (**Table 2**).

### **5.1 PRP infiltrations as conservative treatment**

As in other pathologies, pain is one of the main problems of patients who suffer from peripheral nerve injuries. PRP showed to be a promising therapeutic tool for the relief or reduction of pain associated with neuropathies. Malahias et al. conducted a case series study where patients who suffered from carpal tunnel syndrome (CTS) were treated with one PRP US-guided injection around the median nerve [43]. At 3 months of follow-up, the pain was significantly alleviated in 11 out of 14 patients according to VAS score. A prospective controlled study carried out by Uzun et al. demonstrated the effectiveness of PRP in reducing the pain associated with CTS after one perineural injection of 2 mL of PRP [44]. These kinds of interventions were conducted not only over the median nerve but also over the ulnar nerve. Patients with peripheral neuropathy associated to leprosy received a perineural injection of 1 mL of PRP in the posterior tibial nerves and in the ulnar nerve. The results of this randomized control clinical trial showed a pain decrease 2 weeks after treatment [45].

These results are also accompanied by a functional and clinical improvement, which has a positive impact on the quality of life of patients. Some of the patients mentioned above showed functional recovery together with reduction in pain [42, 43]. More clinical studies also showed improvement in clinical and functional symptomatology when applying PRP in different peripheral nerve lesions. Recently, a randomized clinical study demonstrated better functional outcomes in patients with mild to moderate CTS [46]. Patients who received one US-guided infiltration of PRP into the carpal tunnel achieved a better response than patients treated with

Reference	Condition	Target	Intervention	Improvement
<i>Infiltrations</i>				
[43]	CTS	MN	US-guided perineural injection (1 × 1–2 mL)	Pain and function
[44]	CTS	MN	Perineural injection (1 × 2 mL)	Pain and function
[45]	Leprosy peripheral neuropathy	PTN and UN	Perineural injection (1 × 1 mL)	Pain
[46]	CTS	MN	US-guided perineural injection (1 × 1–2 mL)	Function
[47]	Perinatal cerebral palsy	Systemic	Intravenous injection (1 × 25 mL)	Function
[48]	CTS	MN	Injection at the distal carpal crease (1 × 1 mL)	Pain, function and EMG
[49]	CTS	MN	US-guided perineural injection (1 × 3 mL)	Pain, function and EMG
[50]	CPN palsy	CPN	US-guided intraneural/perineural infiltrations (13 × 3–8 mL)	Pain, function and EMG
[51]	CTS	MN	US-guided perineural injection (2 × 5 mL)	Pain, function and EMG
[52]	Section of RN	RN	US-guided intraneural injections (5 × 4 mL)	Function and EMG
<i>Surgery</i>				
[53]	Nerve gaps in extremities	Nerves of the extremities	Nerve gap bridged with a collagen tube with PRP fibrin	Function
[54]	Persistent pudendal neuralgia	PN	Injection after a transgluteal decompression	Function
[55]	Benign parotid gland tumor with facial muscles and nerve deficit	FN	PRP gel was applied around nerve endings during superficial parotidectomy	Function
<i>CPN, common peroneal nerve; CTS, carpal tunnel syndrome; EMG, electromyography; FN, facial nerve; MN, median nerve; PRP, platelet-rich plasma; PTN, posterior tibial nerve; RN, radial nerve; UN, ulnar nerve; US, ultrasound.</i>				

**Table 2.**  
*Clinical research of PRP application for peripheral nerve injury.*

saline 12 weeks after treatment. However, in this study, no differences in pain scores were found. A case report that described a 6-year-old boy with perinatal cerebral palsy should be noted [49]. After receiving an intravenous injection of 25 mL of PRP, an improvement in the cognitive sphere and language during the follow-up at 3 and 6 months was observed. Levels of GF maintained stable in plasma 3–5 times higher than average for his age group.

It must be taken into consideration that some variables may have a certain subjective component or be influenced by other factors than the treatment administered. Thus, it is advisable to analyze more objective variables such as EMG. A randomized controlled study showed improvement in EMG parameters, such as sensory nerve action potential (SNAP) in CTS patients [48]. However, there were



no differences between control group (splint) and PRP treatment. This could be because the infiltration performed in this study was conducted without US guidance or directly into the median nerve but in adjacent areas, hampering the biological effects of PRP on the nervous tissue. Wu et al. carried out other randomized controlled study of CTS patients achieving an enhancement in sensory nerve conduction velocity (SNCV) and distal motor latency (DML) [49]. Although these EMG values were not significantly better than control group, there were significant differences in terms of pain and other clinical symptoms. The authors observed this improvement 6 months after one US-guided injection of 3 mL of PRP in the median nerve. In a case report described by Sánchez et al., a patient with peroneal nerve palsy underwent serial US-guided intraneural and perineural injections for 33 months [50]. The patient not only achieved improvement related to pain and function but also showed EMG signs of reinnervation for the peroneus longus and tibialis anterior. Specifically, an increase in compound muscle action (CMAP) was reported. In another case report, a 56-year-old woman who suffered from severity of symptoms of CTS received a treatment consisted of two US-guided perineural injections of 5 mL of PRP [51]. During follow-up at 3 and 6 months after the treatment, she revealed significant improvements in the distal motor and sensory latencies as well as the sensory nerve action potential and CMAP amplitudes of the median nerves. Finally, García de Cortazar et al. reported a case that described a patient with a section of the radial nerve [52]. Four months after the trauma and consequent surgery without positive response, serial intraneural infiltrations of PRP were conducted with US guidance. Eleven months after the first injection, EMG showed a complete reinnervation of the musculature of the radial nerve dependent.

## 5.2 PRP as adjuvant in surgery

In addition to the application of PRP in liquid form for neural infiltrations, its versatility allows it to formulate in different ways such as gel, scaffold or fibrin membrane to apply also in surgical interventions. (**Figure 1**). Kuffler et al. took advantage of these properties for patients with nerve gaps in their extremities [53]. In the surgical technique they conducted, collagen tubes filled with PRP formulated as fibrin membrane were used to bridge the nerve gaps. Patients of this case series reached sensory and motor recovery across nerve gap, reduction of pain and functional recovery. Hibner et al. observed in a retrospective analysis the efficacy of injecting PRP around the pudendal nerve after a transgluteal decompression to enclose the nerve in NeuroWrapNerve Protector [54]. The pain of these patients who suffered from persistent pudendal neuralgia after neurolysis and transposition was significantly alleviated. This success was also achieved in patients with facial muscle and nerve deficit associated with benign parotid gland tumor [55]. In this randomized control study, Scala et al. observed significant improvements in several clinical parameters in the group of patients where PRP gel was applied during superficial parotidectomy.

## 6. Conclusion

### 6.1 Final considerations

Neuropathies are very challenging pathologies whose treatment options include conservative procedures as well as surgical interventions. In both cases, PRP is a promising and safe therapeutic tool that can be used as liquid formulation for



US-guided infiltrations or as fibrin scaffold for surgery. Its potential has been proved in diverse in vitro and in vivo studies, and there are constantly more treatments based on this therapy in humans also. The use of this technique allows physicians to take advantage of the biological processes required to achieve an optimal nerve repair and satisfactory clinical results.

## **6.2 Future directions**

Although the PRP application for nerve pathologies is showing encouraging results and no negative side effects, apart from some painful episodes during injections, its use in these pathologies still has to be cautious. Although in some treatments normally the employed product has its importance, the way to use this product is also relevant to achieve a successful response. Elements such as a correct indication, an appropriate PRP elaboration and a suitable administration and application procedures are essential for the success of these treatments. Further studies and cases are needed to increase the knowledge not only of PRP for neuropathies but also of nerve biology, and thus improve protocols as well as clinical outcomes.

## **Author details**

Mikel Sánchez<sup>1,2</sup>, Ane Garate<sup>1</sup>, Ane Miren Bilbao<sup>2</sup>, Jaime Oraa<sup>2</sup>, Fernando Yangüela<sup>2</sup>, Pello Sánchez<sup>1</sup>, Jorge Guadilla<sup>2</sup>, Beatriz Aizpurua<sup>2</sup>, Juan Azofra<sup>2</sup>, Nicolás Fiz<sup>2</sup> and Diego Delgado<sup>1\*</sup>

1 Advanced Biological Therapy Unit, Hospital Vithas San José, Vitoria-Gasteiz, Spain

2 Arthroscopic Surgery Unit, Hospital Vithas San José, Vitoria-Gasteiz, Spain

\*Address all correspondence to: [diego.delgado@ucatrauma.com](mailto:diego.delgado@ucatrauma.com)

## **IntechOpen**

© 2018 The Author(s). Licensee IntechOpen. This chapter is distributed under the terms of the Creative Commons Attribution License (<http://creativecommons.org/licenses/by/3.0>), which permits unrestricted use, distribution, and reproduction in any medium, provided the original work is properly cited. 

## References

- [1] Sánchez M, Delgado D, Sánchez P, Fiz N, Azofra J, Orive G, et al. Platelet rich plasma and knee surgery. *BioMed Research International*. 2014;**2014**:890630. DOI: 10.1155/2014/890630
- [2] Sánchez M, Anitua E, Delgado D, Sanchez P, Prado R, Orive G, et al. Platelet-rich plasma, a source of autologous growth factors and biomimetic scaffold for peripheral nerve regeneration. *Expert Opinion on Biological Therapy*. 2017;**17**(2):197-212. DOI: 10.1080/14712598.201
- [3] Willits K, Kaniki N, Bryant D. The use of platelet-rich plasma in orthopedic injuries. *Sports Medicine and Arthroscopy Review*. 2013;**21**(4):225-230. DOI: 10.1097/JSA.0000000000000001
- [4] Alves R, Grimalt R. A review of platelet-rich plasma: History, biology, mechanism of action, and classification. *Skin Appendage Disorders*. 2018;**4**(1):18-24. DOI: 10.1159/000477353
- [5] Lopez E, Bermejo N, Berna-Erro A, Alonso N, Salido GM, Redondo PC, et al. A relationship between calcium mobilization and platelet  $\alpha$ - and  $\delta$ -granule secretion. A role for TRPC6 in thrombin-evoked  $\delta$ -granule exocytosis. *Archives of Biochemistry and Biophysics*. 2015;**585**:75-81. DOI: 10.1016/j.abb.2015.09.012
- [6] Scully D, Naseem KM, Matsakas A. Platelet biology in regenerative medicine of skeletal muscle. *Acta Physiologica (Oxford, England)*. 2018:e13071. DOI: 10.1111/apha.13071
- [7] Garate A, Sánchez P, Delgado D, Bilbao AM, Muiños-López E, Granero-Moltó F, et al. Autologous bioscaffolds based on different concentrations of platelet rich plasma and synovial fluid as a vehicle for mesenchymal stem cells. *Journal of Biomedical Materials Research. Part A*. 2018;**106**(2):377-385. DOI: 10.1002/jbm.a.36247
- [8] Dohle E, El Bagdadi K, Sader R, Choukroun J, James Kirkpatrick C, Ghanaati S. Platelet-rich fibrin-based matrices to improve angiogenesis in an in vitro co-culture model for bone tissue engineering. *Journal of Tissue Engineering and Regenerative Medicine*. 2018;**12**(3):598-610. DOI: 10.1002/term.2475
- [9] Sánchez M, Garate A, Delgado D, Padilla S. Platelet-rich plasma, an adjuvant biological therapy to assist peripheral nerve repair. *Neural Regeneration Research*. 2017;**12**(1):47-52. DOI: 10.4103/1673-5374.198973
- [10] Koda M, Someya Y, Nishio Y, Kadota R, Mannoji C, Miyashita T, et al. Brain-derived neurotrophic factor suppresses anoikis-induced death of Schwann cells. *Neuroscience Letters*. 2008;**444**(2):143-147. DOI: 10.1016/j.neulet.2008.07.055
- [11] Wang Z, Deng Q, Zhang X, Zhang J. Treatment of injured neurons with bone marrow stem cells cotransfected by hTERT and Ad-BDNF in vitro. *Journal of Molecular Neuroscience*. 2009;**38**(3):265-272. DOI: 10.1007/s12031-009-9208-5
- [12] Zurita M, Otero L, Aguayo C, Bonilla C, Ferreira E, Parajón A, et al. Cell therapy for spinal cord repair: Optimization of biologic scaffolds for survival and neural differentiation of human bone marrow stromal cells. *Cytotherapy*. 2010;**12**(4):522-537. DOI: 10.3109/14653241003615164
- [13] Apel PJ, Ma J, Callahan M, Northam CN, Alton TB, Sonntag WE, et al. Effect of locally delivered IGF-1 on nerve regeneration during aging: An experimental study in rats. *Muscle*

& Nerve. 2010;**41**(3):335-341. DOI: 10.1002/mus.21485

2010;**107**(8):3287-3292. DOI: 10.1073/pnas.0903875106

[14] Erlandsson A, Enarsson M, Forsberg-Nilsson K. Immature neurons from CNS stem cells proliferate in response to platelet-derived growth factor. *The Journal of Neuroscience*. 2001;**21**(10):3483-3491

[21] Kim JY, Jeon WJ, Kim DH, Rhyu IJ, Kim YH, Youn I, et al. An inside-out vein graft filled with platelet-rich plasma for repair of a short sciatic nerve defect in rats. *Neural Regeneration Research*. 2014;**9**(14):1351-1357. DOI: 10.4103/1673-5374.137587

[15] Luo H, Zhang Y, Zhang Z, Jin Y. The protection of MSCs from apoptosis in nerve regeneration by TGF $\beta$ 1 through reducing inflammation and promoting VEGF-dependent angiogenesis. *Biomaterials*. 2012;**33**(17):4277-4287. DOI: 10.1016/j.biomaterials.2012.02.042

[22] Ceccarelli J, Putnam AJ. Sculpting the blank slate: How fibrin's support of vascularization can inspire biomaterial design. *Acta Biomaterialia*. 2014;**10**(4):1515-1523. DOI: 10.1016/j.actbio.2013.07.043

[16] Anitua E, Pascual C, Pérez-Gonzalez R, Orive G, Carro E. Intranasal PRGF-Endoret enhances neuronal survival and attenuates NF- $\kappa$ B-dependent inflammation process in a mouse model of Parkinson's disease. *Journal of Controlled Release*. 2015;**203**:170-180. DOI: 10.1016/j.jconrel.2015.02.030

[23] Zheng C, Zhu Q, Liu X, Huang X, He C, Jiang L, et al. Effect of platelet-rich plasma (PRP) concentration on proliferation, neurotrophic function and migration of Schwann cells in vitro. *Journal of Tissue Engineering and Regenerative Medicine*. 2016;**10**(5):428-436. DOI: 10.1002/term.1756

[17] Li S, Gu X, Yi S. The regulatory effects of transforming growth factor- $\beta$  on nerve regeneration. *Cell Transplantation*. 2017;**26**(3):381-394. DOI: 10.3727/096368916X693824

[24] Takeuchi M, Kamei N, Shinomiya R, Sunagawa T, Suzuki O, Kamoda H, et al. Human platelet-rich plasma promotes axon growth in brain-spinal cord coculture. *Neuroreport*. 2012;**23**(12):712-716. DOI: 10.1097/WNR.0b013e3283567196

[18] Rosenstein JM, Krum JM. New roles for VEGF in nervous tissue—Beyond blood vessels. *Experimental Neurology*. 2004;**187**(2):246-253

[25] Ye F, Li H, Qiao G, Chen F, Tao H, Ji A, et al. Platelet-rich plasma gel in combination with Schwann cells for repair of sciatic nerve injury. *Neural Regeneration Research*. 2012;**7**(29):2286-2292. DOI: 10.3969/j.issn.1673-5374.2012.29.007

[19] Yu CQ, Zhang M, Matis KI, Kim C, Rosenblatt MI. Vascular endothelial growth factor mediates corneal nerve repair. *Investigative Ophthalmology & Visual Science*. 2008;**49**(9):3870-3878. DOI: 10.1167/iovs.07-1418

[26] Yu W, Wang J, Yin J. Platelet-rich plasma: A promising product for treatment of peripheral nerve regeneration after nerve injury. *The International Journal of Neuroscience*. 2011;**121**(4):176-180. DOI: 10.3109/00207454.2010.544432

[20] Borselli C, Storrie H, Benesch-Lee F, Shvartsman D, Cezar C, Lichtman JW, et al. Functional muscle regeneration with combined delivery of angiogenesis and myogenesis factors. *Proceedings of the National Academy of Sciences of the United States of America*.

[27] Cho HH, Jang S, Lee SC, Jeong HS, Park JS, Han JY, et al. Effect of

neural-induced mesenchymal stem cells and platelet-rich plasma on facial nerve regeneration in an acute nerve injury model. *The Laryngoscope*. 2010;**120**(5):907-913. DOI: 10.1002/lary.20860

[28] Lichtenfels M, Colomé L, Sebben AD, Braga-Silva J. Effect of platelet rich plasma and platelet rich fibrin on sciatic nerve regeneration in a rat model. *Microsurgery*. 2013;**33**(5):383-390. DOI: 10.1002/micr.22105

[29] Ma CH, Omura T, Cobos EJ, Latrémolière A, Ghasemlou N, Brenner GJ, et al. Accelerating axonal growth promotes motor recovery after peripheral nerve injury in mice. *The Journal of Clinical Investigation*. 2011;**121**(11):4332-4347. DOI: 10.1172/JCI58675

[30] Sánchez M, Anitua E, Delgado D, Prado R, Sánchez P, Fiz N, et al. Ultrasound-guided plasma rich in growth factors injections and scaffolds hasten motor nerve functional recovery in an ovine model of nerve crush injury. *Journal of Tissue Engineering and Regenerative Medicine*. 2017;**11**(5):1619-1629. DOI: 10.1002/term.2079

[31] Sariguney Y, Yavuzer R, Elmas C, Yenicesu I, Bolay H, Atabay K. Effect of platelet-rich plasma on peripheral nerve regeneration. *Journal of Reconstructive Microsurgery*. 2008;**24**(3):159-167. DOI: 10.1055/s-2008-1076752

[32] Anitua E, Pelacho B, Prado R, Aguirre JJ, Sánchez M, Padilla S, et al. Infiltration of plasma rich in growth factors enhances in vivo angiogenesis and improves reperfusion and tissue remodeling after severe hind limb ischemia. *Journal of Controlled Release*. 2015;**202**:31-39. DOI: 10.1016/j.jconrel.2015.01.029

[33] Schaakxs D, Kalbermatten DF, Raffoul W, Wiberg M, Kingham PJ. Regenerative cell injection in

denervated muscle reduces atrophy and enhances recovery following nerve repair. *Muscle & Nerve*. 2013;**47**(5):691-701. DOI: 10.1002/mus.23662

[34] Shavlakadze T, White JD, Davies M, Hoh JF, Grounds MD. Insulin-like growth factor I slows the rate of denervation induced skeletal muscle atrophy. *Neuromuscular Disorders*. 2005;**15**(2):139-146. DOI: 10.1016/j.nmd.2004.10.013

[35] Giusti I, D'Ascenzo S, Mancò A, Di Stefano G, Di Francesco M, Rughetti A, et al. Platelet concentration in platelet-rich plasma affects tenocyte behavior in vitro. *BioMed Research International*. 2014;**2014**:630870. DOI: 10.1155/2014/630870

[36] Xu Z, Yin W, Zhang Y, Qi X, Chen Y, Xie X, et al. Comparative evaluation of leukocyte- and platelet-rich plasma and pure platelet-rich plasma for cartilage regeneration. *Scientific Reports*. 2017;**7**:43301. DOI: 10.1038/srep43301

[37] Sen O, Sayilgan NC, Tutuncu AC, Bakan M, Koksall GM, Oz H. Evaluation of sciatic nerve damage following intraneural injection of bupivacaine, levobupivacaine and lidocaine in rats. *Brazilian Journal of Anesthesiology*. 2016;**66**(3):272-275. DOI: 10.1016/j.bjane.2014.09.012

[38] Choquet O, Morau D, Biboulet P, Capdevila X. Where should the tip of the needle be located in ultrasound-guided peripheral nerve blocks? *Current Opinion in Anaesthesiology*. 2012;**25**(5):596-602. DOI: 10.1097/ACO.0b013e328356bb40

[39] Damjanovska M, Cvetko E, Hadzic A, Seliskar A, Plavec T, Mis K, et al. Neurotoxicity of perineural vs intraneural-extrafascicular injection of liposomal bupivacaine in the porcine model of sciatic nerve block. *Anaesthesia*. 2015;**70**(12):1418-1426. DOI: 10.1111/anae.13189



- [40] Hasanbegovic I, Kulenovic A, Hasanovic S. Effects of intraneural and perineural injection and concentration of Ropivacaine on nerve injury during peripheral nerve block in Wistar rats. *Journal of Health Sciences*. 2013;**3**(3):243-249. DOI: 10.17532/jhsci.2013.115
- [41] Brierley JB, Field EJ. The fate of an intraneural injection as demonstrated by the use of radio-active phosphorus. *Journal of Neurology, Neurosurgery, and Psychiatry*. 1949;**12**(2):86-99
- [42] Cass SP. Ultrasound-guided nerve hydrodissection: What is it? A review of the literature. *Current Sports Medicine Reports*. 2016;**15**(1):20-22. DOI: 10.1249/JSR.0000000000000226
- [43] Malahias MA, Johnson EO, Babis GC, Nikolaou VS. Single injection of platelet-rich plasma as a novel treatment of carpal tunnel syndrome. *Neural Regeneration Research*. 2015;**10**(11):1856-1859. DOI: 10.4103/1673-5374.165322
- [44] Uzun H, Bitik O, Uzun Ö, Ersoy US, Aktaş E. Platelet-rich plasma versus corticosteroid injections for carpal tunnel syndrome. *Journal of Plastic Surgery and Hand Surgery*. 2017;**51**(5):301-305. DOI: 10.1080/2000656X.2016.1260025
- [45] Anjayani S, Wirohadidjojo YW, Adam AM, Suwandi D, Seweng A, Amiruddin MD. Sensory improvement of leprosy peripheral neuropathy in patients treated with perineural injection of platelet-rich plasma. *International Journal of Dermatology*. 2014;**53**(1):109-113. DOI: 10.1111/ijd.12162
- [46] Malahias MA, Nikolaou VS, Johnson EO, Kaseta MK, Kazas ST, Babis GC. Platelet-rich plasma ultrasound-guided injection in the treatment of carpal tunnel syndrome: A placebo-controlled clinical study. *Journal of Tissue Engineering and Regenerative Medicine*. 2018;**12**(3):e1480-e1488. DOI: 10.1002/term.2566
- [47] Alcaraz J, Oliver A, Sánchez JM. Platelet-rich plasma in a patient with cerebral palsy. *American Journal of Case Reports*. 2015;**16**:469-472. DOI: 10.12659/AJCR.893805
- [48] Raeissadat SA, Karimzadeh A, Hashemi M, Bagherzadeh L. Safety and efficacy of platelet-rich plasma in treatment of carpal tunnel syndrome; a randomized controlled trial. *BMC Musculoskeletal Disorders*. 2018;**19**(1):49. DOI: 10.1186/s12891-018-1963-4
- [49] Wu YT, Ho TY, Chou YC, Ke MJ, Li TY, Huang GS, et al. Six-month efficacy of platelet-rich plasma for carpal tunnel syndrome: A prospective randomized, single-blind controlled trial. *Scientific Reports*. 2017;**7**(1):94. DOI: 10.1038/s41598-017-00224-6
- [50] Sánchez M, Yoshioka T, Ortega M, Delgado D, Anitua E. Ultrasound-guided platelet-rich plasma injections for the treatment of common peroneal nerve palsy associated with multiple ligament injuries of the knee. *Knee Surgery, Sports Traumatology, Arthroscopy*. 2014;**22**(5):1084-1089. DOI: 10.1007/s00167-013-2479-y
- [51] Kuo YC, Lee CC, Hsieh LF. Ultrasound-guided perineural injection with platelet-rich plasma improved the neurophysiological parameters of carpal tunnel syndrome: A case report. *Journal of Clinical Neuroscience*. 2017;**44**:234-236. DOI: 10.1016/j.jocn.2017.06.053
- [52] García de Cortázar U, Padilla S, Lobato E, Delgado D, Sánchez M. Intraneural platelet-rich plasma injections for the treatment of radial nerve section: A case report. *Journal of Clinical Medicine*. 2018;**7**(2):pii:E13. DOI: 10.3390/jcm7020013

[53] Kuffler DP. An assessment of current techniques for inducing axon regeneration and neurological recovery following peripheral nerve trauma. *Progress in Neurobiology*. 2014;**116**:1-12. DOI: 10.1016/j.pneurobio.2013.12.004

[54] Hibner M, Castellanos ME, Drachman D, Balducci J. Repeat operation for treatment of persistent pudendal nerve entrapment after pudendal neurolysis. *Journal of Minimally Invasive Gynecology*. 2012;**19**(3):325-330. DOI: 10.1016/j.jmig.2011.12.022

[55] Scala M, Mereu P, Spagnolo F, Massa M, Barla A, Mosci S, et al. The use of platelet-rich plasma gel in patients with mixed tumour undergoing superficial parotidectomy: A randomized study. *In Vivo*. 2014;**28**(1):121-124