

# We are IntechOpen, the world's leading publisher of Open Access books Built by scientists, for scientists

6,900

Open access books available

185,000

International authors and editors

200M

Downloads

Our authors are among the

154

Countries delivered to

TOP 1%

most cited scientists

12.2%

Contributors from top 500 universities



WEB OF SCIENCE™

Selection of our books indexed in the Book Citation Index  
in Web of Science™ Core Collection (BKCI)

Interested in publishing with us?  
Contact [book.department@intechopen.com](mailto:book.department@intechopen.com)

Numbers displayed above are based on latest data collected.  
For more information visit [www.intechopen.com](http://www.intechopen.com)



---

# Why Do Patients with Controlled Glaucoma Continue to Lose Their Vision?

Shimon Rumelt and Shachar Schreiber

Additional information is available at the end of the chapter

<http://dx.doi.org/10.5772/intechopen.79764>

---

## Abstract

The question why patients with controlled glaucoma continue to lose their vision and may end with blindness was raised at the conference last year, but no answer was provided. This presentation will address some of the possible clinical causes such as supine position during sleep and sleeping on the affected eye(s). Antihypertensive drugs at bedtime increase the risk of anterior ischemic optic neuropathy, which is a challenge to diagnose in advanced glaucoma. Basic causes include the continuation of neuronal apoptosis despite controlled intraocular pressure. To prevent further visual loss in these patients, practical steps such as sleeping at 20–30° head-up position, avoiding sleeping on the affected eye(s), avoiding taking antihypertensive drugs at bedtime, and developing antiapoptotic drugs such as antibodies are essential.

**Keywords:** glaucoma, visual field damage, scotoma, blindness, prevention, intraocular pressure, supine position, antihypertensive drugs, apoptosis

---

## 1. Introduction

Glaucoma is a group of diseases that affect the optic disc, causing a specific type of optic neuropathy characterized by specific changes in the optic disc and visual field that eventually may progress to blindness. A feature common to most of the glaucoma types is high intraocular pressure, which to date is virtually the only target for treatment. The aim of the treatment is to decrease the intraocular pressure to a target pressure that is specific for each patient. This specific pressure is supposed to prevent further deterioration in visual field and irreversible blindness. Unfortunately, despite achieving a target pressure, there is a subpopulation of glaucoma patients who still progress gradually to blindness. This chapter will discuss possible reasons for this phenomenon in those patients who achieve the target pressure.

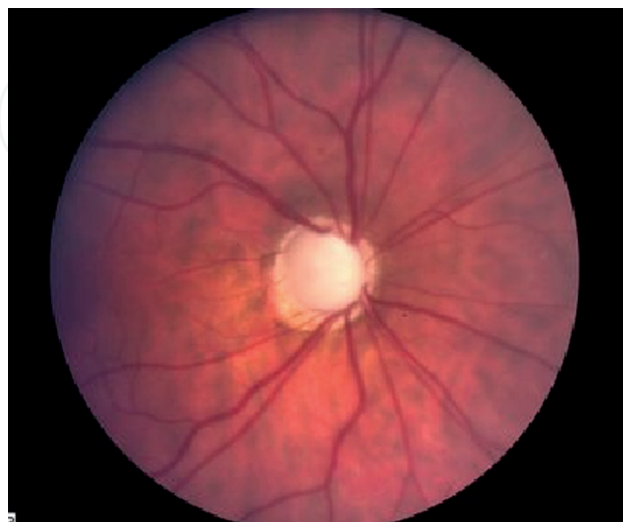## 2. Epidemiology of blindness

The World Health Organization (WHO) estimated that in 2014, 285 million people (4%) out of the 7.2 billion world population had either low vision (246 million) or blindness (49 million) [1]. Ninety percent of these live in low-economic settings and 82% are aged over 50 years. Eighty percent of visual impairment can be prevented or cured. The best examples are correction of refractive errors and cataract surgery.

The most common cause for blindness worldwide is cataract (47%), and it is reversible upon surgery. The second common cause for blindness is glaucoma (12%), and it is the most common cause for irreversible blindness. This is followed by age-related macular degeneration (5%).

## 3. Blindness from glaucoma

Glaucoma is a distinctive group of optic nerve neuropathies characterized by specific optic disc and visual field changes, usually with an increase in intraocular pressure (IOP). In the past, a true IOP of up to 21 mmHg was considered normal in healthy individuals. Today, some consider an IOP between 18 and 22 as borderline. The term “true IOP” addresses the corrected IOP according to the thickness of the cornea and other parameters that influence the IOP. The main optic disc change is the increase of the cup (cupping) and decrease of the rim that contains the axons from the retinal ganglion layer (**Figure 1**). Early signs for this include disc notching, increased excavation, retinal nerve fiber defects, and papillary flame-shape hemorrhages. The early changes in visual field include Bjerrum defects (scotomata), paracentral scotoma, nasal step, and arcuate scotoma. As the disease progresses, visual field defects increase, first in depth and then in size. Arcuate scotoma may join nasal field, and when these increase toward the center and the periphery, tunnel vision and/or a temporal crescent or a



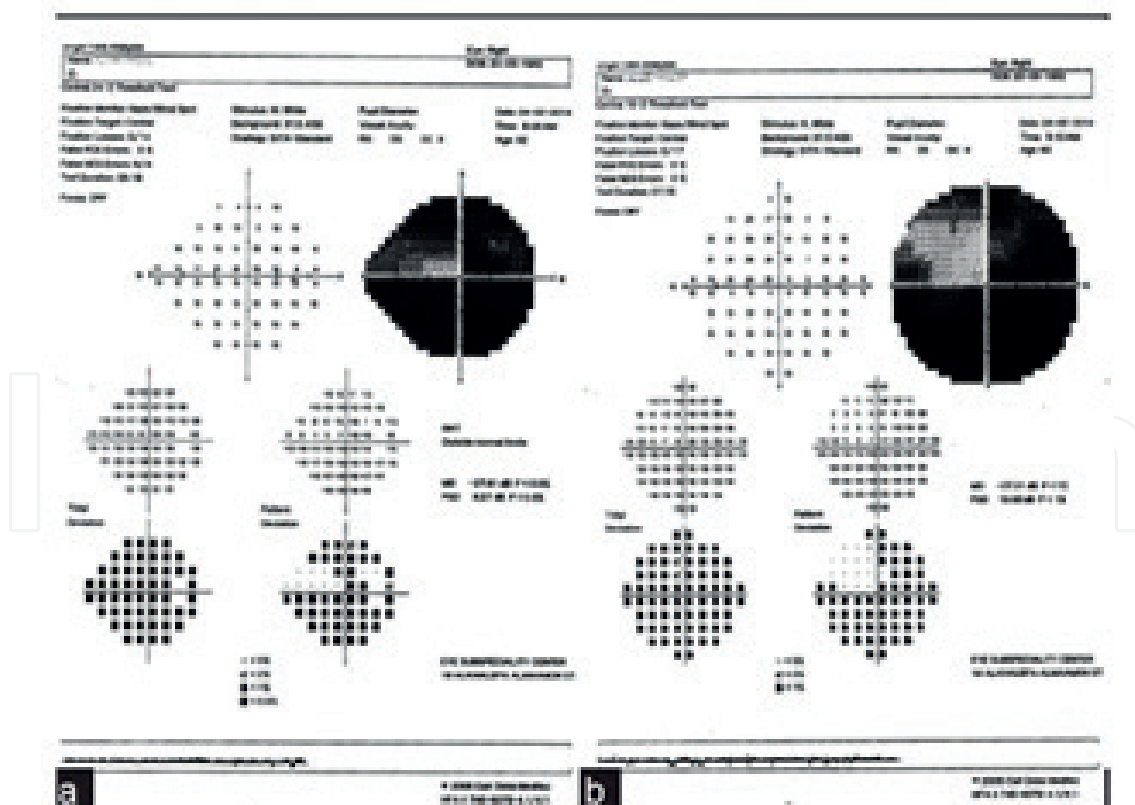
**Figure 1.** An advanced stage of glaucomatous optic disc damage showing thinning of the rim. The cup/disc ratio is almost 1 (subtotal excavation).

few visual islands remains. Eventually, these disappear too and the patient remains with no light perception. The changes in visual field correspond and follow closely with the changes in the optic disc. The chronic forms of this group are asymptomatic until advanced and irreversible visual loss occurs. Patients preserve normal visual acuity (even of 20/20) in one or both eyes until late in the disease. Such patients may not be aware of the small defects early in the course of the disease or even advanced concentric visual loss and tunnel vision, until they completely lose their vision in one or both eyes.

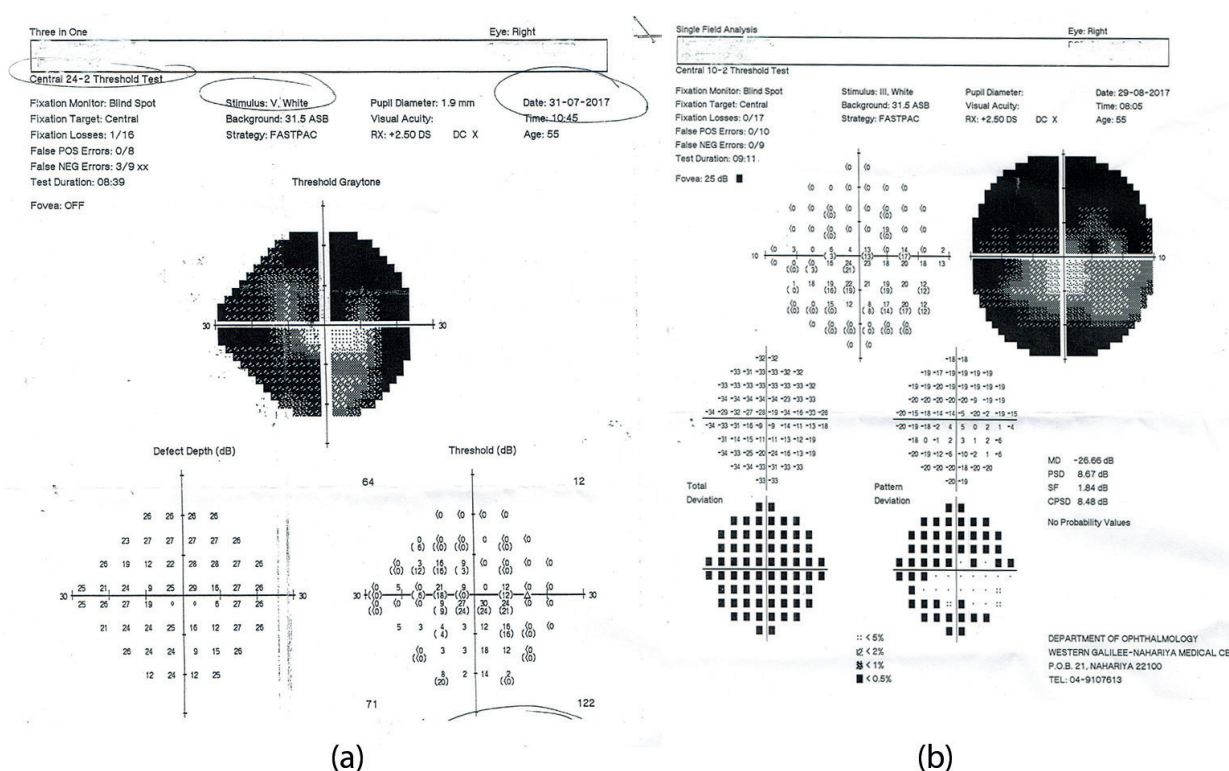
Two theories explain the neuronal loss in glaucoma. The first claims that mechanical force exerted on the optic disc causes direct destruction. The second claims that compromised blood flow causes damage. The damage may be caused also by a combination of these two processes. The end point is apoptosis of the ganglion cell layer.

#### 4. Pattern of visual loss in glaucoma

The visual field loss (scotoma) in glaucoma has a distinctive pattern that differs from visual loss due to other causes (**Figures 2 and 3**). The visual field defects include Bjerrum scotoma, paracentral scotoma, nasal step, and arcuate defect. These defects correspond to retinal nerve



**Figure 2.** Advanced visual field loss of the right eye in a glaucoma patient. On the left, a 24-2 Humphrey visual field demonstrating a concentric visual field loss with only a small para-central island remained. The fixation point is split. This is also demonstrated in the same patient on the right with a 10-2 visual field. Glaucoma surgery at this point can cause the loss of the fixation and a decrease in best-corrected visual acuity to counting fingers.



**Figure 3.** 24-2 and 10-2 Humphrey visual fields of a patient with advanced field damage. The damage encroaches on the fixation but does not split it. In this case, successful trabeculectomy with mitomycin-C was performed. The visual field remained unchanged. The best-corrected visual acuity remained 20/60, and the intraocular pressure decreased from 28 to 34 mmHg to 10–12 mmHg and remained at this level.

fiber loss, which usually begins in the arcuate bundles and the nasal fibers and ends with the papillomacular bundle.

When superior and inferior nasal steps coalesce with arcuate defects and spread centrally and peripherally, tunnel vision evolves. The visual acuity may remain intact (best-corrected visual acuity 20/20) in this situation. Eventually, central vision and/ or temporal peripheral island(s) may remain; when these are lost, the patient remains with no light perception. Occurrence in both eyes results in total blindness. In most types of glaucoma, the chronic ones, the patient may not be aware of the visual field loss, unless comparing each eye to the other. This is the reason that glaucoma is called the silent thief of vision. The patient may present only when the visual acuity in one eye is completely lost because the overlapping between the visual field of both eyes, micro-saccades, and most importantly, turning the head toward the area of interest. Therefore, screening of the population is the most crucial measure to detect glaucoma patients and treat them early.

The goal of treatment is to stabilize the visual field and prevent further deterioration in visual field and visual loss. Unfortunately, currently, the main treatment is aimed only at reducing the intraocular pressure (IOP) and achieving the ideal IOP (target IOP), which differs for each patient and is determined by the type of glaucoma, its severity, progression, patient compliance, and allergy to medications. In general, it should be as low as possible but not too low (hypotonia). Screening of the population includes observing the optic disc and checking



the IOP. It should be performed at least every 5 years before the age of 40 years and every 6 months after the age of 40 years.

## 5. Prevention of visual loss

To date, visual loss in glaucoma is irreversible because of the death of ganglion cells and their axons. The treatment is aimed to prevent continuous visual field loss and is divided into medical, laser, and surgical methods. To prevent visual field loss, the intraocular pressure should be at or below the target IOP, which is individual to each patient and related to the type of glaucoma, severity of the disease, patient's compliance, and allergy to medications. To date, there is no treatment addressing the different genetic defects and molecular mechanisms causing or related to glaucoma. The first line of treatment is usually medications. To enhance treatment, laser treatment may be applied. Some of the laser treatments such as selective laser trabeculoplasty have a short span of effectiveness, usually 1–1.5 years. If these fail, surgery is indicated. The number of medications, laser, and surgical procedures is wide and is determined mainly by the type of glaucoma.

Screening for glaucoma should include the entire population and should be composed of observation of the optic disc and documentation of the cup-disc ratio (C/D ratio) and other features of glaucomatous optic disc damage and intraocular pressure. Screening is usually performed every 5 years and over the age of 40 years twice a year. Patients with higher risk for glaucoma (e.g., family history of glaucoma, pseudoexfoliative syndrome, pigmentary dispersion syndrome, borderline IOP, etc.) may be routinely evaluated more often. Every patient who is diagnosed with glaucoma should be on appropriate medications permanently unless successful surgery has been performed, and even then the patient should be routinely followed.

The follow-up is every 3–4 months for lifetime including after successful surgery. If aggravation occurs, the follow-up intervals may be more frequent. Examination should be performed at different hours of the day, and a diurnal curve is indicated for patients with controlled IOP under medications and continuous visual field damage. The diurnal curve is performed every 4 hours and may even be increased to every 2 hours under medications. Some types of glaucoma such as pseudoexfoliative and pigmentary have a high fluctuation rate that may be missed by routine IOP examination. It is imperative to perform surgery in a timely manner, before the glaucoma is too advanced and before splitting of the fixation on visual field testing. Patients with complete splitting of the fixation are at higher risk to lose their central vision after surgery. Except for glaucoma surgery, other procedures may be required and may result in decrease of IOP. Cataract surgery in presence of risk factors such as hard nucleus (brown, red or black cataract), pseudoexfoliation, phakodonesis, lens subluxation, small pupil, ocular surface disorders such as ocular cicatricial pemphigoid, and Fuch's corneal dystrophy should be performed early. As the number of risk factors increases, surgery should be performed earlier. Visual field should also be obtained for these patients before surgery, if the glaucoma is advanced (C/D ratio of 0.9 or more).

Patients at high risk to lose their vision are those who do not take their medications regularly and/or do not follow-up with their ophthalmologist at regular intervals as indicated above.

Other major factors for visual loss are late diagnosis that may occur with all types of chronic glaucomas and slow decision making. Aggressive glaucoma and poor surgical outcomes may contribute to visual loss.

## 6. How to define controlled glaucoma?

The aim of treatment at present is controlling the IOP to prevent further deterioration in visual fields. The loss of visual field is irreversible. The ideal IOP should be low enough to prevent visual field loss without compromising the functions of the eye. Each patient has a desirable range of IOP—target IOP, which varies between individuals and depends on the aggressiveness of the disease. The aggressiveness of the disease is determined by the IOP, its fluctuations, the type of glaucoma, and the damage to the optic disc and visual field. In normal tension glaucoma, the target IOP is usually less than in other types of glaucoma, because even with normal pressures, the damage continues to progress. The IOP is constantly changing. It depends on the hour (diurnal variations) and seasons. Most but not all subjects have the highest peak in IOP during the early morning.

To be considered as “controlled glaucoma,” the IOP should be within its target during the entire day in a long follow-up with constant use of anti-glaucoma medications or postoperatively. The patients should take their medications properly at a preset times and continuously. Thus, patients intolerant to anti-glaucoma medications or uncompliant are not considered controlled. The IOP may be assessed by diurnal curve every 4 hours, usually between 8 AM and 8 PM, because it changes constantly or even every 2 hours.

## 7. Matters of definition

In this chapter, controlled glaucoma was defined as target IOP under diurnal curve of 4 hours in patients, who are dedicated in taking their anti-glaucoma medications or after surgery. It is a philosophic question whether patients who continue to lose their vision are controlled. Perhaps the definition should be patients who do not show further signs of deterioration. However, since the target pressure has been achieved, it is expected that the patients will demonstrate stability of their visual functions (i.e., visual fields), and this may not occur in a subset of these patients.

## 8. Reasons for progressive visual field loss despite controlled glaucoma

### 8.1. High IOP fluctuations

Secondary glaucomas such as pseudoexfoliative and pigmentary glaucomas have high fluctuations of IOP, which varies depending on the dispersion of pseudoexfoliation material or pigment in the anterior chamber angle. The IOP peaks are unpredictable and variable in time and amplitude and may be missed by diurnal curve even if performed every 2 hours. They may occur between the IOP measurements and may be missed. To overcome this, frequent IOP monitoring including at bedtime and at shorter intervals may reveal such patients. Patients

with high and large fluctuations that are on full medical treatment may benefit from early glaucoma surgery, either trabeculectomy with mitomycin C or shunt procedure. Still, patients without IOP fluctuations may progress to blindness from other reasons as stated below.

### **8.2. Increased IOP in supine position (at bedtime)**

People spend about one third of the day (6–8 hours) sleeping. The resting time may increase after retirement. The IOP increases at supine position compared with standing or sitting in healthy subjects by  $2.47 \pm 2.12$  mmHg (mean  $\pm$  standard deviation) ( $p < 0.001$ ) when measured by non-contact tonometer Keeler, Pulsair EasyEye [2]. In another study, the IOP in sitting position was found to be  $13.5 \pm 2.0$  mmHg in the right eye and  $13.2 \pm 2.3$  mmHg in the left eye in healthy individuals [3]. The IOP increased in supine position to  $16.8 \pm 2.3$  mmHg and  $17.0 \pm 2.3$  mmHg, respectively ( $p = 0.001$ ). This may result in deterioration of the optic disc and visual fields. Diurnal curve has probably no meaning if the patient is awakened at bedtime, and the pressure is measured while sitting.

The intracranial pressure (ICP) may also influence the progression of glaucoma [4, 5]. The ICP is directed through the subarachnoid space opposite to the IOP through the lamina cribrosa, and the difference between them is the translaminar pressure gradient. Theoretically, if this is low, the progression may be slower than if it is high but this may not be true. A high ICP and IOP with a low gradient may be sufficient to cause increased optic disc damage because of the increased shearing force in the lamina cribrosa and decrease in axonal plasma flow. This may initiate or facilitate axonal apoptosis.

### **8.3. Increased IOP when sleeping on the affected eye(s)**

Most ophthalmologists do not live with their glaucoma patients and have no idea about their behavior in daily life. The patients may sleep on their affected eye(s), and this causes further increase of the IOP in addition to the increase caused by supine position. When the eye leans against the bed or pillow or when the entire mass of the head is over all or part of the globe, IOP is increased by 33%. Thus, the physician should inquire about the sleeping habits of the glaucoma patients. Actually, increase in IOP measurement can be seen in patients who squeeze their eyes during evaluation with Goldmann tonometer, as well as with some other instruments. It can also be seen if the examiner presses the globe during IOP measurement.

### **8.4. Antihypertensive drugs at bedtime**

Glaucoma patients are usually older and have many associated aging and pathologic conditions, including atherosclerosis and systemic hypertension. Other ischemic diseases such as diabetes mellitus may also be encountered. Taking antihypertensive drugs before sleeping increases the risk for anterior ischemic optic neuropathy (AION) [6]. Antihypertensive medications decrease the perfusion into the optic disc, and this may join atherosclerotic changes in the blood vessels. AION may be difficult to diagnose in patients with advanced glaucoma. In advanced glaucoma, the cup may be large (cup/disc ratio of 0.8 or more), and the rim is thin enough not to distinguish pallor of the rim following additional AION. In addition, AION field defects may be superimposed on the glaucoma visual field defects. In advanced glaucoma, the visual field scotomata may be large enough (e.g., tubular vision) to prevent detection of the additional scotomata caused by AION. According to the vascular theory, damage to the optic nerve may be caused



also from ischemia if the optic disc does not receive enough oxygen even without AION. This damage is added to the damage caused by the mechanical effect of optic disc compression.

8.5. Continuation of the neuronal apoptosis

Patients with glaucoma suffer loss of axons of the ganglion cells as they pass the optic disc. Two theories explain the axonal loss. The first one is mechanical. According to this theory, the force caused by the IOP impedes axonal transport (flow) (micro-strangulation) and this may trigger axonal apoptosis [7]. The second theory is vascular. This means that the IOP impedes vascular supply to the optic disc. This causes a relative ischemia to the optic disc and triggers apoptosis. It is probable that both mechanisms coexist and the mechanical force may have a greater influence. Nonetheless, apoptosis, and not degeneration/necrosis, is the mechanism of axonal death in glaucoma. Apoptosis is programmed cell death, while necrosis is a different process involving extracellular components of inflammation. It consists of several pathways initiated by certain extracellular ligands such as programmed death ligand 1 (PD-L1), Fas ligand (FasL), tumor necrosis factor (TNF), nerve growth factor (NGF), growth factors, and others (Figure 4) [8, 9]. These molecules attach to receptors on the cell wall such as tropomyosin kinase receptor (TRK), tyrosine kinase receptor (RTK), receptor of apoptosis signal factor (Fas), and tissue necrosis factor receptor (TNFR) that trigger intracellular cascades that involve multiple pathways and molecules including the caspase cascade. These processes

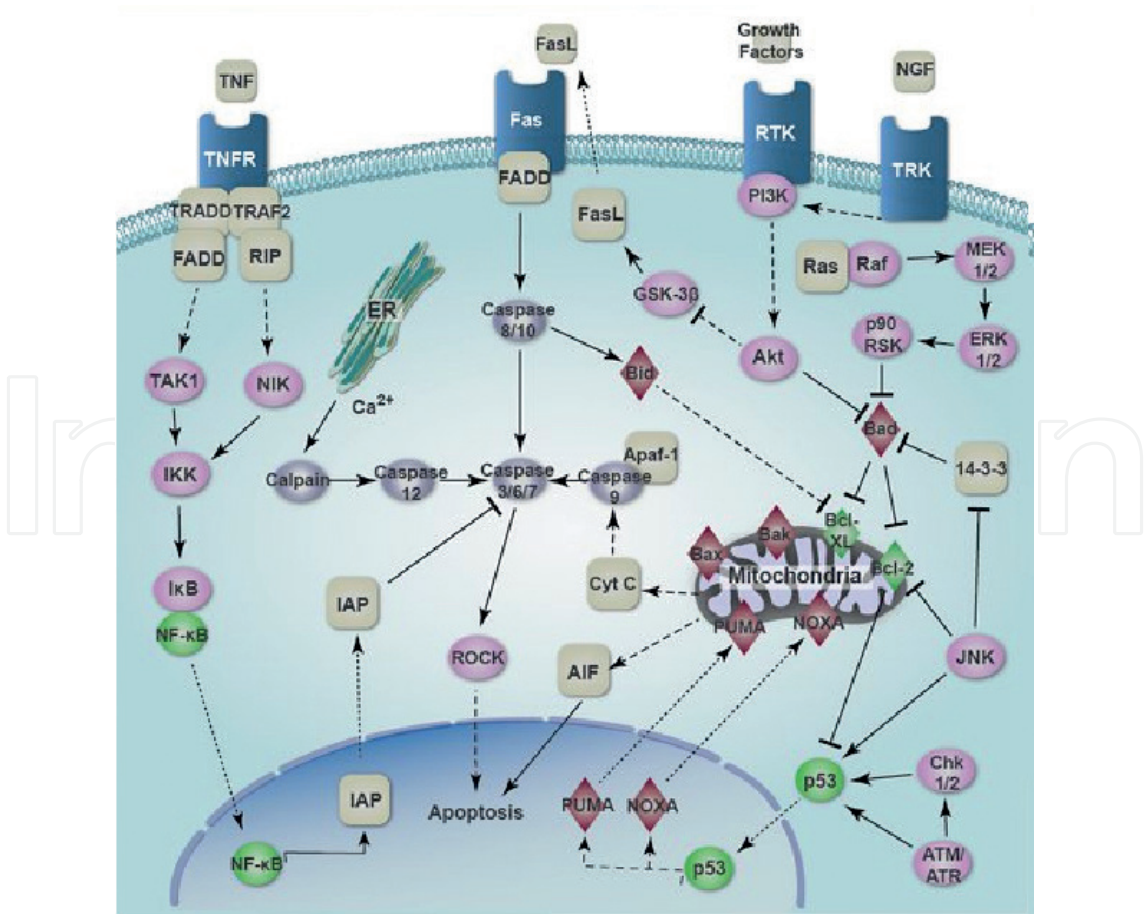


Figure 4. The pathways of apoptosis. Interference with any of these steps may prevent the apoptosis cascade.

occur in the cytoplasm, endoplasmic reticulum, and mitochondria that lead signals to the nucleus to degenerate. The end result is shrinkage of the nucleus, fragmentation of the deoxyribonucleic acid (DNA), and death of the cell. It is possible that some additional mechanisms and pathways exist that involve adjacent cells such as astrocytes, oligodendrocytes, and even vascular endothelial cells. Despite controlled IOP, the apoptosis may continue once started causing additional ganglion cell death. Ganglion cells in different stages of apoptosis may “signal” adjacent normal cells to commence with apoptosis cascade, leading to further loss of neuronal cells.

## 9. Recommendations to prevent further visual loss in patients with controlled glaucoma

Patients with high IOP fluctuations are not controlled and may benefit from early surgery such as trabeculectomy with mitomycin C or shunt procedures. These patients can be traced because they usually have secondary glaucoma mainly pseudoexfoliative and pigmentary. It is worthwhile to ask the patients to sleep at 20–30° head-up position. The IOP decreases when the bed head is tilted up in 30° and is  $14.2 \pm 2.3$  mmHg OD and  $14.1 \pm 1.9$  OS and not when the patient is sleeping on multiple pillows ( $16.3 \pm 2.4$  OD and  $16.5 \pm 2.6$  OS) [3]. In another study, the IOP decreased from  $16.02 \pm 1.65$  to  $14.5 \pm 1.36$  mmHg [10]. The IOP may decrease by 9.33% in glaucoma patients, and this effect is found in 82% of them. Patients should avoid sleeping on their affected eye(s). Sleeping over the back or even on the side as long as the orbital rim is lying against the pillow is the best option for these patients. Antihypertensive medications should be taken when the patient is awake and active, usually in the morning and not at bedtime. It is the physician role to make these recommendations.

Additional efforts should be made to discover drugs that can abolish or slow down the apoptosis. Antibodies against PD-L1, FasL, growth factors, or their receptors may be helpful. Forty chemical compounds have inhibitory effects on different steps of apoptosis but may be toxic to normal cells. Phenoxodiol, an isoflavone that targets a regulator of sphingosine kinase depriving the cell of XIAP and FLIP was evaluated for ovarian cancer but was disappointing. Thus, it is essential to discover biologic agents such as antibodies against one or more of the extracellular mediators with better effects and with few or no side effects that will be approved for clinical use to arrest axonal apoptosis at the optic nerve. So far, none has been discovered, and research efforts are mandatory because such molecules may be used in glaucoma as well as other fields to prevent cellular few or no by apoptosis.

## Author details

Shimon Rumelt\* and Shachar Schreiber

\*Address all correspondence to: [shimonr@gmc.gov.il](mailto:shimonr@gmc.gov.il)

Department of Ophthalmology, Galilee Medical Center, Nahariya and Faculty of Medicine, Bar Ilan University, Zefat, Israel

## References

- [1] World Health Organization. Visual Impairment and Blindness. Fact Sheet No. 282. August 2014
- [2] Jorje J, Ramoa-Marques R, Lourenço S, et al. IOP variations in the sitting and supine positions. *Journal of Glaucoma*. 2010;**19**:609-612
- [3] Yoon D-Y. Effects of head elevation on intraocular pressure in healthy subjects: Raising bed head vs. using multiple pillows. *Eye*. 2014;**28**:1328-1333
- [4] Roy Chowdhury U, Fautch MP. Intracranial pressure and its relationship to glaucoma: Current understanding and future directions. *Medical Hypothesis, Discovery and Innovation in Ophthalmology*. 2015;**4**:71-78
- [5] Berdahl JP, Allingham RR. Intracranial pressure and glaucoma. *Current Opinion in Ophthalmology*. 2010;**21**:106-111
- [6] Hayreh SS. Role of nocturnal arterial hypotension in the development of ocular manifestations of systemic arterial hypertension. *Current Opinion in Ophthalmology*. 1999;**10**:474-482
- [7] Quigly HA. Ganglion cell death in glaucoma: Pathology recapitulates ontogeny. *Australian and New Zealand Journal of Ophthalmology*. 1995;**23**:85-91
- [8] Elmore S. Apoptosis: A Review of programmed cell death. *Toxicologic Pathology*. 2007;**35**:495-516
- [9] Strasser A, O'connor L, Dixit VM. Apoptosis signaling. *Annual Review of Biochemistry*. 2000;**69**:217-245
- [10] Lazzaro EC, Mallick A, Singh M, et al. The effect of positional changes on intraocular pressure during sleep in patients with and without glaucoma. *Journal of Glaucoma*. 2014;**23**:282-287