

# We are IntechOpen, the world's leading publisher of Open Access books Built by scientists, for scientists

6,900

Open access books available

185,000

International authors and editors

200M

Downloads

Our authors are among the

154

Countries delivered to

TOP 1%

most cited scientists

12.2%

Contributors from top 500 universities



WEB OF SCIENCE™

Selection of our books indexed in the Book Citation Index  
in Web of Science™ Core Collection (BKCI)

Interested in publishing with us?  
Contact [book.department@intechopen.com](mailto:book.department@intechopen.com)

Numbers displayed above are based on latest data collected.  
For more information visit [www.intechopen.com](http://www.intechopen.com)



---

# Nontuberculous Mycobacterial Infections: Negligent and Emerging Pathogens

---

Thet Tun Aung and Roger W. Beuerman

Additional information is available at the end of the chapter

<http://dx.doi.org/10.5772/intechopen.80444>

---

## Abstract

Nontuberculous mycobacteria (NTM) are a heterogeneous group of microorganisms other than *Mycobacterium tuberculosis* (*M. tuberculosis*) complex and *Mycobacterium leprae*. NTM infections have increased globally and are now considered an emerging infection as they are often encountered in developed countries. NTMs require extended treatment adding considerably to the economic burden. The increasing number of patients with immunocompromised disorders, increasing usage of immunosuppressive agents, general awareness of the NTM diseases due to the advancement in molecular diagnostic techniques and aging of the population increase the prevalence rate of NTM infections. However, several barriers such as the requirement of better diagnostic techniques, settled treatment guidelines, clinician awareness and knowledge of pathogenesis are limiting and NTM infections are often not treated promptly. Etiology and epidemiology of NTM infections [*Mycobacterium avium* complex (slowly growing mycobacteria, SGM) and rapidly growing mycobacteria (RGM)] are discussed in this chapter. Clinical features, diagnosis and currently available treatment guidelines for these infections in skin, eye and lung are summarized. Suggestions for future research directions are suggested particularly for the better understanding of host-pathogen crosstalk and new therapeutic strategies.

**Keywords:** nontuberculous mycobacteria, rapidly growing mycobacteria, slowly growing mycobacteria, biofilms, eye, lung, skin

---

## 1. Introduction

### 1.1. Etiology, epidemiology and possible sources of NTM infections

The NTM group of mycobacteria is nonmotile aerobic bacilli, acid-fast (AF) staining organisms [1]. The lipid-enriched hydrophobic cell wall is usually thicker than other bacteria

---

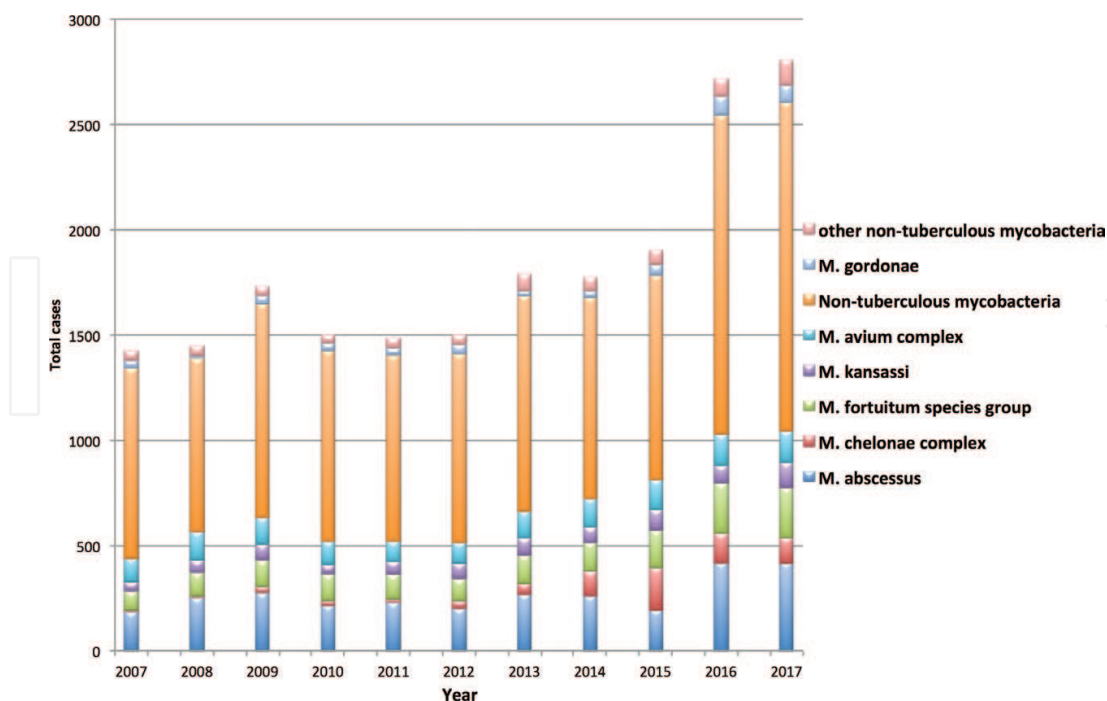
characterized by tolerance to many disinfectants, heavy metals and antibiotics [1, 2]. They are frequently found in the environment such as soil and water. They readily form biofilms, which contributes to their resistance against a variety of antibiotics [3] as well as high temperatures and a wide range of pH [4]. Environmental recovery of these NTM is the same when they do in similar culture techniques in different geographical regions [5]. However, western countries are reporting a greater prevalence of NTM infections compared to Tuberculosis (TB) than most Asian countries due to very stringent prevention and treatment of tuberculosis [6]. Not all the culture-positive samples represent infection and only half of the culture-positive patients have active respiratory infections, highlighting that NTM can be silent in presence of a normal immune response [7]. Reports suggest that older patients and women have higher chances of NTM infections [8]. As an outcome of the Human Immunodeficiency Virus (HIV) epidemic, NTM infections are frequently isolated from the blood of HIV patients [9]. In the United States, NTM cultures (more than 90%) are from pulmonary disease [10]. According to the Infectious Diseases Society of American Emerging Infections Network and Information from referral centers report, NTM infections are emerging pathogens, particularly rapidly growing mycobacteria (RGM) such as *Mycobacterium abscessus* (*M. abscessus*), *Mycobacterium chelonae* (*M. chelonae*) and *Mycobacterium fortuitum* (*M. fortuitum*) [11]. The prevalence and trend of NTM pulmonary infections are increasing, particularly in Florida and New York, calculated from United States census data from 1998 through 2005 [12]. NTM are the most common pathogens after cosmetic surgeries such as tattooing and Laser in situ keratomileusis (LASIK) [13, 14]. Increasing reports of NTM infections are expected in eye, skin, and lung due to the popularity of LASIK, increasing population of immunocompromised patients and older population. NTM pulmonary infections are found in the areas with heavy population, indicating that urban water supply increases individual's exposures to NTM [15]. NTM infections are frequently associated with farmers in Japan, suggesting that soil is the main source of infection there [16]. For NTM lung infections, aerosolization of droplets by bathroom showers may be another route of infection [17]. Water is considered to be a normal habitat for NTM and households with low water heater temperature are found to correlate with NTM infections [18]. Hospital water supply is considered to be vital in controlling NTM infections and dialysis solutions contaminations have led to the NTM outbreaks [19–21]. Contaminated tap water and increased demand of cosmetic surgeries in freestanding health centers that cannot be reviewed frequently by the infectious diseases control center are other concerns for NTM outbreaks [22].

## 1.2. Runyon's classification

Runyon classified NTM into four groups, I–IV [23–25]. Group I, photochromogens, which usually grow slowly about 2–4 weeks and change to yellow with light exposure. Group II, scotochromogens, consist mainly of *M. gordonae* and appear as yellow colonies at 2–4 weeks in agar plates when cultured in the dark. Group III are nonphotochromogens, slowly growing mycobacteria, which grow slowly over 2–4 weeks. The rapid growers, group IV NTMs are the most pathogenic and important for human disease. They are divided into three subgroups: *M. fortuitum*, *M. chelonae/abscessus*, and *M. smegmatis*. According to the literature, they are susceptible to various antibiotics such as sulfonamide, polymyxin B, and the third- and fourth-generation fluoroquinolones [25]. Group III organisms are lung pathogens and Group IV organisms are the most important and prevalent strains for the eye, lung cutaneous and subcutaneous infections [25].

### 1.3. Laboratory diagnosis and barriers

Culture technique is the typical standard method for the identification of suspicious NTM. The organisms must be cultured on specific media such as AF smear, Lowenstein-Jensen (LJ) media, Middlebrook media and MacConkey agar since it cannot be differentiated by Gram-stain [26]. The organisms must be cultured in both liquid medium for growing a large amount of organism for other tests and solid medium to observe colony morphology and characteristic [27]. Moreover, the organisms should be further identified into subspecies level for different appropriate antimicrobial therapy. Subspecies level can be achieved by using gene sequencing, high-performance liquid chromatography (HPLC), and molecular-based methods [28]. HPLC is a fast, reliable method for identifying NTM. However, HPLC has limitations: it cannot separate between *M. abscessus* and *M. fortuitum*/*M. chelonae* [29]. Molecular probes, acridinium ester-labeled DNA probes have been made commercially and approved by the U.S. Food and Drug Administration (FDA) for the rapid identification of NTM [30]. MicroSeq 500 16S rDNA Bacterial Sequencing Kit (PE Applied Biosystems, Foster City, CA) has been developed to identify the NTM strain [31]. However, misdiagnoses frequently occur due to the low frequency of these infections, coupled with a lack of diagnostic experience for NTM infections, as well as confusing morphological features in stained smears [28]. Misdiagnosis can be complicated by incorrectly correlating laboratory results by physicians [32]. Misdiagnosis of NTM infections can lead to fatal incidents and NTM often exhibit the microbiological features of *Corynebacterium* species with long filamentous beaded appearances [33, 34]. NTM microscopic features are also similar to *Nocardia* species [35]. Therefore, clinicians are taking note of these emerging infections for prompt and focused diagnosis to initiate effective treatment.



**Figure 1.** Bar graph showing the incidences of NTM in Singapore (2007–2017). Other NTM consists of *M. szulgai*, *M. terrae* complex, *M. haemophilum*, *M. intracellulare*, *M. marinum*, *M. mucogenicum*, *M. neoaurum*, *M. scrofulaceum*, *M. simiae*, *M. mageritense*, *M. wolinskyi*, *M. asiaticum*, *M. celatum*, *M. chimaera*, *M. duvalli*, *M. cookii*, *M. cosmeticum*, *M. chlorophenolicum*, *M. genavense*, *M. kubicae*, *M. lentiflavum*, *M. mantenii*, *M. obuense*, *M. stomatepiae*, *M. triplex* and *M. xenopi*.

## 1.4. NTM incidence in Singapore (2007–2017)

The incidences of NTM cases in Singapore are rising in the recent years, about 3000 cases per year [36] (**Figure 1**). Among NTM, *M. abscessus* is responsible for most of the identified NTM cases in Singapore, followed by *M. fortuitum*, *M. avium* complex and *M. chelonae* (**Figure 1**).

## 2. NTM cutaneous and subcutaneous infections

### 2.1. *Mycobacterium abscessus*

*M. abscessus*, a fast-growing NTM, is commonly found in water drainage systems and sewage. It is a subset of the *M. chelonae* complex and it is vital to segregate from the *M. chelonae* complex due to the dissimilar antibacterial treatment option. It is well known that the clinical success of *M. abscessus* depends on the host's immune defense [37]. It was reported that *M. abscessus* caused posttransplant infection in cystic fibrosis (CF) patients in spite of having antimicrobial treatment [38]. They are responsible for the major causes of skin and soft tissue infections in the literatures [39] and they are the most common cause of identified NTM infections in Singapore (**Figure 1**). The path of entries for this organism is direct inoculation such as skin piercing or injury [40] or secondary involvement from disseminated infection [41]. The most likely source of infection is from tap water. Water and soil are the natural habitats for *M. abscessus* [4, 42]. *M. abscessus* outbreaks have been reported in clinic and hospitals worldwide and the contaminated instruments or disinfectants are the major sources of the outbreaks [41].

#### 2.1.1. Clinical features and causes of *M. abscessus* cutaneous and subcutaneous infections

*M. abscessus* infected skin usually presents with painful, swollen and tender to the touch, accompanying with pus-filled vesicles. Nonspecific symptoms of infections may be present such as fever with chills, muscle aches, and malaise. Causes of *M. abscessus* infections include posttraumatic wound infections [20], postinjection wound infections [20] and surgical wound infections (mammoplasties, plastic surgeries, and heart surgeries) [20].

### 2.2. *Mycobacterium fortuitum*

*M. fortuitum* is a principal cause of cutaneous and subcutaneous infections associated with catheters [43, 44] as well as post surgical wound infections [45]. The route of entry for *M. fortuitum* is direct inoculation from contaminated water through the lesions.

#### 2.2.1. Clinical features and causes of *M. fortuitum* cutaneous and subcutaneous infections

Small, erythematous papules are frequent signs of the early stages of infection and large, fluctuant, painful violaceous boils and ulcerations are signs for late stage infections [45, 46]. They can be caused by mesotherapy and present with indurated, erythematous and violaceous papules with 3–20 numbers, the diameter ranging from 0.5 to 6 cm, accompanied by inguinal or axillary lymphadenopathy [47]. *M. fortuitum* can also be recovered from blood and

purulent discharge from patients with venous catheters [43, 44] and is the cause of post surgical wound infections such as liver transplant patients, electromyography and punch biopsy procedures [44, 48, 49].

### 2.3. *Mycobacterium chelonae*

*M. chelonae* infections are usually associated with immunocompromised hosts such as HIV patients [50]. It can be seen in postsurgical wounds and can disseminate hematogenously to cause sepsis. Contaminated water is the most common source of infection and the route of entry is direct inoculation.

#### 2.3.1. Clinical features and causes of *M. chelonae* cutaneous and subcutaneous infections

Circumscribed, red, infiltrative plaques, umbilicated papules, and pustules on the upper part of the body and face are features of *M. chelonae* skin lesions and frequently accompanied by cervical lymphadenopathy [51]. Immunocompromised patients, HIV/AIDS patients often contract *M. chelonae* infections [50]. Kidney transplant patients, liver transplant patients, tattooing, kidney dialysis patients and peritoneal dialysis patients are also frequently associated with *M. chelonae* infections [13, 52, 53]. Reports suggest that immunosuppressive drugs such as prednisolone, methotrexate, and adalimumab [54, 55], and autoimmune diseases such as Cushing's syndrome and rheumatoid arthritis are often associated with *M. chelonae* skin infections [55, 56].

### 2.4. NTM cutaneous and subcutaneous infections

The correct choice of antimicrobial agent, anatomic locations of the lesions, intracellular uptake and target binding are essential for the management of NTM cutaneous and subcutaneous infections. Moreover, an appropriate route of drug administration (oral, intravenous or intramuscular), acceptable and effective drug concentration is required for the treatment plan. Drug resistance mechanisms for rapidly growing mycobacteria (RGM) involving *erm* gene must be considered due to the prolonged treatment period. Therefore, it is critical to differentiate and identify rapidly growing mycobacterial at the subspecies level [25, 57]. The decision of choosing either surgical debridement in combination with mono or multidrug therapy, or only mono or multidrug therapy depends on the anatomical location and severity of the lesion, patient's immune status with presence of underlying pathology (**Table 1**) and the Minimum Inhibitory Concentration (MIC) breakpoints from the microbiology lab (**Tables 2 and 3**).

#### 2.4.1. *M. abscessus* cutaneous and subcutaneous infections

Macrolides are the gold standard treatment for *M. abscessus* infections. They exhibit bactericidal actions against *M. abscessus* when the lesion has a small population of bacteria. Reports suggest that azithromycin and clarithromycin are the gold standard for treating *M. abscessus* infections in disseminated cases; however, there are reports suggesting the evolution of resistance against these drugs in prolonged monotherapy [11, 58]. Tigecycline, a new antibiotic,

RGM	Disease pattern	Antimicrobial agents
<i>M. fortuitum</i>	2–8 week duration with significant signs and symptoms	Combination of amikacin, quinolones or tobramycin (imipenem)
	After IV treatment or disease with reduced signs and symptoms	Linezolid
		Doxycycline
		Clarithromycin
<i>M. abscessus</i>	2–8 week duration with significant signs and symptoms	Trimethoprim/sulfamethoxazole
	After IV treatment or disease with reduced signs and symptoms	Combination of clarithromycin, amikacin, ceftazidime (imipenem) or tigecycline
		Linezolid
<i>M. chelonae</i>	2–8 week duration with significant signs and symptoms	Combination of clarithromycin, linezolid (tobramycin, imipenem, tigecycline or oral drug)
	After IV treatment or disease with reduced signs and symptoms	Gatifloxacin
		Doxycycline
		Linezolid
		Clarithromycin

**Table 1.** Clinicians’ choice of antibiotic regimes for different RGM infections [112].

	Susceptible	Intermediate	Resistant
Doxycycline/minocycline	≤1	2–4	≥8
Imipenem/meropenem	≤4	8–16	≥32
TMP/SMX	≤2/38	–	≥4/76
Tobramycin	≤2	4	≥8
Moxifloxacin	≤1	2	≥4

**Table 2.** MIC breakpoints for RGM [112, 113].

may be another choice for *M. abscessus* infections [59]. Amikacin is known to be the treatment of choice since it is active against all the subspecies of RGM and imipenem or ceftazidime can be added to overcome treatment failures [11, 58]. Surgical debridement plays a role in the better treatment outcomes for *M. abscessus* infections [60].

2.4.2. *M. fortuitum* cutaneous and subcutaneous infections

*M. fortuitum* infections are chronic in nature and *in vitro* drug susceptibility tests are required for a guidance of choosing the correct antibiotics. Usually, *M. fortuitum* are sensitive to several oral antimicrobials such as quinolones, sulfonamides, and macrolides [61, 62]. Amikacin is the treatment of choice for *M. fortuitum* with 100% efficacy, while sulfonamide and imipenem/

RGM	Drug	Reporting
<i>M. fortuitum</i>	Clarithromycin	Trailing endpoints, report as resistant
	Imipenem	New breakpoint (8–16 µg/ml) for reproducible MIC
<i>M. abscessus</i>	Amikacin	If MIC is more than 64 µg/ml, need to repeat/confirm
<i>M. chelonae</i>	Tobramycin	If MIC is more than 4 µg/ml, need to repeat/ confirm

**Table 3.** Reporting MICs of RGM [112].

cilastatin also account for 100%, clarithromycin stands for 80% and linezolid and doxycycline accounts for 50% [63]. Due to rising chances of bacterial resistance to macrolide due to the inducible *erm* gene, clarithromycin uses should be carefully assessed and monitored [52, 63, 64]. Linezolid is another good candidate for *M. fortuitum* in *in vitro*; however, more human clinical studies would be warranted for the future use [65]. The minimum 4 months duration of the combination of two drugs is required for severe or critical *M. fortuitum* cutaneous and subcutaneous infections. Reports are suggested that surgical debridement or surgical drainage is indicated for the better antimicrobial treatment therapy or helping to cure the *M. fortuitum* infections particularly in extensive disease and abscesses [66]. *M. fortuitum* usually possess the *erm* gene, which is inducible to promote resistance to clarithromycin. There was a report showing that sensitivity testing of *M. fortuitum* isolates showed trailing MICs against macrolides [67]. However, the relevance of the *erm* gene in *M. fortuitum* and clarithromycin treatment remains to be determined in clinical management.

#### 2.4.3. *M. chelonae* cutaneous and subcutaneous infections

Clofazimine is shown to be effective and the addition of sub MIC concentration of amikacin synergies with clofazimine against RGM including *M. chelonae* [68]. Tobramycin has been suggested to be a better treatment option than amikacin [69]. However, *M. chelonae* isolates showed resistant to cefoxitin and imipenem is the alternative option. There is MIC susceptibility of clarithromycin (100%), tobramycin (100%), linezolid (90%), imipenem (60%), amikacin (50%), doxycycline (25%), clofazimine (25%) and ciprofloxacin (20%) [63]. However, *M. chelonae* is susceptible only to clarithromycin, tobramycin, and tigecycline [70]. Monotherapy is not advisable for *M. chelonae* infections due to its facility to acquire drug resistance and combination treatment is advised [71]. Excision and treatment is still the optimal treatment step in combination with antibiotics in treating *M. chelonae* cutaneous and subcutaneous infections [66]. Treatment guidelines are not yet reported; however, current guidelines recommend using antimicrobial susceptibility tests to predict therapeutic efficacy.

## 3. NTM eye infections

### 3.1. Clinical features and causes of NTM eye infections

The most prevalent NTM strains causing eye infections are *M. fortuitum* and *M. chelonae* [72, 73]. Keratitis is standing as the most common real situation accounting for 69% of ocular NTM infections (Table 4).

Different types of ocular NTM infection	Percentage
1. Ocular surface infections	
a. Keratitis	69
b. Scleritis	4.3
c. Conjunctivitis	0.7
2. Periocular and adnexal infections	13.3
3. Intraocular infections and uveitis	12.6

**Table 4.** Different types of ocular infection caused by NTM [14].

Late presentation of symptoms and diagnosis was reported in NTM keratitis [74]. Pain, decreased vision, and photophobia were present in gradual increasing patterns in the course of NTM keratitis [75]. The multifocal or single lesion surrounded by radiating corneal infiltrates, ‘cracked windshield’ appearance, was reported [74, 76, 77]. Infiltrates had irregular margins, mimicking fungal keratitis [78]. Hypopyon is present in untreated or poorly treated cases [74]. There have been reports of infectious crystalline keratopathy, intrastromal opacity and minimal inflammation in some cases of NTM keratitis leading to a misleading diagnosis of herpetic keratitis [79, 80] (**Table 5**).

The most common association of NTM keratitis is LASIK (47.6%), followed by trauma (14.8%), foreign body (17.6%), implants (17.3%) and contact lens (6.4%) [14]. LASIK is the most popular refractive corrective surgery implemented worldwide since it offers less stromal scarring and rapid recovery of visual acuity. The symptoms for post-LASIK mycobacterial keratitis are less severe than other causes [26]. The time frame of 3 to 14 weeks duration is reported to present post-LASIK NTM keratitis. Some cases of post-LASIK mycobacterial keratitis present within 10 days post surgery [26, 81]. The most probable route of entry for post-LASIK NTM keratitis is during the surgery. Corneal infiltrates are within the lamellar flap or interface presenting with either single white lesion or multiple white granular appearances. Anterior extension of corneal infiltrates is common to form a corneal ulceration. Late diagnosis or treatment can result in the posterior extension into the corneal stroma. The anterior chamber is usually silent or has the mild inflammatory reaction [26, 82].

**3.2. Treatment of NTM eye infections**

Management of NTM keratitis is challenging due to its rarity, potential to acquire antibiotic resistance, natural resistance to a variety of commercially available antibiotics and delayed response to antibiotics. Identification of NTM keratitis can be delayed and one report revealed that the time to identification was delayed for 4 months due to slow growth of the organism [83]. Drug sensitivity tests need to be carried out using a prolonged incubation time, resulting in the delayed treatment of NTM eye infections. Moreover, there are several reports showing that a wide range of antibiotic sensitivities exists in different isolates [84]. Consequently, a combination of two or three drugs helps to prevent acquired antibiotic resistance in long-term

management and clarithromycin, amikacin, and fourth generation fluoroquinolones are mentioned [85]. Topical delivery is the most used method followed by the combination of topical and systemic administration [14]. Amikacin is known to be the treatment of choice for NTM keratitis, however, there have been reports showing corneal toxicity toward the long-term usage of amikacin in high concentration [86]. According to the systemic review, amikacin was given alone in the majority of NTM keratitis cases, followed by amikacin and macrolide (**Table 6**) [14]. Fluoroquinolones, particularly fourth-generation fluoroquinolones, have been accepted as effective for eye infections [3, 86]. Fourth generation fluoroquinolones offer noteworthy benefits over the older generations because of their superior bactericidal activity, decreased risk for resistance and higher corneal concentrations. In contrast, one report suggested that the majority of nontuberculous mycobacteria are resistant to second-generation fluoroquinolones, highlighting the better efficacy properties of fourth generation fluoroquinolones [87].

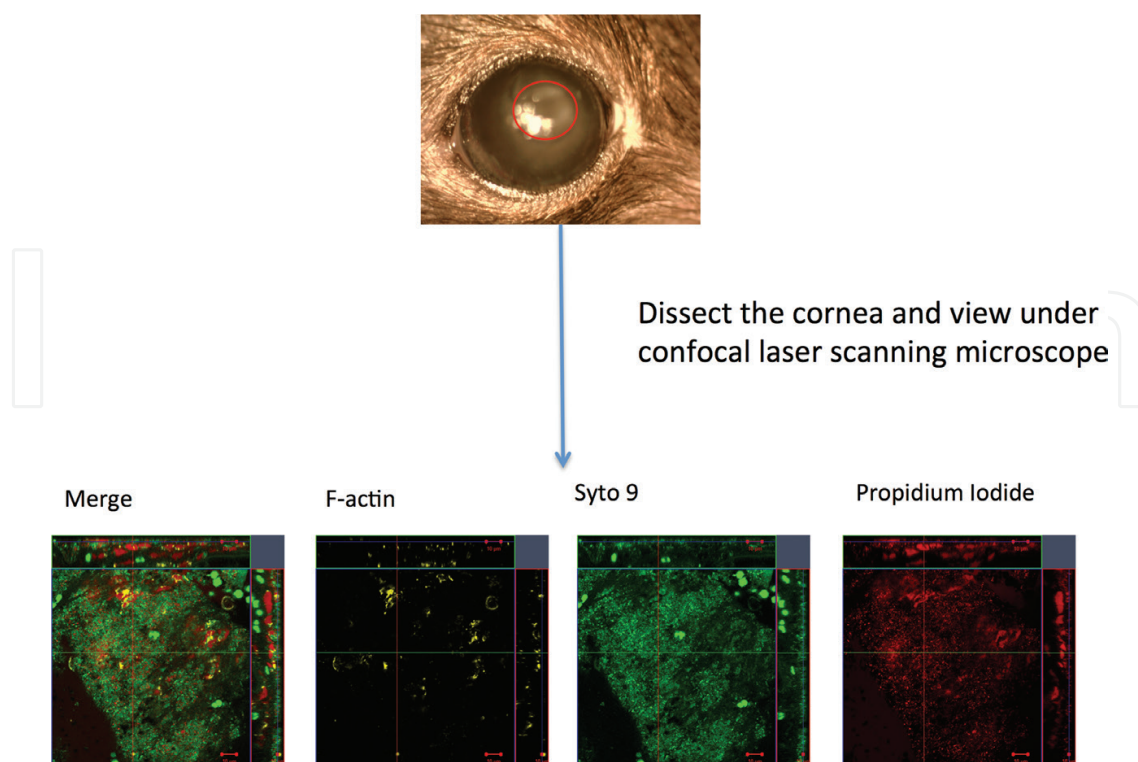
Recent reports suggest a strong synergism between amikacin and fourth generation fluoroquinolone, gatifloxacin, in treating nontuberculous mycobacteria in *in vitro* and *in vivo* mouse keratitis model [88]. Moreover, it was reported that the NTM habitat in a keratitis infection is in the biofilm mode (**Figure 2**) hindering antibiotic penetration and adding DNase to the antibiotic may make a more effective treatment [88]. Surgical debridement can help to facilitate penetration and lower the bacterial load. Topical steroids are controversial for NTM keratitis and one study suggested that a steroid accelerates the infection [89]. Careful follow up of NTM

Symptoms	Signs
Varying degree of pain	Multiple lesions or single lesion surrounded by the radiating projections
Photophobia	Cracked windshield appearance
Tearing and foreign body sensation	Hypopyon
Decreased visual acuity	Mild or Silent anterior chamber

**Table 5.** Signs and symptoms of NTM keratitis.

Different antibiotic regimen	Percentage
Amikacin only	29.2
Combination of amikacin and macrolide	14.1
Combination of amikacin and fluoroquinolone	12.5
Combination of amikacin, fluoroquinolone and macrolide	9.4
Combination of fluoroquinolone and macrolide	8.3
Other antibiotics	7.3
Fluoroquinolone only	6.8

**Table 6.** Different antibiotic regimens for NTM keratitis [14].



**Figure 2.** Slit lamp photograph showing central haziness in NTM keratitis mouse model. Confocal microscopy images showing presence of atypical mycobacterial microcolonies biofilm formation (green color) with abundance of extracellular DNA (a major constituent of mycobacterial biofilm matrix in red color) [88].

keratitis patients is suggested; if the lesion is in progression, or stromal thinning and symptoms persistence continues after 2 days of antibiotics, drug sensitivity should be rechecked for an alternative sensitive antimicrobial. However, there is no agreed-upon treatment plan for NTM keratitis and more research including evaluation of new treatment plans and an in-depth knowledge of NTM keratitis pathogenesis is warranted to treat NTM keratitis effectively.

## 4. NTM lung infections

### 4.1. Clinical features and causes of NTM lung infections

NTM lung infections are often due to *Mycobacterium avium* complex (MAC) and RGM. NTM lung disease may be misdiagnosed as Tuberculosis and require weeks or months [90]. The clinical diagnosis and treatment remain challenging due to its nonspecific symptoms such as low-grade fever, wet chronic cough, weight loss and malaise similar to *M. tuberculosis* [91]. Radiological imaging is a vital test to screen for NTM lung disease. A broad range of radiological patterns such as bronchiectasis, cavitary lesions, nodular lesions and parenchymal lesions, have been observed in NTM lung disease [92]. However, two major radiological findings have been listed, fibrocavitary and nodular bronchiectatic forms [93]. The first form is similar to pulmonary TB and it usually affects elderly male with underlying pathology of the lung. Cavities with increased opacity are usually seen in the upper parts of the lung in the fibrocavitary form [94]. Thin-walled cavities without lymph node involvement and atelectasis are the common findings in this form [95]. The nodular bronchiectatic form often presents

with bilateral, small nodules and multilobar bronchiectasis in the lower and middle parts of the lung [96]. This disease pattern is associated with elderly nonsmoking women without underlying lung diseases [97]. There is a connection between bronchiectasis and NTM lung diseases [98]. Because of NTM's nonspecific symptoms and similar radiological findings as *M. tuberculosis* and other lung pathologies, it is extremely hard to diagnose NTM lung disease. Risk factors causing NTM lung disease are still poorly understood but immune status is vital for NTM lung disease. A study showed that disseminated NTM infection is often associated in patients with profound immunosuppression [99]. NTM are important pathogens for patients who have undergone or are awaiting lung transplant and cystic fibrosis patients [100]. Defects in the crucial elements of the host defense such as interleukin-12 (IL-12) and interferon-gamma (IF- $\gamma$ ) increase susceptibility to NTM lung infections [101]. Increasing usage of tumor necrosis factor (TNF- $\alpha$ ) receptor antagonists usage enhances NTM infections [102]. The rate of NTM prevalence in TNF- $\alpha$  receptor antagonists usage is 74/100,000 persons per year [103].

## 4.2. Treatment of NTM lung infections

### 4.2.1. MAC lung infections

Macrolides are the treatment of choices for MAC lung infections [104]. Rifampin or ethambutol can be added to macrolide administration for 18–24 months [63]. Rifampin 600 mg/kg, ethambutol 25 mg/kg with either azithromycin 500 mg/kg or clarithromycin 1000 mg/kg is frequently given as three-times-weekly intermittent therapy for NTM noncavitary lung disease [63]. It has been suggested that intermittent therapy is more efficient and reduced toxicity than daily therapy [105]. A cocktail of rifampin 10 mg/kg/day, ethambutol 15 mg/kg/day with either azithromycin 250 mg/kg/day or 1000 mg/kg is given daily for cavitary nodular bronchiectatic NTM lung disease, with a possibility of adding either streptomycin or amikacin in the first 2 or 3 months of therapy in severe disease [63].

The addition of moxifloxacin to the standard treatment showed a better response if a standard treatment plan fails [106]. Clofazimine has shown that it can be an alternative option to the rifampin or in refractory MAC lung infections [107]. The successful treatment of NTM lung infections totally relies on the prevention of macrolide-resistant MAC infections with the optimal treatment strategies.

### 4.2.2. RGM lung infections

The management for RGM lung infections typically depends on drug's toxicity and drug sensitivity tests. Treatment for *M. abscessus* lung infection is challenging as shown in previous studies [108]. The recommended guideline for treating RGM lung infection includes a combination of treatment which involves two parenteral antibiotics and an oral macrolide for a relatively long duration (several months) [63]. The most active and useful parenteral agents consist of amikacin 10–15 mg/kg/day, imipenem 500–1000 mg<sup>2</sup>, cefoxitin 200 mg/kg/day, and tigecycline 50 mg/day [108]. Moxifloxacin has been shown as an alternative option for treating RGM lung infections [109]. Aggressive parenteral therapy is suggested for initial 4 months of treatment accompanied later by a treatment combination of macrolide and linezolid or clofazimine or fluoroquinolone for coping with toxicity [108]. Treatment with macrolides for

RGM infection should be carefully assessed on the patient's tolerance and treatment compliance due to the possibility of drug resistance evolved [110]. Surgical resection should be considered to combine with chemotherapy in treating RGM lung infections [111].

## 5. Conclusion

Etiology and epidemiology of NTM infections highlight that NTMs are emerging pathogens, warranting more research. Clinical features, barriers in the diagnosis of NTM and a lack of more effective treatment strategies were discussed for NTM infections in lung, skin and eye system. This overview prompts comments that can be made for NTM infections for future research. (1) NTM infections are considered emerging pathogens around the world including Singapore. (2) Better understanding of microbial life in real human clinical scenarios is important in dealing with the easy biofilm forming NTMs. (3) More research is critically needed to fill a huge gap of host-pathogen interactions in NTM infections. (4) A Multidisciplinary approach, better diagnostic tools, increase public awareness and standard treatment guidelines and new therapeutic research is urgently required.

## Conflict of interest

TTA, RWB- Nil.

## Notes/thanks/other declarations

The authors would like to acknowledge the Central Tuberculosis Laboratory, Department of Microbiology, Singapore General Hospital, for the contribution of Singapore NTM registry. The authors would like to thank the advices and help from A/Prof. Koh Tse Hsien (Department of Microbiology, Singapore General Hospital), A/Prof. Sng Li-Hwei (Central Tuberculosis Laboratory, Singapore General Hospital), A/Prof. Tan Thuan Tong (Department of Infectious Diseases, Singapore General Hospital), A/Prof. Timothy Mark Sebsatian Barkham (Laboratory Medicine, Tan Tock Seng Hospital) and the support of funding from NMRC/TCR/002-SERI/2012/R1018.

## Author details

Thet Tun Aung<sup>1</sup> and Roger W. Beuerman<sup>1,2,3\*</sup>

\*Address all correspondence to: [rwbeuerman@gmail.com](mailto:rwbeuerman@gmail.com)

1 Singapore Eye Research Institute, Singapore

2 SRP Neuroscience and Behavioral Disorders, Duke-NUS, Singapore

3 Department of Ophthalmology, Yong Loo Lin School of Medicine, National University of Singapore, Singapore

## References

- [1] Ray C, Ryan K, Enteroviruses. In: Ryan KJ, Ray CG, editors. Sherris Medical Microbiology. 4th ed. New York, USA: The McGraw-Hill Companies; 2004. pp. 531-541
- [2] Jarlier V, Nikaido H. Mycobacterial cell wall: Structure and role in natural resistance to antibiotics. FEMS Microbiology Letters. 1994;**123**(1-2):11-18
- [3] Aung TT et al. Biofilms of pathogenic nontuberculous mycobacteria targeted by new therapeutic approaches. Antimicrobial Agents and Chemotherapy. 2016;**60**(1):24-35
- [4] Falkinham Iii J. Surrounded by mycobacteria: Nontuberculous mycobacteria in the human environment. Journal of Applied Microbiology. 2009;**107**(2):356-367
- [5] Von Reyn CF et al. Isolation of *Mycobacterium avium* complex from water in the United States, Finland, Zaire, and Kenya. Journal of Clinical Microbiology. 1993;**31**(12):3227-3230
- [6] Cassidy PM et al. Nontuberculous mycobacterial disease prevalence and risk factors: A changing epidemiology. Clinical Infectious Diseases. 2009;**49**(12):e124-e129
- [7] Winthrop KL et al. Pulmonary nontuberculous mycobacterial disease prevalence and clinical features: An emerging public health disease. American Journal of Respiratory and Critical Care Medicine. 2010;**182**(7):977-982
- [8] Adjemian J et al. Prevalence of nontuberculous mycobacterial lung disease in US Medicare beneficiaries. American Journal of Respiratory and Critical Care Medicine. 2012;**185**(8):881-886
- [9] Horsburgh CR Jr, RM Selik. The epidemiology of disseminated nontuberculous mycobacterial infection in the acquired immunodeficiency syndrome (AIDS). The American Review of Respiratory Disease. 1989;**139**(1):4-7
- [10] O'Brien RJ, Geiter LJ, Snider DE Jr. The epidemiology of nontuberculous mycobacterial diseases in the United States: Results from a national survey. American Review of Respiratory Disease. 1987;**135**(5):1007-1014
- [11] De Groote MA, Huitt G. Infections due to rapidly growing mycobacteria. Clinical Infectious Diseases. 2006;**42**(12):1756-1763
- [12] Billinger ME et al. Nontuberculous mycobacteria-associated lung disease in hospitalized persons, United States, 1998-2005. Emerging Infectious Diseases. 2009;**15**(10):1562
- [13] Drage LA et al. An outbreak of *Mycobacterium chelonae* infections in tattoos. Journal of the American Academy of Dermatology. 2010;**62**(3):501-506
- [14] Khair WJ et al. Nontuberculous mycobacterial ocular infections: A systematic review of the literature. BioMed Research International. 2015;**2015**:17
- [15] Winthrop KL et al. Pulmonary disease associated with nontuberculous mycobacteria, Oregon, USA. Emerging Infectious Diseases. 2011;**17**(9):1760
- [16] Maekawa K et al. Environmental risk factors for pulmonary *Mycobacterium avium*-intracellular complex disease. Chest. 2011;**140**(3):723-729

- [17] Falkinham JO et al. *Mycobacterium avium* in a shower linked to pulmonary disease. *Journal of Water and Health*. 2008;**6**(2):209-213
- [18] Falkinham JO. Factors influencing the chlorine susceptibility of *Mycobacterium avium*, *Mycobacterium intracellulare*, and *Mycobacterium scrofulaceum*. *Applied and Environmental Microbiology*. 2003;**69**(9):5685-5689
- [19] Mandel AS et al. State regulation of hospital water temperature. *Infection Control & Hospital Epidemiology*. 1993;**14**(11):642-645
- [20] Uslan DZ et al. Skin and soft tissue infections due to rapidly growing mycobacteria: Comparison of clinical features, treatment, and susceptibility. *Archives of Dermatology*. 2006;**142**(10):1287-1292
- [21] Carson LA et al. Prevalence of nontuberculous mycobacteria in water supplies of hemodialysis centers. *Applied and Environmental Microbiology*. 1988;**54**(12):3122-3125
- [22] Le Dantec C et al. Occurrence of mycobacteria in water treatment lines and in water distribution systems. *Applied and Environmental Microbiology*. 2002;**68**(11):5318-5325
- [23] Runyon EH. Identification of mycobacterial pathogens utilizing colony characteristics. *American Journal of Clinical Pathology*. 1970;**54**(4):578-586
- [24] Murray P, Barron E, Pfaller M. *Mycobacterium*: General characteristics, isolation, and staining procedures. In: *Manual of Clinical Microbiology*. Washington DC: American Society for Microbiology; 2003
- [25] Brown-Elliott BA, Wallace RJ. Clinical and taxonomic status of pathogenic nonpigmented or late-pigmenting rapidly growing mycobacteria. *Clinical Microbiology Reviews*. 2002;**15**(4):716-746
- [26] Moorthy RS, Valluri S, Rao NA. Nontuberculous mycobacterial ocular and adnexal infections. *Survey of Ophthalmology*. 2012;**57**(3):202-235
- [27] Pfyffer GE, Palicova F. *Mycobacterium*: General characteristics, laboratory detection, and staining procedures. In: *Manual of Clinical Microbiology*. 10th ed. Washington DC, USA: American Society of Microbiology; 2011. pp. 472-502
- [28] Somoskovi A, Salfinger M. Nontuberculous mycobacteria in respiratory infections: Advances in diagnosis and identification. *Clinics in Laboratory Medicine*. 2014;**34**(2): 271-295
- [29] Butler WR, Guthertz LS. Mycolic acid analysis by high-performance liquid chromatography for identification of *Mycobacterium* species. *Clinical Microbiology Reviews*. 2001;**14**(4):704-726
- [30] Somoskövi Á et al. False-positive results for *Mycobacterium celatum* with the AccuProbe *Mycobacterium tuberculosis* complex assay. *Journal of Clinical Microbiology*. 2000;**38**(7): 2743-2745

- [31] Hall L et al. Evaluation of the micro Seq system for identification of mycobacteria by 16S ribosomal DNA sequencing and its integration into a routine clinical mycobacteriology laboratory. *Journal of Clinical Microbiology*. 2003;**41**(4):1447-1453
- [32] Somoskovi A et al. Laboratory diagnosis of nontuberculous mycobacteria. *Clinics in Chest Medicine*. 2002;**23**(3):585-597
- [33] Boltin D et al. *Corynebacterium striatum*—A classic pathogen eluding diagnosis. *European Journal of Internal Medicine*. 2009;**20**(3):e49-e52
- [34] Williamson JC et al. Fatal *Mycobacterium abscessus* endocarditis misidentified as *Corynebacterium* spp. *Scandinavian Journal of Infectious Diseases*. 2010;**42**(3):222-224
- [35] Paul J, Baigrie C, Parums D. Fatal case of disseminated infection with the turtle bacillus *Mycobacterium chelonae*. *Journal of Clinical Pathology*. 1992;**45**(6):528-530
- [36] Tang SS et al. Rapidly growing mycobacteria in Singapore, 2006-2011. *Clinical Microbiology and Infection*. 2015;**21**(3):236-241
- [37] Wang H, Jin P, Wu Q. Disseminated cutaneous infection with *Mycobacterium abscessus* in a patient with a low CD4+ T cell count. *European Journal of Dermatology*. 2008;**18**(3):337-340
- [38] Taylor JL, Palmer SM. *Mycobacterium abscessus* chest wall and pulmonary infection in a cystic fibrosis lung transplant recipient. *The Journal of Heart and Lung Transplantation*. 2006;**25**(8):985-988
- [39] Lee M-R et al. *Mycobacterium abscessus* complex infections in humans. *Emerging Infectious Diseases*. 2015;**21**(9):1638
- [40] Ferringer T, Pride H, Tyler W. Body piercing complicated by atypical mycobacterial infections. *Pediatric Dermatology*. 2008;**25**(2):219-222
- [41] Kothavade R et al. Clinical and laboratory aspects of the diagnosis and management of cutaneous and subcutaneous infections caused by rapidly growing mycobacteria. *European Journal of Clinical Microbiology & Infectious Diseases*. 2013;**32**(2):161-188
- [42] Appelgren P et al. Late-onset posttraumatic skin and soft-tissue infections caused by rapid-growing mycobacteria in tsunami survivors. *Clinical Infectious Diseases*. 2008;**47**(2):e11-e16
- [43] TAZAWA S et al. *Mycobacterium fortuitum* infection caused by the organism in subcutaneous abscess mediated by central venous catheter. *Kekkaku (Tuberculosis)*. 2006;**81**(10):609-612
- [44] Zainal MA, Tan A. *Mycobacterium fortuitum* catheter-related sepsis in acute leukaemia. *Singapore Medical Journal*. 2006;**47**(6):543
- [45] Winthrop KL et al. The clinical management and outcome of nail salon—Acquired *Mycobacterium fortuitum* skin infection. *Clinical Infectious Diseases*. 2004;**38**(1):38-44

- [46] Winthrop KL et al. An outbreak of mycobacterial furunculosis associated with footbaths at a nail salon. *New England Journal of Medicine*. 2002;**346**(18):1366-1371
- [47] Quiñones C et al. An outbreak of *Mycobacterium fortuitum* cutaneous infection associated with mesotherapy. *Journal of the European Academy of Dermatology and Venereology*. 2010;**24**(5):604-606
- [48] Ronald Buckley L et al. *Mycobacterium fortuitum* infection occurring after a punch biopsy procedure. *Pediatric Dermatology*. 1997;**14**(4):290-292
- [49] Nolan CM, Hashisaki PA, Dundas DF. An outbreak of soft-tissue infections due to *Mycobacterium fortuitum* associated with electromyography. *Journal of Infectious Diseases*. 1991;**163**(5):1150-1153
- [50] Ferreira O et al. A cutaneous infection by *Mycobacterium chelonae* in a patient with rheumatoid arthritis. *Dermatology Online Journal*. 2010;**16**(4):3-3
- [51] Kullavanijaya P et al. Disseminated *Mycobacterium chelonae* cutaneous infection: Recalcitrant to combined antibiotic therapy. *The Journal of Dermatology*. 2003;**30**(6):485-491
- [52] Patel JB et al. Sequence-based identification of *Mycobacterium* species using the Microseq 500 16S rDNA bacterial identification system. *Journal of Clinical Microbiology*. 2000;**38**(1):246-251
- [53] Drouineau O et al. Infection cutanée à *Mycobacterium chelonae* en hémodialyse. *Néphrologie & Thérapeutique*. 2006;**2**(3):136-139
- [54] Adenis-Lamarre E et al. Cutaneous infection due to *Mycobacterium chelonae* during anti-TNF therapy. 2009;**136**(11):811-814
- [55] Jankovic M et al. A fatal *Mycobacterium chelonae* infection in an immunosuppressed patient with systemic lupus erythematosus and concomitant Fahr's syndrome. *Journal of Infection and Chemotherapy*. 2011;**17**(2):264-267
- [56] Haas SR, Hodge MB, Duncan RA. Cushing's syndrome presenting as disseminated cutaneous *Mycobacterium chelonae* infection. *Clinical Infectious Diseases*. 2001;**33**(6):e51-e53
- [57] Nash KA, Brown-Elliott BA, Wallace RJ. A novel gene, *erm* (41), confers inducible macrolide resistance to clinical isolates of *Mycobacterium abscessus* but is absent from *Mycobacterium chelonae*. *Antimicrobial Agents and Chemotherapy*. 2009;**53**(4):1367-1376
- [58] Colombo RE, Olivier KN. Diagnosis and treatment of infections caused by rapidly growing mycobacteria. In: *Seminars in Respiratory and Critical Care Medicine*. New York, USA: Thieme Medical Publishers; 2008
- [59] Wallace RJ et al. Comparison of the in vitro activity of the glycylicycline tigecycline (formerly GAR-936) with those of tetracycline, minocycline, and doxycycline against isolates of nontuberculous mycobacteria. *Antimicrobial Agents and Chemotherapy*. 2002;**46**(10):3164-3167

- [60] Petrini B. *Mycobacterium abscessus*: An emerging rapid-growing potential pathogen. APMIS. 2006;**114**(5):319-328
- [61] Brown B et al. Activities of four macrolides, including clarithromycin, against *Mycobacterium fortuitum*, *Mycobacterium chelonae*, and *M. chelonae*-like organisms. Antimicrobial Agents and Chemotherapy. 1992;**36**(1):180-184
- [62] Swenson JM et al. Antimicrobial susceptibility of five subgroups of *Mycobacterium fortuitum* and *Mycobacterium chelonae*. Antimicrobial Agents and Chemotherapy. 1985;**28**(6):807-811
- [63] Griffith DE et al. An official ATS/IDSA statement: Diagnosis, treatment, and prevention of nontuberculous mycobacterial diseases. American Journal of Respiratory and Critical Care Medicine. 2007;**175**(4):367-416
- [64] Chang C-Y et al. Venous catheter-associated bacteremia caused by rapidly growing mycobacteria at a medical center in Central Taiwan. Journal of Microbiology, Immunology, and Infection = Wei mian yu gan ran za zhi. 2009;**42**(4):343-350
- [65] Srivastava BK et al. Oxazolidinone antibacterials and our experience. Anti-Infective Agents in Medicinal Chemistry (Formerly Current Medicinal Chemistry-Anti-Infective Agents). 2008;**7**(4):258-280
- [66] Girard D et al. Comparison of azithromycin, roxithromycin, and cephalexin penetration kinetics in early and mature abscesses. Journal of Antimicrobial Chemotherapy. 1993;**31**(suppl\_E):17-28
- [67] da Costa ARF et al. Molecular identification of rapidly growing mycobacteria isolates from pulmonary specimens of patients in the State of Pará, Amazon region, Brazil. Diagnostic Microbiology and Infectious Disease. 2009;**65**(4):358-364
- [68] Shen G-H et al. High efficacy of clofazimine and its synergistic effect with amikacin against rapidly growing mycobacteria. International Journal of Antimicrobial Agents. 2010;**35**(4):400-404
- [69] Chopra S et al. Identification of antimicrobial activity among FDA-approved drugs for combating *Mycobacterium abscessus* and *Mycobacterium chelonae*. Journal of Antimicrobial Chemotherapy. 2011;**66**(7):1533-1536
- [70] Regnier S et al. Clinical management of rapidly growing mycobacterial cutaneous infections in patients after mesotherapy. Clinical Infectious Diseases. 2009;**49**(9):1358-1364
- [71] Tebas P et al. Rapid development of resistance to clarithromycin following monotherapy for disseminated *Mycobacterium chelonae* infection in a heart transplant patient. Clinical Infectious Diseases. 1995;**20**(2):443-444
- [72] Girgis DO, Karp CL, Miller D. Ocular infections caused by non-tuberculous mycobacteria: Update on epidemiology and management. Clinical & Experimental Ophthalmology. 2012;**40**(5):467-475

- [73] Turner L, Stinson I. *Mycobacterium fortuitum*: As a cause of corneal ulcer. American Journal of Ophthalmology. 1965;**60**(2):329-331
- [74] Huang S et al. Non-tuberculous mycobacterial keratitis: A study of 22 cases. British Journal of Ophthalmology. 1996;**80**(11):962-968
- [75] Lalitha P, Rathinam S, Srinivasan M. Ocular infections due to non-tuberculous mycobacteria. Indian Journal of Medical Microbiology. 2004;**22**(4):231
- [76] Hu F-R, Huang W-J, Huang S-F. Clinicopathologic study of satellite lesions in nontuberculous mycobacterial keratitis. Japanese Journal of Ophthalmology. 1998;**42**(2):115-118
- [77] Lazar M et al. *Mycobacterium fortuitum* keratitis. American Journal of Ophthalmology. 1974;**78**(3):530-532
- [78] Brancato R et al. *Mycobacterium chelonae* keratitis after excimer laser photorefractive keratectomy. Archives of Ophthalmology. 1997;**115**(10):1316-1318
- [79] Hu F-R. Infectious crystalline keratopathy caused by *Mycobacterium fortuitum* and *Pseudomonas aeruginosa*. American Journal of Ophthalmology. 1990;**109**(6):738-739
- [80] Dugel PU et al. *Mycobacterium fortuitum* keratitis. American Journal of Ophthalmology. 1988;**105**(6):661-669
- [81] Alvarenga L et al. Infectious post-LASIK crystalline keratopathy caused by nontuberculous mycobacteria. Cornea. 2002;**21**(4):426-429
- [82] Chang MA, Jain S, Azar DT. Infections following laser in situ keratomileusis: An integration of the published literature. Survey of Ophthalmology. 2004;**49**(3):269-280
- [83] Wunsh SE et al. *Mycobacterium fortuitum* infection of corneal graft. Archives of Ophthalmology. 1969;**82**(5):602-607
- [84] Abshire R et al. Topical antibacterial therapy for mycobacterial keratitis: Potential for surgical prophylaxis and treatment. Clinical Therapeutics. 2004;**26**(2):191-196
- [85] de la Cruz J, Behlau I, Pineda R. Atypical mycobacteria keratitis after laser in situ keratomileusis unresponsive to fourth-generation fluoroquinolone therapy. Journal of Cataract & Refractive Surgery. 2007;**33**(7):1318-1321
- [86] Ford JG et al. Nontuberculous mycobacterial keratitis in South Florida. Ophthalmology. 1998;**105**(9):1652-1658
- [87] Alexandrakis G, Alfonso EC, Miller D. Shifting trends in bacterial keratitis in South Florida and emerging resistance to fluoroquinolones. Ophthalmology. 2000;**107**(8):1497-1502
- [88] Aung TT et al. Discovery of novel antimycobacterial drug therapy in biofilm of pathogenic nontuberculous mycobacterial keratitis. The Ocular Surface. 2017;**15**:770-783
- [89] Aylward G, Stacey A, Marsh R. *Mycobacterium chelonae* infection of a corneal graft. British Journal of Ophthalmology. 1987;**71**(9):690-693

- [90] Kwon YS, Koh W-J. Diagnosis of pulmonary tuberculosis and nontuberculous mycobacterial lung disease in Korea. *Tuberculosis and Respiratory Diseases*. 2014;**77**(1):1-5
- [91] Koh W et al. Pulmonary TB and NTM lung disease: Comparison of characteristics in patients with AFB smear-positive sputum. *The International Journal of Tuberculosis and Lung Disease*. 2006;**10**(9):1001-1007
- [92] Jeong YJ et al. Nontuberculous mycobacterial pulmonary infection in immunocompetent patients: Comparison of thin-section CT and histopathologic findings. *Radiology*. 2004;**231**(3):880-886
- [93] Marras TK et al. Opinions differ by expertise in *Mycobacterium avium* complex disease. *Annals of the American Thoracic Society*. 2014;**11**(1):17-22
- [94] Yuan M-K et al. Comparative chest computed tomography findings of non-tuberculous mycobacterial lung diseases and pulmonary tuberculosis in patients with acid fast bacilli smear-positive sputum. *BMC Pulmonary Medicine*. 2014;**14**(1):65
- [95] Chu H et al. Chest imaging comparison between non-tuberculous and tuberculosis mycobacteria in sputum acid fast bacilli smear-positive patients. *European Review for Medical and Pharmacological Sciences*. 2015;**19**(13):2429-2439
- [96] Koh W-J et al. Bilateral bronchiectasis and bronchiolitis at thin-section CT: Diagnostic implications in nontuberculous mycobacterial pulmonary infection. *Radiology*. 2005;**235**(1):282-288
- [97] Kim RD et al. Pulmonary nontuberculous mycobacterial disease: Prospective study of a distinct preexisting syndrome. *American Journal of Respiratory and Critical Care Medicine*. 2008;**178**(10):1066-1074
- [98] Park IK, Olivier KN. Nontuberculous mycobacteria in cystic fibrosis and non-cystic fibrosis bronchiectasis. In: *Seminars in Respiratory and Critical Care Medicine*. New York, USA: Thieme Medical Publishers; 2015
- [99] Horsburgh CR Jr. Epidemiology of disease caused by nontuberculous mycobacteria. 1996;**11**(4):244-251
- [100] Olivier KN et al. Nontuberculous mycobacteria: I: Multicenter prevalence study in cystic fibrosis. *American Journal of Respiratory and Critical Care Medicine*. 2003;**167**(6): 828-834
- [101] Dorman SE, Holland SM. Interferon- $\gamma$  and interleukin-12 pathway defects and human disease. *Cytokine & Growth Factor Reviews*. 2000;**11**(4):321-333
- [102] Winthrop KL et al. Nontuberculous mycobacteria infections and anti-tumor necrosis factor- $\alpha$  therapy. *Emerging Infectious Diseases*. 2009;**15**(10):1556
- [103] Winthrop K et al. Mycobacterial diseases and antitumour necrosis factor therapy in USA. *Annals of the Rheumatic Diseases*. 2013;**72**(1):37-42

- [104] Egelund EF, Fennelly KP, Peloquin CA. Medications and monitoring in nontuberculous mycobacteria infections. *Clinics in Chest Medicine*. 2015;**36**(1):55-66
- [105] Wallace RJ et al. Macrolide/azalide therapy for nodular/bronchiectatic *Mycobacterium avium* complex lung disease. *Chest*. 2014;**146**(2):276-282
- [106] Koh W-J et al. Treatment of refractory *Mycobacterium avium* complex lung disease with a moxifloxacin-containing regimen. *Antimicrobial Agents and Chemotherapy*. 2013; **57**(5):2281-2285
- [107] Jarand J et al. Long-term follow-up of *Mycobacterium avium* complex lung disease in patients treated with regimens including clofazimine and/or rifampin. *Chest*. 2016;**149**(5): 1285-1293
- [108] Kasperbauer SH, De Groote MA. The treatment of rapidly growing mycobacterial infections. *Clinics in Chest Medicine*. 2015;**36**(1):67-78
- [109] Kim SY et al. The drug susceptibility profile and inducible resistance to macrolides of *Mycobacterium abscessus* and *Mycobacterium massiliense* in Korea. *Diagnostic Microbiology and Infectious Disease*. 2015;**81**(2):107-111
- [110] Choi G-E et al. Macrolide treatment for *Mycobacterium abscessus* and *Mycobacterium massiliense* infection and inducible resistance. *American Journal of Respiratory and Critical Care Medicine*. 2012;**186**(9):917-925
- [111] Jarand J et al. Clinical and microbiologic outcomes in patients receiving treatment for *Mycobacterium abscessus* pulmonary disease. *Clinical Infectious Diseases*. 2011;**52**(5): 565-571
- [112] Woods G et al. Susceptibility Testing of Mycobacteria, Nocardiae, and Other Aerobic Actinomycetes; Approved Standard M24-A. Vol. 23, No. 18. Wayne, PA: NCCLS; 2003. pp. 1-56238
- [113] Cavusoglu C, Gulpinar T, Ecemis T. Evaluation of antimicrobial susceptibilities of rapidly growing mycobacteria by Sensititre RAPMYCO panel. *New Microbiologica*. 2012;**35**(1): 73-76