

We are IntechOpen, the world's leading publisher of Open Access books Built by scientists, for scientists

6,900

Open access books available

186,000

International authors and editors

200M

Downloads

Our authors are among the

154

Countries delivered to

TOP 1%

most cited scientists

12.2%

Contributors from top 500 universities



WEB OF SCIENCE™

Selection of our books indexed in the Book Citation Index
in Web of Science™ Core Collection (BKCI)

Interested in publishing with us?
Contact book.department@intechopen.com

Numbers displayed above are based on latest data collected.
For more information visit www.intechopen.com



Optical Coherence Tomography: Essential Tool in Macular Hole Management

Sana I. Tinwala

Additional information is available at the end of the chapter

<http://dx.doi.org/10.5772/intechopen.79279>

Abstract

Optical coherence tomography (OCT) is a noninvasive, diagnostic technique for accurately identifying and quantitatively characterizing macular holes. OCT is crucial in assessing fellow eyes of patients with a macular hole to detect preclinical changes leading to subsequent hole formation. The tomographic information provided by OCT, akin to an *in vivo* biopsy, has led to a better understanding of the pathogenesis of hole formation. The cross-sectional view produced by OCT effectively distinguishes full-thickness macular holes from mimicking conditions like lamellar holes, macular pseudoholes, and cysts, which may sometimes be difficult to differentiate clinically. This information enables early diagnosis and can guide the intervention of choice when treatment is deemed necessary. OCT is useful to prognosticate cases, thereby facilitating discussions with patients and managing visual expectations preoperatively. Intraoperative OCT (iOCT) can identify intraoperative changes in the macular anatomy during surgery that can influence functional outcomes. Postoperatively, OCT is extremely useful for documenting serial changes in the foveal architecture and is helpful in correlating functional and anatomic outcomes. As the technology continues to improve, OCT has become indispensable for all aspects of patient care for macular holes.

Keywords: OCT, macular hole, diagnosis, management, prognosis

1. Introduction

Optical coherence tomography (OCT) was developed by David Huang and colleagues at the Massachusetts Institute of Technology (MIT) [1]. Prior to its development, clinical biomicroscopic examination using the slit lamp was the mainstay for retinal structural assessment.

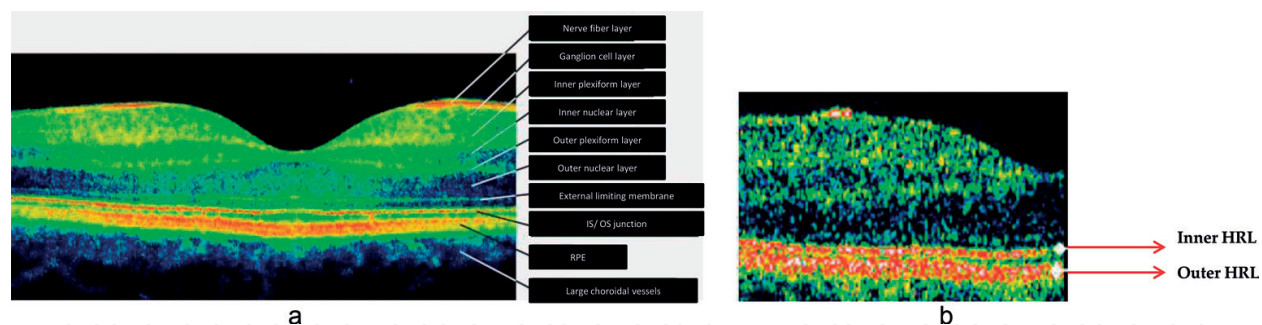


Figure 1. (a) Layers of retina. (b) The inner HRL (corresponding to the photoreceptors IS/OS junction) is thinner than the outer, which corresponds to a hyper-reflective normal complex formed by RPE and choriocapillaris.

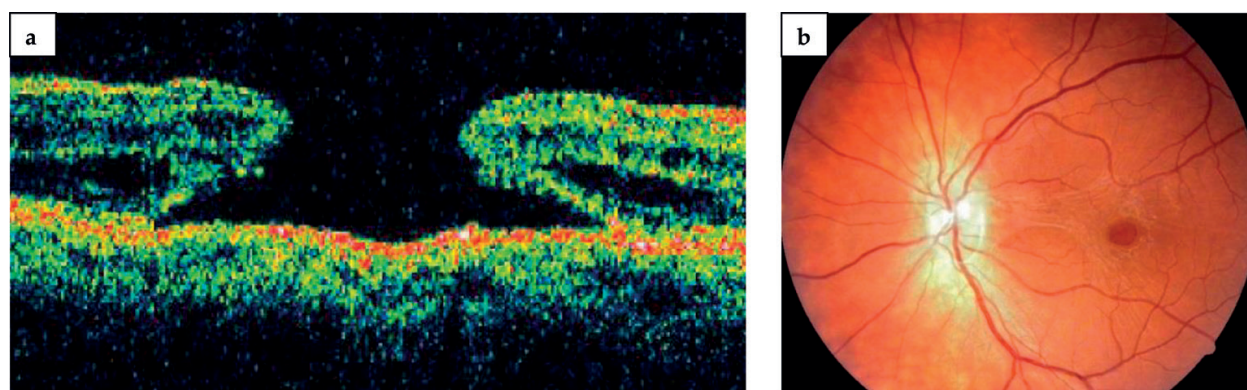


Figure 2. Full thickness macular hole (a) OCT cross sectional image; (b) color fundus photograph).

OCT is based on the imaging of reflected light. In addition to measuring transverse dimensions, it also resolves depth. OCT is akin to noninvasive tissue “biopsy”—it provides in vivo cross-sectional views (tomography) of internal tissue structures similar to tissue sections under a microscope [2, 3]. The depth resolution of OCT is typically of the order of 0.4 thousandth of an inch.

A macular hole is defined as a full-thickness defect of retinal tissue involving the anatomic fovea and primarily the foveola of the eye (**Figures 1a, b and 2**). Since its development, OCT is the gold standard in the diagnosis and management of this condition. The high-resolution imaging on OCT allows cross-sectional and three-dimensional evaluation of the macula, thereby providing far greater details than what can be discerned clinically. It is helpful in detecting subtle early MHs as well as staging the more obvious and larger ones. OCT is now used to guide management of macular holes based on various parameters, as highlighted in the subsequent sections.

2. Classification of macular holes and OCT

Evolution of macular hole and *clinical appearance* of the different stages of its development has been described by Gass [4, 5]. The earliest stage is an impending hole, characterized by a

yellow spot (stage 1a) or a yellow ring (stage 1b) at the fovea [4, 5]. Stage 1 macular holes are difficult to diagnose by slit lamp biomicroscopic examination alone, leading to a lot of subjective variation in diagnosis [6].

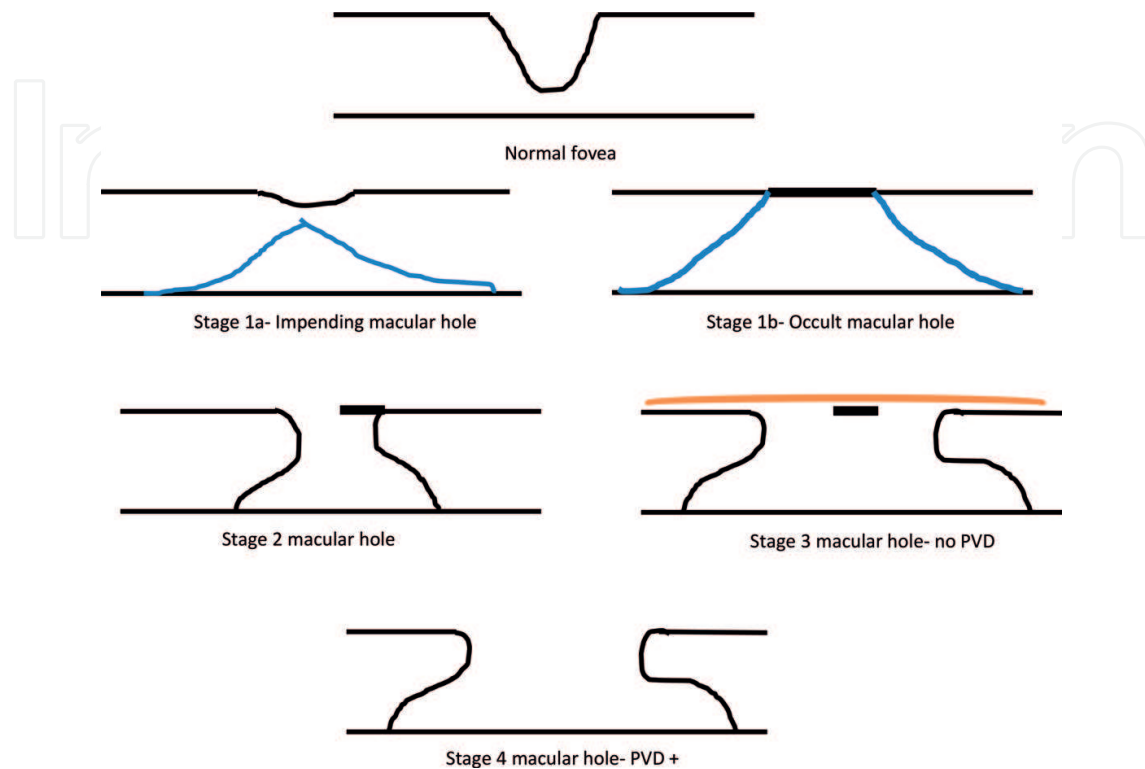


Figure 3. Grading scheme proposed and revised by Gass.

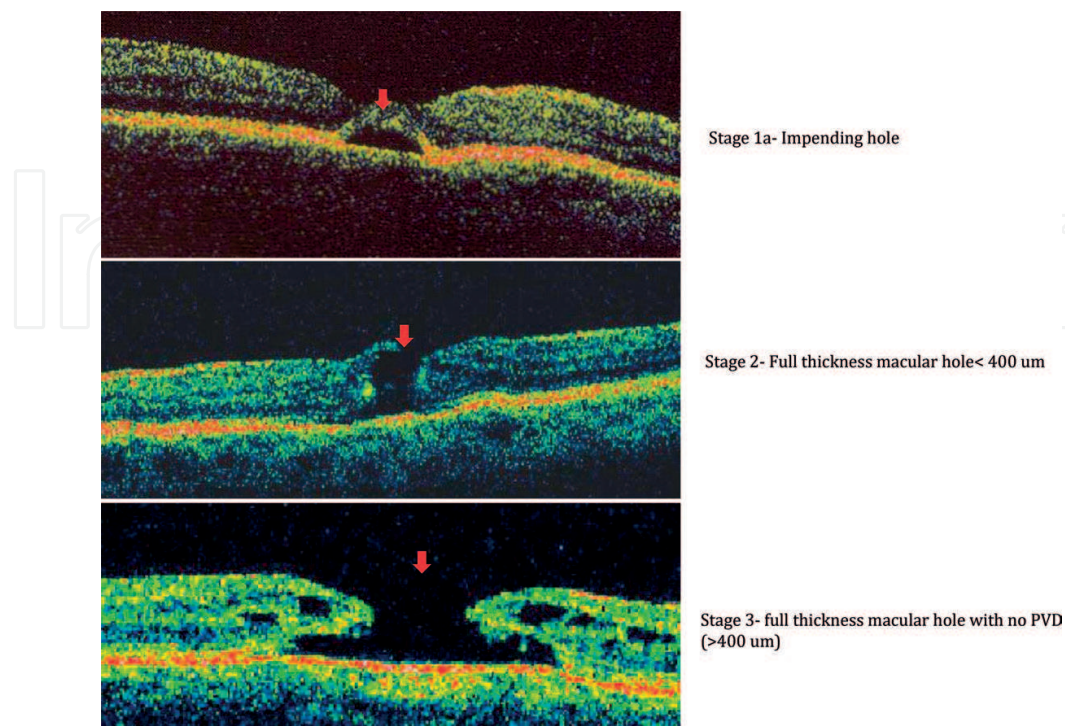


Figure 4. Stages of macular hole on OCT.

Since its introduction, OCT has been an extremely useful tool for diagnosing and staging macular holes. On OCT, a stage 1 hole appears as a cystic lesion in the inner layers of the retina (**Figure 3**) [7, 8]. *Stage 2* macular holes present as a *full-thickness defect at the fovea* (size < 400 μm in diameter). *Stage 3* macular hole is a completely evolved hole (size > 400 μm in diameter). In some patients, a small operculum can be seen suspended in front of the lesion. *Stage 4* macular holes appear similar to stage 3 holes except that in stage 4 holes there is *complete posterior vitreous detachment*, as frequently evidenced by a visible Weiss ring.

Hee et al. first described the use of OCT in diagnosing and monitoring macular holes [9]. Gaudric et al. later described the sequence of events in the evolution of macular holes using OCT—from anteroposterior vitreofoveal traction to full-thickness macular hole formation (**Figure 4**) [7].

3. Aiding early differential diagnosis

Diagnosing early macular hole lesions and differentiating them from other mimicking conditions are the clinical challenges in the management of macular holes. Fluorescein angiography (FA) was the earlier imaging modality of choice to identify macular holes. Although useful in characterizing full-thickness holes, this test does not help in identifying stage 1 macular holes, which are the source of clinical dilemma. The purpose of FA was largely to demonstrate other biomicroscopically similar lesions that have classic angiographic features (e.g., choroidal neovascular membranes), thereby excluding the diagnosis of macular hole.

Optical coherence tomography, as compared to FA, provides noninvasive diagnostic imaging helping early and accurate diagnosis. At the same time, it rules out other mimicking conditions, allowing the clinician to distinguish these from pseudohole and prehole conditions in almost all instances (**Figure 5**). It has been useful in demonstrating the sequence of events leading to macular hole formation over time and has thus increased our understanding of the anatomic relations in macular holes [9–11].

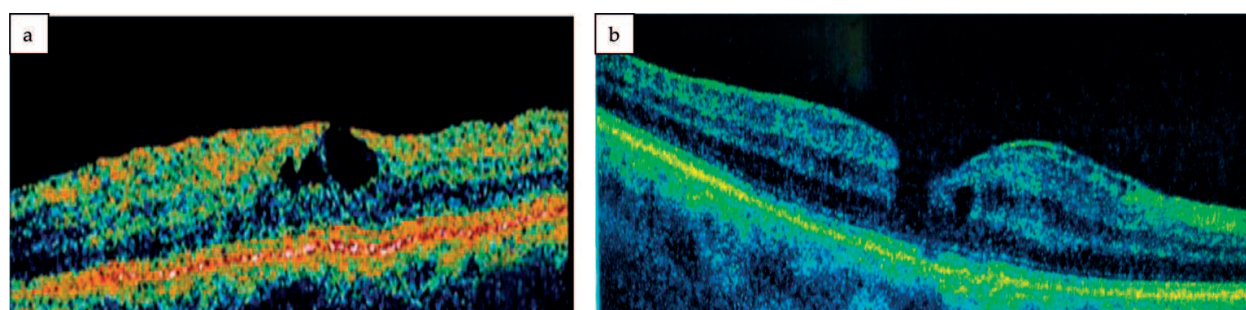


Figure 5. (a) Lamellar macular hole; (b) pseudohole.

4. Preoperative role-OCT factors

Apart from a major role in diagnosis, *preoperative OCT is an important tool for counseling patients* regarding postoperative prognosis on the basis of various OCT-based measurements (**Figure 6a–d**).

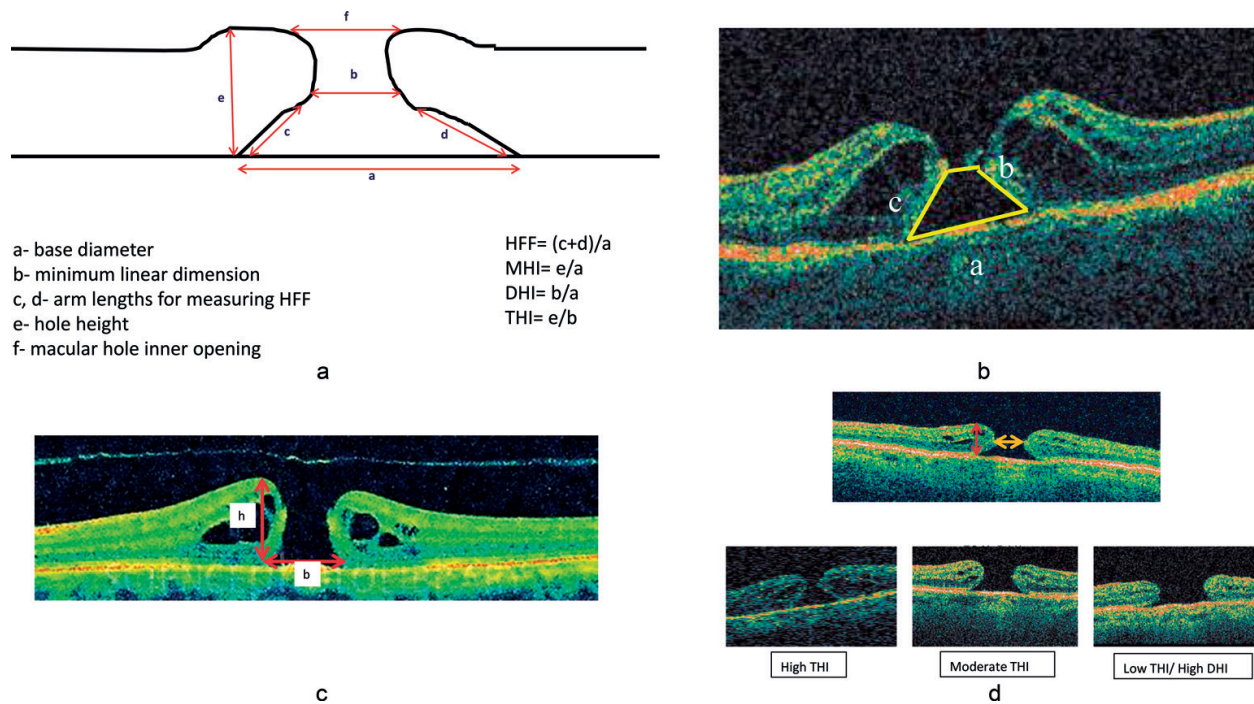


Figure 6. (a) Schematic representation of OCT factors; (b) $HFF = (b + c)/a$; (c) $MHI = \text{height/base } (h/b)$; (d) Tractional hole index.

a. Hole form factor (HFF)

- It is the ratio of left arm length and right arm length to the base diameter of macular hole [10].
- In a study by Ullrich et al., it was observed that if **HFF was greater than 0.9**, the macular hole closed following a single surgical procedure, whereas if **HFF was less than 0.5**, anatomical success was achieved in 67% cases. Also, **higher HFF** preoperatively was associated with **better postoperative functional outcomes**. The base or minimum diameters were independent of the duration of the symptoms [12].

b. Macular hole index (MHI)

- It is the ratio of hole height to base diameter (ratio of perpendicular and horizontal dimensions of the hole). It can be calculated from OCT transverse images of the macular area.
- The MHI represents the **preoperative configuration** of a macular hole and is a prognostic factor for visual outcome. It was suggested that **MHI value of ≥ 0.5** could be used to predict better postoperative outcomes [13].

4.1. Clinical significance

In a study of large macular holes (low MHI macular holes) by Kumar et al. [14], preoperative screening for low MHI macular holes was done using spectral domain OCT. In view of large base diameters and low MHI, an additional maneuver was incorporated during surgery— intraoperative tapping of macular hole edges in all quadrants from the inner side. This leads to an in situ increase in perpendicular height of the macular hole compared with the base

diameter, thus translating to an intraoperative increase in MHI and facilitating hole closure. This was done along with other surgical modifications including a large arcade to arcade ILM peel and removing any ERM associated with it. An improvement in the postoperative visual outcome was observed with large macular holes with MHI as low as 0.25.

Thus, OCT not only facilitates an accurate diagnosis, but preoperative surgical planning based on OCT factors also helps in improving anatomic and functional prognosis.

Another surgical technique proposed for large macular holes, to improve anatomic and functional outcomes of surgery by *preventing postoperative flat-open configuration* of macular holes, is the inverted ILM flap technique [15]. In this technique, after core vitrectomy and dye staining, the ILM is not completely removed from the retina but is left in place, attached to the edges of the MH. This ILM remnant is then inverted to cover and fill the MH (**Figure 7**).

The rationale for tissue repair that occurs following the use of this technique is: the inverted ILM, containing Muller cell fragments, induces glial cell proliferation, resulting in the macular hole filling with proliferating cells that enhance closure. It also works as a scaffold for tissue proliferation, creating a microenvironment that encourages correct photoreceptor alignment. This allows a near-perfect anatomic restoration, *with OCT demonstrating restoration of normal foveal architecture*. Hence, this technique results in better postoperative anatomic and functional outcome.

Also, because ILM is a basement membrane, it allows glial cell proliferation, allowing large MHs to fill with tissue over time further expanding its use to repeat MH surgery [16].

c. Diameter hole index (DHI)

- It is the ratio of minimum diameter of MH to base diameter and is an indicator of extent of tangential traction.

d. Tractional hole index (THI)

- It is the ratio of maximal height of MH to minimum diameter and is an indicator of AP traction and retinal hydration.

Patients with higher THI values (>1.41) and low DHI values (<0.50) had the best post-op VA recovery [17].

As an increasing number of surgeons opt for ILM peeling to facilitate hole closure, vital dyes have become useful tools for the membrane and ensuring its complete removal [18]. Also, mixtures of dyes with high-density dextrose or polyethylene glycol (PEG) solution have improved the staining of the macula [19]. These high-density solutions when combined with the dye promote immediate settling of the dye onto the macula and minimize its dispersion throughout the vitreous cavity.

With the availability of several dyes and formulations, concerns regarding chemical or phototoxicity are always expressed. Hence, the need to develop new methods to enhance the visualization of the ILM. One example is the use of intraoperative optical coherence tomography (iOCT), which has the potential to visualize the ILM during vitrectomy with immediate surgical feedback.

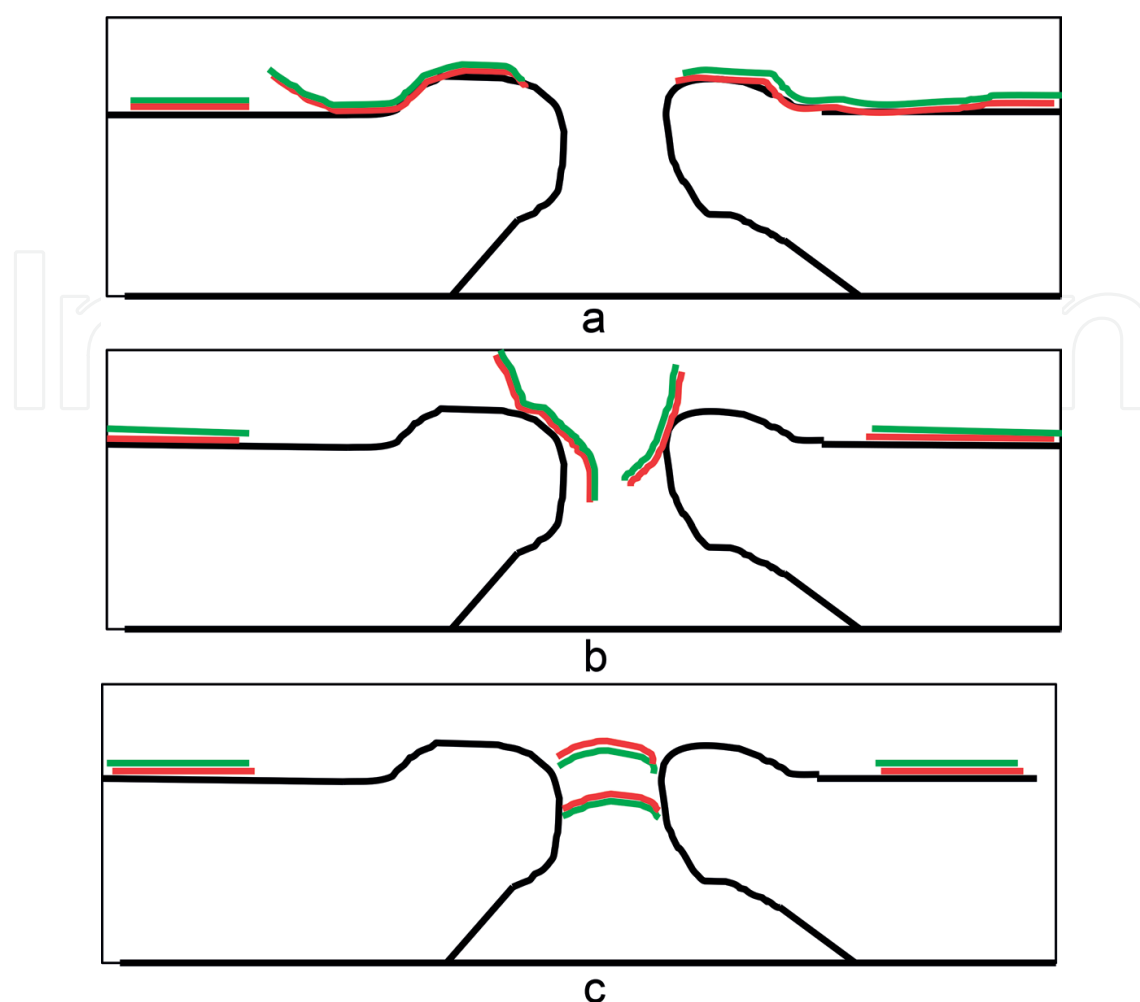


Figure 7. Line diagram demonstrating inverted ILM flap technique. (a) The surface of the ILM facing the hyaloid is depicted in green and the surface facing the retinal surface is depicted in red. (b) Trimming of the peripheral part of the ILM. (c) Inverting the central ILM flap over the macular hole. Now the surface of the ILM depicted in red faces the hyaloid and the green surface is toward the RPE—thus “inverted”.

5. Intraoperative OCT (iOCT)

OCT is fundamental to our clinical decision-making for management of macular holes. It has now been incorporated as intraoperative OCT (iOCT)—supplementing surgical assessments in the operating room and guiding surgical decisions.

Intraoperative OCT consists of spectral domain optical coherence tomography (SD-OCT) on an OCT-mounted surgical microscope. It identifies intraoperative changes in the macular anatomy and provides additional information to predict visual outcomes of macular surgery. The SD-OCT scan taken immediately after ERM removal identifies a cleavage plane for the subsequent ILM peeling, allowing an accurate ILM peel causing minimum disruption of retinal architecture [20].

Intraoperative OCT has been described in several types of retinal surgeries, including vitrectomy for the macular hole. During membrane peeling, the surgeon’s impression of membrane

peel completeness conflicted with iOCT data in 19% of cases (e.g., iOCT displayed a persistent occult residual membrane or showed lack of residual membrane). For posterior segment surgery, it has been reported that the use of iOCT provided valuable feedback in 71% (97 of 136) of cases.

The use of iOCT, being in its early stages, has certain limitations—real-time membrane peeling using metallic instruments creates absolute shadowing. Despite this drawback, it is still useful in visualizing tissue-instrument interactions, revealing residual membranes, and confirming completion of surgical objectives in macular surgery [21, 22].

This new modality will help improve anatomic and visual outcomes by helping the surgeon ensure completeness of surgical intervention and at the same time minimizing tissue manipulation.

6. Post-op role of OCT: anatomic versus functional success

a. Photoreceptor inner/outer segment junction

- IS/OS junction is seen as the bright band proximal to the RPE. It is an indicator of photoreceptor alignment.
- Grade 0: IS/OS junction absent under the fovea.

Grade 1: IS/OS junction present under the fovea (abnormal).

Grade 2: IS/OS junction present under the fovea (normal).

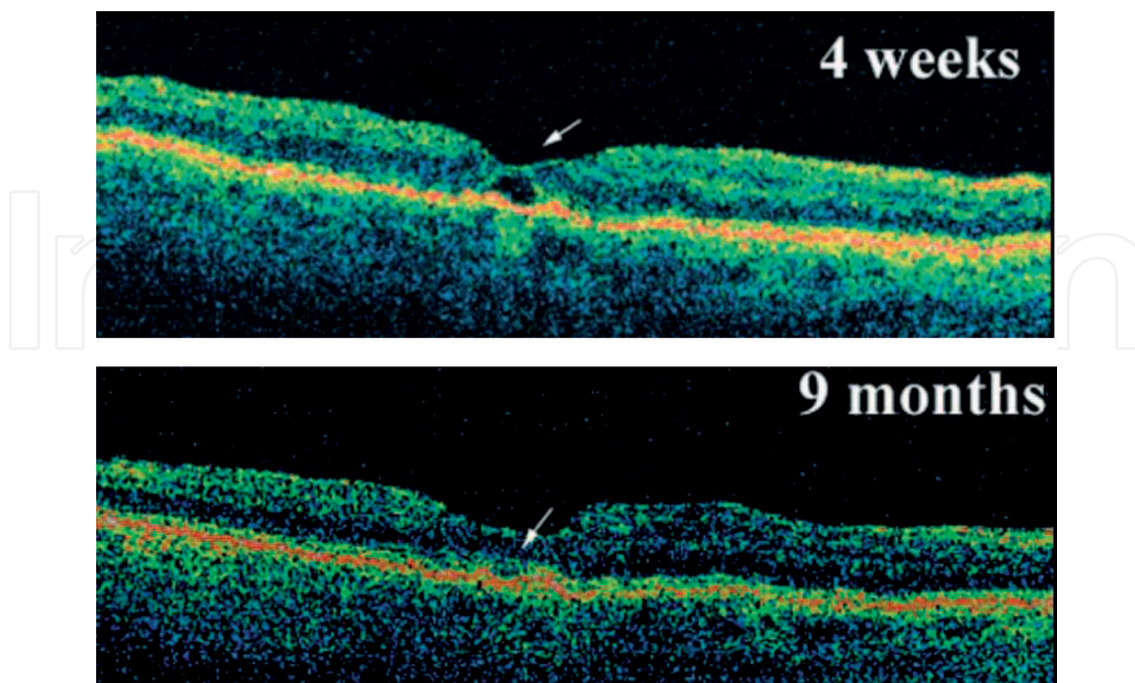


Figure 8. Spontaneous resolution of foveal lucency.

It has been noted in various studies that photoreceptor integrity is the best prognostic factor for VA.

Analysis of the inner HRL (hyperreflective layer) allows a better understanding of the outcomes of macular hole surgeries. It has been seen that anatomic success with restoration of foveal contour does not always translate to improved postoperative visual acuity. Irregularities at the level of the inner HRL after macular hole surgery may prevent visual acuity improvement. On the other hand, improvement in BCVA has been noted with IS/OS junction normalization in the postoperative period [23].

- b. Foveolar gaps (lucencies) are a common occurrence post MH surgery. Conservative treatment with patient reassurance is the treatment of choice as has been demonstrated by serial OCT follow-up (**Figure 8**) [24].
- c. Macular hole closure can be observed ophthalmoscopically 9–10 days after gas injection.
 - Flat/open and flat/closed anatomic closure
 - Elevated/open

The closed macular holes have been variously classified based on OCT

- type 1 closure (closed without foveal neurosensory retinal defect) and type 2 closure (closed with foveal neurosensory retinal defect) (**Figure 9a**) [25]. The extent of postoperative visual improvement of type 1 closure group was larger than that of type 2 closure group. Also, only type 2 closure was associated with recurrence of the pathology. Thus, the postoperative visual prognosis directly correlated to the type of hole closure, which in turn was seen to correspond to the preoperative hole diameter [25].

In another study by Imai et al. [26], OCT images of repaired macular holes were categorized into three patterns (**Figure 9b**).

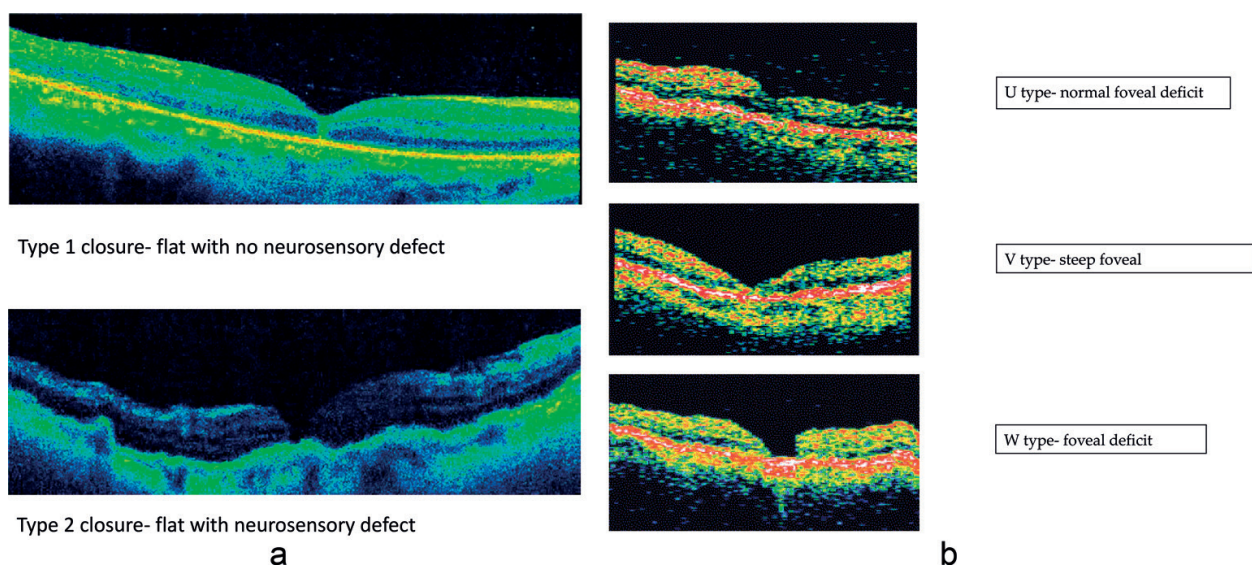


Figure 9. Types of macular hole closure on (a) OCT-Kang et al. [25] and (b) OCT-Imai et al. [26].

- U-type (normal foveal contour)—the retinal pigment epithelium and choriocapillaris layers covered by a smooth surface
- V-type (steep foveal contour)—retinal pigment epithelium and choriocapillaris layers covered with moderately backscattering layers with a notch
- W-type (foveal defect of neurosensory retina)—terminating of sensory retinal layers leading to exposure of retinal pigment epithelium and choriocapillaris layers to the surface

Postoperative acuity was well correlated with these patterns of OCT images.

7. OCT in the fellow eye

OCT can be used for serial follow-up of the fellow eye to pick up early changes. Patients with a full-thickness macular hole in one eye and foveal abnormalities in the fellow eye, consistent with a stage 1 macular hole, have a high risk of progression in the fellow eye. A close follow-up of these patients can help early intervention resulting in better visual outcomes.

8. Summary

OCT is vital for ophthalmologic clinical and surgical decision-making, in particular for macular pathologies. It complements clinical examination in diagnosing vitreoretinal interface pathologies, including macular hole [27]. OCT allows the clinician to detect initial stages of macular hole, follow its progression, and intervene early in case of progression to full-thickness holes. It can unequivocally detect the presence of a macular hole as well as changes in the surrounding retina, distinguishing it from lamellar holes and cystic lesions of the macula. Also, the status of the vitreomacular interface can be evaluated. Various macular hole factors enable the surgeon to discuss the prognosis with patients to give a more realistic expectation. Novel surgical modifications have been attempted for large macular holes diagnosed on OCT, with improved postoperative results. Intraoperative OCT is a new tool in the armamentarium helping the surgeon evaluate the completeness of ILM peel with minimal tissue disruption, thus aiding postoperative hole closure. Postoperative evaluation with OCT helps to elucidate the structural and functional changes associated with different surgical techniques. It helps us understand the mechanisms of postoperative improvement observed along with changes in the retinal architecture. OCT also helps us correlate anatomic success with functional success/failure, based on various types of hole closures and integrity of IS/OS junction.

With advances in OCT entering clinical practice, we can see an exponential expansion of our ophthalmic knowledge with a parallel improvement in patient care.

Conflict of interest

No conflict of interest.

Author details

Sana I. Tinwala

Address all correspondence to: sanailyas22@gmail.com

Anuditi Eye Care, Mumbai, India

References

- [1] Huang D, Swanson EA, Lin CP, et al. Optical coherence tomography. *Science*. 1991;**254**: 1178-1181
- [2] Drexler W, Sattmann H, Hermann B, et al. Enhanced visualization of macular pathology with the use of ultrahigh resolution optical coherence tomography. *Archives of Ophthalmology*. 2003;**121**:695-706
- [3] Potsaid B, Gorczynska I, Srinivasan VJ, et al. Ultrahigh speed spectral/Fourier domain OCT ophthalmic imaging at 70,000 to 312,500 axial scans per second. *Optics Express*. 2008;**16**:15149-15169
- [4] Gass JD. Idiopathic senile macular hole. Its early stages and pathogenesis. *Archives of Ophthalmology*. 1988;**106**:629-639
- [5] Gass JD. Reappraisal of biomicroscopic classification of stages of development of a macular hole. *American Journal of Ophthalmology*. 1995;**119**:752-759
- [6] Gass JD, Joondeph BC. Observations concerning patients with suspected impending macular holes. *American Journal of Ophthalmology*. 1990;**109**:638-646
- [7] Gaudric A, Haouchine B, Massin P, Paques M, Blain P, Erginay A. Macular hole formation: New data provided by optical coherence tomography. *Archives of Ophthalmology*. 1999;**117**:1744-1751
- [8] Haouchine B, Massin P, Gaudric A. Foveal pseudocyst as the first step in macular hole formation: A prospective study by optical coherence tomography. *Ophthalmology*. 2001;**108**:15-22
- [9] Hee MR, Puliafito CA, Wong C, et al. Optical coherence tomography of macular holes. *Ophthalmology*. 1995;**102**:748-756
- [10] Puliafito CA, Hee MR, Lin CP, et al. Imaging of macular disease with optical coherence tomography. *Ophthalmology*. 1995;**102**:217-229
- [11] Azzolini C, Patelli F, Brancato R. Correlation between optical coherence tomography data and biomicroscopic interpretation of idiopathic macular hole. *American Journal of Ophthalmology*. 2001;**132**:348-355
- [12] Ullrich S, Haritoglou C, Gass C, Schaumberger M, Ulbig MW, Kampik A. Macular hole size as a prognostic factor in macular hole surgery. *The British Journal of Ophthalmology*. 2002;**86**(4):390-393

- [13] Kusahara S, Teraoka Escaño MF, Fujii S, Nakanishi Y, Tamura Y, Nagai A, Yamamoto H, Tsukahara Y, Negi A. Prediction of postoperative visual outcome based on hole configuration by optical coherence tomography in eyes with idiopathic macular holes. *American Journal of Ophthalmology*. 2004;**138**(5):709-716
- [14] Kumar A, Tinwala SI, Gogia V, Sehra SV. Tapping of macular hole edges: The outcomes of a novel technique for large macular holes. *The Asia-Pacific Journal of Ophthalmology*. 2013;**2**:305-309
- [15] Michalewska Z, Michalewski J, Adelman RA, Nawrocki J. Inverted internal limiting membrane flap technique for large macular holes. *Ophthalmology*. 2010;**117**(10):2018-2025
- [16] Hayashi H, Kuriyama S. Foveal microstructure in macular holes surgically closed by inverted internal limiting membrane flap technique. *Retina*. 2014;**34**(12):2444-2450
- [17] Ruiz-Moreno JM, Staicu C, Piñero DP, Montero J, Lugo F, Amat P. Optical coherence tomography predictive factors for macular hole surgery outcome. *The British Journal of Ophthalmology*. 2008;**92**(5):640-644
- [18] Rodrigues EB, Maia M, Meyer CH, Penha FM, Dib E, Farah ME. Vital dyes for chromovitrectomy. *Current Opinion in Ophthalmology*. 2007;**18**(3):179-187
- [19] Veckeneer M, Mohr A, Alharthi E, et al. Novel 'heavy' dyes for retinal membrane staining during macular surgery: Multicenter clinical assessment. *Acta Ophthalmologica*. 2014;**92**:339-344
- [20] Pichi F, Alkabes M, Nucci P, Ciardella AP. Intraoperative SD-OCT in macular surgery. *Ophthalmic Surgery, Lasers and Imaging Retina*. 2012;**43**(6):S54-S60
- [21] Ehlers JP, Modi YS, Pecun PE, Goshe J, Dupps WJ, Rachitskaya A, Sharma S, Yuan A, Singh R, Kaiser PK, Reese JL, Calabrise C, Watts A, Srivastava SK. The DISCOVER Study 3-year results: Feasibility and usefulness of microscope-integrated intraoperative OCT during ophthalmic surgery. *Ophthalmology*. 2018;**17**:32218-32212. pii: S0161-6420
- [22] Ehlers JP, Tao YK, Farsiu S, et al. Integration of a spectral domain optical coherence tomography system into a surgical microscope for intraoperative imaging. *Investigative Ophthalmology & Visual Science*. 2011;**52**:3153-3159
- [23] Baba T, Yamamoto S, Arai M, Arai E, Sugawara T, Mitamura Y, Mizunoya S. Correlation of visual recovery and presence of photoreceptor inner/outer segment junction in optical coherence images after successful macular hole repair. *Retina*. 2008;**28**(3):453-458
- [24] Mahmoud TH, BW MC 2nd. Natural history of foveolar lucencies observed by optical coherence tomography after macular hole surgery. *Retina*. 2007;**27**(1):95-100
- [25] Kang SW, Ahn K, Ham DI. Types of macular hole closure and their clinical implications. *The British Journal of Ophthalmology*. 2003;**87**(8):1015-1019
- [26] Imai M, Iijima H, Gotoh T, Tsukahara S. Optical coherence tomography of successfully repaired idiopathic macular holes. *American Journal of Ophthalmology*. 1999;**128**(5):621-627
- [27] Mirza RG, Johnson MW, Jampol LM. Optical coherence tomography use in evaluation of the vitreoretinal interface: A review. *Survey of Ophthalmology*. 2007;**52**:397-421