

We are IntechOpen, the world's leading publisher of Open Access books Built by scientists, for scientists

6,900

Open access books available

185,000

International authors and editors

200M

Downloads

Our authors are among the

154

Countries delivered to

TOP 1%

most cited scientists

12.2%

Contributors from top 500 universities



WEB OF SCIENCE™

Selection of our books indexed in the Book Citation Index
in Web of Science™ Core Collection (BKCI)

Interested in publishing with us?
Contact book.department@intechopen.com

Numbers displayed above are based on latest data collected.
For more information visit www.intechopen.com



Clinical Application of DDM/rhBMP-2 in Implant Dentistry

In-Woong Um, Young-Kyun Kim, Pil-Young Yun,
Zi-Yu Yan and Yu-Mi Kim

Additional information is available at the end of the chapter

<http://dx.doi.org/10.5772/intechopen.79871>

Abstract

Recombinant human bone morphogenetic protein-2 (rhBMP-2) is well-known osteoinductive growth factors that can be used along with various carriers. Demineralized dentin matrix (DDM) that has osteoinductive and osteoconductive capacities was developed as potential candidate for rhBMP-2 carrier that has its endogenous growth factors and fulfils the requirements such as controlled release kinetics, biocompatibility, biodegradabilities and bone forming capacity. DDM loaded with rhBMP-2 (DDM/rhBMP-2) have been subjected to in vitro, in vivo studies for the purpose of proving the clinical safety and efficacy. Recently the clinical trials and outcomes of DDM/rhBMP-2 have also proved this composite to be safe and efficient in terms of enhanced bone formation, remodeling capacity and reduced concentration of rhBMP-2 in implant dentistry in Korea. This chapter will introduce the clinical application of DDM/rhBMP-2 in implant dentistry based on the related experimental and clinical researches.

Keywords: demineralized dentin matrix (DDM), recombinant human bone morphogenetic protein-2 (rhBMP-2), DDM loaded with rhBMP-2 (DDM/rhBMP-2), bone graft, bone regeneration

1. Introduction

Since the first report of clinical application of DDM (AutoBT® Korea Tooth Bank, Seoul, Korea) that were developed by Korea Tooth Bank in 2010, many experimental and clinical studies have been subjected to improve the biocompatibility, bone forming capacity and to expand clinical applications.

DDM is fabricated from the tooth that is traditionally discarded after extraction as medical waste product. Based on the historical work of Dr. Urist since 1965 [1], DDM itself can be defined as acid insoluble, microporous, type I collagenous scaffold that has several non-collagenous growth factors such as BMPs, PDGF and FGF2 in addition to a mineral phase [2–4]. DDM is mainly processed by dehydration, defatting, and partial demineralization. Demineralization with 0.6 N HCl results in the elimination of the major part of the mineral phase and immunogenic components, while retaining a very low fraction of minerals (5–10 wt.%), the majority of Type I collagen, and non-collagenous proteins (NCPs), providing an osteoconductive and osteoinductive scaffold [5, 6].

We developed two types of DDM (AutoBT®): one is powder, the other is block. The clinical efficacy and safety of DDM powder and block have been approved as new health technology assessment (nHTA) in Korea 2015 based on the several experimental and clinical evidences [7–11].

DDM powder, which is proved to be osteoinductive and osteoconductive, is 300–800µm size with enlarged dentinal tubules and loosened collagen matrix that serve as channels for releasing essential growth factors from the dentin matrix. The indications of powder are socket preservation, alveolar bone augmentation, guided bone regeneration and sinus augmentation [12].

DDM block, which is osteoconductive and osteoinductive, is root form shaped and has several 200–300 µm-sized macropores from surface to pulp chamber and canal to provide a space for vascular invasion from the host tissues when implanted in the alveolar bone. The indication of block are socket preservation, alveolar wall repair and replacement of conventional membranes [11].

The rhBMP-2 was well known cytokines that has great potential of stimulation, proliferation, and differentiation of stem cells into osteoblastic cells to deposit newly formed osteoid. It has been shown that rhBMP-2 requires suitable carrier to achieve clinical efficacy. Suitable carriers should meet some requirements such as adequate porosity to allow cell and blood vessel infiltration, appropriate mechanical stability against compression and tension, biocompatibility, biodegradability, amenability to sterilization, adhesiveness to adjacent bone, affinity for BMPs, and should provide retention of the protein for a sufficient period of time to affect the repair [13].

Type I collagen (absorbable collagen sponge, ACS) is the most preferred and commonly used BMP carrier. In 2007, the FDA granted approval of rhBMP-2/ACS (INFUSE Bone Graft®, Medtronic, Memphis, TN) as an alternative to autogenous bone grafts for sinus augmentations, and for localized alveolar ridge augmentation of defects associated with extraction sockets. Dose dependent clinical studies have determined 1.5mg/cc as a safe and predictable dose for bone formation. However, the only approved carrier for rhBMP-2 by the US FDA at this time has many drawbacks such as poor mechanical properties, squeezing tendency of rhBMP-2 resulting in burst release and overdose complication, and less osteoconductivities. So that ideal rhBMP-2 carrier has not been established yet in field of clinical implant dentistry [14–16].

DDM has been considered as one of the potential candidate of the rhBMP-2 carrier in perspectives of the main role that is to retain the factor at the site for a prolonged period of time [17]. Regarding to DDM as rhBMP-2 carrier, Ike et al. reported that exogenous rhBMP-2 adsorbed into pulverized root partially demineralized dentin matrix (PDM) proved to be as osteoinductive as autogenous bone graft [18]. Murata et al. also showed that human DDM particles are osteoinductive, insoluble collagenous matrices, and DDMs might be effective as an rhBMP-2 carrier for bone engineering [19].

Based on the previous report of Ike and Murata, Kim et al. [20] and Um et al. [21] have reported and confirmed *in vivo* and *in vitro* studies that support the observations of efficacy of DDM as rhBMP-2 carrier. With regard to clinical applications, Kim reported the first successful use of DDM/rhBMP-2 in humans in 2014, while allogenic DDM/rhBMP-2 was successfully applied for upper right alveolar bone repair in 2016 [22].

Jeon et al. reported the evaluation of soft tissue volume change after socket preservation using DDM/rhBMP-2 compared with Bio-Oss collagen (Geistlich, Wolhusen, Switzerland) that the volume decreases of DDM/rhBMP-2 is not inferior to Bio-Oss [23].

Another clinical study of a total of 23 patients who received DDM/rhBMP-2 with implant placements (36 implants; maxilla: 14, mandible: 22) showed favorable osseointegration in terms of the implant stability, marginal bone loss, and clinical outcomes [24].

Recently, the author reported a clinical study of DDM/rhBMP-2 application on extraction socket preservation that DDM may be potential carrier of rhBMP-2 with reduced concentration of rhBMP-2 [25]. This chapter will introduce the surgical technique, clinical outcome, long term results of DDM/rhBMP-2 graft in implant dentistry.

2. Case reports

2.1. Preparation of DDM/rhBMP-2

DDM powder was produced using human teeth that were soaked in 70% ethyl alcohol. After dividing the teeth into the crown and root, the root portion was crushed to a powder. The size of the particles was between 300 and 800 μm diameter. The crushed particles were soaked in distilled water and a hydrogen dioxide solution, and the remaining foreign substances were removed by using an ultrasonic cleaner. The cleaned particles were dehydrated with ethyl alcohol and went through defatting using ethyl ether solutions. The particles were then demineralized for 30 min in 0.6 N HCl. The demineralized particles were lyophilized and sterilized with ethylene oxide gas (**Figure 1a**).

DDM block also was fabricated after crowns were severed at the cementoenamel junctions. Only root dentin part was processed for the block fabrication (European Patent No. 2462899) for its intended use as described in other report. [11] Additional holes sized in 0.2–0.3 mm were made from surface of the root to the canal area to create through and

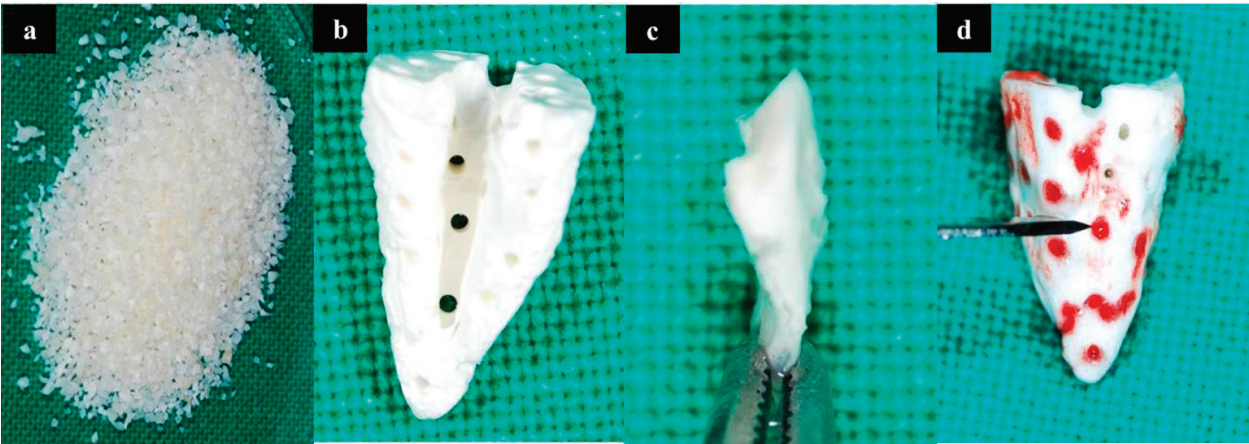


Figure 1. Types of DDM. (a) DDM powder; (b) DDM block with the through and through holes, 200–300µm diameter; (c) sheet like structure fabricated from block; (d) wettability with the blood via macropores.

through macropores for promoting vascular invasion and bone formation. The block went through the same fabrication process with the powder form, but the only difference was not being crushed into particles so that the block maintains the original tooth root form and shape (**Figure 1b**).

DDM block can be transformed into various shapes according to its indication such as sheet like structure to be membrane substitute, ring structure for vertical augmentation (**Figure 1c**). **Figure 1d** shows the characteristic wettability with patient’s own blood via macropores of DDM block (**Figure 1d**).

The rhBMP-2 was loaded on the DDM powder and block by placing 5.0 µg of 0.2 mg/mL rhBMP-2 (Cowellmedi, Busan, Korea) and 0.3 g of DDM powder into individual 15-mL conical tubes. The mixtures were frozen in a deep freeze at -70°C for 60 min, slotted into a lyophilization glass bottle, and then fixed in a lyophilizer (ILShin Lab, Seoul, Korea). After sterilization with ethylene oxide, the DDM powder loaded with rhBMP-2 was packed and transported to the hospital where the implant surgery would be performed [22].

Because DDM/rhBMP-2 powder and block were manufactured in laboratory with maintaining its form and shape clinician can use this material simple and easy as usual.

Demographic information of patients, sites, procedure, materials and follow-up periods are summarized in **Table 1**.

Case No.	Age/Gender	Site	Procedure	Materials	Follow up
1	44 / F	Lower left first molar	SP /Simultaneous	Powder / No membrane	4 month
2	56 / F	Upper right first molar	SP / Simultaneous	Powder / No membrane	3 year 7 month
3	55 / F	Upper right central incisor	GBR /Simultaneous	Powder / No membrane	3 year
4	66 / F	Lower central incisors	Ridge split / Simultaneous	Powder / No membrane	3 year
5	54 / M	Lower left canine	GBR (alveolar) / Simultaneous	Powder / No membrane	3 year
6	43 / M	Lower left first molar	GBR / Staged	Block+Powder / No membrane	7 month
7	41 / M	Upper right first molar	Onlay / Simultaneous	Block+Powder / No membrane	7 year

F: Female, M: Male, SP: Socket prevention, GBR: Guided Bone Regeneration

Table 1. Demography of DDM/rhBMP-2 application.

2.2. DDM/rhBMP-2 powder

2.2.1. Case 1: socket preservation on lower left first molar extraction site with simultaneous implant placement

Implants were placed on the extraction socket of the lower left first molar (**Figure 2**) together with DDM/rhBMP-2 powder to prevent buccal wall resorption otherwise buccal wall collapse could hinder the dental implant management (**Figure 2a**). During the secondary surgery, 4 months post-implantation, sound bone and well organized tissues around the dental implant can be seen. DDM/rhBMP-2 powder seemed to be well incorporated with the extraction socket wall because both the border between the defect and DDM/rhBMP-2 particles was no longer visible (**Figure 2b**).

2.2.2. Case 2: socket preservation on upper right first molar with simultaneous implant placement

Implants was placed on the extraction socket of the upper right first molar (**Figure 3**) together with DDM/rhBMP-2 powder to prevent anticipated buccal wall resorption (**Figure 3a**). A cone beam computerized tomography (CBCT, Vatech, Seoul, Korea) image of the upper right first molar, taken three months after first surgery showed the graft which patched up the thin buccal cortical bone (**Figure 3b**). Six months post-implantation, i.e., at the time of secondary surgery, the buccal cortical bone seems to be resorbed and replaced with newly formed bone with the volume of socket wall maintained (**Figure 3c**). Three year seven months later with final prosthesis, the alveolar housing, surrounded dental implant, maintain its volume and shape as natural alveolar bone (**Figure 3d**).

Comparing 3D reconstructive images of immediate post operation to 3 year 7 months later indicated that the thin buccal cortical bone which was expected to be resorbed due to slightly

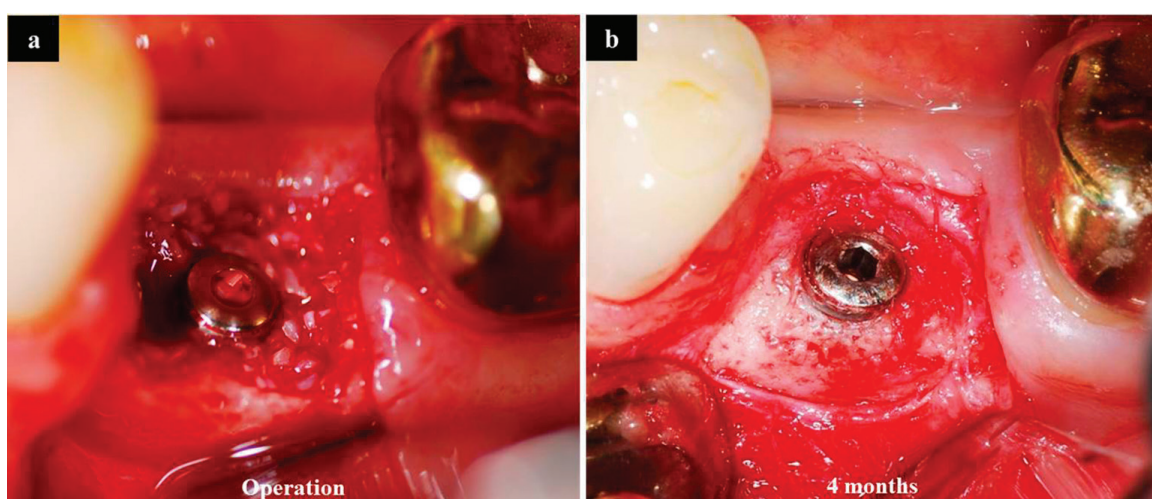


Figure 2. Socket preservation on lower left first molar without covering membrane. (a). Dental implant was placed in the extraction socket with primary stability, and the gap between the implant and socket wall was filled with DDM/rhBMP-2 powder without membrane. (b) Four months later, well organized bone was seen that surround the dental implant and repair all the gaps. Remnants of DDM/rhBMP-2 particles can not be seen.

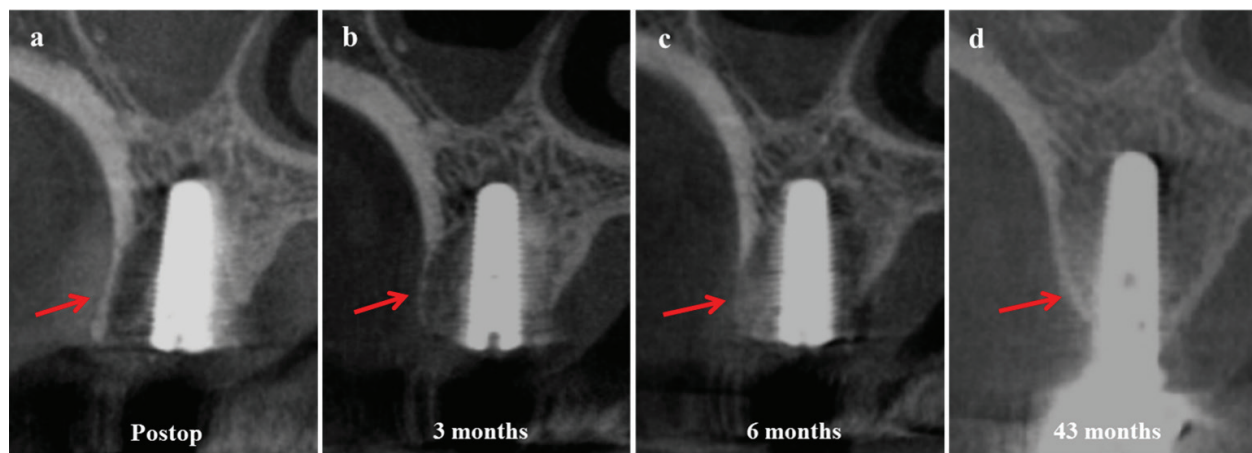


Figure 3. CBCT of socket preservation on upper right first molar with simultaneous implant placement. (a) Immediate postoperative image showed gap between the implant and thin buccal cortical bone which is expected to be resorbed. (b) Three months after graft, thinning buccal cortical bone indicated the beginning of remodeling. (c) Six months after graft, buccal cortical bone was almost disappeared with the volume of extraction socket maintained. (d) Three year 7 months after, alveolar bone around the dental implant turned into a mature cortical-cancellous bone complex (arrow = alveolar bone).

demineralized appearance (**Figure 4a**), and the alveolar bone surround the dental implant neck have been completely remodeled into a mature cortical bone which was fully supported by cancellous bone and marrow (**Figure 4b**).

2.2.3. Case 3: GBR on upper right central incisor

Upper right central incisor was extracted due to intermittent pain, swelling, and mobility for the past three years. One week after extraction, the implant (diameter: 3.8 mm, length: 13 mm; Dio, Busan, Korea) was placed and the DDM/rhBMP-2 was grafted simultaneously with securing excellent primary stability (**Figure 5a**).

The labial defect and exposed implant were covered with DDM/rhBMP-2 powders (**Figure 5b**). The muco-periosteal flap was replaced and stabilized without a covering membrane. After one and half months, the patient underwent secondary surgery earlier than the conventional waiting period of 6 months due to her inevitable schedule. Newly formed bone was covered the labial defect and exposed implant completely. The volume was maintained and the remained particles were no longer seen (**Figure 5c**).

A CBCT image taken before and immediately after the primary surgery showed the missing part of the labial cortex and exposed implant that had been patched up by the DDM/rhBMP-2 powder (**Figure 6a** and **b**). There were clear border lines separating the graft from the remaining labial cortex (**Figure 6b**). After 3 years with final prosthesis, the labial defect appeared completely repaired by sound cortico-cancellous bone. The border at the upper labial defect had completely disappeared, indicating good incorporation of the graft into the alveolar bone as well as remodeling capacity into sound cortico-cancellous bone complex around implant neck (**Figure 6c**).

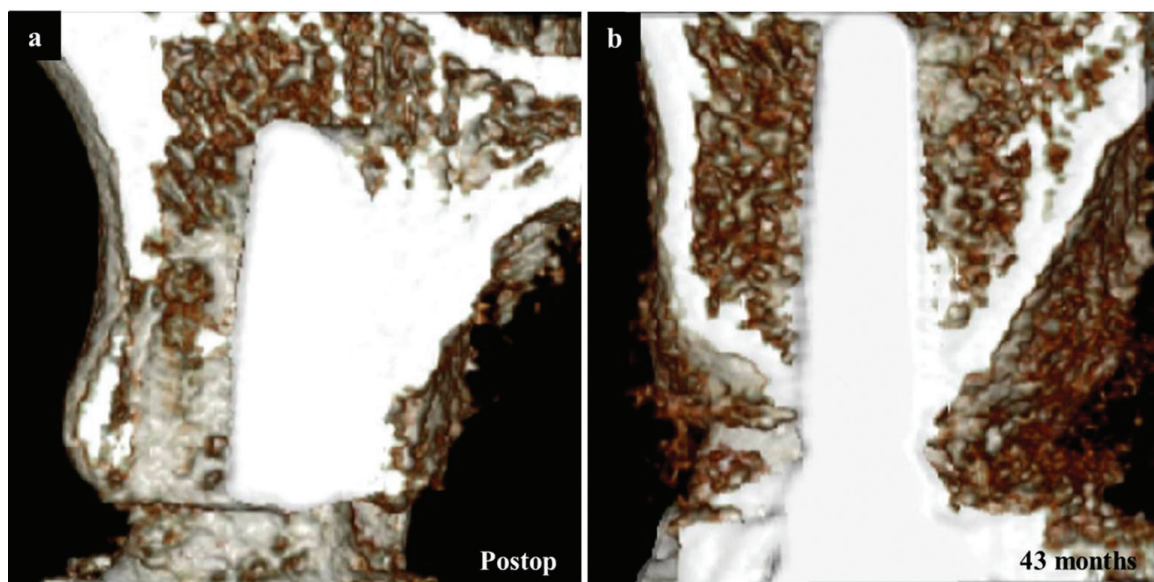


Figure 4. 3D reconstructive image from CBCT. (a) The demineralized buccal cortical bone which was expected to be resorbed. (b) The alveolar bone surround the implant neck have been completely remodeled into a mature cortico-cancellous bone complex.

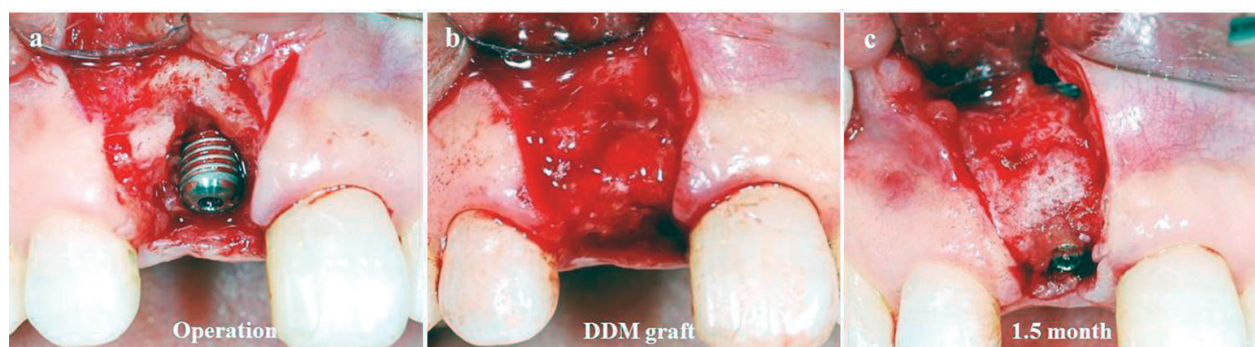


Figure 5. GBR on upper right central incisor. (a) Exposed dental implant and labial defect immediate after implant placement. (b) Exposed defect were covered with DDM/rhBMP-2 powders. See the wettability of DDM with blood that provides immobility to the powders without membrane. (c) Six weeks after, well organized, newly formed bones filled the labial defect and surround the dental implant.

2.2.4. Case 4: ridge split and expansion on lower central incisors

Ridge split procedure was performed to secure the labio-lingual dimension for implant placement (diameter: 3.8 mm, length: 13 mm; Daemul, Seoul, Korea) on lower central incisors (**Figure 7a**). The gaps created by ridge split and implant placement were filled with DDM/rhBMP-2 powders (**Figure 7b**). Two and a half months later, the whole DDM/rhBMP-2 particles have changed into well-organized bone-like structure with remarkably increased ridge width and height (**Figure 7c**). Well organized tissues covered screw was retrieved for histological examination (**Figure 7d**). There were no inflammatory cells or foreign body reactions and were no gaps between the DDM particle and the newly formed bone (**Figure 7e**).

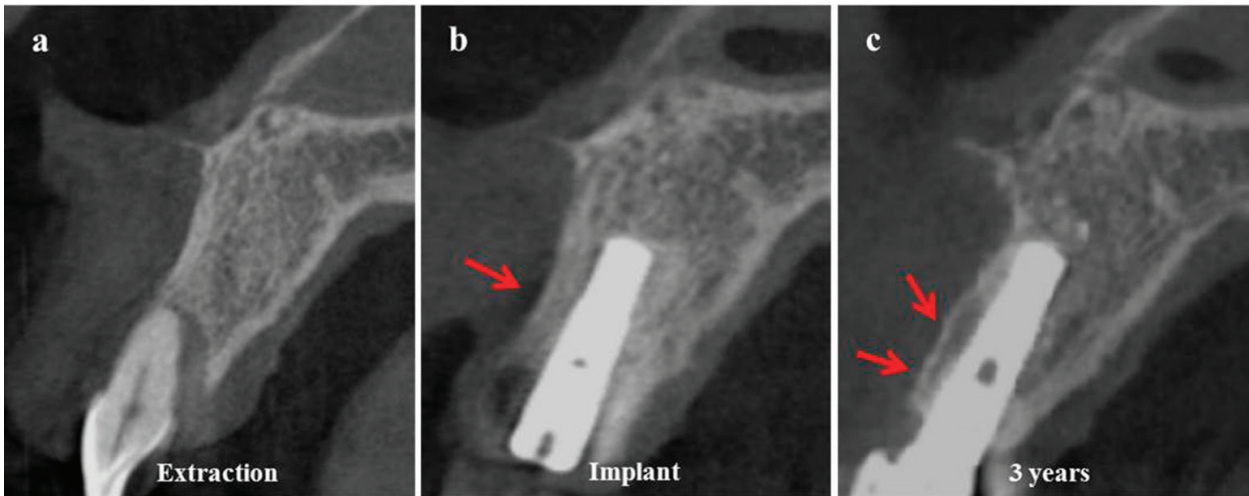


Figure 6. CBCT images of GBR on upper right central incisor. (a) Before extraction of upper right central incisor; (b) placement of dental implant and GBR was done for labial defect; (c) Three years follow up. The cortico-cancellous bone complex was recovered completely (arrow = alveolar bone).

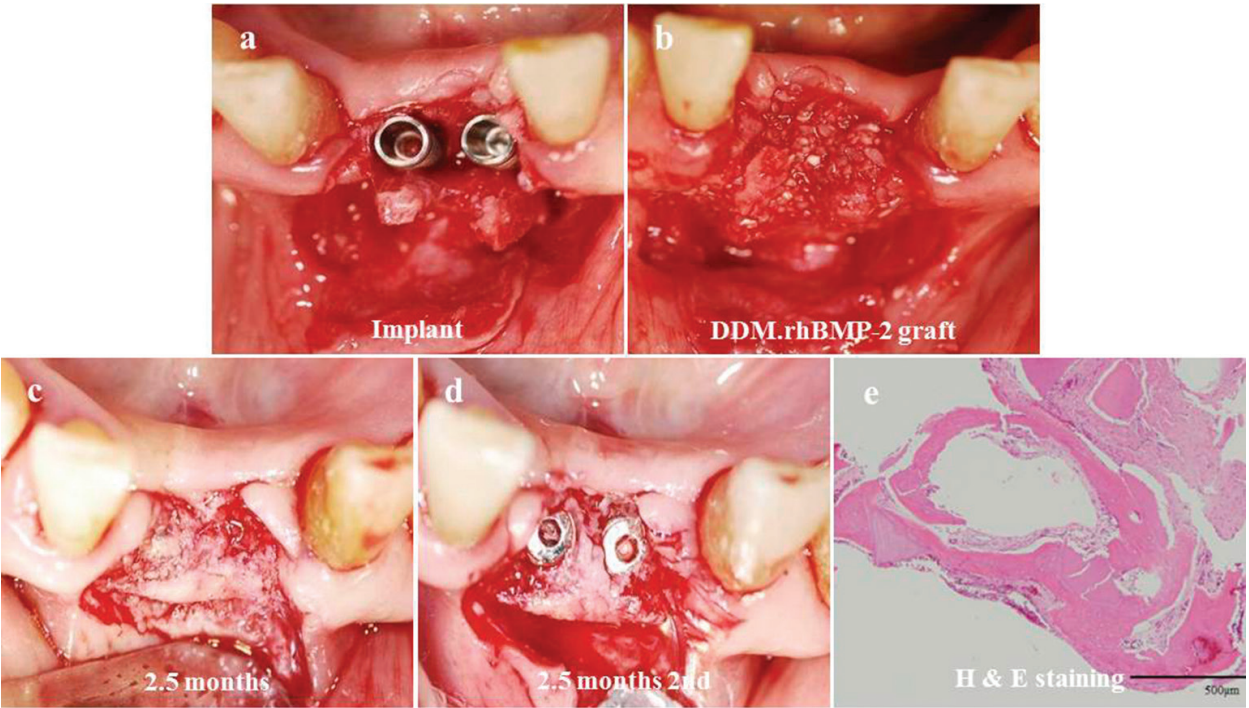


Figure 7. DDM/rhBMP-2 powder application on lower central incisors. (a) Implant placement after ridge split procedure. (b) The space between the implants and labial cortical plate is filled with DDM/rhBMP-2. No membrane is used. (c) Two and a half months later, a well-organized bone-like structure surrounded implant. The ridge width increased remarkably. (d) Uncovering implant. Tissue over the implant is used for histological evaluation. (e) Histologic specimen shows active new bone formation around DDM particle. Void space is the DDM which was detached during histologic processing. (Hematoxylin and eosin staining, Scale bar = 5.0 µm). From Um et al. [22] (**Figure 3**).

Histologic specimens of DDM alone at this area have shown that the particle was surrounded by a dense fibrotic capsule consisting of 3–4 cell layers where there are no inflammatory cells or foreign body reactions as the evidences of biocompatibility of DDM due to the environmental

factors of poor blood supply in between the cover screw and the gingiva, we could not find the bone formation at this area before. [22] However, DDM/rhBMP-2 specimen in this case showed remarkable amount of bone formation around DDM/rhBMP-2 particles (**Figure 7e**). This may be explained by the positive effect of additional rhBMP-2 on DDM.

A CBCT image taken seven months after surgery showed a completely repaired labial bone. The demarcated border between the remaining labial cortex and the repaired bone has almost disappeared (**Figure 8a and b**). After 3 years with final prosthesis, the labial cortex becomes more thickened and fully supported by cancellous bone and marrow (**Figure 8c**).

2.2.5. Case 5: alveolar bone augmentation on lower left canine

Extraction of canine, which were sent to Korea Tooth Bank for fabrication of DDM/rhBMP-2, were performed one week before implant placement. Full thickness flaps were elevated to expose the alveolar crest and locate the defective area. Cleaning and removal of the granulation tissues revealed a huge, crater-like defect with complete destruction of the labial wall (**Figure 9a**). The implant (diameter: 3.8 mm, length: 13 mm; Dio, Busan, Korea) was placed and an excellent primary stability was obtained (**Figure 9b**). The huge defect and exposed implant were filled and augmented with DDM/rhBMP-2 that was prepared for easy molding and shaping (**Figure 9c**). The DDM/rhBMP-2 was placed and carefully packed into the destroyed area of the lingual wall and extended to the surface of the lateral buccal wall, without applying excessive pressure. The mucoperiosteal flap was replaced without a covering membrane (**Figure 9d**).

When the patient underwent secondary surgery, six months later, well-formed bone, which surrounds the implant and fill the gap, can be seen (**Figure 9e**). All routine prosthetic procedures after removal of bone over cover screw were performed (**Figure 9f**).

A CBCT image taken immediately after surgery showed that the missing part of the labial cortex had been patched up by the DDM/rhBMP-2 powder. There was clear border line

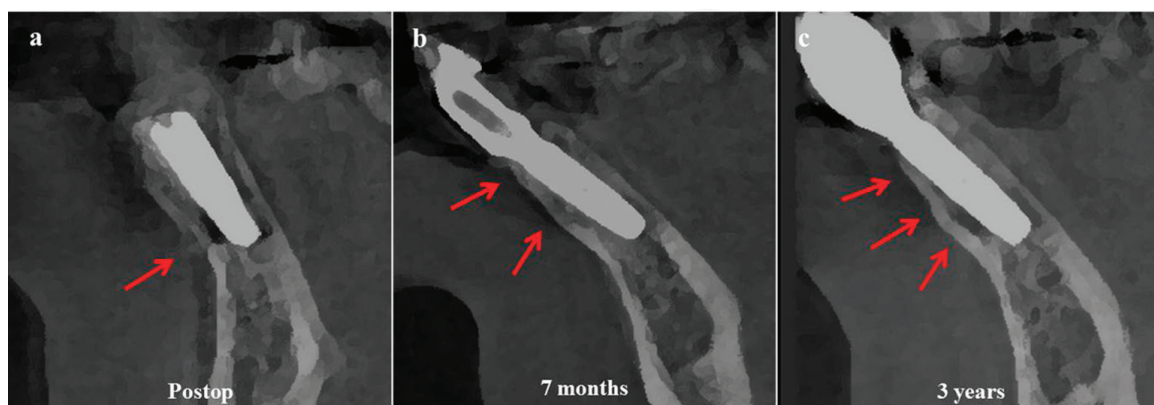


Figure 8. Cone beam computerized tomography (CBCT) of DDM/rhBMP-2 application on lower central incisor. (a) Immediately after implant placement and DDM/rhBMP-2 graft. There is obvious lower labial defect. (b) After 7 months. Labial cortical bone is completely repaired and the demarcated defect border has almost disappeared. (c) After 3 years. The labial cortex becomes thicker and shows fully developed cortico-cancellous bone complex (arrow = alveolar bone). From Um et al. [22] (**Figure 4**).

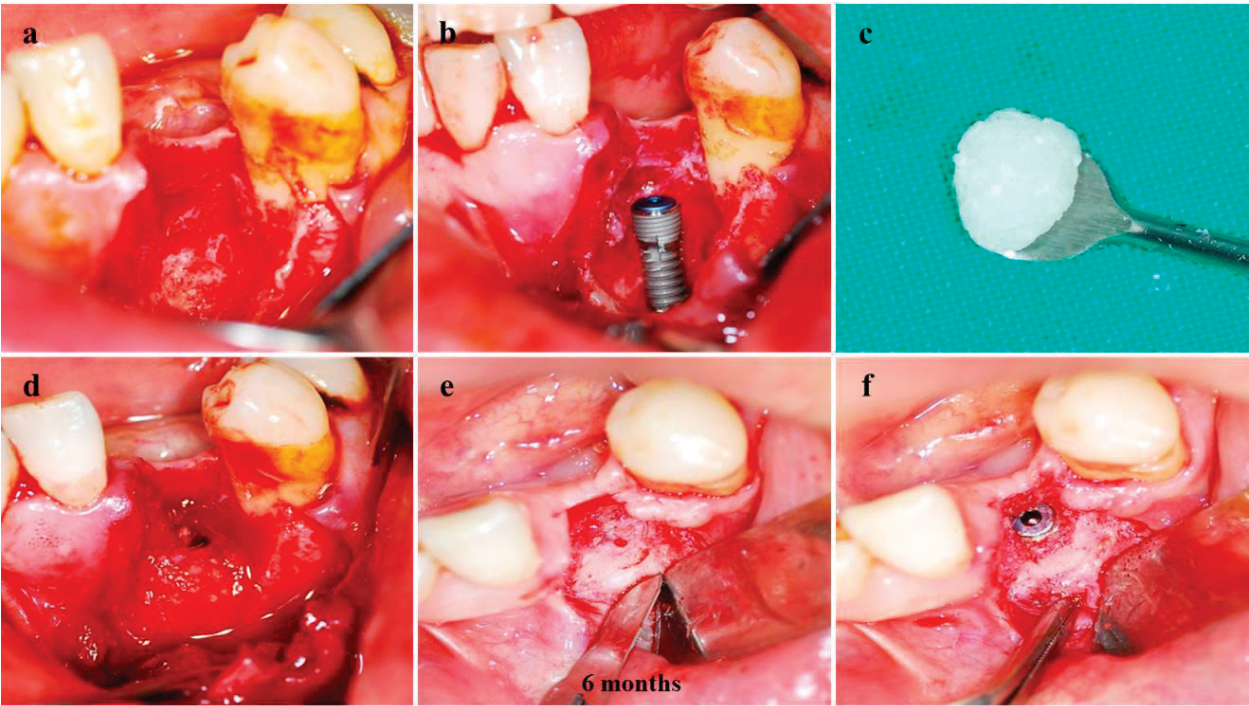


Figure 9. DDM/rhBMP-2 application on lower left canine. (a). There was huge defect after removal of all granulations on lower left canine. (b). Placement of implant (diameter: 3.8 mm, length: 13 mm) ensuring initial stability. (c). DDM/rhBMP-2 particles can be molded and shaped easily. (d). DDM/rhBMP-2 is packed into the lingual wall gap and along the labial wall. No membrane is used. (e). Well-organized bone tissue was found, filling the gap and surround the implant completely. None of the particles can be seen. (f). The tissue over the cover screw is typically removed in order to go through the prosthetic procedure and histological evaluation. From Um et al. [22] (**Figure 1**).

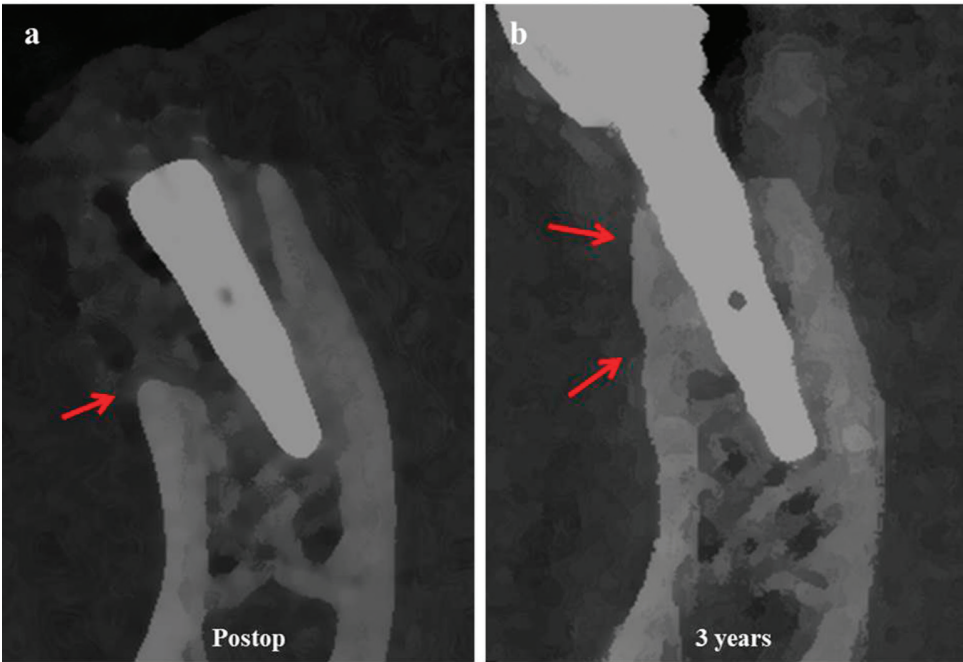


Figure 10. Cone beam computerized tomography (CBCT) of lower left canine repaired by DDM/rhBMP-2. (a) Immediately after implant placement and graft. DDM/rhBMP-2 particles surround the implant, patching up the labial and crestal alveolar bone. (b) After 3 years, the border line at the lower labial defect has completely disappeared. The repaired labial cortical bone was fully supported by cancellous bone and marrow (arrow = alveolar bone). From Um et al. [22] (**Figure 2**).

separating the graft from the remaining labial cortex (**Figure 10a**). After three years with final prosthesis, the alveolar bone was repaired completely in both volume and shape. The border at the lower labial defect had completely disappeared, indicating good incorporation of the graft into the alveolar bone. The repaired labial cortical bone seemed to be fully supported by cancellous bone and marrow (**Figure 10b**).

2.3. DDM/rhBMP-2 block

2.3.1. Case 1: GBR for the repair of alveolar wall on lower left first molar

After extraction of lower left first molar, there was collapsed buccal wall resulting in huge, crater-like defect (**Figure 11a and b**). Using the extracted tooth, block and powder type DDM/rhBMP-2 were prepared (**Figure 11c**). Buccal wall was repaired by block and the alveolar proper was repaired by powder (**Figure 11d**). Six months later for the staged procedure of implant placement, there was a bone-like tissue that was completely transformed from the block and powder of DDM/rhBMP-2. Alveolar bone seemed to be repaired completely without any remnants of block and powder (**Figure 11e**). So that the implant can be secured safely on the repaired alveolar bone (**Figure 11f**).

A CBCT image taken before and after extraction showed complete loss of buccal wall (**Figure 12a and b**). The alveolar proper was repaired by DDM/rhBMP-2 powder while the missing part of buccal wall was repaired by DDM/rhBMP-2 block. There was clear border line separating the block graft from the remaining buccal cortical bone (**Figure 12c**). After 6 months, the border line began to disappear that indicate good incorporation and remodeling

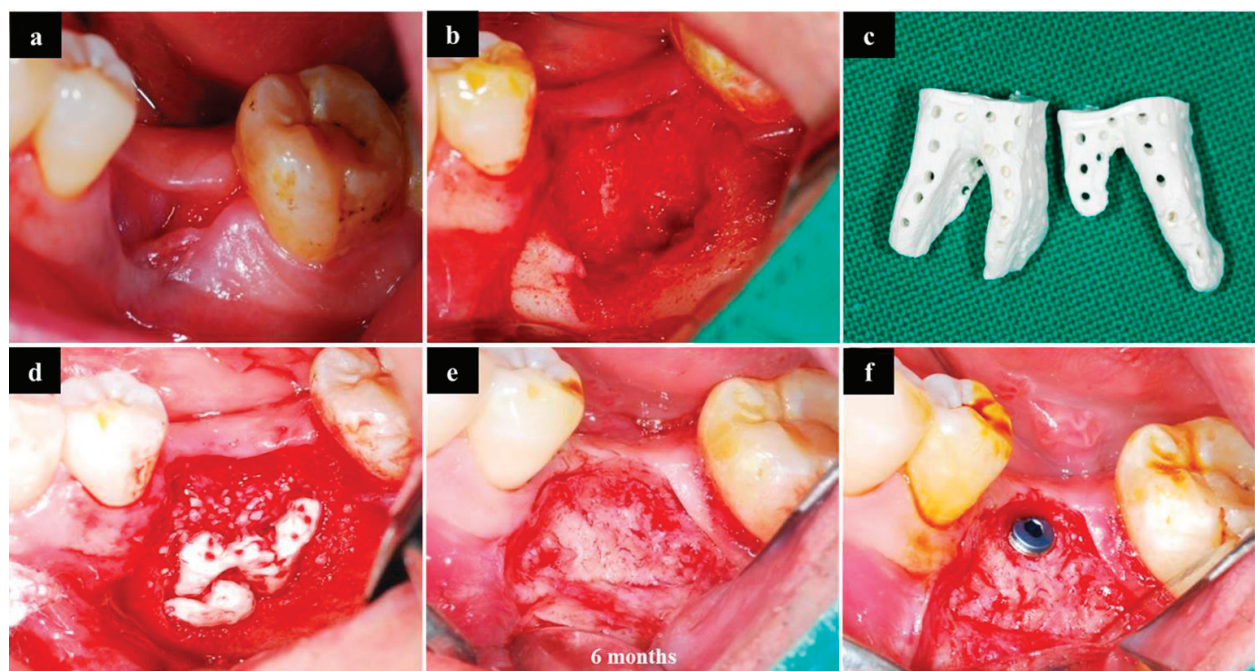


Figure 11. GBR for the repair of alveolar wall on lower left first molar. (a) Collapsed buccal wall after extraction of lower left first molar. (b) Reflection of flap and removal of granulation tissues. Huge defect and resorbed buccal wall can be seen. (c) Fabricated DDM/rhBMP-2 block from extracted tooth. (d) The huge defect was repaired by DDM/rhBMP-2 block and powder. (e) Six months later, whole DDM/rhBMP-2 was completely transformed into bone like structure. (f) Implant placement (staged procedure).

(**Figure 12d**), and 12 months later, radiopaque outer cortex and remodeled powder can be seen (**Figure 12e**). The alveolar bone surround the implant appeared completely repaired in both volume and shape.

2.3.2. Case 2: onlay graft on upper right first molar for volume expansion

After placement of implant, there was an atrophy of buccal cortical area (**Figure 13a**). DDM/rhBMP-2 block and powder was put on the buccal resorbed area that showed sound wettability with patients own blood and immobilization. The color change of the DDM/rhBMP-2 is mainly due to soaking with the patient's own blood into the macropores and collagenous dentin matrix (**Figure 13b**). Flap was closed without using membrane. The flap reflected again for the prosthetic procedure 4 months later, there were no discernible block and powders remained and well organized tissues replaced the onlay graft with the volume and shape maintained (**Figure 13c and d**).

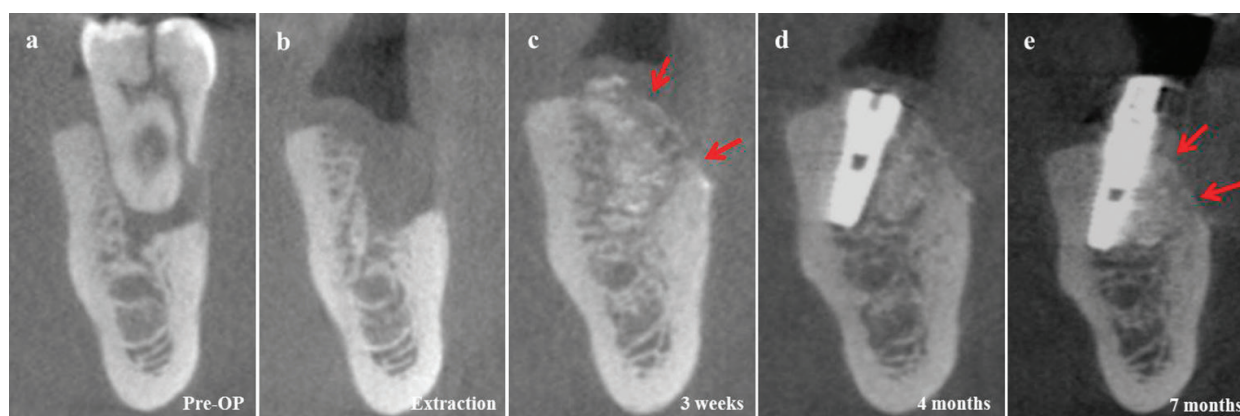


Figure 12. GBR for the repair of alveolar wall on lower left first molar. (a) Before extraction. (b) Immediate after extraction. Complete loss of buccal wall can be seen. (c) Repair the alveolar proper with DDM/rhBMP-2 powder and the buccal wall with DDM/rhBMP-2 block. (d) Six months later, placement of implant. See the remodeled powder. (e) Seven months after. Powders are remodeled in the alveolar proper, while the block repaired buccal cortical bone (arrow = alveolar bone).

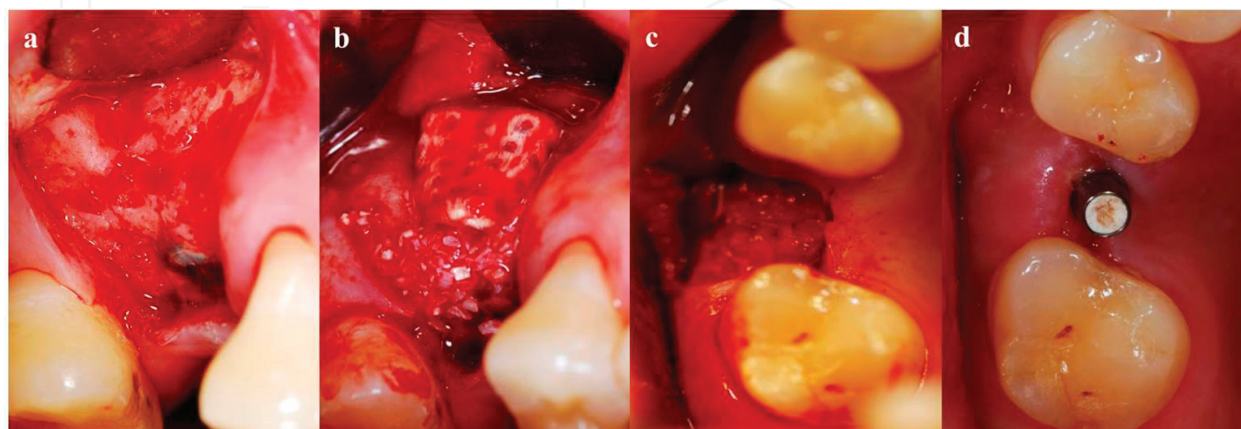


Figure 13. Onlay graft on upper right first molar for volume expansion. (a) Atrophied buccal area can be seen after placement of implant. (b) DDM/rhBMP-2 block and powder were put on the buccal resorbed area. No membrane was used due to the wettability of block and powder with patient's own blood resulting in immobilization. (c) Four months later, there were no DDM particles and block that have changed into well-organized tissues maintaining the whole volume of DDM/rhBMP-2. (d) See the increased volume of buccal gingiva and texture.

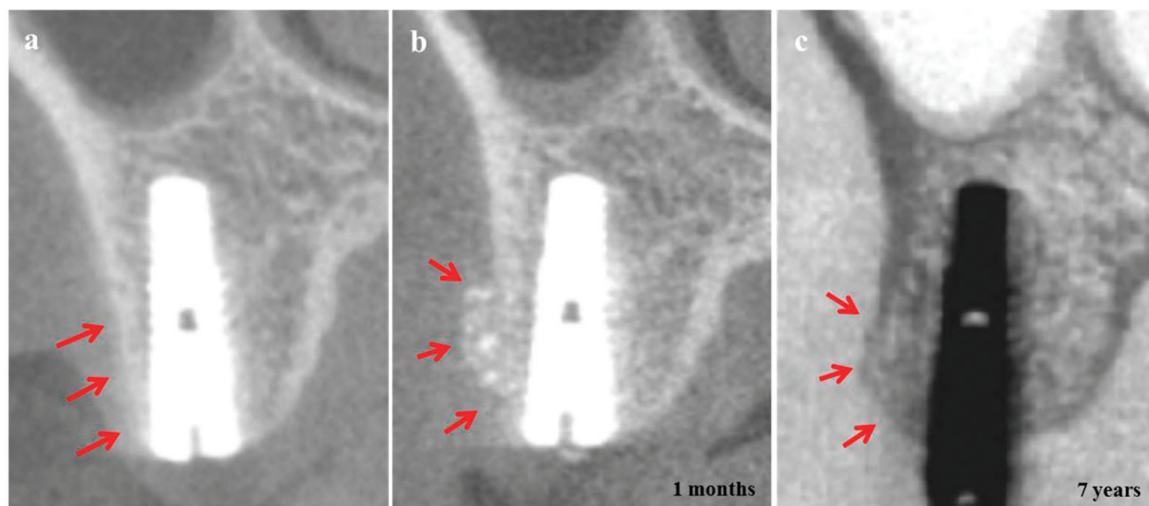


Figure 14. CBCT images of onlay graft on upper right first molar. (a) After placement of 3.8 mm diameter implant, the buccal cortical bone around the dental implant is too thin and close to implant neck. (b) Increased alveolar bone volume around implant neck area by DDM/rhBMP-2 application can be seen. (c) Seven years later, onlay DDM/rhBMP-2 was well incorporated with the buccal cortical bone under continuous remodeling, that create new cortico-cancellous bone complex (arrow = alveolar bone).

CBCT images after implant placement on upper right first molar. As a result of long term missing of tooth, alveolar ridge became narrow and the buccal cortical bone around the dental implant is too thin and close to implant neck (**Figure 14a**). Increased alveolar bone width and volume by DDM/rhBMP-2 application can be seen (**Figure 14b**). Seven years later, increased volume of alveolar housing, remodeled completely, shows mature cortico-cancellous bone complex (**Figure 14c**).

3. Discussion

Unlike other scaffolds, for example, ACS which has a limited capacity for controlled release, lacks of structural stability, risk of physiologically excessive doses, and the insufficient retention of BMP-2 [14–16], DDM has adequate porosity to allow cell and blood vessel infiltration, appropriate mechanical stability to withstand compression and tension, biocompatibility, biodegradability, amenability to sterilization, adhesiveness to adjacent bone, affinity for BMPs, and the ability to retain the protein for a sufficient period [17, 26]. DDM has a microporous structure with dentinal tubules 3–5 μm in diameter, which allows it not only to contain BMPs, but also to efficiently release them at surgical site [20]. Numerous studies have reported on the performance of DDM as a scaffold for BMPs; the osteoconductive and osteoinductive abilities of DDM are deemed to be its greatest strengths [18–20].

3.1. Experimental studies of DDM/rhBMP-2

As a candidate for an rhBMP-2 carrier, Ike et al. reported that xenogenous rhBMP-2 adsorbed into pulverized root and partially DDM proved to be as osteoinductive as an autogenous bone graft [18]. Murata also showed that human DDM particles are osteoinductive, insoluble collagenous matrices, and that DDMs might be effective as an rhBMP-2 carrier for bone engineering [19].

The first report of human DDM/rhBMP-2 have demonstrated that DDM displays the highest released to loaded rhBMP-2 ratio, the lowest release speed, and the highest induction of osteonectin expression, resulting in augmented mature bone formation compare with tricalcium phosphate (TCP) [12]. Um et al. examined the bone induction capacity of DDM/ rhBMP-2 compare with conventional TCP in the muscle pouches of nude mice. The results were that the early cellular reaction on the surface of particles was superior in the DDM/ rhBMP-2 group, more osteoid was deposited on the DDM/ rhBMP-2 group [25].

In the rabbit's calvarial defect, the DDM and anorganic bovine bone combined with rhBMP-2 (ABB/rhBMP-2) groups showed osteoconductive bone formation, while the DDM/rhBMP-2 group showed osteoconductive and osteoinductive bone formation. The DDM/rhBMP-2 group showed a twofold greater amount of bone formation compared to the DDM alone and ABB/rhBMP-2 groups. The μ CT analysis showed markedly increased bone volume in the DDM/rhBMP-2 group at eight weeks compared with that of the DDM group [21]. Kim et al. evaluated the efficacy of DDM/rhBMP-2 in the unilateral upper second and third premolars of eight beagles compare with the autogenous bone and reported equality of DDM/rhBMP-2 to autogenous bone [24].

3.2. Clinical studies of DDM/ rhBMP-2

Case series study of comparing short term outcome of DDM/rhBMP-2 (Bio α , Seongnam, Korea) with hydroxyapatite (HA)/rhBMP-2 (Bio α , Seongnam, Korea), reported that rhBMP-2 combined with HA or DDM scaffolds can be used for bone graft procedures such as guided bone regeneration [20].

About the effectiveness of DDM/rhBMP-2 (CowellMedi, Busan, Korea) for alveolar bone repair [27, 28], the clinical findings with respect to the healing process were that there were no remarkable inflammation and immune rejection that impair the healing process and are coincident with those of the previous studies of DDM alone [8, 10, 29]. The nanopore structure of dentinal tubules in unique avascular and acellular Type I collagenous dentin matrix seems to make it feasible to carry and release rhBMP-2 effectively on local site based on the previous study [30, 31].

In the clinical study of histological comparison of autogenous and allogenic DDM/rhBMP-2 at the site between the implant cover screw and gingiva, as the poor blood supply allows it to simulate a heterotopic condition, three patients undergoing simultaneous implant placement and receiving a different type of graft were included: allogenic DDM loaded with rhBMP-2 (DDM/rhBMP-2), autogenous DDM/rhBMP-2 and autogenous DDM. After 3–6 months of grafts, the antigenicity and immunogenicity of the carrier allogenic DDMS are low enough to maintain both the biocompatibility of the scaffold and the activity of the loaded rhBMP-2 [22].

Jeon et al. reported study to evaluate soft tissue volume change after socket preservation using DDM alone, DDM/rhBMP-2 and Bio-Oss collagen (Geistlich, Wolhusen, Switzerland). According to soft tissue volume changes, each groups showed statistically meaningful volume decreases. Bio-Oss collagen showed 15.4% volume decrease, DDM showed 18.8% and DDM/rhBMP-2 showed 16.1% decrease, respectively. However, there were no significant differences among groups [23].

In the clinical study of a total of 23 patients who received bone grafts using human DDM/rhBMP-2 with implant placements (36 implants; maxilla: 14, mandible: 22). The implant stability, marginal bone loss, and clinical outcome were evaluated. Favorable osseointegration was obtained in 35 out of 36 implant sites (one case of osseointegration failure) and severe complications were not observed in all cases [24].

3.3. Case report of DDM/ rhBMP-2

Each case report represent socket preservation, GBR, ridge split and expansion, onlay graft with simultaneous or staged implant placement. Besides the crucial factors for implant success such as stability, peri-implantitis, the first critical observation in this case presentation is the texture of tissues formed around the implant at second surgery time without using any membranes. The powder or block that were no longer visible when the flap reflected at 3–6 months after graft indicated good incorporation and remodeling capacities of DDM into host bed. These phenomena might be explained by the synergistic effect of exogenous rhBMP-2 with endogenous growth factors in DDM that is both increased bone formation and accelerated DDM degradation. This is assumption raised and explained in the previous report [18, 19, 31].

Second observation is the structure of bone around the implant neck area where the major peri-implantitis start and accumulated. What we need for ideal osseointegration is sound alveolar bone with appropriate volume and shape at this defense front area. The sound alveolar bone consist of cortical bone with enough thickness, and cancellous bone with mature bone marrow that is inevitable for continuous remodeling with standing for occlusal forces. At least one year after final prosthesis, we found sound cortical bone supported by fully developed cancellous bone in CBCT analysis. And the time to achieve sound bone around the neck area might be faster than that of DDM alone [8].

Third observation is histologic evidences we presented recently that shows more bone formation at each time point and accelerated resorption of DDM compare to other carriers such as HA and TCP [25].

Finally, the rationale for not using membrane is that carrier DDM is a collagenous scaffold with minerals to be able to absorb enough blood resulting in space maintenance and invasion of blood vessels from the host. In the clinical study of DDM/rhBMP-2 application in on extraction socket preservation, there were no cellular invasion from gum tissues to hinder bone formation clinically and radiologically [25].

4. Conclusion

The clinical application of DDM/ rhBMP-2 showed successful alveolar socket preservation, GBR, onlay graft in implant dentistry without any complications. Furthermore, this clinical success may open the way to new technology for alveolar bone repair, even though the cases presented here are small numbers and not representative to conclude the clinical superiority compare to others. For example, because the long term data of DDM/rhBMP-2 in sinus augmentation are not established yet, we need to collect more data from well controlled prospective studies.

Based on several other reports that have shown favorable results from using DDM/rhBMP-2 in implant dentistry, we are going to perform more number of clinical studies such as prospective, randomized, controlled clinical trials for the purpose of assuring the safety and efficacy of DDM as a promising carrier for rhBMP-2.

By the application of rhBMP-2 from experimental researches to clinical reality, the number of choice of alternative bone graft substitutes has been increased in implant dentistry. Although significant effort has been made to find a safer, cheaper, and more efficient scaffold for rhBMP-2 carrier, there have not been sufficient studies and efforts that focused on the application of rhBMP-2 in dental field.

By the discovery and successful applications of DDM as rhBMP-2 carrier in implant dentistry, we might have cheaper, safer and more efficient bone graft substitute. Reduced concentration of rhBMP-2 with similar or superior efficacy in inducing bone formation without the adverse effects made the DDM/rhBMP-2 revolutionary cost-effective and safe that eliminates most of the side effects associated with supraphysiologic overdose concentration.

Up to date, the long term results of DDM/rhBMP-2 are clearly promising in biologic activities and cost-benefits for the patients that would open the door to develop DDM as carrier of stem cells to be applied in implant dentistry.

Acknowledgements

This study was provided the data by the Seoul National University Bundang Hospital, Peking University, and the In-Dental Clinic.

Conflict of interest

The authors have declared that no conflict of interests exists.

Author details

In-Woong Um^{1*}, Young-Kyun Kim², Pil-Young Yun², Zi-Yu Yan³ and Yu-Mi Kim¹

*Address all correspondence to: h-bmp@hanmail.net

1 R&D Institute, Korea Tooth Bank, Seoul, Republic of Korea

2 Department of Oral and Maxillofacial Surgery, Section of Dentistry, Seoul National University Bundang Hospital, Seongnam, Republic of Korea

3 Department of Oral and Maxillofacial Surgery, Peking University School and Hospital of Stomatology, Beijing, China

References

- [1] Urist MR. Bone: Formation by autoinduction. *Science*. 1965;**150**:893-899
- [2] Murata M. Collagen biology for bone regenerative surgery. *Journal of the Korean Association of Oral and Maxillofacial Surgeons*. 2012;**38**:321-325. DOI: 10.5125/jkaoms.2012.38.6.321
- [3] Yeomans JD, Urist MR. Bone induction by decalcified dentine implanted into oral, osseous and muscle tissues. *Archives of Oral Biology*. 1967;**12**:999-1008. DOI: 10.1016/0003-9969(67)90095-7
- [4] Kim YK, Lee JK, Kim KW, Um IW, Murata M. Advances in biomaterials science and biomedical applications. In: Pignatello R, editor. *Healing Mechanism and Clinical Application of Autogenous Tooth Bone Graft Material*. Catania: InTech; 2013. pp. 405-437. DOI: 10.5772/53200
- [5] Kim YK, Lee JH, Kim KW, Um IW, Murata M, Ito K. Analysis of organic components and osteoinductivity in autogenous tooth bone graft material. *Journal of the Korean Association of Maxillofacial Plastic and Reconstructive Surgeons*. 2013;**35**:353-359. DOI: 10.14402/jkamprs.2013.35.6.353
- [6] Kim YK, Kim SG, Yun PY, Yeo IS, Jin SC, Oh JS, Kim HJ, Yu SK, Lee SY, Kim JS, Um IW, Jeong MA, Kim GW. Autogenous teeth used for bone grafting: A comparison with traditional grafting materials. *Oral Surgery, Oral Medicine, Oral Pathology, Oral Radiology*. 2014;**117**:e39-e45. DOI: 10.1016/j.oooo.2012.04.018. Epub 2012 Aug 30
- [7] Kim YK, Um IW, Murata M. Tooth bank system for bone regeneration—Safety report. *Journal of Hard Tissue Biology*. 2014;**23**:371-376. DOI: 10.2485/jhtb.23.371
- [8] Kim YK, Lee JH, Um IW, Cho WJ. Guided Bone regeneration using demineralized dentin matrix: Long-term follow-up. *Journal of Oral and Maxillofacial Surgery*. 2016;**74**(3):515.e1-515.e9. DOI: 10.1016/j.joms.2015.10.030. Epub 2015 Nov 10
- [9] Lee HJ, Hong JS, Kim YK, Um IW, Lee JI. Osteogenic potential of demineralized dentin matrix as bone graft material. *Journal of Hard Tissue Biology*. 2017;**26**:223-230. DOI: 10.2485/jhtb.26.223
- [10] Pang KM, Um IW, Kim YK, Woo JM, Kim SM, Lee JH. Autogenous demineralized dentin matrix from extracted tooth for the augmentation of alveolar bone defect: A prospective randomized clinical trial in comparison with anorganic bovine bone. *Clinical Oral Implants Research*. 2017;**28**:809-815. DOI: 10.1111/clr.12885. Epub 2016 Jun 8
- [11] Kim YK, Pang KM, Yun PY, Leem DH, Um IW. Long-term follow-up of autogenous tooth bone graft blocks with dental implants. *Clinical Case Reports*. 2017;**5**:108-118. DOI: 10.1002/ccr3.754. eCollection 2017 Feb
- [12] Kim YK, Kim SG, Bae JH, Um IW, Oh JS, Jeong KI. Guided bone regeneration using autogenous tooth bone graft in implant therapy: Case series. *Implant Dentistry*. 2014;**23**(2):138-143. DOI: 10.1097/ID.0000000000000046

- [13] Burg KJ, Porter S, Kellam JF. Biomaterial developments for bone tissue engineering. *Biomaterials*. 2000;**21**:2347-2359. DOI: 10.1016/S0142-9612(00)00102-2
- [14] Benglis D, Wang MY, Levi AD. A comprehensive review of the safety profile of bone morphogenetic protein in spine surgery. *Neurosurgery*. 2008;**62**:ONS423-ONS431. DOI: 10.1227/01.neu.0000326030.24220.d8
- [15] Ripamonti U, Duarte R, Ferretti C. Re-evaluating the induction of bone formation in primates. *Biomaterials*. 2014;**35**:9407-9422. DOI: 10.1016/j.biomaterials.2014.07.053. Epub 2014 Aug 23
- [16] Seeherman H, Li R, Bouxsein M, Kim H, Li XJ, Smith-Adaline EA, Aiolo M, Wozney JM. rhBMP-2/calcium phosphate matrix accelerates osteotomy-site healing in a nonhuman primate model at multiple treatment times and concentrations. *The Journal of Bone and Joint Surgery. American Volume*. 2006;**88**:144-160
- [17] Li RH, Wozney JM. Delivering on the promise of bone morphogenetic proteins. *Trends in Biotechnology*. 2001;**19**:255-265
- [18] Ike M, Urist MR. Recycled dentin root matrix for a carrier of recombinant human bone morphogenetic protein. *The Journal of Oral Implantology*. 1998;**24**:124-132
- [19] Murata M. Bone Engineering using human demineralized dentin matrix and recombinant human BMP-2. *Journal of Hard Tissue Biology*. 2005;**14**:80-81. DOI: 10.2485/jhtb.14.80
- [20] Kim YK, Um IW, An HJ, Kim KW, Hong KS, Murata M. Effects of demineralized dentin matrix used as an rhBMP-2 carrier for bone regeneration. *Journal of Hard Tissue Biology*. 2014;**23**:415-422
- [21] Um IW, Hwang SH, Kim YK, Kim MY, Jun SH, Ryu JJ, Jang HS. Demineralized dentin matrix combined with recombinant human bone morphogenetic protein-2 in rabbit calvarial defects. *Journal of the Korean Association of Oral and Maxillofacial Surgeons*. 2016;**42**:90-98. DOI: 10.5125/jkaoms.2016.42.2.90. Epub 2016 Apr 27
- [22] Um IW, Jun SH, Yun PY, Kim YK. Histological comparison of autogenous and allogenic demineralized dentin matrix loaded with recombinant human bone morphogenetic protein-2 for alveolar bone repair: A preliminary report. *Journal of Hard Tissue Biology*. 2017;**26**:417-424. DOI: 10.2485/jhtb.26.417
- [23] Jeon TH, Kang MH, Um IW, Ryu JJ, Jun SH. Volumetric assessment of alveolar bone ridge after socket preservation using 3-dimensional surface model analysis. *The Korea Research Society for Dental Material*. 2017;**44**:377-386. DOI: 10.14815/kjdm.2017.44.4.377
- [24] Kim SY, Kim YK, Park YH, Park JC, Ku JK, Um IW, Kim JY. Evaluation of the healing potential of demineralized dentin matrix fixed with recombinant human bone morphogenetic protein-2 in bone grafts. *Materials (Basel)*. 2017;**7**:10. DOI: 10.3390/ma10091049
- [25] Um IW. Demineralized dentin matrix as a carrier of recombinant human morphogenetic proteins. In: *Proceeding of the 59th Congress of Korean Association of Oral and Maxillofacial Surgeons (JKAOMS)*; 26-28 April 2018; Korea. Korea: ISSN; 2018. pp. 72-73

- [26] Kirker-Head CA. Potential applications and delivery strategies for bone morphogenetic proteins. *Advanced Drug Delivery Reviews*. 2000;**43**:65-92
- [27] Um IW, Cho WJ, Kim YK. Experimental study on human demineralized dentin matrix as rhBMP-2 carrier *in vivo*. *Journal of Dental Applications*. 2015;**2**:269-273
- [28] Kim YK, Jang HJ, Um IW. A case report of allogenic demineralized dentin matrix loaded with recombinant human bone morphogenetic proteins for alveolar bone repair. *Journal of Dental and Oral Health*. 2016;**2**:45
- [29] Kim YK, Kim SG, Byeon JH, Lee HJ, Um IU, Lim SC, Kim SY. Development of a novel bone grafting material using autogenous teeth. *Oral Surgery, Oral Medicine, Oral Pathology, Oral Radiology, and Endodontics*. 2010;**109**:496-503. DOI: 10.1016/j.tripleo.2009.10.017. Epub 2010 Jan 8
- [30] Murata M, Sato D, Hino J, Akazawa T, Tazaki J, Ito K, Arisue M. Acid-insoluble human dentin as carrier material for recombinant human BMP-2. *Journal of Biomedical Materials Research. Part A*. 2012;**100**:571-577. DOI: 10.1002/jbm.a.33236. Epub 2011 Dec 30
- [31] Um IW, Kim YK, Jun SH, Kim MY, Cui NH. Demineralized dentin matrix as a carrier of recombinant human bone morphogenetic proteins: *In vivo* study. *Journal of Hard Tissue Biology*. 2018;**27**:219-226

IntechOpen

