

# We are IntechOpen, the world's leading publisher of Open Access books Built by scientists, for scientists

6,900

Open access books available

186,000

International authors and editors

200M

Downloads

Our authors are among the

154

Countries delivered to

TOP 1%

most cited scientists

12.2%

Contributors from top 500 universities



WEB OF SCIENCE™

Selection of our books indexed in the Book Citation Index  
in Web of Science™ Core Collection (BKCI)

Interested in publishing with us?  
Contact [book.department@intechopen.com](mailto:book.department@intechopen.com)

Numbers displayed above are based on latest data collected.  
For more information visit [www.intechopen.com](http://www.intechopen.com)



---

# **Laparoscopic Endoscopic Cooperative Surgery: Current Status and Perspective**

---

Shunsuke Sakuraba

Additional information is available at the end of the chapter

<http://dx.doi.org/10.5772/intechopen.76983>

---

## **Abstract**

Laparoscopic endoscopic cooperative surgery (LECS) is now performed worldwide as a result of the invention of new operative techniques. It is seromuscular resection by laparoscopy for gastric submucosal tumors such as gastrointestinal stromal tumors (GISTs). Endoscopic dissection of the mucosal to the submucosal layer determines the appropriate incision line, resects the tumor, and closes the visceral wall defect. Various minimally invasive LECS techniques are now well established. LECS-associated techniques, adaptation of them, and challenges for the future are reviewed in this chapter.

**Keywords:** LECS, SMT, GIST

---

## **1. Introduction**

In the last decade, LECS has been performed all over the world in association with the invention of new operative techniques. Approaches are grouped into three major categories: laparoscopy-assisted endoscopic resection (LAER) in which resection is performed primarily by the endoscopic team under laparoscopic control; endoscope-assisted laparoscopic resection (EALR), where the laparoscopic teams perform the resection under endoscopic monitoring; and combined laparoscopic endoscopic resection (CLER), which is performed by the laparoscopic and the endoscopic teams. Description of these approaches and the details about CLER, especially LECS, nonexposed endoscopic wall-inversion surgery (NEWS), and a combination of laparoscopic endoscopic approaches to neoplasia with a nonexposure technique (CLEANET) are described in the following chapters. Various LECS techniques for GIST are recently established, and the application of this approach to early stage gastric cancer, which is difficult to resect with the ESD technique because of severe scars or ulcers, is described. LECS for other

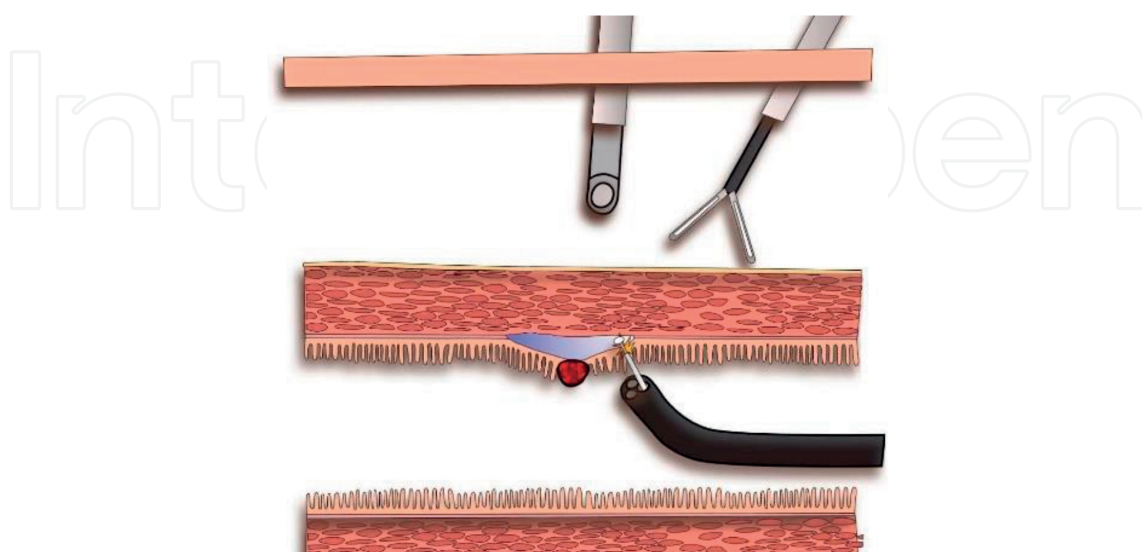
organs such as the duodenum or colorectum is also being attempted, but only with expert technique and specialist knowledge. LECS plus biopsy of sentinel lymph node for early gastric cancer is planned as a clinical trial.

### 1.1. Laparoscopy-assisted endoscopic resection

Endoscopic resection is performed under laparoscopic control [1–3]. The endoscopist performs an endoscopic mucosal resection (EMR) or endoscopic submucosal dissection (ESD) with laparoscopic assistance (**Figure 1**). Laparoscopic support has many advantages. First, when accidental complications such as perforation or massive bleeding occur during the endoscopic resection, laparoscopic surgeons can treat them immediately. Second, if the endoscopist has difficulty in resecting the tumor as a result of tumor location, the laparoscopic team can reposition the stomach with manipulation of the serosal side. Although laparoscopy-assisted endoscopic resection (LAER) requires a laparoscopic team and general anesthesia in addition to endoscopy, the advantage is greater safety; therefore, perforation risk is high in ESD because of massive tumor or duodenal location, LAER is preferred. Irino et al. reported LECS for duodenal tumors in three patients using LAER, demonstrating feasibility of this approach [4]. A unique point of their method is that the laparoscopist places seromuscular sutures to reinforce the thinned duodenal wall in order to prevent postoperative perforation or bleeding. Seromuscular reinforcement is performed for all cases. As such, these techniques can be grouped into the CLER. The perforation rate for duodenal-ESD is still much higher than for gastric-ESD, esophageal-ESD and colorectal-ESD [5–10], so LAER or CLER are good alternatives.

#### 1.1.1. Endoscope-assisted laparoscopic resection

In this category, laparoscopic surgeons mainly resect the tumor with endoscopic support as follows:



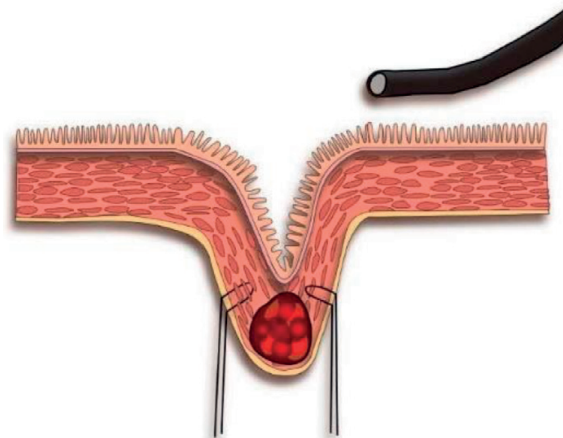
**Figure 1.** The endoscopist performs an endoscopic mucosal resection (EMR) or endoscopic submucosal dissection (ESD) with laparoscopic assistance.

# 1. Endoscope-assisted wedge resection:

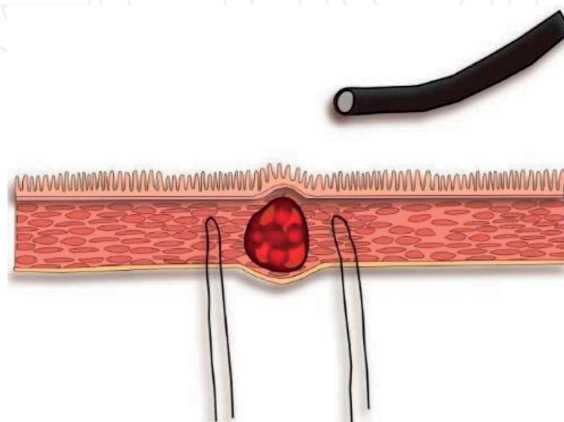
Under endoscopic monitoring, tumor location is confirmed, and blood vessels in the excision area around the tumor are prepared and if necessary the omentum is dissected, and the greater curvature of the stomach is mobilized by the laparoscopist. Several seromuscular sutures are placed around the lesion (**Figure 2**) and by pulling the stitches upward with laparoscopic forceps (**Figure 3**), the tumor is removed with laparoscopic linear stapling devices (**Figures 4 and 5**). According to laparoscopic surgeons, the staple line can be reinforced with a hand sewing suturing. The abovementioned technique is the most commonly combined surgery in the world, with more than 500 cases published [11–17]. Although the complication rate is 0–3% [11], the main problem can be excessive gastric resection by the laparoscopic linear stapling devices resulting in transformation or stenosis.

# 2. Endoscope-assisted laparoscopic transluminal (transgastric) surgery:

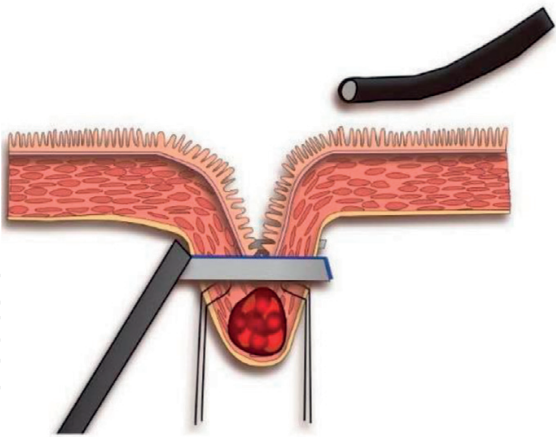
When the tumor is located along the posterior gastric wall, it is difficult for the laparoscopist to obtain a visual field, so a transgastric technique is often used. Under endoscopic monitoring, the laparoscopic surgeons make an incision in the anterior abdominal wall (**Figures 6 and 7**). The laparoscopic team directly confirms the lesion and removes it with



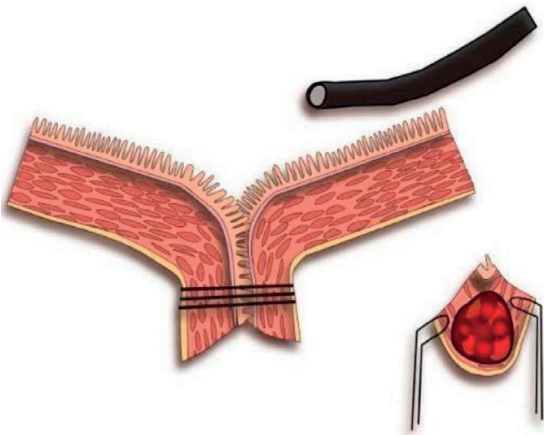
**Figure 2.** Several seromuscular sutures are placed around the lesion.



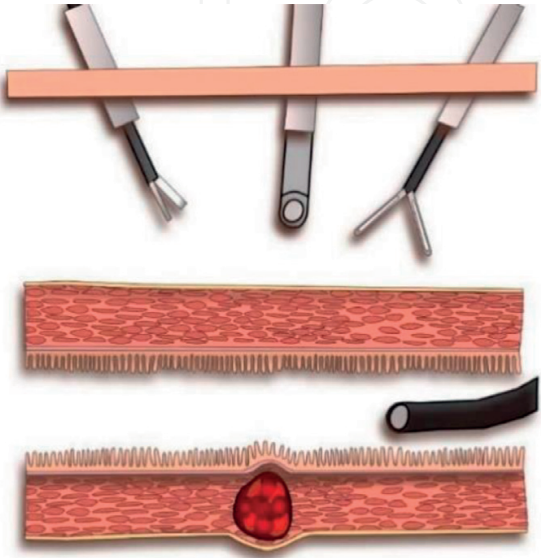
**Figure 3.** Surgeons pull the stitches upward with laparoscopic forceps.



**Figure 4.** The appropriate incision line is determined under endoscopic monitoring.



**Figure 5.** The tumor is removed with laparoscopic linear stapling devices.



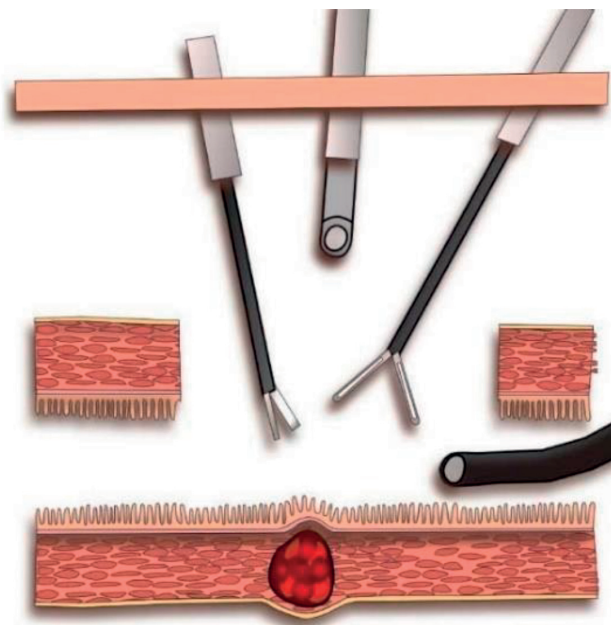
**Figure 6.** The tumor is located along the posterior gastric wall.



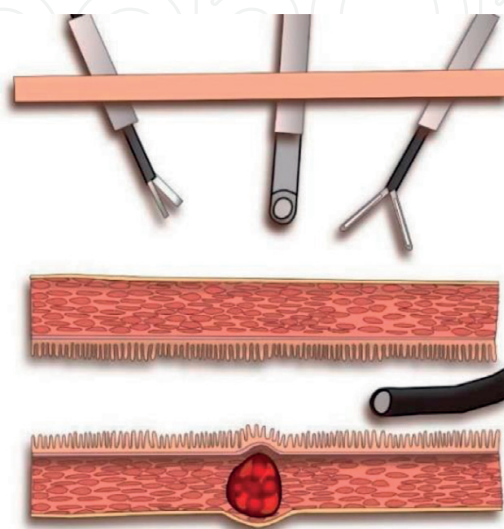
an inverted wedge resection using laparoscopic stapling devices. The opened gastric wall is closed with laparoscopic staplers or hand sewing sutures.

### 3. Endoscope-assisted laparoscopic intraluminal (intra gastric) surgery:

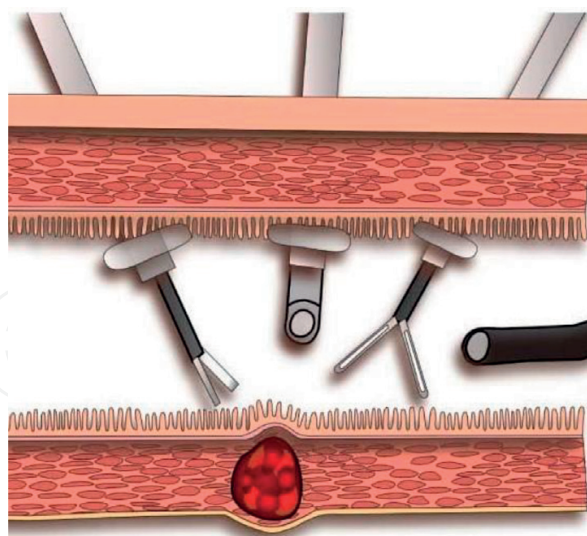
Indication for this technique is the same as for transgastric surgery approaching the posterior gastric wall. This technique was first reported by Ohashi et al. in [18], and a modified procedure was described by Dong et al. in [19]. All laparoscopic trocars are placed in the gastric cavity, penetrating both the abdominal and stomach walls. All trocars are fixed with balloon inflation of the stomach and the abdominal wall (**Figures 8 and 9**). The laparoscopist secures a visual field in the gastric lumen, and the tumor is removed by full-thickness resection or laparoscopic stapling devices. The trocar holes are closed with sutures or clips. **Figures 1–9** are excerpted from Dimitrios's report.



**Figure 7.** The laparoscopic surgeons make an incision in the anterior abdominal wall.



**Figure 8.** It is difficult for laparoscopist to approach the tumor.



**Figure 9.** All laparoscopic trocars are placed in the gastric cavity, penetrating both the abdominal and stomach walls. All trocars are fixed with balloon inflation of the stomach and the abdominal wall. The **Figures 1-9** are excerpted from Dimitrios's report.

## 2. History of the LECS technique

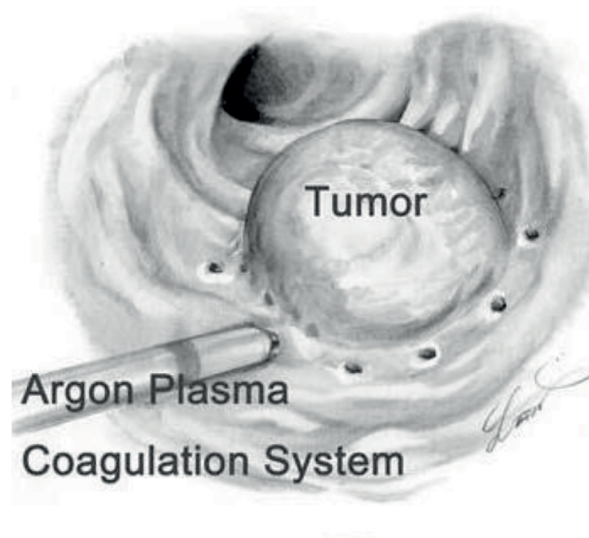
Although surgical local resection with laparotomy or laparoscopic surgery is performed for gastric submucosal tumor (SMT), it is difficult when tumors are small or have an intramural growth pattern. It is difficult to determine the appropriate incision line from the abdominal cavity side, so excessive gastric resection might result in transformation or stenosis. LECS is a newly developed technique, first reported by Hiki et al. in [20] for local resection of GIST. This procedure is further categorized into CLER, which is an approach that combines ESD and laparoscopic gastric resection to determine the incision line, to resect the tumor and to close the stomach wall. As LECS can minimize the resected region and preserve the function of the stomach after surgery, the procedure was added to the national insurance list in Japan in 2014, and subsequently rapidly diffused throughout the surgical community [21–24]. Further applications of LECS then developed, so the first version is named classical LECS to distinguish it from subsequent modified LECS techniques. Classical LECS involves whole layer resection using laparoscopy and endoscopy. However, this technique may lead to contamination of and seeding of tumor cells into the peritoneal cavity, especially when the tumor is associated with an ulcer or epithelial lesion. To prevent peritoneal spread, modified LECS procedures now include inverted LECS with crown method [25], nonexposed endoscopic wall-inversion surgery (NEWS) [26] and a combination of laparoscopic endoscopic approaches to neoplasia with a nonexposure technique (CLEAN-NET) [27].

## 3. Classical LECS

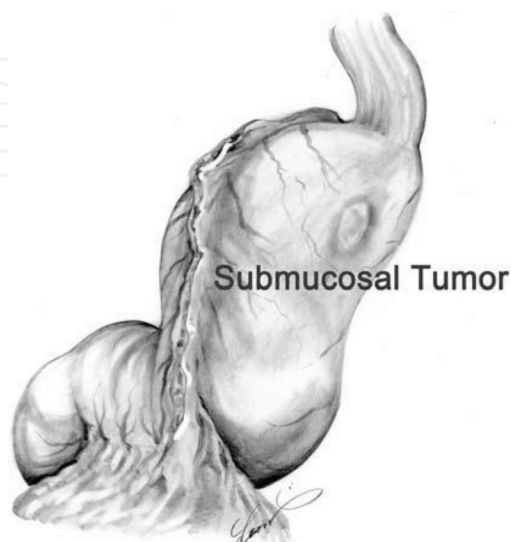
Hiki et al. first reported classical LECS in 2006 [20] for local resection of GISTs in order to prevent excessive gastric resection followed by transformation, stenosis or stasis of food after surgery. In classical LECS, the incision line is determined by the endoscopist, and an

endoscopic mucosal incision is made. Artificial perforation is performed by endoscopic forceps, and the seromuscular layer is dissected using laparoscopic and endoscopic forceps. The gastric wall defect is closed with laparoscopic stapling devices. Hiki described his LECS procedure in detail, and the following are excerpted from his writing.

1. "Tumor location was confirmed by intraluminal endoscopy." (**Figure 10**)
2. "Blood vessels in the excision area around the tumor were prepared by laparoscopy." (**Figure 11**)
3. "Endoscopic submucosal resection around the tumor and artificial perforation was performed." (**Figure 12**)
4. "Operation device was inserted into the perforation hole, and seromuscular dissection began by laparoscopy." (**Figure 13**)

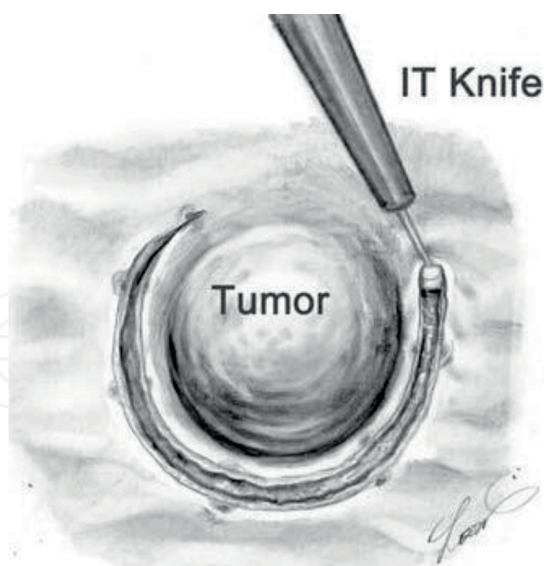


**Figure 10.** Tumor location was confirmed by intraluminal endoscopy.

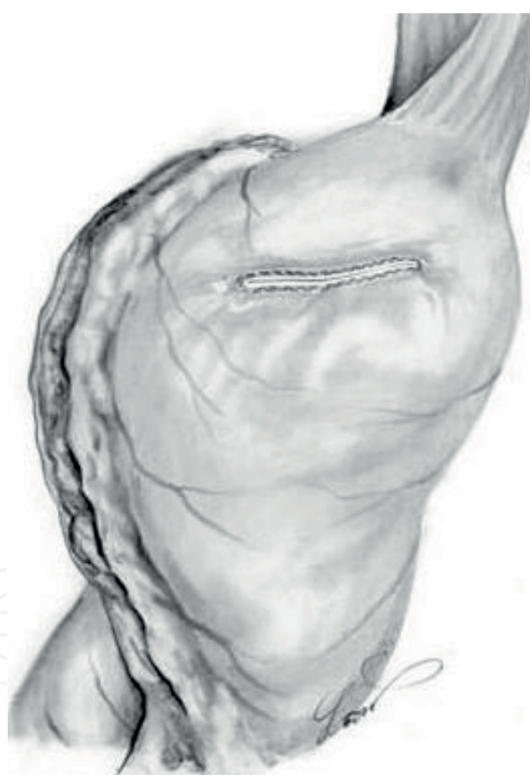


**Figure 11.** Blood vessels in the excision area around the tumor were prepared by laparoscopy.





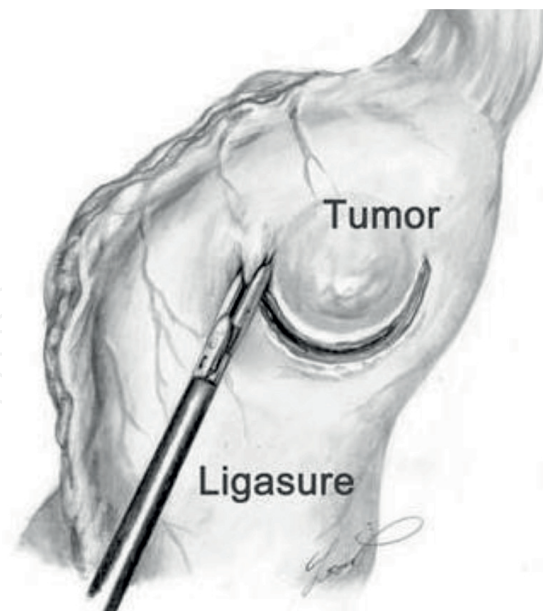
**Figure 12.** Endoscopic submucosal resection around the tumor and artificial perforation was performed.



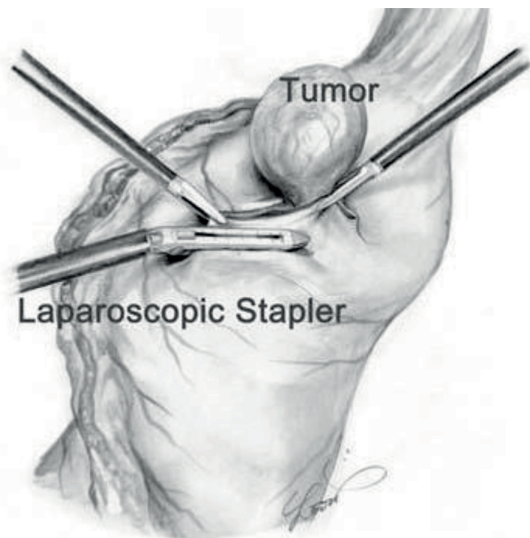
**Figure 13.** Operation device was inserted into the perforation hole, and seromuscular dissection began by laparoscopy.

5. “After resecting the tumor, the incision line was closed using laparoscopic stapling devices.” (Figures 14 and 15). Figures 10–15 are excerpted from Hiki’s report.

Although modified LECS techniques are used, the Hiki procedure is a basic concept that is employed throughout low invasive surgery for GISTs. By minimizing the resected region,



**Figure 14.** After resecting the tumor, the incision line was closed using laparoscopic stapling devices.



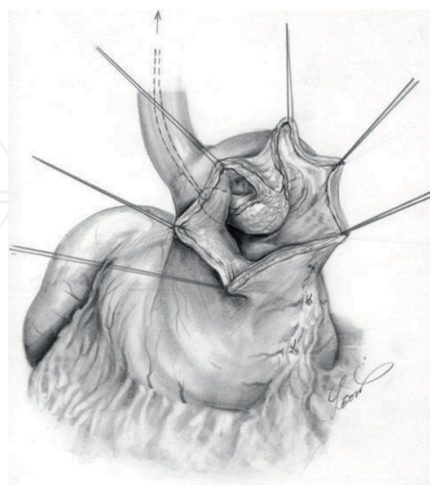
**Figure 15.** LECS technique can minimize the resected region. The **Figures 10-15** are excerpted from Hiki's report.

LECS makes it possible to preserve the postoperative function of the stomach. Hiki maintains that removal of the tumor must be performed carefully with a specimen retrieval bag in order to prevent peritoneal and port-site dissemination of tumor.

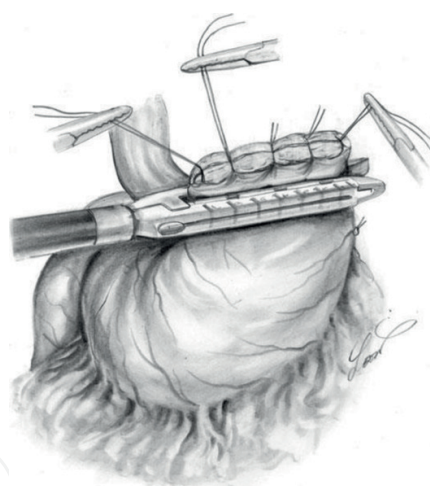
#### 4. LECS with crown method

In order to reduce the transmural communication during the operation, Nunobe et al. reported the crown method and inverted LECS [25]. By pulling up the incision line of the stomach with

several stitches, abdominal cavity contamination is prevented. This technique was named crown method because pulled-up stomach wall looks like a crown (**Figure 16**). Using the traction of the stitch, the resected specimen is inverted to the intragastric cavity. This technique



**Figure 16.** Surgeons pull up the incision line of the stomach with several stitches and pulled up stomach wall looks like a crown.



**Figure 17.** The stitches are also used as a supporting tool when the incision line is closed with a laparoscopic stapling device. The **Figures 16** and **17** are excerpted from Nunobe's report.

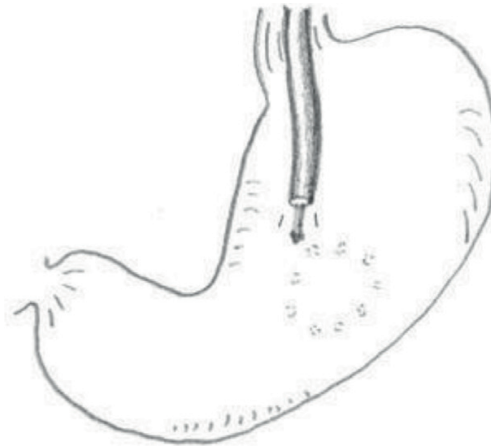
was named inverted LECS. Inverted LECS with crown method is not only useful for preventing tumor seeding into peritoneal cavity, but also for securing the visual field during the operation. The stitches are also used as a supporting tool when the incision line is closed with a laparoscopic stapling device (**Figure 17**). Although nonexposed endoscopic wall-inversion surgery (NEWS) [26] and a combination of laparoscopic endoscopic approaches to neoplasia with a nonexposure technique (CLEAN-NET) [27] are described later as nonexposure procedures, inverted LECS with crown method has few limitations such as tumor size or tumor location in comparison with NEWS or CLEAN-NET. As such, it can make it possible

to remove the tumor without the contamination of abdominal cavity. **Figures 16 and 17** are excerpted from Nunobe's report.

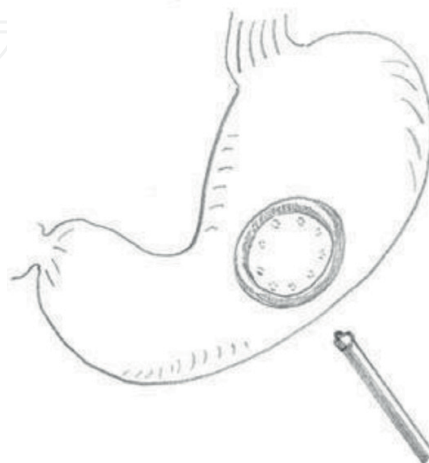
## 5. NEWS

Classical LECS with crown method is an improved technique that reduces the risk of cancer cell dissemination. However, it can be difficult to completely prevent the contamination because of transmural communication during the procedure. Nonexposed endoscopic wall-inversion surgery (NEWS) was first reported by Goto et al. in 2011 with the goal of minimizing transmural communication during the operation [26]. They performed NEWS in an *ex vivo* porcine model and described the usefulness of this procedure. By inverting the tumor into the inside of the stomach without opening the gastric lumen, complete resection with nonexposure was achieved. The procedure is as follows:

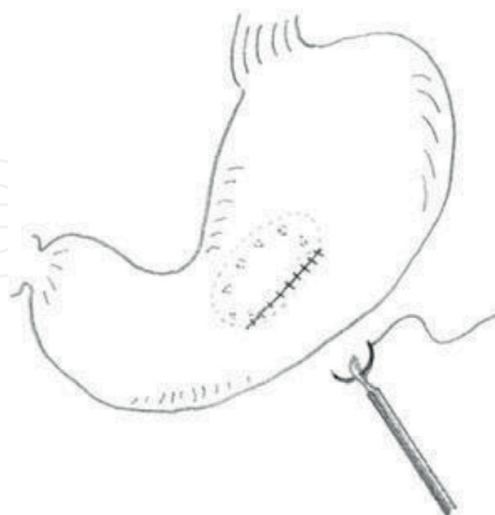1. "Markings around a model lesion are made with electrocautery knife."



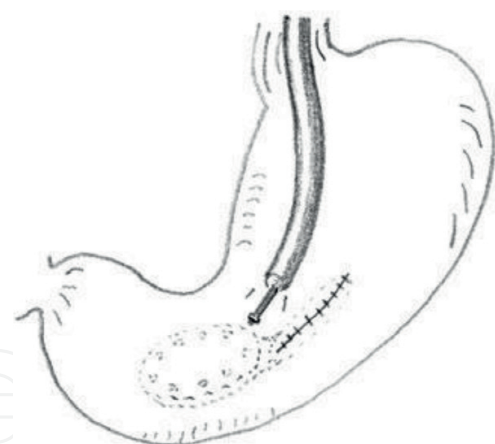
2. "A circumferential seromuscular incision is made from the outside."



3. "The muscle layer is linearly sutured at approximately 5 mm intervals with the lesion inverted into the inside."



4. "A circumferential mucosubmucosal incision is performed from inside with electrocautery knife guided by the endoscope." These figures are excerpted from Goto's report.



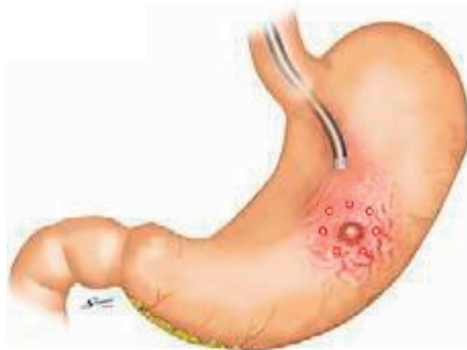
He reported NEWS for three lesions (one anterior wall, one lesser curve and one posterior wall of the gastric body) using porcine stomach, and complete resection was achieved for all lesions safely and without perforation or air leakage. Nonexposure techniques such as NEWS and CLEAN-NET are adequate for SMT without ulceration as well as SMT with ulceration or even early gastric cancer. In his report, the maximal specimen size was 50 mm; however, there is a limit of removable tumor size. Because the resected tumor is removed through the pharynx by the endoscope, solid tumor such as GIST over 30 mm is thought to be difficult to retrieve.



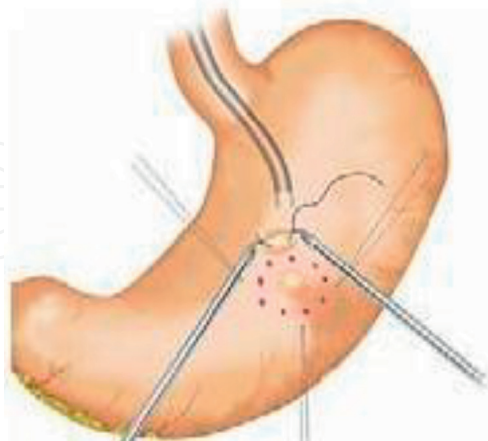
## 6. CLEAN-NET

A combination of laparoscopic endoscopic approaches to neoplasia with a nonexposure technique (CLEAN-NET) was first reported by Inoue et al. in [27]. This procedure also involves a nonexposure technique like NEWS, but with a difference. By preserving the continuity of the mucosa, the mucosa works as a barrier (a clean net), to prevent abdominal cavity contamination and seeding of tumor cells into the peritoneal cavity. The specimen is lifted from the peritoneal cavity, so it is retrieved laparoscopically. Inoue actively performs endoscopic and laparoscopic full-thickness resection for not only GISTs but also for early gastric cancer. The procedures are described below.

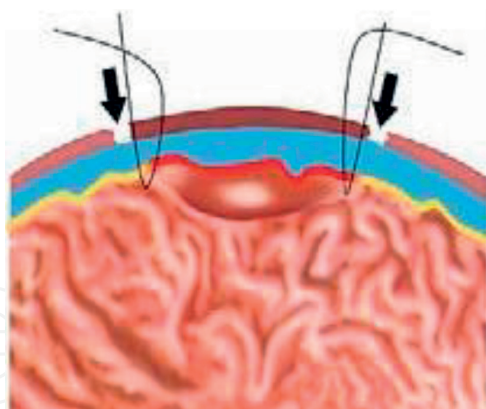
1. "Endoscopic markings are placed on the surrounding mucosa of the lesion with electrocautery knife."



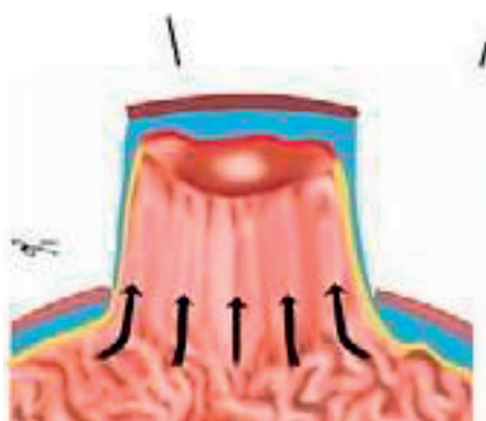
2. "The mucosal layer is fixed onto the seromuscular layer using four stay sutures."



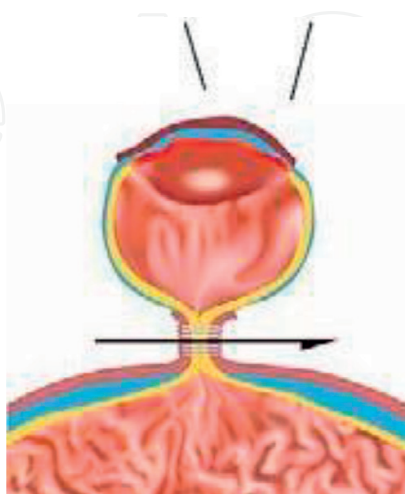
3. "By pulling four stitches upward with laparoscopic forceps, selective seromuscular dissection outside the four stitches is performed using a laparoscopic electrocautery knife."



4. "A full-layer specimen is lifted by four stay sutures. This process allows a wider cancer-free margin around a full-thickness lesion."



5. "A full-layer resection using a mechanical stapler is performed and the resected tumor is removed from abdominal cavity side." These figures are excerpted from Inoue's report.



The abovementioned procedure with nonexposure technique is advantageous for epithelial tumor and GIST with ulceration. CLEAN-NET also makes it possible to secure a sufficient margin around the tumor and to resect lymph nodes together with the tumor if it is located at either the lesser or greater curvature of the stomach. Because the CLEAN-NET procedure needs the process that the mucosal layer stretches without breaking apart, a large tumor is thought to be difficult to resect.

## 7. Laparoscopy-assisted endoscopic full-thickness resection

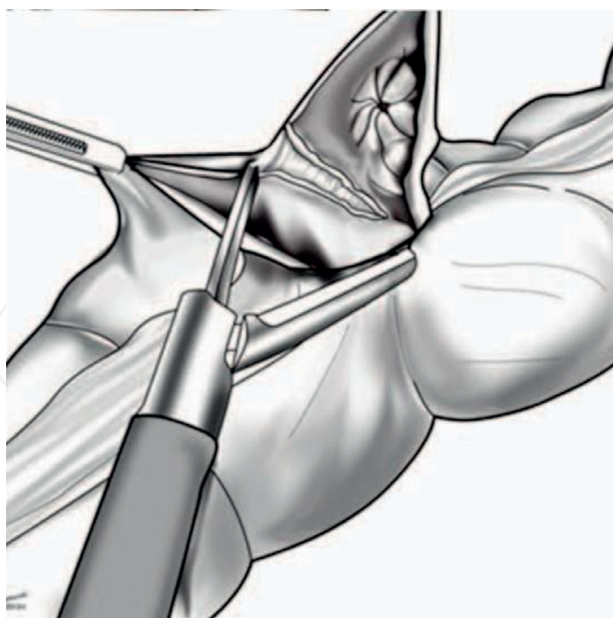
This technique was reported by Abe et al. in [28]. The same procedure as LECS technique is applied; however, the endoscopist plays an important role in resecting the tumor. The endoscopic team starts full-thickness resection around the tumor, and after two-thirds of the resection is performed, the laparoscopic team finishes the full-thickness resection with laparoscopic devices.

### 7.1. LECS for duodenal tumors

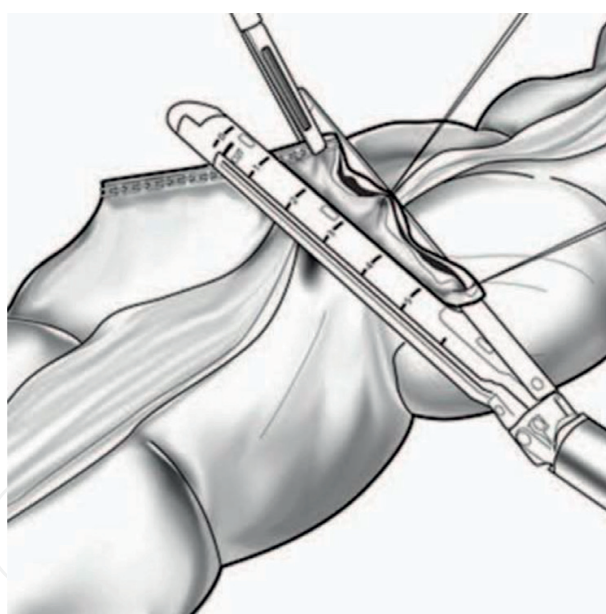
There are some limitations with LECS for removal of duodenal tumors. First, anatomical elements such as the pyloric ring, Vater's papilla and the third to fourth portion make it difficult to perform. Second, there are a few reports of lymph node metastasis from submucosal invading duodenal cancers or carcinoids, so partial resection is controversial. Small submucosal tumors, duodenal adenomas, or intramucosal carcinomas at duodenal bulb or the opposite side of the papilla are indications for LECS. The basic concept of gastric LECS also applies to duodenum LECS [4, 29]. The difficulty in mobilizing organs and closing the defected walls needs to be advanced.

### 7.2. LECS for colorectal tumors

LECS for colorectal tumors is not often used. We rarely experience GISTs in the colorectum, and in many cases the laparoscopist must achieve adequate mobilization which may be difficult in colorectal-LECS. Some researchers have reported the laparoscopy-assisted endoscopic resection (LAER) for colorectal tumors [30–32], and as the combined laparoscopic endoscopic resection (CLER). Fukunaga et al. reported LECS for laterally spreading colorectal tumors, which are difficult to resect by the ESD technique because of submucosal fibrosis or multiple surrounding diverticula [33] (**Figures 18 and 19**). He suggested several concerns about his technique: limitation for tumors located on the mesenteric side, strictures after surgery, and contamination of the abdominal cavity by bowel contents. He proposed several adjustments in his report. Indications for colorectal LECS are the same as for colorectal ESD. Tumors that would be difficult to resect endoscopically are good indications for both. **Figures 18 and 19** are excerpted from Fukunaga's report.



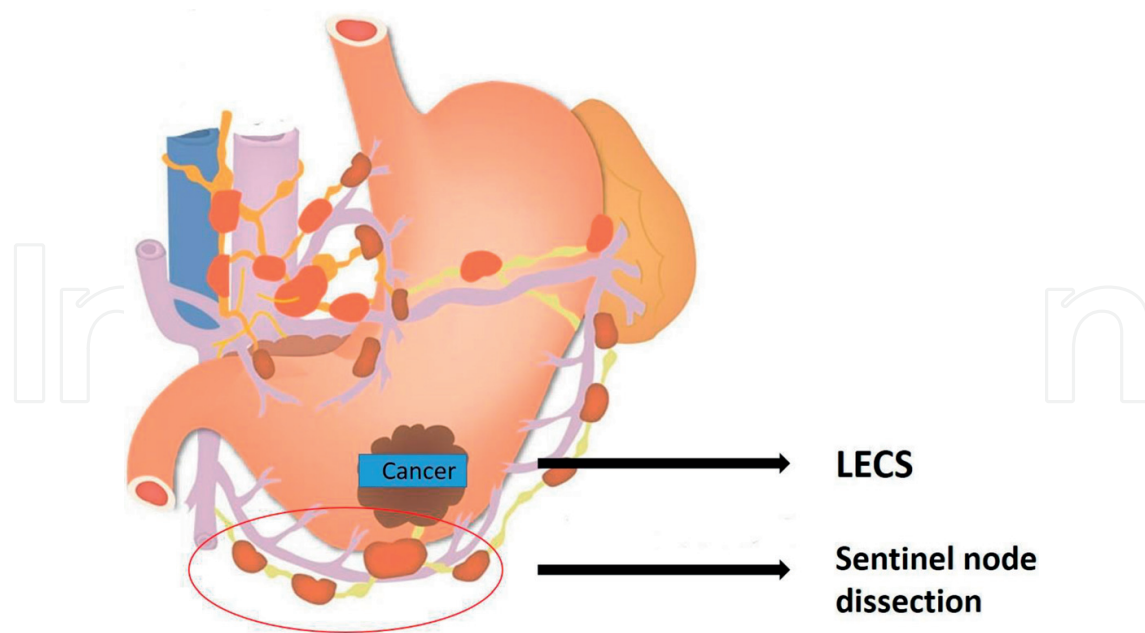
**Figure 18.** A laparoscopic coagulating system is used to dissect the full thickness of the colon wall along the submucosal line created by endoscopic dissection.



**Figure 19.** The incision line was closed using laparoscopic stapline devices. The **Figures 18** and **19** are excerpted from Fukunaga's report.

### 7.3. LECS plus biopsy to sentinel lymph node for early gastric cancer

The application LECS has progressed from resection of gastric submucosal tumors to early stage gastric cancer. The current therapeutic adaptation is for removal of low-risk lymph node metastases. Further, there still remains the possibility of lymph node metastasis in treating



**Figure 20.** By combining LECS technique and sentinel node biopsy, LECS with lymph node dissection might become possible in the future.

gastric cancer. On the other hand, some researchers reported the utility of sentinel node biopsy in patients with gastric cancer [34–36]. Although gastric lymphatic drainage is often complicated, by using the dual tracer method with radiolabeled tin colloid and blue dye, Kitagawa reported that the sentinel node detection rate was 97.5% (387 of 397) and the accuracy of nodal evaluation for metastasis was 99% (383 of 387) in cT1 and tumors <4 cm [36]. These facts implicate that by combining LECS technique and sentinel node biopsy, LECS with lymph node dissection might become possible in the future (**Figure 20**). More research and clinical trials about LECS and biopsy to sentinel lymph node for early gastric cancer are expected.

## Author details

Shunsuke Sakuraba

Address all correspondence to: [lunlun8shunsuke@gmail.com](mailto:lunlun8shunsuke@gmail.com)

Department of Surgery, Juntendo Shizuoka Hospital, Shizuoka, Japan

## References

- [1] Qiu WQ et al. Minimally invasive treatment of laparoscopic and endoscopic cooperative surgery for patients with gastric gastrointestinal stromal tumors. *Journal of Digestive Diseases*. 2013;**14**:469-473



- [2] Acker S et al. Laparoscopic-assisted endoscopic resection of a gastric leiomyoma. *European Journal of Pediatric Surgery Reports*. 2014;**2**:003-006
- [3] Kato M et al. Local resection by combined laparoendoscopic surgery for duodenal gastrointestinal stromal tumor. *Diagnostic and Therapeutic Endoscopy*. 2011;**2011**:645609
- [4] Irino T et al. Laparoscopic-endoscopic cooperative surgery for duodenal tumors: A unique procedure that helps ensure the safety of endoscopic submucosal dissection. *Endoscopy*. 2015;**47**(4):349-351
- [5] Ohara Y et al. Enormous postoperative perforation after endoscopic submucosal dissection for duodenal cancer successfully treated with filling and shielding by polyglycolic acid sheets with fibrin glue and computed tomography-guided abscess puncture. *Clinical Journal of Gastroenterology*. 2017;**10**:524-529
- [6] Fujihara S et al. Management of a large mucosal defect after duodenal endoscopic resection. *World Journal of Gastroenterology*. 2016;**22**(29):6595-6609
- [7] Tsujii Y et al. Clinical outcomes of endoscopic submucosal dissection for superficial esophageal neoplasms: A multicenter retrospective cohort study. *Endoscopy*. 2015;**47**:775-783
- [8] Shin KY et al. Clinical outcomes of the endoscopic submucosal dissection of early gastric cancer are comparable between absolute and new expanded criteria. *Gut and Liver*. 2015;**9**:181-187
- [9] Repici A et al. Efficiency and safety of endoscopic submucosal dissection for colorectal neoplasia: A systematic review. *Endoscopy*. 2012;**44**:137-150
- [10] Toyonaga T et al. Endoscopic submucosal dissection cases in the esophagus, stomach, and colorectum: Complication rates and long-term outcomes. *Surgical Endoscopy*. 2013;**27**:1000-1008
- [11] Ntourakis D et al. Cooperative laparoscopic endoscopic and hybrid laparoscopic surgery for upper gastrointestinal tumors: Current status. *World Journal of Gastroenterology*. 2015;**21**(43):12482-12497
- [12] Kang WM et al. Laparoscopic-endoscopic cooperative surgery for gastric submucosal tumors. *World Journal of Gastroenterology*. 2013;**19**:5720-5726
- [13] Privette A et al. Laparoscopic approaches to resection of suspected gastric gastrointestinal stromal tumors based on tumor location. *Surgical Endoscopy*. 2008;**22**:487-494
- [14] Wilhelm D et al. Simultaneous use of laparoscopy and endoscopy for minimally invasive resection of gastric subepithelial masses—Analysis of 93 interventions. *World Journal of Surgery*. 2008;**32**:1021-1028
- [15] Huguet KL et al. Laparoscopic gastric gastrointestinal stromal tumor resection: The mayo clinic experience. *Archives of Surgery*. 2008;**143**:587-590; discussion 591

- [16] Marano L et al. Combined laparoscopic-endoscopic “Rendez-vous” procedure for minimally invasive resection of gastrointestinal stromal tumors of the stomach. *The American Surgeon*. 2011;**77**:1100-1102
- [17] Sasaki A et al. Tailored laparoscopic resection for suspected gastric gastrointestinal stromal tumors. *Surgery*. 2010;**147**:516-520
- [18] Ohashi S et al. Laparoscopic intraluminal (intra-gastric) surgery for early gastric cancer. A new concept in laparoscopic surgery. *Surgical Endoscopy*. 1995;**9**:169-171
- [19] Dong HY et al. Modified laparoscopic intra-gastric surgery and endoscopic full-thickness resection for gastric stromal tumor originating from the muscularis propria. *Surgical Endoscopy*. 2014;**28**:1447-1453
- [20] Hiki N et al. Laparoscopic and endoscopic cooperative surgery for gastrointestinal stromal tumors dissection. *Surgical Endoscopy*. 2008;**22**(7):1729-1735
- [21] Hiki N et al. Laparoscopic endoscopic cooperative surgery. *Digestive Endoscopy*. 2015;**27**:197-204
- [22] Matsuda T et al. Laparoscopic endoscopic cooperative surgery (LECS) for the upper gastrointestinal tract. *Translational Gastroenterology and Hepatology*. 2017;**2**(40)
- [23] Hiki N et al. Function-preserving gastrectomy for early gastric cancer. *Annals of Surgical Oncology*. 2013;**20**:2683-2692
- [24] Matsuda T et al. Feasibility of laparoscopic and endoscopic cooperative surgery for gastric submucosal tumors (with video). *Gastrointestinal Endoscopy*. 2016;**84**:47-52
- [25] Nunobe S et al. Successful application of laparoscopic and endoscopic cooperative surgery (LECS) for a lateral-spreading mucosal gastric cancer. *Gastric Cancer*. 2012;**15**(3):338-342
- [26] Goto O et al. New method of endoscopic full-thickness resection: A pilot study of non-exposed endoscopic wall-inversion surgery in an ex vivo porcine model. *Gastric Cancer*. 2011;**14**(2):183-187
- [27] Inoue H et al. Endoscopic mucosal resection, endoscopic submucosal dissection, and beyond: Full-layer resection for gastric cancer with non-exposure technique (CLEAN-NET). *Surgical Oncology Clinics of North America*. 2012;**21**(1):129-140
- [28] Abe N et al. Successful-treatment of early stage gastric cancer by laparoscopy-assisted endoscopic full-thickness resection with lymphadenectomy. *Gastrointestinal Endoscopy*. 2008;**68**:1220-1224
- [29] Otowa Y et al. Safe management of laparoscopic endoscopic cooperative surgery for superficial non-ampullary duodenal epithelial tumors. *Endoscopy International Open*. 2017;**5**(11):E1153-E1158
- [30] Wilhelm D et al. Combined laparoscopic-endoscopic resections of colorectal polyps: 10-year experience and follow-up. *Surgical Endoscopy*. 2009;**23**:688-693

- [31] Wood JJ et al. Laparo-endoscopic resection for extensive and inaccessible colorectal polyps: A feasible and safe procedure. *Annals of the Royal College of Surgeons of England*. 2011;**93**:241-245
- [32] Yan J et al. Treatment for right colon polyps not removable using standard colonoscopy: Combined laparoscopic-colonoscopy approach. *Diseases of the Colon and Rectum*. 2011; **54**:753-758
- [33] Fukunaga Y et al. New technique of en bloc resection of colorectal tumor using laparoscopy and endoscopy cooperative (laparoscopy and endoscopy cooperative surgery – colorectal). *Disease of the Colon and Rectum*. 2014;**57**:2
- [34] An JY et al. Which factors are important for successful sentinel node navigation surgery in gastric cancer patients? Analysis from the SENORITA prospective multicenter feasibility quality control trial. *Gastroenterology Research and Practice*. 2017;**2017**:1732571, 7 pages
- [35] Huang L et al. Feasibility and diagnostic performance of dual-tracer-guided sentinel lymph node biopsy in cT1-2N0M0 gastric cancer: A systematic review and meta-analysis of diagnostic studies. *World Journal of Surgical Oncology*. 2017;**15**:103
- [36] Kitagawa Y et al. Sentinel node mapping for gastric cancer: A prospective multicenter trial in Japan. *Journal of Clinical Oncology*. 2013;**31**(29):3704-3710