

We are IntechOpen, the world's leading publisher of Open Access books Built by scientists, for scientists

6,900

Open access books available

186,000

International authors and editors

200M

Downloads

Our authors are among the

154

Countries delivered to

TOP 1%

most cited scientists

12.2%

Contributors from top 500 universities



WEB OF SCIENCE™

Selection of our books indexed in the Book Citation Index
in Web of Science™ Core Collection (BKCI)

Interested in publishing with us?
Contact book.department@intechopen.com

Numbers displayed above are based on latest data collected.
For more information visit www.intechopen.com



Quality of Life Following Intersphincteric Resections for Low Rectal Cancer: Early Results

Călin Molnar, Marian Botoncea,
Claudiu Varlam Molnar and Vlad-Olimpiu Butiurca

Additional information is available at the end of the chapter

<http://dx.doi.org/10.5772/intechopen.79727>

Abstract

Intersphincteric resections are part of the therapeutic arsenal that preserves the sphincterian apparatus. This chapter analyzes the evolution of rectal surgery leading up to intersphincteric resections, deals with anatomical and oncological aspects in rectal cancer, and finally shows our own personal experience with ISR in a series of 40 cases focusing on oncological outcomes, continence, and defecation. As a conclusion, intersphincteric resection represents a feasible therapeutic option in highly selected cases that exempts the patient from the need of a permanent colostomy bag without compromising oncological principles. The Wexner score system is simple and effective in objectifying continence in patients that undergo this type of surgery.

Keywords: intersphincteric resection, ISR, TME, functional outcomes, oncological outcome

1. Introduction

1.1. History of rectal surgery

Surgery for rectal cancer has been around ever since 1907, when William Ernest Miles performed the first rectal surgery with radical intent known today as abdominoperineal resection (APR) [1]. The intervention devised by Miles quickly gained followers, and for years, it established itself as a gold standard for rectal cancer. Miles based his procedure on the assumption that rectal cancer spreads in a cylindrical manner both downward and upward and thus both abdominal- and perineal approaches are necessary to completely remove the tumor. Sigmoid

division and rectal dissection were started from above and then completed in the perineal approach with total sphincter removal [1, 2]. The Miles procedure, albeit being seemingly satisfactory at the time from an oncological point of view, had a 58% 1-year survival rate and numerous complications. Even at that distant time, an important question arose regarding what the best level of arterial ligation and division should be in radical rectal resection [1]. That question is still to be answered.

Following Miles APR, Henri Albert Hartmann devised the Hartmann's procedure in 1921 or the anterior resection of the rectum that consisted of the removal of the rectum with preservation of the distal third, internal and external sphincter and a left flank permanent colostomy [1]. This intervention was designed as an alternative to APR in the case of proximal rectal tumors. The main goal of the Hartmann's procedure was to reduce complications and mortality rates. As previously stated, the indications for this procedure were tumors of the proximal rectum still leaving low rectum and mid rectum tumors with no other surgical option than APR. Both procedures left patients with a permanent colostomy that had a major impact on quality of life. At that time, the "colostomy bag industry" was underdeveloped and bags had frequent odor and leakage problems, eventually leading to patients refusing surgery that entailed a permanent colostomy. This obvious downside of APR and Hartmann's procedure led surgeons to develop techniques that allowed the preservation of the sphincter and normal defecation.

World events and WWII left the development of rectal surgery techniques in obscurity and it was only in 1948 when Claude F. Dixon presented the results of restorative anterior resection for proximal rectum and distal sigmoid tumors that rectal surgery took its first steps into sphincter saving techniques [3]. His data published in *Annals of Surgery*, showed a 5-year survival rate of 64% [3], as compared to Miles's procedure that had a 58% 1-year survival rate.

In 1951, Golligher, Dukes, and Bussey proved that local tumor spread in rectal cancer did not exceed 2 cm from tumor margins (cancer cells were discovered at >2 cm from the distal margin of tumor in only 2% of 1500 analyzed specimens); therefore, the authors considered that a 5-cm margin of clearance would have ensured a reasonable radicality [4]. These figures changed in the following years: first a safety margin of <5 cm and down to 2.5 cm was considered acceptable, then, in 1983, Nichols proved that a safety margin of 2 cm allows the same radicality of more extended resections with no change in overall survivals; finally, in most recent years, no differences in oncological outcomes were found with a safety margin of even <1 cm [5–7].

The work of Golligher, Dukes, Bussey, and Nichols set the premises for the development of sphincter saving techniques for tumors of the mid and lower part of the rectum. Their studies allowed surgeons to apply surgical techniques that exempt the patient from the need of a permanent colostomy bag while maintaining an acceptable oncological outcome. The decrease of the safety margin from <5 to <1 cm in rectal cancer surgery nowadays also led to the more detailed study in the anatomy of defecation and of the structures involved in continence. This interest of rectal surgeons coupled with patient request to avoid a colostomy bag following surgery set the premises for true sphincter saving surgery for mid and especially low rectal cancer.

One of the most important technological breakthrough in rectal cancer surgery was the development of surgical staplers. The diffusion of stapler technology and its application in surgery started in 1972 thanks to Mark Mitchell Ravitch who introduced stapler suturing in the GI tract [8]. The development of surgical staplers started in the Moscow Scientific Research Institute for experimental Surgical Apparatus and Instruments in the ex-Soviet Union after WWII and then found its way to the United States of America thanks to Dr. Nikolai Amosov [9]. The first use of circular staplers in rectal surgery was reported by Fain in 1975 who stated that the device made low colorectal anastomosis easier with a leakage rate like that of hand-sewn anastomosis [10]. The stapler was further refined in the 1980 by Knight and Griffen who introduced the double stapling technique for low colorectal anastomosis [11].

From 1980 to 1986, coloanal anastomosis, intersphincteric rectal dissection, and colonic-pouch anal anastomosis were introduced by Parks, Lazorthes, and Parc, respectively, with the aim to preserve or improve sphincter function even in low rectal tumors [5, 7].

In 1994, Schiessel further brought into light the intersphincteric resection for low rectal cancer by publishing a series of 34 patients with low rectal cancer that underwent ISR with good postoperative results focusing on postoperative continence.

1.2. TME: total mesorectal excision

The concept of TME was introduced by Heald in 1982 and it represents a true milestone in modern rectal cancer surgery [12]. As opposed to the interventions described by Miles, Hartmann, and Dixon that used blunt dissection of the mid and distal rectum without taking into account the subtle differences in anatomy of the rectum, Heald theorized that rectal cancer is “more apt to spread initially along the field of active lymphatic and venous flow” and that the mesorectal fascia itself is “impenetrable only in the sense of being an avascular interface between viscus and soma.” He named the said space as the *holy plane* (**Figure 1**).

Heald’s principle was grounded on the knowledge that “the plane which surrounds the mesorectum is created by its separate embryological origin;” whereas, the whole rectum and mesorectum, which have the same embryological origin, “are one distinct lymphovascular entity” [13].

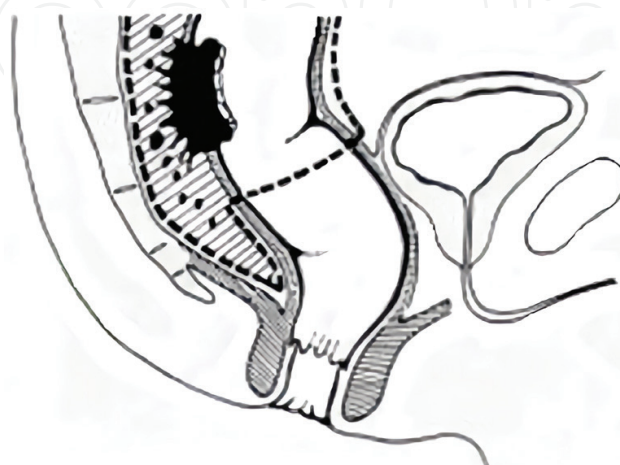


Figure 1. TME—Total mesorectal excision.

A surgical plane represents a “potential space between contiguous organs which can be reproducibly created by dissection” [13]. From a rectal surgeon’s point of view, this space is indeed a *holy plane* and finding the right plane during rectal surgery can mean the difference between a radical intervention and a palliative one. Dissection along this plane should be done under visual control, be sharp and be done under gentle continuous traction [13].

Performing TME during rectal surgery for mid and low rectal tumors caused an increase in survival rate topping at 80% at 5 years following surgery and a local recurrence rate of only 4%, thus proving Heald’s hypothesis [14].

1.3. Anatomy

The anal canal is the most terminal part of the lower gastrointestinal tract that lies between the anal verge (anus, anal orifice) in the perineum below and the rectum above.

The demarcation between the rectum above and the anal canal below is the anorectal ring or anorectal flexure, where the puborectalis muscle forms a sling around the posterior aspect of the anorectal junction, kinking it anteriorly. The anal canal is completely extraperitoneal. The length of the anal canal is about 4 cm (range, 3–5 cm), with two-thirds of this being above the pectinate line (also known as the dentate line) and one-third being below the pectinate line [15].

The pectinate line is the site of transition of the proctodeum below and the postallantoic gut above. It is a scalloped demarcation formed by the anal valves (transverse folds of mucosa) at the inferior-most ends of the anal columns. Anal glands open above the anal valves into the anal sinuses. The pectinate line is not seen on inspection in clinical practice, but under anesthesia the anal canal descends, and the pectinate line can be seen on slight retraction of the anal canal skin [15].

The anal canal just above the pectinate line for about 1–2 cm is called the anal pecten or transitional zone. Above this transitional zone, the anal canal is lined with columnar epithelium (which is insensitive to cutting). Anal columns (of Morgagni) are 6–10 longitudinal (vertical) mucosal folds in the upper part of the anal canal [15].

The anorectal junction or anorectal ring is situated about 5 cm from the anus. At the anorectal flexure or angle, the anorectal junction is pulled anterosuperiorly by the puborectal sling to continue below as the anal canal [15].

Levator ani and coccygeus muscles form the pelvic diaphragm. Lateral to the anal canal are the pyramidal ischioanal (ischioanal) fossae (1 on either side), below the pelvic diaphragm and above the perianal skin. The paired ischioanal fossae communicate with each other behind the anal canal [15].

The anterior relations of the anal canal are, in males, the seminal vesicles, prostate, and urethra, and in females, the cervix and vagina with perineal body in between. In front of (anterior to) the anal canal is the rectovesical fascia (of Denonvilliers), and behind (posterior) is the presacral endopelvic fascia (of Waldeyer), under which lie a rich presacral plexus of veins. Posterior to the anal canal lie the tip of the coccyx (joined to it by the anococcygeal ligament) and lower sacrum [15].

The anal canal is surrounded by several perianal spaces: subcutaneous, submucosal, intersphincteric, ischioanal (rectal), and pelvirectal [15].

1.4. Blood supply

The anal canal above the pectinate line is supplied by the terminal branches of the superior rectal (hemorrhoidal) artery, which is the terminal branch of the inferior mesenteric artery. The middle rectal artery (a branch of the internal iliac artery) and the inferior rectal artery (a branch of the internal pudendal artery) supply the lower anal canal.

Beneath the anal canal skin (below the pectinate line) lies the external hemorrhoidal plexus of veins, which drains into systemic veins. Beneath the anal canal mucosa (above the pectinate line) lies the internal hemorrhoidal plexus of veins, which drains into the portal system of veins. The anal canal is, therefore, an important area of portosystemic venous connection (the other being the esophagogastric junction). Lymphatics from the anal canal drain into the superficial inguinal group of lymph nodes.

1.5. Nerves

The advent of laparoscopic surgery and the awareness of the importance of autonomic nerve identification and preservation during rectal surgery both had a positive impact on the patients' postoperative quality of life. The identification of pelvic splanchnic nerves, the bundle of Walsh, hypogastric nerves identifications and plexus saving techniques lowered the rate of postoperative sexual and bladder dysfunction according to Hojo et al. [16].

In the era of laparoscopic surgery, minimally invasive surgery and robotic surgery rectal nerves visualization and preservation have become significantly easier. This is due to the optical magnification by even more sophisticated camera systems including 3D imaging and to the intraperitoneal pressure that "shows the surgeon the correct plane."

Long-term results of the first randomized controlled trials (CLASICC RCT, COLOR II RCT, ACOSOG Z6051 Study), all done between 2013 and 2015, are available. The oncological results are questionable, but postoperative pain and quality of life resulted significantly better after laparoscopic rectal resections [17–19].

2. Material and method

2.1. Case series

We performed a prospective study on a group of 40 patients admitted in the First Surgical Clinic of the Țirgu-Mureș Emergency County Hospital between 2015 and 2017. All patients were diagnosed with low rectal cancer. One of our main inclusion criteria was the flat denial of patients to have a permanent colostomy bag, even a temporary one. Patient's refusal was registered in the written informed consent. Tumor localization, tumor type, and the preoperative Wexner score were also considered alongside with preoperative antigen levels.

Most of the patients were from an urban background, 75% were males and none of them had a previous personal oncological background. Median age of the group was 66 years old.

2.2. ISR technique

Intersphincteric resections can be performed for type II (juxta-anal) or type III (intra-anal) low rectal tumors (<6 cm from the anal verge), cases in which partial intersphincteric resection is performed, respectively total intersphincteric resection [21].

The first part of the surgery starts with the primary vascular approach of the inferior mesenteric artery in all cases followed by left colon mobilization and ligation of the inferior mesenteric vein and TME (total mesorectal excision). This first aspect of the surgery can be done either by conventional surgery or using a laparoscopic or robotic approach, each with its own pros and cons. Conventional surgery in low volume centers has a smaller operative time as compared to laparoscopic approach, and it allows the surgeon direct mobilization and approximation of local tumor spread. Laparoscopic surgery, however, seems to be superior to conventional surgery regarding nerve identification and the use of nerve sparing techniques. Both the laparoscopic and robotic approaches require specialized instruments and have a long learning curve for the surgeon [20].

The intersphincteric groove is entered from the abdomen whenever possible to assess tumor invasion. The perineal part begins with digital and instrumental dilatation followed by the exposure of the anal canal using four to six traction threads (in the absence of a designated retractor). Following exposure, a circular incision is made on the anal mucosa distal to the dentate line—in the event of a total ISR—or at the level of it—for partial ISR. A minimum distance of 1 cm distally was maintained in all cases. The perineal phase continues with intersphincteric circumferential cranial preparation to meet the dissection plane from the abdomen. Following the completion of the dissection, the rectum is delivered through the anus with the transection of the sigmoid colon at the appropriate level. The final part of the surgery consists of a hand-sewn coloanal anastomosis.

2.3. Preoperative staging and preparation

Preoperative investigations consisted of a standard rectal touch, tumor biopsy with a malignant histopathology report. Preoperative imaging consisted of MR in most of cases and computed tomography in some of them and showed stage T2 tumors in all patients (tumor confinement to the rectal wall). Abdominal ultrasound and standard chest X-ray was also routinely performed to further assess the presence of distant metastatic disease.

All patients received long-term pelvic neoadjuvant radiotherapy with a total dose of 50 Gy for 5 weeks according to NCCN Guidelines, V2 and none of them received preoperative chemotherapy. From the entire series, 10 patients showed a type III inferior rectal tumor (intra-anal) and 30 had type II tumors (juxta-anal). From an antigen point of view, CEA and CA 19-9 levels were elevated in all cases and no signs of distant metastatic disease were found on preoperative imaging.

2.4. Preoperative sphincter function

We chose case series to evaluate the sphincter function using the Wexner score (**Figure 2**). There are numerous ways to evaluate the continence (FIQL, RAFST etc.), but we consider the Wexner score to be the easiest to accomplish and having the best correlation between the patient's perception of continence and the clinical assessment of the surgeon [22–24].

In our case series, we performed preoperative evaluation of the Wexner score in all patients followed by postradiotherapy evaluation. The Wexner score was calculated again at 3, 6 and 12 months following surgery to assess the continence. The median value of the preradiotherapy Wexner score was 7.65 and the median value for the preoperative (post neoadjuvant radiotherapy) was 4.9.

2.5. Surgery

All surgical procedures were performed by the same surgeon, 33 partial intersphincteric resections and 7 total intersphincteric resections for type II and III rectal tumors following the technique described above. In five cases, a partial laparoscopic approach was used, and in two cases, full laparoscopic surgery was performed.

Restoration of bowel continuity was achieved by performing a hand-sewn coloanal anastomosis with absorbable threads in all cases, without a protection ileostomy or colostomy. We did not perform a colonic J pouch in any patient. The technique consists of some key points illustrated below (**Figures 3–9**).

The WEXNER SCORE A Frequency Assessment Tool					
Type of Incontinence	Never	Rarely	Sometimes	Usually	Always
Solid	0	1	2	3	4
Liquid	0	1	2	3	4
Gas	0	1	2	3	4
Wear Pad	0	1	2	3	4
Lifestyle altered	0	1	2	3	4

Never -	0
Rarely -	Less than once a month
Sometimes -	Less than once a week or once a month
Usually -	Once a day or once a week
Always -	Once a day or more

Figure 2. Wexner score system.

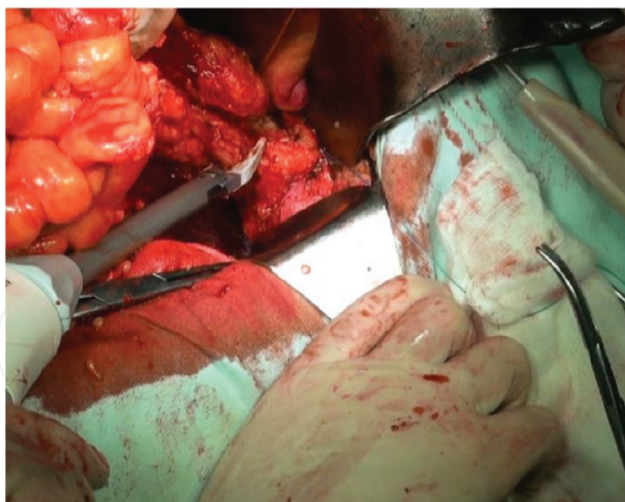

Figure 3. Mobilization of the sigmoid and rectum during the abdominal time.

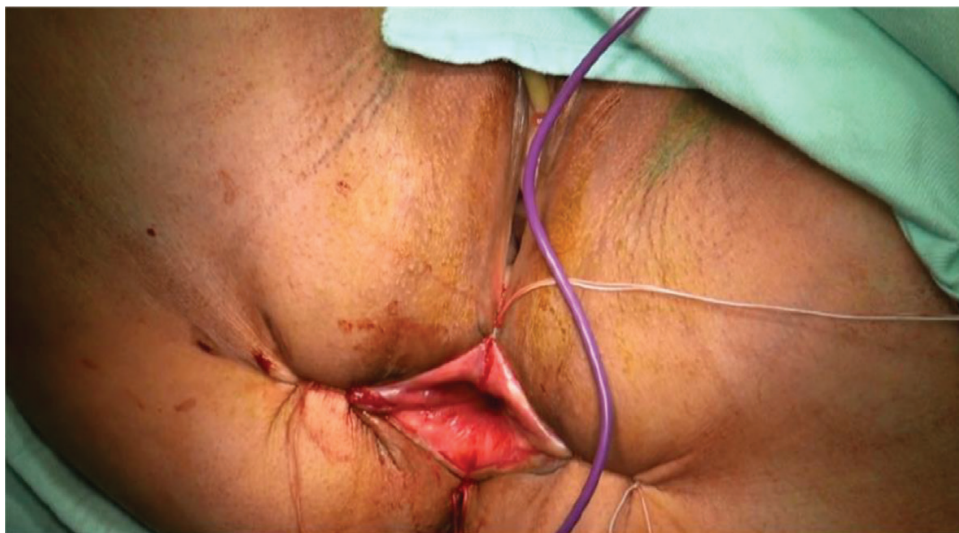

Figure 4. Exposure of the anal canal for the perineal time.

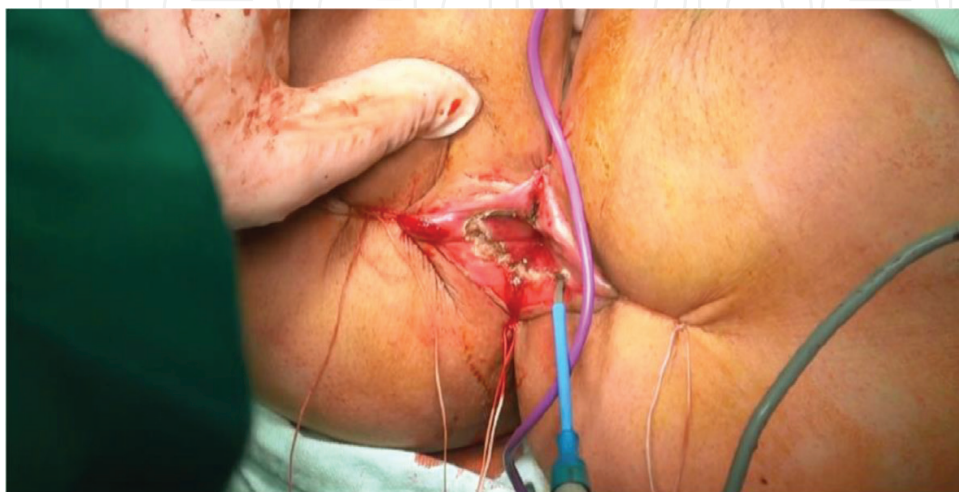

Figure 5. Demarcation of the anal resection line.

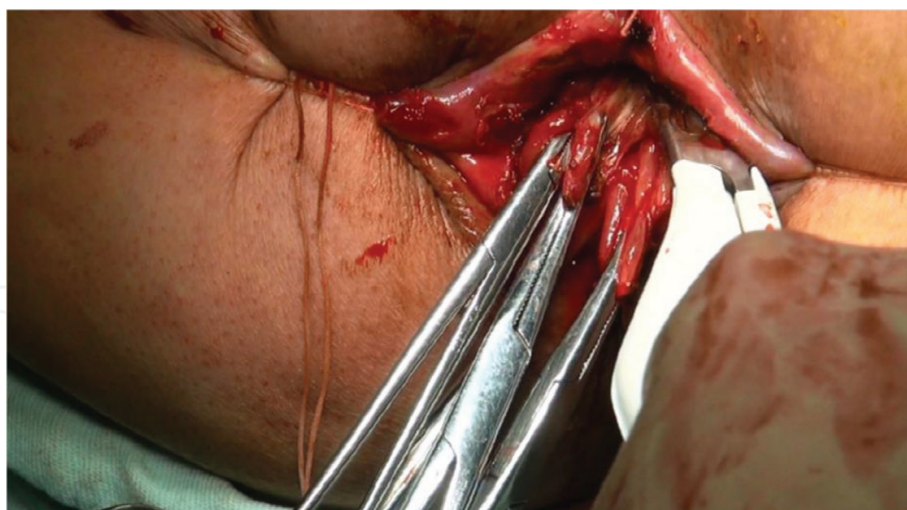


Figure 6. Intersphincteric removal of the anal canal.

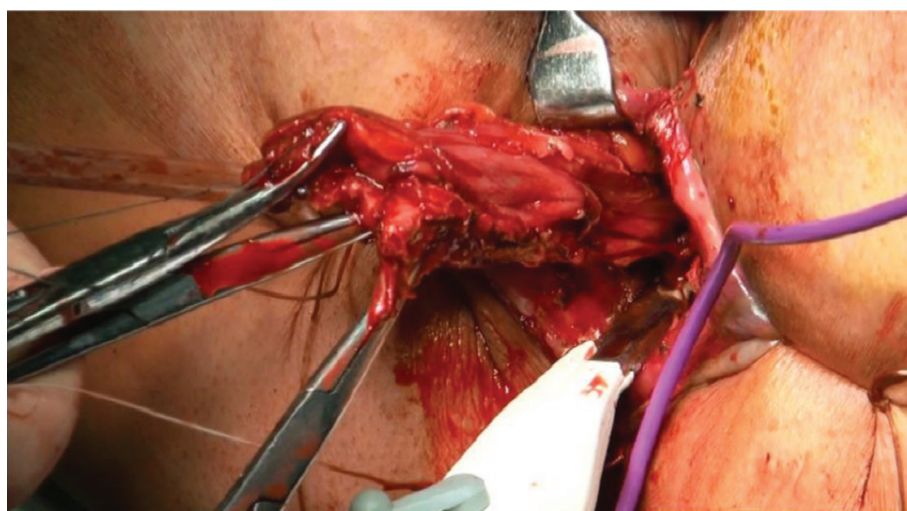


Figure 7. Advancement with the removal of the anal canal.

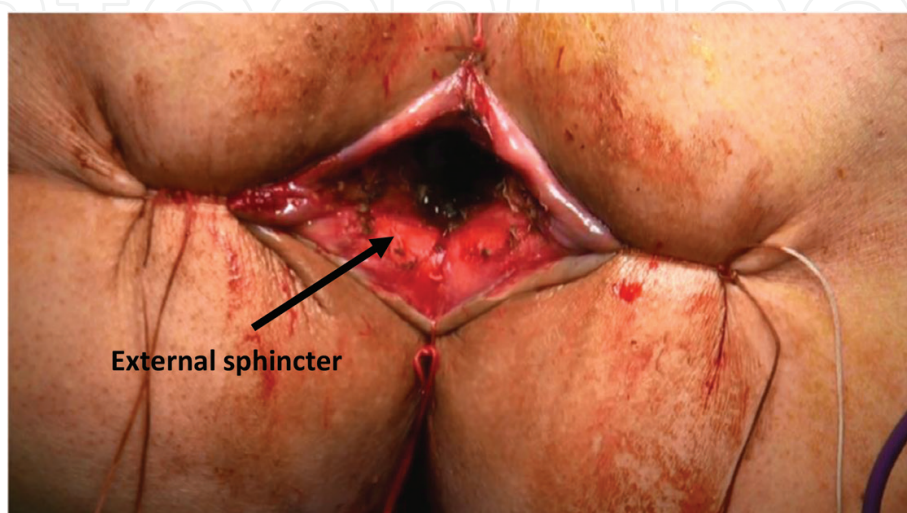


Figure 8. Anal sphincter—final aspect.

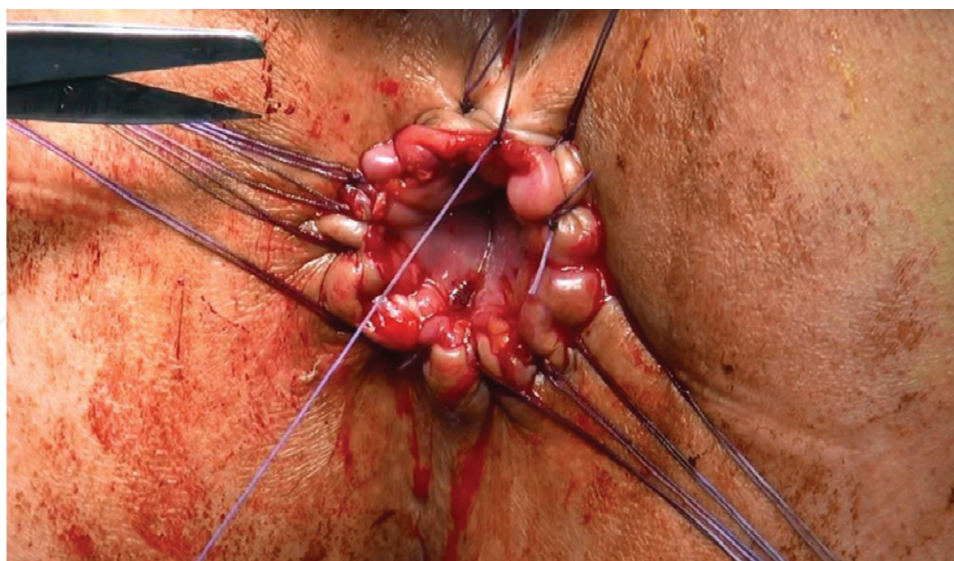


Figure 9. Colo-cutaneous hand-sewn anastomosis.

3. Results

The medium hospital stay was 9 days. Bowel movement resumed on the first or second day following surgery.

There were no perioperative complications and no hospital mortality was present. What we consider a minor complication was noted in the case of five patients at ~10 days following surgery in the form of a muco-submucosal necrosis at the level of the pulled throw colonic segment [25], complication treated in an ambulatory setting, without the need of anesthesia. This complication is probably due to mucosal ischemia. We recorded no wound infections/ wound dehiscence or intra-abdominal abscess. None of the patients developed anastomotic leakage or required a second surgery.

At 3 months after surgery, patients had no signs of local tumor recurrence on clinical exam and imaging (MR). CEA and CA 19-9 levels were still elevated in the case of 22 patients 3 months following surgery. The Wexner score obtained at this time showed a median value of **13.2**. The patients subjectively reported a relatively unsatisfactory continence especially in the case of gas.

At 6 months following surgery, only three patients had elevated CEA and CA 19-9 levels. Clinical exam and imaging invalidated the presence of local relapse or the existence of metastatic disease except for one case that presented with sacrum local recurrence (**Figure 10**) that required removal. The Wexner score obtained at this time showed a median value of **9.7**. Subjectively, patients reported a satisfactory continence with few episodes/week of especially gas incontinence.

At 12 months postoperative all patients showed normal CEA and CA 19-9 values. Clinical exam and follow-up imaging invalidated the presence of local relapse or existence of metastatic

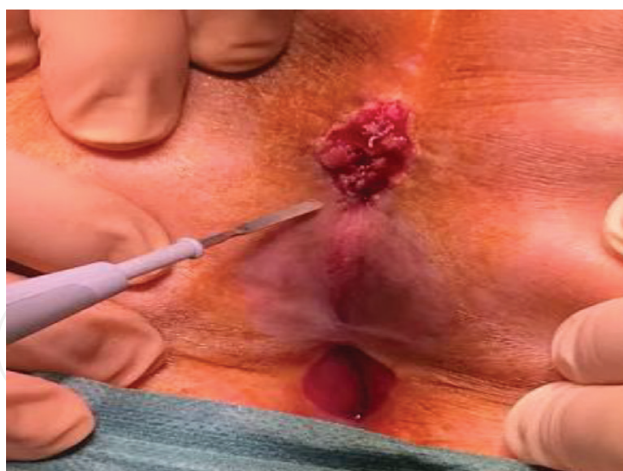

Figure 10. Local recurrence at 6 months following surgery.

disease. The median Wexner score was 8.2 in the case of these patients, and they declared that they are satisfied regarding the choice of surgery and the level of continence, under the terms of major surgery.

4. Discussions

Although intersphincteric resections are relatively “new to the surgeon’s arsenal” numerous studies have been published regarding its effectiveness and overall satisfaction of patients following this type of surgery. Hohenberger et al. found that in carcinomas of the lower third of the rectum, the application of abdomino-peranal intersphincteric resection can reduce the need for rectal excision by 20%. Neo-/adjuvant radiochemotherapy is required to reduce locoregional recurrence to an acceptable level [26]. These findings are consistent with our own findings in our relatively small group.

The “father” of intersphincteric resections, Schiessel states that in a study consisting of 121 patients, the technique has satisfactory long-term results not only in functional and oncologic respects, but also states that an important aspect is the preoperative correct staging of cases. Preoperative imaging consisting of MRI, sphincter manometry is mandatory. Case selection is the key to success [27].

5. Conclusions

Intersphincteric resections seem to be a feasible option in highly selected cases with low rectal cancer that refuse the presence of a colostomy bag be it a temporary one.

Oncologic outcome is like that of classic procedures.

Functional outcomes are satisfactory following ISR from the patient’s point of view.

Complications found in our small study group are “mild” and seldom met as compared to complications reported in the case of abdominoperineal resections.

Other authors have also evaluated found ISR to be satisfactory from an oncological point of view. In one study, authors report a 3-year disease-free survival in ISR group was 97% and a 5-year disease-free survival was 93% [28].

Acknowledgements

“Publications of this chapter has been funded by the “Toma Ionescu” Foundation, Gheorghe Marinescu Street no. 50, Targu-Mures, Romania.”

Conflict of interest

The authors declare no conflict of interest in preparing this article.

Funding

This research received no specific grant from any funding agency in the public, commercial, or not-for-profit sectors.

Limitations of the study

The limitations of this study are represented by the low number of cases, our center not being a colorectal surgery center thus the addressability of the patients is low. Our study is focused predominantly on the use of the Wexner score system for the evaluation of sphincter function, other scoring systems (Rothenberger, Vaizey, Fecal Incontinence Severity Index) could provide a better assessment of the functional outcome, but the easiest score to use is in our opinion the Wexner. The short-term follow-up is another inconvenient of the study, the results being preliminary. Follow-up of these patients is ongoing.

Abbreviations

APR	abdominoperineal resection
WWII	World War Two
GI tract	gastrointestinal tract
ISR	intersphincteric resection

TME	total mesorectal excision
MR	magnetic resonance
CT	computed tomography

Author details

Călin Molnar¹, Marian Botoncea^{2*}, Claudiu Varlam Molnar³ and Vlad-Olimpiu Butiurca⁴

*Address all correspondence to: botonceam@gmail.com

1 Head of Surgery, M5 Department, University of Medicine and Pharmacy Tîrgu-Mureş, Tîrgu-Mureş Emergency County Hospital, Tîrgu-Mureş, Romania

2 Surgery Department, University of Medicine and Pharmacy Tîrgu Mureş, Tîrgu Mureş Emergency Clinical County Hospital, Tîrgu Mureş, România

3 Obstetrics and Gynecology Department, University of Medicine and Pharmacy Tîrgu Mureş, Tîrgu Mureş Emergency Clinical County Hospital, Tîrgu Mureş, România

4 Surgery Department, University of Medicine and Pharmacy of Tîrgu Mureş, Tîrgu Mureş Emergency Clinical County Hospital, Mureş County, România

References

- [1] Lirici MM, Hüscher CGS. Techniques and technology evolution of rectal cancer surgery: A history of more than a hundred years. *Minimally Invasive Therapy & Allied Technologies*. 2016;**25**(5):226-233. DOI: 10.1080/13645706.2016.1198381
- [2] Perry WB, Connaughton JC. Abdominoperineal resection: How is it done and what are the results? *Clinics in Colon and Rectal Surgery*. 2007;**20**(3):213-220. DOI: 10.1055/s-2007-984865
- [3] Dixon CF. Anterior resection for malignant lesions of the upper part of the rectum and lower part of the sigmoid. *Annals of Surgery*. 1948;**128**(3):425
- [4] Goligher JC, Dukes CE, Bussey HJR. Local recurrences after sphincter-saving excisions for carcinoma of the rectum and rectosigmoid. *British Journal of Surgery*. 1951;**39**(155):199-211
- [5] Reguero JL, Longo WE. The evolving treatment of rectal cancer. In: *Modern Management of Cancer of the Rectum*. London: Springer; 2015. pp. 1-12
- [6] Pollett WG, Nicholls RJ. The relationship between the extent of distal clearance and survival and local recurrence rates after curative anterior resection for carcinoma of the rectum. *Annals of Surgery*. 1983;**198**(2):159
- [7] Lange MM, Rutten HJ, Van de Velde CJH. One hundred years of curative surgery for rectal cancer: 1908-2008. *European Journal of Surgical Oncology*. 2009;**35**(5):456-463

- [8] Ravitch MM, Hirsch LC, Noiles D. A new instrument for simultaneous ligation and division of vessels, with a note on hemostasis by a gelatin sponge-staple combination. *Surgery*. 1972;**71**(5):732-737
- [9] Vitone E. The surgical curmudgeon. *Pitt Med*. 2013;**Spring**:19-23
- [10] Fain SN, Patin CS, Morgenstern L. Use of a mechanical suturing apparatus in low colorectal anastomosis. *Archives of Surgery*. 1975;**110**(9):1079-1082
- [11] Knight CD, Griffen FD. An improved technique for low anterior resection of the rectum using the EEA stapler. *Surgery*. 1980;**88**(5):710-714
- [12] Heald RJ, Husband EM, Ryall RDH. The mesorectum in rectal cancer surgery – The clue to pelvic recurrence? *British Journal of Surgery*. 1982;**69**(10):613-616
- [13] Heald RJ. The 'Holy Plane' of rectal surgery. *Journal of the Royal Society of Medicine*. 1988;**81**(9):503
- [14] Heald RJ, Moran BJ, Ryall RD, Sexton R, MacFarlane JK. Rectal cancer: The Basingstoke experience of total mesorectal excision, 1978-1997. *Archives of Surgery*. 1998;**133**(8):894-898
- [15] Sinnatamby CS. *Last's Anatomy e-Book: Regional and Applied*. Elsevier Health Sciences; 2011
- [16] Hojo K, Sawada T, Moriya Y. An analysis of survival and voiding, sexual function after wide iliopelvic lymphadenectomy in patients with carcinoma of the rectum, compared with conventional lymphadenectomy. *Diseases of the Colon & Rectum*. 1989;**32**(2):128-133
- [17] Green BL, Marshall HC, Collinson F, Quirke P, Guillou P, Jayne DG, Brown JM. Long-term follow-up of the Medical Research Council CLASICC trial of conventional versus laparoscopically assisted resection in colorectal cancer. *British Journal of Surgery*. 2013;**100**(1):75-82
- [18] Bonjer HJ, Deijen CL, Abis GA, Cuesta MA, van der Pas MH, de Lange-de Klerk ES, Rosenberg J. A randomized trial of laparoscopic versus open surgery for rectal cancer. *New England Journal of Medicine*. 2015;**372**(14):1324-1332
- [19] Fleshman J, Branda M, Sargent DJ, Boller AM, George V, Abbas M, Fichera A. Effect of laparoscopic-assisted resection vs open resection of stage II or III rectal cancer on pathologic outcomes: The ACOSOG Z6051 randomized clinical trial. *JAMA*. 2015;**314**(13):1346-1355
- [20] Molnar C, Vlad-Olimpiu B, Marian B, Cornelia T, Simona G. Survival and functional and oncological outcomes following intersphincteric resection for low rectal cancer: Short-term results. *Journal of International Medical Research*. 2018;**46**(4):1617-1625
- [21] Rullier E, Denost Q, Vendrely V, Rullier A, Laurent C. Low rectal cancer: Classification and standardization of surgery. *Diseases of the Colon & Rectum*. 2013;**56**(5):560-567

- [22] de la Portilla F, Calero-Lillo A, Jiménez-Rodríguez RM, Reyes ML, Segovia-González M, Maestre MV, García-Cabrera AM. Validation of a new scoring system: Rapid assessment faecal incontinence score. *World Journal of Gastrointestinal Surgery*. 2015;7(9):203
- [23] Bols EM, Hendriks EJ, Berghmans BC, Baeten CG, de Bie RA. A critical evaluation of the Vaizey score, Wexner score and the fecal incontinence quality of life scale for clinical use in patients with faecal incontinence. *Pelvic Physiotherapy in Faecal Incontinence*. 2011;169
- [24] Rodrigues BDS, Reis IGN, de Oliveira Coelho FM, Buzatti KCDLR. Fecal incontinence and quality of life assessment through questionnaires. *Journal of Coloproctology*. 2017
- [25] Molnar C, Butiurca VO. Muco-submucosal necrosis-early novel complication following Intersphincteric resections. *Austin Journal of Pathology & Laboratory Medicine*. 2017; 4(1):1017. ISSN: 2471-0156
- [26] Hohenberger W, Merkel S, Matzel K, Bittorf B, Papadopoulos T, Göhl J. The influence of abdomino-peranal (intersphincteric) resection of lower third rectal carcinoma on the rates of sphincter preservation and locoregional recurrence. *Colorectal Disease*. 2006;8(1):23-33
- [27] Schiessel R, Novi G, Holzer B, Rosen HR, Renner K, Hölbling N, Urban M. Technique and long-term results of intersphincteric resection for low rectal cancer. *Diseases of the Colon & Rectum*. 2005;48(10):1858-1867
- [28] Tulina IA, Bredikhin MI, Gerasimov AN, Krylov NN, Reshetov IV, Tsarkov PV. Intersphincteric resection for stage I-III low rectal cancer is an oncologically safe alternative to extralevator abdomino-perineal rectal resection. *Khirurgiia*. 2017;4:61-68

