

We are IntechOpen, the world's leading publisher of Open Access books Built by scientists, for scientists

6,900

Open access books available

186,000

International authors and editors

200M

Downloads

Our authors are among the

154

Countries delivered to

TOP 1%

most cited scientists

12.2%

Contributors from top 500 universities



WEB OF SCIENCE™

Selection of our books indexed in the Book Citation Index
in Web of Science™ Core Collection (BKCI)

Interested in publishing with us?
Contact book.department@intechopen.com

Numbers displayed above are based on latest data collected.
For more information visit www.intechopen.com



Temporomandibular Joint Disorders and Tinnitus

Henrique F. Pauna, Maria S.A. Amaral and Miguel Â. Hyppolito

Abstract

Tinnitus is defined as a sound a person hears that is generated by the body, rather than by outside source. The word tinnitus is derived from the Latin “*tinnire*” meaning “to ring” and is perceived as ringing, buzzing, or hissing in or around the ear(s). Approximately 50 million Americans are affected, while there is a prevalence of 10% in the United Kingdom among adult population. It has multiple etiologies and is sometimes idiopathic. Tinnitus may vary widely to pitch, loudness, description of sound, special localization, and temporal pattern. Most often, tinnitus is associated with other aural symptoms, such as hearing loss and hyperacusis. Tinnitus may result in sleep disturbances, work impairments, distress. Males are more likely to suffer from tinnitus. In the mechanically demanding and biochemically active environment of the temporomandibular joint (TMJ), therapeutic approaches are capable of restoring joint functionality. TMJ treatments including splints, occlusal adjustments, and jaw exercises have been shown to be more effective than no treatment. The following chapter presents a synopsis of etiology, current treatment methods, and the future of tissue engineering for repairing and/or replacing diseased joint components, specifically the mandibular condyle and TMJ disc.

Keywords: tinnitus, temporomandibular joint, anatomical interactions, multidisciplinary approach, hypersensitivity

1. Introduction

Tinnitus is a sensation of sound perceived by the individual regardless of external sound stimulus. It is a symptom present or considered as a manifestation of different diseases. It can be manifested as a simple noise with no clinical complaining, or intense enough to prohibit the social activities of the individual. Up to 50% of cases are tinnitus, the etiology of which is unknown, but often tinnitus is associated with hearing loss, trauma, or ototoxic medication leading to cochlear damage, with sustained neural changes in the central auditory system causing such lesions [1, 2].

The global prevalence of tinnitus reaches 14–32%. It occurs at all ages and increases with aging, which can affect both men and women alike. Approximately 4% of the North American population suffers from a severe form of tinnitus [3, 4]. In a more recent meta-analysis, McCormack et al. found a prevalence of tinnitus ranging from 5.1 to 42.7%. They also found that tinnitus is commonly observed among elderly population (8–20% in individuals above the age of 60 years) [5].

Disabling tinnitus was considered by the “Public Health Agency of America” in 1984 and 1985 to be the third worst condition a person can have [6].

One of the most known classifications to address tinnitus is the one that address to its source of origin. Tinnitus can originate from the sensorineural hearing system and para-auditory system. Tinnitus classified as sensorineural origin occurs due to injury and/or functional breakdown in the sensorineural hearing system, whether in the inner ear or the central auditory pathways. Tinnitus originated from the para-auditory system can be caused by vascular or muscular structures [7].

Tinnitus originated from the sensorineural hearing system is more frequent than the tinnitus originated from the para-auditory system and may be accompanied by a hearing loss (more frequently) or not [8].

2. Physiopathology of tinnitus

The pathophysiology of tinnitus of sensorineural origin has not yet been fully established, although some authors believe that tinnitus would be the result of an exacerbated neuronal activity in the auditory pathways, usually of an excitatory nature, which would be interpreted as sound by the auditory cortex [9].

Both expression and intensity of tinnitus are difficult to quantify, leading to diagnostic, prognostic, and therapeutic difficulties. Several methods of examination, such as clinical and laboratory tests, scales and questionnaires, have been proposed to measure the intensity of tinnitus [10, 11]. However, the internal contradictions of each of these methods, such as the imprecision of the tests, limit the possibility of establishing a safety application tool focused on the manifestation of these symptoms.

In 1995, Zenner and Ernst hypothesized that tinnitus generation was due to cochlear disorders caused by mechanical trauma or altered blood supply, leading to changes in the properties of inner ear hair cells, increasing spontaneous neurotransmission, increasing the activity of the auditory nerve fibers, and, consequently, tinnitus [12]. Henry et al. described that central neuronal activity would be the basis of tinnitus. Deafferentation of the resulting VIII cranial nerve leads to a central increase of upward regulation, thus increasing spontaneous activity, burst activity, and neural synchrony of the central auditory system [13].

Connections between the dorsal column and trigeminal systems, where the projections end in the cochlear nucleus (CN), have been demonstrated [14, 15]. Excitation of the ventral CN (VCN) neurons in the absence of sound upon stimulation of the trigeminal ganglion has also been documented, and others have shown both excitation and inhibition in dorsal CN (DCN) neurons [16, 17].

According to the animal theory proposed by Shore et al., cochlear damage triggers tinnitus by inducing aberrant stimulus to central auditory structures and increasing the spontaneous activity in the DCN and VCN neurons [15, 18]. The study also shows an increased activity in DCN fusiform cells as a result of upregulation of the glutamatergic somatosensory innervation or changes in glycine receptors [19].

Tinnitus can be a manifestation of a turbulent blood flow near to the auditory pathways, caused by a vascular pathology (such as fistulas or aneurysms) [8]. Tinnitus can also be caused by myoclonic activity of the muscles of the middle ear or the palate, or by functional alterations of the stomatognathic system (such as dental problems, alteration of the condyle position, or loss of the dental support). Individuals with temporomandibular disorders (TMDs) may complain of tinnitus in 33–46% of cases [3, 4]. TMD is related to occlusal, emotional, and

neuromuscular (in the mastication muscles). TMD pain may be a contributing factor in the generation of tinnitus, with great interest among many areas [4, 20, 21].

The pathophysiology of tinnitus caused by TMD, as well as the pathophysiology of sensorineural tinnitus, is also a controversial subject. Some authors believe that tinnitus caused by TMD could be explained by many craniofacial nociceptive receptors (such as the ones present under the skin, fascia, periosteum, fibrous capsule, and temporomandibular joint (TMJ) ligaments). These receptors would be stimulated by mechanical forces that deform or alter the surrounding tissues resulting from the inflammatory process and ischemia [22, 23]. In addition, it was proposed that innervation plays a role in the vascular tone of cochlear blood vessels and may also provide a pathophysiological explanation for ear manifestations that occur in trigeminal nerve irritation as in TMD and may lead to tinnitus sensation [24, 25, 26].

3. Anatomical relationship of the ear and temporomandibular joint

Temporomandibular joint is a ginglymoarthrodial joint (meaning hinge joint which permits a gliding motion of the surfaces) that allows the movement in one plane—backward and forward. The TMJ forms a bicondylar articulation with an elliptical shape, and its articular surface is covered by a fibrocartilage (**Figure 1**) [27]. Movement is guided by the shape of the bones, muscles, ligaments and also by the occlusion of the teeth.

3.1 Mandibular component

It consists of an ovoid condylar process seated atop a narrow mandibular neck. It is 15–20 mm side to side and 8–10 mm from front to back. Thus, if the long axes of two condyles are extended medially, they meet at approximately the basion on the anterior limit of the foramen magnum, forming an angle that opens toward the front ranging from 145 to 160°. The articular surface lies on its anterosuperior aspect, thus facing the posterior slope of the articular eminence of the temporal bone [27, 28].

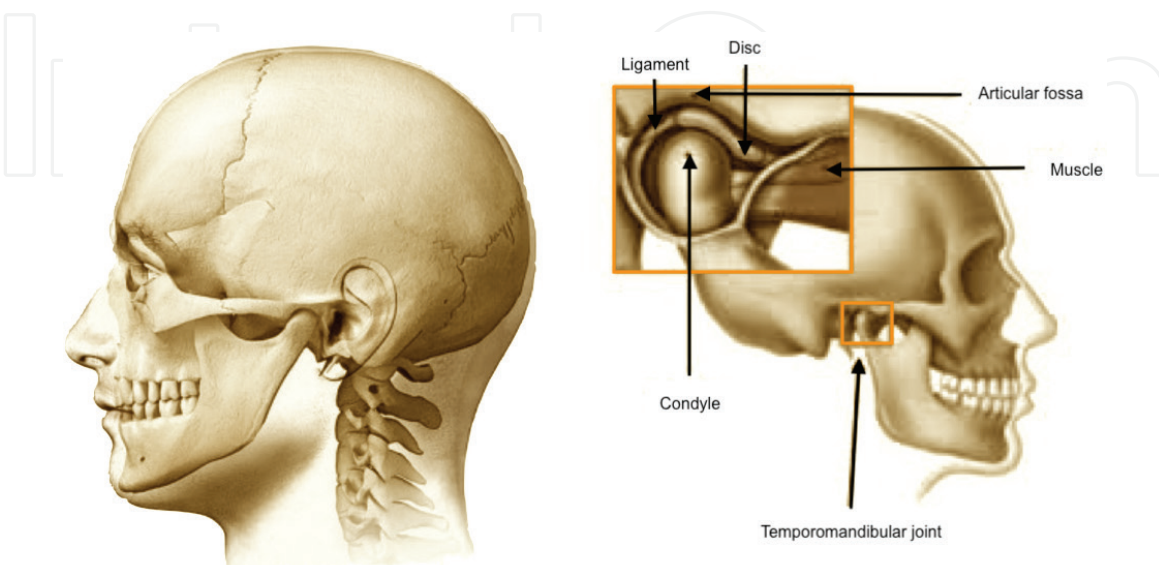


Figure 1.
Left: General picture of the relationship of TMJ and other cranial structures. Right: A closer image of the components of the TMJ.

The mandibular condyle varies greatly among different ages and individuals. Morphologic changes occur based on each individual's development as well as remodeling secondary to malocclusion, trauma, and other developmental abnormalities [28].

3.2 Articular disc

The articular disc is a biconcave fibrocartilaginous structure located between the mandibular condyle and the temporal bone. The articular disc—the most important structure of the TMJ—is an oval fibrous plate. The superior surface of the disc is saddle-shaped to fit into the cranial contour, and the inferior surface is concave to fit against the mandibular condyle.

The disc is attached all around the joint capsule except for the medial and lateral condylar poles, which ensure that it moves in protraction and retraction [29].

Functionally, the condyle and the disc are seated more anteriorly. When the jaw is opened, the condyle moves down and forward (translates). The upper part of the retrodiscal attachment has a rather prominent vascular shunt, and this vascular network is contained within loosely organized fat, collagen, and elastin [30].

3.3 Fibrous capsule

This is a thin tissue completely surrounding the joint. On the lateral part of the joint, the capsule functionally limits the condyle to move forward. This capsule is reinforced more laterally by an external TMJ ligament, which also limits the posterior movement of the condyle.

The synovial membrane covers all the intra-articular surfaces except the pressure-bearing fibrocartilage. The lower and upper compartments form fluid-filled sulci in the joint. These sulci change shape during translatory movements, which requires the synovial membrane to be flexible [31].

3.4 Muscular component

The masticatory muscles surrounding the joint are groups of muscles that contract and relax in harmony so that the jaws function properly. Different muscles are required for the opposite movements of the mandible. These muscles are abductors (jaw openers) and adductors (jaw closers). The temporalis, masseter, and medial pterygoids muscles are adductors, while the lateral pterygoids muscles are the primary abductors of the jaw.

4. Physiopathology of temporomandibular joint disorder

A large percentage of individuals with tinnitus report tinnitus modulation by TMJ and head and neck maneuvers. Up to half the patients who have TMJ dysfunction have tinnitus as one of their symptoms, and in these patients, success rates in eliminating these sounds approach 90%. This suggests that the auditory pathway inputs from the cranial nerves and upper cervical region of the spinal cord are more important in modulating tinnitus than the inputs from the caudal spinal cord [15].

It has been established that, while progressive and regressive, mechanically induced remodeling is a normal process early on. When the capacity for the joint to remodel has been exceeded, remodeling merges into osteoarthritis. Characteristic osteoarthritic changes observed in the TMJ include alterations in shape and overall size of joint components. Degenerative remodeling present in pathologic TMJs

may result from either decreased adaptive capacity in the articulating structures or from excessive or sustained physical stress to the articulating structures [32]. Microtrauma of the TMJ (which is caused by bruxism or jaw tightening) or macrotrauma of the TMJ (punch to the jaw or impact in an accident) can lead to muscle inflammation, dislocation of the TMJ, or damage to the cartilaginous disc. Other inflammatory diseases, such as osteoarthritis, may cause degeneration of the cartilage and increased blood flow that may lead to a greater number of inflammatory cells close to the TMJ and the ear. This increase in blood flow may be suggestive of tinnitus perception.

The TMD has as signs and symptoms the limitation of mouth opening, the presence of articular noises during its opening and/or closing, and pain in the musculature of the face and in the TMJ to chew, both uni- and bilaterally. TMD may be presented with chronic pain in the head and neck region, in the cervical region, and the TMJ itself [33].

There are three main theories behind why problems with the TMJ may cause tinnitus or make it worse. Firstly, the chewing muscles are near to some of the muscles that insert into the middle ear (tensor tympani muscle) and so may have an effect on hearing and so may promote tinnitus. Secondly, there can be a direct connection between the ligaments that attach to the jaw and one of the hearing bones that sits in the middle ear. Thirdly, the nerve supply from the TMJ has been shown to have connections with the parts of the brain that are involved with both hearing and the interpretation of sound. The general discomfort associated with TMJ problems can also aggravate any preexisting tinnitus.

Patients with tinnitus and TMD often have excessive somatic concern syndrome with complaints disproportionate to the severity of physical and clinical findings exacerbated by emotional disturbances and are often diagnosed as depression and anxiety. Studies indicate that patients with TMD report their auditory and vestibular symptoms exacerbated, being alleviated by drug treatment and emotional control [34]. These patients demonstrate emotional imbalance, depression, and anxiety. They manifest periods of control of their symptoms. They present physical and cognitive limitations, and the intensity of the symptoms and signs oscillates in an uneven way, suffering the distinct influence of personal, family, professional, and social problems in their daily life [34].

5. TMD diagnosis and complementary tests

The diagnosis of TMD is clinical, being performed through the clinical history and complete physical examination of the joint with palpation, measurement of mouth opening movements, functional tests, and evaluation of joint noises. TMD patients were defined as those who had experience of TMJ symptoms over the previous year as indicated by the presence of one or more of the following symptoms:

- a. clicking sounds in the auricular area during the past year,
- b. pressure or pain in the auricular area during the past year, or
- c. discomfort opening the mouth during the past year [35].

Functional disorders of the masticatory organs are often manifested by acute or chronic pain in and around the TMJ and/or masseter muscles. Impaired dynamics of mandibular movements is manifested as restricted or enhanced range of jaw openings, deviations in the course of abduction and adduction of the mandible,

and lack of symmetry of mandibular lateral movements. Acoustic symptoms within the joints, manifested as popping and cracking sounds, are an evidence of the lack of coordination between the articular head TMJ articular discs during mandible movements [2]. Patients with TMD characterize their tinnitus as acute, continuous, sporadic, of short duration, moderate intensity, and that generally did not interfere with their daily activities [36]. Otolaryngological symptoms are a less common group of dysfunction symptoms, including sudden hearing impairment or loss, ear plugging sensation and earache, sore and burning throat, difficulties in swallowing, and vertigo [3, 4, 6].

Due to the latter symptom, patients may experience fear when moving around. Tinnitus may be experienced as squeaks, whistles, chirps, bubbling sounds, pulsations, howls, paper rustle, or sea humming [7]. Facial pain and headache are one of the symptoms of the painful form of the functional dysfunction of the masticatory organ, commonly misdiagnosed and treated as pain of some other etiology [8–10]. The impact of the emotional factors in the development of TMD and common concomitance of otolaryngological symptoms should also be noted. Tinnitus, chronic facial pains, and dysfunctions were commonly reported in depressive patients [10, 12, 13, 37].

Imaging examinations can be performed to confirm the clinical diagnosis, as well as to verify the degree of impairment and integrity of the structures involved. In addition, imaging may also confirm the extent of TMD and assists to document the effects of the treatment already initiated [38, 39].

The imaging tests that may be requested are simple or panoramic X-ray of TMJ, CT, and MRI scans. Both simple radiography and panoramic jaw radiography have low-cost and low-radiation dose but have low sensitivity rates. They are indicated for initial evaluations of less complex symptoms and in the differential diagnosis between TMD and maxillofacial inflammatory conditions [38, 39].

CT scan is considered the “gold standard” for the evaluation of bone structures. This examination is necessary for evaluation in cases of sudden trauma, occlusal changes and limitation of mouth opening, the presence of joint noises, joint systemic diseases, infection, and failure in conservative treatments. Cone-beam computed tomography (CBCT) currently presents an increased indication during the evaluation of TMD [32, 38, 39].

MRI scan has been the method of choice for the study of TMJ pathologic processes involving soft tissues such as discs, ligaments, retrodiscal tissues, intracapsular synovial contents, adjacent masticatory musculature, as well as the cortical and medullary integrity of the bone components, respectively, in the axial, coronal, and sagittal planes, and is highly sensitive for intra-articular degenerative changes [32, 38, 39].

5.1 Electromyography

Electromyography is the study of muscle function, obtained from electrodes placed on the surface of the skin around the muscle, and connected to an equipment for amplification and recording of signals and, therefore, an examination that is capable to verify the action potentials of the muscle fibers of patients. It is considered a safety, easy, and noninvasive method that objectively allows quantification of energy within the studied muscle. It can be useful to assess TMD changes and to follow-up after the established therapy [32, 38, 39].

6. Tinnitus diagnosis and complementary tests

Tinnitus should be evaluated according to a clinical questionnaire, characterizing the type of tinnitus, laterality, continuity, whether there is modulation or not,

if there are associated symptoms (hearing loss, vertigo, previous exposure to noisy environments), improvement and worsening, and eating habits, in order to quantify the limitations caused by tinnitus.

The prevalence of TMD was higher in patients with tinnitus and hearing difficulty symptoms than in patients without tinnitus or hearing difficulty, which is consistent with previous TMD studies where reports of auditory complaints are common [35]. Moreover, patients with TMDs were at a greater risk of developing tinnitus and symptoms of a greater severity than patients without TMDs [40]. Excessive mechanical irritation of the disco-malleolar ligament is suspected to play a definitive role in the development of tinnitus in TMD patients [41]. Tinnitus has also been linked with pressure and strain from mastication and jaw movement [42]. In an audiological evaluation of aural symptoms in TMD, hearing loss was observed in up to 15–32% of TMD patients [35, 43]. A previous study by Riga et al. attributed the hearing difficulty in TMD cases to increase in resonant frequency in the tympanum ipsilateral to the TMD [44]. The association between tinnitus, hearing difficulty, and TMDs has thus been ascribed to a bidirectional delivery of mechanical stimulation and stress due to anatomical proximity.

TMD prevalence was found to be higher in patients with dizziness/balance disorder than in those without. Otologic complaints most frequently cited with TMDs in the study are dizziness, tinnitus, ear pain, ear fullness, and hearing loss [35]. de Moraes Marchiori et al. reported that patients with TMDs are 2.38 times more likely to present with dizziness, and Chole et al. conducted a case–control study to determine whether dizziness is more common in TMD patients compared to age-matched controls, finding dizziness to be significantly more prevalent in TMD group [3, 45].

The otolaryngological examination should be performed with flexible fibroscopy, verifying the palatal myoclonus. Laboratory tests should be performed with glucose and insulin curves, thyroid function tests, blood count, lipidogram, and audiometric tests (audiometry, impedanciometry, and acuphenometry), electrophysiological examinations (auditory brainstem response, otoacoustic emissions, and electrocochleography). Cervical spine X-ray, CT of ears, and carotid Doppler can be performed [46].

7. Integrated therapeutic approach

The difficulty of associating tinnitus and TMD is very much associated with the unilateral view of the professionals involved in patient care over the integrated multiprofessional approach [46].

In addition, another difficulty in managing such pathologies is that there is a high number of drugs for the treatment and control of symptoms related to tinnitus and TMD and that have as their side effects the very triggering of these, making diagnosis related to side effects or caused by congenital or acquired disease.

Patients with tinnitus and TMD complaints require careful attention and should be assisted by a multidisciplinary team of dentists, nurses, speech pathologists, ENT doctors, and psychologists. This approach is more effective in diagnosis, therapeutic plan, and prognosis by hierarchizing specific procedures of each professional to approach this patient [15, 46].

8. Results of multidisciplinary approach

Studies have shown benefits for treating tinnitus associated with TMD. Wright and Bifano, in 1997, studied tinnitus in patients with TMD and reported that 56%

were cured and 30% showed significant improvement with cognitive therapy and modulation through maneuvers [47]. Sherman et al. in 2001 found that TMD treatment resulted in greater improvement when combined with psychological and dental treatment, showing improved outcomes when combined with conventional dental therapy alone, implying that psychological factors should be taken into account in the treatment of TMD [48].

Stomatognathic treatment includes therapy of myorelaxant plaques, therapeutic exercises for lower jaw, and occlusal adjustment. Occlusal plaques, considered as reversible and noninvasive devices for the treatment of TMD, can regulate the vertical dimension of occlusion and eliminate malocclusion. They contribute to muscle relaxation, pain relief, and promote neuromuscular stability [49].

Referral to dentists or orthodontists, referral to audiologists, utilization of hearing aids or tinnitus-dampening devices, tinnitus-retaining therapy, music therapy, behavioral therapy related to reducing factors that lead to jaw clenching and bruxism, and osteopathic-manipulative treatment are all therapeutic options that can be considered. In addition, therapeutic options with less of an evidence basis such as acupuncture, tinnitus therapy, hyperbaric oxygen, and others may also be considered for patients who have not responded to other modalities [32, 49, 50].

Treatment through muscle relaxation, through massage and stretching exercises, is reported by some authors. Other authors have shown good results with drug treatment (vasodilators, hemorrhages, calcium-channel blockers, anxiolytics, antiplatelet agents, anticonvulsants, and vitamins) [50]. Okeson et al., comparing muscle relaxation therapies with the use of occlusal plaques, concluded that occlusal plaque therapy was more effective than muscle relaxation therapy in the treatment of temporomandibular disorders [51].

Somatic modulation therapy (treatment aimed at modulating the intensity of a particular symptom, by motion) and electrical stimulation in the treatment of tinnitus have recently been cited. The electrical stimulation of the skin areas near the ear could increase the activation of the dorsal cochlear nucleus through the somatosensory pathway, increasing the inhibitory role of this nucleus in the central nervous system and thus improving tinnitus [52]. For the most debilitating and severe tinnitus, the transcranial stimulation by magnetic stimulation has been studied [53].

9. Prognostic

The increased prevalence of TMD with increased modulation of tinnitus by somatic maneuvers highlights the role of somatosensory afferents, depicting somatosensory tinnitus. However, many questions remain regarding the clinical approach to patients with tinnitus.

1. How close is the association between the capability to modulate tinnitus following somatic maneuvers and the presence of a somatic disorder? The evidence in the study is still scarce.
2. Are there specific individual demographic or tinnitus-related factors that increase the chance of tinnitus modulation? Identification of a tinnitus profile could facilitate patient selection during somatic testing.
3. What is the relationship between tinnitus modulation and the efficacy of somatic treatment? It is hard to hypothesize the relationship of demographic or tinnitus-related factors in patients who are able to modulate their tinnitus,

a characteristic that seems more closely related to somatic components such as the presence of musculoskeletal disorders than to specific demographic profiles.

Current evidence supports a link, mainly for TMD, between the presence of a somatic disorder and higher modulation of tinnitus, especially in patients with a normal hearing threshold.

Identification of specific individual demographic or tinnitus-related factors that increase the chance of tinnitus modulation can be helpful in the management of patients with somatosensory tinnitus. Although some of these treatments may have a positive effect on tinnitus, their effect depends on the correct identification of the underlying somatic disorder, when present.

10. Conclusion

Somatosensory tinnitus is certainly a widespread condition, and further animal studies are required to better understand its pathophysiologic basis. New studies are necessary to investigate whether the correct diagnosis and treatment of a possible underlying somatic disorder could contribute to the management of tinnitus.

Accurate screening for somatosensory modulation of tinnitus is imperative to correctly select patients who would benefit from a multidisciplinary somatic approach. Chronic diseases were associated with a higher TMD prevalence. These findings suggest that TMD treatment should employ an interdisciplinary approach in an effort to extend and maximize its effect.

Conflicts of interest

None to declare.

Author details

Henrique F. Pauna*, Maria S.A. Amaral and Miguel Â. Hyppolito
Department of Ophthalmology, Otolaryngology, Head and Neck Surgery, Ribeirão Preto Medical School, University of São Paulo (FMRP-USP), Ribeirão Preto, São Paulo, Brazil

*Address all correspondence to: h_pauna@hotmail.com

IntechOpen

© 2018 The Author(s). Licensee IntechOpen. This chapter is distributed under the terms of the Creative Commons Attribution License (<http://creativecommons.org/licenses/by/3.0>), which permits unrestricted use, distribution, and reproduction in any medium, provided the original work is properly cited. 

References

- [1] Møller AR. The role of neural plasticity in tinnitus. In: Møller AR, DeRidder D, Langguth B, Kleinjung T, editors. *Textbook of Tinnitus*. New York: Springer; 2011. pp. 99-102
- [2] Langguth B, Kreuzer PM, Kleinjung T, De Ridder D. Tinnitus: Causes and clinical management. *Lancet Neurology*. 2013;**12**:920-930
- [3] Chole RA, Parker WS. Tinnitus and vertigo in patients with temporomandibular disorder. *Archives of Otolaryngology – Head & Neck Surgery*. 1992;**118**(8):817-821
- [4] Pascoal MIN, Rapoport A, Chagas JFS, Pascoal MBN, Costa CC, Magna LA. Prevalência dos sintomas otológicos na desordem temporomandibular: estudo de 126 casos. *Brazilian Journal of Otorhinolaryngology*. 2001;**67**(5):627-633
- [5] McCormack A, Edmondson-Jones M, Somerset S, et al. A systematic review of the reporting of tinnitus prevalence and severity. *Hearing Research*. 2016;**337**:70-79
- [6] Sanchez TG, Bento RF, Miniti A, Câmara J. Zumbido: características e epidemiologia–experiência do Hospital das Clínicas da Faculdade de Medicina da Universidade de São Paulo. *Brazilian Journal of Otorhinolaryngology*. 1997;**63**(3):229-235
- [7] Sanchez TG, Miotto Netto B, Sasaki F, Santoro PP, Bento RF. Zumbidos gerados por alterações vasculares e musculares. *International Archives of Otorhinolaryngology*. 2000;**4**(4):136-142
- [8] Person OC, Féres MCLC, Barcelos CEM, Mendonça RR, Marone MR, Rapoport PB. Zumbido: aspectos etiológicos, fisiopatológicos e descrição de um protocolo de investigação. *Arquivos de Medicina do ABC*. 2005;**30**(2):111-118
- [9] Jastreboff PJ. Phantom auditory perception (tinnitus): Mechanisms of generation and perception. *Neuroscience Research*. 1990;**8**:221-254
- [10] Sanchez TG, Lorenzi MC, Brandão AL, Bento RF. O zumbido como instrumento de estudo das conexões centrais e da plasticidade do sistema auditivo. *Brazilian Journal of Otorhinolaryngology*. 2002;**65**(6):839-849
- [11] Chen YC, Li X, Liu L, Wang J, Lu CQ, Yang M, Teng GJ. Tinnitus and hyperacusis involve hyperactivity and enhanced connectivity in auditory–limbic–arousal–cerebellar network. *eLife*. 2015;**4**:e06576
- [12] Zenner HP, Ernst A. Cochlear motor tinnitus, transduction tinnitus, and signal transfer tinnitus: Three models of cochlear tinnitus. In: Vernon JA, Møller AR, editors. *Mechanisms of Tinnitus*. Boston: Allyn and Bacon; 1995. pp. 237-254
- [13] Henry JA, Roberts LE, Caspary DM, Theodoroff SM, Salvi RJ. Underlying mechanisms of tinnitus: Review and clinical implications. *Journal of the American Academy of Audiology*. 2014;**25**(1):5-22
- [14] Shore SE, Roberts LE, Langguth B. Maladaptive plasticity in tinnitus–Triggers, mechanisms and treatment. *Nature Reviews. Neurology*. 2016;**12**:150-160
- [15] Ralli M, Greco A, Turchetta R, Altissimi G, Vincentiis M, Cianfrone G. Somatosensory tinnitus: Current evidence and future perspectives. *The Journal of International Medical Research*. 2017;**45**(3):993-947

- [16] Shore SE, El Kashlan H, Lu J. Effects of trigeminal ganglion stimulation on unit activity of ventral cochlear nucleus neurons. *Neuroscience*. 2003;**119**:1085-1101
- [17] Shore SE. Multisensory integration in the dorsal cochlear nucleus: Unit responses to acoustic and trigeminal ganglion stimulation. *The European Journal of Neuroscience*. 2005;**21**:3334-3348
- [18] Shore S, Zhou J, Koehler S. Neural mechanisms underlying somatic tinnitus. *Progress in Brain Research*. 2007;**166**:107-123
- [19] Zeng C, Nannapaneni N, Zhou J, et al. Cochlear damage changes the distribution of vesicular glutamate transporters associated with auditory and nonauditory inputs to the cochlear nucleus. *The Journal of Neuroscience*. 2009;**29**:4210-4217
- [20] Felício CM, Oliveira JAA, Nunes LJ, Jeronymo LFG, Jeronymo RRF. Alterações auditivas relacionadas ao zumbido nos distúrbios otolológicos da articulação têmporo-mandibular. *Brazilian Journal of Otorhinolaryngology*. 1999;**65**(2):141-146
- [21] Norena AJ, Farley BJ. Tinnitus-related neural activity: Theories of generation, propagation, and centralization. *Hearing Research*. 2013;**295**:161-171
- [22] Santos Júnior J. Oclusão: aspectos clínicos da dor facial. São Paulo: Meddens;1980
- [23] Kaltenbach JA. Tinnitus: Models and mechanisms. *Hearing Research*. 2011;**276**:52-60
- [24] Vass Z, Shore SE, Nuttall AL, Miller JM. Direct evidence of trigeminal innervation of the cochlear blood vessels. *Neuroscience*. 1998;**84**:559-567
- [25] Sobhy OA, Koutb AR, Abdel-Baki FA, Ali TM, El Raffa IZ, Khater AH. Evaluation of aural manifestations in temporomandibular joint dysfunction. *Clinical Otolaryngology and Allied Sciences*. 2004;**29**(4):382-385
- [26] Algieri GMA, Leonardi A, Arangio P, Vellone V, Paolo CD, Cascone P. Tinnitus in temporomandibular joint disorders: Is it a specific somatosensory tinnitus subtype? *The International Tinnitus Journal*. 2017;**20**(2):83-87
- [27] Alomar X, Medrano J, Cabratosa J, Clavero JA, Lorente M, Serra I, Monill JM, Salvador A. Anatomy of the temporomandibular joint. *Seminars in Ultrasound, CT and MRI*. 2007;**28**:170-183
- [28] Yale SH. Radiographic evaluation of the temporomandibular joint. *Journal of the American Dental Association* (1939). 1969;**79**(1):102-107
- [29] Williams PL. Skeletal System. In: *Gray's Anatomy*. London: Churchill Livingstone; 1999. pp. 578-582
- [30] Ferreira LA et al. Diagnóstico das disfunções da articulação temporomandibular: indicação dos exames por imagem. *Brazilian Journal of Otorhinolaryngology*. 2016;**82**(3):341-352
- [31] Toller PA. Temporomandibular capsular rearrangement. *The British Journal of Oral Surgery*. 1974;**11**(3):207-212
- [32] Murphy MK, MacBarb RF, Wong ME, Athanasiou KA. Temporomandibular joint disorders: A review of etiology, clinical management, and tissue engineering strategies. *The International Journal of Oral & Maxillofacial Implants*. 2013;**28**(6):e393-e414
- [33] Pereira KNF, Andrade LLS, Costa MLG, Portal TF. Sinais e

sintomas de pacientes com disfunção temporomandibular. *Revista CEFAC*. 2005;7(2):221-228

[34] Brown JT, Walker JI. Excessive somatic concern: Diagnostic and treatment issues. In: Walker JI, Brown JT, Galls HA, editors. *The Complicated Medical Patient*. New York: Human Sciences Press; 1987. pp. 13-30

[35] Song HS, Shin JS, Lee J, Lee YJ, Kim M, Cho JH, Kim KW, Park Y, Song HJ, Park SY, Kim S, Ha IH. Association between temporomandibular disorders, chronic diseases, and ophthalmologic and otolaryngologic disorders in Korean adults: A cross-sectional study. *PLoS One*. 2018;13(1):e0191336

[36] Moraes AA, Gil D. Zumbido em indivíduos sem perda auditiva e sua relação com a disfunção têmporo-mandibular. *Brazilian Journal of Otorhinolaryngology*. 2012;78(2):59-65

[37] Ferendiuk E, Zajdel K, Pihut M. Incidence of otolaryngological symptoms in patients with temporomandibular joint dysfunctions. *BioMed Research International*. 2014. ID 824684. DOI: 10.1155/2014/824684

[38] Ormeño G, Miralles R, Santander H, Casassus R, Ferrer P, Pallazi C, Moya H. Body position effects on sternocleidomastoid and masseter EMG pattern activity in patients undergoing occlusal splint therapy. *Cranio*. 1997;15(4):300-309

[39] Malta J, Campolongo GD, Pessoa de Barros TE, Oliveira RP. Eletromiografia aplicada aos músculos da mastigação. *Acta Ortopédica Brasileira*. 2006;14(2):106-107

[40] Fernandes G, Siqueira JT, Godoi Goncalves DA, Camparis CM. Association between painful temporomandibular disorders, sleep bruxism and tinnitus. *Brazilian Oral Research*. 2014;28(1):1-7

[41] Pekkan G, Aksoy S, Hekİmoglul C, Oghan F. Comparative audiometric evaluation of temporomandibular disorder patients with otological symptoms. *Journal of Cranio-Maxillo-Facial Surgery*. 2010;38(3):231-234

[42] Pinchoff RJ, Burkard RF, Salvi RJ, Coad ML, Lockwood AH. Modulation of tinnitus by voluntary jaw movements. *Otology & Neurotology*. 1998;19(6):785-789

[43] Lacout A, Marsot-Dupuch K, Smoker WR, Lasjaunias P. Foramen tympanicum, or foramen of Huschke: Pathologic cases and anatomic CT study. *AJNR. American Journal of Neuroradiology*. 2005;26(6):1317-1323

[44] Riga M, Xenellis J, Peraki E, Ferekidou E, Korres S. Aural symptoms in patients with temporomandibular joint disorders: Multiple frequency tympanometry provides objective evidence of changes in middle ear impedance. *Otology & Neurotology*. 2010;31(9):1359-1364

[45] de Moraes Marchiori LL, Oltramari-Navarro PVP, Meneses-Barriviera CL, Melo JJ, Macedo J, Bruniera JRZ, Gorres VC, Navarro RL. Probable correlation between temporomandibular dysfunction and vertigo in the elderly. *International Archives of Otorhinolaryngology*. 2014;18(1):49-53

[46] Onishi ET, Coelho CCB, Oiticica J, Figueiredo RR, Guimarães RCC, Sanchez TG, Gürtler AL, Venosa AR, Sampaio ALL, Azevedo AA, Pires APBÁ, Barros BBC, Oliveira CACP, Saba C, Yonamine FK, Medeiros ÍRT, Rosito LPS, Rates MJA, Kii MA, Fávero ML, Santos MAO, Person OC, Ciminelli P, Marcondes RA, Moreira RKP, Torres SMS. Tinnitus and sound intolerance: Evidence and experience of a Brazilian group. *Brazilian Journal of Otorhinolaryngology*. 2018;84(2):135-149

[47] Wright EF, Bifano SL. Tinnitus improvement through TMD therapy. *Journal of the American Dental Association* (1939). 1997;**128**:1424-1432

[48] Sherman JJ, Turk DC. Nonpharmacologic approaches to the management of myofascial temporomandibular disorders. *Current Pain and Headache Reports*. 2001;**5**(5):421-431

[49] Kovalesski WC, De Boever J. Influence of occlusal splints on jaw position and musculature in patients with temporomandibular joint dysfunction. *The Journal of Prosthetic Dentistry*. 1975;**33**(3):321-327

[50] Herraiz C, Toledano A, Diges I. Trans-electrical nerve stimulation (TENS) for somatic tinnitus. *Progress in Brain Research*. 2007;**166**:389-394

[51] Okeson JP. Tratamento das desordens da articulação temporomandibular. In: Okeson JP, editor. *Tratamento das desordens temporomandibulares e oclusão*. 7th ed. Rio de Janeiro: Elsevier; 2013. pp. 317-361

[52] Haider HF, Hoare DJ, Costa RFP, Potgieter I, Kikidis D, Lapira A, Nikitas C, Caria H, Cunha NT, Paço JC. Pathophysiology, diagnosis and treatment of somatosensory tinnitus: A scoping review. *Frontiers in Neuroscience*. 2017;**28**(11):207

[53] De Ridder D, Vanneste S, Kovacs S, Sunaert S, Menovsky T, van de Heyning P, Moller A. Transcranial magnetic stimulation and extradural electrodes implanted on secondary auditory cortex for tinnitus suppression. *Journal of Neurosurgery*. 2011;**114**(4):903-911