

We are IntechOpen, the world's leading publisher of Open Access books Built by scientists, for scientists

6,900

Open access books available

186,000

International authors and editors

200M

Downloads

Our authors are among the

154

Countries delivered to

TOP 1%

most cited scientists

12.2%

Contributors from top 500 universities



WEB OF SCIENCE™

Selection of our books indexed in the Book Citation Index
in Web of Science™ Core Collection (BKCI)

Interested in publishing with us?
Contact book.department@intechopen.com

Numbers displayed above are based on latest data collected.
For more information visit www.intechopen.com



Cerebral Palsy and Epilepsy

Alexey Kholin

Additional information is available at the end of the chapter

<http://dx.doi.org/10.5772/intechopen.79565>

Abstract

The frequency of epilepsy in children with cerebral palsy is 40 times higher than the common population rate. The presence of epilepsy aggravates the clinical course of cerebral palsy, complicates the rehabilitation, affects the prognosis of motor and intellectual functions, and could be life-threatening. Another problem is the possibility of aggravation of epileptic seizures and their appearance *de novo* due to application of some neuro-rehabilitation methods (electrophoresis, acupuncture, nootropic drugs, brain stimulators, etc.). Children with cerebral palsy have a broad spectrum of epilepsies—varying from favorable combinations with benign idiopathic forms to extremely severe epileptic encephalopathies. Frequent combination of epileptic and non-epileptic paroxysms causes difficulty in their interpretation and differential diagnosis. Video-EEG monitoring is the “golden standard” for differential diagnostic of epileptic and non-epileptic events, and it is very useful for investigation of patients with cerebral palsy. Treatment of epilepsy in combination with cerebral palsy strictly requires an individual approach due to the form of epilepsy, seizure types, age of the patient, comorbidity, and somatic and mental condition of the patient.

Keywords: cerebral palsy, epilepsy, epileptic seizures, EEG, AEDs

1. Introduction

The actual problem is the presence of epileptic seizures in children with cerebral palsy that caused deterioration of disease, complicates the rehabilitation, affects the prognosis of motor and intellectual functions, and could be life-threatening. Also, the presence of epileptiform discharges with high index can cause progression of cognitive defects and also with possible increasing of motor deficits. These phenomena violate such a core criterion of cerebral palsy as nonprogressive process.

The frequency of neonatal seizures in children with cerebral palsy in 17 times is higher than common population rate, febrile seizures (2.5 times), and epilepsy (more than 40 times higher) [1].

Epilepsy in cerebral palsy occurs according to different authors data in 28% [2], 36.4% [3], 44% [4], 43.2% [1], 62% [5], and even 75% [6].

2. Cerebral palsy and epilepsy

2.1. Risk factors for epilepsy in cerebral palsy

Among infants at group of risk for the development of cerebral palsy and among those who had formed cerebral palsy are advisable to identify also the group of risk for development of epilepsy.

Risk factors for epilepsy in cerebral palsy are [1, 7–10]:

- The presence of neonatal seizures.
- Low Apgar score (≤ 4 points).
- Extremely preterm infants (≤ 31 weeks of gestation).
- Neonatal resuscitation.
- Family history of epilepsy.
- Cerebral palsy caused by prenatal factors, especially cerebral dysgenesis.
- Intrauterine infection (especially herpes encephalitis).
- Hemiplegic and tetraplegic forms of cerebral palsy.
- Severe mental retardation.
- The presence of epileptiform discharges on the EEG.

2.2. Characteristics of epilepsy in cerebral palsy

Despite the wide polymorphism of clinical cases, epilepsy in combination with cerebral palsy epilepsy has a number of common characteristics.

They can be expressed as the following features [1, 5, 7–11]:

1. In the majority of cases (up 74.2%), epilepsy in children with cerebral palsy debuted at the first year of life.
2. Children with cerebral palsy have a broad spectrum of epilepsies—varying from favorable combinations with benign idiopathic forms to extremely severe epileptic encephalopathies.

3. Non-rare cerebral palsy is combined with epileptic encephalopathies of infancy and early childhood (Ohtahara, West, Markand-Blume-Ohtahara, Lennox-Gastaut syndromes, etc.).
4. The prevalence of the clinical picture of complex focal, secondarily generalized, and so-called pseudo-generalized epileptic seizures (atypical absence, tonic spasms, and bilateral myoclonic seizures with focal origin).
5. Frequent combination of epileptic and non-epileptic paroxysms, as well as possible similarity of their kinematics, causes difficulty in their interpretation and differential diagnosis. For example, the “dystonic attacks” with kinetic type of asymmetric tonic neck reflex (ATNR) and versive tonic epileptic seizures.
6. The presence of epilepsy aggravated motor and cognitive impairment in cerebral palsy. Frequently, epileptic seizures and epileptiform discharges with high index caused cognitive epileptiform disintegration or partial cognitive defects, as well as a possible increase of motor deficits and progressive loss of certain motor and speech skills.
7. Frequent combination of cerebral palsy and benign epileptiform discharges of childhood (BEDC) on the EEG. Children with periventricular leukomalacia (PVL) and diffuse myelination defects had favorable prognosis for epileptic seizures but in combination with drug-resistant epileptiform discharges (including BEDC) and disintegrative epileptiform processes.
8. In children with cerebral palsy (unless caused by cerebral dysgenesis) may not be a correlation between the sites of epileptiform activity and the area most pronounced structural changes in neuroimaging.
9. There is often a reflex provocation under the influence of audiogenic seizures and somatosensory stimulation (including epilepsy of feeding). The problem of differential diagnosis of startle reflex and startle epilepsy in children with cerebral palsy.
10. Increased risk of recurrence of epilepsy in children with cerebral palsy after antiepileptic drug (AED) discontinuation.

Children with cerebral palsy have a wide spectrum of epilepsies which varies from favorable combinations with benign idiopathic forms to extremely severe epileptic encephalopathies.

So, in the total of 231 pediatric cases of cerebral palsy observed and treated on the Department of Psychoneurology N2 Russian Children Clinical Hospital (Moscow) at 2007–2012 years, 84 children (36.4%) had a combination of cerebral palsy and epilepsy [3].

The following forms of epilepsy were fixed: symptomatic focal frontal lobe epilepsy (25 patients (29.7%)), temporal lobe epilepsy (15 patients (17.9%)), parietal lobe epilepsy (3 patients (3.6%)), occipital lobe epilepsy (8 patients (9.5%)), SE-MISF (severe epilepsy with multifocal independent spike foci or Markand-Blume-Ohtahara syndrome) (7 patients (8.3%)), other multifocal epilepsies (4 patients (4.8%)), West syndrome (5 patients (6%)), focal epilepsy

of childhood with structural brain changes and benign epileptiform discharges of childhood on the EEG (FECSBC-BEDC) (10 patients (11.9%)), and cognitive epileptiform disintegration (CED) with ESES (electrical status epilepticus at slow-wave sleep) (7 patients (8.3%)) [3].

2.3. Epileptiform activity in children with cerebral palsy and epilepsy

Morphologic characteristics of epileptiform activity in children with cerebral palsy and epilepsy are very different and depend on the form of epilepsy, patient age, severity, and nature of brain damage.

In children with cerebral palsy, the high frequency of so-called benign epileptiform discharges of childhood pattern (“BEDC,” “BEDOC,” or “Rolandic” spikes and spike-wave complexes) was noted and could be found in epileptic (**Figures 1 and 2**) and also non-epileptic patients.

Over the past decades, the world’s scientific and clinical experience accumulates the observation of patients with the so-called double pathology — the presence of structural brain damages with motor deficit in combination with epileptic idiopathic component including “BEDC.”

Mukhin et al. proposed the definition “focal epilepsy of childhood with structural brain changes and benign epileptiform discharges in EEG” (“FECSBC-BEDC”) for the group of children with focal epilepsy, associated with BEDC on EEG and perinatal organic brain damage, which has a special “interim” position between idiopathic and symptomatic epilepsies due to its clinical electrical and neuroimaging characteristics [12].

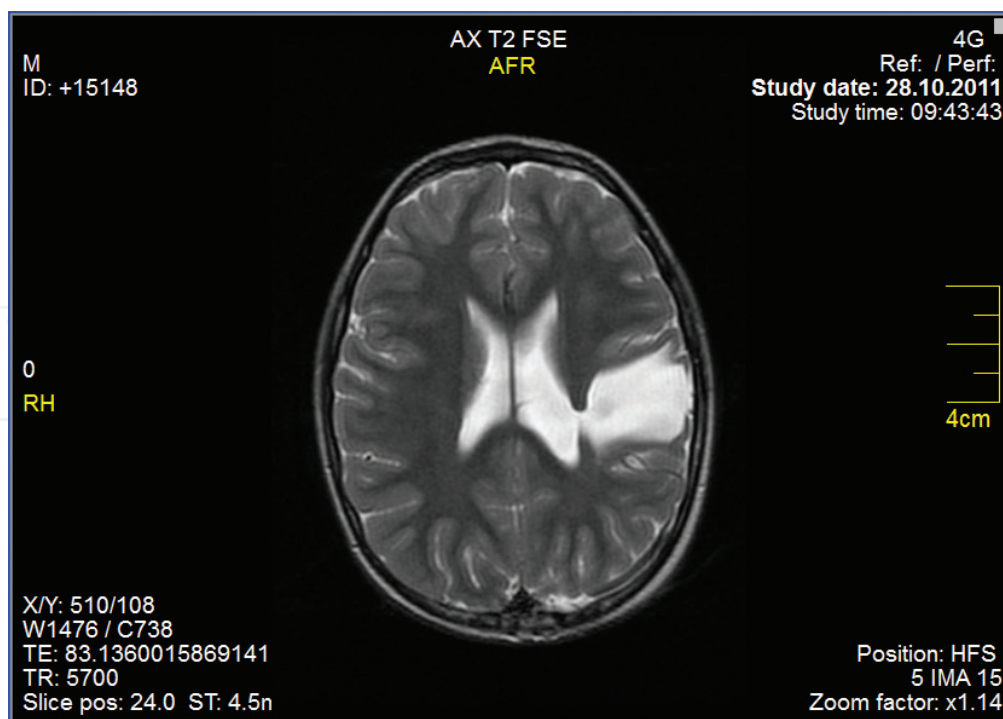


Figure 1. Boy Sh.I. (7 years old). Hemiparetic form of cerebral palsy (right-side hemiparesis). Symptomatic focal epilepsy with right-side hemiconvulsive, versive, dialeptic, and myoclonic-astatic seizure types. Porencephalic cyst in the left hemisphere (parietotemporal region).

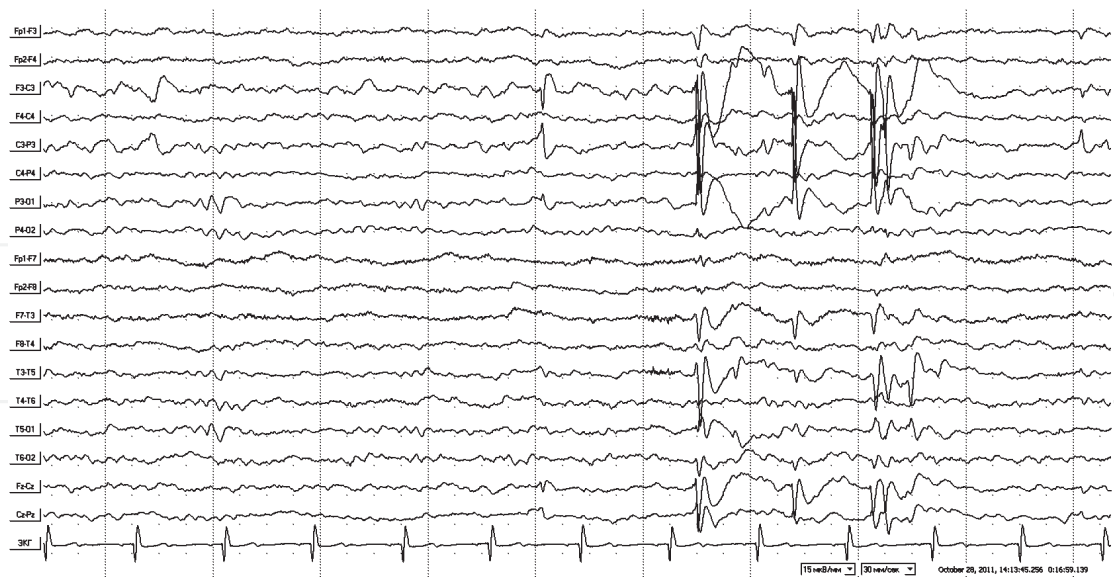


Figure 2. Boy Sh.I. (7 years old) (the same patient). Wake EEG. Regional epileptiform activity in left central and centroparietotemporal region in the manner of spike-wave with “BEDC” morphology and sharp- and slow-wave complexes in combination with regional slowing.

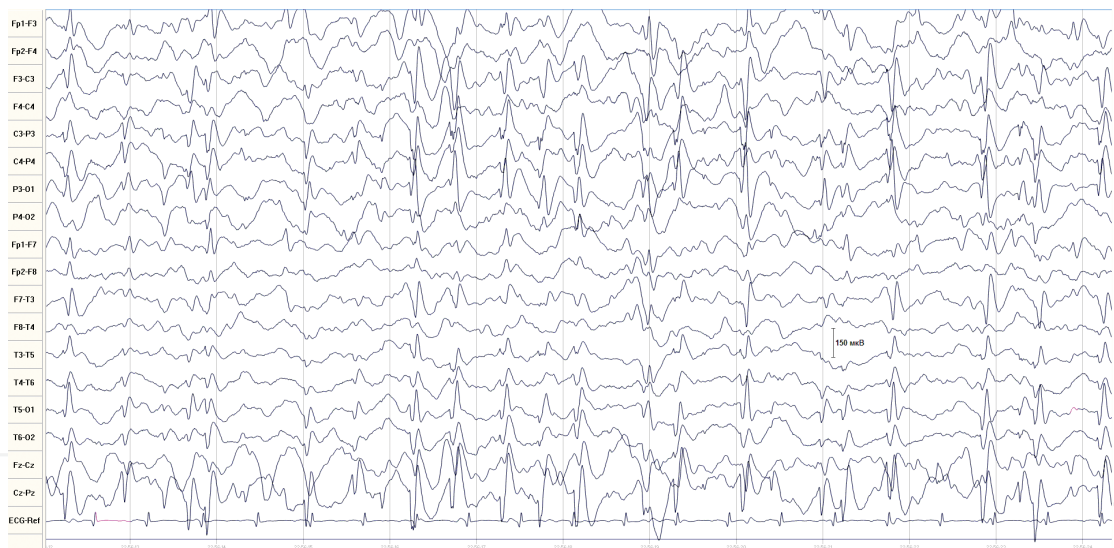


Figure 3. Girl V.M. (11 years old). Cerebral palsy, moderate right-side hemiparesis. Sleep EEG-ESES pattern.

High index (85–100% of recording) of such spikes-waves in sleep formed EEG patterns of CSWS (continuous spikes-and-waves during sleep) and ESES (electrical status epilepticus in sleep) in cases of diffuse spreading of epileptiform discharges (**Figure 3**). It usually correlates with severe speech and cognitive deficit in children.

Sometimes, early appearance on the EEG “BEDC”-like complexes is prognostically unfavorable and preceding the development of hypersarrhythmia. Five-point epileptiform complexes as “Rolandic” at the first months of life in children with hypoxic-ischemic brain damage and periventricular leukomalacia could precede hypersarrhythmia, epileptic spasms, and the development of epileptic encephalopathy (**Figures 4–7**).

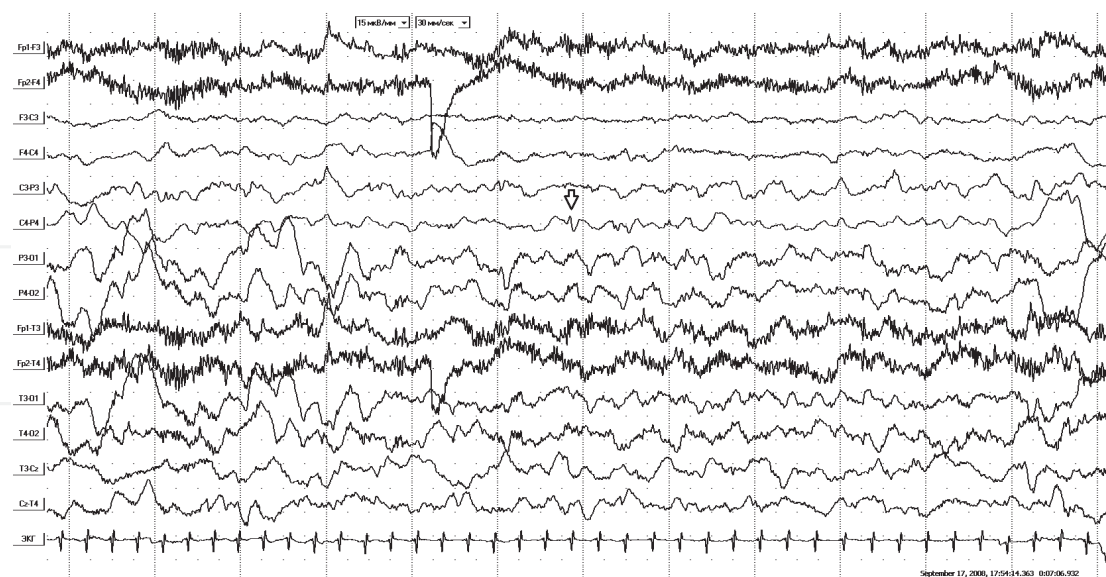


Figure 4. Boy B-H.A. (4 months old). Retardation of psychomotor and preverbal development due to perinatal brain damage. Risk of cerebral palsy. EEG during wakefulness 2 months before the onset of infantile spasms. In the center-right parietal region, low-amplitude five-pointed epileptiform complexes are observed, similar in morphology to the “Rolandic” complexes.

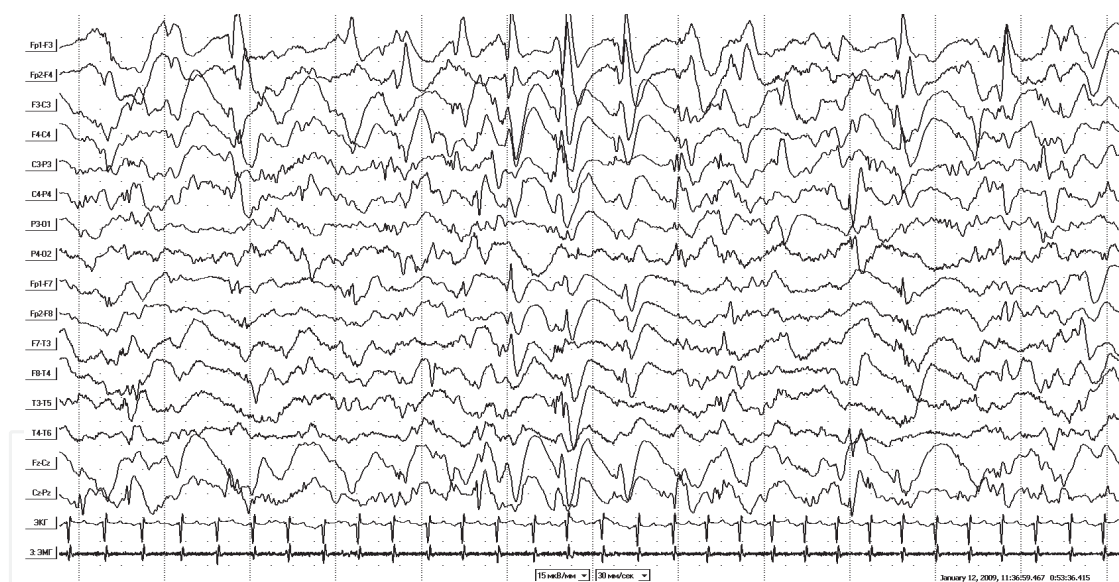


Figure 5. The same patient (4 months later; age of 8 months). Spastic tetraparesis. Infantile spasms. Psychomotor retardation. EEG during wakefulness: modified hypsarrhythmia with a multiregional component (right parietal, left and right frontal areas).

Frequent combination of epileptic seizures and non-epileptic events, as well as possible similarity of their kinematics, causes difficulty in their interpretation and differential diagnosis. For example, we can see EEG illustrations (**Figures 8–12**) of the girl N.A. (age 1 year and 3 months); we can see her interictal EEG pattern and patterns of non-epileptic event and ictal recording. Surprisingly, events considered as asymmetric tonic versus seizures were diagnosed as non-epileptic, but video-EEG also demonstrated minimal motor seizures of temporal

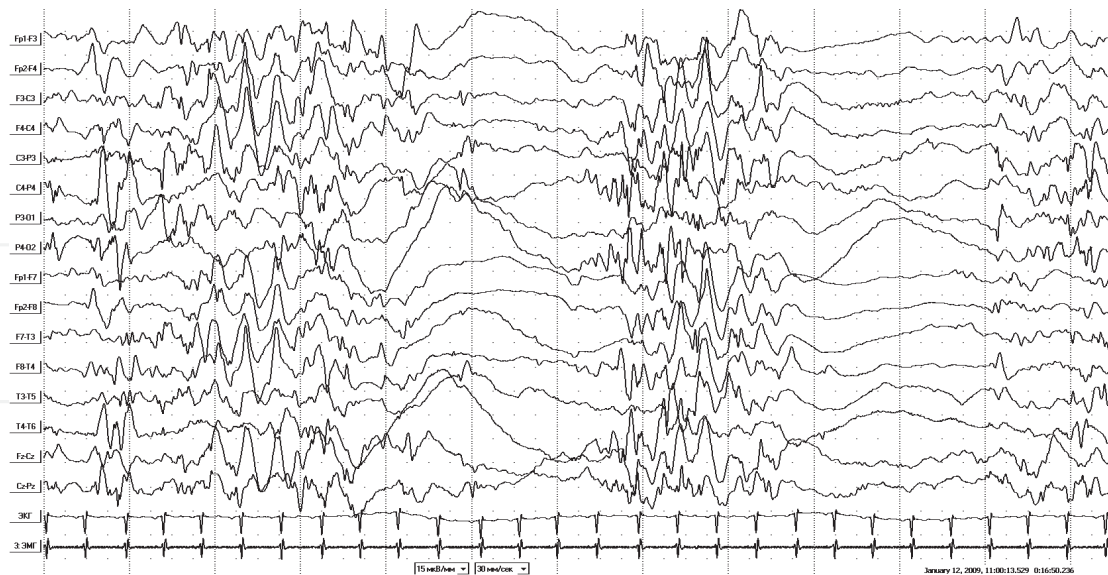


Figure 6. The same patient (age of 8 months). EEG during sleep: modified hypsarrhythmia with persistence of suppression burst pattern and main regional focus in the right parietal area.

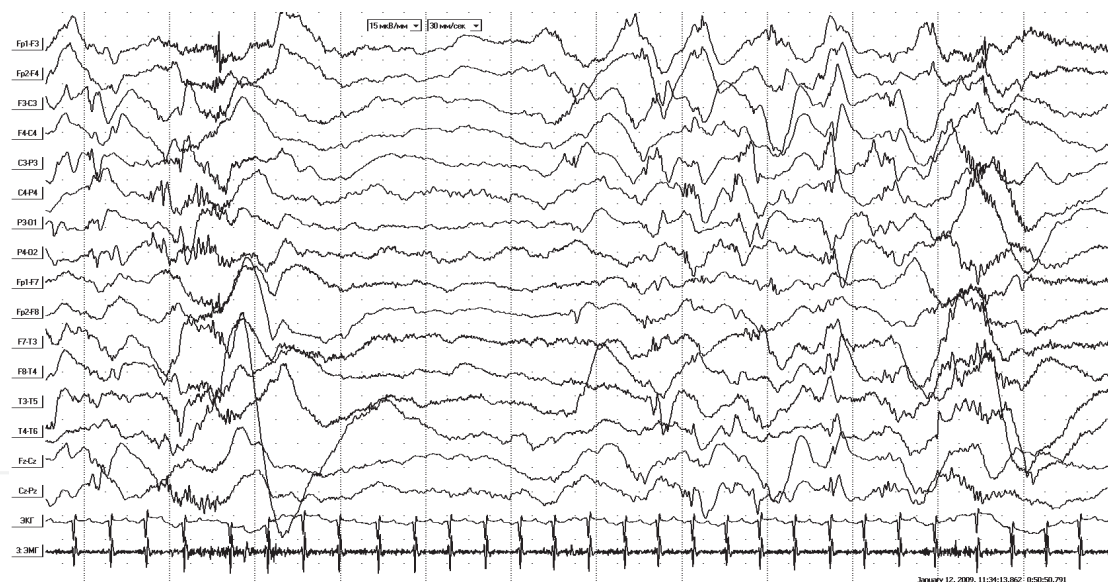


Figure 7. The same patient (age of 8 months). EEG during a series of tonic axial and axiorhizomelic flexor epileptic spasms. Marked diffuse ictal runs of "low-amplitude fast activity" ("lafa") and "fast activity" with predominant right-hemisphere parietal involvement and postictal partial inhibition of bioelectric activity.

lobe genesis not considered by the father of the child and even the physicians. The girl had spastic tetraplegic-type cerebral palsy, microcephaly, symptomatic focal epilepsy, pseudobulbar syndrome, chronic aspiration syndrome, and severe delay of psychomotor development. According to the anamnesis data, the mother 34 years old, and the father is 50 years old. The girl from the first physiological pregnancy, delivery at the 40th month of gestation. Her mother died during status epilepticus of bilateral tonic-clonic seizures. Mechanic extraction of the child with obstetric forceps from dying mother. The girl was born with weight 3510 g,

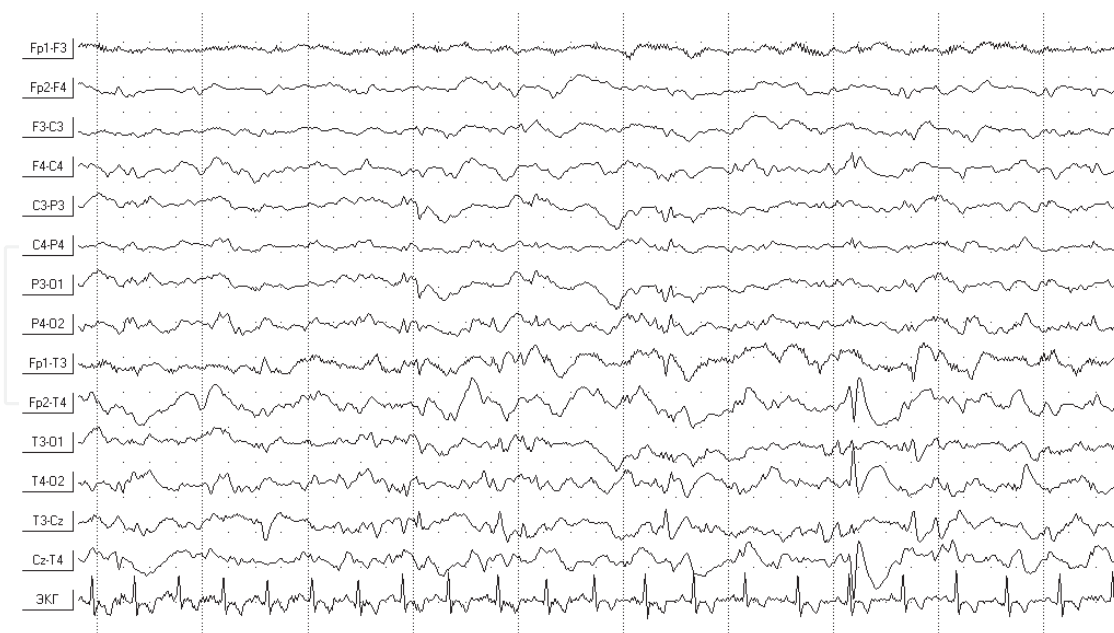

Figure 8. Girl N.A. (1 year and 3 months). Cerebral palsy. Interictal EEG with “BEDC” complexes of the left and independently right temporal, temporo-central, and temporoparietal localization.

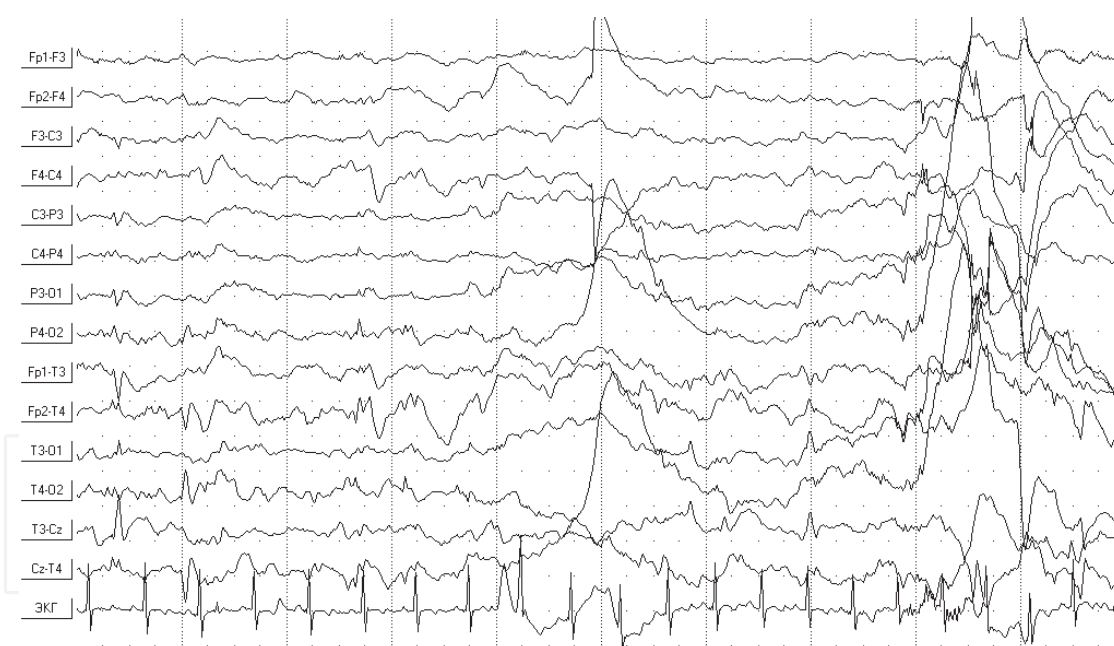


Figure 9. The same girl and EEG record. EEG of non-epileptic paroxysm (the beginning)—“dystonic attacks” with kinetic type of asymmetric tonic neck reflex (ATNR). No ictal pattern. Movement artifacts with the same background interictal “BEDC” complexes.

length of 53 cm, and Apgar score of 4/5 degrees. She was on the artificial lung ventilation for 3 weeks. Neonatal seizures appear from the first days of life.

Esipova E.S. and coauthors (2017) have analyzed video-EEG monitoring results of 133 children (87 boys and 46 girls) with spastic forms of cerebral palsy who underwent examination and

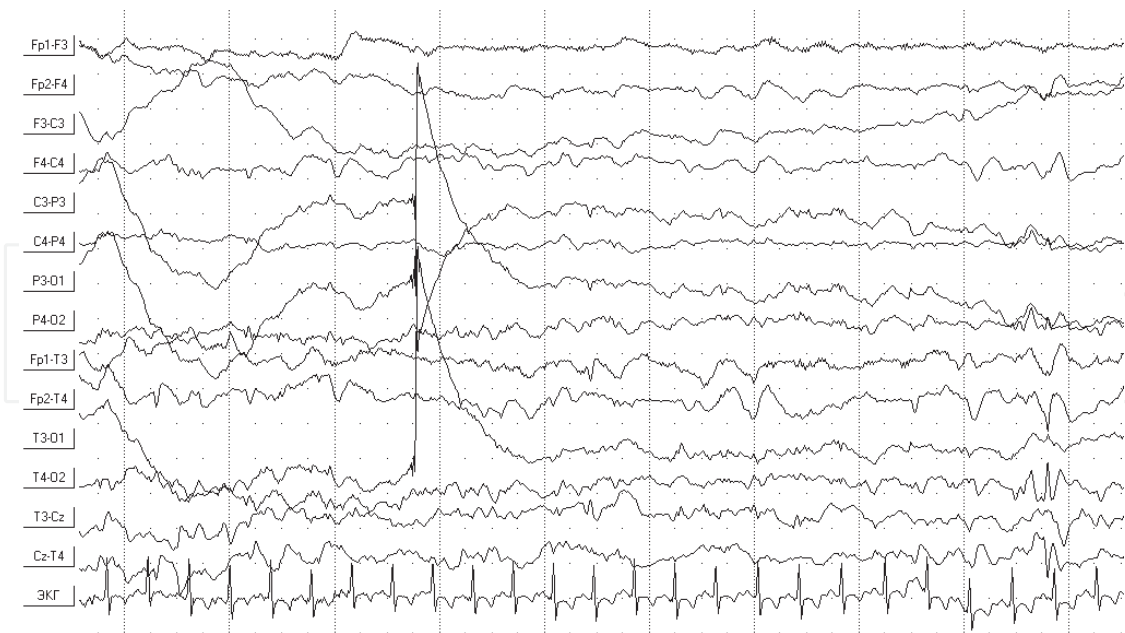


Figure 10. The same girl and EEG record. The end of non-epileptic paroxysm.

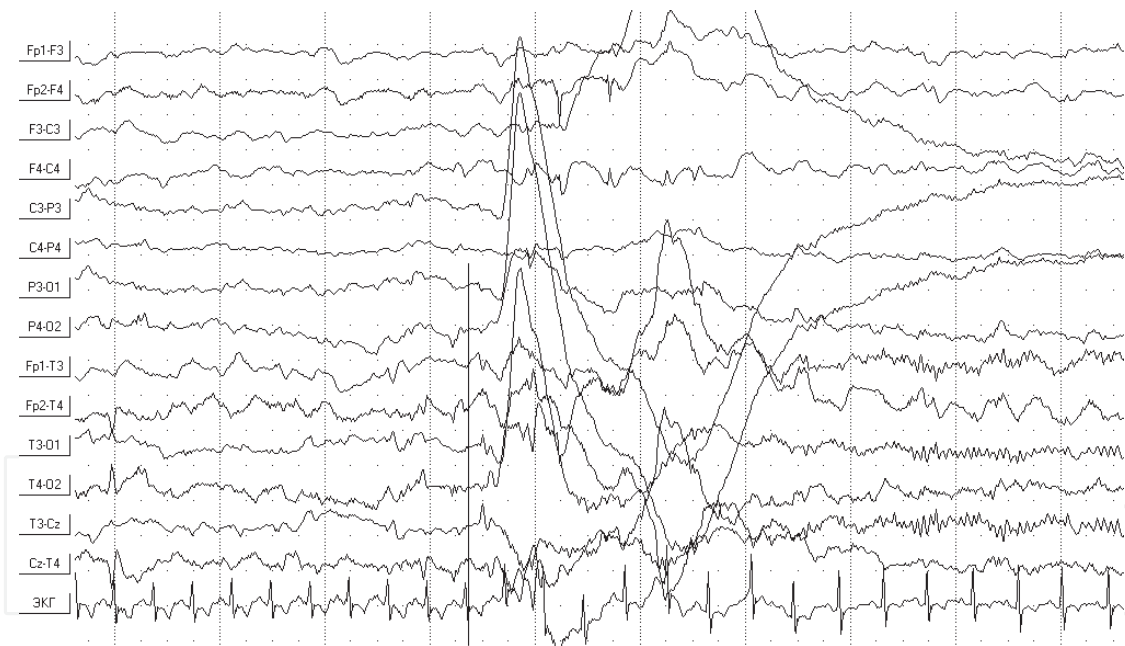


Figure 11. The same girl and EEG record. The ictal event—minimal motor seizure (“subtile” bilateral spasm with dystonic set of the right hand) with “fast activity” pattern in the left temporal region.

treatment at the Department of Psychoneurology N2 Russian Children Clinical Hospital in 2014–2016 years. In a group of spastic tetraparesis ($n = 79$), the presence of epilepsy was 54.43% ($n = 43$), and the presence of epileptiform activity on the EEG was 72.15% ($n = 57$) including 24 children (30.38%) with “benign epileptiform discharges of childhood” (“BEDC”). In a group of spastic hemiparesis ($n = 18$), the presence of epilepsy was 27.78% ($n = 5$), but the presence of epileptiform activity on the EEG was 61.11% ($n = 11$) including 8 children (44.45%) with

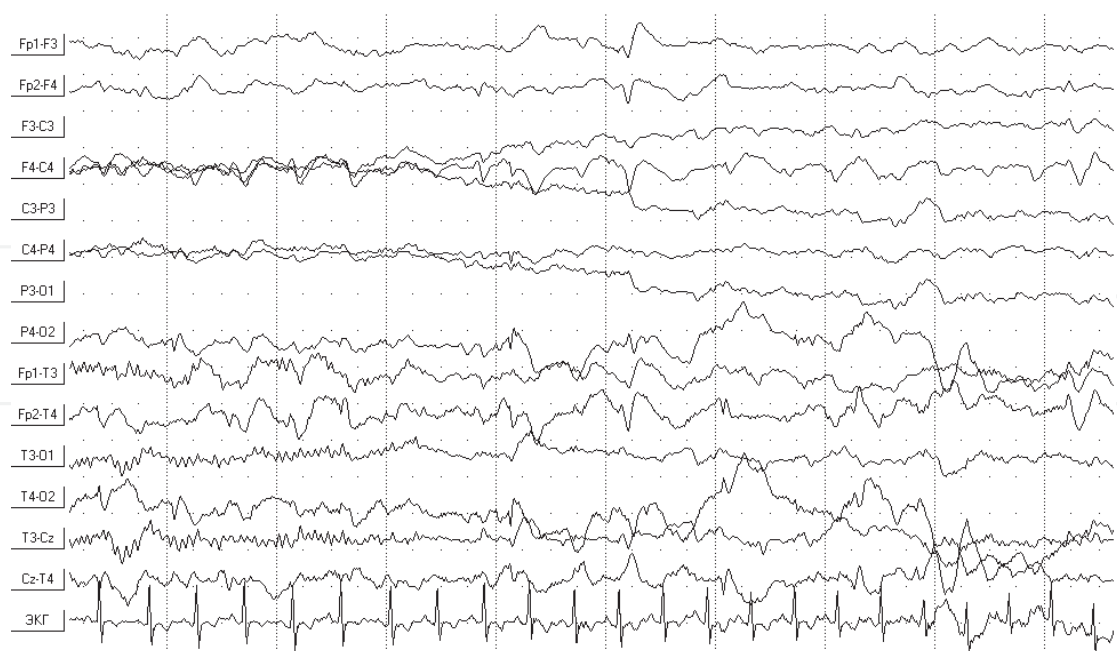


Figure 12. The same girl and EEG record. The end of ictal event—"fast activity" pattern in the left temporal region stopped.

"BEDC." In a group of Little's disease (spastic diplegia) ($n = 25$), the presence of epilepsy was 20% ($n = 5$), and the presence of epileptiform activity was 48% ($n = 12$) including 7 children (28%) with "BEDC." Mixed form of cerebral palsy ($n = 11$) contains seven epileptic patients, and the presence of epileptiform activity was 72.73% ($n = 8$) including 5 children (45.45%) with "BEDC." Among the 133 children, 72.2% ($n = 96$) of all the presented patients had non-epileptic paroxysms on the EEG considered by parents and also mentioned by EEG assistants. In 18.1% ($n = 24$) of patients, a combination of epileptic and non-epileptic events on the video-EEG monitoring was fixed. In 13 patients only epileptic events were fixed (9.7%) [13].

2.4. Treatment of epilepsy in children with cerebral palsy

Drugs of choice in the treatment of epilepsy in children are valproates in doses of 20–100 mg/kg/daily. It should be emphasized that the high incidence of bulbar palsy disorders in children causes serious problems with the use of tablet and capsule forms of antiepileptic drugs (AEDs). This problem has been solved by the use of such forms of valproates such as depakine chronosphere, depakine syrup, convulex in the syrup and drops form, etc.

In cases of atypical absences and BEDC-associated conditions, succinimides (suxilep, petnidan) at doses 20–35 mg/kg/day are appropriate.

In children with cerebral palsy and cognitive epileptiform disintegration with BEDC on EEG, also levetiracetam (keppra, epiterra, levetinol) in doses 20–80 mg/kg/day could be very good.

In application of carbamazepine group, oxcarbazepine, lamotrigine, and topiramate in pediatric patients under the age of 7 years should be considered the high risk of aggravation of the

phenomenon of secondary bilateral synchronization of the EEG, with clinical manifestations of myoclonic seizures, atypical absences, and secondarily generalized seizures. This group of drugs to be combined with a broad-spectrum AED with low aggravation risk (as valproates) and their use requires careful dynamic video-EEG monitoring to detect early signs of aggravation. But carbamazepine, oxcarbazepine, eslicarbazepine acetate, lamotrigine, and topiramate could be very useful in focal tonic and clonic seizures. In older children and adult patients, topiramate is one of the best drugs in frontal lobe epilepsy with secondary bilateral synchronization. Carbamazepine group and oxcarbazepine are better in temporal and occipital localization of epileptic focus.

In frequent epileptic seizures, especially myoclonic types, benzodiazepines are very useful (clonazepam 0.1–0.3 mg/kg/daily, frisium 0.3–1 mg/kg/daily). Benzodiazepines may also be helpful to reduce muscle tonus and decreased expression of dystonic non-epileptic attacks.

In young children with cerebral dysgenesis, vigabatrin may be effective in treatment (30–150 mg/kg/daily). It is useful to give predominant part or total daily dose at the evening for peak of drug concentration in blood at the dark for preventing retinotoxicity.

In prolonged clusters of seizures and status epilepticus - diazepam in rectal tubes, buccal or nasal midazolam, benzodiazepines i.m., i.v. In benzodiazepine-resistant status epilepticus and in tonic-autonomic seizures with apnea and bradyarrhythmia, valproates strictly i.v. (depakin, convulex) is recommended.

In consideration with the high risk of seizure recurrence and severity of epilepsy structural defects of the brain in patients with cerebral palsy, the duration of antiepileptic therapy should be at least 3 years after achieving clinical remission (usually for ≥5 years).

In the presence of drug-resistant epilepsy, it is necessary to decide on the possibility of epileptic surgery, which will be appropriate for cerebral dysgenesis, especially in cases of focal cortical dysplasia. On the contrary, the presence of a structural defect of hypoxic-ischemic or posthemorrhagic genesis and epileptiform discharge “BEDC” type in contralateral (in potentially “healthy” hemisphere as a result of a combination of cerebral palsy and idiopathic epileptic component) is a contraindication for epileptic surgery.

In cases of pharmacoresistance and impossibility or absence of indications for surgical treatment, VNS therapy (implantation of a vagus nerve stimulator) may be considered.

The serious problem is the possibility of aggravation of epileptic seizures and their appearance de novo due to application of some neurorehabilitation methods (electrophoresis, acupuncture, electroretinostimulation, application of nootropic drugs and brain stimulators, etc.). Of course, rehabilitation methods in every child will individually depend on motor and mental skills and the severity of epileptiform process. Reflex locomotion gymnastic (the Vojta method) and neurodynamic rehabilitation therapy (the Bobath method) have minimal epilepsy aggravation risk and are strongly recommended for all children with motor retardation as well as in cases of cerebral palsy with epilepsy and epileptiform activity. Metabolic L-carnitine treatment is very useful for patients with cerebral palsy especially in cases of prolonged antiepileptic therapy (extremely important in long-term therapy with valproates causing

carnitine deficiency). Peptidergic nootropic therapy in cerebral palsy associated with epilepsy also demonstrated its efficiency and safety [14].

3. Conclusions

- Epilepsy is non-rare condition in patients with spastic forms of cerebral palsy.
- The presence of epilepsy aggravates the clinical course of cerebral palsy, complicates the rehabilitation, affects the prognosis of motor and intellectual functions, and could be life-threatening.
- Frequent combination of epileptic and non-epileptic paroxysms, as well as possible similarity of their kinematics, causes difficulty in their interpretation and differential diagnosis.
- Video-EEG monitoring as a “golden standard” for differential diagnostic of epileptic and non-epileptic events is very useful for investigation of patients with cerebral palsy. Sleep EEG is very important for detection of epileptiform discharges especially in children with CSWS or ESES pattern.
- Treatment of epilepsy in combination with cerebral palsy strictly requires an individual approach due to the form of epilepsy, seizure types, age of the patient, comorbidity, and somatic and mental condition of the patient.
- The presence of epilepsy is not a contraindication for rehabilitation and nootropic treatment. But we need to use methods with minimal risk of possibility for aggravation of seizures and epileptiform discharges.

Acknowledgements

I would like to express my special thanks to the Director of Academy of the Developmental Medicine in Slovenia Professor Milivoj Velickovic Perat, to the Head of the Department of Neurology, Neurosurgery, and Medical Genetics of Pirogov Russian National Research Medical University Professor Nikolay Nikolaevich Zavadenko, to the Head of the Department of Psychoneurology N2 of Russian Children Clinical Hospital doctor Elena Stepanovna Il'ina, and to all my colleagues.

Conflict of interest

No conflict of interest.

Author details

Alexey Kholin

Address all correspondence to: drkholin@mail.ru

Department of Neurology, Neurosurgery and Medical Genetics of Pediatric Faculty, Pirogov Russian National Research Medical University, Moscow, Russia

References

- [1] Belousova ED. Risk factors, management and prognosis of seizures and epilepsy in children with cerebral palsy. Autoref. Diss. Doc. Med. Nauk. (In Russ) Moscow. 2004. 48 p
- [2] Bax M, Tydeman C, Flodmark O. Clinical and MRI correlates of cerebral palsy: The European cerebral palsy study. *Journal of the American Medical Association*. 2006;**296**(13): 1602-1608. DOI: 10.1001/jama.296.13.1602
- [3] Kholin AA, Il'ina ES, Bembeeva RC, Simbirtseva EG, Kolpakchi LM, Fedonyuk ID, Nemkova SA, Zavadenko NN. Epilepsy in children with cerebral palsy. IV. Baltic congress on pediatric neurology. Proceedings (in Russ). St. Petersburg. 2013. pp. 346-347
- [4] Himmelmann K, Uvebrant P. Function and neuroimaging in cerebral palsy: A population-based study. *Developmental Medicine and Child Neurology*. 2011;**53**(6):516-521. DOI: 10.1111/j.1469-8749.2011.03932.x
- [5] Bruck I, Antoniuk SA, Spessatto A, Bem RS, Hausberger R, Pacheco CG. Epilepsy in children with cerebral palsy. *Arquivos de Neuro-Psiquiatria*. 2001;**59**(1):35-39
- [6] Rolón-Lacarriere OG, Hernández-Cruz H, Tableros-Alcántara CM, Pérez-Moreno JC. Control of epilepsy in children and adolescents suffering from cerebral palsy, with respect to their etiology and cerebral lesion background. *Revista de Neurologia*. 2006;**43**(9):526-530
- [7] Arpino C, Curatolo P, Stazi MA, Pellegri A, Vlahov D. Differing risk factors for cerebral palsy in the presence of mental retardation and epilepsy. *Journal of Child Neurology*. 1999;**14**(3):151-155
- [8] Zelnik N, Konopnicki M, Bennett-Back O, Castel-Deutsch T, Tirosh E. Risk factors for epilepsy in children with cerebral palsy. *European Journal of Paediatric Neurology*. 2010;**14**(1):67-72. DOI: 10.1016/j.ejpn.2009.06.002
- [9] Mert GG, Incecik F, Altunbasak S, Herguner O, Mert MK, Kiris N, Unal I. Factors affecting epilepsy development and epilepsy prognosis in cerebral palsy. *Pediatric Neurology*. 2011;**45**(2):89-94. DOI: 10.1016/j.pediatrneurol.2011.03.001

- [10] Garfinkle J, Shevell MI. Cerebral palsy, developmental delay, and epilepsy after neonatal seizures. *Pediatric Neurology*. 2011;**44**(2):88-96. DOI: 10.1016/j.pediatrneurol.2010.09.001
- [11] Kholin AA, Zavadenko NN, Esipova ES. Cerebral palsy and epilepsy. *Voprosy Prakticheskoy Pediatrii* [article in Russian]. 2016;**11**(4):66-72. DOI: 10.20953/1817-7646-2016-4-66-72
- [12] KYu M, Mironov MB, Borovikov KS, Petrukhin AS. Focal epilepsy of childhood with structural brain changes and benign epileptiform discharges in EEG, FECSBC-BEDC (preliminary results) [article in Russian]. *Russian Journal of Child Neurology*. 2010;**5**(1):3-18. ISSN: 2073-8803
- [13] Esipova ES, Kholin AA, Il'ina ES, Zavadenko NN. Presence of epilepsy and non-epileptic paroxysms in children with spastic forms of cerebral palsy. In: 22st Congress of Child Neurologists of Mediterranean; 18-21 October 2017; Ljubljana, Slovenia. Book of Abstracts. p. 12
- [14] Kholin AA, Zavadenko NN, Il'ina ES, Kolpakchi LM, Fedonyuk ID, Bembeeva RC, Esipova ES. Peptidergic nootropic therapy in cerebral palsy associated with epilepsy [article in Russian]. *Zhurnal Nevrologii i Psikhatrii Imeni S.S. Korsakova*. 2017;**117**(9): 37-42. PMID: 29053119. DOI: 10.17116/jnevro20171179137-42