

We are IntechOpen, the world's leading publisher of Open Access books Built by scientists, for scientists

6,900

Open access books available

185,000

International authors and editors

200M

Downloads

Our authors are among the

154

Countries delivered to

TOP 1%

most cited scientists

12.2%

Contributors from top 500 universities



WEB OF SCIENCE™

Selection of our books indexed in the Book Citation Index
in Web of Science™ Core Collection (BKCI)

Interested in publishing with us?
Contact book.department@intechopen.com

Numbers displayed above are based on latest data collected.
For more information visit www.intechopen.com



Crush Injuries of the Hand Part II: Clinical Assessment, Management and Outcomes

Roohi Sharifah Ahmad and Pho Robert Wan Heng

Additional information is available at the end of the chapter

<http://dx.doi.org/10.5772/intechopen.78298>

Abstract

This chapter details crush injuries of the hand as opposed to crush syndrome. The definition along with the spectrum of injury is described including a historical review of the causative mechanisms to help in the understanding of basic pathomechanics. The main menu comprises Clinical Assessment, Management and Outcomes, where the reader is taken through the steps one by one on how to approach such an injury, from the history, examination and investigations pointing out important aspects. Basic facts and figures to know and memorize have been placed in an easy-to-absorb format of tables and highlighted boxes. Key points are emphasized, and important aspects of management as well as those simple tips to improve outcome are given to ease the novice as well as the tempered surgeon's encounter. A special section on management of specialized tissue is given toward the end after the basic management is dealt with so that a deeper understanding is gained and applied. Possible outcomes would alert the surgeon on both adverse events to avoid and excellent results to aim for. As always, good functional outcome is sought after but a good cosmetic appearance should be constantly filed away in mind's eye to enhance the final result.

Keywords: crush, hand, injuries, mangled extremity, trauma

1. Introduction

Crush injuries of the hand pose a challenge to even the most accomplished hand surgeons whether it is a minor fingertip injury sustained by getting squashed in a closing door or a high-pressure compression injury involving the palm or wrist.

2. Clinical presentation

The crush injury may present from the tip of the finger to proximally right up to the arm. Although the management of more proximal and therefore potentially life-threatening injuries is precluded from this chapter, we will deal briefly with their management. There are certain principles in the management of all injuries be they minor or major (**Table 1**), and these have to be adhered to, especially if it is a high-energy trauma as in a road traffic accident (RTA) or a fall from a height.

Thus, the primary aim in any trauma is to stabilize the patient and rule out any life-threatening injuries. Airway, breathing and circulation must be first secured. Subsequent management will focus on the limb at hand and its systemic sequelae. After the early treatment and resuscitation of the patient, antibiotic and tetanus cover is ensured and the hand surgeon alerted for further assessment.

2.1. Clinical assessment

The most important part in the management of the crushed hand is the assessment. The crush injury has to be given due respect because neglect in adequate assessment will result in poor functional outcome or unacceptable cosmesis. Thus, a judgment call by an experienced hand surgeon for all tissue components i.e., skin and its contents (tendon, bone, joint, vessels, nerves and muscles), is essential. The aim of the treatment is to provide the hand with basic hand functions most importantly: functioning *pincer mechanism* and *sensation for grasping* (**Figure 1**).

2.1.1. Functional anatomy of the hand

The hand is basically composed of two types of skin, thick palmar glabrous skin and thin dorsal skin. As can be seen in **Figure 1E**, the dorsal skin is thin, loose, mobile and stretchable. The palmar side, however, is thickened for protection with papillary ridges to increase the surface area as well as improve the grip. These ridges form our finger prints. The fingers are highly innervated to provide a two-point discrimination of 4–6 mm at the fingertip, as measured by the two-point discriminator disc (2-PD: **Figure 1F**). The sweat glands give lubrication to aid in feeling and function (**Table 2**).

There are numerous flexure creases to anchor the skin down, and with the palmaris brevis muscle, they aid in holding and gripping objects. The muscles of the hypothenar and thenar eminences allow specialized functions of opponens, abduction, adduction and flexion (**Figure 2**).

<ul style="list-style-type: none">• Life before limb• Limb can endanger life e.g., compartment syndrome, infection• Look for proximal hidden injuries which can be fatal e.g., head injury, cervical spine injury, associated pneumothorax, intra-abdominal injury• Thorough assessment – primary survey of the patient as a whole• Secondary survey of traumatized limb

Table 1. Principles of management of crush injury.




Figure 1. A–D: Of the four basic functions above, the pincer mechanism or “pinch” function is most useful. Pictures taken from Dr. Lim Beng Hai. **E:** Dorsal skin is thinner and pliable. **F:** A two-point discriminator (2-PD) used to measure sensation, which an unfolded paperclip too can do. The patient is first shown the device and explained how it is used to feel one or two points on their fingertip.

2.1.2. History

The injury may be small involving just the digits or the hand, or it may be more extensive including the wrist and even the forearm. It may even be segmental with intervening areas of normal tissue. It may be open or closed, with associated elements of degloving or avulsion. They may be either clean as in door jamb injuries or obviously dirty as the trash compactor or farm injuries. One must also be alerted to marine-related open wounds with their own peculiar pathogens (*Mycobacterium marinum*). It may be contaminated with paint or grease and be sustained in a high-pressure printing press (see previous chapter, **Figure 13**) or injection mechanism (**Figure 3**). Aggravating factors such as friction burns, industrial hot pressure injuries, multidirectional forces and contamination should be assessed carefully.

Palmar skin	Dorsal skin
1. Specialized glabrous epithelium	Nonglabrous, hirsute
2. Thick cornified surface	Thin
3. Immobile skin	Mobile
4. High-density sensory receptors	Less dense
5. Subcutaneous pulp	Nail matrix & plate

Table 2. Comparison of specialized tissue in palmar & dorsal surfaces.

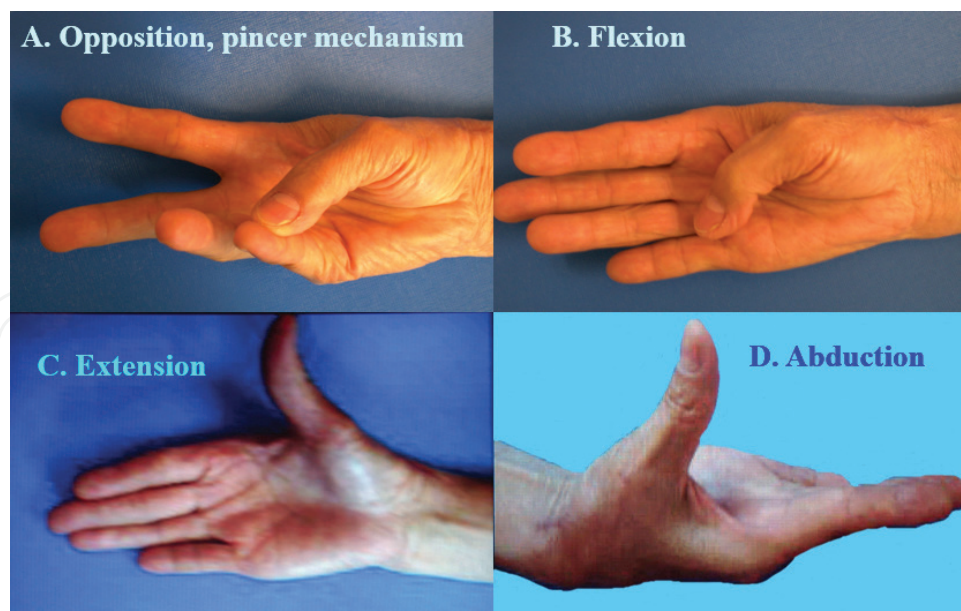


Figure 2. A–D Movements of the thumb: opposition, flexion, extension and abduction. All of these combine to perform circumduction.

The patient's occupation, associated medical conditions and allergies if any, and dominant hand should be recorded. A mental or written note of the patient's expectations would complete the history.

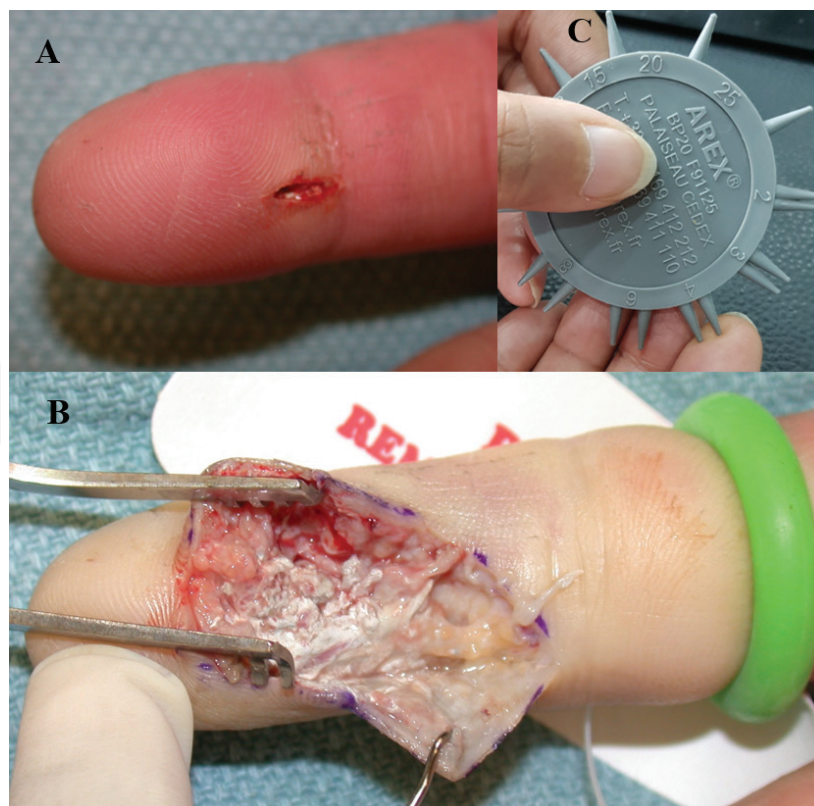


Figure 3. Paint injection injury. **A:** a very small entry point, **B:** but once explored, the extensive damage can be seen. The paint is toxic and needs to be painstakingly cleared. **C:** assessment of nerve function using a 2-PD disc. The test is administered on the normal hand first, then only on the affected digit with the patient's keeping their eyes closed. Just enough pressure needs to be applied so as to lightly blanch the skin.

2.1.3. Examination

Initial assessment in the emergency room can be conducted while obtaining the history from the patient and observing the hand posture, cascade (**Figure 4**), color as well as assessing flexor and extensor mechanisms even without exposing the wound. Local anaesthesia should only be given *after* a sensory examination has been performed, preferably with a 2-PD disc (**Figure 1F**). If delay to theater is expected, a lavage under some local anesthesia maybe performed as necessary. Swabs should be taken if it is potentially contaminated or infection suspected. A more thorough evaluation of the extent of injuries can then be made in the operating theater under general anesthesia and tourniquet control. The assessment should be thorough, with minimum number of wound inspections and made with the surgical treatment options in mind (**Table 3**).

In order to make the choice to replant, reconstruct or amputate, a number of factors have to be taken into consideration (**Table 4**). These deciding factors will influence the surgeon's final decision.

2.1.4. General factors

The patient's general condition is of prime importance in making a decision since an elderly patient in hypovolemic shock would not be able to tolerate further ischemic insult in terms of prolonged operative time and potential blood loss implicated in reconstruction or limb salvage. Similarly, a patient with diabetes would be more prone to infection and complications. In contrast, severe crushing to a contralateral limb would necessitate more extreme measures to attempt salvage. There has been no consensus achieved yet on the maximum time

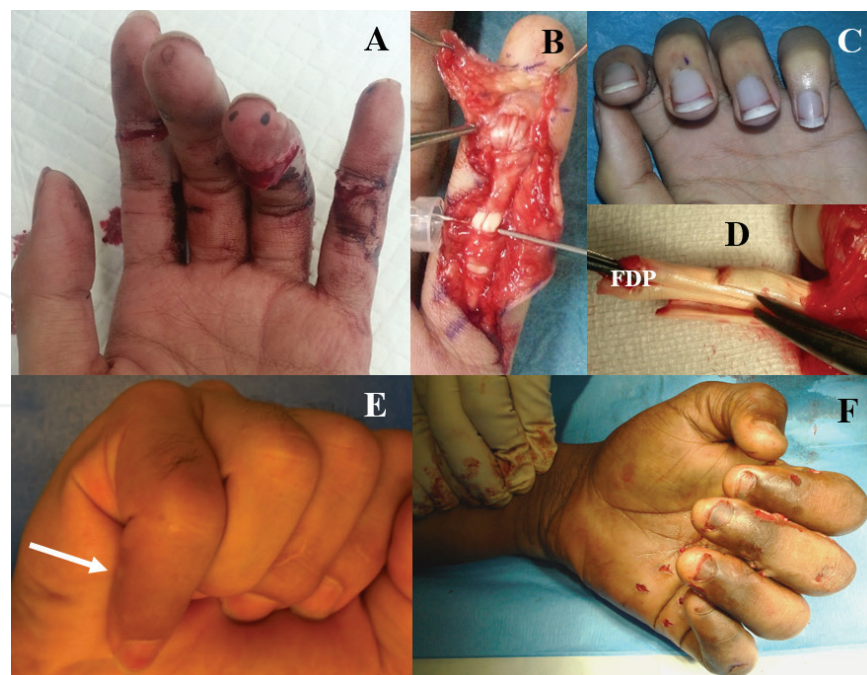


Figure 4. A: Damage to flexor tendons of the index and small fingers can be seen in the flattened posture of those fingers. The index finger cannot be flexed at the DIPJ indicating an intact FDS but a severed FDP (FDS finger). B: adequate exposure by gentle retraction with skin hooks and meticulous repair of both FDS and FDP, allows good motion within the sheaths. C: restoration of the normal cascade. D: the chiasma of the superficialis (tenotomy scissors) opens out and from a volar position proximally, curves 180° to insert dorsal to the FDP on the base of the middle phalanx distally. E: in another patient, the small finger cannot be flexed at the DIPJ indicating an intact FDS but a severed FDP. F: normal cascade of the hand elicited by the squeeze test.

-
1. Replantation
 2. Resurfacing with skin graft
 3. Reconstruct with flap (local or free)
 4. Revision amputation
 5. Rehabilitation—potential prosthesis/orthosis
-

Table 3. Surgical treatment options.

General factors	Local factors
1. Age	1. Circulation
2. Circulatory stability	2. Sensation
3. Life-threatening conditions	3. Tendon movements
4. Associated medical problems	4. Loss of skin
5. Injury to contralateral limb	5. Loss of bone & joints
6. Time lapse—warm & cold ischemia tissue	6. Loss of specialized tissue
	7. Mechanism of Injury

Table 4. Assessment of general factors & local factors.

an amputated part of a limb can tolerate ischemia and gain good functional postreplantation. Many factors are involved such as ambient temperature, collateral circulation and level of amputation. Many attempts have been made to assist in this decision-making process but none are ideal. Although MESS (**Table 5:** Mangled Extremity Scoring System) was initially developed for the lower limb [1], it has subsequently been applied to the upper limb as well with some degree of success, provided one knows its limitations [2, 3]. In this score, a total of six implies the limb is salvageable, while seven or more advocates amputation. The score, however, does not take into consideration other major injuries causing hypovolemia, associated medical conditions, injuries to the other limbs that may necessitate salvage, nerve injuries and the type of damage sustained, and a more subdivided range of ages. The latter is important in that an infant would have better nerve regeneration capabilities than an adult, whereas a 90-year-old would have less cardiovascular reserve than a 50-year-old, both situations not being differentiated. The exact mechanism of injury (crush, avulsion, guillotine), as well as the amount of force, its velocity & the width of the offending object are all important factors in decision-making. Smith et al. suggested three contraindications to major replantation, namely brachial plexus avulsion, severely mangled extremity and an excessive ischemia time [4]. There have been many advances since then to overcome some of these obstacles, for example, highly innovative developments in the field of neuromuscular prosthetics; however, brachial plexus avulsion remains challenging. There will come a time though when an equilibrium will be reached in the two arms.

Skeletal/soft tissue injury	
• Low energy (stab, fracture, civilian gunshot wound)	1
• Medium energy (open or multiple fracture)	2
• High energy (military gunshot wound, crush)	3
• Very high energy (+gross contamination)	4
Limb ischemia	
• Pulse reduced or absent but perfusion normal	1
• Pulseless, diminished capillary refill	2
• Pt is cool, paralyzed, insensate, numb	3
Age	
• <30	0
• 30–50	1
• >50	2
Shock	
• Systolic BP always >90 mmHg	0
• Systolic BP transiently <90 mmHg	1
• Systolic BP persistently <90 mmHg	2

Table 5. Mangled extremity severity score.

2.1.5. The five P's

The most important aspect in the assessment of the limb will be the *vascularity*. Traditionally described as the 5 P's namely:

- Pain
- Paresthesia
- Paralysis
- Pallor
- Pulselessness and additionally a
- Cold limb

Pain, paresthesia and paralysis may not be detected in the head injured patient, patients that are heavily sedated, or those with brachial plexus injuries. Pallor may be unreliable in certain situations such as hypovolemic shock, massive blood loss, pigmented individuals and compartment syndrome. Dyes and other coloring materials as well as grease have to be scrubbed off in order to properly assess the circulation. Other parameters such as capillary refill, bleeding on pin prick, and transcutaneous oxygen pulse pressure may be used as an adjunct in the assessment.

2.1.6. Specific structures

Neurological damage also has to be outlined prior to exploration and also to prepare the surgical field in case a nerve graft is required. Gross sensation being inadequate, two-point discrimination should be used whenever possible to ascertain neurological deficit. Failure to differentiate 8 mm is the cutoff point where damage is certain.

Assessment of **tendons** can be tricky, especially if an adjacent nerve is also damaged or if the injury is closed. The best way to assess tendon damage is to observe the **resting posture** of the hand (**Figure 4C**). The unmistakable cascade of increasing flexion from the index to the little fingers is lost if there is any discontinuity. Complete division of both flexor tendons to the digits results in a straight finger in comparison with the adjacent flexed digits (**Figure 4A**). Division of the flexor digitorum profundus (FDP) straightens out the DIP joint (**Figure 4E**). A cut flexor digitorum superficialis (FDS) alone may not produce any visible abnormality (**Figure 4A**); however, a partial tear may be diagnosed by eliciting pain while stress testing the affected tendon. In a child or semiconscious adult, flexion may be reproduced by squeezing the forearm volar surface (**Figure 4F**). All these subtle differences should be looked for in the initial examination. **Flexor tendons** are tough structures and usually the last to be severed. Nonetheless, they are not easily replaced, having an intricate anatomy and biomechanism not completely reproducible. Therefore, it follows that they should be debrided with care.

Extensor tendons may be partially or totally cut presenting in a spectrum from a closed mallet, to just weakness in extension, or complete inability to extend the finger. Extension should be tested against resistance and if weak may indicate either a partial tear, damage to the collateral bands, or a single tendon cut in a dual tendon finger such as the index or little fingers. Avulsion of the central slip may present as a boutonniere deformity (**Figure 5**). Patency of the central slip is determined by Elson's test, where the finger is tested against resistance with the PIP is flexed 90° over the edge of a table and resistance applied to active extension [5]. If the central slip is avulsed, the PIP extension will be weak and the DIP will be rigid [6].

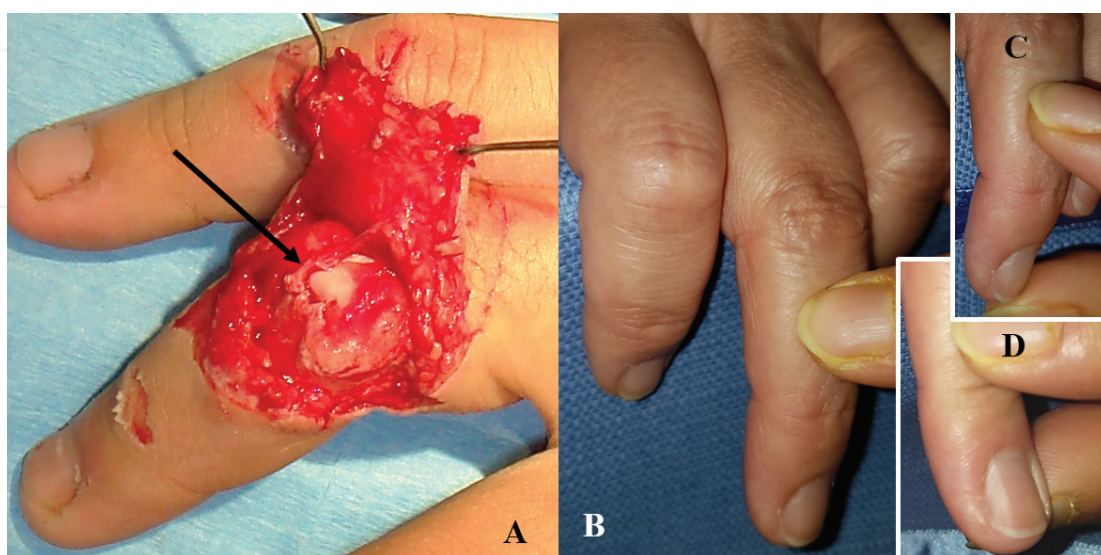


Figure 5. **A:** The central slip is torn (black arrow), and this discontinuity will result in difficulty for the PIP joint to be extended. **B:** The finger can still be extended (weakly) through the lateral bands, which are intact and inserted via the terminal tendon into the distal phalanx. **C:** If the central slip is intact; however, the P3 will be “floppy” (**D**) While extending the PIPJ in flexion. See video by Dr. Mike Hayton: <https://youtu.be/G9HY0qXWUvE> [6].

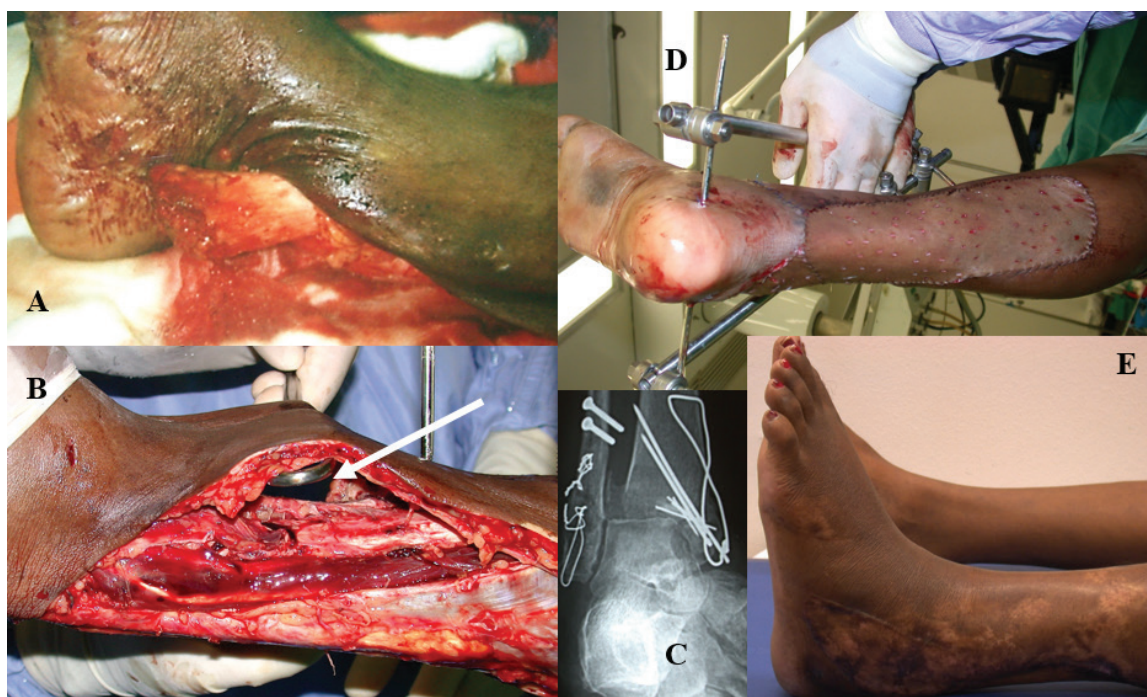


Figure 6. **A:** A 35 year old sustained a highly comminuted fracture of the distal end of her tibia and fibula. **B:** She also had a severe degloving injury (arrow) with partial loss of skin cover. **C:** Meticulous reconstruction with wires, screws and basic principles. **D:** Stabilization with an external fixator and skin graft posteriorly. **E:** Good healing 3 months later with relatively normal gait.

Skin is assessed both from the history and then examination. A roller or roll-over injury suggests degloving (**Figure 6**), which can be more extensive than the wound implies. Bleeding from the wound edge and to pin-prick, color of the skin and separation from the underlying subcutaneous plane all play an important role. If the color is pink with active bleeding and a rapid refill, circulation is intact. If the color is slightly dusky, and the refill is rapid but bleeding is dark in color, there may be venous congestion. If, however, the skin is pale and refill is poor, revascularization may be necessary. A note is made to the patient and his family, of the possible flaps, both local and distant that may be required.

If **radiographs** from the emergency room are not satisfactory in assessing the **bony** injury, it may be necessary to repeat them either after splintage or in the operating room. This would aid in assessing the damage accurately and also in planning the implants to be used in the repair or reconstruction of the skeletal framework. Ideally, anteroposterior and lateral films should be available, and preferably oblique as well if the fracture configuration is complex. Torsional injuries may require reduction and splintage in position prior to radiographic evaluation. It may save time to order chest and cervical radiographs for the preoperative assessment if the patient is older and general anesthesia is required for surgery.

3. Management

3.1. Preoperative assessment

After a relevant detailed history and thorough examination, the patient is worked up for the operative procedure. The assessment is targeted to evaluating his general condition and co-morbidities

if any, and locally to the injury concerned. The pre-operative laboratory tests would depend on the hospital policy, the patient’s age and associated medical conditions if any. Thus, while the older patient (above 40 years of age) would require a chest film, electrocardiogram, full blood count, glucose levels and renal function, the younger patient may do with just the blood counts.

3.2. Surgical treatment

The primary aim of management is to save life, limb and then restore limb function in that order. After that, the aim must be to achieve a function better than that offered by a prosthesis. The principles of replantation and hand reconstruction (Table 6), however, are very stringent and demanding for there is little room for error.

3.3. Radical debridement

The hand surgeon’s greatest enemy is infection secondary to inadequate debridement and lavage, cited by Wang et al. as the most common cause for failure of survival [7]. It follows therefore that the most important step after the initial assessment is meticulous and thorough debridement of all devitalized tissue and foreign bodies to convert a dirty contaminated wound into a clean surgical wound.

Prior to starting surgical debridement, the wound should be adequately irrigated with copious amounts of saline, povidone-iodine (Betadine) and hydrogen peroxide. Some authors have advocated a concoction of the three in a ratio of five parts to one to one, respectively [8]. Washing with gentamycin either neat or diluted with saline is also practiced by some, although clinical support for this is not convincing. Pulsatile lavage has also been advocated as has rigorous scrubbing with a brush. Ultimately, the aim is to get the wound clean *with minimal amount of tissue damage*.

Tomaino said “débridement must be consummate, as if ablating tumor” [9]. Therefore, shredded tendon pieces and avulsed nerve without axonal elements must be excised. Similarly, bone pieces without any muscular or tendinous attachments should be removed. Although difficult to replace some tissue types (such as tendon, nerve and joints), retention of these contaminated or devitalized tissues may result in more harm than good. Whether to debride under tourniquet control or not is dependent on surgeon’s preference. No doubt, the surgical field is much clearer with the tourniquet up, but one has to consider tourniquet time, especially if it is a replantation.

<ul style="list-style-type: none">• Radical debridement to convert dirty to clean surgical wound• Obtain a stable skeletal scaffold• Good soft tissue repair and reconstruction• Adequate skin resurfacing, soft tissue cover• Rehabilitation and mobilization to restore function and early return to work• Cosmetic acceptability by the patient• Psychological support

Table 6. Principles in hand reconstruction.

Preferably, the skin edges should be débrided with a sharp instrument such as a blade without the tourniquet to assess skin, subcutaneous, muscle as well as bony viability. When it comes to fine dissection and meticulous débridement; for example, around vessels and digital nerves, the tourniquet could be inflated for that particular period. Of course, preferentially, tourniquet control is used for repair of bones, arteries & veins, tendons, and nerves in that order. The use of diathermy should be restricted and drains avoided (**Table 7**). The wounds should not be closed under tension, and if highly contaminated, delayed primary closure is entertained. If in doubt, a second look and repeated débridements should be carried out. Emergency free flaps have been found to have a higher rate of success with fewer numbers of procedures. They prevent desiccation of tissue & reduce infection, thus ultimately improving the function and eventual outcome [10].

3.4. Management of specialized tissue

Once the wound has been thoroughly débrided, a secondary inspection should be carried out to assess the damage sustained and the best course of action to be undertaken. Reid classified mutilating injuries of the hand into (1) dorsal injuries, (2) palmar injuries, (3) radial hemiamputation, (4) ulnar hemiamputation, (5) distal amputation, and (6) degloving injuries [11]. Das De et al. preferred assessment of injuries to be based on damage sustained in terms of tissue components—bone & joints, tendon, muscles, nerve, vessels, and skin—involving different anatomical parts [12]. Although various authors have used different anatomical classification areas (e.g., Tomaino—dorsum of hand, volar forearm and thumb-index web [9]), we feel division into digits, midhand, wrist and forearm is simple and useful both anatomically as well as functionally. The various tissues will still have to be considered individually in each of these areas.

3.4.1. Skeletal stabilization

Bones provide the stability and skeletal framework to which the soft tissues are attached while joints offer mobility to the hand and digits. When damaged severely as in crush injuries, the hand becomes flail and thus useless and repair of the skeleton has to be undertaken before soft tissue reconstruction proceeds. It is therefore essential that fracture fixation is adequately performed primarily and is *strong enough to provide a stable scaffold to undertake further soft tissue repairs as well as undergo rehabilitation*. The issue of internal versus external fixation is not so much of a dilemma in the upper limb as it is in the lower limb and decision-making is

-
- Adequate lavage, with saline, gentamycin or H₂O₂
 - Reduction in the prolonged use of the tourniquet
 - Sharp debridement and meticulous tissue handling
 - Minimize diathermy
 - Avoid wound closure under tension
 - Leave wounds open if heavily contaminated
 - A second look and repeated debridements after 48–72 h
 - Emergency free flap if required
-

Table 7. Guidelines to achieve satisfactory debridement and closure of wounds.

relatively straightforward (See previous chapter, Figure 22). The upper extremity is blessed by a better blood supply and less infection. Grade IIIB and IIIC fractures are common but deserve respect and caution. Whether to use plates, screws or Kirschner wires depends on the amount of contamination, bone loss, soft-tissue defect, tendon system and rigidity desired. Of course, surgeon's preference and the time factor play an important role too. There are now a compendium of internal fixation devices of which we find the low-profile variable angle locking plates very handy (**Figure 7**) [13]. When there is a soft tissue deficit, implants may be exposed, but if cover can be achieved within 5–7 days, Godina believes infection is usually not a problem [14]. Bone loss, however, preferably should be grafted within 8–10 days, so long as a clean surgical wound has been created after adequate debridement [15].

Sometimes in severe comminution in the **digits**, closed pinning with cross K-wires has been found to be quite useful, since the intact periosteal sleeve provides support. Some surgeons believe, however, that K-wires cause “spot-welding” of tendons, especially on the dorsum of the hand, pinning down the extensor mechanism. Care should be taken in placement of these wires, which should preferably be buried under the skin and away from tendinous or ligamentous structures for ease of hand rehabilitation as well as reduction in infection rates (especially in tropical climes). They can be removed later if need be rather than earlier if they are subcutaneous.

Severe damage to the **DIPJs** is fairly well tolerated by fusion, but with the advent of the miniscrew (1.0 and 1.2 mm), tiny fractures may be dealt with precisely. The hook plate by Medartis® tackles the difficult dorsal lip avulsion fracture beautifully; however, the sequence of performing the fixation is key and care should be taken not to injure the germinal matrix (**Figure 8**). **PIPJs**, however, are a different matter. Every effort should be made to salvage the PIPJ if feasible especially in a badly mutilated digit. The articular surface should be painstakingly reconstructed with interfragmentary microscrews, cerclage wires, K-wires, or even the hook plates (**Figure 9**). Stable fixation will allow early mobilization and achieve better results.

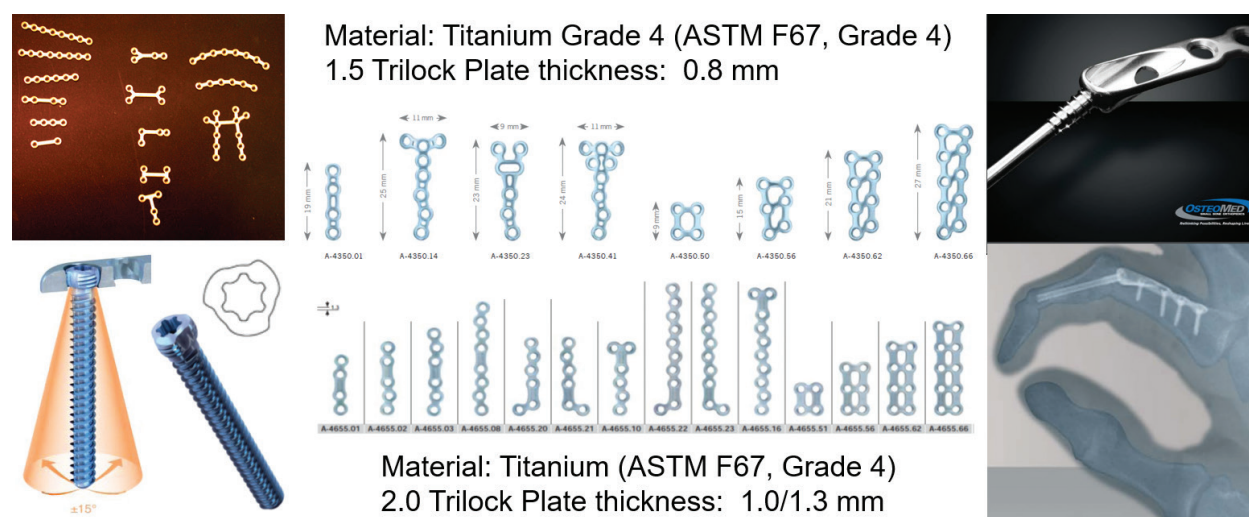


Figure 7. A wide array of titanium low-profile plates of various sizes and shapes are now available to suit the hand surgeon's and patient's needs. Top left: the older miniplates. Left: the trilock mechanism—a neat way to get the screw head to lock in the plate. Middle: the Medartis® range—one of the most “low-profile” plates in the market with chamfered edges for both plates and screws. Right: the Osteomed® PIP and MCP fusion plates—a novel development.

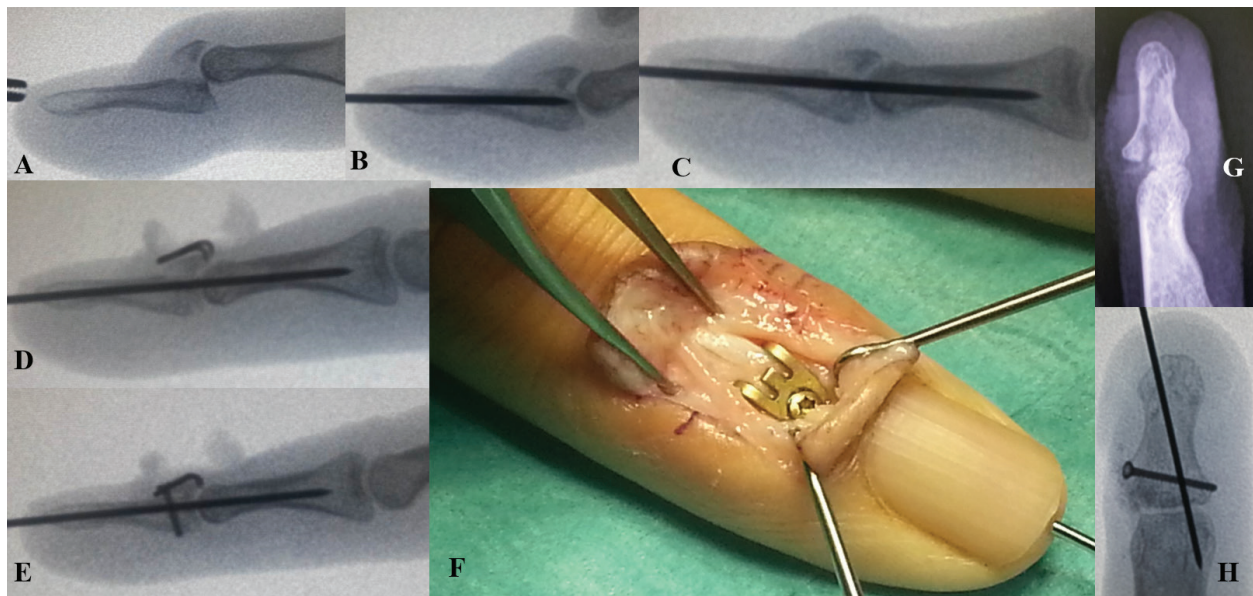


Figure 8. **A:** there is an avulsion fracture of the dorsal lip of the distal phalanx (P3) and the DIP joint is subluxed volarly. **B:** a central 0.8-mm K-wire is inserted in to P3, the joint is reduced and **C:** the wire is pushed into the middle phalanx (P2). **D:** the approach is then made dorsally and the fracture fragment reduced to P3. An incision made in the germinal matrix prevents it from being compressed. **E:** the holding screw is inserted. **F:** final picture. **G:** a severely crushed P3 with mallet deformity requiring bony stability was fixed with a 1.0-mm miniscrew. **H:** postoperative film.

Having said that, however, we have had success with an intra-articular pylon fracture treated nonoperatively with ligamentotaxis (**Figure 10**). MCPJs tolerate fusion to a better degree than PIPJs, but it is rarely required for they adapt quite well to marked degrees of malpositioning. Basal **metacarpal** fractures may be stabilized by transverse K-wiring to maintain height unless it involves the ulnar base of the fifth metacarpal (attachment of the ADM), where

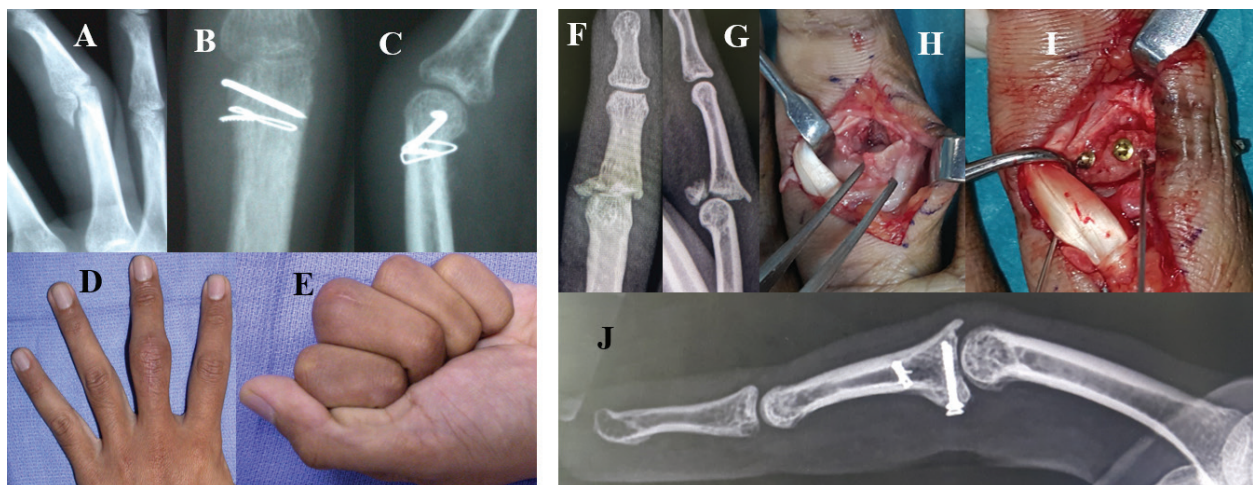


Figure 9. **A:** intra-articular fracture of the radial condyle of P1 of the left MF. **B, C:** reduction and fixation with a 0.6-mm K-wire and a 0.4-mm cerclage wire. **D, E:** good grip and ROM—10–110°. **F, G:** a 23-year-old engineering student presented a month later with a volar lip fracture (P2) and dorsal dislocation of his R ring finger. **H, I:** through a volar approach, the two condylar fragments were reduced and held with K-wires before miniscrews were inserted. **J:** the volar plate was reattached with a bone anchor suture. At 3 months postoperation, he had a 20°-extension lag and full flexion.

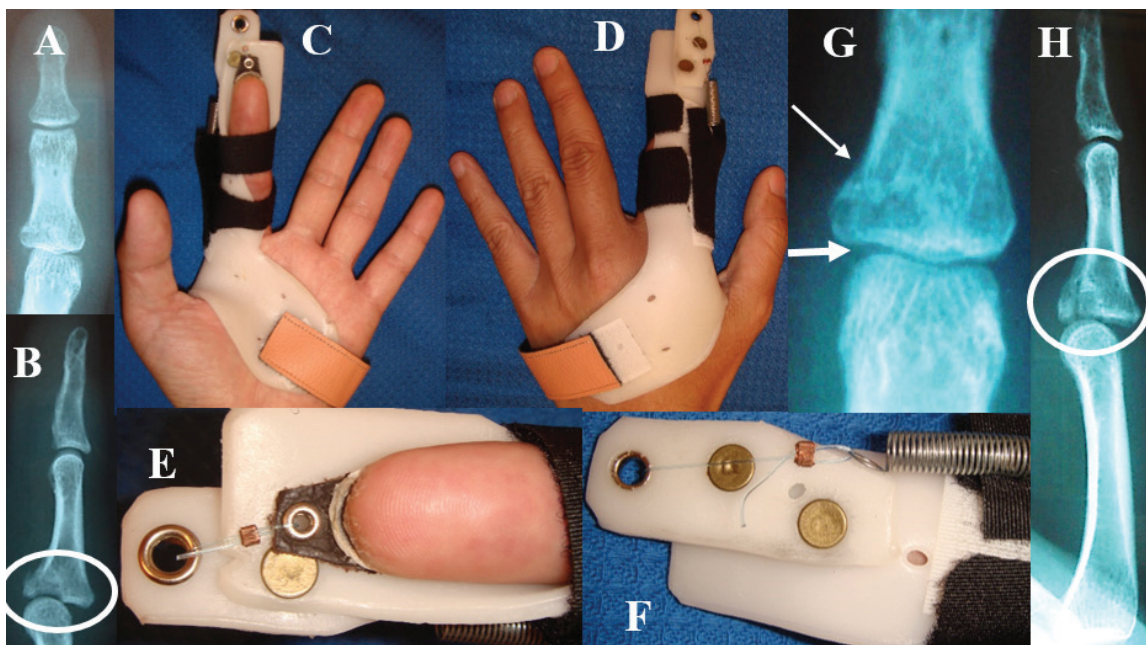


Figure 10. A, B: a die-punch type of pylon injury to the base of the middle phalanx (P2). The patient was not keen on surgery. C, D: overall view of the thermoplastic splint. E, F: close-up view. A strap was glued to the dorsal nail plate and traction applied. G, H: the fracture reduction as seen after 3 to 4 weeks.

fixation ensures no displacement (**Figure 11**). Fractures of the neck of the fifth metacarpal deserve special mention because of the associated stiffness that develops in the MCP joint. Cross K-wiring is good in experienced hands, however, unpredictable in terms of adhesions, so we advocate low-profile plating and early mobilization (**Figure 11**). Metacarpal **diaphyseal** fractures, on the other hand, may require either intramedullary fixation or plates and screws. In spiral fractures, two interfragmentary screws or even cannulated microscrews (**Figure 12**) are warranted for there is a likelihood of shortening. In stabilization of transverse or comminuted fractures, especially in multiple segments and multiple digits, however, *rotation of digits should be given special attention*. Axial and especially rotational malalignment is magnified from proximal to distal starting at the metacarpal level, thus plating is a better option and little added time is necessary. Prevention is the key, by checking rotation after the fixation. The present minihand plates are lower in profile, chamfered (including the screws) and even locking, causing little interference to the tendons and providing the required rigidity. If there is a significant amount of bone loss, the normalization of length can be achieved by transfixing K-wires through the adjacent metacarpals and bone grafting the defect plus plating if the gap is up to 8 cm long (**Figure 13**). Another option, which is useful in replantation surgery, toe transfer or transverse fractures, is intraosseous 90–90° wiring, be it digital or metacarpal level (**Figure 14**). This may also be used to fuse the DIPJ or the PIPJ, as modified by Lister with one intraosseous wire and a transfixing K-wire [16]. The MCPJ can also be fused using a plate and screws: a special set is available from Osteomed® [17] (**Figure 7**). Fusion of a joint primarily has to be thought of carefully and prior discussion with the patient is essential. The angle of fusion would depend on the patient's vocation, age, the dominant hand, involvement of adjacent joints, in the same digit, the neighboring digit and the other hand.

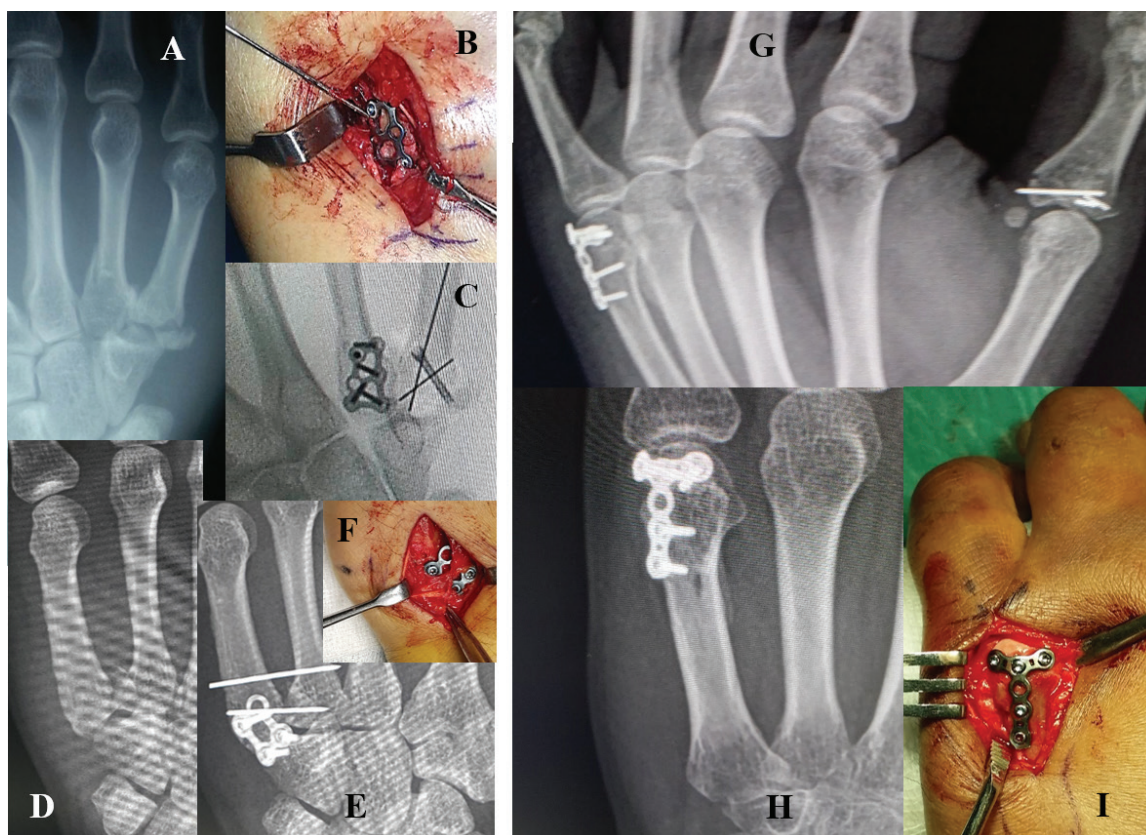


Figure 11. **A:** intra-articular fractures of the bases of the fourth and fifth metacarpals. **B:** a low-profile ladder plate from Medartis® is used to attain precise reduction. **C:** a cannulated screw and K-wires were only possible for the fifth base due to extensive comminution. **D:** another patient with basal fracture dislocation of the fifth metacarpal and CMC joint. **E:** the basal K-wire was used to reduce the fracture fragment, but it started to push it away, so the proximal K-wire was used to maintain height as well as push the fifth metacarpal toward the fourth and hold it in place. **E, F:** a square plate was applied on the dorsal surface straddling the joint with screws in the hamate to keep reduction and immobility. **G, H:** patient with a very distal fracture neck of the fifth metacarpal. **I:** the miniplate applied (1.5 mm Medartis® Aptus) allows a full hand grip without interfering with the tendon mechanism reducing fifth MCPJ stiffness.

Forearm fractures present a challenge since they need to be internally fixed in order to achieve bony stability. In forearm fractures where open fractures are more common than closed [18], Gustillo type I, II and IIIA are safely fixed internally, while with IIIB and IIIC fractures, there is still debate [19]. Early internal fixation (within the golden 6-h period) seems to be acceptable, but patient selection is still important and if in doubt, external fixation is advised, converting 8–10 days later to internal devices when bone grafting can also be done [20].

3.4.2. Tendon repair and reconstruction

Flexor tendons are special because they are not only intricately entwined (**Figure 4D**) but they are housed in a unique tunnel providing nutrition, a smooth gliding environment and a bio-mechanical advantage. This pulley system is as important as the tendons themselves and any damage to the A2 and A4 pulleys should be repaired or reconstructed. Tendon repair should be tension free and fairly good quality tendon should be used. The advantage of a strong repair and early mobilization over a tenuous repair and cautious rehabilitation cannot be over-emphasized.

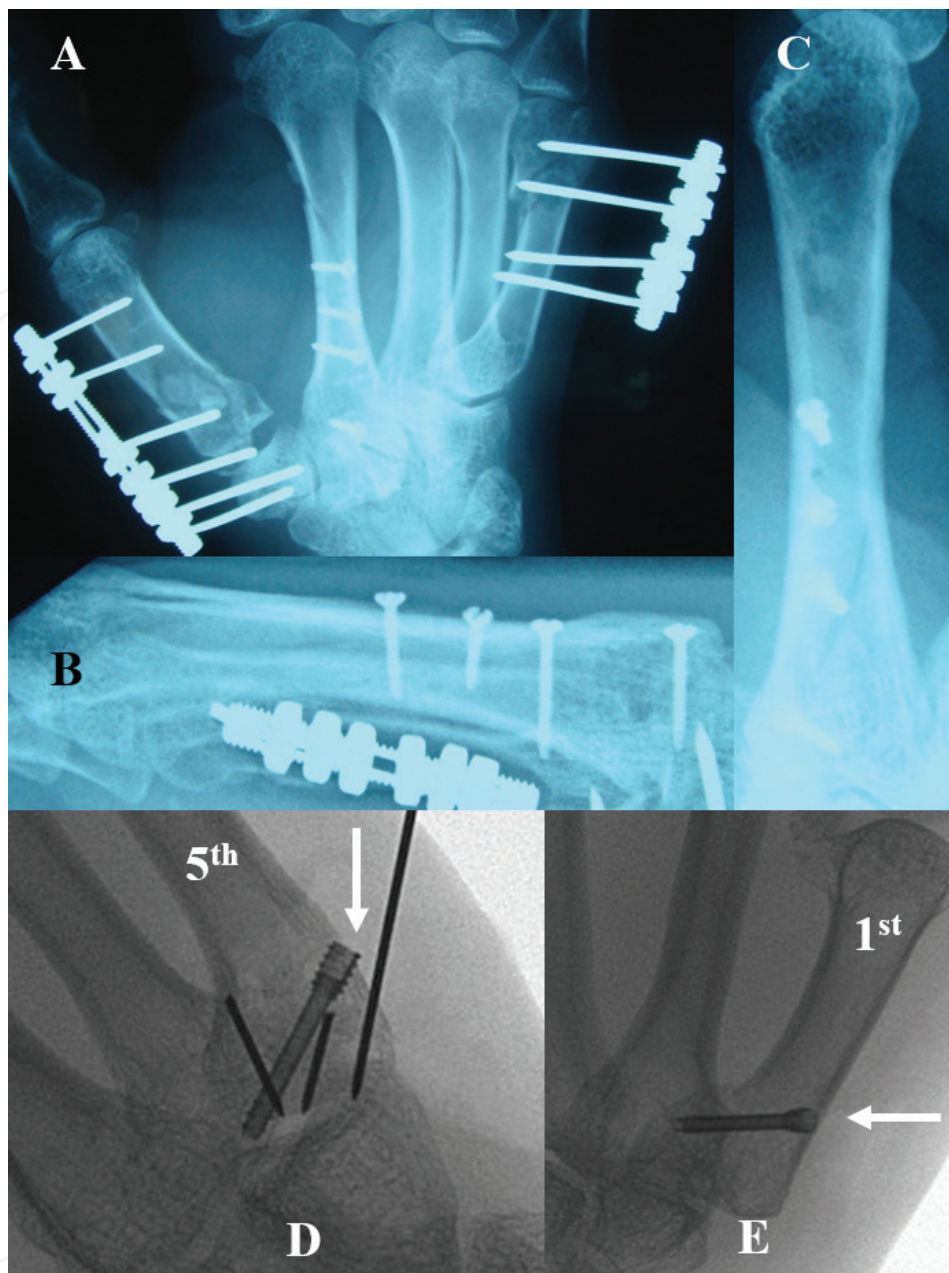


Figure 12. **A:** very comminuted fractures of the first and fifth metacarpals, while the second (**B, C**) was relatively amenable to minimal screw fixation because it was a long spiral. Four screws were required! **D:** a basal fracture of the fifth metacarpal with considerable comminution addressed by a cannulated screw (white arrow) and K-wires. **E:** similarly a single cannulated 2.2-mm screw (white arrow) correctly placed can tackle the volar beak fragment of the first metacarpal fracture.

A strong repair constitutes a 4/0-sized core suture (four or better still six strands) with an epitendinous 6/0 suture, which usually provides 20% of the strength. The key is to balance the number of core sutures (strength) versus overstuffing the flexor tendon and adversely affecting its blood supply [21]. Another point to note is if the technique is too complicated, repeated grasping of the tendon (should only be held once with an Adson toothed forceps) would cause damage. If the tendon is frayed, attenuation and gapping may occur inevitably resulting in delayed rupture and less than optimal results. A tendon gap may be bridged by

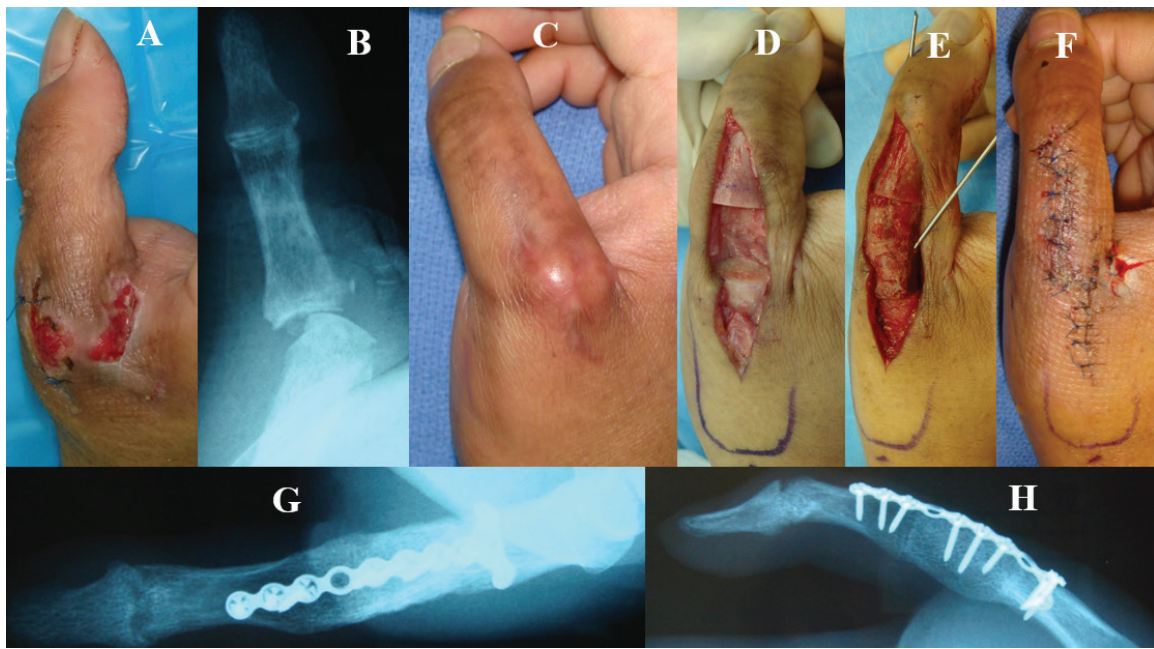


Figure 13. A, B: an infected wound after a snake bite destroyed the proximal phalanx (P1) of this gentleman's right thumb. C: once the infection cleared, the affected thumb was pronated, dislocated and nonfunctional. D, E: a 2-cm segment was removed and replaced (fused) with a bone graft and plated, F: in the correct position.

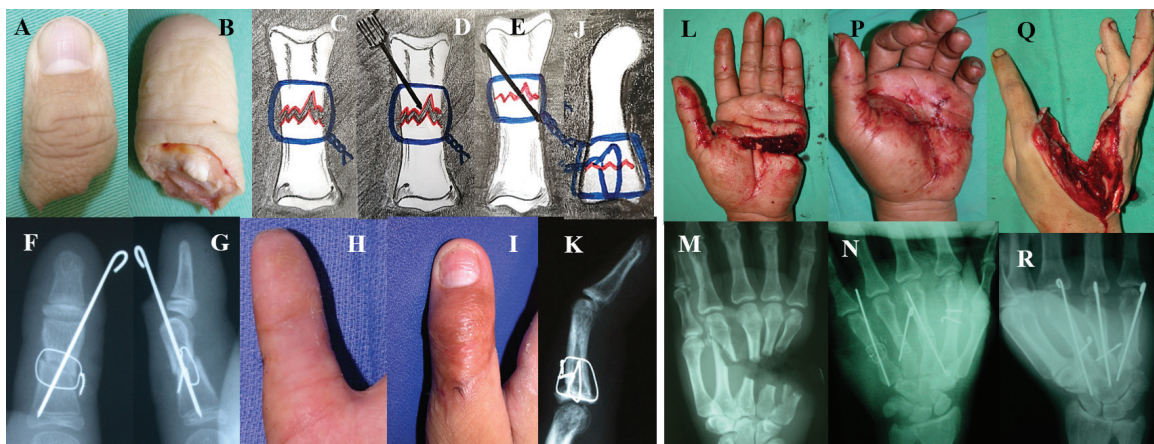

Figure 14. A, B: a complete amputation of the right thumb in a 10 year old. C: the cerclage wire (0.4 mm) is placed in position around the fractured bone ends as shown and twisted. D: an appropriately sized cross K-wire is then passed through the first cortex but not through the fracture site. E: the bone ends are approximated and the wire tightened (a drill may be used for this) with care so as not to break it. The K-wire is then pushed through as reinforcement. F, G: on x-ray. H, I: clinical picture at 3 months. J, K: if no K-wire is used but two cerclage wires are placed at 90° to each other. L, M: a transverse transmetacarpal partial amputation. The metacarpal area has a lot of structure packed tightly together making this a challenging surgery. Minimal and rapid fixation is key to avoid muscle ischemia as well. N, P: Lister's wiring may be used or Q, R: cross K-wires.

an intercalary tendon graft, but extensive damage with resultant tendon loss especially after debridement is best treated with tendon transfers or two-stage reconstruction. If a flexor tendon is forcibly approximated, or the pulleys are by-passed, contracture is almost inevitable (Figure 15).

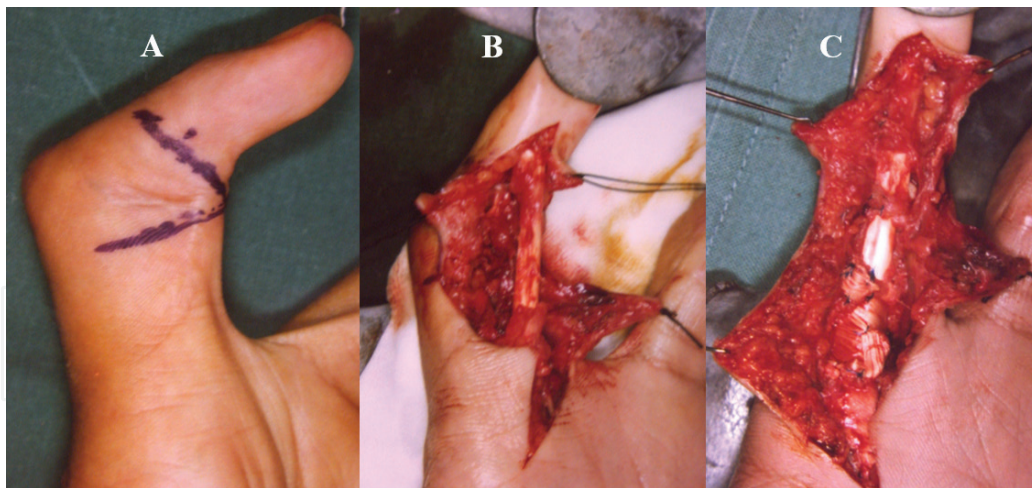


Figure 15. **A:** 17-year-old boy was referred for a flexion contracture of the PIPJ by a district hospital. **B:** the surgeon had done a repair of the FDP tendon outside the pulleys, resulting in “bowstringing.” **C:** a reconstruction of the pulley system was done using one slip of the FDS tendon.

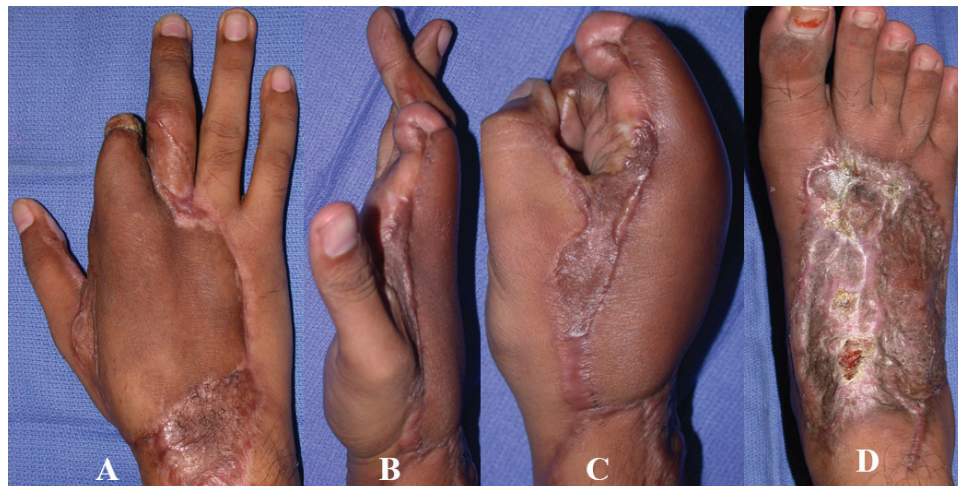


Figure 16. A 25 year old used the dorsum of his right hand to stem his slide on the road from a motor vehicle accident—“brake pad” injury. **A:** dorsal defect exposing second metacarpal, proximal, middle and distal phalanges was covered with a dorsalis pedis flap. **B:** active extension achieved in the index with the extensor digitorum brevis graft anchored to the distal part of the middle phalanx. **C:** a reasonable grip. **D:** the donor defect is not cosmetically pleasing even in a young healthy patient.

Extensor tendons are flatter and more superficial also requiring a favorable soft tissue environment for gliding. Thus, extensive dorsal soft tissue defects with tendon loss should also be treated with tendon reconstruction be it either with a composite graft as in a dorsalis pedis flap (**Figure 16**) or a tendon graft in a free flap. Larger tendon gaps are also not well tolerated if primarily repaired. They cause shortening and alter the biomechanics of the extensor mechanism. The dorsal capsule (wrist) may be used to bridge smaller defects of less than 3 cm (one phalanx). A minimal gap that can be repaired without undue tension, usually gives good results, and is more forgiving than the flexor side. Sometimes even closed management with splintage gives good results as in a closed mallet.

Distal anchorage of tendons can be difficult and various ways have been devised to overcome the problem. The steel suture with a button is traditionally used for zone 1 FDP injuries.

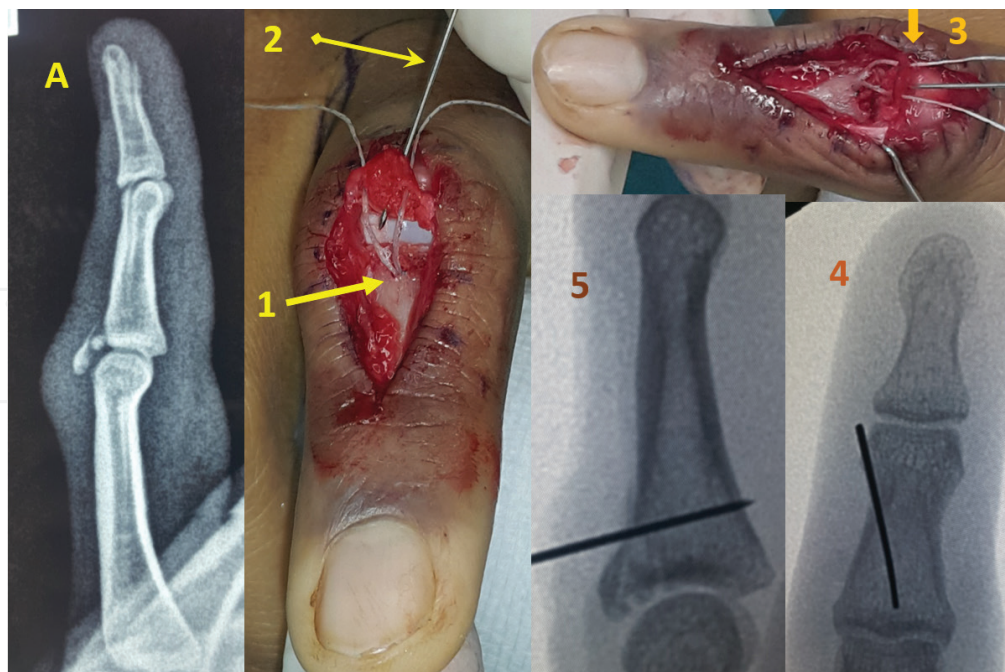


Figure 17. A 25-year-old male skidded off his bike and sustained an extensor central slip avulsion fracture of his right index finger. (1) The first step is to lift off the avulsed fragment and centrally place a bone anchor at the base of the middle phalanx (P2). We used a JuggerKnot soft Anchor 1.0 mm® [23]. (2) An appropriate K-wire is then used to hold the avulsed bone fragment. (3) The suture needles are carefully threaded through either side of the fragment taking care not to fracture it further! (4) The fragment is reduced distal to proximal against the pull of the tendon. (5) K-wire is anchored through volar cortex.

Newer methods include mini-Mitek screws with swaged sutures for both flexor and extensor tendons [22]. These provide firm anchorage to the proximal phalanx, carpal bones and small structures via a 1.8 or 2.0 mm screw and sutures swaged to it to reattach the severed tendon. A very recent product in the market is the absorbable JuggerKnot® soft Anchor 1.0 mm mini where there is no metal implant hence no chance of irritation to adjacent tendons (**Figure 17**).

3.4.3. Muscles

Crushed, contused, contaminated and frayed muscle fibers should be excised to prevent infection. Retention of these would cause fibrosis, contracture and stiffness [24]. Ischemic muscle similarly should be excised. This problem is frequently encountered with the intrinsic muscles of the hand, and special thought should be given intraoperatively since inadequate excision will subsequently interfere with tendon excursion. A “burst laceration” of the first web space also demands *wide excision* and perhaps prophylactic release of certain compartments (see previous chapter, **Figure 19**). A close watch for nerve compressions and compartment syndrome should be instituted with anticipated repeated debridements.

3.4.4. Nerve

Of all the tissues that are damaged, nerve recovery is the worst, even in the best of circumstances. We have made advances in the repair and reconstruction of bone, soft tissue and vessels, but nerve repair remains a challenge. Perhaps biological options may be the way to go in the future—these are promising results [25]. At present, a clean cut nerve in a young patient with the best repair

possible may still not recover full function. The functional outcome of nerve repair depends on the **age** of the patient, the nature (**mechanism**) of the injury, the **distance** from the end organ and any **associated medical** conditions. The younger the patient, the better the outcome, and more aggressive methods may be attempted, such as nerve grafting or using a venous conduit to bridge a gap [26]. In older patients, and those with associated ailments, it is best not to await nerve regeneration, especially if it is a proximal injury. Tendon transfers may be considered at an earlier date, and even primarily. A clean cut injury to the nerve has a better prognosis than crush injuries, which are better than avulsions. If the wound is contaminated or there is a wide gap, it is better to perform delayed nerve grafting. The **nerve involved** also plays a role in functional outcome, the radial being more forgiving as compared to the ulnar, with the median in between. In the fingers, (with the exception of the little finger), the radial digital nerve is preferentially repaired over the ulnar where both cannot be repaired and one has to be sacrificed. In the thumb although both are important, the ulnar digital is essential for pinch grip. In the event of a missing segment, nerve grafts may be harvested from cutaneous nerves in the antecubital fossa.

3.4.5. Vessels

Once skeletal stability is obtained, repair of arteries should take precedence over the veins especially when ischemic time is of importance. This may not be evident in the digits, but in the **hand, wrist and forearm**, it becomes crucial. In **major replantations** and revascularizations, even bony stability may have to be sacrificed in the interest of ischemic time and early reestablishment of circulation. This comes at a cost of subsequent damage to the repair. Alternatively, shunting has been used to decrease the risk of metabolic toxicity upon revascularization and also accumulation of these toxins in the limb by mechanical washout and chemical nutrition. Some have tried free radical scavengers in this process to reduce the ischemic-reperfusion injury (as cited by Shatford and King [3]). In segmental injuries, it may be best to use an interpositional vein graft to achieve reperfusion across the zone of injury.

In the **hand**, blood supply can be adequately assessed by clinical examination. There is little use for angiography and time is of the essence. If a pedicled regional flap based on the ulnar or radial artery is being planned, however, then it may be warranted. Usually, the hand is well perfused with the distal and proximal arches and numerous collaterals. Damage may cause some ischemia that may be noticed only later on in the intrinsic musculature.

In **digits**, the dominant digital artery is usually the radial digital in the little & ring fingers and the ulnar in the index and thumb. These again are preferentially repaired. Repairing one artery and one vein improves circulation to all the ischemic tissues and aids healing. Thrombosed and contused vessels (arteries) should be adequately resected and bridged by an interpositional vein graft if revascularization is indicated. Failure of the digit to pink up after repair should alert the surgeon to check on the patient's hypovolemic, hypothermic and peripheral circulation before proceeding to check the anastomosis, proximal pathology and distal vessel or end organ damage.

3.4.6. Skin and subcutaneous tissues

"Tendons, nerves, joints and bones cannot be left exposed to the outside world and when infected cause sloughing, purulent arthritis, osteomyelitis, months of dressing and final

crippling. All vulnerable parts should be protected from such fate by covering them over and the wound closed, thus saving months of invalidism, compensation and industrial waste, and big permanent disability.” These prophetic words written by Sterling Bunnell in *Surgery of the Hand* in 1944 still stand true to this day.

3.4.7. *Resurfacing options*

In resurfacing a loss of skin and subcutaneous tissue in the hand, the choice option will depend on the **extent** of skin loss, the **site** involved including the **specialized tissue** lost and the personal preferences and **skills** of the surgeon.

The reconstructive ladder (**Table 8**) as referred to by Levin was designed from the simplest option to the technically most demanding [27]. The best option, however, still has to consider the above-mentioned factors and may differ from surgeon to surgeon. With a small sized wound of less than 1 cm², **epithelialization** takes about as much time (2 weeks) as **primary closure**, hence the former is usually chosen. **Skin grafting** has specific requirements, like a healthy bed with adequate blood supply. It cannot be placed on exposed tendons or bone and does not provide sensation. It is not as durable and contouring becomes difficult over the web spaces. Sometimes the damaged skin when healed causes a contracture, which may be dealt with by z-plasty, especially to deepen the first web space or to release a volar flexion contracture in the digits (**Figure 18**). In the first web space, we have found the Ostrowski flap to be particularly useful (**Figure 19**).

A **local flap** garners its blood supply from the surrounding tissue and hence may not be suitable if the bed is unhealthy and sources outside the zone of pathology are preferable.

The **pedicled flap**—so-called because it is based on a named artery—although away from the injury area and does not require microsurgery, has its limitations in size and reach. Besides, donor sites are limited and donor morbidity can be high. However, we have found homodigital neurovascular island flaps, cross finger flaps, reverse digital flaps and posterior interosseous flaps to be useful and safe flaps to cover hand and digital skin losses. The kite flap described by Foucher [29] leaves a prominent scar on the dorsum of the hand (**Figure 20**) but a slight modification as in the radial transposition flap described by Rae and Pho results in a cosmetically pleasing fine line, which can be placed on the radial border of the index [30].

Epithelialization
Direct closure
Grafting—split or full thickness
Local flap
Pedicled flap
Free flap

Table 8. The reconstructive ladder.

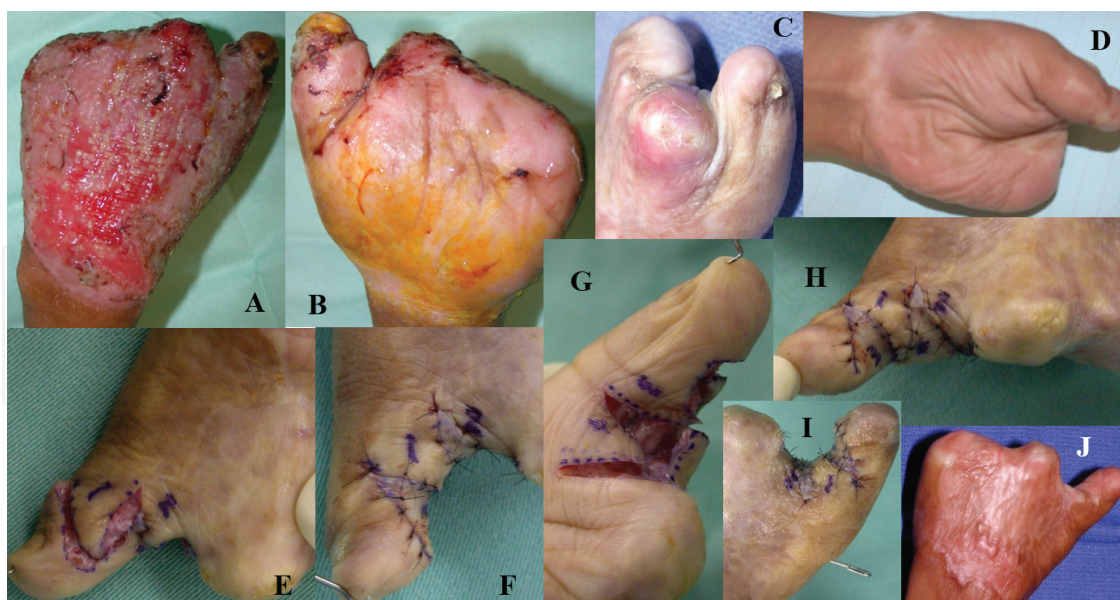


Figure 18. A, B: two days post-trauma (PT), the patient ends up with a metacarpal hand and a partial take of the thumb replantation. C, D: 6 and 9 months PT—there is no pincer grasp. E, F: the dorsal and volar designs of the Z-plasty flaps. G, H: the flaps in place. I: held in abduction with a K-wire. J: final result at 18 months PT.

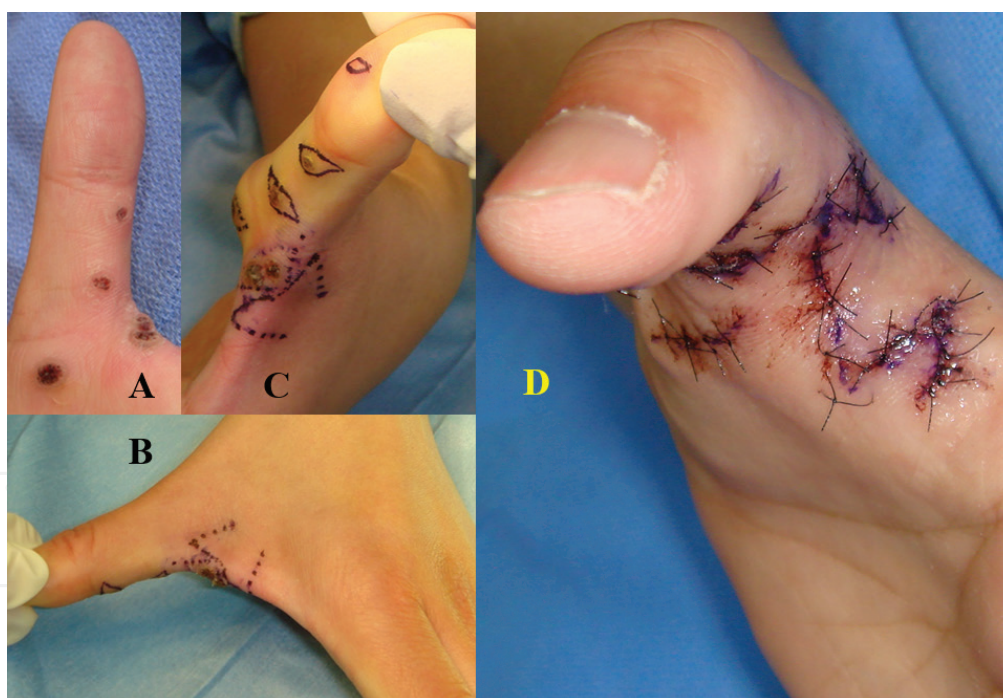


Figure 19. A: a child with multiple viral warts not responding to conservative treatment. B, C: due to the placement of the lesions, it was necessary to perform a flap to prevent later contracture of the first web. D: the Ostrowski flap was thus designed for that purpose [28]. A very useful flap to know for contractures of the first web secondary to burns and crush injuries.

A **free flap** has numerous options, and with choice, suitability increases. It's only disadvantage is that it is technically demanding and the patient has to be able to withstand considerable hemodynamic insult.

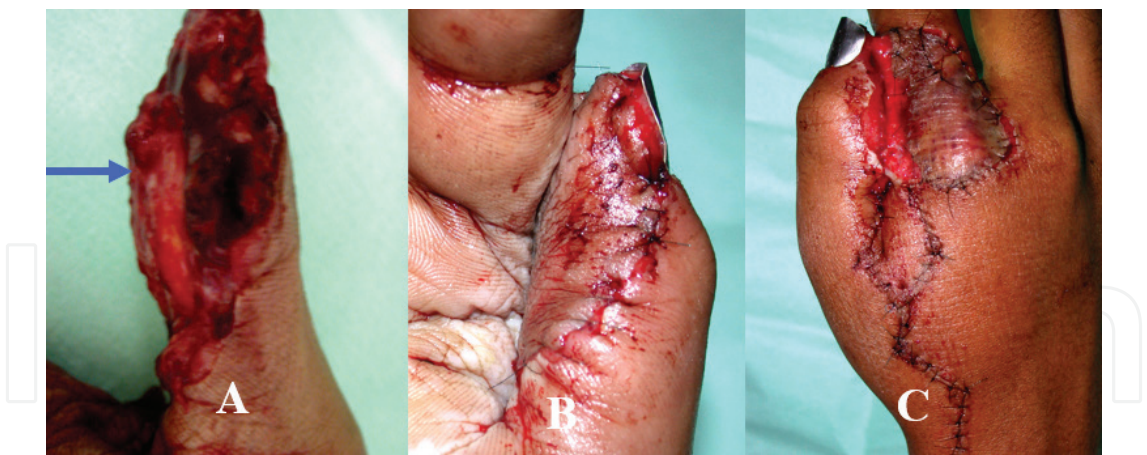

Figure 20. **A:** a large pulp defect of the dominant thumb in a laborer. The flexor pollicis longus (FPL) was intact as can be seen (blue arrow), but the radial neurovascular bundle was sheared off. **B:** a radially innervated cross finger (kite) flap was donated from the dorsum of the adjacent index. **C:** the subsequent donor defect was covered with a full thickness skin graft. See text for options.

Replace like skin for like skin
Mobility over dorsum of hand
Availability of tendons on dorsum
Durability (glabrous) and sensibility
Contouring of web space and fingers
Specialized structures e.g., nail complex
Preferably compatible vessel size
Avoid dependent state e.g., groin flap
Good donor morbidity

Table 9. Principles of hand resurfacing.

The principles of hand resurfacing (**Table 9**) demand that skin should be replaced by like for like, meaning glabrous palmar skin should ideally be replaced by glabrous skin. The skin on the **dorsum of the hand** should be thin and allow for the gliding of the extensor tendons. If there is a deficit of the **extensor mechanism**, then a suitable donor site for a composite flap such as the dorsalis pedis flap may be chosen. Donor morbidity is quite high though. Scheker et al. have shown, however, that tunneling extensor tendon grafts under free lateral arm or groin flaps allows functional tendon excursion [31]. These may be performed as a single stage primary procedure. Medium sized defects can be covered by medialis pedis flaps or groin flaps. The latter can cause dependent edema. Better options include the lateral arm flap, temporalis flap and anterolateral tibial flap. Extensive defects on the **dorsum of the hand or forearm** may require free flaps especially if composite tissue is required and the hand is not to be placed in a dependent position to avoid edema. These may be offered by latissimus dorsi, serratus anterior or parascapular flaps. Medium to large defects of **glabrous skin** may be obtained as a free flap from the medial aspect of the sole of the foot, at the medial arch,

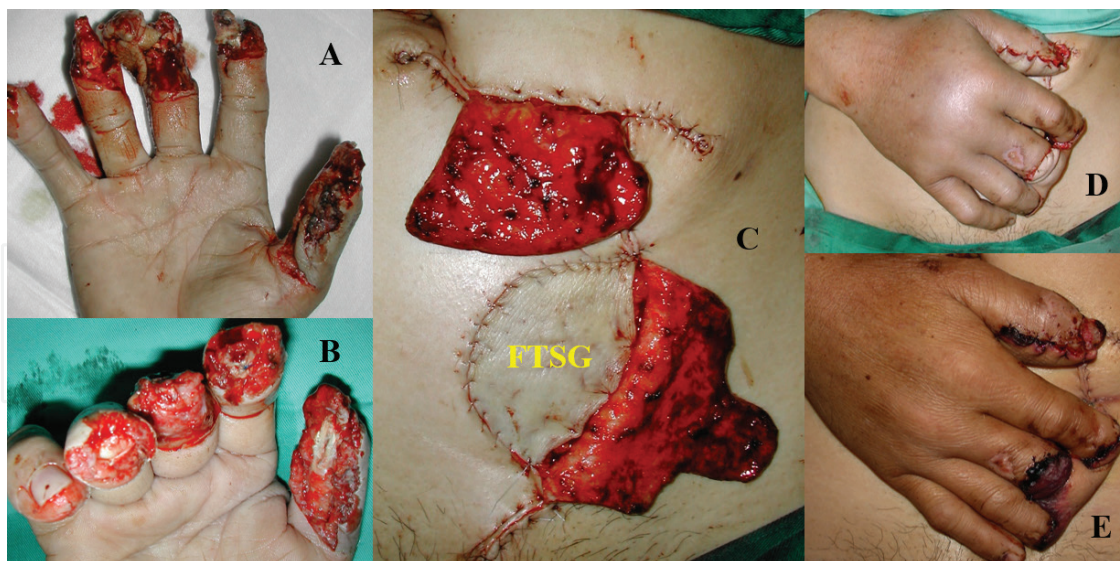


Figure 21. A: severe crushing of all digits in a 56-year-old man. B: postdebridement. C: a custom-designed abdominal flap to cover the deficit. D: the right hand in place. Notice the dependent edema. E: 20 days post op, prior to division of the flap.

in the form of either a medial plantar flap or a medialis pedis flap, while small defects on the palmar aspect may be covered by local or pedicled flaps such as a thenar, cross finger or neurovascular island flap. Replacement of the pulp may be sufficient with the former if small, but may require a toe pulp transfer if large. The posterior interosseous flap is a good flap to use, since it does not rob the forearm of one of its dual blood supplies, has an extensive coverage area and may even replace bone [32]. It is often used to widen the first web space but can be extended distally to cover just up to the metacarpophalangeal joint. However, it can be used to cover multiple digital and pulp losses by flexing the digits. Alternatively, multiple **digits** can initially be syndactylized and surfaced with a pedicled groin or abdominal flap

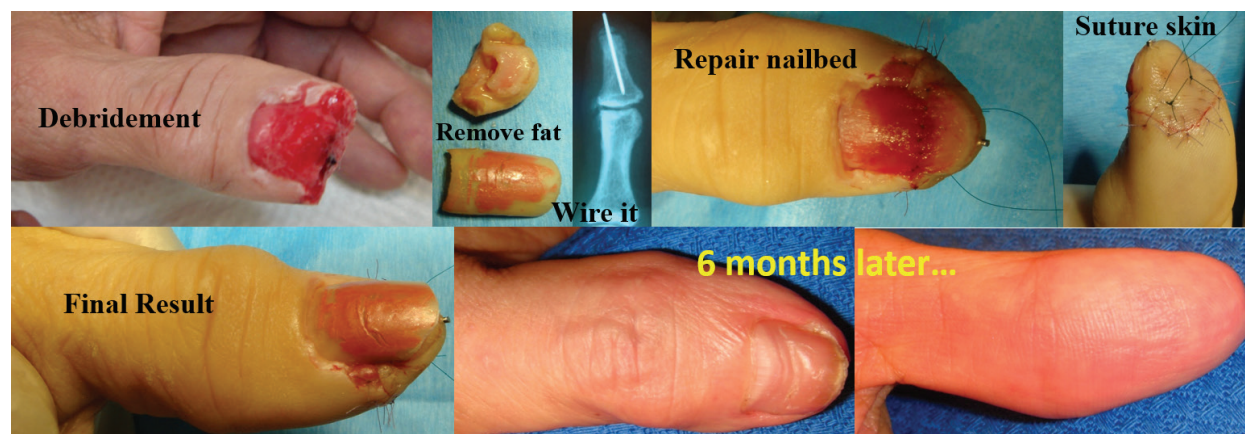

Figure 22. A 73-year-old lady caught her thumb in the door and sustained a complete amputation as shown. The amputated part was only brought in 24 h later although it was stored in a fridge. All the subcutaneous fat was removed completely and the sterile matrix and hyponychium remained. The skin edges were trimmed. The next step is to fix the remnant bone to the proximal fragment and compress it tight. The nail bed is then meticulously repaired with Vicryl 7/0. The skin is sutured with Ethilon 6/0 as a full thickness graft. Flavine emulsion dressing is applied. A reasonable good result is obtained and 2-P.D. Returns to at least 5–6 mm.

(**Figure 21**), with subsequent release. Alternative options include a medialis pedis flap, which has compatible vessel size and good donor morbidity. For single digits and smaller areas, Littler's flap, free vascular island flaps, or venous flaps may be utilized. Distally based flaps of degloved skin may be revascularized by restoring both arterial inflow and venous outflow.

The **fingertip** is composed of the nail complex and the pulp. Both of these are highly specialized tissue and require meticulously sparing debridement. The **nail complex** is composed of the nail plate, and the nail bed sitting on the distal phalanx being proximally covered by the eponychium. Nail bed lacerations should be repaired under loupes magnification with absorbable 6/0 if not 7/0 sutures (**Figure 22**), while nail bed defects may require grafting. More extensive loss may require a partial toe transfer especially in thumb reconstruction. Other options for the nail complex and distal phalanx would be to use a second toe or a great toe wrap around.

Pulp loss replacement is for cosmetic reasons similar to the nail complex. It is highly sensitive at the tip and hence prone to neuromas and hypersensitivity. Minimal loss can be replaced by V-Y, thenar, cross finger or hypothenar flaps, while more extensive loss requires toe pulp transfer [33].

4. Learning from outcomes and case examples

4.1. Fingertip injuries and amputations

These are by far the most common hand injuries seen in the emergency and may range from a simple laceration to a complete amputation of the fingertip. The anatomy of the fingertip may be accessed in many esteemed publications but the basic components that are the bone, the overlying nail bed and the volar pulp. As mentioned before, the scaffold must sustain the structure, thus it is imperative to achieve bony stability. **In children**, it may not be necessary (and even detrimental to the blood supply) to place a Kirschner wire, and up to the age of 5, the amputated part may just be capped on with gentle encircling sutures of 7/0 Vicryl or 6/0 Monosyn depending on the size of the digit (See previous chapter, **Figure 11**). The key is to reinsert the original nail plate or a synthetic material in the eponychial fold—for at least 2 weeks—to maintain it open. **In adults**, of course replantation has the best outcome [34], but if the amputation is through the midpoint of the nail plate, we find a good cosmetic outcome—with a much lower learning skill—can be achieved by performing a “cap reattachment” [35], also known as a non-microsurgical attachment, somewhat similar to a composite graft [36]. The basis we believe behind this is that all the three structures are meticulously approximated by fine sutures to provide a continuum of the blood supply, encouraging healing. First, the amputated part is thoroughly cleaned by removing **only** the subcutaneous fat from under the skin and leaving in essence a full thickness skin graft (with the edges trimmed), the bone and the hyponychium with the sterile matrix still attached to it. The bone is then K-wired together and compressed proximally. The nail bed is sutured and lastly the skin is tied over and attached as one would do a full thickness graft (**Figure 22**). A “cap” graft in our experience may be performed for crush injuries with amputations just distal to the lunula (Tamai I or Allen II) with opposition of all the three components of tissue (pulp, nail and bone) as described in [37, 38].

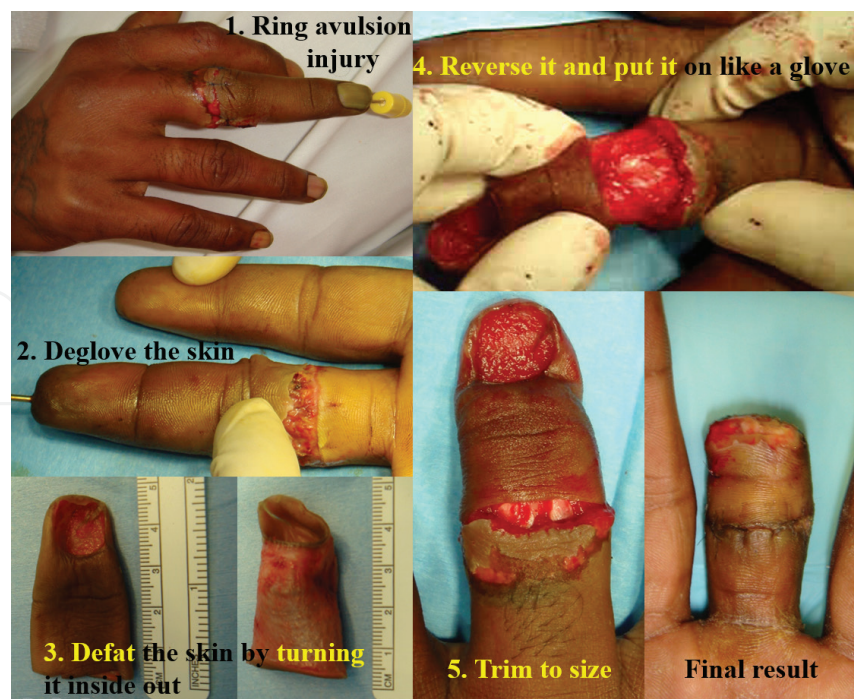


Figure 23. Ring full thickness skin graft (FTSG) in an avulsion amputation or a failed replant.

4.2. Digital amputations

Without doubt, amputations are challenging to the junior as well as the senior surgeon and the difficulty increases the more distal it is. Although replantation is the most obviously best option if it is possible and there are a number of good articles on the technique [34, 39, 40], a revision amputation may be performed with some tips and tricks in mind to maximize the function. In a ring avulsion injury where the skin and subcutaneous tissues are avulsed and the bone plus tendinous structures are intact, or not (Urbaniak II, III), a ring skin graft may be applied (**Figure 23**) and the use of some regenerating agents may prove to be helpful [41]. Wherever possible, the proximal interphalangeal (PIP) joint should be preserved, for a prosthesis is more functional at this level. Replantation of digits with amputations distal to the FDS insertion do better as opposed to zone 2 ones and Urbaniak advocates amputation [42]. In these instances, placing a full thickness skin graft in a ring fashion may be helpful because it is firmly adherent on its base, provides a good cosmetic outcome and is relatively easy to perform. Alternatively, an abdominal flap may be fashioned (**Figure 19**) or a venous flow through free flap, in increasing degrees of difficulty.

4.3. Multiple fractures and soft tissue injuries

The key is to stabilize the bony structure as sturdily and speedily as possible. Once that is achieved, the soft tissue elements will fall into place and be relatively easier to repair and reconstruct. The servile Kirschner wire may prove to be very useful as do the miniexternal fixators from LINK®. It is extremely useful to master Lister's technique as well as polishing one's skills in applying a (minilocking) plate. We have found using bone grafts (synthetic) may aid

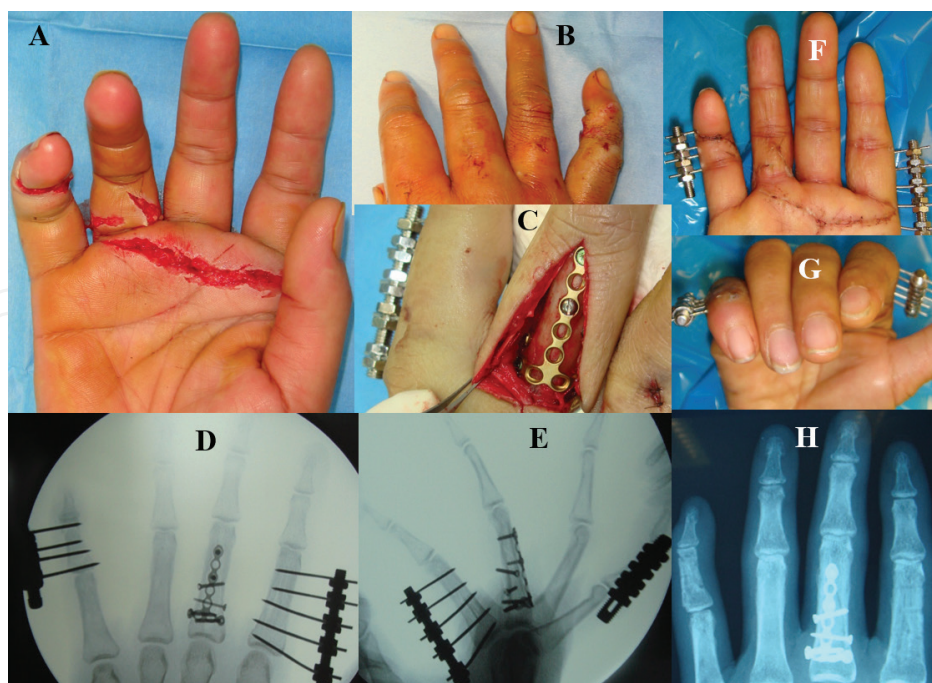


Figure 24. A, B: a crushing line of force runs across all four fingers, sparing the ring. C-E: miniexternal fixators were applied to the border digits—the index and small, whereas the middle was plated partly also due to extensive comminution. F, G: she was able to move within a week of the trauma. H: fixators removed after 6 weeks and plating remains.

tremendously in filling up gaps and aiding the healing process. Restoration of blood supply or minimizing use of the tourniquet is also a tip to remember. In a number of cases of forklift injury to the hand where multiple comminuted fractures occurred in one hand, we used a combination of plates, screws and external fixators to attain rapid stabilization of the skeleton (Figure 24). Damaged flexor and extensor tendons were also repaired in the same sitting.

5. Poor functional outcome

A poor outcome is unintentional and part of a learning curve that a surgeon goes through. There are certain pointers to avoid, which ensure known complications (Figure 25) do not occur. Amongst these are:

- i. a poor history, neglecting to ask the mechanism, the ischemic time and if the patient smokes!
- ii. insufficient radiographs depicting the extent of injury
- iii. inadequate wound debridement of devitalized and crushed tissue leading to delayed healing and infection
- iv. infection causing fibrosis, scarring and contracture, a sure sign of stiffness
- v. insufficient strength of repair of structures (such as nerve, tendon and bony stabilization) to start early active rehabilitation

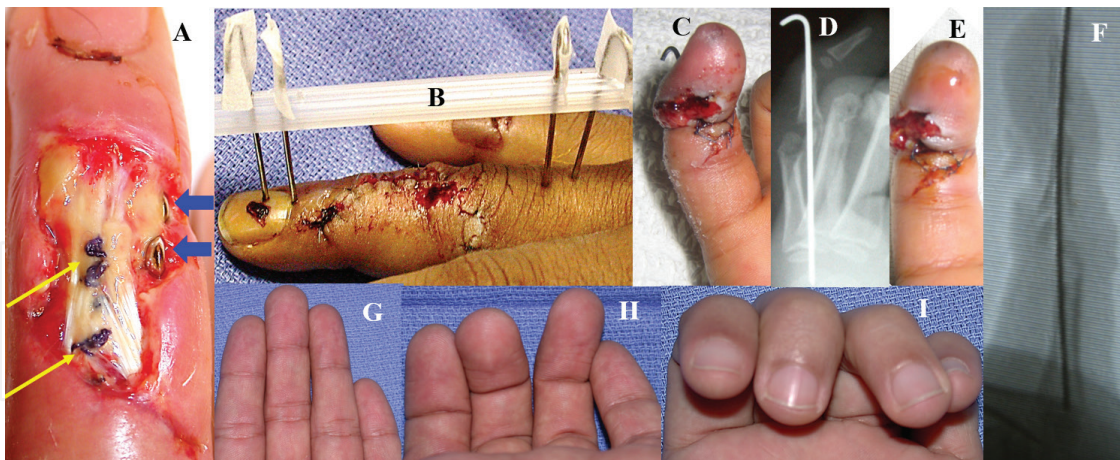


Figure 25. A: extensor tendon repair with Vicryl 3/0 (yellow arrows)—it eroded the thin overlying dorsal skin. The screw heads (blue arrows) are way too big too. B: K-wires passed through the germinal matrix will result in nail deformities. C, D: an enormous K-wire driven through a 5-year-old's little finger causing sluggish venous return. E: wire removal decongests. F: a finer wire does the trick. G: no malrotation. H: on slight flexion, the malrotation of the ring is seen. I: full flexion reveals more.

- vi. poor vascular bed and perfusion leading to iii as well
- vii. inadequate soft tissue cover especially over hardware or incorrect choice of implant size
- viii. placing fixation through the germinal or sterile matrix resulting in nail deformities
- ix. malunion in terms of angulation or rotation—1° of MC rotation results in 5° of fingertip malrotation [43] and 5° of MC rotation ends up with 1.5 cm digital overlap [44], thus fixation has to be very precise
- x. malunion in terms of shortening—2 mm of MC shortening produces a 7° extension lag, while 1 mm of P1 shortening gives a 12°-extension lag [43]
- xi. skin closure under tension will result in ischemic and necrotic tips
- xii. poor hand immobilization.

Thus as can be seen, most of the adverse outcomes can be avoided. The hand surgeon has a multitude of options in resurfacing the hand. Though there are challenges to be overcome, present day microsurgical and other techniques together with biological options offer the hope of good functional outcome in crush injuries to the hand.

6. Conclusion

These are devastating injuries that are daunting; however, after the patient is stabilized and initial first aid is administered, the assessment should provide a checklist of what is damaged, and what is available for reconstruction; this would include what may be “scavenged” from the parts that are not reattachable—such as skin, parts of bone, even tendons nerves and vessels. The most challenging part is for the surgeon to accept that a “normal” hand will not result

but we must remember that if almost all is lost, whatever we salvage is a plus point. Having said that, there are some main points to bear in mind—the goal should be the “greatest total benefit for our patient” [45], which may be different in various countries, cultures and beliefs. Clear communication, an idea of what is feasibly possible and the likely end result are some of the factors to bear in mind when discussing options with the patient and their relatives.

Acknowledgements

Roohi SA would like to thank Prof. Dr. Lim Beng Hai for his guidance as well as the use of some of his work in the figures as acknowledged. With gratitude to great teachers: Drs. Gill RS, Shukur MH, and Pathmanathan V.

Conflict of interest

The authors declare no conflict of interest and have not received any remuneration or benefit from any entity for the writing or publication of this article.

Appendix & nomenclature

2-PD:	two-point discriminator
ADM:	abductor digiti minimi
DIPJ:	distal interphalangeal joint
FDP:	flexor digitorum profundus
FDS:	flexor digitorum superficialis
K-wire:	Kirschner wire
MCPJ:	metacarpophalangeal joint
MESS:	Mangled Extremity Scoring System
MVA:	motor vehicle accident
P:	phalanx 1: proximal, 2: middle, 3: distal
PIPJ:	proximal interphalangeal joint
PT:	post-trauma
ROM:	range of motion
RTA:	road traffic accident

Author details

Roohi Sharifah Ahmad^{1*} and Pho Robert Wan Heng²

*Address all correspondence to: roohihandsurgery@gmail.com

1 Universiti Putra Malaysia, Serdang, Selangor, Malaysia

2 National University of Singapore, Singapore

References

- [1] Johansen K, Daines M, Howey T, et al. Objective criteria accurately predict amputation following lower extremity trauma. *The Journal of Trauma*. 1990;**30**:568-73
- [2] Durham RM, Mistry BM, Mazuski JE, Shapiro M, Jacobs D. Outcome and utility scoring systems in the management of the mangled extremity. *The American Journal of Surgery*. 1996;**172**(5):569-574
- [3] Shatford RA, King DH. The treatment of major devascularizing injuries of the upper extremity. *Hand Clinics*. 2001;**17**(3):371-393
- [4] Smith RJ, Malt RA, Harris WH, et al. Long-term results of upper-limb replantation. In: Urbaniak JR, editor. *Microsurgery for Major Limb Reconstruction*. St Louis: CV Mosby; 1987
- [5] Elson RA. Rupture of the central slip of the extensor hood of the finger. A test for early diagnosis. *Journal of Bone and Joint Surgery*. 1986;**68-B**(2):229-231
- [6] Elson's Test by Dr. Mike Hayton. Available from: <https://youtu.be/G9HY0qXWUvE>
- [7] Wang SH, Young KF, Wei JN. Replantation of severed limbs—Clinical analysis of 91 cases. *Journal of Hand Surgery*. 1981;**6A**:311-318
- [8] Lester B. Crush Injuries in the Acute Hand. Applegate & Lange; 1999. pp. 259-267. Chapter 17
- [9] Tomaino MM. Treatment of composite tissue loss following hand and forearm trauma. *Hand Clinics*. 1999;**15**(2):319-333
- [10] McCabe SJ, Breidenbach WC. Role of emergency free flaps. *Hand Clinics*. 1999;**15**(2):275-288
- [11] Reid DAC. Escalator injuries of the hand. *Injury*. 1973;**5**(1):47-50
- [12] Das De S, Tai LS, Pho RW. Emergency repair and reconstruction in the severely crushed hand. *World Journal of Surgery*. 1991;**15**(4):470-476
- [13] Medartis® Aptus Trilock Plates—A Unique Locking System. Available from: http://www.medartis.com/uploads/HAND-01010001_v6.pdf
- [14] Godina M. Early microsurgical reconstruction of complex trauma of the extremities. *Plastic and Reconstructive Surgery*. 1986;**78**:285-292

- [15] Freeland AE, Jabaley ME, Burkhalter WE, et al. Delayed primary bone grafting in the hand and wrist after traumatic bone loss. *Journal of Hand Surgery*. 1984;**9A**:22-28
- [16] Lister G. Intraosseous wiring of the digital skeleton. *Journal of Hand Surgery*. 1978;**3A**(5):427-435
- [17] Osteomed Fusion Set (HPS). Available from: <http://osteomed.com/Literature/OsteoMedHand-Fusion-Brochure.pdf>
- [18] Boyd HB, Lipinski WW, Wiley JH. Observations on non-unions of the shafts of long bones, with a statistical analysis of 842 patients. *The Journal of Bone and Joint Surgery*. 1961;**46A**:159-168
- [19] Gustillo RB, Mendoza RM, Williams DN. Problems in the management of type III (severe) open fractures. *The Journal of Trauma*. 1984;**24**:742-746
- [20] Shea KG, Fernandez DL, Casillas M. Fixation methods in contaminated wounds and massive crush injuries of the forearm. *Hand Clinics*. 1997;**13**(4):737-743
- [21] Gill RS, Lim BH, Shatford RA, Toth E, Voor MJ, Tsai TM. A comparative analysis of the six-strand double loop flexor tendon repair and three other techniques: A human cadaveric study. *Journal of Hand Surgery*. 1999;**24A**(6):1315-1322
- [22] Merle M, Duteille F, Rehart S, et al. Use of Mitek anchors in the digits. *Techniques in Hand & Upper Extremity Surgery*. 2000;**4**(3):189-200
- [23] The JuggerKnot® soft Anchor 1.0mm mini. Available from: <http://www.zimmerbiomet.com/medical-professionals/sports-medicine/product/juggerknot-soft-anchor-1-mm-mini.html>
- [24] Chow SP, So YC, Pun WK, Luk JD, Leong JC. Thenar crush injuries. *The Journal of Bone and Joint Surgery*. 1988;**70B**(1):135-139
- [25] Hassan NH, Sulong AF, Ng M-H, Htwe O, Idrus RBH, Roohi S, Naicker AS, Abdullah S. Neural-differentiated mesenchymal stem cells incorporated into muscle stuffed vein scaffold forms a stable living nerve conduit. *Journal of Orthopaedic Research*. 2012;**30**(10):1674-1681
- [26] Tan CW, Ng MH, Ohnmar H, Lokanathan Y, Nur-Hidayah H, Roohi SA, Ruszymah BHI, Nor-Hazla MH, Shalimar A, Naicker AS. Sciatic nerve repair with tissue engineered nerve: Olfactory ensheathing cells seeded poly (lactic-co-glycolic acid) conduit in an animal model. *Indian Journal of Orthopaedics*. 2013;**47**(6):548-552
- [27] Levin LS. The reconstruction ladder: An orthoplastic approach. *The Orthopedic Clinics of North America*. 1993;**24**:393
- [28] Ostrowski DM1, Feagin CA, Gould JS. A three-flap web-plasty for release of short congenital syndactyly and dorsal adduction contracture. *Journal of Hand Surgery*. 1991;**16A**(4):634-64
- [29] Foucher G, Braun JB. A new island flap transfer from the dorsum of the index to the thumb. *Plastic and Reconstructive Surgery*. 1979;**63**(3):344-349

- [30] Rae PS, Pho RWH. The radial transposition flap a useful composite flap. *The Journal of Hand Surgery, European Volume*. 1983;**15**(1):96-102
- [31] Scheker LR, Langley SJ, Martin DL, et al. Primary extensor tendon reconstruction on dorsal hand defects requiring free flaps. *The Journal of Hand Surgery British & European Volume*. 1993;**18B**:568-575
- [32] Penteado CV, Masquelet AC, Chevrel JP. The anatomic basis of the fascio-cutaneous flap of the posterior interosseous artery. *Surgical and Radiologic Anatomy*. 1986;**8**:209-215
- [33] Yeo CJ, Sebastin SJ, Chong AKS. Fingertip injuries. *Singapore Medical Journal*. 2010;**51**(1):78-87
- [34] Dagum A. Fingertip amputations: Supermicrosurgery and replantation. In: Rozmaryn L, editor. *Fingertip Injuries*. Cham: Springer; 2015. pp. 83-95
- [35] Roohi SA, Zanariah O, Naicker AS. Preliminary results of a new technique in the management of fingertip injuries. *Journal of Hand Surgery European*. 2008;**33**(S1):164
- [36] Choo J, Sparks B, Kasdan M, Wilhemi B. Composite grafting of a distal thumb amputation: A case report and review of literature. *Eplasty*. 2015;**15**:29-36
- [37] Tamai S. Twenty years experience of limb replantation review of 293 upper extremity replants. *Journal of Hand Surgery*. 1982;**7A**:549-556
- [38] Allen MJ. Conservative management of fingertip injuries in adults. *The Hand*. 1980;**12**:257-265
- [39] Tsai TM, McCabe SJ, Maki Y. A technique for replantation of the fingertip. *Microsurgery*. 1989;**10**:1-4
- [40] Venkatramani H, Raja Sabapathy S. Fingertip replantation: Technical considerations and outcome analysis of 24 consecutive fingertip replantations. *Indian Journal of Plastic Surgery*. 2011;**44**(2):237-245
- [41] Ahmad SR. Use of regenerative agents in hand surgery. *BMC Proceedings*. 2015;**9** (Suppl. 3):A103
- [42] Urbaniak JR, Evans JP, Bright DS. Microvascular management of ring avulsion injuries. *Journal of Hand Surgery*. 1981;**6A**:25-30
- [43] Opgrande JD, Westphal SA. Fractures of the hand. *The Orthopedic Clinics of North America*. 1983;**14**(4):779-792
- [44] Freeland AE, ME J, Hughes JL. *Stable Fixation of the Hand and Wrist*. New York: Springer-Verlag; 1986
- [45] Chen ZW, Meyer VE, Kleinert HE, et al. Present indications and contraindications for replantation as reflected by long-term functional results. *The Orthopedic Clinics of North America*. 1981;**12**:849-870