

# We are IntechOpen, the world's leading publisher of Open Access books Built by scientists, for scientists

6,900

Open access books available

186,000

International authors and editors

200M

Downloads

Our authors are among the

154

Countries delivered to

TOP 1%

most cited scientists

12.2%

Contributors from top 500 universities



WEB OF SCIENCE™

Selection of our books indexed in the Book Citation Index  
in Web of Science™ Core Collection (BKCI)

Interested in publishing with us?  
Contact [book.department@intechopen.com](mailto:book.department@intechopen.com)

Numbers displayed above are based on latest data collected.  
For more information visit [www.intechopen.com](http://www.intechopen.com)



---

## Three-Dimensional Printing and Navigation in Bone Tumor Resection

---

Lucas E. Ritacco, Candelaria Mosquera,  
Ignacio Albergo, Domingo L. Muscolo,  
German L. Farfalli, Miguel A. Ayerza,  
Luis A. Aponte-Tinao and Axel V. Mancino

Additional information is available at the end of the chapter

<http://dx.doi.org/10.5772/intechopen.79249>

---

### Abstract

One of the most promising advances raised by the current computer age is performing research “in silico,” which means computer-assisted. The objective of this chapter is firstly to evaluate if a 3D in-silico model of an oncological patient could be used to make a 3D-printed prototype in real scale, discriminating precisely healthy tissues, tumoral tissues and oncological margins. Secondly, the objective is to evaluate if this prototype could be representative enough to allow testing osteotomies under navigated guidance based on images. A tumor resection for a patient with diagnosed metaphyseal osteosarcoma of the proximal tibia was transferred into a rapid prototyping model, fabricated using 3D printing and representing different structures in different colors. The planned osteotomy was executed using Stryker Navigator to guide the cutting saw and the prototype was opened to verify the precision of the performed osteotomy. Both osteotomy planes showed successful correspondence with the safe margin, with a maximum error of 1 mm. The application of these techniques in general orthopedics would help to reduce the incidence of unforeseen intraoperative failures, contributing to obtain predictable surgical procedures. This would implement a new way of performing development, research and training in orthopedics and traumatology by in-silico technology.

**Keywords:** bone tumor resection, computer-assisted surgery, image-based navigation, 3D printing, orthopedic oncology

---

## 1. Introduction

One of the challenges of orthopedics and traumatology has been recreating a preoperative planning scenario that contemplates 3D space, without the need to use cadaverous specimens, and being able to reproduce it in the real world. Thanks to the advent of new technologies within the computer age, a new research model was born: “in silico” [1], which means “done by computer or via computer simulation.” In addition to the phrases “in vivo” and “in vitro” of Latin, which are used in systems biology and refer to experiments done in living organisms or outside living organisms, respectively, “in silico” is translated to “in silicium,” which refers to the material from which semiconductors are made, alluding to computer information storage. This creates the concept of turning a virtual computer scenario into a research lab.

One of the possibilities of in-silico research and development consists of performing virtual 3D models that faithfully represent reality. In the field of orthopedics and traumatology, this type of tool opens room for many new developments, such as a virtual 3D model based on images of computer tomography (CT) and magnetic resonance that could simulate the specific anatomical structure of a patient.

In orthopedics surgery, the precision of the cut when performing a particular osteotomy can have a great impact in the final surgical outcome. For example, in bone tumor resection, the osteotomy should leave free margins outside tumoral contamination but at the same time respect as much healthy bone tissue as possible. Therefore, the use of a simulation scenario to determine where and how to execute an osteotomy with the greatest precision possible would mean a clear advantage when planning and performing this type of orthopedic surgery.

In the same way that a global positioning system (GPS) can orientate a person through an unknown path, an intraoperative simulation scenario would be able to guide the path that the cutting saw must follow during a surgical procedure. The surgical planification can be done in a virtual 3D model and then executed under virtual navigation [2–7].

However, virtual navigation based on images contemplates a unique point in space, therefore guiding the tip of the surgeon’s instrumental through the bone surface. For this reason, it is necessary to mark the planned scheme on the patient’s cortical surface and then execute it with a conventional saw under navigated guidance. This makes the level of precision and accuracy questionable, when performing a uniplanar, biplanar or multiplanar osteotomy [5–7].

Many experiments have been conducted to measure the precision associated with an osteotomy, which has been virtually planned and performed under navigation. Wong et al. were one of the first to report that planned tumor resections were facilitated with the use of intraoperative navigation and that this gives clinical benefits [8, 9]. These advantages were also probed in the computer-assisted surgery of the pelvis and sacrum [10, 11]. Postoperative computer tomography (CT) images of the patient can be superimposed to the original preoperative 3D scenario, allowing digital measuring of the distance between the target plane and executed plane [12].

A common approach to measure surgical precision is to use the resected specimen, which contains the tumor, obtained from surgery. Possible methods include the histological evaluation of the specimen, which determines the distance between the cut edge and the tumor by microscopy imaging measurement [12]. However, this does not allow comparison with the planned osteotomy, as it only reports the effective oncological margins. Another method consists of CT scanning the surgical specimen and adding it to the preoperative 3D scenario as another 3D piece [13]. The specimen piece location is manually matched against the original bone structure by an operator, obtaining the best possible image registration. The distance between the target plane and the executed plane can then be measured virtually.

The possibility of measuring the surgical precision obtained after performing an osteotomy is a key factor to allow continuous improvement in the field of orthopedic surgery. This is necessary for evaluating the effect of new instruments and surgical technologies, new surgical techniques, or any development that needs to be tested. Moreover, surgeons could experience a better learning curve for navigation systems if they could study the results they obtain.

In this context, the technological advancement provided by 3D printing represents an interesting possibility. 3D printers have become very popular and it is common to find them in clinical research environments. The concept of rapid prototyping (RP) allows to create very specific models based on computer-assisted designs (CAD). In this way, a virtual scenario can be reconstructed for visualizing the bone, the tumor and the planes of osteotomies and then print those structures, giving the surgeon the possibility to have in his hands a 3D model, in real scale, that faithfully represents the patient's situation. As described below, we can use this prototype model to simulate a surgery. The principles of navigation based on images (combining magnetic resonance images [magnetic resonance imaging MRI] with CT studies) can be applied to the RP model [6–8, 10]. In this way, a correspondence between the real structure of the RP model and its 3D reconstruction is obtained in the navigation computer. Finally, surgeons can carry out the reproduction of a virtual plan in a prototyped bone.

The main objectives of this chapter are to evaluate:

1. if it is possible to create a 3D model in a virtual scenario based on CT scans and MRI, which can simulate the morphology of the bone structure, the tumor and the oncological margins, obtaining a virtual three-dimensional preoperative planning;
2. if it is possible to print a 3D prototype (in this case, a model of proximal tibia) in real scale, which is representative of an oncological patient. This includes contemplating the healthy bone tissue, the tumor tissue and the oncological margins;
3. if it is possible to use this prototype to test osteotomies under navigated guidance based on images.

## 2. Materials and methods

The procedure included three distinctive stages: virtual 3D planning, printing a rapid prototyping (RP) model and image-based navigation.

## 2.1. Virtual 3D planning

The workflow needed to obtain a 3D reconstruction of a patient's anatomical structure can be divided into three phases, which are explained below.

### 2.1.1. Image acquisition phase (computer tomography and magnetic resonance)

Both a conventional magnetic resonance imaging (MRI) study and a multiknee computer tomography (CT) were performed for an 11-year-old patient. The patient's only symptom was recurrent knee pain, and diagnosis of metaphyseal osteosarcoma in the proximal tibia was confirmed by biopsy. The treatment chosen was transepiphyseal tumor resection and reconstruction of the defect with structural allograft bench [14].

Toshiba CT scanner (Aquilion, Japan) was used and the tomographic acquisition protocol was the following: FOV 32 cm; pixel size 0.625 mm; KV 120; 100 mAs; thickness of cut 1 mm; and height and width of image (512 × 512 pxl). Images were digitized in digital imaging and communication in medicine (DICOM) format. Siemens resonator (Avanto, Germany) was used and the digital resonance acquisition protocol was the following: FOV: 32 cm; pixel size 0.75 mm; thickness of cut 1 mm; height and width of image (256 × 256 pxl); in time T1.

### 2.1.2. Image segmentation phase

Once the image files are obtained, the objective is to eliminate elements that look like bone but are not bone. This process, known as image segmentation, is done by establishing a colorimetric assessment. **Figure 1** shows bone tissue represented in yellow, eliminating other elements such as cartilage, muscle, fat, skin or other elements that do not belong to the bone, such as the CT scanner lead. This procedure is performed manually by the operator and determines the final reconstruction of the bone, eliminating structures foreign to the bone tissue that can alter the anatomical form of the bone.

The bone tissue was segmented from CT scan, while the tumor tissue was segmented from MRI. Image fusion was then performed using a mold that overlaps both images in the proper place.

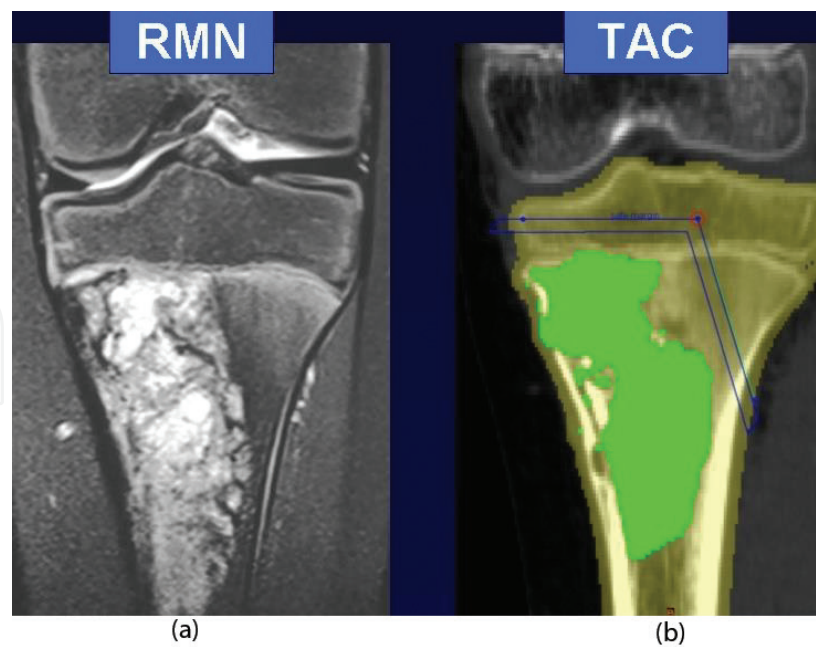
### 2.1.3. 3D reconstruction and planning phase

Once the entire volume of 2D is segmented, this volume is transformed into a 3D bone structure within a virtual scenario. By representing all three axes of space [15], this scenario implies an advance in the way of measurement previously used with CT images and 2D MRI, obtaining a virtual 3D bone that aims to reproduce reality. In this way, the bone morphology and the tumor as a structure can be obtained in a virtual space.

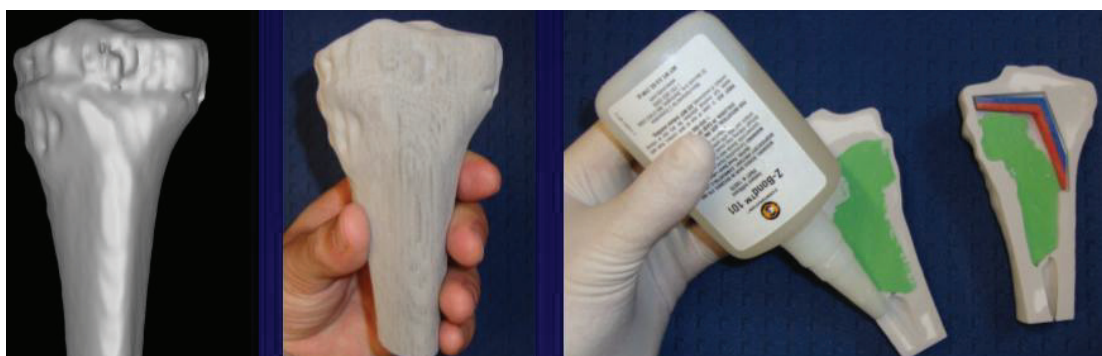## 2.2. Printing the RP model

The rapid prototyping model was created using Z-Printer Spectrum Z-510 printer, in 1 hour and 47 min of printing. It was printed in two halves to include within it four colors that define what the tumor is and where the oncological margins are. Two planes were created near the





**Figure 1.** (a) Magnetic resonance where hyperintense tumor lesion observed in the proximal region of the tibia. (b) Tomography image. The area corresponding to the tumor was painted (segmented) in green, while healthy bone was segmented yellow. This process is repeated in each of the cuts.

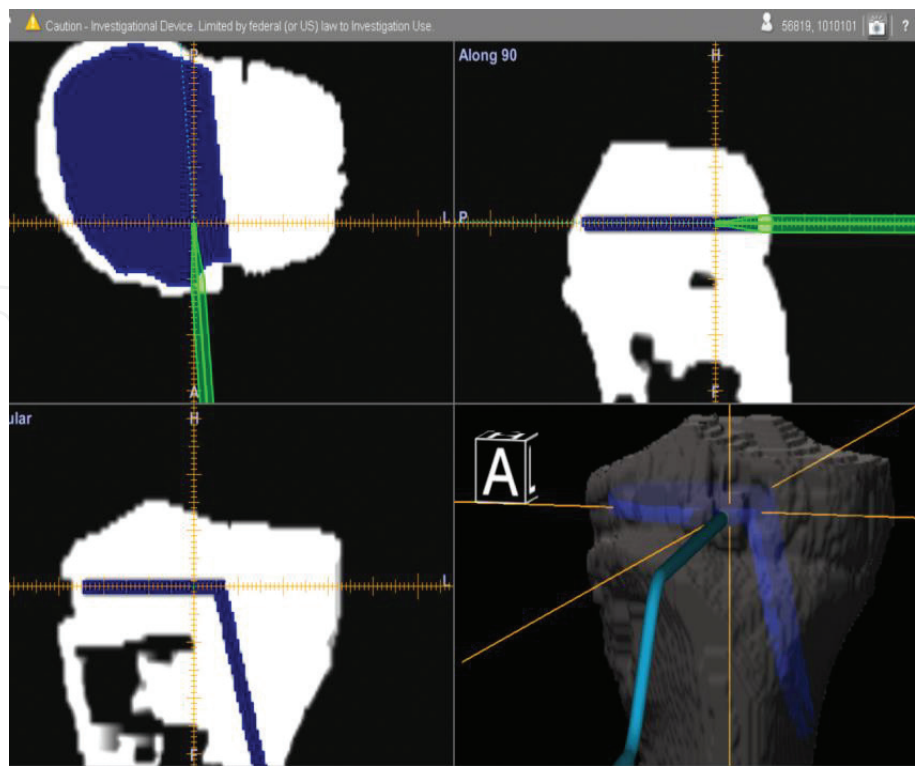


**Figure 2.** Three-dimensional in-silico planning model printed as RP model.

tumor: one in red (unsafe margin of 3 mm) and the other in blue (safe margin of 3 mm). The tumor was colored in green while the rest of the structure corresponding to healthy tissue was printed in white.

The printing technique consists mainly of spilling a film of 0.1 mm of dust ZP131 on the base of more dust (flat) of 2 cm of thickness. Next, a liquid adhesive is printed on that thin film leaving the shape of the first layer of the object under study (proximal tibia), which will correspond to a biplane section of 0.1 mm in thickness. This act is repeated consecutively until the finished piece is obtained. In this work, the tibia was printed in two halves.

Due to the fragility of the newly manufactured piece, the next step consisted of structural fixation with isocyanato, polyol and acetone. Then, both halves were bonded together with Z-Bond 101 glue, as shown in **Figure 2**. The precision of the printed piece was validated by measuring four-known distances in silico and comparing them in the RP model created.



**Figure 3.** Real-time three-dimensional cut map displayed in the browser during cutting. The instrument colored in green corresponds to the blade of the saw. The safe margin is observed in blue.



**Figure 4.** Saw with recorder. The RP model is osteotomized with a saw, which has a recorder attached to guide the direction of the cut in a navigated manner.

**2.3. Image-based navigation**

Once the RP model was prepared, it was fixed to a work table with a vice. The 3D preoperative surgical plan was loaded to Stryker Navigation System II (Figure 3). Then, an infrared surface recorder (tracker) was firmly fixed to the RP model with two pins and a label (Figure 4). This

device generates a 3D coordinate system surrounding a specific area of interest, thus allowing to guide the navigator by matching the 3D preoperative scheme with the RP model.

After this, the model is ready to be osteotomized with navigation tools. The same tracking procedure was carried out on a cutting saw, with a 1.5 mm thick blade. In this case, an appropriate hook was used to fix the crawler to it, allowing one to see the edge of the saw and its trajectory in real time in the screen of the navigation equipment. In this way, the operator visualizes the virtual plane of the previously planned cut from the scenario *in silico* and directs the saw accordingly, contemplating all three spatial axes.

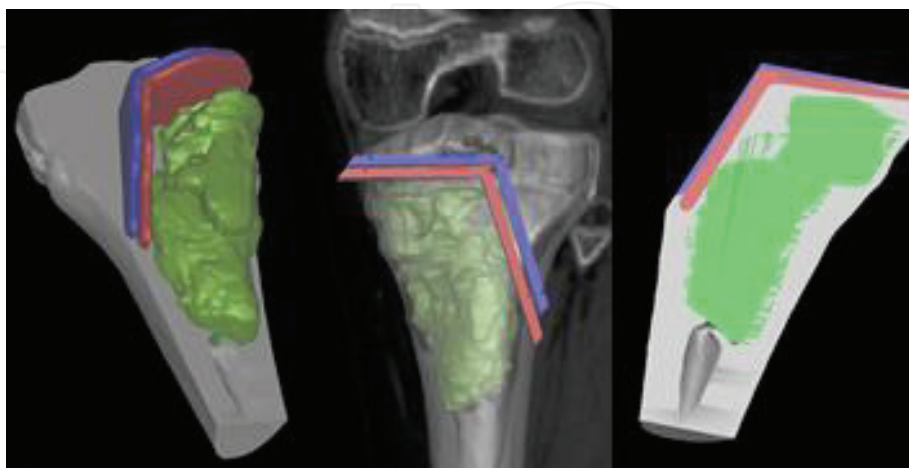
Once the navigated osteotomy was performed, the piece was opened to verify the correspondence of the virtual planning and the RP model.

### 3. Results

#### 3.1. Virtual 3D planning

The segmentation of healthy and tumoral bone tissue was performed. In this way, a 3D piece was built in a virtual scenario, where surgical approaches were evaluated until a final system of osteotomies was chosen. The choice was done contemplating the oncological margins with colors for both distal and proximal osteotomies to the tumor.

The preoperative planning, shown in **Figure 5**, was designed based on this 3D scenario. Two virtual osteotomy planes 3 mm thick were created. This thickness represents the cutting saw and its oscillation. The original coronal plane corresponding to the MRI at T1 was used to determine the distance of the oncological margin. This distance determines the location of the planes. In this way, we can establish a 3D cutting plane that considers the distance between the tumor tissue and the necessary oncological margin.



**Figure 5.** Three-dimensional preoperative planning model “*in silico*.” Healthy bone tissue is represented in gray and tumoral tissue in green. The blue cut plane represents safe oncological margin, and the red cut plane represents unsafe oncological margin.



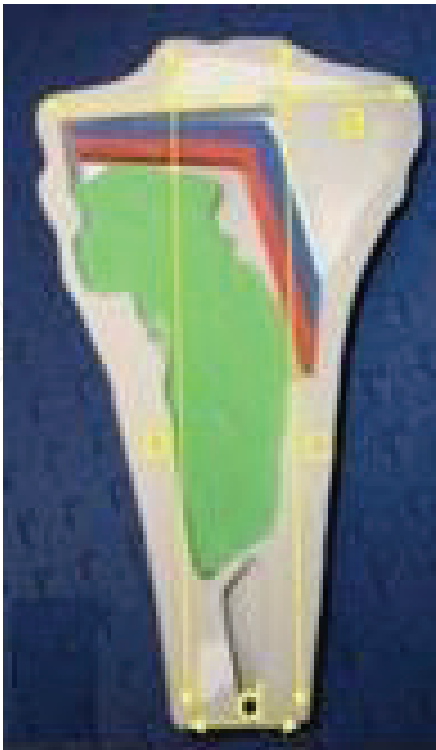

Figure 6. Validation distances.

	Virtual measurement (mm)	Difference between virtual and physical measurement (mm)	Relative error (%)
A	62.8	0.5	0.7962
B	112.2	0.1	0.0891
C	110.8	0.3	0.2708
D	19	0.5	2.6316

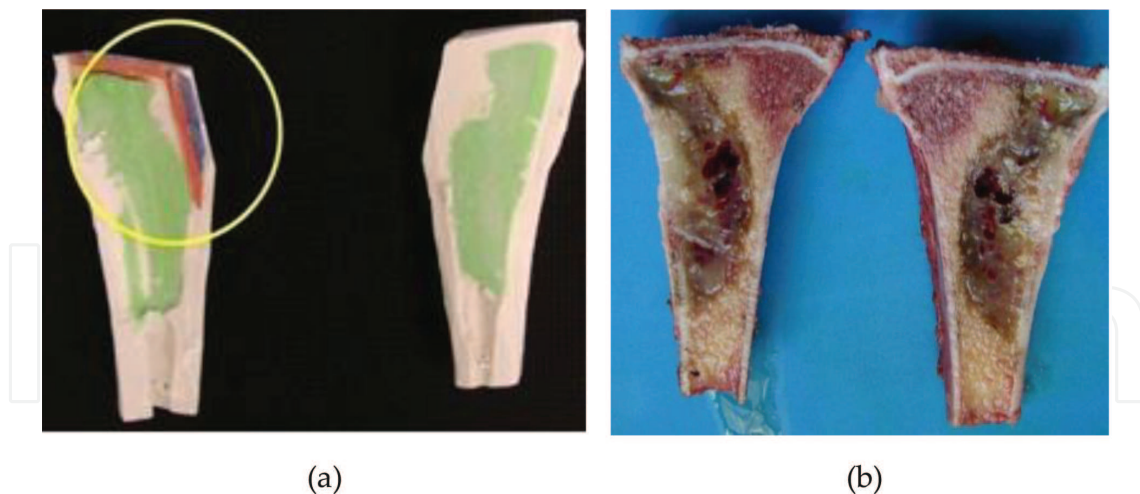
Table 1. Measurement of distances to validate the RP model’s precision.

3.2. Printing the RP model

By printing the bone in two halves, we were able to create a solid structure that corresponded in size and shape to what was observed in our virtual scenario.

The validation of said procedure was carried out by comparing the measurement of four known distances in silico to their measurement in the RP model (Figure 6). These differences are stated in Table 1.

The average relative error, considering the virtual measurement as true measurement, is of 0.9469%. The level of error is considered tolerable for this application; therefore, it can be concluded that the prototyping method shows good reproduction of patient’s structure in real scale.



**Figure 7.** (a) Osteotomized RP model. (b) Pathological anatomy of tibial osteosarcoma. The similarity between the pathological anatomy and our RP model in colors can be noted, as well as the accuracy of the cut coinciding with the blue osteotomy plane, which corresponds to the safe margin.

### 3.3. Image-based navigation

The surgeons were able to reproduce the preoperative plan on the RP model by using a conventional saw under intraoperative navigation guidance. The procedure was validated by opening the piece and confirming its correlation with the previous biplanar osteotomy planned in silico. This is represented as the distance between each cut edge of the piece and its corresponding oncological margin planes.

The distal plane showed correspondence with the safe margin limit of the planned plane, not reaching the red plane (unsafe margin) at any point. The proximal plane obtained was parallel to the planned plane but showed a translation of 1 mm toward the healthy tissue side. In both cases the unsafe margin, colored in red, maintained all its integrity.

In **Figure 7(a)**, we can see both halves of the RP model after osteotomies were performed, identifying clearly where the margin was greater than planned for the proximal plane and how the distal plane was correctly executed. In **Figure 7(b)**, we can see the real specimen of proximal tibia presenting osteosarcoma, for comparison.

## 4. Discussion

Although the combination of preoperative planning with image-based navigation has already been used in other areas such as maxillofacial surgery [16], spine surgery [17] and cardiac surgery [18], among others, no work could be found in which RP models were cut with saw as part of the training for surgical navigation. As a matter of fact, one technical question that was present before doing this work was whether the RP model could withstand the oscillation of an orthopedic saw without being destroyed. In this experience of only two cases, we probed that the behavior of the material maintained its structure until the end of the experiment.

By taking advantage of the retrospective RP model created, one important challenge was improving the amount of healthy bone preserved compared to that of conventionally performed resections. This means reducing the healthy bone in the resected specimen and leaving a greater volume of healthy bone in the patient, while always maintaining a safe oncological margin. This objective was fulfilled thanks to the 3D control in 3D planning and the 3D control provided by the navigator during the execution of the cut, as it can be observed in the RP model with colors.

Surgical precision, understood as the correspondence between a target osteotomy and an executed osteotomy, is not the only factor to consider when evaluating navigation-assisted surgery. Some complications associated with intraoperative navigation, such as increased procedure time or uncompleted navigation due to technical problems, have shown to decrease as the surgeon team familiarizes with the technology (increasing their total amount of surgeries performed under navigation) [19]. On the contrary, the accuracy level in the registration process appears to be independent of the learning curve and not decreasing with user experience. Local tumor recurrence and non-oncological complications have also been used as parameters to evaluate the benefits of navigation-assisted surgery [20].

The experiment designed for this chapter shows how 3D printing can be applied to build experimental models, specifically for orthopedical oncology, that can be used for multiple applications. In the first place, these models are useful to test and characterize new surgical technologies such as image-based navigation. In the second place, these models can be used by the surgeons for training on particular procedures.

The potential of 3D printed models as surgical training tools for patient-specific procedures has been evidenced for ENT surgery. In a case report where transtemporal tumor drainage assisted with intraoperative navigation was determined as treatment, the preoperatively planned trajectory to access the tumor was executed under navigation first on a 3D model of the patient's skull and then on the real patient. The mean distance between target trajectory and executed trajectory measured in the 3D model was reduced by 73.66% when measured in the real patient. This probes how 3D printed models are a promising method to increase accuracy in surgeries assisted with navigation [21].

3D-printed prototypes are currently gaining accessibility, as 3D printers become more massive and more economical. This manufacturing method is improving both its technical characteristics (such as the speed of printing, resolution and the variety of materials available) and its cost. Therefore, it is reasonable to believe this method can be easily available in clinical practice, turning it into a promising option for the testing of new surgical technologies and procedures.

This work was the first validation experiment of the workflow proposed, which consists of preoperative planning and image-based navigation for orthopedic precision surgery. Subsequent validation and protocolization works have followed this experiment, finally building a routine that is implemented on a weekly basis at the department of computer-assisted surgery at our hospital (Unidad de Cirugía Asistida por Computadora, Hospital Italiano de Buenos Aires) [22].

## 5. Conclusion

The ability to combine different emerging technologies gives important solutions in the field of surgery planning and preoperative surgical design. The 3D prototype as a way of reproducing a surgery is a training model for surgeons interested in knowing the behavior of 3D planning and its reproduction through the navigation of osteotomies in orthopedic oncology. It is possible, in this way, to test surgeries from RP models manufactured from real cases. This method stands out as it is easy to implement and to understand, as well as technically simple and economical.

Likewise, other benefits of this conglomerate of technologies include multiplanar or difficult osteotomies in limb deformities, pre-cast in osteosynthesis plates using the RP models as a guide mold, controlling oncological margins to avoid errors of cut in real surgery and, above all, save surgical time with its cascade of beneficial effects for the surgeon and the patient.

In our hospital department, we were able to adopt computer-assisted surgery for oncologic orthopedics as a standard routine. This includes weekly meetings of specialized medical professionals who perform the preoperative planning for challenging surgical cases, which are then executed intraoperatively under navigation guidance. More than 250 patients have been treated to date following this working protocol, since its introduction 8 years ago. This is an example of how new technologies developed in silico can rapidly reach health care activities.

## Conflict of interest

Lucas Ritacco has a consultancy with Stryker Corporation.

All other authors of this chapter certify that they have no affiliations with or involvement in any organization or entity with any financial interest in the subject matter or materials discussed in this manuscript.

## Author details

Lucas E. Ritacco<sup>1\*</sup>, Candelaria Mosquera<sup>1</sup>, Ignacio Albergo<sup>2</sup>, Domingo L. Muscolo<sup>2</sup>, German L. Farfalli<sup>2</sup>, Miguel A. Ayerza<sup>2</sup>, Luis A. Aponte-Tinao<sup>2</sup> and Axel V. Mancino<sup>1</sup>

\*Address all correspondence to: [lucas.ritacco@hiba.org.ar](mailto:lucas.ritacco@hiba.org.ar)

1 Virtual Planning and Navigation Unit, Department of Health Informatics, Hospital Italiano de Buenos Aires, Argentina

2 Carlos E. Ottolenghi Institute of Orthopedics, Italian Hospital of Buenos Aires, Buenos Aires, Argentina

## References

- [1] van de Waterbeemd H, Gifford E. ADMET in silico modelling: Towards prediction paradise? *Nature Reviews. Drug Discovery*. 2003;**2**(3):192-204
- [2] Cho HS et al. Joint-preserving limb salvage surgery under navigation guidance. *Journal of Surgical Oncology*. 2009;**100**(3):227-232
- [3] DiGioia AM 3rd, Jaramaz B, Colgan BD. Computer assisted orthopaedic surgery. Image guided and robotic assistive technologies. *Clinical Orthopaedics and Related Research*. 1998;**354**:8-16
- [4] Rajasekaran S et al. Computer navigation-guided excision of cervical osteoblastoma. *European Spine Journal*. 2010;**19**(6):1046-1047
- [5] Simon DA, Lavalley S. Medical imaging and registration in computer assisted surgery. *Clinical Orthopaedics and Related Research*. 1998;**(354)**:17-27
- [6] So TY, Lam YL, Mak KL. Computer-assisted navigation in bone tumor surgery: Seamless workflow model and evolution of technique. *Clinical Orthopaedics and Related Research*. 2010;**468**(11):2985-2991
- [7] Wong KC et al. Precision tumour resection and reconstruction using image-guided computer navigation. *Journal of Bone and Joint Surgery. British Volume (London)*. 2007;**89**(7):943-947
- [8] Wong KC, Kumta SM, Antonio GE, Tse LF. Image fusion for computer-assisted bone tumor. *Clinical Orthopaedics and Related Research*. 2008;**466**(10):2533-2541
- [9] Wong K, Kumta S, Tse L, Ng E, Lee K. Image fusion for computer-assisted tumor surgery (CATS). *Image Fusion*. London, UK: InTechOpen; 2011. pp. 373-390
- [10] Cho HS, Kang HG, Kim HS, Han I. Computer-assisted sacral tumor resection. A case report. *The Journal of Bone and Joint Surgery. American Volume*. 2008;**90**(7):1561-1566
- [11] Krettek CJG. Computer aided tumor resection in the pelvis. *Injury*. 2004;**35**(suppl 1): S-A79-S-A83
- [12] Gouin F, Paul L, Odri GA, Cartiaux O. Computer-assisted planning and patient-specific instruments for bone tumor resection within the pelvis: A series of 11 patients. *Sarcoma*. 2014
- [13] Ritacco LE, Milano FE, Farfalli GL, Ayerza MA. Accuracy of 3-D planning and navigation in bone tumor resection. *Orthopedics*. 2013;**36**(7):942-950
- [14] Muscolo DL et al. Proximal tibia osteoarticular allografts in tumor limb salvage surgery. *Clinical Orthopaedics and Related Research*. 2010;**468**(5):1396-1404
- [15] Roos PJ et al. A new tibial coordinate system improves the precision of anterior-posterior knee laxity measurements: A cadaveric study using roentgen stereophotogrammetric analysis. *Journal of Orthopaedic Research*. 2005;**23**(2):327-333



- [16] Robiony M et al. Accuracy of virtual reality and stereolithographic models in maxillo-facial surgical planning. *The Journal of Craniofacial Surgery*. 2008;**19**(2):482-489
- [17] Lu S et al. A novel computer-assisted drill guide template for lumbar pedicle screw placement: A cadaveric and clinical study. *The International Journal of Medical Robotics*. 2009;**5**(2):184-191
- [18] Sodian R et al. Pediatric cardiac transplantation: Three-dimensional printing of anatomic models for surgical planning of heart transplantation in patients with univentricular heart. *The Journal of Thoracic and Cardiovascular Surgery*. 2008;**136**(4):1098-1099
- [19] Farfalli GL, Albergo JI, Ritacco LE, Ayerza MA, Milano FE, Aponte-Tinao LA. What is the expected learning curve in computer-assisted navigation for bone tumor resection? *Clinical Orthopaedics and Related Research*. 2017;**475**(3):668-675
- [20] Farfalli GL, Albergo JI, Piuze NS, Ayerza MA, Muscolo DL, Ritacco LE, Aponte-Tinao LA. Is navigation-guided en bloc resection advantageous compared with Intralesional curettage for locally aggressive bone Tumors? *Clinical Orthopaedics and Related Research*. 2018;**476**(3):511-517
- [21] Ritacco Lucas E, Di Lella Federico, Mancino Axel, Gonzalez Bernaldo de Quiros Fernando, Boccio Carlos, Milano Federico E. 3D printed models and navigation for Skull Base surgery: Case report and virtual validation. *Studies in Health Technology and Informatics*. 2015;**216**:1025
- [22] Ritacco LE, Milano FE, Chao E. *Computer-Assisted Musculoskeletal Surgery: Thinking and Executing in 3D*. Switzerland: Springer International Publishing; 2016

