

# We are IntechOpen, the world's leading publisher of Open Access books Built by scientists, for scientists

6,900

Open access books available

186,000

International authors and editors

200M

Downloads

Our authors are among the

154

Countries delivered to

TOP 1%

most cited scientists

12.2%

Contributors from top 500 universities



WEB OF SCIENCE™

Selection of our books indexed in the Book Citation Index  
in Web of Science™ Core Collection (BKCI)

Interested in publishing with us?  
Contact [book.department@intechopen.com](mailto:book.department@intechopen.com)

Numbers displayed above are based on latest data collected.  
For more information visit [www.intechopen.com](http://www.intechopen.com)



---

# Spine Endoscopy

---

Állynson Larocca Kulcheski, Xavier Soler I Graells and  
André Luís Sebben

Additional information is available at the end of the chapter

<http://dx.doi.org/10.5772/intechopen.79298>

---

## Abstract

The evolution of medicine has led to the appearance of increasingly invasive surgeries. Inside the spine area was no different. Currently, there are minimally invasive procedures in the spine, and endoscopic spine surgery has been the peak of these procedures. This procedure was initially described for the treatment of lumbar disc herniations, but with the technical improvement, the materials used are already being made for other pathologies such as lumbar stenosis, thoracic disc hernias, spinal infections, posterior cervical decompression, and cervical herniations. It has a long learning curve, but the benefits of endoscopic surgery are remarkable, such as less postoperative pain, less bleeding, smaller scars, lower infection rate, less injury to the operated tissues, and a return to earlier work activities, among others. In this way, we must follow the evolution of medicine with the learning of these new techniques.

**Keywords:** spine, intervertebral disc displacement, endoscopy, pain, spinal diseases

---

## 1. Introduction

Medicine is always under constant development. All the medical specialties have their progress with new techniques. In spine surgery, it is not different. Degenerative diseases of the spine form part of daily medical practice and their treatment is complicated by medical and socioeconomic problems. Where severe pain or neurologic deficits persist and all conservative treatment options have been exhausted, surgery may be required. Traditional operations of the spine can achieve good results at the expense of great tissue damage, which causes lesions in the coordination and stabilization of the spine. This type of damage occurs even with the use of microsurgery, causing, therefore, the occurrence of cicatricial fibrosis in the epidural space, which influences the postoperative pain syndrome.

---

One of the most revolutionary progresses in the spine surgery was the recent development of the spine endoscopy for the treatment of various pathologies. Although the field of endoscopic spine surgery is still young and is rapidly evolving, with precise indication, proper diagnosis, and good training, the endoscopic spine surgery can give equally good result as open spine surgeries.

The goal of the endoscopic surgery is to get the same results obtained using standard surgeries, providing effective treatments and not only focused on temporary pain relief, such as in nerve root blocks, but also at the same time avoiding discomfort related with open techniques.

## **2. History of the spine endoscopy**

Minimally invasive spine surgery treatment started with chemonucleolysis in 1963. Lyman Smith described this technique injecting chymopapain intradiscally [1]. After this first step, in 1973, Kambin described an endoscopic posterolateral approach to access the disc space. This was the primordium of the development of the spine endoscopy. In this technique, an inside-out decompression of the disc space was done but without the view of an endoscope. Fifteen years later, in 1988, the same author achieved the first endoscopic views of a herniated nucleus pulposus [2]. After that, the specific instruments have been developed with working-channel rigid endoscopes, high-definition cameras, drills, trephines, and articulated graspers. Kambin, in 1990, after extensive studies on a cadaver, described a triangular safe zone bordered by the exiting root anteriorly, the traversing root medially, and the superior end plate of the lower lumbar vertebra inferiorly [2]. The anatomical description of this safe zone allowed the field of endoscopic spine surgery to outgrow the technique of percutaneous nucleotomy, which was limited by the use of small needle-like instruments. Kambin's triangle was a working corridor that allowed larger instruments and working channels to be introduced in even closer proximity to foraminal pathology without injuring the exiting nerve. Along the years, multi-channel endoscopes with larger working channels were introduced by Tsou et al. in 1997 and Ruetten et al. in 2007 [3, 4]. In 1997, Anthony Yeung had designed Yeung Endoscopic Spine System (YESS) endoscope with multichannel fluid integrated working channel rigid endoscope. After that, the modern era of endoscopic disc surgery began. Yeung's technique was based on principle of identification and treatment of pain generators into the foramen and the disc, by freeing exiting and traversing roots, by fragmentectomy, visualization, and clearance of annular tear by ablation and irrigation. This was the Inside-out technique [5, 6]. Choi et al. contributed to the modification of endoscopic technique by access to the far lateral disc herniation, transiliac and interlaminar approach for difficult L5-S1 level disc herniations, approach for up-migrated and down-migrated disc herniations, transpedicular approach for high-grade down-migrated disc herniation, and endoscopic treatment for lumbar spinal canal stenosis [7].

## **3. Why microendoscopic surgery?**

The conventional spine open procedures have their own limitations. They can produce more complications and morbidity to the patients. This has, for many years, led to distrust of patients regarding the acceptance of performing a procedure in the spine.

The minimally invasive surgery, as well as the trend in medicine, has been developing a lot in recent years, whether in anatomical knowledge or in the development of techniques and materials, and this has led to the development of less aggressive surgeries.

Endoscopic spine surgery aims to reduce tissue trauma, prevent iatrogenic problems, and preserve spinal motion and stability. The main benefits are [8–10]:

- smaller incisions and less tissue trauma
- avoid detachment of tendons to the posterior bony elements, especially the multifidus attachments to the spinous process and superior articular processes
- maintain the integrity of the dorsolumbar fascia
- causing lesser soft tissue injury, is less likely to progress to failed back surgery syndrome
- minimal blood loss
- improved illumination and visibility
- earlier return to activities and work
- easier operative approach in obese patients
- easier revision surgery because of less scar tissue in the access portal
- lower complication rates
- lower morbidity in elderly, obese, diabetic, cardiac patients, and smokers
- local or regional anesthesia combined with conscious sedation can be used
- in most cases, less postoperative pain medication is required
- as a consequence, outpatient procedures are possible
- lower costs due to shorter operating times and shorter inpatient stay

#### **4. Indications of the spine endoscopy**

Initially, endoscopic technique was restricted to the lumbar spine. With the popularization of the lumbar surgery, gradually, surgeons started to perform cervical and thoracic disc herniation procedures. Today, expert surgeons can also use the endoscopy for spinal canal stenosis and endoscopic assisted fusion surgeries.

The main indications for spine endoscopy are as follows [11]:

- Endoscopic spine surgery can play an important role in the treatment of adolescent disc herniations, especially for the persons who engage in competitive sports and the athletes where less tissue trauma, cosmesis, and early functional recovery is desirable
- Lumbar, thoracic, and cervical disc herniations with radicular symptoms

- Lateral spinal canal (recess) and foraminal stenosis with radicular symptoms
- Degenerative facet joint cysts with radicular symptoms
- In experienced hands also central spinal canal stenosis with claudication or radicular symptoms
- Some cases of spondylodiscitis (biportal access)

## 5. Contraindications for spine endoscopy

Although the endoscopic surgical technique is a growing field of study and is valid for many cases, care must be taken not to indicate it indiscriminately. We must follow rigorous criteria of selection of pathologies, as well as patients, in order to be successful with the results. In this way, the future of this access route will be promising. With this in mind, we must always respect the following contraindications of the technique, which are [11]:

- Cauda equina syndrome
- Clinically relevant instabilities, deformities, or back pain that is not due to neural compression are contraindications for endoscopic spine surgery (e.g., spondylolisthesis).
- Very large disc herniations (occupying greater than 50% of the spinal canal) with or without a fresh motor deficit may be contraindications for less experienced endoscopic surgeons
- Calcified herniations
- Nerve root anomalies such as conjugate root

## 6. Surgical planning

In order to perform the endoscopic surgery in the spine, we must perform, as in any other surgical procedure, rigorous planning. Most cases treated by endoscopic surgery are for the treatment of lumbar disc herniations. In these cases, several parameters such as the height of the patient's iliac crest, the size of the interlaminar window, the location of the herniated disc at the column level, or its positioning—as foraminal or extraforaminal, central or centrolateral—must be evaluated.

In general, foraminal and extraforaminal herniations tend to be treated by the transforaminal or extreme lateral pathway. The central or centrolateral hernias are preferably treated by the interlaminar technique.

At the L5-S1 level, there is a tendency to perform the procedure via the interlaminar pathway, considering that the iliac crest acts as a mechanical barrier for access by the transforaminal pathway. The size of the interlaminar window, which is generally larger at the L5-S1 level, should always be evaluated by radiographs to evaluate the possibility of the interlaminar pathway.

For higher lumbar levels, mainly from L4 to cranial, a coronal evaluation, preferably with magnetic resonance, is mandatory to visualize the positioning of organs in the retroperitoneal space, such as the kidneys, and thus verify if the transforaminal technique is plausible from the point of anatomical view, without causing damages to the organs in the way of access [4, 7, 9].

## **7. Imaging exams**

### **7.1. Radiography**

The radiography of the spine, be it lumbar, thoracic, or cervical, is mandatory for performing the planning of the endoscopic procedure. It must be requested in the incidence front, profile, and dynamic incidence in maximum flexion and extension. Thus, important parameters for surgical planning can be evaluated as: presence of instabilities (which would contraindicate the endoscopic procedure), height of the disc space, and intervertebral foramen (The diameter of the intervertebral foramen decreases in a cranial to caudal direction and additional narrowing may result from degenerative changes), size of the interlaminar window, and deviations of the spine axis (kyphosis, scoliosis, loss of the sagittal balance).

### **7.2. Computed tomography**

Computed tomography of the spine is not the exam of choice for the diagnosis of neural compressions; however, it becomes useful for the diagnosis of calcified disc hernias, which are also contraindication to the endoscopic procedure. This exam helps for planning surgeries in the thoracic spine and in the highest lumbar levels, in in which the study of the thoracoabdominal organs is required.

### **7.3. Magnetic resonance**

Magnetic resonance of the spine is the gold standard examination for the spine. It identifies specifically where and which is the neural compression. This is the best exam for the diagnosis and the best exam for planning the access route for the procedure [11].

## **8. Anesthesia**

### **8.1. Transforaminal and extreme lateral**

For the transforaminal and extreme lateral pathways, a mild sedation and local anesthesia are recommended so that the patient is awake and responsive throughout the procedure. The patient can then provide real-time feedback in case of nerve irritation from instrument pressure or retraction, adding a layer of safety and allowing the surgeon to adjust the instruments accordingly. We use midazolam, fentanyl, and dexmedetomidina for sedation and recommend against using general anesthetics like propofol, which can produce temporary total analgesia,

eliminating the patient's responsiveness to any nerve stimuli. The skin, needle tract, and annulus are anesthetized with lidocaine. This allows anesthesia without motor block of the nerve roots.

## 8.2. Interlaminar

For the interlaminar procedure, general anesthesia is used. As the surgeon needs to manipulate the neural tissues, the patient would feel pain, and it would be difficult to perform the procedure with safety.

General anesthesia is used for other endoscopic procedures such as spinal stenosis, cervical, and thoracic spine [11].

## 9. Techniques

The most common techniques for performing the lumbar microendoscopic discectomy are the transforaminal, the extreme lateral technique, and the interlaminar approaches.

There are others less common techniques, which are the thoracic transforaminal and the cervical decompression [12].

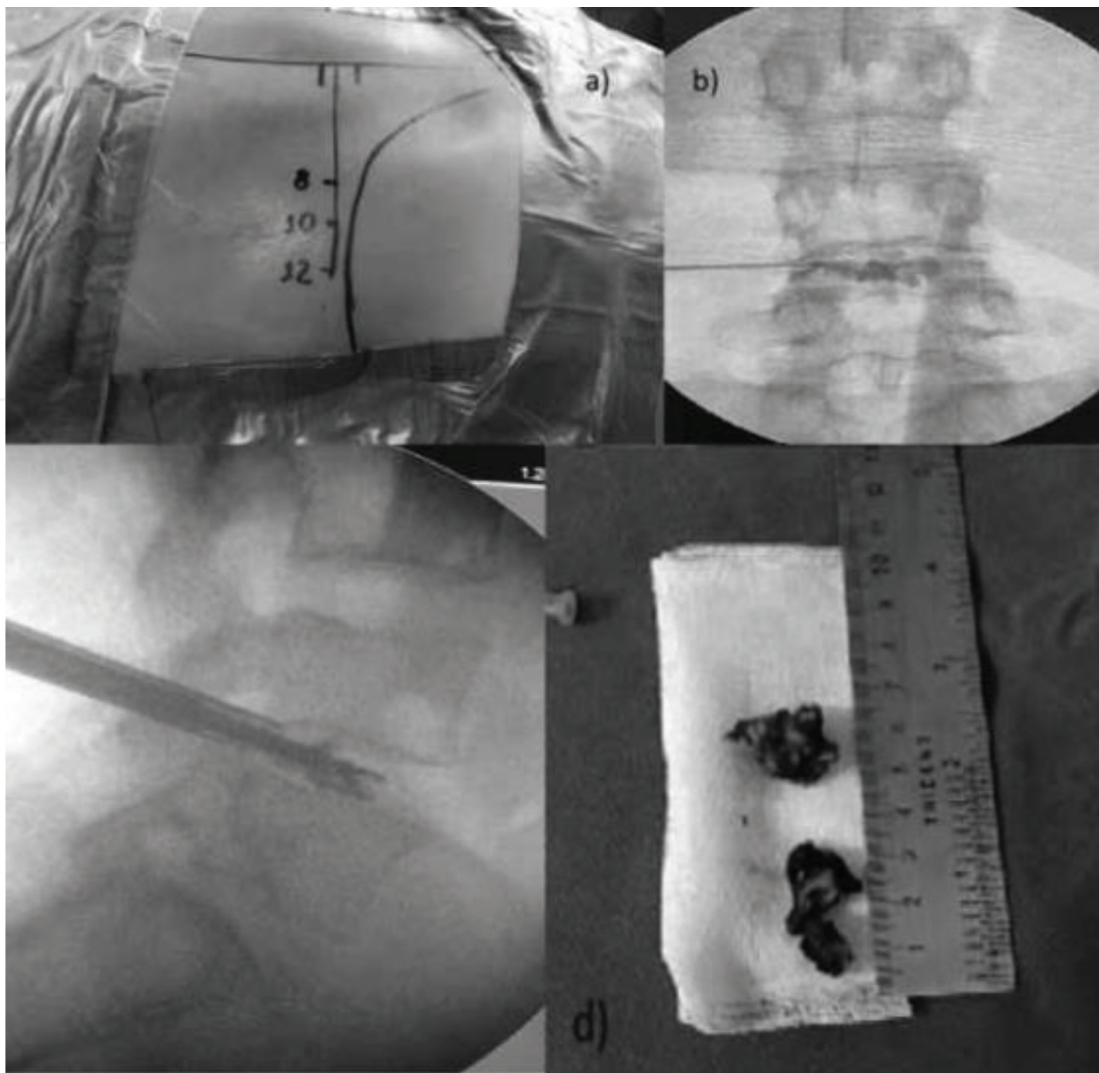
### 9.1. Transforaminal

In the transforaminal technique, the patient is positioned in the ventral decubitus position, prone on a radiolucent table with a pelvic and a thoracic roll. Use of a C-arm is required during the operation. The midline, the inferior, and superior vertebral plates of the desired level are marked, under visualization of the image intensifier, and lateral markings to the midline of 8, 10, and 12 cm which will be the possible entry points. The patient is submitted to a light sedation, and at the point of entry an infiltration with local anesthetic without vasoconstrictor is performed. The sedation should be light, since the patient must be aware so that he can be alert if some nerve root is stimulated during the procedure. After this step, the intervertebral disc is punctured and a discography with methylene blue or indigo carmine, associated with non-ionic contrast, is done. Through the guides, the endoscope is inserted into the intervertebral disc and an indirect decompression of the intervertebral disc is performed (inside-out technique), followed by a thermal nucleoplasty. Reduction of intradiscal volume and pressure can reduce disc-related compression. The entire procedure is performed through the intervertebral foramen between the exiting and traversing nerve roots (Kambin's safety triangle) without need for resection of bony or ligamentous structures [6, 12–15] (**Figure 1**).

In some cases of spondylodiscitis, the possibility of the treatment with a biportal transforaminal technique can be considered. With a biportal, it is possible to achieve decompression, debridement, and biopsy samples for the microbiological diagnosis.

### 9.2. Extreme lateral

The extreme lateral technique was a modification of the transforaminal technique. It was developed by the German Sebastian Ruetten. First, the location of the incision on the skin is marked.



**Figure 1.** Transforaminal percutaneous endoscopic discectomy. (a) Markings on the skin. (b) Discography in the anterior-posterior view of radioscopy. (c) Imaging in a radioscopy profile with demonstration of the “inside-out” technique of discectomy. (d) Disc material removed.

This depends on the patient's anatomy and the location of the hernia. The smaller the foramen, the more lateral the entrance. The goal is to make the tangential reach to the spinal canal possible. For L3-L4 and L4-L5 levels, the dorsal border of the lower articular process seen in radioscopy is the ventral border of the entry point. At higher levels, such as L1-L2 and L2-L3, due to increased intervertebral foramen, the entry may be less lateral. At these high lumbar and thoracic levels, an axial tomography scan should be performed to evaluate the position of the abdominal and thoracic organs. An initial needle is introduced with an acute angle with the spine, practically parallel to the skin. In profile radioscopy, the needle should remain in the posterior region of the fibrous annulus and in the anteroposterior image remain in the medial pedicular line. Thereafter, a guidewire and, subsequently, a dilator are inserted. Afterwards, the cannula is inserted over the dilator, with the ventral opening, the bevel is rotated 90 degrees, and it remains with the bevel open to the region of the vertebral canal, protecting the emerging root. From this moment, surgical decompression is performed. This is an outside-inside procedure. As in the transforaminal technique, in the extreme lateral, it is not necessary to perform a flavectomy [16].

### 9.3. Interlaminar

Another technique is the interlaminar endoscopic discectomy. It is preferably used for the lower lumbar levels (L4-L5 and L5-S1) because of the size of the interlaminar window. The patient is positioned in the ventral decubitus position, on a radiolucent table, under general anesthesia. In this technique, general anesthesia is necessary because it is vital to move away from the neural root, which causes discomfort to the patient. The interlaminar window at the desired level is marked on the skin under the aid of the image intensifier and a 1-cm longitudinal access is made near the midline. An initial dilator is positioned in the interlaminar space and the endoscope is inserted. First, the multifidus musculature is dissected to the yellow ligament, which is opened for exposure of the descending root and the perineural fat. The opening of the yellow ligament is a fundamental step during endoscopic surgery by the interlaminar approach, in order to access the nerve structures and the intervertebral disc. This yellowish-colored structure measures 2–6 mm thick and is a protective barrier for the teal sac and nerve structures. The nerve root is removed and protected with a beveled cannula. The intervertebral disc is perforated and decompressed. At the end of the procedure, a thermal nucleoplasty is performed (**Figure 2**). The surgeon needs full anatomical knowledge of structures that are not directly visualized, such as laminae, ligaments, and nerve structures. A complete notion of three dimensionality is required in this type of surgical approach [17–19].

### 9.4. Lumbar stenosis

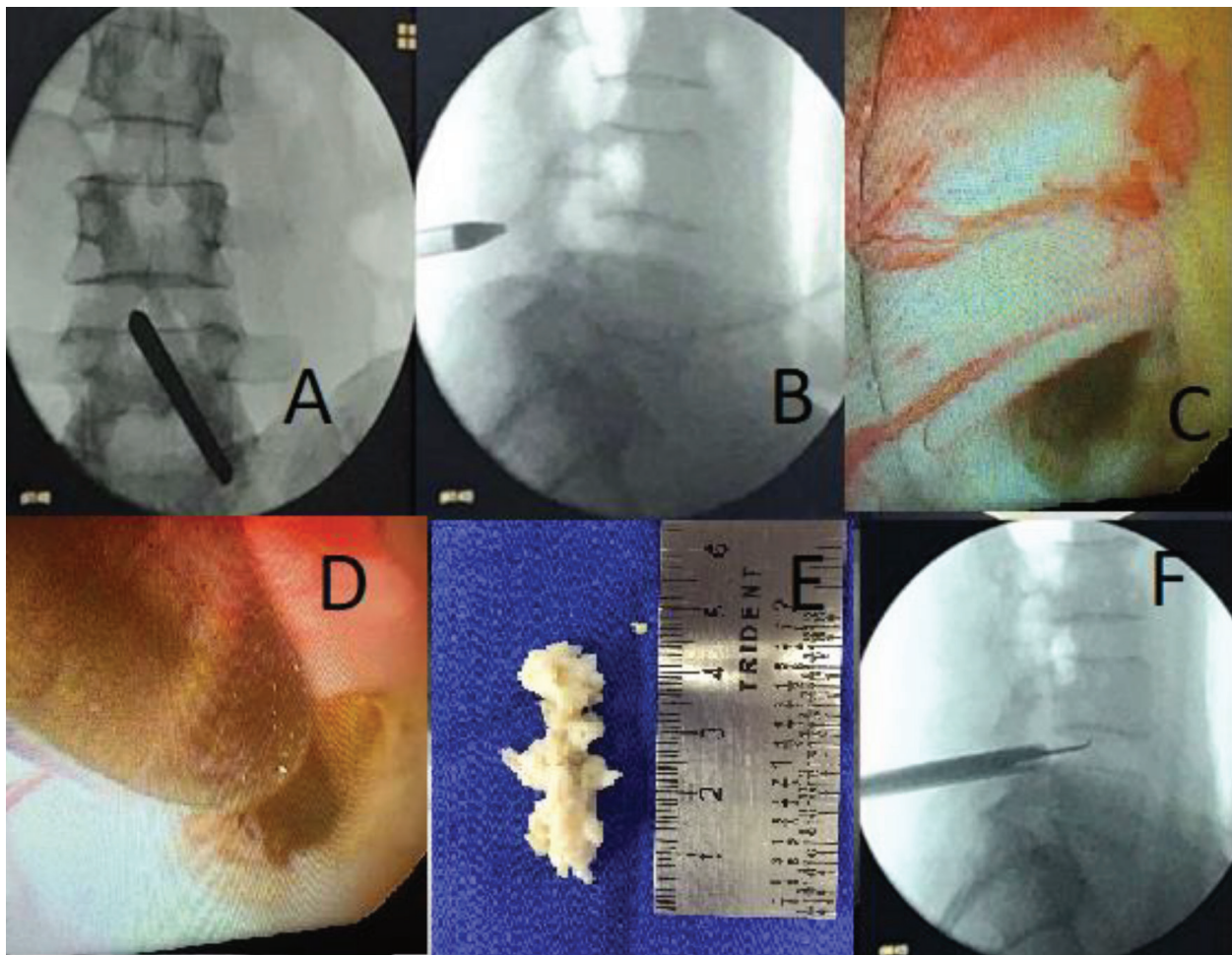
Patients with lateral recess stenosis may benefit from the endoscopic procedure. In these cases, through interlaminar access, with burrs and rougeurs, decompression of the lateral recess can be performed.

After the access has been obtained, the bony structures are dissected. It may be useful to start decompression at the caudal end of the descending facet. The medial parts of the descending or ascending facet or of the caudal and cranial lamina can also be resected if needed [20].

### 9.5. Cervical

The main indications for cervical spine endoscopy are the presence of lateral disc herniations and stenosis with exclusively lateral localization. These are the same indications for posterior foraminotomy.

The operation is performed with the patient lying prone. The cervical spine is delordosated and the head fixed in place with tape. The arms are positioned toward caudal on the body with gentle tension. The line of spinal joints is marked under posterior–anterior X-ray control (about 2-cm lateral from the midline). From this point on, the operation is performed under lateral X-ray control. The procedure comprises determination of the segment, performance of skin incision, and blunt insertion of a dilator onto the facet joint. Insertion of the operation sheath via the dilator beveled opening is made. The dilator is removed. After insertion of the optic, further operation is performed under visual control and continuous irrigation with 0.9% saline solution. The facet joint and the flavum ligament are prepared: start of the



**Figure 2.** Interlaminar percutaneous endoscopic discectomy. (a) Point of entry into the anteroposterior view of the radioscopy. (b) Multifidus muscle limits in radioscopy profile. (c) Neural root visualized. (d) Probe removing the root after performing the discectomy. (e) Disc material. (f) Probe inside the disc space.

foraminotomy by bone resection at the medial joint segments, resection of the lateral flavum ligament, and identification of the lateral edge of the spinal cord and branching of the spinal nerves. Bipolar radiofrequency coagulation of the venous plexus and dissection spinal nerves. If there is a disc herniation, the nerves should be immobilized and the herniated disc material should be resected. Depending on the pathology in each case, the foraminotomy can be extended toward lateral or craniocaudal. After all instruments are removed, direct closure of the skin is performed [12].

## 10. Selection of the technique

In general, patients with central and centrolateral disc herniations should be submitted to the interlaminar technique. On the other hand, those who have foraminal and extraforaminal herniation should be submitted to the transforaminal technique. This technique is preferable in the lumbar spine in the levels of L3-L4 and L4-L5. The transforaminal approach is


possible in higher levels, but it is mandatory in the study of the position of the thoracoabdominal organs. Depending on anatomical landmarks, for example, the height of the iliac crest makes the transforaminal technique in the L5-S1 level not possible. In this case, you should consider using the interlaminar technique or the traditional open discectomy. For sequestered and/or migrated disc herniations, it is possible to use the extreme lateral technique in which you have an increased mobility of the endoscope in searching the herniation [17, 19, 21].

## 11. Surgical equipment for spine endoscopy

The material used for the endoscopic procedures of the spine is highly technological and specialized equipment. (**Figures 3–5**). In general, the equipment consists of an endoscopy tower that is composed of a high-resolution monitor, irrigation pump system, shaver system, radiofrequency system, and lighting system connected to fiber optic cables.



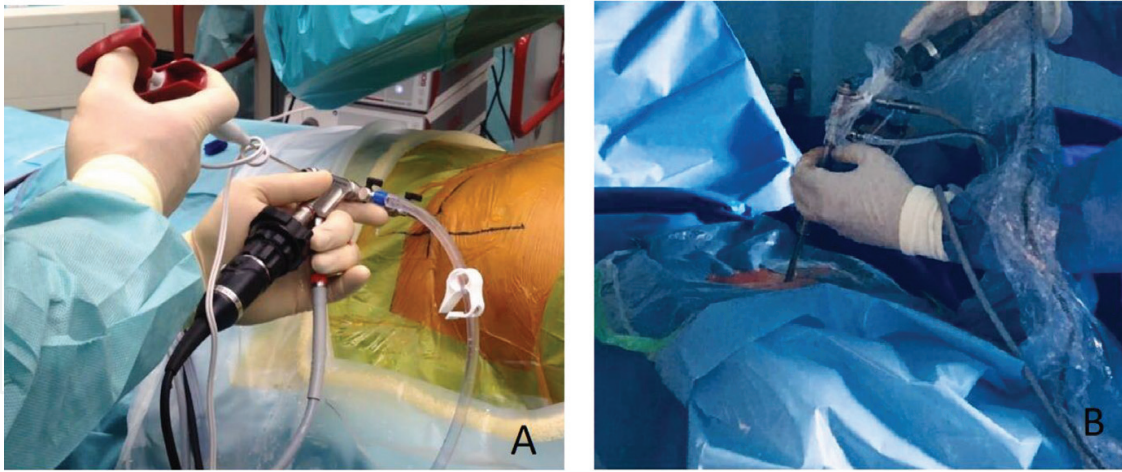
**Figure 3.** Endoscopy tower.



**Figure 4.** Spine endoscopy equipment.

The materials used in the procedure are varied and have particularities specific to each technique but, in general, are the following [4]:

- Working sleeve with bevel
- Dilators
- Probes
- Endoscopes with different working channels



**Figure 5.** A-extreme lateral endoscopic procedure B-spinal endoscopic procedure- interlaminar approach.

- Optical cannula
- Dissector
- Trigger flex radiofrequency
- Burrs
- Rongeurs
- Mallet
- Guide wires
- Trephines
- Forceps
- Scissors
- Fluid adapters
- Various accessories (hooks, elevators, etc.)

## 12. Learning curve

It should be taken into account that the endoscopic surgical techniques present greater technical difficulties and challenges than the traditional ones and, consequently, a greater learning curve.

The transforaminal procedure requires less operative learning time than the interlaminar procedure. This approach is recommended for beginning full-endoscopic lumbar discectomy.

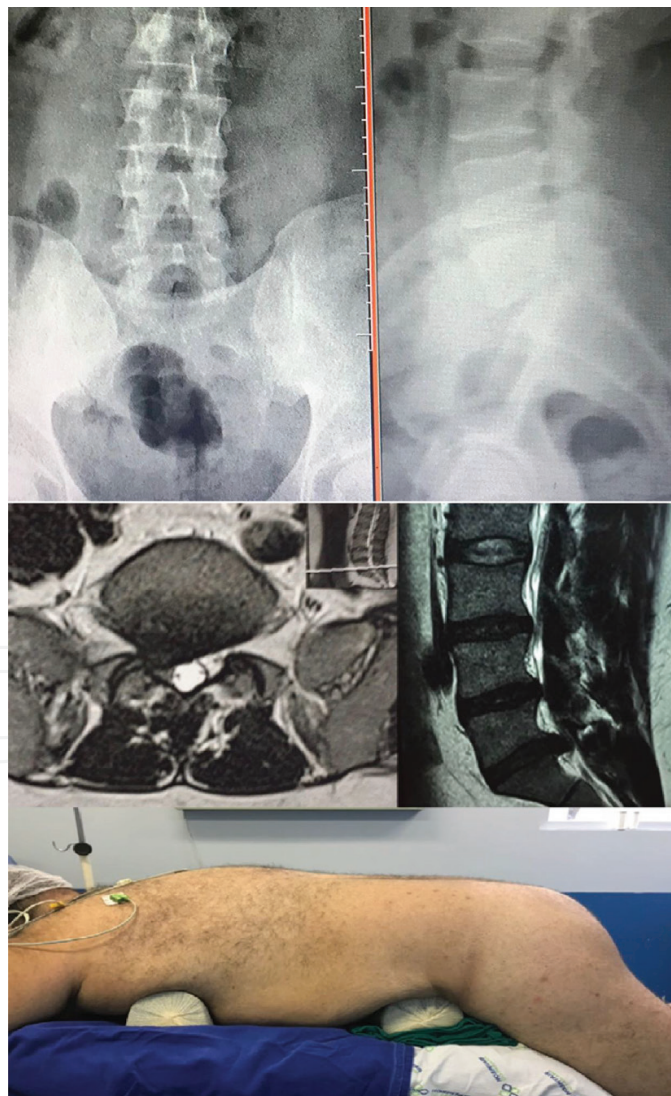
Hsu et al. showed that the stabilization of the learning curve for the transforaminal approach occurred around the 10th case based on the operative time, resulting in a steep learning curve, which represents the rapid acquisition of skills and a good thing for a beginner [22, 23].

Lee et al. observed a significant reduction in the operative time after the 17th patient was treated by percutaneous endoscopic lumbar discectomy [24].

Choi et al. recommended supervision by an experienced surgeon in the initial 10 cases to overcome the learning curve for the interlaminar procedure at L5-S1. Surgeons should gain adequate experience by starting with simple cases first, with small herniations and larger interlaminar windows, in which no serious problems are anticipated from the anatomic conditions [17].

### 13. Results

The majority of endoscopic spinal procedures are concerned with the surgical treatment of lumbar disc herniations, for which microsurgical intervention using an operating microscope currently is the gold standard when conservative treatment fails or when it is not indicated.



**Figure 6.** Obese patient positioned for interlaminar spine endoscopy and the MRI images of L5/S1 lumbar disc herniation. Note on MRI the extensive subcutaneous tissue.

Microsurgical microscopic disc surgery, also termed “microdiscectomy,” therefore has to be the reference to which endoscopic disc surgery is compared [25].

The literature data show that the spine endoscopy yields as good a result as the gold standard.

In a meta-analysis of He et al., that compared the results of microendoscopic discectomy versus open discectomy for lumbar disc herniation, they concluded that the microendoscopic discectomy was associated with similar improvement of symptoms and smaller surgical trauma, but it requires a demanding learning curve [26].

In a prospective study comparing the clinical outcomes of 55 patients with lumbar disc herniation treated with lumbar endoscopic percutaneous discectomy, Sebben et al., showed good results in more than 90% of the patients [27].

The literature evidences that the spinal endoscopy has a special advantage for treating lumbar disc herniation in patients with high body mass index. The endoscopic approach in obese individuals allows a lower surgical risk when compared to conventional open surgery, showing a safe technique with promising results (**Figure 6**) [28].

The results of the spine surgeries, in general, should always be evaluated with scores. Some of the main scores used are: Oswestry 2.0, Visual analogue scale (VAS), SF-36, Roland-Morris Disability Questionnaire, Quebec Back Pain Disability Questionnaire (Neck Disability Index, World Health Organization Quality of Life Assessment, Fear Avoidance). The use of questionnaires for evaluation of spine surgery helps to identify factors that may influence surgical results [29].

## 14. Complications

As any spine surgery, the endoscopic procedures also have its complications. As in open surgery, many complications can occur such as incomplete removal of herniated discs, recurrence of herniations, nerve root injury, dural tear, and nerve root-induced hyperalgesia or burning-like nerve root pain, epidural hematoma, posterior neck pain, or surgical site infection. Unique complications in the endoscopic procedures are passage of the working channel through the spinal canal into the disc space, super-elastic nerve hook caught by exiting nerve root and intra-operative seizure due to high depression of the saline fluid into the spine canal. Most of the dural tears do not need to be repaired because of the small damage of the surrounding tissues [30].

The literature shows that the occurrence of major complications as cardiac events, respiratory complications, pulmonary embolism, stroke and acute renal failure, and in-hospital death are significantly less likely in patients treated with microendoscopic spine surgeries [31].

## 15. Limitations

Most of the spine surgeons did not have training for the development and application of the minimally invasive technique during their formation, having to learn on their own the technique of endoscopic surgery. There are many steps to this learning, and with proper training and selection of patients, the initial difficulties can be overcome.

The surgeon needs clinical experience and repetitive training to overcome the high technical demand that the approach requires, such as limitation of the surgical field, absence of area and surrounding structures visible and that act as anatomical reference, difficulty in the perception of three dimensionality in a field two-dimensional visual.

In many countries, especially the underdeveloped countries, this technique is not yet part of the routine of spinal surgery, either because of lack of training of the medical team or because of the lack of access to material that is expensive. The high cost becomes a limiting factor to the dissemination of the endoscopic technique, and the procedure is often not covered by the health insurance plans [32, 33].

## 16. Take-away message

- Spinal endoscopy will probably become the gold standard in the surgical treatment of lumbar disc herniations.
- Less postoperative complications
- Faster return to work
- Still higher costs
- Steep learning curve
- Promising future for this technique

## 17. Conclusion

The development of new techniques and technologies in medicine has become a constant. However, its transformation into a gold standard is a long and arduous step. In many medical areas, endoscopic treatments are the reference technique. Further dissemination of endoscopic spinal techniques is required with more frequent and easily accessible courses for all spine surgeons. This makes medicine evolve, and professionals become more and more empowered. Thus, it is expected that in the near future, these techniques will become the standard of comparison to others that will emerge.

## Acknowledgements

We appreciate the opportunity to participate by writing a chapter to such a select and remarkable book. We are also grateful to the Universidade Federal do Paraná and the Hospital do Trabalhador that provided a sophisticated environment with all the necessary technologies and inputs to implant the endoscopic spinal surgery. This equipment is costly and is not accessible to most hospitals in Brazil.

## Conflict of interest

The authors have no conflict of interest to declare.

## Notes/Thanks/Other declarations

The success of this project was only possible thanks to the support, collaboration, and trust of many people who helped to make it a reality. Therefore, we would like to record our thanks here.

We consider it essential to thank our great supporter, Dr. Xavier Soler i Graells, head of the spine group of the Hospital do Trabalhador of the Universidade Federal do Paraná, in Curitiba, Brazil, who believed in the project when it was just an idea. His confidence and participation was fundamental to the accomplishment of this work. When many doubted the plausibility of starting the preparations, courses, and studies about the endoscopic spine surgery, his support was fundamental.

We are also grateful for the opportunity to be able to disseminate the experience of endoscopic spinal surgery in this reference book in endoscopic techniques.

## Author details

Álynson Larocca Kulcheski\*, Xavier Soler I Graells and André Luís Sebben

\*Address all correspondence to: alylarocca@gmail.com

Hospital do Trabalhador, Universidade Federal do Paraná, Curitiba, Brazil

## References

- [1] Smith L, Garvin PJ, Jennings RB, Gesler RM. Enzyme dissolution of the nucleus pulposus. *Nature*. 1963;**198**:1311-1312
- [2] Kambin P, editor. *Arthroscopic Microdiscectomy: Minimal Intervention Spinal Surgery*. Baltimore, MD: Urban & Schwarzenberg; 1990
- [3] Tsou PM, Yeung CA, Yeung AT. Posterolateral transforaminal selective endoscopic discectomy and thermal annuloplasty for chronic lumbar discogenic pain: A minimal access visualized intradiscal surgical procedure. *The Spine Journal*. 2004;**4**:564-573
- [4] Ruetten S, Komp M, Merk H, Godolias G. Use of newly developed instruments and endoscopes: Full-endoscopic resection of lumbar disc herniations via the interlaminar and lateral transforaminal approach. *Journal of Neurosurgery. Spine*. 2007;**6**:521-530

- [5] Yeung AT. The evolution and advancement of endoscopic foraminal surgery: One surgeon's experience incorporating adjunctive technologies. *SAS Journal*. 2007;**1**:108-117
- [6] Yeung AT, Gore SR. Evolving methodology in treating discogenic back pain by selective endoscopic discectomy (SED) and thermal annuloplasty. *Journal of Minimally Invasive Spine Surgery & Technique*. 2001;**1**:8-16
- [7] Kim DH, Choi G, Lee SH. *Endoscopic Spine Procedures*. New York:Thieme; 2011. pp. 42-58
- [8] Nellensteijn J, Ostelo R, Bartels R, Peul W, Van Royen B, Van Tulder M. Transforaminal endoscopic surgery for symptomatic lumbar disc herniations: A systematic review of the literature. *European Spine Journal*. 2010;**19**(2):181-204
- [9] Ruetten S, Komp M, Merk H, Godolias G. Full-endoscopic interlaminar and transforaminal lumbar discectomy versus conventional microsurgical technique: A prospective, randomized, controlled study. *Spine (Phila Pa 1976)*. 2008;**33**(9):931-939
- [10] Pan L, Zhang P, Yin Q. Comparison of tissue damages caused by endoscopic lumbar discectomy and traditional lumbar discectomy: A randomised controlled trial. *International Journal of Surgery*. 2014;**12**(5):534-537
- [11] Birkenmaier C, Chiu J, Fontanella A, Leu H, Ruetten S. Guidelines for Percutaneous Endoscopic Spinal Surgery. Issue 2;February 2010
- [12] Choi G, Pophale CS, Patel B, Uniyal P. Endoscopic spine surgery. *Journal of Korean Neurosurgical Association*; **60**(5):485-497
- [13] Yeung AT, Tsou PM. Posterolateral endoscopic excision for lumbar disc herniation: Surgical technique, outcome, and complications in 307 consecutive cases. *Spine (Phila Pa 1976)*. 2002;**27**(7):722-731
- [14] Yeung AT. Minimally invasive disc surgery with the yeung endoscopic spine system (YESS). *Surgical Technology International*. 1999;**8**:267-277
- [15] Yeung AT, Yeung CA. Advances in endoscopic disc and spine surgery: Foraminal approach. *Surgical Technology International*. 2003;**11**:255-263
- [16] Ruetten S, Komp M, Godolias G. An extremelateral access for the surgery of lumbar disc herniations inside the spinal canal using the full-endoscopic uniportaltransforaminal approach-technique and prospective results of 463 patients. *Spine (Phila Pa 1976)*. 2005 Nov 15;**30**(22):2570-2578
- [17] Choi G, Lee SH, Raiturker PP, Lee S, Chae YS. Percutaneous endoscopic interlaminar discectomy for intracanalicular disc herniations at L5-S1 using a rigid working channel endoscope. *Neurosurgery*. 2006;**58**(1 Suppl):ONS59-ONS68
- [18] Ruetten S, Komp M, Godolias G. A new full-endoscopic technique for the interlaminar operation of lumbar disc herniations using 6-mm endoscopes: Prospective 2-year results of 331 patients. *Minimally Invasive Neurosurgery*. 2006;**49**(2):80-87
- [19] Ruetten S, Komp M, Godolias G. Full-endoscopic interlaminar operation of lumbar disc herniations using new endoscopes and instruments. *Orthopädische Praxis*. 2005;**10**:527-532

- [20] Ruetten S, Komp M, Hahn P, Oezdemir S. Decompression of lumbar lateral spinal stenosis: Full-endoscopic, interlaminar technique. *Operative Orthopädie und Traumatologie*. 2013 Feb;**25**(1):31-46
- [21] Blamoutier A. Surgical discectomy for lumbar disc herniation: Surgical techniques. *Orthopaedics & Traumatology, Surgery & Research*. 2013;**99**:S187-S196
- [22] Hsu H, Chang S, Yang SS, Chai CL. Learning curve of full-endoscopic lumbar discectomy. *European Spine Journal*. 2013;**22**:727-733
- [23] Benzel EC, Orr RD. A steep learning curve is a good thing. *The Spine Journal*. 2011;**11**:131-132
- [24] Lee DY, Lee SH. Learning curve for percutaneous endoscopic lumbar discectomy. *Neurologia Medico-Chirurgica (Tokyo)*. 2008;**48**:383-389
- [25] Kreiner DS, Hwang SW, Easa JE, Resnick DK, Baisden JL, Bess S, Cho CH, DePalma MJ, Dougherty PN, Fernand R, Ghiselli G, Hanna AS, Lamer T, Lisi AJ, Mazanec DJ, Meagher RJ, Nucci RC, Patel RD, Sembrano JN, Sharma AK, Summers JT, Taleghani CK, Tontz WJ, Toton JF. An evidence-based clinical guideline for the diagnosis and treatment of lumbar disc herniation with radiculopathy. *The Spine Journal*. 2014;**14**:180-191
- [26] He J, Xiao S, Wu Z, Yuan Z. Microendoscopic discectomy versus open discectomy for lumbar disc herniation: A meta-analysis. *European Spine Journal*. 2016;**25**:1373-1381
- [27] Sebben AL, Graells XS, Benato ML, Santoro PG, Kulcheski AL. Lumbar endoscopic percutaneous discectomy – Clinical outcome. *Coluna/Columna*. 2017;**16**(3):177-179
- [28] Wang YP, Zhang W, An JL, Zhang J, Bai JY, Sun YP. Evaluation of transforaminal endoscopic discectomy in treatment of obese patients with lumbar disc herniation. *Medical Science Monitor*. 2016 Jul 18;**22**:2513-2519
- [29] Falavigna A, Teles AR, Braga GL, Barazzetti DO, Lazzaretti L, Tregnago AC. Instruments of clinical and functional evaluation in spine surgery. *Coluna/columna*. 2011;**10**(1):62-67
- [30] Zhou C, Zhang G, Panchal RR, Ren X, Xiang H, Xuexiao M, Chen X, Tongtong G, Hong W, Dixon AD. Unique complications of percutaneous endoscopic lumbar discectomy and percutaneous endoscopic interlaminar discectomy. *Pain Physician*. 2018;**21**:E105-E112 ISSN 2150-1149
- [31] Oichi T, Oshima Y, Chikuda H, Ohya J, Matsui H, Fushimi K, Tanaka S, Yasunaga H. In-hospital complication rate following microendoscopic versus open lumbar laminectomy: a propensity score-matched analysis. *The Spine Journal*. 2018. <https://doi.org/10.1016/j.spinee.2018.03.010>
- [32] Webb J, Gottschalk L, Lee YP, Garfin S, Kim C. Surgeon perceptions of minimally invasive spine surgery. *SAS Journal*. 2008;**2**(3):145
- [33] Kafadar A, Kahraman S, Akboru M. Percutaneous endoscopic transforaminal lumbar discectomy: a critical appraisal. *Minimally Invasive Neurosurgery*. 2006;**49**(2):74-79