

We are IntechOpen, the world's leading publisher of Open Access books Built by scientists, for scientists

6,900

Open access books available

185,000

International authors and editors

200M

Downloads

Our authors are among the

154

Countries delivered to

TOP 1%

most cited scientists

12.2%

Contributors from top 500 universities



WEB OF SCIENCE™

Selection of our books indexed in the Book Citation Index
in Web of Science™ Core Collection (BKCI)

Interested in publishing with us?
Contact book.department@intechopen.com

Numbers displayed above are based on latest data collected.
For more information visit www.intechopen.com



OCT in Lamellar Corneal Transplantation

Mehmet Cüneyt Özmen and
Hüseyin Baran Özdemir

Additional information is available at the end of the chapter

<http://dx.doi.org/10.5772/intechopen.78294>

Abstract

Anterior segment optical coherence tomography (AS-OCT) is a valuable tool in corneal transplantation surgery. In deep anterior lamellar keratoplasty (DALK), AS-OCT gives valuable information on preoperative decision process. AS-OCT image of the recipient cornea helps the surgeon to decide whether to proceed with a big bubble DALK or a manual dissection. Preoperative AS-OCT imaging of recipient stroma can also predict Descemet membrane perforation during big bubble induction. Intraoperative AS-OCT assures reaching the proper depth in order, and postoperatively, a surgeon can objectively assess the Descemet membrane and donor association and define complications such as a double anterior chamber. Before deciding for a Descemet membrane endothelial keratoplasty (DMEK), preoperative stromal scars can be identified with an AS-OCT and might affect the decision of the surgical procedure (DMEK or penetrating keratoplasty). After DMEK, graft detachment can be visualized by AS-OCT and treated accordingly.

Keywords: anterior segment optical coherence tomography, AS-OCT, lamellar keratoplasty, deep anterior lamellar keratoplasty, DALK, Descemet stripping automated endothelial keratoplasty, DSAEK, Descemet membrane endothelial keratoplasty, DMEK

1. Introduction

Since lamellar keratoplasty has developed for replacing only a diseased corneal layer, new advantages and challenges showed up [1–4]. Changing only the pathologic tissue brings closed globe surgery, which is safer than conventional penetrating keratoplasty [5]. It also helps to fasten rehabilitation after surgery. The anterior layer of corneal pathologies may be treated by deep anterior lamellar keratoplasty (DALK), and endothelial dysfunctions can be

managed by posterior lamellar procedures such as Descemet stripping automated endothelial keratoplasty (DSAEK) and Descemet membrane endothelial keratoplasty (DMEK) [6–8]. Each technique requires specific experience and tricks and has their own difficulties and complications. Beside these challenges, all these procedures provide safer surgery, faster rehabilitation, better functional, and anatomical outcomes [1].

Anterior segment optical coherence tomography (AS-OCT) is a non-contact imaging system that obtains high-resolution images of cornea and anterior chamber [9, 10]. It allows visualizing the shape and depth of corneal lesions such as scarring, measuring central corneal thickness, and lesion size [11, 12]. It can be used before, during, and after lamellar keratoplasty to evaluate the cornea [13]. In this chapter, we discuss the role of AS-OCT on the basis of different corneal lamellar procedures such as DALK, DSAEK, and DMEK.

2. OCT in deep anterior lamellar keratoplasty

DALK has been introduced as an alternative to penetrating keratoplasty (PK) for the diseases that affect anterior layers of cornea [14, 15]. Preserving the endothelium in DALK obtains reduced graft rejections [16, 17]. Many techniques have been described to separate corneal stroma and Descemet's membrane (DM). Peeling stroma up to near DM is called manual dissection [18, 19]. This procedure can be used as the first choice in some situations such as deep scarring, or the second choice intraoperatively when it cannot be progressed with other techniques [20–22]. Other option is the separation of stroma and DM with injection of air, fluid, or viscoelastic into deep stroma [14, 23–25].

Anterior lamellar keratoplasty was described first by Gasset in keratoconus patients which was named as conectomy and included transplantation of DM stripped full thickness graft [26]. Archila et al. introduced deep lamellar keratoplasty, using intrastromal air to separate stroma from DM [27]. After that, different techniques have been described, and today, the most frequently used procedure is “Big Bubble” that Anwar and Teichmann reported [14]. The technique includes 27-gauge needle with air-filled syringe inserted into deep stroma for 3–4 mm centrally and air injection to separate DM from stroma. It has been shown that outcomes of DALK were similar to PK with lower rejection or failure rates. However, Big Bubble can be obtained in only 56–82% of eyes [28–30].

For the improvement of these surgical techniques, new and unique complications beside advantages have emerged. The main purpose during separation of stroma from DM is to obtain a non-damaged DM [31]. But perforation or tears in DM occur in 4–20% of cases which is the most important complication during surgery [28–30, 32]. The risk of perforation is higher if proper big bubble formation is not achieved [33]. Unsuccessful big bubble formation is more frequently seen in patients with keratoconus and deep corneal scar involving DM [34–36]. Microperforations can be managed with air injection to the anterior chamber and careful manual dissection, but most of the macroperforations need to be converted to PK [14, 37]. The other complication is pseudoanterior chamber [38]. It can occur as double or triple anterior chamber [39, 40]. It usually develops after perforation in DM [41]. Remnant viscoelastic

material may also cause double anterior chamber [42]. Pseudoanterior chamber may resolve spontaneously when it is shallow but larger chambers should need surgical intervention [43].

The role of AS-OCT in DALK begins at a preoperative assessment. Patient selection and the right indication for surgery can be decided with many variables including AS-OCT findings. AS-OCT images provide central corneal thickness, anterior chamber biometry, angle and iris measurements, and lens thickness [13]. These findings help planning trephination depth during surgery, intraocular lens power assessment if needed combined with phacoemulsification and intraocular lens implantation, detecting narrow angle before surgery [11]. AS-OCT can also visualize corneal pathologies such as scarring in central or periphery, corneal degenerations or dystrophies and cysts. The importance of the imaging is to inform the surgeon about the location, size, and depth of the corneal lesion.

Big bubble procedure in DALK requires well-adjusted trephination depth and centrally inserted air cannula without damaging DM. This technique needs experience and has a steep learning curve. One of the difficulties is reaching the intended depth of the cornea with cannula and advancement to the central stroma. To overcome this challenge, preoperative central and peripheral corneal thickness measurement with AS-OCT is sensible. Busin et al. reported a modified big bubble technique, which needs AS-OCT [44]. They evaluated the thickness of trephination size with AS-OCT and aimed to reach a depth within 50 μm from the internal corneal surface. Air cannula was advanced only 1 mm into the cornea and air injected. They reported a successful pneumatic dissection in 85% of patients with this procedure. AS-OCT was very useful to show the depth of trephination site, and perforation during trephination occurred in only 2.3% (two patients) of patients. Moreover, AS-OCT has superiority over topography with Scheimpflug camera while planning the depth of trephination for DALK. Riss et al. measured corneal thickness with Scheimpflug camera, planned the depth of trephination to 90% of the thinnest pachymetric value, and faced perforation during trephination in 30.1% of patients [45]. Intraoperative AS-OCT seems to increase the choice of DALK rather than PK with easing lack of experience and surgical difficulties.

It is known that corneal stromal scar has effect on the success rate of DALK. Big bubble can be achieved in 56–82% of keratoconus patients without a corneal stromal scar. The success rate varies from keratoconus grade, central corneal thickness, and trephination size in these patients [28, 29, 46]. Corneal stromal scar is a very important risk factor in keratoconus patients and other corneal diseases influencing DALK success rate. Ozmen et al. reported that big bubble formation was achieved in 63.2% of patients and DALK was completed in 91% of patients [47]. The most important factor affecting DALK and big bubble success was the ratio of corneal scar depth and central corneal thickness (scar depth/central corneal thickness) which was calculated with AS-OCT, a cut-off point was given as $>53\%$ for scar depth/central corneal thickness, which has an acceptable sensitivity (100%) and specificity (67%). AS-OCT has been evaluated as crucial for measuring this risk factor and planning the right operation for patients. Corneal scar in keratoconus patients may be caused by hydrops. DALK has a relative contraindication for patients with stromal scar [38]. But considering rejection rates after PK, DALK can be an option when carried with great attention in patients with stromal scar. To avoid macroperforation during DALK, preoperative assessment and planning should

be proper (**Figure 1**). Nanavaty et al. reported that all of their patients had successful DALK and none required PK even though microperforation occurred in 60% of patients, with the help of AS-OCT at preoperative evaluation [48].

Recent improvements in surgical devices allow us to use AS-OCT at intraoperative evaluation. Several studies point out that visual acuity after DALK is better when stromal dissection is carried to the DM or when there is minimal residual stroma [20, 49–51]. AS-OCT provides intraoperative assessment of the cornea with high resolution. AS-OCT can be used to measure the depth of air cannula while using big bubble technique and may increase the rate of a successful big bubble formation. Scorgia et al. reported the first study in 2013 using intraoperative AS-OCT to visualize air cannula depth and big bubble formation [52]. It was emphasized that if the cannula reached the optimal depth, big bubble could be obtained more probably, but bubble achievement reduced when air was injected superficially. Successful big bubble in 90% of patients was obtained when the cannula reached within 100 μm from the DM. De Benito-Llopis et al. reported similar results and indicated that AS-OCT is also useful when big bubble could not be achieved and manual dissection was performed [53]. AS-OCT images can be used to evaluate a residual stromal bed during the manual dissection of corneal stroma.

Real-time intraoperative AS-OCT device provides imaging of all surgical steps continuously. Steven et al. reported a case series with using intraoperative AS-OCT. They succeeded monitoring big bubble formation in two of six patients [54]. They performed a micro-bubble incision technique in a patient that they could not obtain big bubble and documented with AS-OCT. Half of the patients was complicated with DM rupture. They indicated that the accurate measurement of trephination depth and cannula advancement into the deep central stroma is possible with real-time intraoperative AS-OCT. Sharma et al. published a case report of a patient who has undergone DALK. The procedure was complicated with DM detachment [55]. They used continuous intraoperative AS-OCT while intracameral sulfur

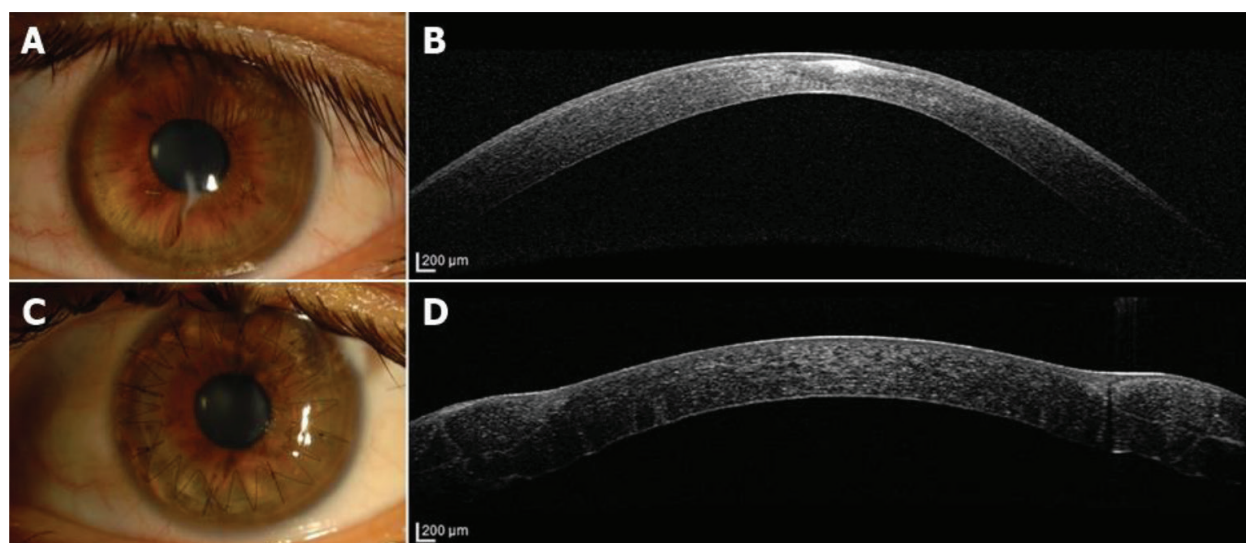


Figure 1. A patient with keratoconus who has an apical scar. (A) Anterior segment photography showing corneal scar. (B) AS-OCT showing corneal scar, which does not involve deep stromal layers and Descemet's membrane. With these findings, DALK was performed. (C) Anterior segment photography after surgery. (D) AS-OCT image of the patient after surgery.

hexafluoride injection and visualized re-attachment of DM with real-time images. Chaniyara et al. reported a complicated DALK case with repair of graft dehiscence with descemetopexy under the guidance of continuous intraoperative AS-OCT [56]. The use of real-time intraoperative AS-OCT seems to increase.

Intraoperative AS-OCT may obtain the depth and central advancement of the cannula while performing surgery. Image distortion caused by metallic objects is the major disadvantage of intraoperative AS-OCT [53]. The depth of the cannula could be assessed with only the image of the tunnel that is created by the cannula. With the manufacturing of plastic needles instead of metallic ones, one may overcome this drawback. Another disadvantage of intraoperative AS-OCT is caused by the devices which are mounted on the operation microscope separately. These devices have a handicap that they need to interrupt the surgery to take AS-OCT images. This disadvantage causes a delay in surgery. New devices that could obtain real-time images that are integrated into the operating microscope are being developed.

Pseudoanterior chamber due to DM detachment is frequently associated with microperforations during surgery, and management includes observation, intracameral gas injection, or reoperation (**Figure 2**). Slit-lamp biomicroscopy is enough to detect clinically significant detachment, but minimal double anterior chamber may not be seen by examination. The decision of treatment type and follow-up requires documentation of the patient. AS-OCT is very helpful to detect DM detachment and follow-up of the patient [57]. It allows to measure the size of pseudoanterior chamber initially and after the treatment [58]. AS-OCT can also visualize Dua's layer in case of triple anterior chamber occurrence [40].

AS-OCT can evaluate other postoperative complications of DALK. Bahadir et al. reported a candida interface keratitis after DALK, showing the keratitis site at AS-OCT [59]. Mukhopadhyay et al. reported a rhinosporidiosis keratitis case and they performed a repeat DALK procedure successfully after determining the site of the infiltrate in corneal stroma with AS-OCT [60]. Muller et al. published a case report with granular corneal dystrophy type-1 and reported that although they achieved pneumatic dissection to predescemetic layer during DALK, AS-OCT showed granular opacities between DM and graft [61]. It is thought that granular deposition occurs at predescemetic layer in granular corneal dystrophy type-1 and PK could be a better alternative than DALK. Costa et al. reported an iris cyst seen after DALK which was documented with AS-OCT and anterior segment photography [62].

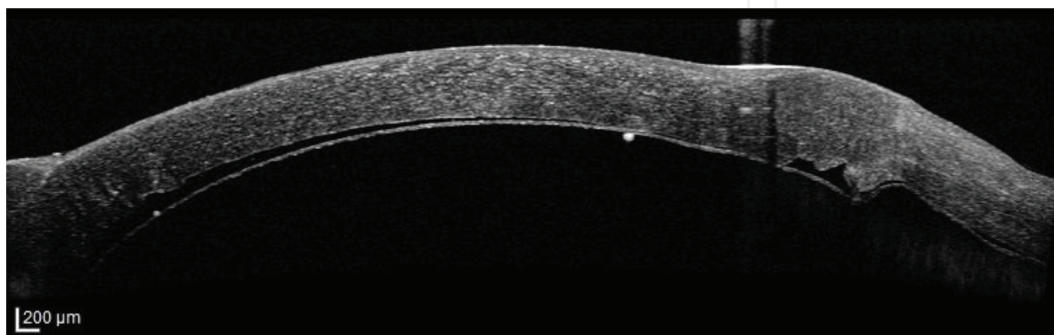


Figure 2. AS-OCT of a patient who had DALK surgery showing pseudoanterior chamber.

3. OCT in posterior lamellar keratoplasty

Posterior lamellar keratoplasty has emerged as an alternative to PK to treat corneal endothelial pathology [63, 64]. Evolution of the posterior lamellar keratoplasty procedures began with Melles et al., who reported deep lamellar endothelial keratoplasty (DLEK) that includes sutureless transplantation of posterior lamellae of cornea from a scleral incision [65]. Following DLEK, Descemet's stripping endothelial keratoplasty (DSEK) and DSAEK were developed [3, 66]. Corneal graft is prepared with automated microkeratome in DSAEK and it has been used worldwide [67]. Recently, DMEK is introduced as the latest posterior lamellar keratoplasty technique by Melles et al. [4]. Today, DSAEK and DMEK are the most popular posterior lamellar keratoplasty procedures [68].

DSAEK and DMEK are completely different interventions and both have different maneuvers [69]. DSAEK needs a 4- or a 5-mm limbal or corneo-scleral incision to insert the donor lamella. Descemet stripping of the host cornea is performed over an 8-mm diameter circle with a reverse Sinsky hook. Preparation of donor cornea is performed with automated microkeratome. Donor button consists of a thin stroma and Descemet's endothelial complex. Femtosecond laser has also been used recently for the preparation of the DSAEK graft. After trephination of donor lamella, it is inserted into the anterior chamber. Graft is attached to the host cornea with an air bubble. By contrast, DMEK provides transplantation of the endothelium with DM layer with minimal or absent stroma [70]. DM is stripped from the posterior stroma [71]. There are two methods of stripping: the first described procedure consists of DM stripping after corneal button trephination and the other technique consists of scoring edge of DM and stripping away from the stroma nearly half way to the center for 360° before trephination. Recently, DM dissection can be performed by an automated microkeratome and called as Descemet's membrane automated endothelial keratoplasty (DMAEK) [72, 73].

Several studies and meta-analysis reported that DMEK has superiority over DSAEK, considering visual outcome and patient satisfaction but DSAEK is used more frequently because of the steeper learning curve of DMEK [1, 74–77]. DMEK and DSAEK have a similar complication profile [78–80]. The most common early complications following posterior lamellar keratoplasty are graft dislocation and primary graft failure [81]. Other complications are graft rejection, endothelial cell loss, iatrogenic pupillary block glaucoma, keratitis, and endophthalmitis.

AS-OCT is a useful tool for posterior lamellar keratoplasty. It is valuable for preoperative assessment, intraoperative maneuvers, and postoperative follow-up. The preoperative duration of corneal stromal edema is found to be an important factor for visual outcome in patients who underwent endothelial keratoplasty [82]. It is known that the long duration of corneal stromal edema causes an increase in fibroblastic activity, irreversible fibrotic changes, and corneal scarring [83–85]. PK can be chosen in patients who have bullous keratopathy more than 12 months, instead of endothelial keratoplasty [82, 86]. AS-OCT may detect these stromal changes and obtain objective data for the decision of a planned surgery (**Figure 3**). AS-OCT images may help to decide which patients with stromal edema more than 12 months will benefit from endothelial surgery. AS-OCT can also obtain fine images of corneal epithelium. Long-standing bullous keratopathy may also cause subepithelial haze and fibrosis [87]. Agarwal et al. reported that endothelial keratoplasty with epithelial debridement provides a

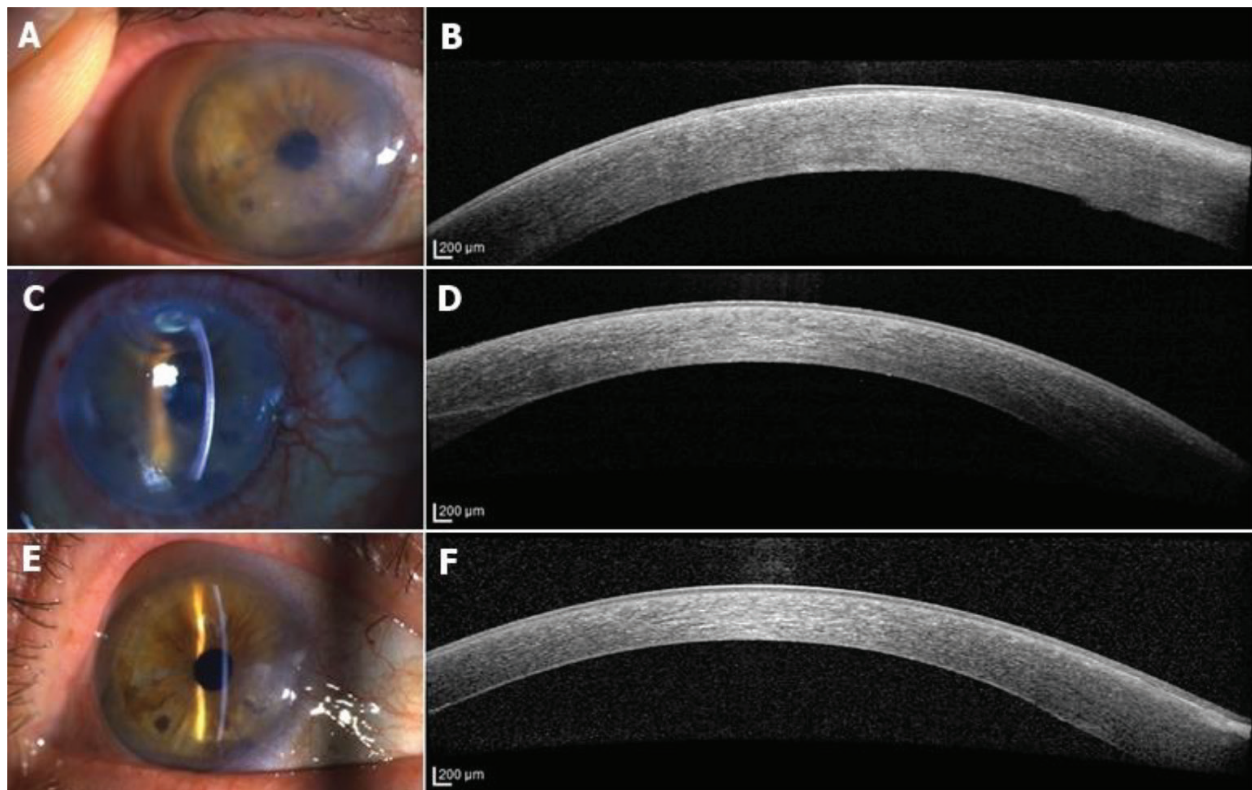


Figure 3. A patient with pseudophakic bullous keratopathy has underwent DMEK. (A) Preoperative anterior segment photography showing corneal edema. (B) Preoperative AS-OCT showing thickened corneal epithelium, subepithelial hyper-reflectance and corneal stromal edema. The central corneal thickness was 771 μm . (C) Early postoperative anterior segment photography shows reduced corneal edema. (D) Early postoperative AS-OCT shows reduced corneal edema and loss of subepithelial hyper-reflectance. The central corneal thickness was 615 μm . (E) Late postoperative anterior segment photography shows a clear cornea. (F) Late postoperative AS-OCT image shows normal corneal reflectance. The central corneal thickness was 555 μm .

better visual outcome in patients with chronic stromal edema [88]. AS-OCT was used to show corneal layers before and after endothelial keratoplasty which indicates that subepithelial haze and opacification of cornea decreased with surgery (**Figure 4**).

DMEK needs special maneuvers to unfold the graft and attach to the host. Attachment of the graft in both DMEK and DSAEK was performed with an air bubble, and there should be no interface fluid. Intraoperative AS-OCT can evaluate the graft orientation and obtain images of interface. Ide et al. reported the successful use of intraoperative AS-OCT in six consecutive patients showing no interface fluid at the end of the DSAEK [89]. Knecht et al. reported that their intraoperative AS-OCT study with six cases underwent DSAEK and indicated that detectable interface space does not mean a failure because the fluid may regress 1 day after surgery [90]. They also reported that detectable interface fluid may disappear with vent incisions by the guidance of intraoperative AS-OCT. In addition to that, PIONEER study published two separate results from DSAEK surgery with intraoperative AS-OCT. The first study indicated that transient interface fluid at the end of the surgery and first postoperative day is more likely to develop textural interface opacity [91]. The second study reported that a larger residual interface fluid volume, area, and thickness at the end of surgery are associated with early-graft detachment [92]. These results emphasize that minimal or no interface fluid should be left at the end of the DSAEK surgery.

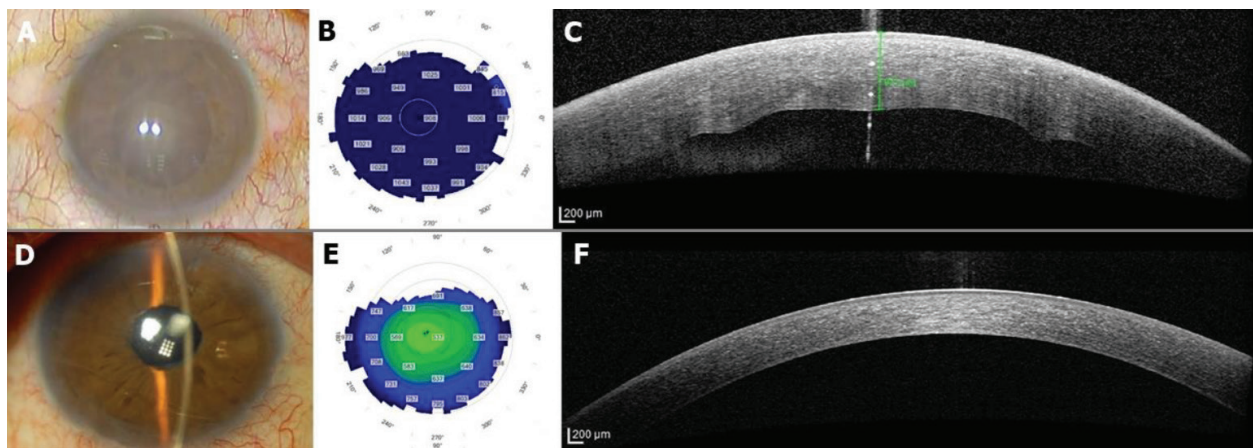


Figure 4. Triple-DMEK was performed successfully to a patient who had Fuchs endothelial dystrophy, severe corneal stromal edema with epithelial bullae, and angle closure glaucoma. (A) Preoperative anterior segment photography showing cataract and severe corneal edema. Visual acuity was hand movements. (B) Preoperative corneal thickness map in corneal topography. (C) preoperative AS-OCT image showing that corneal thickness was 917 μm . (D) Corneal edema was diminished 1 month after surgery and visual acuity was increased to 20/20. (E) Postoperative corneal thickness map showing resolved corneal edema. (F) AS-OCT image showing that corneal layers were returned to normal and the central corneal thickness was 530 μm .

Initial studies were performed with handheld AS-OCT devices, and imaging caused interruption of the surgery. Initial publications were followed by studies with real-time intraoperative AS-OCT which is integrated with the operating microscope [93–96]. Real-time imaging provided more comfortable surgery with simultaneous imaging. Besides evaluating interface fluid during surgery, intraoperative AS-OCT has additional benefits. Intraoperative AS-OCT assists in obtaining images of the nearly opaque corneas caused by stromal edema which could not be assessed well with an operation microscope [95]. This helps the surgeon to manipulate the graft easily in the operation.

DMEK is a relatively new technique than DSAEK, and studies on DMEK with intraoperative AS-OCT are fewer. Steven et al. published a study with 26 patients who underwent DMEK and reported that the usage of intraoperative AS-OCT enhances the graft visibility and surgeon's orientation [97]. Saad et al. reported that intraoperative AS-OCT enables a faster graft positioning with less manipulation in DMEK [96]. DISCOVER study indicated that intraoperative AS-OCT is very useful to confirm graft orientation and to reduce the iatrogenic graft failure [98].

Postoperative follow-up for graft dehiscence and graft failure is crucial in posterior lamellar keratoplasty. The fluid between the cornea and the graft can be seen with a slit-lamp biomicroscopy but Tarnawska and Wylegala reported that half of the interface fluid cannot be seen with examination which was detected by AS-OCT [99]. Early detection of interface fluid and graft detachment provides early intervention. In addition to that, postoperative measurement of graft thickness is an important factor for graft failure in DSAEK patients [100]. Eyes with thick grafts are more prone to graft failure (**Figure 5**). It is important to provide improvement in visual acuity after endothelial keratoplasty but fewer patients achieve excellent quality of vision. Many reasons were suggested including anterior stromal changes, graft-related problems, induced high-order aberrations, and interface-related problems. Turnbull et al. commented that the evolving anterior segment imaging could increase our

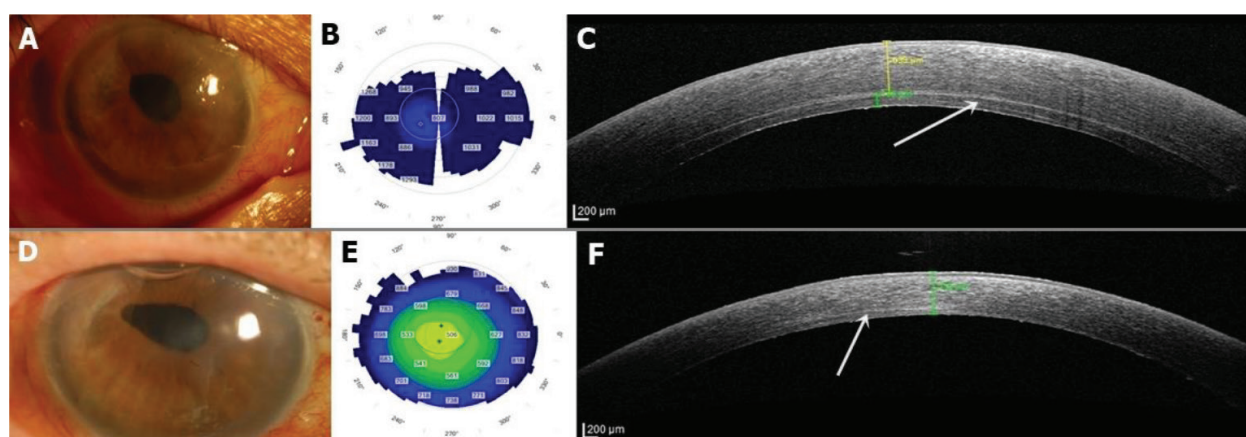


Figure 5. A patient who underwent DSAEK surgery for pseudophakic bullous keratopathy, presented with primary graft failure. DMEK was performed as a second surgery and corneal edema reduced. (A) Anterior segment photography before surgery showing severe edema. (B) Corneal thickness map in corneal topography showing corneal edema. (C) Corneal thickness was 753 μm and DSAEK graft's thickness was 113 μm . Hyperreflective line shown with white arrow shows interphase between posterior corneal stroma and DSAEK graft. (D) Anterior segment photography 1 day after DMEK; there was corneal haze without edema. (E) Corneal thickness map in corneal topography showing thinning in central cornea. (F) AS-OCT image showing that the central corneal thickness was 515 μm . DMEK graft cannot be visualized by AS-OCT. White arrow shows a horizontal hyperreflective posterior corneal stromal scar surface.

understanding of the reason to the solution of these difficulties [85]. Suh et al. reported that the evaluation of epithelial ingrowth in DSAEK patient can be possible with AS-OCT [101]. Kymionis et al. reported a case with residual DM after DSAEK that was shown with AS-OCT [102]. Lopez and Melles et al. published a study that described rebubbling techniques in DMEK, and they showed detached and folded DM with AS-OCT [103]. The assistance of AS-OCT for the assessment and management of complications in DMEK was studied in many publications [104–107].

4. Conclusion

AS-OCT is a valuable tool for assessing lamellar keratoplasty in all steps of the surgery. The use of AS-OCT starts from patient selection to postoperative late complications. Both anterior and posterior lamellar procedures need proper patient selection to obtain desired outcomes. Imaging the graft-host relationship with AS-OCT allows proper assessment of interface and helps surgeon to perform fast and successful surgeries. Some complications such as graft detachment can be visualized with AS-OCT postoperatively, more accurate than a conventional slit-lamp examination. AS-OCT is currently being used widely in corneal surgeries, and its role in lamellar keratoplasty seems to be increasing.

Acknowledgements

The authors thank the technicians of anterior segment imaging, Gazi University Medical School Department of Ophthalmology (Aynur Kartal, Cengiz Aksel, Nilgun Taşçı, Suat Avcı, Şenay Çay, Zafer Yıldırım), for the excellent photographs that have been used in this chapter.

Conflict of interest

None of the authors have any financial interest in any material or method mentioned in this chapter.

Author details

Mehmet Cüneyt Özmen^{1*} and Hüseyin Baran Özdemir²

*Address all correspondence to: mcozmen@gmail.com

1 Department of Ophthalmology, Faculty of Medicine, Gazi University, Ankara, Turkey

2 Ulucanlar Eye Training and Research Hospital, University of Health Sciences, Ankara, Turkey

References

- [1] Kymionis GD, Mikropoulos DG, Portaliou DM, Boboridis KG, Voudouragkaki IC, Dragoumis ND, et al. New perspectives on lamellar keratoplasty. *Advances in Therapy*. 2014;**31**:494-511. DOI: 10.1007/s12325-014-0121-0
- [2] Borderie VM, Sandali O, Bullet J, Gaujoux T, Touzeau O, Laroche L. Long-term results of deep anterior lamellar versus penetrating keratoplasty. *Ophthalmology*. 2012;**119**:249-255. DOI: 10.1016/j.ophtha.2011.07.057
- [3] Gorovoy MS. Descemet-stripping automated endothelial keratoplasty. *Cornea*. 2006;**25**:886-889. DOI: 10.1097/01.ico.0000214224.90743.01
- [4] Melles GR, Ong TS, Ververs B, van der Wees J. Descemet membrane endothelial keratoplasty (DMEK). *Cornea*. 2006;**25**:987-990. DOI: 10.1097/01.ico.0000248385.16896.34
- [5] Maharana PK, Agarwal K, Jhanji V, Vajpayee RB. Deep anterior lamellar keratoplasty for keratoconus: A review. *Eye & Contact Lens*. 2014;**40**:382-389. DOI: 10.1097/ICL.0000000000000076
- [6] Dapena I, Ham L, Lie J, Van-Der-Wees J, Melles GR. Descemet membrane endothelial keratoplasty (DMEK): Two-year results. *Archivos de la Sociedad Española de Oftalmología*. 2009;**84**:237-243
- [7] Shimmura S, Tsubota K. Deep anterior lamellar keratoplasty. *Current Opinion in Ophthalmology*. 2006;**17**:349-355. DOI: 10.1097/01.icu.0000233953.09595.91
- [8] Price MO, Price FW. Descemet's stripping endothelial keratoplasty. *Current Opinion in Ophthalmology*. 2007;**18**:290-294. DOI: 10.1097/ICU.0b013e3281a4775b
- [9] Huang D, Swanson EA, Lin CP, Schuman JS, Stinson WG, Chang W, et al. Optical coherence tomography. *Science*. 1991;**254**:1178-1181

- [10] Izatt JA, Hee MR, Swanson EA, Lin CP, Huang D, Schuman JS, et al. Micrometer-scale resolution imaging of the anterior eye in vivo with optical coherence tomography. *Archives of Ophthalmology*. 1994;**112**:1584-1589
- [11] Ramos JL, Li Y, Huang D. Clinical and research applications of anterior segment optical coherence tomography - a review. *Clinical & Experimental Ophthalmology*. 2009;**37**: 81-89. DOI: 10.1111/j.1442-9071.2008.01823.x
- [12] Maeda N. Optical coherence tomography for corneal diseases. *Eye & Contact Lens*. 2010; **36**:254-259. DOI: 10.1097/ICL.0b013e3181ef0dbb
- [13] Doors M, Berendschot TT, de Brabander J, Webers CA, Nuijts RM. Value of optical coherence tomography for anterior segment surgery. *Journal of Cataract and Refractive Surgery*. 2010;**36**:1213-1229. DOI: 10.1016/j.jcrs.2010.05.002
- [14] Anwar M, Teichmann KD. Deep lamellar keratoplasty: Surgical techniques for anterior lamellar keratoplasty with and without baring of Descemet's membrane. *Cornea*. 2002;**21**:374-383
- [15] Vajpayee RB, Tyagi J, Sharma N, Kumar N, Jhanji V, Titiyal JS. Deep anterior lamellar keratoplasty by big-bubble technique for treatment corneal stromal opacities. *American Journal of Ophthalmology*. 2007;**143**:954-957. DOI: 10.1016/j.ajo.2007.02.036
- [16] Reinhart WJ, Musch DC, Jacobs DS, Lee WB, Kaufman SC, Shtein RM. Deep anterior lamellar keratoplasty as an alternative to penetrating keratoplasty a report by the american academy of ophthalmology. *Ophthalmology*. 2011;**118**:209-218. DOI: 10.1016/j.ophtha.2010.11.002
- [17] Olson EA, Tu EY, Basti S. Stromal rejection following deep anterior lamellar keratoplasty: Implications for postoperative care. *Cornea*. 2012;**31**:969-973. DOI: 10.1097/ICO.0b013e31823f8a99
- [18] Sugita J, Kondo J. Deep lamellar keratoplasty with complete removal of pathological stroma for vision improvement. *The British Journal of Ophthalmology*. 1997;**81**:184-188
- [19] Melles GR, Lander F, Rietveld FJ, Remeijer L, Beekhuis WH, Binder PS. A new surgical technique for deep stromal, anterior lamellar keratoplasty. *The British Journal of Ophthalmology*. 1999;**83**:327-333
- [20] Knutsson KA, Rama P, Paganoni G. Modified big-bubble technique compared to manual dissection deep anterior lamellar keratoplasty in the treatment of keratoconus. *Acta Ophthalmologica*. 2015;**93**:431-438. DOI: 10.1111/aos.12705
- [21] Leccisotti A. Air-assisted manual deep anterior lamellar keratoplasty for treatment of herpetic corneal scars. *Cornea*. 2009;**28**:728-731. DOI: 10.1097/ICO.0b013e3181930a7e
- [22] Chew AC, Mehta JS, Tan DT. Deep lamellar keratoplasty after resolution of hydrops in keratoconus. *Cornea*. 2011;**30**:454-459. DOI: 10.1097/ICO.0b013e3181f0b1f3
- [23] Amayem AF, Anwar M. Fluid lamellar keratoplasty in keratoconus. *Ophthalmology*. 2000;**107**:76-79 discussion 80

- [24] Manche EE, Holland GN, Maloney RK. Deep lamellar keratoplasty using viscoelastic dissection. *Archives of Ophthalmology*. 1999;**117**:1561-1565
- [25] Muftuoglu O, Toro P, Hogan RN, Bowman RW, Cavanagh HD, McCulley JP, et al. Sarnicola air-visco bubble technique in deep anterior lamellar keratoplasty. *Cornea*. 2013;**32**:527-532. DOI: 10.1097/ICO.0b013e31826cbe99
- [26] Gasset AR. Lamellar keratoplasty in the treatment of keratoconus: Conectomy. *Ophthalmic Surgery*. 1979;**10**:26-33
- [27] Archila EA. Deep lamellar keratoplasty dissection of host tissue with intrastromal air injection. *Cornea*. 1984;**3**:217-218
- [28] Feizi S, Javadi MA, Daryabari SH. Factors influencing big-bubble formation during deep anterior lamellar keratoplasty in keratoconus. *The British Journal of Ophthalmology*. 2016;**100**:622-625. DOI: 10.1136/bjophthalmol-2015-307111
- [29] Fogla R, Padmanabhan P. Results of deep lamellar keratoplasty using the big-bubble technique in patients with keratoconus. *American Journal of Ophthalmology*. 2006; **141**:254-259. DOI: 10.1016/j.ajo.2005.08.064
- [30] Fontana L, Parente G, Tassinari G. Clinical outcomes after deep anterior lamellar keratoplasty using the big-bubble technique in patients with keratoconus. *American Journal of Ophthalmology*. 2007;**143**:117-124. DOI: 10.1016/j.ajo.2006.09.025
- [31] El-Danasoury A. Big bubble deep anterior lamellar keratoplasty (BB-DALK). *International Ophthalmology Clinics*. 2013;**53**:41-53. DOI: 10.1097/IIO.0b013e3182713434
- [32] Arslan OS, Unal M, Tuncer I, Yucel I. Deep anterior lamellar keratoplasty using big-bubble technique for treatment of corneal stromal scars. *Cornea*. 2011;**30**:629-633. DOI: 10.1097/ICO.0b013e3181eeb44a
- [33] Jhanji V, Sharma N, Vajpayee RB. Intraoperative perforation of Descemet's membrane during "big bubble" deep anterior lamellar keratoplasty. *International Ophthalmology*. 2010;**30**:291-295. DOI: 10.1007/s10792-009-9334-7
- [34] Michieletto P, Balestrazzi A, Balestrazzi A, Mazzotta C, Occhipinti I, Rossi T. Factors predicting unsuccessful big bubble deep lamellar anterior keratoplasty. *Ophthalmologica*. 2006; **220**:379-382. DOI: 10.1159/000095864
- [35] Huang T, Zhang X, Wang Y, Zhang H, Huand A, Gao N. Outcomes of deep anterior lamellar keratoplasty using the big-bubble technique in various corneal diseases. *American Journal of Ophthalmology*. 2012;**154**:282-289 e281. DOI: 10.1016/j.ajo.2012.02.025
- [36] Shimmura S, Shimazaki J, Omoto M, Teruya A, Ishioka M, Tsubota K. Deep lamellar keratoplasty (DLKP) in keratoconus patients using viscoadaptive viscoelastics. *Cornea*. 2005;**24**:178-181
- [37] Leccisotti A. Descemet's membrane perforation during deep anterior lamellar keratoplasty: Prognosis. *Journal of Cataract and Refractive Surgery*. 2007;**33**:825-829. DOI: 10.1016/j.jcrs.2007.02.016

- [38] Karimian F, Feizi S. Deep anterior lamellar keratoplasty: Indications, surgical techniques and complications. *Middle East African Journal of Ophthalmology*. 2010;**17**:28-37. DOI: 10.4103/0974-9233.61214
- [39] Higaki S, Maeda N, Watanabe H, Kiritoshi A, Inoue Y, Shimomura Y. Double anterior chamber deep lamellar keratoplasty: Case report. *Cornea*. 1999;**18**:240-242
- [40] Selvan H, Patil M, Yadav S, Tandon R. Triple chamber: A clinical rarity after deep anterior lamellar keratoplasty and role of optical coherence tomography in management. *International Ophthalmology*. 2017. DOI: 10.1007/s10792-017-0755-4
- [41] Venkatraman A. Spontaneous resolution of double anterior chamber with perforation of Descemet's membrane in deep anterior lamellar keratoplasty. *Oman Journal of Ophthalmology*. 2012;**5**:112-114. DOI: 10.4103/0974-620X.99376
- [42] Bhojwani RD, Noble B, Chakrabarty AK, Stewart OG. Sequestered viscoelastic after deep lamellar keratoplasty using viscodissection. *Cornea*. 2003;**22**:371-373
- [43] Passani A, Sframeli AT, Loiudice P, Nardi M. Late spontaneous resolution of a double anterior chamber post deep anterior lamellar keratoplasty. *Saudi Journal of Ophthalmology*. 2017;**31**:58-60. DOI: 10.1016/j.sjopt.2017.01.003
- [44] Busin M, Scordia V, Leon P, Nahum Y. Outcomes of air injection within 2 mm inside a deep trephination for deep anterior lamellar Keratoplasty in eyes with Keratoconus. *American Journal of Ophthalmology*. 2016;**164**:6-13. DOI: 10.1016/j.ajo.2015.12.033
- [45] Riss S, Heindl LM, Bachmann BO, Kruse FE, Cursiefen C. Pentacam-based big bubble deep anterior lamellar keratoplasty in patients with keratoconus. *Cornea*. 2012;**31**:627-632. DOI: 10.1097/ICO.0b013e31823f8c85
- [46] Feizi S, Javadi MA, Jamali H, Mirbabaee F. Deep anterior lamellar keratoplasty in patients with keratoconus: Big-bubble technique. *Cornea*. 2010;**29**:177-182. DOI: 10.1097/ICO.0b013e3181af25b7
- [47] Ozmen MC, Yesilirmak N, Aydin B, Ceylanoglu KS, Atalay HT, Akata F. Prediction of descemet membrane perforation during deep anterior lamellar keratoplasty in patients with keratoconus with stromal scar. *Eye & Contact Lens*. 2017. DOI: 10.1097/ICL.0000000000000434
- [48] Nanavaty MA, Daya SM. Outcomes of deep anterior lamellar keratoplasty in keratoconic eyes with previous hydrops. *The British Journal of Ophthalmology*. 2012;**96**:1304-1309. DOI: 10.1136/bjophthalmol-2012-302110
- [49] Sarnicola V, Toro P, Gentile D, Hannush SB. Descemetetic DALK and predescemetetic DALK: Outcomes in 236 cases of keratoconus. *Cornea*. 2010;**29**:53-59. DOI: 10.1097/ICO.0b013e3181a31aea
- [50] Feizi S, Javadi MA, Rastegarpour A. Visual acuity and refraction after deep anterior lamellar keratoplasty with and without successful big-bubble formation. *Cornea*. 2010;**29**:1252-1255. DOI: 10.1097/ICO.0b013e3181d83710

- [51] Tan DT, Anshu A, Parthasarathy A, Htoon HM. Visual acuity outcomes after deep anterior lamellar keratoplasty: A case-control study. *The British Journal of Ophthalmology*. 2010;**94**:1295-1299. DOI: 10.1136/bjo.2009.167528
- [52] Scorgia V, Busin M, Lucisano A, Beltz J, Carta A, Scorgia G. Anterior segment optical coherence tomography-guided big-bubble technique. *Ophthalmology*. 2013;**120**:471-476. DOI: 10.1016/j.ophtha.2012.08.041
- [53] De Benito-Llopis L, Mehta JS, Angunawela RI, Ang M, Tan DT. Intraoperative anterior segment optical coherence tomography: A novel assessment tool during deep anterior lamellar keratoplasty. *American Journal of Ophthalmology*. 2014;**157**:334-341 e333. DOI: 10.1016/j.ajo.2013.10.001
- [54] Steven P, Le Blanc C, Lankenau E, Krug M, Oelckers S, Heindl LM, et al. Optimising deep anterior lamellar keratoplasty (DALK) using intraoperative online optical coherence tomography (iOCT). *The British Journal of Ophthalmology*. 2014;**98**:900-904. DOI: 10.1136/bjophthalmol-2013-304585
- [55] Sharma N, Aron N, Kakkar P, Titiyal JS. Continuous intraoperative OCT guided management of post-deep anterior lamellar keratoplasty descemet's membrane detachment. *Saudi Journal of Ophthalmology*. 2016;**30**:133-136. DOI: 10.1016/j.sjopt.2016.01.001
- [56] Chaniyara MH, Bafna R, Urkude J, Sharma N. Rescuing the host Descemet's membrane in full-thickness traumatic wound dehiscence in deep anterior lamellar keratoplasty: Intraoperative optical coherence tomography (iOCT)-guided technique. *BML Case Reports*. 2017;**2017**. DOI: 10.1136/bcr-2017-221495
- [57] Lim LS, Aung HT, Aung T, Tan DT. Corneal imaging with anterior segment optical coherence tomography for lamellar keratoplasty procedures. *American Journal of Ophthalmology*. 2008;**145**:81-90. DOI: 10.1016/j.ajo.2007.08.019
- [58] Wylegala E, Nowinska A. Usefulness of anterior segment optical coherence tomography in Descemet membrane detachment. *European Journal of Ophthalmology*. 2009;**19**:723-728
- [59] Bahadir AE, Bozkurt TK, Kutun SA, Yanyali CA, Acar S. Candida interface keratitis following deep anterior lamellar keratoplasty. *International Ophthalmology*. 2012;**32**:383-386. DOI: 10.1007/s10792-012-9545-1
- [60] Mukhopadhyay S, Datta H, Sen D. Intracorneal rhinosporidiosis managed with deep anterior lamellar keratoplasty. *Middle East African Journal of Ophthalmology*. 2014;**21**:361-362. DOI: 10.4103/0974-9233.142282
- [61] Muller EG, Gomes JAP, Nose W, Nose RM. Persistence of granular corneal dystrophy type-1 deposits in the predescemetic layer after big-bubble deep anterior lamellar keratoplasty. *Arquivos Brasileiros de Oftalmologia*. 2018;**81**:66-69. DOI: 10.5935/0004-2749.20180015
- [62] Costa JF, Rego M, Rosa A, Costa E, Fonseca P, Cachulo ML, et al. Anterior chamber epithelial cyst after uneventful deep anterior lamellar Keratoplasty. *Cornea*. 2016;**35**:1372-1374. DOI: 10.1097/ICO.0000000000000866

- [63] Maier P, Reinhard T, Cursiefen C. Descemet stripping endothelial keratoplasty—rapid recovery of visual acuity. *Deutsches Ärzteblatt International*. 2013;**110**:365-371. DOI: 10.3238/arztebl.2013.0365
- [64] Grottone GT, Pereira NC, Gomes JA. Endothelial keratoplasty: Evolution and horizons. *Arquivos Brasileiros de Oftalmologia*. 2012;**75**:439-446
- [65] Melles GR, Lander F, van Dooren BT, Pels E, Beekhuis WH. Preliminary clinical results of posterior lamellar keratoplasty through a sclerocorneal pocket incision. *Ophthalmology*. 2000;**107**:1850-1856 discussion 1857
- [66] Price FW Jr, Price MO. Descemet's stripping with endothelial keratoplasty in 50 eyes: A refractive neutral corneal transplant. *Journal of Refractive Surgery*. 2005;**21**:339-345
- [67] Veldman PB, Terry MA, Straiko MD. Evolving indications for Descemet's stripping automated endothelial keratoplasty. *Current Opinion in Ophthalmology*. 2014;**25**:306-311. DOI: 10.1097/ICU.0000000000000073
- [68] Dapena I, Ham L, Melles GR. Endothelial keratoplasty: DSEK/DSEK or DMEK--the thinner the better? *Current Opinion in Ophthalmology*. 2009;**20**:299-307. DOI: 10.1097/ICU.0b013e32832b8d18
- [69] Talajic JC, Straiko MD, Terry MA. Descemet's stripping automated endothelial keratoplasty: Then and now. *International Ophthalmology Clinics*. 2013;**53**:1-20. DOI: 10.1097/IIO.0b013e32827eb6ba
- [70] Terry MA, Straiko MD, Veldman PB, Talajic JC, VanZyl C, Sales CS, et al. Standardized DMEK technique: Reducing complications using Prestripped tissue, novel glass injector, and sulfur hexafluoride (SF₆) gas. *Cornea*. 2015;**34**:845-852. DOI: 10.1097/ICO.0000000000000479
- [71] Birbal RS, Sikder S, Lie JT, Groeneveld-van Beek EA, Oellerich S, Melles GRJ. Donor tissue preparation for descemet membrane endothelial keratoplasty: An updated review. *Cornea*. 2018;**37**:128-135. DOI: 10.1097/ICO.0000000000001368
- [72] Kymionis GD, Yoo SH, Diakonis VF, Grentzelos MA, Naoumide I, Pallikaris IG. Automated donor tissue preparation for descemet membrane automated endothelial keratoplasty (DMAEK): An experimental study. *Ophthalmic Surgery, Lasers & Imaging*. 2011;**42**:158-161. DOI: 10.3928/15428877-20101223-01
- [73] Pereira Cda R, Guerra FP, Price FW Jr, Price MO. Descemet's membrane automated endothelial keratoplasty (DMAEK): Visual outcomes and visual quality. *The British Journal of Ophthalmology*. 2011;**95**:951-954. DOI: 10.1136/bjo.2010.191494
- [74] Green M, Wilkins MR. Comparison of early surgical experience and visual outcomes of DSAEK and DMEK. *Cornea*. 2015;**34**:1341-1344. DOI: 10.1097/ICO.0000000000000590
- [75] Hamzaoglu EC, Straiko MD, Mayko ZM, Sales CS, Terry MA. The first 100 eyes of standardized Descemet stripping automated endothelial Keratoplasty versus standardized Descemet membrane endothelial Keratoplasty. *Ophthalmology*. 2015;**122**:2193-2199. DOI: 10.1016/j.optha.2015.07.003

- [76] Maier AK, Gundlach E, Gonnermann J, Klamann MK, Bertelmann E, Rieck PW, et al. Retrospective contralateral study comparing Descemet membrane endothelial keratoplasty with Descemet stripping automated endothelial keratoplasty. *Eye (London, England)*. 2015;**29**:327-332. DOI: 10.1038/eye.2014.280
- [77] Tourtas T, Laaser K, Bachmann BO, Cursiefen C, Kruse FE. Descemet membrane endothelial keratoplasty versus descemet stripping automated endothelial keratoplasty. *American Journal of Ophthalmology*. 2012;**153**:1082-1090 e1082. DOI: 10.1016/j.ajo.2011.12.012
- [78] Thiel MA, Bochmann F, Schmittinger-Zirm A, Banninger PB, Schmid MK, Kaufmann C. Complications of descemet stripping automated endothelial keratoplasty (DSAEK). *Der Ophthalmologe*. 2015;**112**:969-973. DOI: 10.1007/s00347-015-0166-8
- [79] Gorovoy MS. DMEK complications. *Cornea*. 2014;**33**:101-104. DOI: 10.1097/ICO.0000000000000023
- [80] Straiko MD, Terry MA, Shamie N. Descemet stripping automated endothelial keratoplasty under failed penetrating keratoplasty: A surgical strategy to minimize complications. *American Journal of Ophthalmology*. 2011;**151**:233-237 e232. DOI: 10.1016/j.ajo.2010.08.017
- [81] Pavlovic I, Shajari M, Herrmann E, Schmack I, Lencova A, Kohnen T. Meta-analysis of postoperative outcome parameters comparing Descemet membrane endothelial Keratoplasty versus Descemet stripping automated endothelial Keratoplasty. *Cornea*. 2017;**36**:1445-1451. DOI: 10.1097/ICO.0000000000001384
- [82] Morishige N, Chikama T, Yamada N, Takahashi N, Morita Y, Nishida T, et al. Effect of preoperative duration of stromal edema in bullous keratopathy on early visual acuity after endothelial keratoplasty. *Journal of Cataract and Refractive Surgery*. 2012;**38**:303-308. DOI: 10.1016/j.jcrs.2011.08.032
- [83] Morishige N, Yamada N, Teranishi S, Chikama T, Nishida T, Takahara A. Detection of subepithelial fibrosis associated with corneal stromal edema by second harmonic generation imaging microscopy. *Investigative Ophthalmology & Visual Science*. 2009;**50**:3145-3150. DOI: 10.1167/iovs.08-3309
- [84] Ljubimov AV, Burgeson RE, Butkowski RJ, Couchman JR, Wu RR, Ninomiya Y, et al. Extracellular matrix alterations in human corneas with bullous keratopathy. *Investigative Ophthalmology & Visual Science*. 1996;**37**:997-1007
- [85] Turnbull AM, Tsatsos M, Hossain PN, Anderson DF. Determinants of visual quality after endothelial keratoplasty. *Survey of Ophthalmology*. 2016;**61**:257-271. DOI: 10.1016/j.survophthal.2015.12.006
- [86] Morishige N, Nomi N, Morita Y, Nishida T. Immunohistofluorescence analysis of myofibroblast transdifferentiation in human corneas with bullous keratopathy. *Cornea*. 2011;**30**:1129-1134. DOI: 10.1097/ICO.0b013e318213798d
- [87] Chaurasia S, Price MO, McKee Y, Price FW Jr. Descemet membrane endothelial keratoplasty combined with epithelial debridement and mitomycin-C application for fuchs

dystrophy with preoperative subepithelial fibrosis or anterior basement membrane dystrophy. *Cornea*. 2014;**33**:335-339. DOI: 10.1097/ICO.0000000000000078

- [88] Agarwal A, Narang P, Kumar DA, Agarwal A. Young donor-graft assisted endothelial keratoplasty (PDEK/DMEK) with epithelial debridement for chronic pseudophakic bullous keratopathy. *Canadian Journal of Ophthalmology*. 2017;**52**:519-526. DOI: 10.1016/j.jcjo.2017.03.004
- [89] Ide T, Wang J, Tao A, Leng T, Kymionis GD, O'Brien TP, et al. Intraoperative use of three-dimensional spectral-domain optical coherence tomography. *Ophthalmic Surgery, Lasers & Imaging*. 2010;**41**:250-254. DOI: 10.3928/15428877-20100303-15
- [90] Knecht PB, Kaufmann C, Menke MN, Watson SL, Bosch MM. Use of intraoperative fourier-domain anterior segment optical coherence tomography during descemet stripping endothelial keratoplasty. *American Journal of Ophthalmology*. 2010;**150**:360-365 e362. DOI: 10.1016/j.ajo.2010.04.017
- [91] Juthani VV, Goshe JM, Srivastava SK, Ehlers JP. Association between transient interface fluid on intraoperative OCT and textural interface opacity after DSAEK surgery in the PIONEER study. *Cornea*. 2014;**33**:887-892. DOI: 10.1097/ICO.0000000000000209
- [92] Hallahan KM, Cost B, Goshe JM, Dupps WJ Jr, Srivastava SK, Ehlers JP. Intraoperative interface fluid dynamics and clinical outcomes for intraoperative optical coherence tomography-assisted descemet stripping automated endothelial keratoplasty from the PIONEER study. *American Journal of Ophthalmology*. 2017;**173**:16-22. DOI: 10.1016/j.ajo.2016.09.028
- [93] Kobayashi A, Yokogawa H, Mori N, Sugiyama K. Visualization of pre-cut DSAEK and pre-stripped DMEK donor corneas by intraoperative optical coherence tomography using the RESCAN 700. *BMC Ophthalmology*. 2016;**16**:135. DOI: 10.1186/s12886-016-0308-z
- [94] Siebelmann S, Bachmann B, Lappas A, Dietlein T, Hermann M, Roters S, et al. Intraoperative optical coherence tomography in corneal and glaucoma surgical procedures. *Der Ophthalmologe*. 2016;**113**:646-650. DOI: 10.1007/s00347-016-0320-y
- [95] Pasricha ND, Shieh C, Carrasco-Zevallos OM, Keller B, Izatt JA, Toth CA, et al. Real-time microscope-integrated OCT to improve visualization in DSAEK for advanced bullous keratopathy. *Cornea*. 2015;**34**:1606-1610. DOI: 10.1097/ICO.0000000000000661
- [96] Saad A, Guilbert E, Grise-Dulac A, Sabatier P, Gatinel D. Intraoperative OCT-assisted DMEK: 14 consecutive cases. *Cornea*. 2015;**34**:802-807. DOI: 10.1097/ICO.0000000000000462
- [97] Steven P, Le Blanc C, Velten K, Lankenau E, Krug M, Oelckers S, et al. Optimizing descemet membrane endothelial keratoplasty using intraoperative optical coherence tomography. *JAMA Ophthalmology*. 2013;**131**:1135-1142. DOI: 10.1001/jamaophthalmol.2013.4672
- [98] Cost B, Goshe JM, Srivastava S, Ehlers JP. Intraoperative optical coherence tomography-assisted descemet membrane endothelial keratoplasty in the DISCOVER study. *American Journal of Ophthalmology*. 2015;**160**:430-437. DOI: 10.1016/j.ajo.2015.05.020

- [99] Tarnawska D, Wylegala E. Monitoring cornea and graft morphometric dynamics after descemet stripping and endothelial keratoplasty with anterior segment optical coherence tomography. *Cornea*. 2010;**29**:272-277. DOI: 10.1097/ICO.0b013e3181b61496
- [100] Shih CY, Ritterband DC, Palmiero PM, Seedor JA, Papachristou G, Harizman N, et al. The use of postoperative slit-lamp optical coherence tomography to predict primary failure in descemet stripping automated endothelial keratoplasty. *American Journal of Ophthalmology*. 2009;**147**:796-800, 800 e791. DOI: 10.1016/j.ajo.2008.12.015
- [101] Suh LH, Shousha MA, Ventura RU, Kieval JZ, Perez VL, Wang J, et al. Epithelial ingrowth after Descemet stripping automated endothelial keratoplasty: Description of cases and assessment with anterior segment optical coherence tomography. *Cornea*. 2011;**30**:528-534. DOI: 10.1097/ICO.0b013e3181fb8149
- [102] Kymionis GD, Suh LH, Dubovy SR, Yoo SH. Diagnosis of residual Descemet's membrane after Descemet's stripping endothelial keratoplasty with anterior segment optical coherence tomography. *Journal of Cataract and Refractive Surgery*. 2007;**33**:1322-1324. DOI: 10.1016/j.jcrs.2007.03.029
- [103] Fernandez Lopez E, Baydoun L, Gerber-Hollbach N, Dapena I, Liarakos VS, Ham L, et al. Rebubbling techniques for graft detachment after Descemet membrane endothelial Keratoplasty. *Cornea*. 2016;**35**:759-764. DOI: 10.1097/ICO.0000000000000829
- [104] Werkmeister RM, Sapeta S, Schmidl D, Garhofer G, Schmidinger G, Aranha Dos Santos V, et al. Ultrahigh-resolution OCT imaging of the human cornea. *Biomedical Optics Express*. 2017;**8**:1221-1239. DOI: 10.1364/BOE.8.001221
- [105] Leon P, Parekh M, Nahum Y, Mimouni M, Giannaccare G, Sapigni L, et al. Factors associated with early graft detachment in primary Descemet membrane endothelial Keratoplasty. *American Journal of Ophthalmology*. 2018;**187**:117-124. DOI: 10.1016/j.ajo.2017.12.014
- [106] Satue M, Idoipe M, Sanchez-Perez A, Liarakos VS, Mateo A, Garcia-Martin E, et al. Evaluation of early graft detachment after Descemet membrane endothelial Keratoplasty using new swept-source optical coherence tomography. *Cornea*. 2016;**35**:1279-1284. DOI: 10.1097/ICO.0000000000000925
- [107] Ang M, Dubis AM, Wilkins MR. Descemet membrane endothelial keratoplasty: Intraoperative and postoperative imaging spectral-domain optical coherence tomography. *Case Reports in Ophthalmological Medicine*. 2015;**2015**:506251. DOI: 10.1155/2015/506251