

We are IntechOpen, the world's leading publisher of Open Access books Built by scientists, for scientists

6,900

Open access books available

186,000

International authors and editors

200M

Downloads

Our authors are among the

154

Countries delivered to

TOP 1%

most cited scientists

12.2%

Contributors from top 500 universities



WEB OF SCIENCE™

Selection of our books indexed in the Book Citation Index
in Web of Science™ Core Collection (BKCI)

Interested in publishing with us?
Contact book.department@intechopen.com

Numbers displayed above are based on latest data collected.
For more information visit www.intechopen.com



Management of Placenta Accreta in Pregnancy with Placenta Previa

Kenji Tanimura and Hideto Yamada

Additional information is available at the end of the chapter

<http://dx.doi.org/10.5772/intechopen.79185>

Abstract

Placenta accreta is a life-threatening obstetrical condition. Prenatal prediction of placenta accreta helps to minimize clinical complications. Placenta previa is one of the most important factors associated with placenta accreta. In our prospective cohort study, ultrasound finding of loss of the retroplacental hypoechoic clear zone was found to be a single predictor of placenta accreta in women with placenta previa (odds ratio, 15.6; 95% confidence interval, 2.1–114.6; $p < 0.01$). In addition, we have devised a novel scoring system for predicting placenta accreta in pregnancy with placenta previa, yielding 91.3% sensitivity, 98.0% specificity, 87.5% positive predictive value, and 98.7% negative predictive value. Planned preterm cesarean hysterectomy with the placenta left in situ is generally recommended for women with suspicion of placenta accreta. If the women have a desire for future fertility, conservative approach may be considered.

Keywords: cesarean section, placenta accreta, prenatal diagnosis, placenta previa, scoring system

1. Introduction

Placenta accreta is a life-threatening obstetrical condition. Clinical complications of placenta accreta involve massive hemorrhage, damage to adjacent organs, cesarean hysterectomy, and maternal death. Placenta previa is one of the most important risk factors for placenta accreta [1]. Prenatal prediction of placenta accreta helps to minimize clinical complications by enabling obstetricians to plan for resources that may be required during cesarean delivery,

including obstetric anesthesia, appropriate surgical expertise, available blood products, and interventional radiology for uterine artery embolization [2, 3]. Therefore, accurate prenatal prediction of placenta accreta in women with placenta previa is important.

This review will focus on the recent knowledge regarding the prenatal diagnosis and management of placenta accreta in women with placenta previa.

2. The prenatal prediction of placenta accreta in women with placenta previa

2.1. Ultrasonography

It has been reported that ultrasonography is the most useful method for diagnosing placenta accreta. Previous studies have demonstrated that ultrasound (US) findings involving the presence of placental lacunae (PL) [4], an anterior myometrial thickening [5], loss of the retroplacental hypoechoic clear zone (LCZ) [6], anomalies of the bladder-myometrium interface [7], and the presence of turbulent blood flow (TBF) in the arteries radiating from the placenta toward the uterine serosa, detected by color Doppler [8] are associated with placenta accreta. However, these previous results were based on retrospective studies for pregnant women with and without placenta previa.

In the prospective study, we aimed to determine more effective imaging for predicting placenta accreta in women with placenta previa using stepwise logistic regression analyses [9]. Univariate logistic regression analyses demonstrated that US findings of anterior placental location (odds ratio [OR], 5.1; 95% confidence interval [CI], 1.2–20.5; $p < 0.05$), grade 2 or higher PL (PL \geq G2) (OR, 17.0; 95%CI, 4.0–71.1; $p < 0.01$), LCZ (OR, 49.4; 95% CI, 8.5–2862; $p < 0.01$), and magnetic resonance imaging (MRI) (OR, 24.6; 95% CI, 4.7–129.2; $p < 0.01$) were associated with placenta accreta. Multivariable analyses revealed that LCZ (OR, 15.6; 95%CI, 2.1–114.6; $p < 0.01$) was a single significant predictor of placenta accreta in women with placenta previa [9]. In this study, LCZ yielded 86.7% sensitivity, 88.4% specificity, 72.2% positive predictive value (PPV), and 95.0% negative predictive value (NPV) for the prediction of placenta accreta in women with placenta previa. In contrast, a previous study found that LCZ had low PPV for predicting placenta accreta, because LCZ is often observed among women with anterior placental location during normal pregnancy [10]. However, the previous study enrolled women who had anterior placental location and a history of cesarean section (CS); if the subjects were limited to women with placenta previa, diagnostic accuracy of LCZ might be improved.

Recently, we demonstrated that a novel US finding referred to as an “irregular sign” might be useful for predicting placenta accreta in women with placenta previa [11]. The irregular sign is defined as the irregularity of the border between the placenta and the myometrium around internal uterine os observed by transvaginal ultrasonography (**Figure 1**). The presence of irregular sign yielded 56.5% sensitivity, 99.3% specificity, 92.9% PPV, and 93.8% NPV for predicting placenta accreta in women with placenta previa [11].

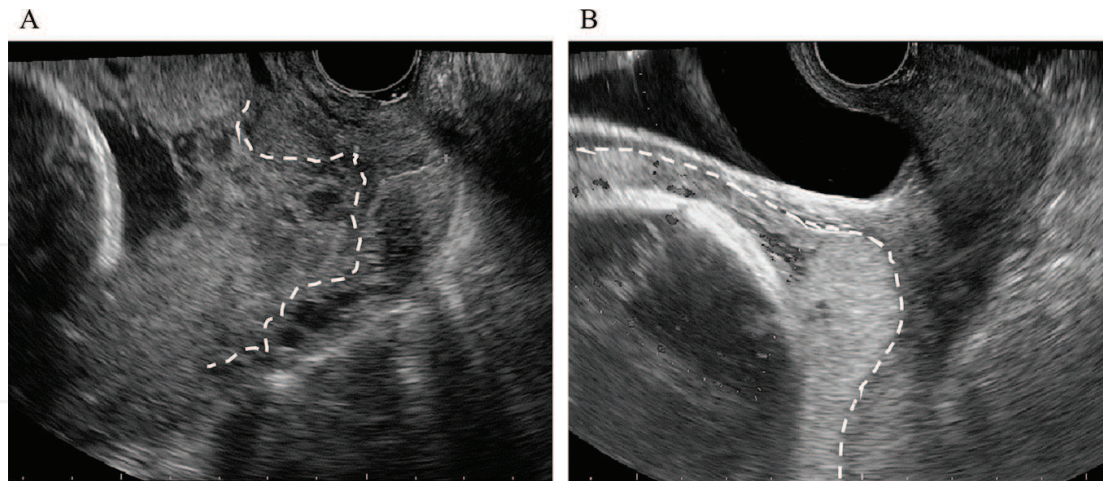


Figure 1. (A) The presence of the irregular sign in a case with placenta accreta. (B) The absence of the irregular sign in a case without placenta accreta. Dashed white marks indicate the border between the placenta and myometrium around internal uterine os [11].

2.2. Magnetic resonance imaging

Some investigators suggested that MRI was a useful tool for diagnosing placenta accreta prenatally [12, 13]. MRI findings suggestive of placenta accreta included indistinctness or the absence of myometrial wall at the placental site, loss of the thin T2 dark uteroplacental interface, a nodular interface between the placenta and the uterus, a mass effect of the placenta on the uterus causing uterine outer bulge, heterogeneous signal intensity within the placenta, dark intraplacental bands on T2-weighted images, and abnormal dilated venous lakes within the placenta [13–15]. MRI provided advantages in diagnosing placenta accreta in women who had posterior placental location [16]. We found that MRI was selected as a significant finding in predicting placenta accreta in pregnant women with placenta previa by univariate analyses in the prospective study (OR, 24.6; 95% CI, 4.7–129.2; $p < 0.01$) [9].

However, other investigators claimed that MRI was more expensive and invasive examination than US; therefore, US should be the diagnostic modality of first choice for placenta accreta, and MRI was not always necessary [17]. Dynamic contrast-enhanced MRI with gadolinium (Gd) is not recommended at any time during pregnancy, because the use of Gd increases the risk of a broad set of rheumatological, inflammatory, or infiltrative skin conditions and of stillbirth or neonatal death [18].

2.3. Diagnostic scoring systems

Diagnostic scoring systems may be more useful than a single US finding for predicting placenta accreta in women with a history of previous CS, placenta previa, or low-lying placenta [19–21]. These scoring systems include several US findings suggestive of placenta accreta, the presence of placenta previa, and the number of prior CS. Optimal cut-off values of these scores determined in the retrospective or prospective studies yielded 72.0–94.2% sensitivity, 52.5–85.0% specificity, 63.4–70.0% PPV, and 86.0–100% NPV for the prediction of placenta accreta [19–21].

We devised a novel scoring system for predicting placenta accreta in women with placenta previa, and in a prospective cohort study evaluated the diagnostic efficacy of this scoring system named the placenta previa with adherent placenta (PPAP) score [11]. The PPAP score is composed of two categories: (1) past history of CS, surgical abortion, and/or uterine surgery and (2) US and MRI findings. Each category is graded as 0, 1, 2, or 4 points, yielding a total score between 0 and 24 (**Table 1**).

Women with placenta previa who had PPAP score ≥ 8 were considered to be at a high risk for placenta accreta. The PPAP score yielded 91.3% sensitivity, 98.0% specificity, 87.5% PPV, and 98.7% NPV for predicting placenta accreta in women with placenta previa [11]. However, the

Variables		Level of variable	Score
Past history			
Number of previous CS		0	0
		1	2
		≥ 2	4
Number of previous surgical abortion		<3	0
		≥ 3	2
Other uterine surgery		No	0
		Present	2
		Placenta is located on the uterine scar	4
Imaging examination			
USG	Grade of placental lacunae	0	0
		1	2
		≥ 2	4
	Loss of clear zone	Absent	0
		Equivocal	2
		Present	4
	Turbulent blood flow	Absent	0
		Equivocal	1
		Present	2
	Irregular sign	Absent	0
		Present	2
MRI	Suspicious of placenta accreta	No	0
		Yes	2

PPAP, placenta previa with adherent placenta; CS, cesarean section; USG, ultrasonography; and MRI, magnetic resonance imaging.

Table 1. The variables and scores in the PPAP scoring system.

PPAP scoring failed to predict two women with placenta accreta. One woman had a history of myomectomy and PPAP score of 6 and another had a past history of myometrium resection for adenomyosis and PPAP score of 4. The presence of a history of myomectomy and myometrium resection for adenomyosis seems to increase the risk for placenta accreta in women who had PPAP score < 8. Special attention should be paid to the risk of placenta accreta regardless of US or MRI findings.

3. The management of placenta accreta in women with placenta previa

All pregnant women with placenta previa suspected to have placenta accreta should be managed at specialized tertiary centers [22]. Their deliveries should be performed by an experienced medical team consisted of obstetric surgeons, urologists, general surgeons, and gynecologic oncologists [23]. Planned cesarean hysterectomy decreases the morbidity and mortality rates in women complicated by placenta accreta [3]. The timing of delivery in such women must be individualized; however, a recent study suggested that delivery at 34 weeks of gestation (GW) in stable women with placenta accreta optimized the outcomes of both mothers and neonates [24].

The anesthesiologists should assess which anesthetic techniques are used before delivery. Both general and regional anesthetic techniques are available, and the decision of which type of technique to be used should be made on an individual basis [23]. Preoperative cystoscopy with placement of ureteral stents may help prevent accidental urinary tract injury. In addition, sufficient amount of blood products should be available in the operating room.

Planned preterm cesarean hysterectomy with the placenta left in situ is generally recommended for women with suspicion of placenta accreta, because forced removal of the placenta causes massive hemorrhage. Midline vertical incision may be considered because it provides sufficient exposure if hysterectomy is needed. CS using transverse uterine fundal incision method is often used to avoid the placenta and allow delivery of the infant.

Hysterectomy is performed in the usual fashion. In some cases with anterior placenta accreta, especially in cases with placenta percreta, partial resection of the bladder wall is necessary. On the other hand, if the women have a strong desire for future fertility, conservative approach, i.e. leaving the placenta in situ, may be considered. However, a review, which summarized the conservative management of 60 women with placenta accreta, showed that infection occurred in 11 of the 60 women (18%), bleeding in 21 (35%), and disseminated intravascular coagulation in 4 (7%) [25]. Therefore, this conservative approach should be considered only when women are willing to accept the risks involved in this approach.

There has been lack of sufficient evidence for beneficial effects of prophylactic catheter placement for balloon occlusion or artery embolization [26–28] as well as treatment with methotrexate [29–31]. Therefore, a firm recommendation on the use of these procedures cannot be made [23, 31]. It is difficult to establish evidence-based management strategies for placenta accreta in pregnancy with placenta previa. Therefore, clinicians should manage these women by suitable approaches in each medical institution.

Figure 2 shows an algorithm used in the Kobe University Hospital for the management of pregnant women with placenta previa. All pregnant women with placenta previa receive workup for placenta accreta in inpatient or outpatient care. If women have bleeding, they are hospitalized immediately and receive intravenous administration of tocolytic agents such as magnesium sulfate or β -stimulant. Even if they do not have bleeding, they are hospitalized at 32–34GW. Women have a PPAP score ≥ 8 , who are suspected of having placenta accreta, receive both preoperative internal iliac artery occlusion balloon catheters placement and elective CS at 35–37GW.

Figure 3 shows a flow algorithm used in the Kobe University Hospital for the preoperative preparation and operative procedures for women with suspicion of placenta accreta. Women with placenta previa had a PPAP score ≥ 8 , who were suspected of having placenta accreta, received preoperative internal iliac artery occlusion balloon catheters placement. After fetal delivery by a CS using transverse uterine fundal incision method, the internal iliac artery occlusion balloon catheters were inflated. After occlusion of the artery, local injection of oxytocin into the myometrium and uterine massage were performed to induce spontaneous placental separation. If placental separation did not occur at all and women did not have a desire for future fertility, cesarean hysterectomy was performed. When the placenta was not partially separated, partial resection of uterine wall or removal of placenta using advanced bipolar was performed.

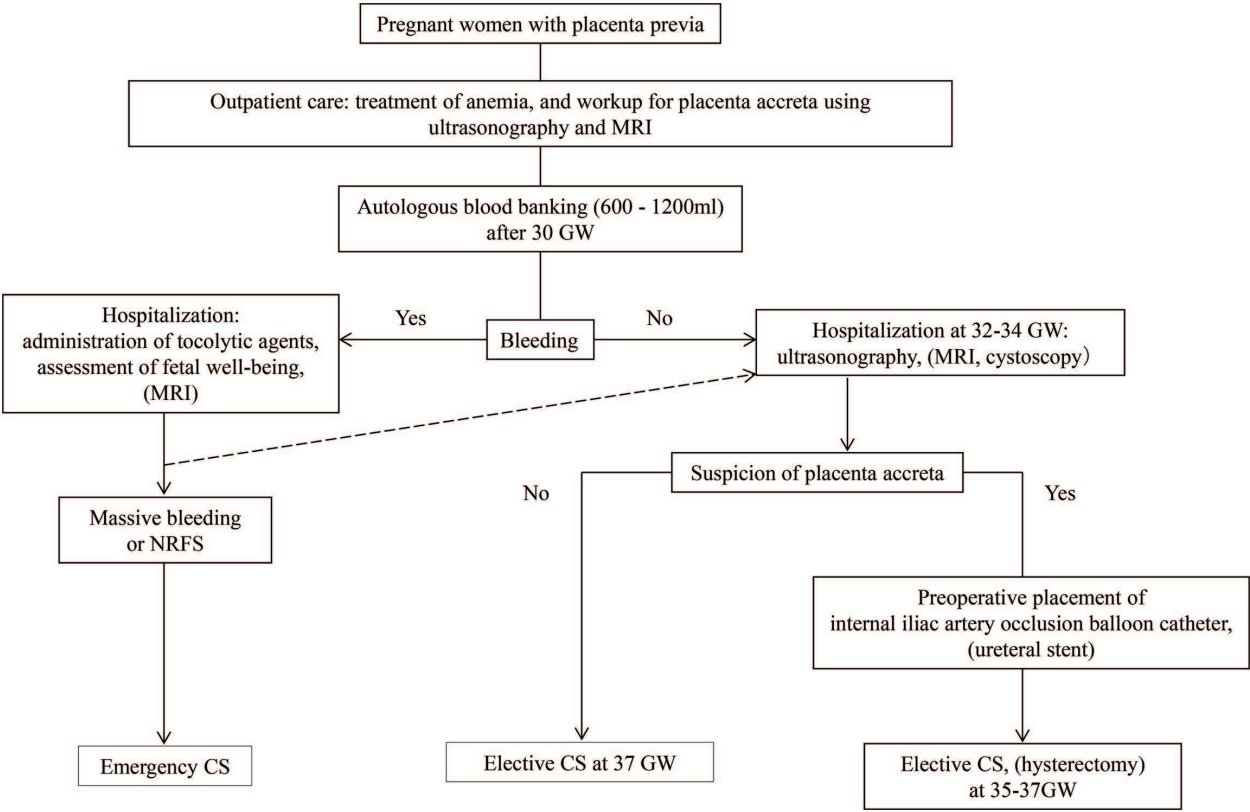


Figure 2. An algorithm for the management of pregnant women with placenta previa. MRI, magnetic resonance imaging; GW, weeks of gestation; NRFS, non-reassuring fetal status; and CS, cesarean section.

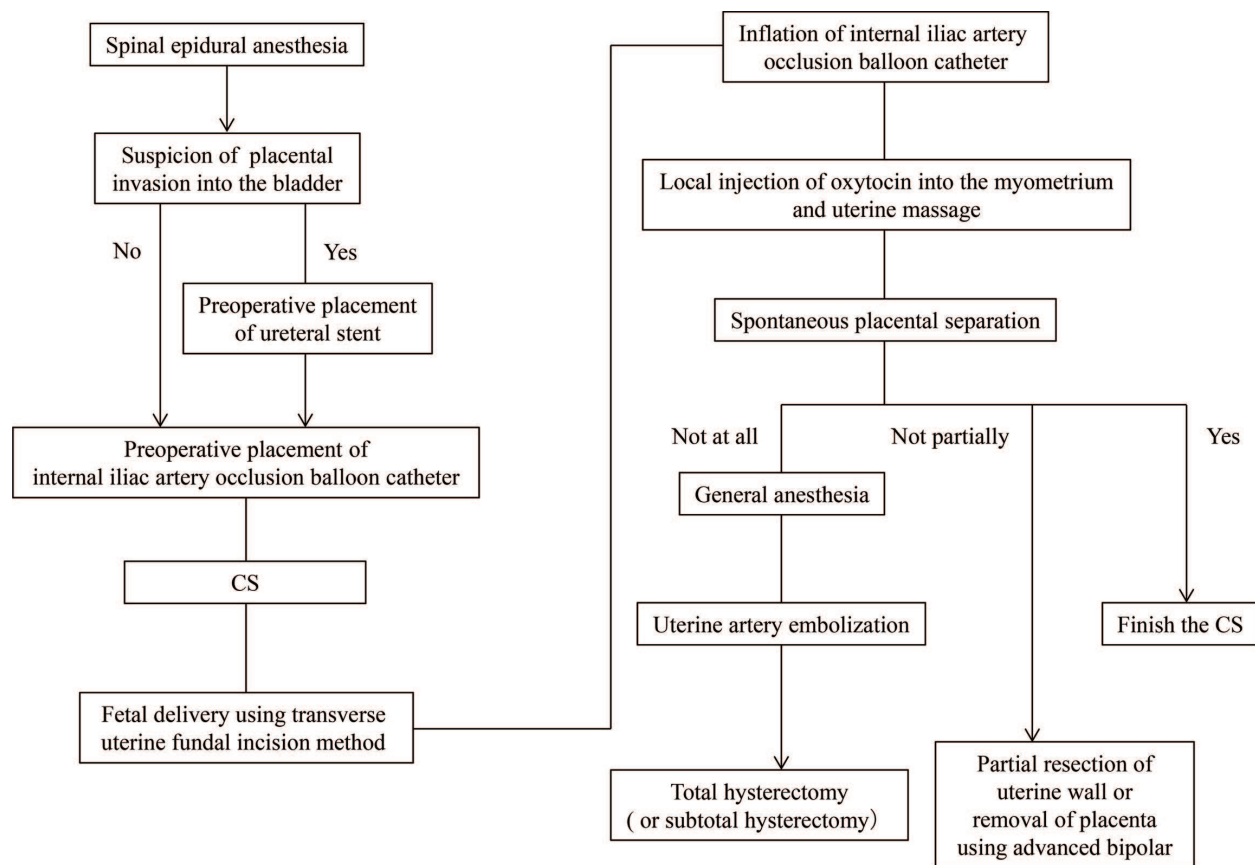


Figure 3. A flow algorithm for the preoperative preparation and operative procedures against women with suspicion of placenta accreta. CS, cesarean section.

Author details

Kenji Tanimura and Hideto Yamada*

*Address all correspondence to: yhideto@med.kobe-u.ac.jp

Department of Obstetrics and Gynecology, Kobe University Graduate School of Medicine, Kobe, Japan

References

- [1] Wu S, Kocherginsky M, Hibbard JU. Abnormal placentation: Twenty-year analysis. *American Journal of Obstetrics and Gynecology*. 2005;**192**:1458-1461
- [2] Angstmann T, Gard G, Harrington T, Ward E, Thomson A, Giles W. Surgical management of placenta accreta: A cohort series and suggested approach. *American Journal of Obstetrics and Gynecology*. 2010;**202**:38 e31-38 e39

- [3] Eller AG, Porter TF, Soisson P, Silver RM. Optimal management strategies for placenta accreta. *BJOG: An International Journal of Obstetrics and Gynaecology*. 2009;**116**:648-654
- [4] Yang JI, Lim YK, Kim HS, Chang KH, Lee JP, Ryu HS. Sonographic findings of placental lacunae and the prediction of adherent placenta in women with placenta previa totalis and prior cesarean section. *Ultrasound in Obstetrics and Gynecology: The Official journal of the International Society of Ultrasound in Obstetrics and Gynecology*. 2006;**28**:178-182
- [5] Hudon L, Belfort MA, Broome DR. Diagnosis and management of placenta percreta: A review. *Obstetrical and Gynecological Survey*. 1998;**53**:509-517
- [6] Pasto ME, Kurtz AB, Rifkin MD, Cole-Beuglet C, Wapner RJ, Goldberg BB. Ultrasonographic findings in placenta increta. *Journal of Ultrasound in Medicine: Official Journal of the American Institute of Ultrasound in Medicine*. 1983;**2**:155-159
- [7] Finberg HJ, Williams JW. Placenta accreta: Prospective sonographic diagnosis in patients with placenta previa and prior cesarean section. *Journal of Ultrasound in Medicine: Official Journal of the American Institute of Ultrasound in Medicine*. 1992;**11**:333-343
- [8] Taipale P, Orden MR, Berg M, Manninen H, Alafuzoff I. Prenatal diagnosis of placenta accreta and percreta with ultrasonography, color Doppler, and magnetic resonance imaging. *Obstetrics and Gynecology*. 2004;**104**:537-540
- [9] Tanimura K, Yamasaki Y, Ebina Y, Deguchi M, Ueno Y, Kitajima K, Yamada H. Prediction of adherent placenta in pregnancy with placenta previa using ultrasonography and magnetic resonance imaging. *European Journal of Obstetrics, Gynecology, and Reproductive Biology*. 2015;**187**:41-44
- [10] McGahan JP, Phillips HE, Reid MH. The anechoic retroplacental area: A pitfall in diagnosis of placental–endometrial abnormalities during pregnancy. *Radiology*. 1980;**134**:475-478
- [11] Tanimura K, Morizane M, Deguchi M, Ebina Y, Tanaka U, Ueno Y, Kitajima K, Maeda T, Sugimura K, Yamada H. A novel scoring system for predicting adherent placenta in women with placenta previa. *Placenta*. 2018;**64**:27-33
- [12] Thorp JM Jr, Councell RB, Sandridge DA, Wiest HH. Antepartum diagnosis of placenta previa percreta by magnetic resonance imaging. *Obstetrics and Gynecology*. 1992;**80**:506-508
- [13] Ueno Y, Kitajima K, Kawakami F, Maeda T, Suenaga Y, Takahashi S, Matsuoka S, Tanimura K, Yamada H, Ohno Y, Sugimura K. Novel MRI finding for diagnosis of invasive placenta praevia: Evaluation of findings for 65 patients using clinical and histopathological correlations. *European Radiology*. 2014;**24**:881-888
- [14] Lax A, Prince MR, Mennitt KW, Schwebach JR, Budorick NE. The value of specific MRI features in the evaluation of suspected placental invasion. *Magnetic Resonance Imaging*. 2007;**25**:87-93
- [15] Derman AY, Nikac V, Haberman S, Zelenko N, Opsha O, Flyer M. MRI of placenta accreta: A new imaging perspective. *American Journal of Roentgenology*. 2011;**197**:1514-1521

- [16] Levine D, Hulka CA, Ludmir J, Li W, Edelman RR. Placenta accreta: Evaluation with color Doppler US, power Doppler US, and MR imaging. *Radiology*. 1997;**205**:773-776
- [17] Berkley EM, Abuhamad AZ. Prenatal diagnosis of placenta accreta: Is sonography all we need? *Journal of Ultrasound in Medicine: Official Journal of the American institute of Ultrasound in Medicine*. 2013;**32**:1345-1350
- [18] Ray JG, Vermeulen MJ, Bharatha A, Montanera WJ, Park AL. Association between MRI exposure during pregnancy and fetal and childhood outcomes. *The Journal of the American Medical Association*. 2016;**316**:952-961
- [19] Rac MW, Dashe JS, Wells CE, Moschos E, McIntire DD, Twickler DM. Ultrasound predictors of placental invasion: The placenta accreta index. *American Journal of Obstetrics and Gynecology*. 2015;**212**:343 e341-347
- [20] Weiniger CF, Einav S, Deutsch L, Ginosar Y, Ezra Y, Eid L. Outcomes of prospectively-collected consecutive cases of antenatal-suspected placenta accreta. *International Journal of Obstetric Anesthesia*. 2013;**22**:273-279
- [21] Tovbin J, Melcer Y, Shor S, Pekar-Zlotin M, Mendlovic S, Svirsky R, Maymon R. Prediction of morbidly adherent placenta using a scoring system. *Ultrasound in Obstetrics and Gynecology: The Official Journal of the International Society of Ultrasound in Obstetrics and Gynecology*. 2016;**48**:504-510
- [22] Eller AG, Bennett MA, Sharshiner M, Masheter C, Soisson AP, Dodson M, Silver RM. Maternal morbidity in cases of placenta accreta managed by a multidisciplinary care team compared with standard obstetric care. *Obstetrics and Gynecology*. 2011;**117**:331-337
- [23] Committee on Obstetric Practice. Committee opinion no. 529: Placenta accreta. *Obstetrics and Gynecology*. 2012;**120**:207-211
- [24] Robinson BK, Grobman WA. Effectiveness of timing strategies for delivery of individuals with placenta previa and accreta. *Obstetrics and Gynecology*. 2010;**116**:835-842
- [25] Timmermans S, van Hof AC, Duvekot JJ. Conservative management of abnormally invasive placentation. *Obstetrical and Gynecological Survey*. 2007;**62**:529-539
- [26] Dubois J, Garel L, Grignon A, Lemay M, Leduc L. Placenta percreta: Balloon occlusion and embolization of the internal iliac arteries to reduce intraoperative blood losses. *American Journal of Obstetrics and Gynecology*. 1997;**176**:723-726
- [27] Ojala K, Perala J, Kariniemi J, Ranta P, Raudaskoski T, Tekay A. Arterial embolization and prophylactic catheterization for the treatment for severe obstetric hemorrhage. *Acta Obstetrica et Gynecologica Scandinavica*. 2005;**84**:1075-1080
- [28] Bodner LJ, Noshier JL, Gribbin C, Siegel RL, Beale S, Scorza W. Balloon-assisted occlusion of the internal iliac arteries in patients with placenta accreta/percreta. *Cardiovascular and Interventional Radiology*. 2006;**29**:354-361
- [29] Mussalli GM, Shah J, Berck DJ, Elimian A, Tejani N, Manning FA. Placenta accreta and methotrexate therapy: Three case reports. *Journal of Perinatology*. 2000;**20**:331-334

- [30] Butt K, Gagnon A, Delisle MF. Failure of methotrexate and internal iliac balloon catheterization to manage placenta percreta. *Obstetrics and Gynecology*. 2002;**99**:981-982
- [31] Royal College of Obstetricians and Gynecologists. Placenta praevia, placenta praevia accreta and vasa previa: diagnosis and management. Green-Top Guideline No. 27. 2011. pp. e1-e26

IntechOpen

IntechOpen