

We are IntechOpen, the world's leading publisher of Open Access books Built by scientists, for scientists

6,900

Open access books available

186,000

International authors and editors

200M

Downloads

Our authors are among the

154

Countries delivered to

TOP 1%

most cited scientists

12.2%

Contributors from top 500 universities



WEB OF SCIENCE™

Selection of our books indexed in the Book Citation Index
in Web of Science™ Core Collection (BKCI)

Interested in publishing with us?
Contact book.department@intechopen.com

Numbers displayed above are based on latest data collected.
For more information visit www.intechopen.com



Spectral Domain Optical Coherence Tomography in the Diagnosis and Monitoring of Diabetic Macular Edema

Simona Delia Nicoară

Additional information is available at the end of the chapter

<http://dx.doi.org/10.5772/intechopen.78681>

Abstract

Currently, spectral domain optical coherence tomography (SD-OCT) is a basic tool in diagnosing and monitoring diabetic macular edema (DME), which is the most frequent cause of visual impairment in the diabetic patients. OCT technology has changed the classification of DME from the traditional criteria. Macular thickness measured on OCT is considered an outcome measure to evaluate the structural and functional outcome of various therapeutic means used in DME. SD-OCT evaluates ultrastructural retinal parameters, such as the ellipsoid zone, photoreceptor outer segment length and quantifies the individual layers according to various algorithms. The aim is to present the way in which SD-OCT technology has changed our clinical practice during the last years, in diagnosing, classifying and treating DME and to illustrate its impact with practical cases.

Keywords: spectral domain-optical coherence tomography, diabetic macular edema, macular thickness, macular traction

1. Introduction

Currently, there are 400 million diabetics in the world and according to World Health Organization, by the year 2030 the population of diabetics will double [1, 2]. Diabetic retinopathy (DR) is the main cause of visual impairment within the working age population group [1, 2]. Quality of life is affected even if visual acuity decrease is mild/moderate. In the context of DR, diabetic macular edema (DME) is the most common cause of visual impairment, especially in type 2 diabetes. It is estimated that one out of four diabetics develops DME over a lifetime [1, 2].

OCT represented a breakthrough in the management of DME, both for its diagnosis and monitoring of treatment effects. OCT technology offers valuable quantitative data (macular thickness, extension of edema, macular volume) and qualitative ones (macular morphology, vitreo-macular interface) [3].

The advantages of OCT over other imaging modalities are as follows: its noninvasiveness, rapidity and safety profile [3, 4].

2. Theoretical consideration on OCT

The principle of tomography consists in the reconstruction of cross-sectional images of an object using its projections. The concept of OCT developed in 1990 and the first commercial version of OCT belongs to Carl-Zeiss in 1996. The first clinical application of OCT technology was in the field of ophthalmology. The obtained images reveal the optical properties of the scanned tissues and not the tissues themselves, and they are very similar to the histological sections.

There are two OCT methods: time domain (TD-OCT) and spectral domain (SD-OCT). The properties of the two methods are synthesized in **Table 1** [3, 4].

The most common application of OCT is the measure of macular thickness. With TD-OCT, macular thickness map is calculated from six radial scans crossing at the fovea from which result the medium macular thickness and the total macular volume. With SD-OCT, image resolution is significantly higher. Different landmarks are used to calculate macular thickness with TD-OCT and SD-OCT. With TD-OCT, photoreceptors external segments are not differentiated from the retinal pigmented epithelium (RPE) and are therefore excluded from

Property	TD-OCT	SD-OCT
Principle	Low-coherence interferometry	Fourier equation
Acquisition	An interferometer evaluates <i>sequentially</i> the back scattering of the light by the retinal structures	A spectrometer evaluates <i>simultaneously</i> the back scattering of the light by the retinal structures
Sampling	Point by point	All points simultaneously
Acquisition time	1–2 s	60 times faster
Target area	Six radial scans 20 μm wide and 6 mm long	Φ 6 mm = 65,000 scans
Acquisition rate	400 scans/s	25,000–52,000 scans/s
Display	2D	3D
Axial resolution	10–15 μ	3–7 μ

Table 1. Properties of TD-OCT and SD-OCT.

Device (company)	Axial resolution (μ)	Scans/s
Cirrus HD-OCT (Carl Zeiss Meditec)	5	27,000
Spectralis (Heidelberg Engineering)	7	40,000
RE Vue (Optovue)	5	26,000
3D OCT-1000	6	18,000
3D OCT-2000 (Topcon)		
Spectral OCT/SLO (OPKO/OTI)	5	27,000
SOCT Copernicus (Optopol)	6	25,000
SOCT Copernicus HR (Canon/Optopol Inc.)	3	50,000
SD-OCT (Bioptigen)	4	20,000
Retinascans RS 3000 (Nidek)	7	53,000

Table 2. SD-OCT devices used in ophthalmology.

the evaluation of macular thickness. SD-OCT allows photoreceptors external segments be differentiated from the retinal pigmented epithelium (RPE) and are included in the value of the macular thickness [3, 4].

Many SD-OCT devices are used in the clinical practice. Their axial resolutions and scanning speeds are presented in **Table 2**.

OCT and ultrasounds are complementary methods in assessing the vitreo-retinal interface. Ultrasound scans provide a more complete image of the vitreo-retinal interface, but with significantly lower resolution. OCT offers a high resolution image of a limited area. Since OCT uses light to acquire images, its use is limited by media opacities [5, 6].

OCT is a noninvasive, well-tolerated method, easy to understand and explain. It offers qualitative information on retinal thickness, and it is reliable and reproducible. OCT reveals the presence and extension of vitreo-macular traction (VMT) [5, 6].

OCT technology holds the promise for the unprecedented capability to describe and monitor the changes in retina geometry.

3. Normal OCT aspect of the macula

The normal retinal layers have different reflectivity on OCT scans. Thus, the nerve fibers and the retinal pigmented epithelium (RPE) display high reflectivity, the plexiform and the nuclear layers have intermediate reflectivity and the photoreceptors display low reflectivity [3, 4]. The most commonly scan algorithms used in the clinical practice are the line and the volume (cube). Retinal thickness is automatically measured by the use of device software. The

distance between the vitreo-retinal interface and the anterior surface of the RPE is generally comprised between 200 and 275 μm ; the foveal depression ranges from 170 to 190 μm and the thickness of the peripheral retina is between 220 and 280 μm [5].

4. Macular edema

Macular edema is the main pathologic feature of diabetic maculopathy. According to ETDRS, it is defined as any detectable retinal thickening due to fluid accumulation. It may be localized in a sector of the macular region (focal) or it may be diffused. Persistent macular edema leads to the necrosis of Muller cells with subsequent formation of cystoid cavities localized mainly in the outer retinal layers (Henle's fiber, external plexiform) and sometimes in the inner plexiform layer too. In more advanced stages, the cavities may coalesce centrally forming a large hyporeflective cavity that accounts for the significant increase of foveal thickness. By consequence, beside increase of macular thickness (which is the most important OCT sign) in DME appear: large intraretinal spaces of reduced reflectivity, loss of the normal layered retinal structure and flattening of the central foveal depression. Sometimes fluid can be seen under the neurosensory retina. Hard exudates and hemorrhages are typical landmarks for DR and they appear on OCT images as small hyperreflective deposits with posterior shadowing [6].

The cysts that develop in the retina during DME vary in size. According to their size, a classification of cystoid edema was proposed by Koleva-Georgieva into mild, moderate and severe. In mild edema, cysts are small and predominantly located in the outer retinal layers. In the intermediate and severe forms, cysts are located in the outer layers, especially in the fovea. If cysts continue to increase, they occupy the whole thickness of the retina, leading to macular atrophy and profound visual loss. In mild edema, the cysts have a horizontal diameter below 300 μm , in intermediate edema the horizontal diameter of the cysts is between 300 and 600 μm and in the severe one the horizontal diameter of the cysts is above 600 μm or large confluent cavities with retinoschisis appearance are identified [6–8].

It has been shown that the status of the outer retinal layers is important for the visual outcome in patients with DME. Yohannan et al. proved that disruption of the IS/OS junction correlates well with a significant decrease of point sensitivity in patients with DME. Also, the integrity of ELM and IS/OS junctions correlates positively with visual acuity. Therefore, OCT evaluation of the outer retinal layers in patients with DME is important in predicting visual outcome [6].

Vitreo-retinal interface is very important in diabetic patients. It is known that diabetics have higher than normal vitreo-retinal adherence and that vitreo-macular traction is one of the factors explaining DME. OCT identifies various aspects: incomplete posterior vitreous detachment (PVD), epiretinal membranes (ERM) [6, 7]. OCT identifies vitreo-macular interface disorders from the preclinical stage. If posterior hyaloid is thin and partly detached from the macula, this aspect cannot be seen on biomicroscopy, but it is easily detectable on OCT. The same is true regarding the thin ERM. Thus, OCT is a very useful tool that establishes the best

therapeutic option in these cases: vitrectomy with release of vitreo-macular traction/dissection of ERM, from the early stages, when the chances for a good functional outcome are the highest. Assessment of vitreo-macular interface is an important step in evaluating diabetic patients. Not only does OCT indicate the moment for vitrectomy in these patients, but it also monitors the postoperative morphological outcomes: favorable evolution (decrease of macular thickness), development of ERM or of lamellar macular hole [6].

The detached posterior vitreous face appears on OCT scans as a thin horizontal or oblique line with low/medium reflectivity in the nonreflective vitreous, above or inserting into the retina. If PVD is incomplete, it may adhere to the foveal or peripapillary region. ERM appears on OCT as a hyperreflective line on the surface of the retina. Its presence leads to retinal modifications: increase of macular thickness, loss of foveal depression, formation of intraretinal cysts and pseudoholes. The difference between PVD and ERM is made according to their reflectivity (low in PVD, high in ERM). OCT provides other details related to ERM (degree of opacity, thickness, and distance from the macula) and to its effects on the underlying retina: distortion, edema, neurosensory detachment [6].

OCT is a very reliable and reproducible method to assess and monitor macular thickness following various treatments for DME: intravitreal injections with anti-VEGF and steroids, laser photocoagulation, vitrectomy. OCT also identifies macular atrophy which explains functional failure despite resolution of edema. Monitoring patients with DME must include two major parameters: functional (visual acuity) and anatomical (OCT) [5, 6].

Cystoid macular edema (CME) appears like large ovoid spaces of low reflectivity separated by hyperreflective septae that represent intraretinal cystoid-like cavities. Posterior hyaloid traction (PHT) appears like a highly reflective band on the surface of the retina. Serous retinal detachment (SRD) appears as a dark accumulation of subretinal fluid beneath the high reflective and dome-like elevation of detached retina. The highly reflective band which represents the outer surface of the retina helps differentiating subretinal fluid from the intraretinal fluid. Tractional retinal detachment (TRD) is identified as the area of low signal underlying the highly reflective border of detached retina. It often takes the appearance of a pick-shaped configuration [5, 6].

The most common finding in diabetics is diffuse retinal thickening (DRT) [6].

There is a correlation between macular thickness and visual acuity in patients with DME. The OCT pattern that was associated with worse visual outcome is CME [6].

In DME OCT technology has significant impact at various levels: it elucidates the pathogenic mechanisms of DME; it has a major contribution in identifying hyaloid-macular traction; it identifies the subclinical DME allowing early treatment; it makes it possible to correlate macular thickness with visual acuity; it monitors the evolution of DME following treatment [5–7].

5. OCT classification of macular edema

Along with the development of OCT imaging, various classifications of DME have been elaborated. The first OCT classification of DME belongs to Otani, and it is based on morphological

Retinal thickness	No macular edema	Normal macular thickness
	Early subclinical ME	Macular thickening nondetectable clinically Retinal thickness increased on OCT
	Established ME	Retinal thickening and morphological signs of edema
Retinal morphology	Simple noncystoid ME	Increased retinal thickness; reduced retinal reflectivity; irregularities of the layered retinal structure; flattening of the foveal depression; no cystoid spaces
	Cystoid ME	Well-defined intraretinal cystoids spaces
	Serous macular detachment	Hyporeflective area under the detached neurosensory retina and over the hyperreflective line of EPR
Vitreo-macular interface	No MT	Complete PVD/no PVD/no ERM
	Questionable MT	Incomplete PVD with no detectable distortion of retinal surface contour at the point of adhesion
	Definite MT	Incomplete PVD with distortion of retinal surface contour at the point of adhesion
Retinal outer layers	IS/OS and ELM intact	IS/OS and ELM intact
	IS/OS and ELM with disrupted integrity	IS/OS and ELM with disrupted integrity

Table 3. OCT classification of macular edema (after Koleva-Georgieva).

parameters, into three categories: sponge-like swelling, cystoid edema and serous retinal detachment [5]. A fourth category was added by Trichonas et al., posterior hyaloid traction (PHT) [6]. A more detailed classification was proposed by Koleva-Georgieva, and it is based on quantitative and qualitative OCT data: retinal thickness, retinal morphology, retinal topography, macular traction, foveal photoreceptor status (**Table 3**) [8].

6. OCT-angiography

OCT-Angiography (OCT-A) enables the noninvasive visualization of 3D retinal capillary network. It correlates very well with fluorescein angiography (FA), and it is able to show even more capillaries in the pericentral macula than FA and to separate and individualize the superficial and deep capillary plexus.

7. Personal experience with SD-OCT in DME

The personal experience in using SD-OCT for the management of DME is illustrated by several cases (**Figures 1–8**).

In this case, the OCT aspect of the macula favored intravitreal injection of anti-VEGF in AO, given the absence of PHT and the high amount of fluid within the retina OS. In OD, early

Thickness Map Single Exam Report OU
 SPECTRALIS® Tracking Laser Tomography

HEIDELBERG
 ENGINEERING

Patient: ---

Patient ID: ---

Diagnosis: ---

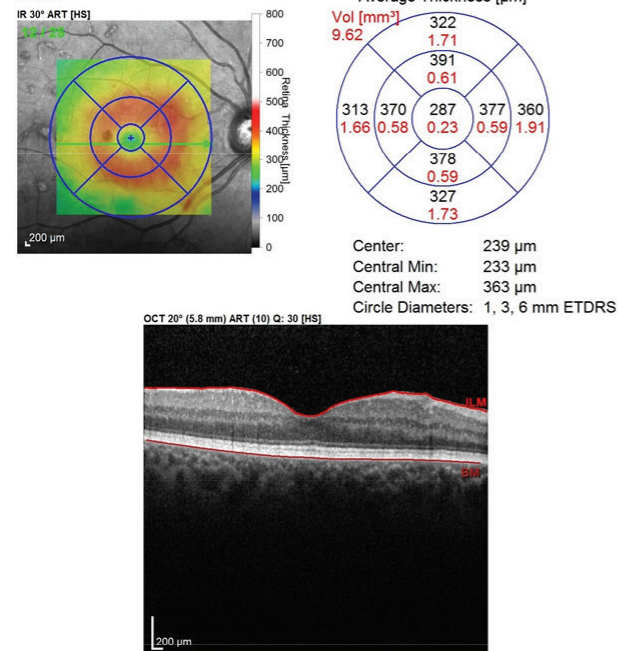
DOB: ---

Exam.: Mar/22/2018

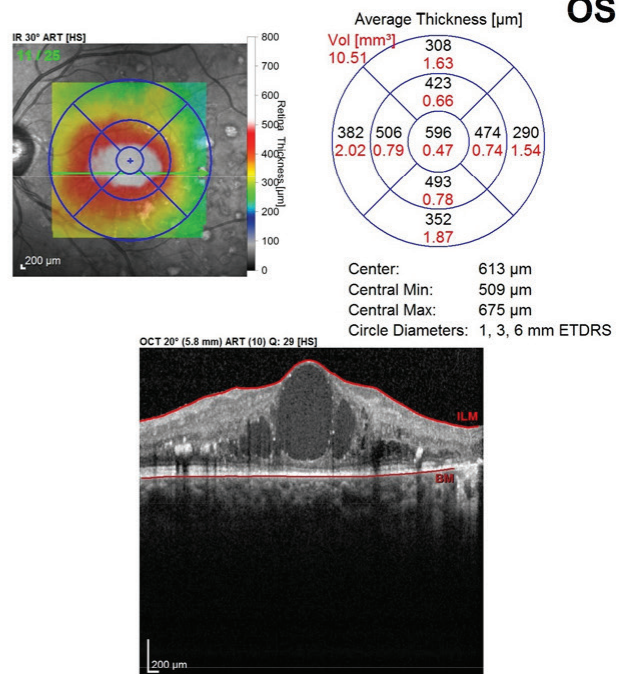
Comment: ---

Sex: M

OD



OS



Notes:

Date: 4/13/2018

Signature:

Software Version: 6.7.12

www.HeidelbergEngineering.com

Thickness Map Single Exam Report OU

Figure 1. OD diffuse mild thickening of the macular region. OS large ovoid spaces of low reflectivity (liquid content) separated by hyperreflective septae located in the neurosensory retina that represent intraretinal cystoid-like cavities; hyperreflective deposits with posterior shadowing (hard exudates, hemorrhages) in the neurosensory retina; no evidence of PHT; significant increase of the macular thickness, mainly centrally—on the account of the cystoids cavities.

treatment in the stage of mild edema had positive outcome. In OS, the high degree of macular disorganization prevented a significant improvement in vision (**Figure 2**).

In this case, intravitreal anti-VEGF injections alone would probably not lead to the resolution of edema, because vitreo-macular traction is also involved in its pathophysiology. Therefore, pars plana vitrectomy with dissection of the posterior hyaloid from the macular area was indicated (**Figures 3 and 4**).

In this case, anti-VEGF injections are indicated in AO, but with a much better prognosis in LE where edema is mild, as compared to RE in which the macula is disorganized (**Figures 5 and 6**).

In this case, beside anti-VEGF injections, pars plana vitrectomy appears reasonable in order to release the traction exerted by the posterior hyaloid on the macula.

Even if macular edema is mild, intravitreal anti-VEGF would prevent its progression toward more advanced stages with cystoid degeneration of the macula (**Figure 7**).

On the ground of the OCT aspect, intravitreal anti-VEGF injections are indicated in OD, but not in LE in which retinal atrophy is present (**Figure 8**).

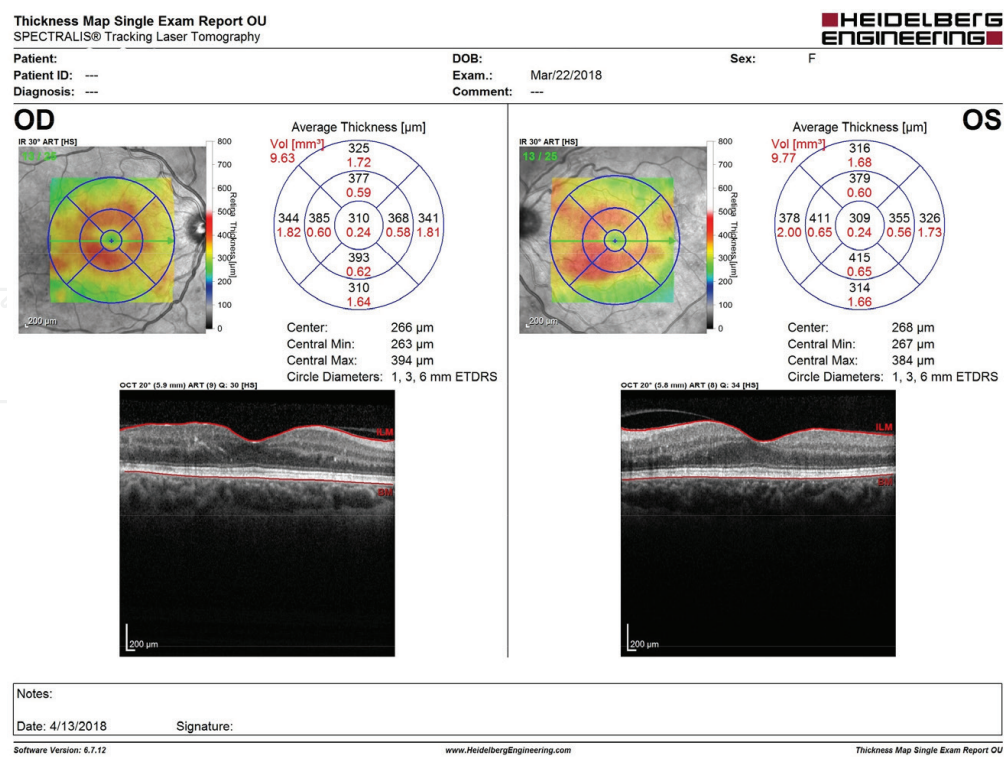


Figure 2. Moderate increase of the macular thickness in a diffuse manner, most likely caused by PHT: posterior hyaloid appears as a highly reflective band adherent to the underlying retina.

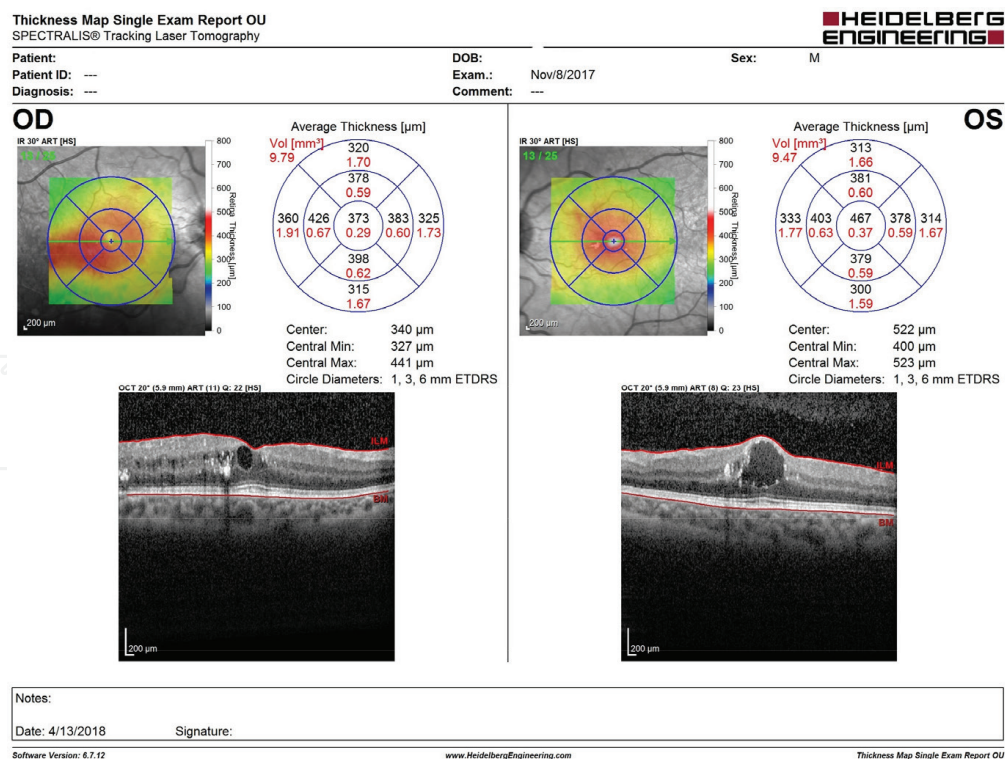


Figure 3. Diffuse DME in AO in a young patient with type 1 diabetes. Fluid is present within the neurosensory retina in the fovea (dark spaces). PHT is not present; therefore, intravitreal anti-VEGF injections were indicated with good outcome.

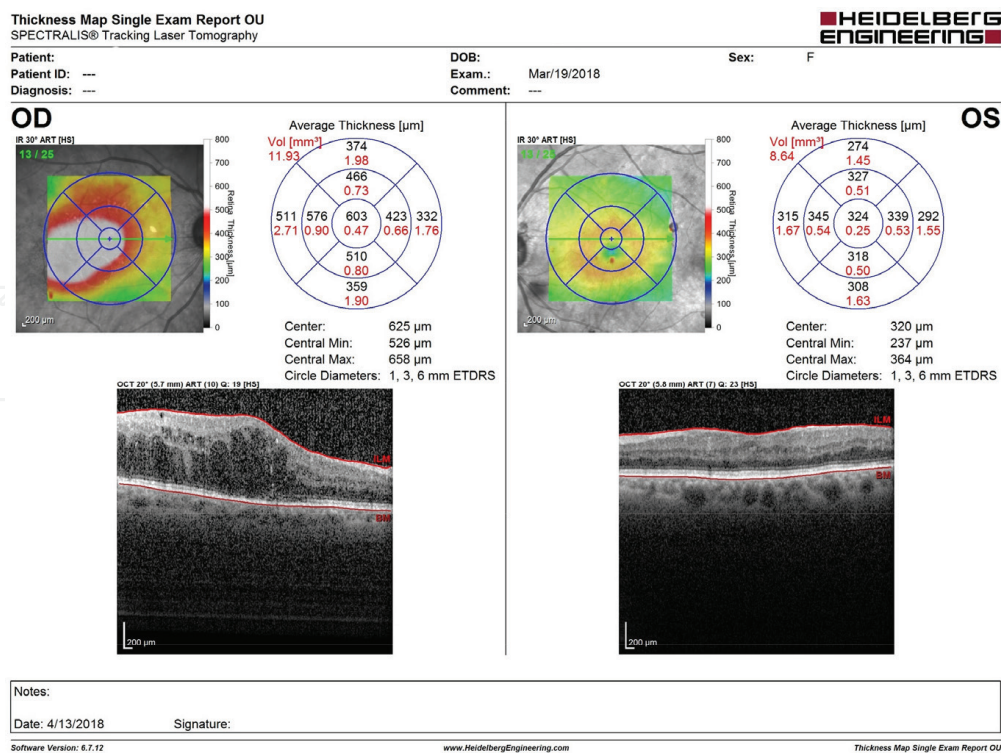


Figure 4. OD marked increase of the macular thickness, large cystoid cavities in the neurosensory retina separated by moderately reflective septae; OS slight increase of the macular thickness with diminishing of the foveal profile and tendency to flattening of the macular retina (early macular edema).

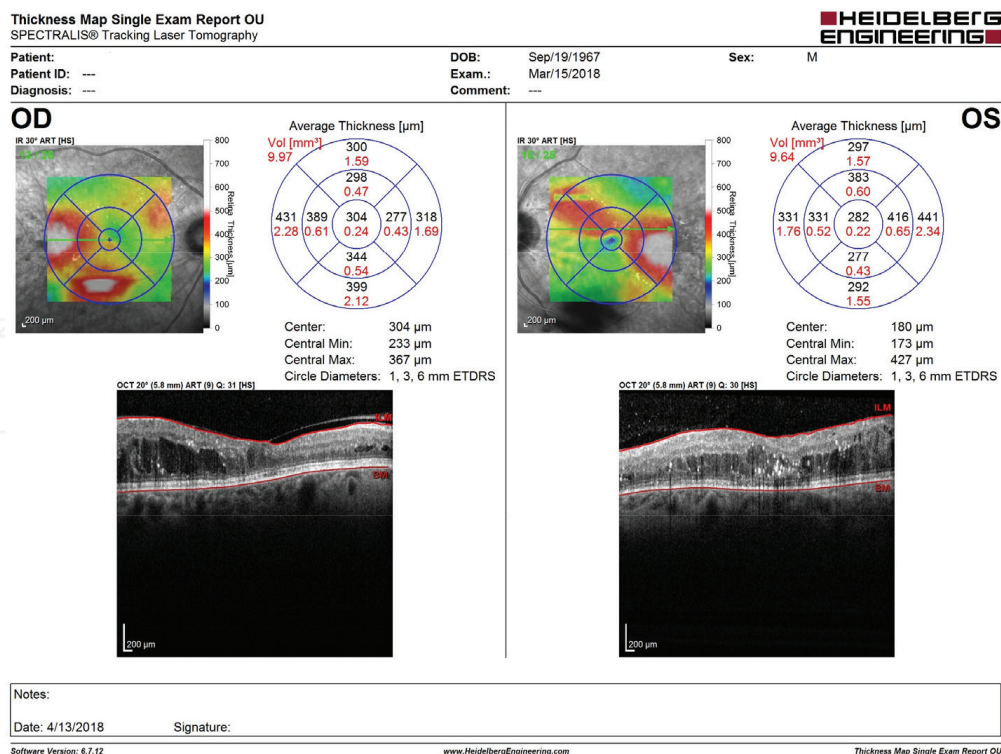


Figure 5. Focal macular edema OU: OD—beside the cystoid cavities within the neurosensitive retina, PHT is revealed; OS—smaller cystoid cavities with hyperreflective deposits and loss of normal foveal contour.

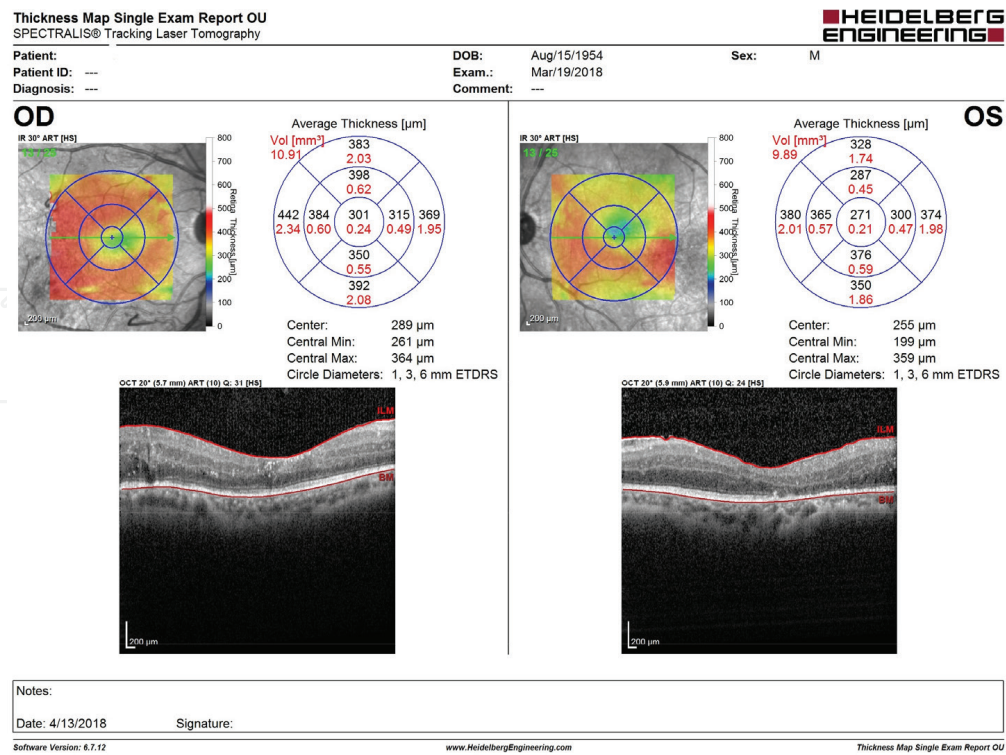


Figure 6. OD diffuse macular edema with preservation of the foveal contour and hyperreflective deposits in the neurosensory retina; OS mild focal macular edema.

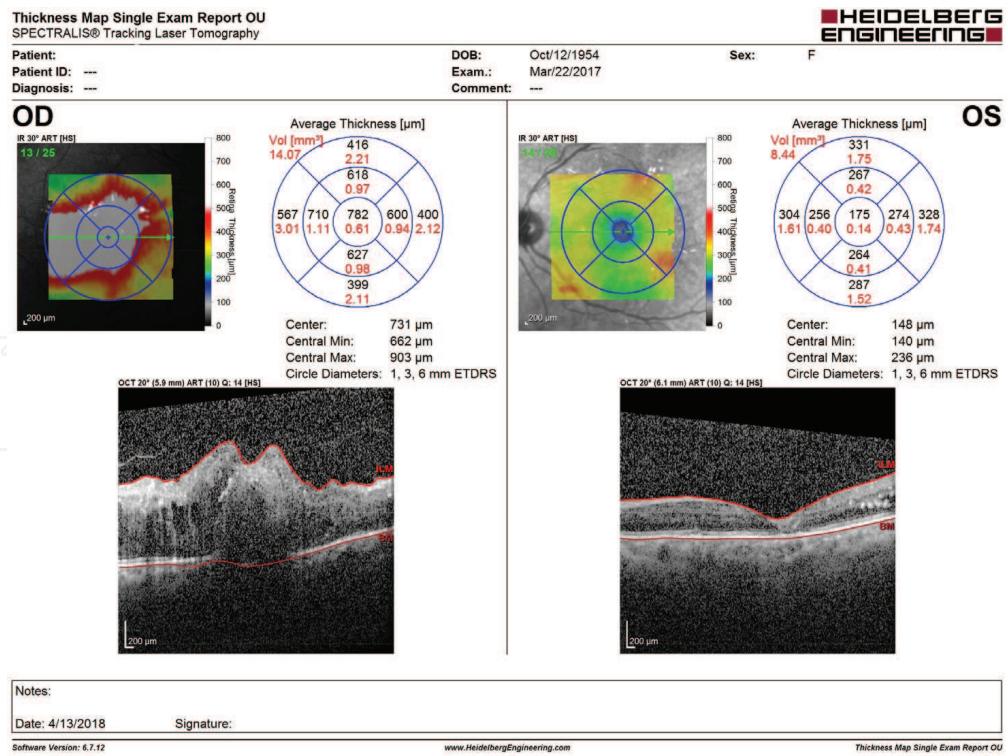


Figure 7. OD severe macular edema with considerable thickening of the macular area, cystoid cavities within the retina with involvement of the outer retinal layers and disorganization of the retinal pigmented epithelial line, PHT; OS retinal atrophy at the level of the foveal region.

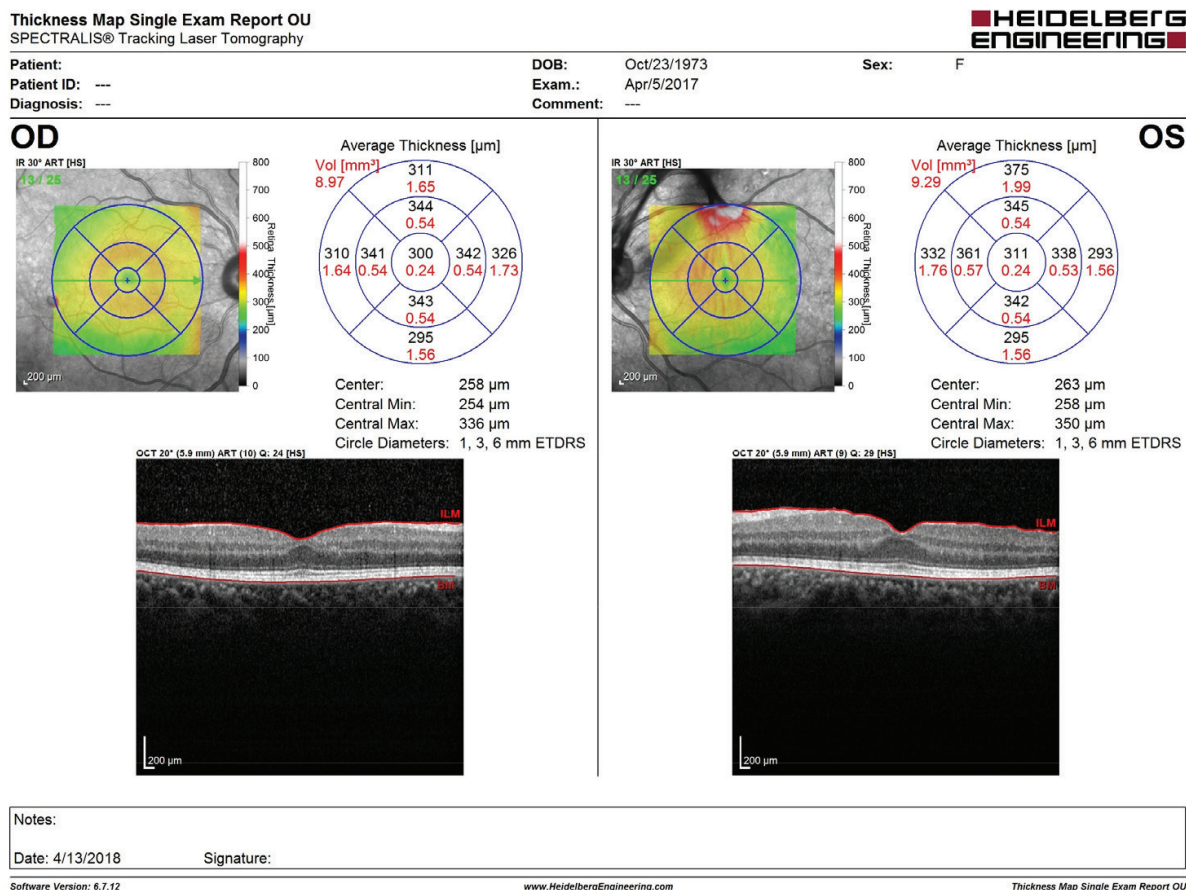


Figure 8. OD aspect following pars plana vitrectomy and dissection of the posterior hyaloid: mild diffuse macular edema, with normal foveal profile; OS mild macular edema with reflective posterior hyaloid adherent to the macula.

In LE (not vitrectomized) there is a slightly increase in macular thickness related to the traction of the posterior hyaloid on the macula. In RE, vitrectomy released the vitreo-macular traction and macular thickness is almost within the normal range.

8. Importance of OCT in selecting the appropriate therapy for DME

For many years, the only therapy of DME was laser photocoagulation which was indicated exclusively on clinical criteria, defined by Early Treatment Diabetic Retinopathy Study (ETDRS) as clinically significant macular edema [9]. Currently, therapeutic approaches of DME expanded, including anti-VEGF and steroid intravitreal injections and vitreo-retinal surgery [9]. The selection of the optimal therapy is correlated with the pathogeny of DME, which is best elucidated by OCT.

In most circumstances, DME is the consequence of internal blood-retinal barrier break-down with subsequent accumulation of fluid in the retina. Macular thickness and fluid topography are precisely evaluated by OCT. In these DME categories, the first line treatment is represented in our practice by intravitreal anti-VEGF injections. In refractory cases intravitreal steroids are considered.

OCT is the only method capable to identify and describe the aspect of the vitreoretinal interface. As such, within the DME group OCT individualizes a subgroup of patients with posterior hyaloid traction (PHT) which is often overlooked with fundus biomicroscopy. This particular form of DME is more resistant to medical therapy and vitreo-retinal surgery with membrane dissection is indicated. Intraoperative OCT is an important decision-making tool assisting the surgeon to identify the surgical planes and define the relationships of the membrane with the retina [9].

Not only does OCT identify the causes of DME, but it also allows early diagnosis and treatment of DME, before it is clinically significant [10]. This is translated in the clinical practice by better anatomical and functional outcomes.

The moment of treatment emerges from the OCT aspect correlated with visual acuity. Generally, there is a parallel correspondence between the anatomical and functional data. However, if OCT shows a slight increase in central retinal thickness (CRT) but visual acuity is 20/20, the patient is watched closely, and treatment is promptly initiated if the visual function follows a negative trend [10].

Usually, the evolution of OCT aspect of the macula is parallel to the response of visual acuity. If the increase of visual acuity does not correspond to the improvement of OCT aspect, a long time evolution of DME and/or the use of multiple treatment modalities should be considered [10].

9. Conclusions

OCT is a noninvasive, well-tolerated method, easy to understand and explain. It offers qualitative information on retinal thickness, and it is reliable and reproducible. OCT reveals the presence and extension of vitreo-macular traction.

There is a correlation between macular thickness and visual acuity in patients with DME. The OCT pattern that was associated with worse visual outcome is CME.

In DME OCT technology has significant impact at various levels: it elucidates the pathogenic mechanisms of DME; it has a major contribution in identifying hyaloid-macular traction; it identifies the subclinical DME allowing early treatment; it makes it possible to correlate macular thickness with visual acuity; it monitors the evolution of DME following treatment.

Acknowledgements

This study was funded by grant number PED 156, Executive Agency for Higher Education, Research, Development and Innovation Funding, Romania.

Conflict of interest

The author declares that there is no conflict of interest regarding the publication of this chapter.

Author details

Simona Delia Nicoară

Address all correspondence to: simonanicoara1@gmail.com

Faculty of Medicine, Department of Ophthalmology, "Iuliu Hațieganu" University of Medicine and Pharmacy, Cluj-Napoca, Romania

References

- [1] Ross AH, Bailey CC. The management of diabetic macular edema. *Saudi Journal of Ophthalmology*. 2011;**25**(2):123-129. DOI: 10.1016/j.sjopt.2011.01.011
- [2] Kiire CA, Porta M, Chong V. Medical management for the prevention and treatment of diabetic macular edema. *Survey of Ophthalmology*. 2013;**58**(5):459-465. DOI: 10.1016/j.survophthal.2012.10.002
- [3] Țălu SD, Țălu S. Use of OCT imaging in the diagnosis and monitoring of age related macular degeneration. In: Ying G-S, editor. *Age-Related Macular Degeneration – The Recent Advances in Basic Research and Clinical Care*. Rijeka: In Tech; 2012. pp. 253-273. DOI: 274383296
- [4] Țălu SD. New insights into the optical coherence tomography – Assessment and follow up of age related macular degeneration. In: GL Giudice, editor. *Age-Related Macular Degeneration – Etiology, Diagnosis and Management – A Glance at the Future*. Rijeka: In Tech; 2013. pp. 133-159. DOI: 10.5772/53357
- [5] Ahmadpour-Baghdadabad M, Manaviat M, Shojaoddini-Ardekani A. Optical coherence tomography in diabetic macular edema: Patterns and related risk factors. *Nepalese Journal of Ophthalmology*. 2013;**5**(10):190-194. DOI: 10.3126/nepjoph.v5i2.8727
- [6] Trichonas G, Kaiser PK. Optical coherence tomography imaging of the macular oedema. *The British Journal of Ophthalmology*. 2014;**98**(Suppl II):ii24-ii29. DOI: 10.1136/bjophthalmol-2014-305305
- [7] Sikorski BL, Malukiewicz G, Stafiej J, Lesiewska-Junk H, Raczynska D. The diagnostic function of OCT in diabetic maculopathy. *Mediators of Inflammation*. 2013;**1**:1-12. DOI: 10.1155/2013/434560
- [8] Koleva-Georgieva D. Optical coherence tomography findings in diabetic macular edema. In: Ola MS, editor. *Diabetic Retinopathy*. Vienna: InTech; 2012. pp. 225-249. DOI: 10.5772/30302
- [9] Modi YS, Ehlers JP. Imaging modalities for the management of DME. *Retina Today*. 2015;**6**:66-69
- [10] Kiss S. OCT useful in management of DME. *Ocular Surgery News*. 2016;**2**:1-3

