

We are IntechOpen, the world's leading publisher of Open Access books Built by scientists, for scientists

6,900

Open access books available

185,000

International authors and editors

200M

Downloads

Our authors are among the

154

Countries delivered to

TOP 1%

most cited scientists

12.2%

Contributors from top 500 universities



WEB OF SCIENCE™

Selection of our books indexed in the Book Citation Index
in Web of Science™ Core Collection (BKCI)

Interested in publishing with us?
Contact book.department@intechopen.com

Numbers displayed above are based on latest data collected.
For more information visit www.intechopen.com



Ebstein's Anomaly

Sinem Altunyuva Usta, Ayşe İnci Yıldırım,
Aysu Türkmen Karaağaç and Kaan Kırallı

Additional information is available at the end of the chapter

<http://dx.doi.org/10.5772/intechopen.78067>

Abstract

Ebstein's anomaly (EA), a rare congenital heart disease, results from the failure of delamination of tricuspid valve (TV) leaflets from the endocardium of the right ventricle (RV) and apical displacement, particularly of the septal and posterior leaflets of TV. The most commonly accompanying cardiac malformation is atrial septal defect. Most EA cases are sporadic; familial ones are rare. EA patients may present at any age. Symptoms result from TV regurgitation, RV dysfunction, inadequate left ventricular filling owing to ventricular septal bowing, inadequate pulmonary flow, and arrhythmias. Atrial tachyarrhythmias are the most common late complications. There have been more techniques of tricuspid repair reported in the literature than any other congenital or acquired cardiac lesion. Neonatal operation has a higher risk of mortality than the operations performed beyond infancy. Late survival rate and the quality of life for hospital survivors are excellent.

Keywords: congenital heart anomaly, heart failure, tricuspid regurgitation

1. Introduction

EA is a congenital malformation involving the tricuspid valve (TV) and right ventricle (RV). This myopathy is associated with the failure of TV delamination and highly variable tricuspid valve morphology that usually results in severe regurgitation and atrialized right ventricular dilatation. This anomaly has an extremely variable natural history depending on the degree of abnormality of the right ventricle and the tricuspid valvar apparatus. If the deformity of the TV is severe, it may result in profound congestive heart failure in the neonatal period or even in intrauterine death. At the other end of the spectrum, patients with mild degrees of displacement and dysfunction may remain asymptomatic until late adult life or may remain

symptomless throughout life. There is a genetic heterogeneity; most of the cases are sporadic, familial ones are rare. Asymptomatic patients with EA can be conservatively treated and kept under close follow-up, whereas surgical operation is indicated for those with the evidence of right heart dilation and progressively impaired ventricular systolic function. A biventricular repair is suitable for most of the patients. While 1.5-ventricular repair (bidirectional Glenn shunt) is indicated for the patients with poor right ventricular function, heart transplantation is suggested for the patients with severe left ventricular dysfunction.

2. History

This anomaly was first described by Wilhelm Ebstein, a German physician, in a report titled “Concerning a very rare case of insufficiency of the tricuspid valve caused by a congenital malformation” [1, 2]. Ebstein’s own description of the malformation in 1866, with illustrations by Dr. Weiss, was based upon the anatomical findings related to the heart of Joseph Prescher, a 19-year-old cyanotic laborer with dyspnea, palpitations, jugular venous distension, and cardiomegaly [1, 2]. Ebstein described an enlarged and fenestrated anterior leaflet of the tricuspid valve in the findings of the autopsy. The posterior and septal leaflets were hypoplastic, thickened, and adherent to the right ventricle. There was also a thinned and dilated atrialized portion of the right ventricle, an enlarged right atrium, and a patent foramen ovale [3, 4]. The first case described in the English literature was not published until 1900 years [5–7]. In the 1950s, successful surgical palliation was achieved.

3. Prevalence

EA occurs in about 1/200.000 live births. It accounts for no more than 0.3–0.5% of congenital heart disease [8, 9]. The male–female incidence is equal [9].

4. Anatomy of tricuspid valve

Normally, the TV has three valvar leaflets referred to as the anterosuperior, the septal and the mural leaflets. However, in EA, the anterosuperior is the largest, redundant anterior leaflet, which contains fenestrations. It stretches from the infundibulum anteriorly to the inferolateral wall posteriorly, whereas the septal leaflet, the smallest, arises medially from the annulus above the interventricular septum. Mural or posterior leaflet attaches along the posterior margin of the tricuspid annulus from the septum to the inferolateral wall [10]. The leaflets of TV develop equally from the endocardial cushion tissues and the myocardium [10]. EA is a myopathy of the RV with abnormalities in both myocardial structure and function, besides the characteristic valvar deformities [9, 11]. Embryonic failure of delamination of the septal, inferior and anterior leaflets of the TV results in the apical displacement of the tricuspid leaflets to the underlying RV myocardium. Such failure in delamination creates the characteristic downward (apical) displacement of the functional orifice and dilation of the atrialized right ventricle (aRV), with

various degrees of hypertrophy and thinning of the wall. This malformation is characterized by the displacement of the points of attachment, or the hinges, of the septal and mural leaflets into the right ventricle, away from the atrioventricular junction. As the anterosuperior leaflet has a different developmental origin, its junctional hinge usually retains a normal position [8, 13, 14].

The failure in delamination also results in various degrees of displacement of TV leaflets, and the movement of the tricuspid hinge points both anteriorly and toward the right ventricular apex. The adherent portions of the valvar leaflets usually have little or no motion. This generally leads to tricuspid regurgitation or rarely to stenosis. [10–13]. Chordae tendineae of anterior leaflets are generally short, tethered, poorly formed and severely deformed. Therefore, the only mobile leaflet tissue is displaced into the right ventricular outflow tract (RVOT), where it may cause obstruction or forms a large sail-like intracavitary curtain. The septal and mural leaflets are usually rudimentary, dysplastic or may be absent due to failure of delamination. These leaflets may be freely mobile or adhered (tethered) to the endocardium [9, 13].

The maximal displacement is at the commissure level between the mural and septal leaflets of the TV [14]. Apical displacement of the septal leaflet by at least 8 mm/m² of body surface area is considered as a diagnostic feature of EA in the echocardiographic evaluation [12]. The spectrum of the malformation in EA may range from a minimal displacement of the septal and mural leaflets to an imperforate membrane or muscular shelf between the inlet and trabecular zones of the right ventricle. There is often a marked dilatation of the true TV annulus, and the aRV separating this true annulus from the functional right ventricle (fRV) [6, 12].

4.1. Atrium and atrioventricular sulcus

The right atrium is usually very dilated, and the right atrioventricular junction, or true annulus of the TV, is enlarged circumferentially. The valve of the inferior vena cava (eustachian valve) is often very prominent.

4.2. Coronary arteries

In the usual form of Ebstein's anomaly, the coronary arteries are normal except the right coronary artery (RCA). It may be displaced superiorly and posteriorly because of an aneurysmatic dilatation of aRV. Therefore, the surgeon should carefully follow the course of the RCA during the operation. It demarcates the level of the true annulus and may become kinked during plication annuloplasty procedures or TV replacement [12].

4.3. Right ventricle

Because of the displaced TV, the RV is divided into two regions in Ebstein's anomaly: the inlet portion [atrialized right ventricle (aRV)] and the trabecular or outlet portion [functional ventricle (fRV)]. The inlet portion, directly involved with the malformation, is functionally integrated with the right atrium, whereas the outlet portion constitutes the functional RV. The aRV usually has a thinner wall than the fRV and may account for more than half of the RV volume in extreme cases, instead of its usual location in one-third of the RV [8, 9]. There is often a marked dilatation of the true TV annulus and a large chamber separating this annulus from the functional RV. Two-thirds of EA cases possess dilated RV, which commonly involve

the functional RV apex and outflow tract. In some cases, RV dilatation is so significant that the ventricular septum bulges leftward, compressing the left ventricular (LV) chamber, and may cause episodic left ventricular outflow tract (LVOT) obstruction [8]. In such cases, the short-axis view demonstrates a circular right ventricle and a crescentic left ventricle.

4.4. Conduction tissue

EA cases have specialized conduction tissues [9, 14]. The sinoatrial node appears to be normally positioned, but various abnormalities of the right bundle branch have been reported. It may be located superficially in the subendocardium of the atrialized ventricle and encased in fibroelastic tissue. Arrhythmias such as accessory conduction pathways (Wolff-Parkinson-White (WPW) syndrome), atrial fibrillation or flutter are common. They occur with increasing frequency with advancing age [15]. Patients who have accessory conduction pathways are diagnosed and treated by catheter ablation technique with high succession rates.

4.5. Left ventricle

Histology of the left LV in patients with EA has shown variable degrees of fibrosis, hypertrophy, and nonspecific dysplasia [14]. LV dysfunction leads to abnormal leftward bowing of the ventricular septum and mitral valve prolapse. Regional dysfunction of LV may also develop secondary to RV dilatation.

4.6. Associated cardiac defects

The most commonly associated cardiac defects are atrial septal defect and patent foramen ovale, present in 80–94% of EA patients [16]. Other associated anomalies include bicuspid or atretic aortic valves, pulmonary atresia or hypoplastic pulmonary artery, subaortic stenosis, coarctation, mitral valve prolapse, accessory mitral valve tissue or muscle bands of the left ventricle, ventricular septal defects (VSD), and pulmonary stenosis [17]. Abnormalities of LV morphology and function, as well as other left-sided heart lesions, may also occur in EA [9, 10, 16–23]. Most patients with congenitally corrected transposition of the great arteries have an abnormal systemic TV, which fulfills the criteria for EA in 15–50% of cases. It is unclear whether the fundamental nature of the anomaly is identical in concordant and discordant atrioventricular connections [24–26]. The morphological RV is rarely dilated in congenitally corrected transposition.

5. Classifications

There are two approaches in the description of the anatomic severity of EA. The first approach is based on the echocardiographic appearance. The abnormality is described anatomically as mild, moderate, or severe. The amount of displacement and tethering of the leaflets and the degree of RV dilatation are assessed. This classification is imprecise but simple. The second approach is to describe the exact anatomy of each of the involved cardiac structures as visualized at operation. This nomenclature system emphasizes the characteristics that surgeons find

GOSE score	Ratio	Mortality rate (%)
Grade 1	<0.5	5–8
Grade 2	0.5–0.99	8–10
Grade 3	1–1.49	45 (acyanotic) 100 (cyanotic)
Grade 4	>1.5	100

Table 1. The Great Ormond Street Echocardiography (GOSE) score and mortality rate are seen.

important when considering repair versus replacement of the TV [10]. In 1988, according to the classification of Carpentier, EA was divided into four types. Type A: The volume of the true RV is adequate. Type B: Large atrialized component of the RV exists, but the anterior leaflet of the TV moves freely. Type C: The anterior leaflet is severely restricted in its movement and may cause significant obstructions of the RVOT. Type D: Almost complete atrialization of the ventricle except for a small infundibular component [27].

The Celermajer classification [28] of EA was according to echocardiographic measurements calculating the ratio of the combined area of the right atrium and aRV to that of the fRV and the left heart in a four-chamber view at the end diastole ($\text{GOSE} = \text{RA} + \text{aRV} / \text{fRV} + \text{LV} + \text{LA}$). There is an echocardiographic grading score for neonates with Ebstein's anomaly, The Great Ormond Street Echocardiography (GOSE) score, with grades 1 to 4. Increasing severity, that is, a higher grade, was associated with a high mortality rate. This classification is particularly helpful with neonatal Ebstein's anomaly [28]. The Great Ormond Street Echocardiography (GOSE) score and mortality rate are demonstrated in the **Table 1**.

6. Causation and genetics

No specific cause has been consistently associated with EA. Based on retrospective case reporting, treatment with lithium during the first trimester of pregnancy was thought to be strongly associated, a 400-fold relative risk, with the occurrence of EA in the fetus. However, recent cohort and case–control epidemiologic studies have not confirmed these initial findings.

There are heterogeneous genetic factors in EA. Most cases are sporadic; familial ones are rare. Duplication of 15q affects the early morphogenesis of cardiac structures, including the normal formation of TV. Therefore, the gene located on the long arm (q) of chromosome 15 is likely to be involved in the development of EA [29, 30]. Distinct rearrangements of the chromosomal region 11q arm and deletion of 10p13–p14 and 1p34.3–p36.11 have also been described in association with EA. Genetic bases of this anomalies may be associated with the mutations in the genes MYH7 and NKX2.5 and among others [31–38]. Moreover, heterozygous mutations of NKX2.5 have been identified in the EA cases accompanied by atrioventricular (AV) block, atrial septal defect (ASD), ventricular septal defect (VSD), tetralogy of Fallot or double-outlet RV, and other TV abnormalities [39].

7. Pathophysiology

The broad spectrum of anatomic severity in EA is due to the wide spectrum of clinical and hemodynamic manifestations. The pathophysiologic changes are related to the RV functional impairment and the degree of TV regurgitation or, rarely, stenosis; the size of the interatrial communication; LV dysfunction and other associated congenital cardiovascular malformations. The aRV acts as a passive reservoir during contraction of the atrium due to the decreasing volume of ejected blood. The overall effect on the right atrium is dilatation and an increase in size of the interatrial communication. Tricuspid regurgitation increases with perogressive annular dilatation. To a lesser degree, the pathologic substrates predisposing to tachyarrhythmias produce an additional dimension contributing to the pathophysiology.

Dysfunction of the RV myocardium, and the abnormalities of the TV contribute to the impaired flow into the right heart and the pulmonary circulation. The dilated right atrium and RVa decrease the right heart flow. There is no valvar tissue separating this area from the true atrial chamber and the great veins. This results in increased venous pressure, which leads to an elevation in resistance to forward flow. A larger volume of RA due to RA distension results in right to left shunting at the atrial level in the presence of an ASD. When the aRV relaxes, it will expand, and can even balloon outwards during true atrial contraction. This creates a reservoir for venous blood and decreases the amount of effective forward flow that crosses the abnormal TV. This to-and-fro flow pattern between the right atrium and the aRV not only decreases effective output from the right heart but also provides an ongoing stimulus for atrial dilatation and atrial arrhythmias. The degree of functional impairment has been directly related to these anatomic and physiologic abnormalities. A small fRV and large aRV, extreme displacement or absence of the septal leaflet, the degree of displacement or tethering of the anterosuperior leaflet, and the aneurysmal dilation of the RVOT were all associated with a reduced functional state of the New York Heart Association [40]. A small fRV and large aRV, and extreme displacement of the septal leaflet is shown in <https://mts.intechopen.com/download/index/process/176/authkey/53ae2bbd4b7866a29632305139289c32>.

Although the primary focus in patients with EA has been on right-sided structures, there have been an increasing number of reports of left-sided abnormalities, especially in LV size, shape, and function [35–37]. Radionuclide scans and cineangiograms have shown disturbed LV function at rest in nonoperated patients. During formal exercise testing, these patients show an appropriate increase in LV ejection fraction due to a reduced end-systolic volume and unchanged end diastolic volume [37]. EA is related to the abnormal echocardiographic appearance of the LV myocardium: myocardial noncompaction and hypertrabeculated segments. Most patients have satisfactory LV function; a small percentage show severe systolic and diastolic dysfunction even if patients have LV myocardial abnormalities [41]. These left-sided myocardial abnormalities, although seen in only a few patients, support the concept that EA is actually a global myocardial disorder that primarily manifests itself within the RV and TV. Pulmonary vascular resistance is always high immediately after birth and usually decreases rapidly in the first days of life. It is highly difficult for the infant with severe EA to deal with neonatal circulation due to the high pulmonary vascular resistance. The combination

of RV myopathy, tricuspid regurgitation, and elevated pulmonary resistance can lead to poor pulmonary perfusion when the arterial duct constricts or closes. Venous pressures rise, leading to right-heart failure and cyanosis due to right-to-left shunting across the foramen ovale. Until the pulmonary resistance decreases, and the pulmonary flow increases, these infants present a diagnostic and therapeutic dilemma. Patency of the pulmonary outflow tract and valve must be confirmed [42]. This can be achieved by demonstrating the opening of the pulmonary valvar leaflets by cross sectional echocardiographic scans, or by documenting either forward or more commonly regurgitant flow across the valve using Doppler techniques.

8. Clinical presentation

The manifestations of EA are cyanosis, right-sided heart failure, arrhythmias, and sudden cardiac death. The hemodynamic variations and clinical presentation depend on the age at presentation, anatomic severity, hemodynamics, and the degree of right-to-left interatrial shunting [38, 41].

Patients with EA may present at any age and the majority is diagnosed in infancy or childhood, but a small percentage with less severe malformations present in adulthood. The most severe cases present prenatally or as newborns. Prenatal diagnosis is dependent upon ultrasonic screening examinations. The mortality rate is higher in the patients with severe EA. In the severe forms of EA, cardiomegaly, hydrops, and tachyarrhythmias may be seen in the fetal echocardiography. Marked cardiac enlargement may lead to pulmonary parenchymal hypoplasia in the most severe cases. Prenatal arrhythmia is not common. Neonates usually present with cyanosis and heart failure and secondary TV regurgitation resulting from decreased pulmonary blood flow, depressed RV function, and low cardiac output [42]. Murmurs and arrhythmias are frequently encountered presenting complaints in children, adolescents and adults. Adults also present with progressive cyanosis, decreasing exercise tolerance, fatigue, or right-sided heart failure. Palpitations in a cyanotic child should raise the possibility of EA [38, 41, 42]. In the presence of an interatrial communication, the risk of paradoxical embolization, brain abscess, and sudden death increases. Exercise tolerance is dependent on the cardiac function and oxygen saturation [43, 44].

9. Physical findings

Growth and development are generally normal. Physical signs vary depending on the severity of pathology and magnitude of the right-to-left atrial shunt, which may lead to cyanosis and digital clubbing in patients with interatrial communication. Cyanosis is typically pronounced in the neonate and infants, whereas it is milder (sometimes only exertional) in older children. Many have an unusual facial coloration, described as violaceous hue, red-cheeked, or malar flush. Usually these patients have an associated mild polycythemia. Asymmetry of the chest is a frequent finding secondary to the right heart dilatation. Arterial and venous pulsations are

usually normal, even in the presence of tricuspid insufficiency. The jugular venous pulsations may not have a large V wave because of poor transmission of the venous pulse wave in the presence of a dilated and compliant right atrium [41, 42]. Jugular venous and hepatic distention may be present in advanced cases. The praecordium is usually not overactive. After the neonatal period, it is auscultation that often alerts the physician to the diagnosis of EA. The systolic murmur of tricuspid regurgitation is variable and its intensity depends on the degree to which contractility of the fRV is preserved. Multiple first heart sounds are heard because the highly mobile anterosuperior valvar leaflets and anterior leaflet mimic ejection clicks. Occasionally, the heart sounds are soft, but usually they are of normal intensity. The first heart sound is widely split because of the increased excursion of the anterosuperior leaflet and the subsequent delayed closure of the abnormal TV. The second heart sound is often split owing to the late closure of the pulmonary valve as a result of the conduction delay associated with severe RV enlargement. A holosystolic murmur is found along the left sternal border in those with an organized jet of tricuspid regurgitation. Diastolic murmurs are rare, unless there is coexisting pulmonary regurgitation. Low-intensity diastolic murmurs can be auscultated in the same location as a result of antero-grade flow across the TV [42]. Importantly, murmurs may be very soft or absent if the coaptation gap is very large; the velocity of to-and-fro flow is low, and rapid equalization of pressure across the functional TV does not result in blood flow turbulence.

10. Diagnosis

10.1. Electrocardiography

The electrocardiogram (ECG) is usually abnormal and helps to confirm the clinical diagnosis. Sinus rhythm is usually present at the time of initial diagnosis. ECG may show tall and broad P waves as a result of right atrial enlargement, as well as complete or incomplete right bundle-branch block. Complete AV block is rare and first degree AV block is present in approximately half the patients. The QRS axis in the frontal plane occasionally shows right-axis deviation. Most patients have right bundle branch block and many have low-voltage QRS complexes in the right precordial leads. Right ventricular hypertrophy criterion are extremely uncommon [41, 45].

The downward displacement of the septal leaflet of the TV is associated with discontinuity of the central fibrous body and septal atrioventricular ring with direct muscular connections, thus creating a potential substrate for accessory atrioventricular connections and preexcitation. Occasionally, the pattern is transient or intermittent. Paroxysmal tachyarrhythmias in EA are based on fast conducting atrioventricular accessory pathways with both antegrade and retrograde conduction properties in most patients. In addition, wide QRS tachycardia over a septal accessory atrioventricular pathway, ventricular tachycardia, or flutter, as well as ectopic atrial tachycardia, atrial flutter, and atrial fibrillation can occur. Concealed accessory pathways, without manifest delta waves, are also common. Absence of anterograde preexcitation, therefore, neither indicates that the accessory connection is no longer present nor that the patient is no longer susceptible to tachycardia. The patient may still have retrograde conduction, which allows for atrioventricular reciprocating tachycardia. The presence of left axis

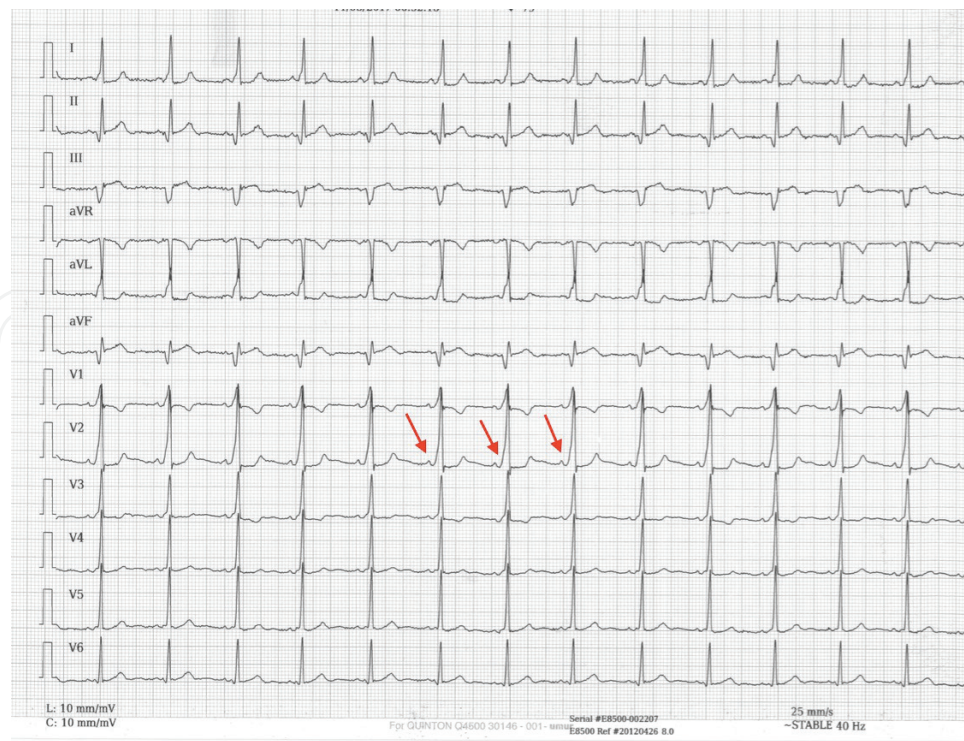


Figure 1. ECG of a patient with Ebstein's anomaly and the wolf Parkinson white syndrome showing the typical changes, with reduced PR interval, and preexcitation (delta wave) configuration of the QRS complex.

deviation in a patient with EA suggests the presence of the Mahaim variant of preexcitation, produced by atriofascicular tracts. The patients with arrhythmias or symptoms compatible with arrhythmia are significantly older than those without symptoms or arrhythmias [46–48]. Accessory conduction pathways [Wolff-Parkinson-White (WPW) syndrome] arrhythmias are seen approximately 15–20%. Atrial fibrillation or flutter can occur with increasing frequency with older age. ECG shows EA patients with WPW syndrome in **Figure 1**.

Even prior to the widespread application of complex surgical antiarrhythmic procedures, surgical intervention appeared to decrease the frequency of arrhythmias, at least in early, short-term follow-up. Despite the overall reduction in arrhythmias, when arrhythmias were observed early during postoperative recovery, these patients had an increased risk of late sudden death [15, 49].

10.2. Chest radiography

The cardiac silhouette may vary from nearly normal to extreme cardiomegaly. When the heart is severely dilated, it takes a globular shape similar to that observed with large pericardial effusions or severe dilated cardiomyopathy. The dilated right atrium is responsible for most of the enlarged cardiac silhouette. In the frontal view, the right atrium produces a significant convexity of the right heart border, and in the lateral view, the right atrium may fill the entire retrosternal space. The convex left border is primarily due to dilation of the right ventricular outflow tract. The convexities of both left and right heart borders produce the characteristic

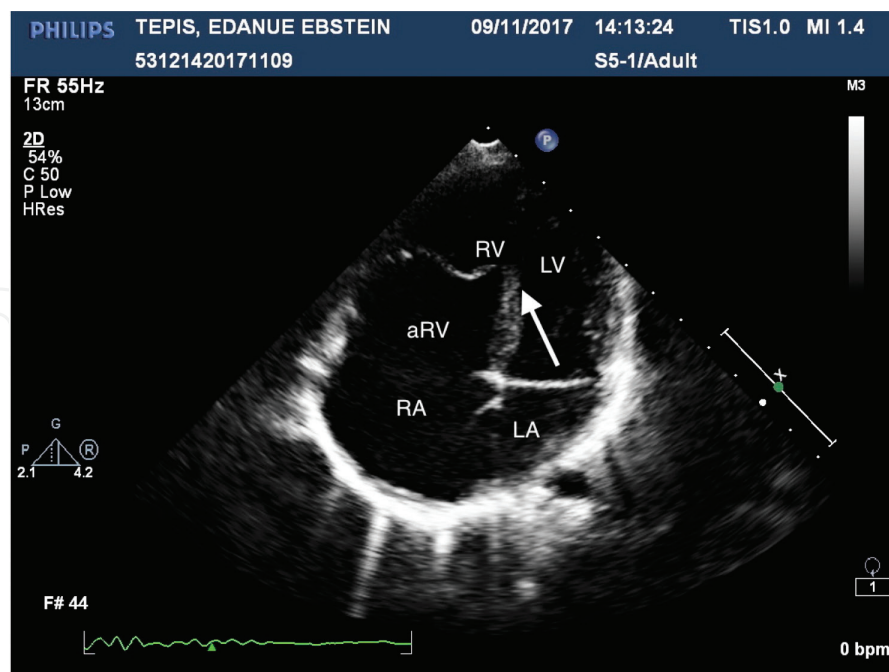
globular cardiac silhouette. In cyanotic patients with a right-to-left shunt, the pulmonary vascularity is decreased. A cardiothoracic ratio of 0.65 carries a poor prognosis [14].

10.3. Echocardiography

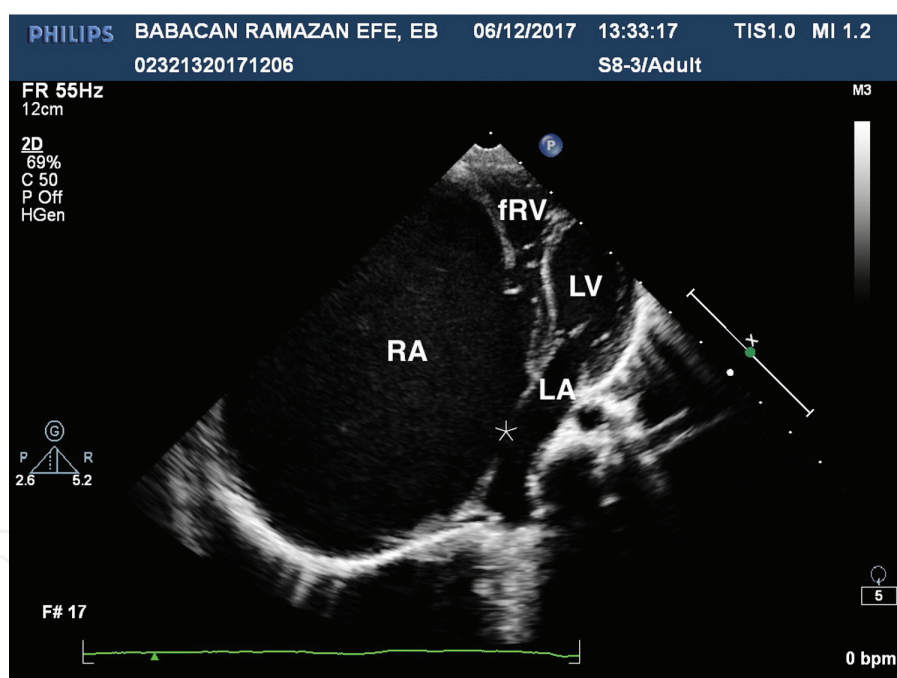
Two-dimensional echocardiography is the diagnostic test used also in the long-term assessment of patients with EA. More recently 3D echocardiography has been utilized as an adjunct for the assessment of additional details about TV anatomy-leaflets and subvalvar apparatus, the size and function of the cardiac chambers, and other associated cardiac defects. The single most sensitive and specific diagnostic feature is the displacement of the annular hinge of the septal leaflet. The distance between the valvar hinge points can easily be measured. Apical displacement of the septal leaflet of the TV from the insertion of the mitral anterior leaflet hinge point should be at least 8 mm/m² when evaluated in the apical four-chamber view [14]. An echocardiogram (four-chamber view) of a patient with severe Ebstein's anomaly showing a displaced septal leaflet, atrialized RV and small functional RV is shown in **Figure 2**.

Other echocardiographic features that help in diagnosis include: (1) elongation of the anterosuperior leaflet, (2) tethering of the leaflets to the underlying myocardium, (3) shortened cordal support, (4) attachment of the leading edge of the anterosuperior leaflet to the right ventricular myocardium, (5) displacement of the annular attachment of the anterosuperior leaflet, (6) absence of the septal or mural leaflets, (7) congenital fenestration of the leaflets, and (8) enlargement of the valvar annulus [24].

Echocardiography is also used to evaluate the suitability for valvar repair, associated cardiovascular abnormalities, and myocardial function. The most important determinant of a durable monoleaflet repair is a freely mobile anterosuperior leaflet, especially its leading edge. The mobile leaflet tissue should be visualized within the right ventricular inflow tract, and this assessment must be made in the apical four-chamber view. Extensive adherence of more than half of the anterosuperior leaflet to the ventricular myocardium makes a successful repair unlikely. A single central jet of regurgitation is more easily eliminated than multiple regurgitant orifices. Even when there is a significant amount of leaflet tissue, direct muscular insertions from the ventricular free wall into the body of the anterosuperior leaflet can make repair impossible. The functional impact of the malformation of the RV and TV should be determined. Anatomic and functional severities are usually similar, but they are not always the same. For example, a patient can have a severe anatomic displacement with EA but only mild functional impairment. This generally occurs if the interatrial communication is small, the displaced valve is relatively competent, and the myocardium is only mildly dysfunctional. Both aspects of severity play an important role in determining the functional state, prognosis, and reparability of the TV. The degree of RA and RV enlargement and functional state of the RV myocardium should also be defined. Other important features include the degree of dilation of RVOT, the presence and size of any ASD, and the degree of transvalvar regurgitation. The left ventricular myocardium has also been described as being abnormal in a significant number of patients with EA. Therefore, quantitative evaluation of LV performance should also be a routine component of the echocardiographic evaluation in EA patients. VSD and pulmonary stenosis may also be associated with EA. Doppler and color flow echocardiographic



(a)



(b)

Figure 2. (a) Echocardiographic view (four-chamber view, apex up) of a patient with Ebstein's anomaly showing a displaced septal leaflet (arrow). (b) The anterior leaflet is severely tethered and nearly immobile. The functional right ventricle (RV) is small. aRV indicates atrialized right ventricle; LA, left atrium; LV, left ventricle; and RA, right atrium.

assessment can help determine hemodynamic alterations such as valvar regurgitation and intracardiac shunting [13, 17, 24, 40]. An echocardiogram shows the displacement septal leaflet of TV and the anterosuperior leaflet which is the largest, redundant and contains fenestrations that led to tricupid regurgitations **Figure 3**.

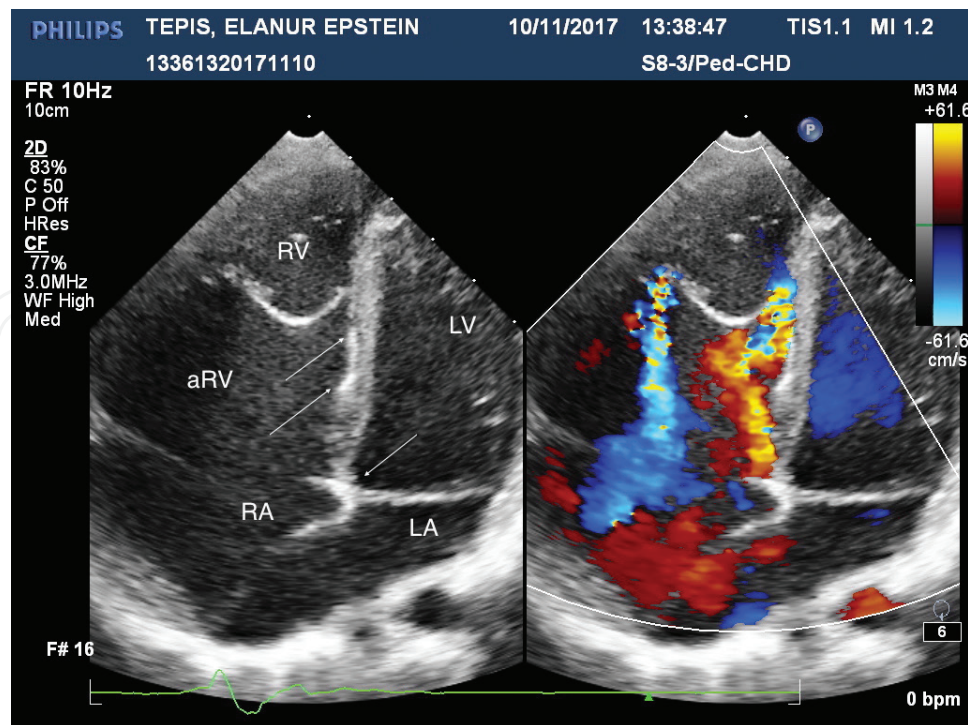


Figure 3. An echocardiogram (four-chamber view, apex up) showing the displacement of septal leaflet (in the right hand panel), anterior leaflet fenestrations, and tricuspid regurgitations (in the left hand panel). The hinge point of the normal septal tricuspid leaflet is positioned slightly toward the cardiac apex relative to the septal hinge point of the anterior mitral leaflet. This displacement is exaggerated in hearts with Ebstein's malformation, as shown in the image (outlined by the arrow, in the right hand panel). This can be quantitated by the displacement index, dividing the distance between the valvar insertions divided by the body surface area. A value of greater than 8 mm/m² is diagnostic of Ebstein's malformation. It should be noted that the valvar leaflets are also abnormal in Ebstein's malformation. LA, left atrium; LV, left ventricle; RA, right atrium; RV, right ventricle.

Echocardiography also plays an important role in the intraoperative and postoperative assessment of adequacy of TV repair or replacement. The most important use of intraoperative echocardiography is the immediate evaluation of the repaired valve functions. The postoperative examination is used to assess prosthetic valvar function, the changes in right and left ventricular functions and to exclude significant residual atrial level shunting. Postoperative echocardiography is also important to evaluate the adequacy of the surgical repair, presence of pericardial or pleural effusion, mediastinal hematoma, intracardiac thrombus, and the degree of residual tricuspid regurgitation or tricuspid stenosis. The flow can rarely be compromised in the RCA because of its proximity to the plicated portion of the aRV [13, 41].

10.3.1. Prenatal detection of Ebstein's malformation

Echocardiography can accurately define the EA features in the fetus. Characteristics related with the early neonatal mortality include marked enlargement of the right heart, severe tethering of the anterosuperior leaflet, left ventricular compression, and associated lesions as pulmonary atresia [42]. Pulmonary hypoplasia develops as a result of severe cardiomegaly and hydrops with pleural and pericardial effusions. Detection of rhythm disturbances, such as supraventricular tachycardia, should be attempted at the time of fetal echocardiography due

to its contribution to the development of hydrops. If the ratio of the combined right atrial and atrialized ventricular area compared to the combined area of the functional right ventricle and left heart is greater than one, fetal or neonatal outcome is very poor. Other fetal or neonatal findings associated with increased risk of mortality were a larger ASD, functional or anatomic pulmonary atresia, or reduced LV function [40–42].

10.4. Cardiac catheterization and hemodynamics

Diagnostic cardiac catheterization is rarely necessary in EA patients, except for preoperative coronary angiography or diagnosis of the associated cardiac anomalies. RV and pulmonary artery pressures are usually normal, even if the RV end-diastolic pressure is increased. RA pressure may be normal, despite severe TV regurgitation, especially if the right atrium is markedly dilated. Oximetry may show systemic arterial desaturation in the presence of an interatrial communication and right-to-left shunting [13, 14].

10.5. Cardiac magnetic resonance imaging

Cardiac magnetic resonance imaging (CMRI) is used for the quantitative measurement of right atrial and ventricular size and systolic function in Ebstein's patient. Axial imaging is a more reliable analysis for defining the disease severity [41]. Cardiac magnetic resonance imaging of a patient with severe Ebstein's anomaly showing displacement of septal leaflet, atrialized right ventricle (ARV) and small functional right ventricle is shown in **Figure 4**, septal bowing in **Figure 5**.

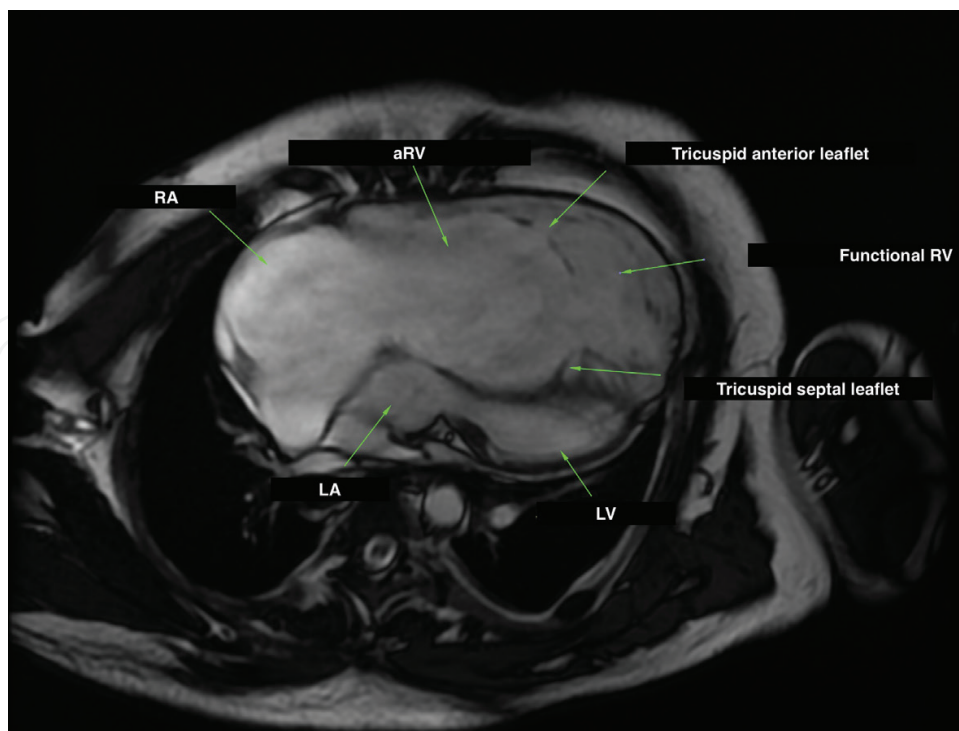


Figure 4. Cardiac MRI of a patient with Ebstein's anomaly showing displacement of septal leaflet, atrialized right ventricle (ARV) and small functional right ventricle (fRV); LA, left atrium; LV, left ventricle; and RA, right atrium.

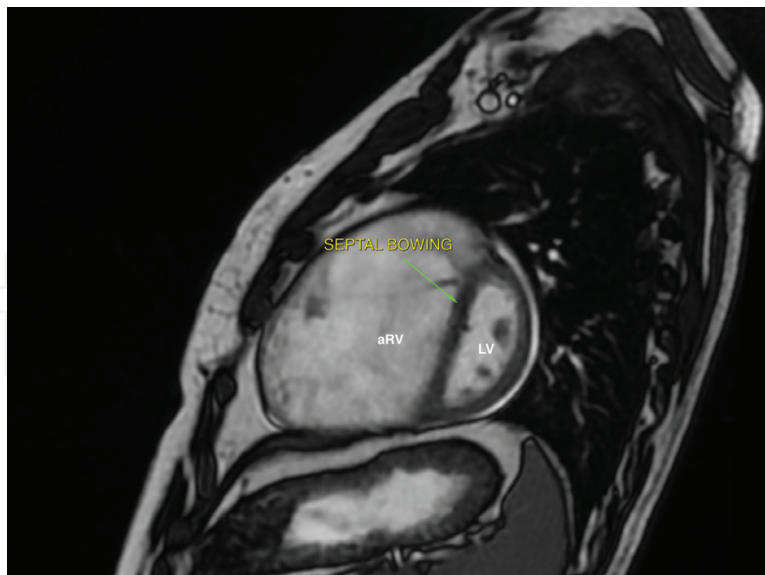


Figure 5. An example of a cardiac MRI showing septal bowing in short axis views. (Used with permission of the Sonomed Imaging Center).

11. Management

11.1. Medical treatment

Any patient with EA needs to be evaluated regularly by a cardiologist who has expertise in congenital heart disease. Prophylaxis for endocarditis is recommended despite its low risk. In neonates, congestive heart failure or profound cyanosis may be substantial. Medical therapy is the initial and preferred line of treatment. However, failure in weaning from the ventilator or persistent metabolic abnormalities often result in the need for operation. Patients with EA and cardiac failure who are not candidates for surgery are treated with standard cardiac failure therapy, including diuretics and digoxin. The efficacy of angiotensin-converting enzyme inhibitors in the patients with right-sided heart failure is unproved. Medical management of arrhythmias should be individualized and combined with operative or catheter-based intervention.

11.2. Catheter ablation

Electrophysiological evaluation and radiofrequency ablation of symptomatic accessory pathways should be performed when feasible in EA patients with tachyarrhythmias. Catheter ablation has a lower success rate in patients with an accompanying anomaly than in those with structurally normal hearts, and the risk of recurrence is increased [45, 46]. Supraventricular tachyarrhythmia associated with EA can also be ablated at the time of operative repair [45].

Tachycardia mediated via an accessory pathway is very common. Ten percent of the patients have other mechanisms for their tachyarrhythmias. The pathways are right-sided or septal in the majority of patients with reentrant arrhythmias, with only 4% being left-sided. Thirty percent of the patients may have multiple pathways. Radio-frequency ablation is able to eliminate

the tachycardia in almost 90% of cases, depending on its mechanism; however, recurrence is common. Long-term success is achieved in only one-third of the cases [15, 46–48].

11.3. Surgical treatment

11.3.1. *Indications for operation*

Children who have survived infancy generally remain asymptomatic for several years. The surgery can be postponed until symptoms appear, cyanosis becomes evident, or paradoxical emboli occur. Deliberations about an operation should begin if evidence of deterioration exists, such as progressive increase in right heart size, reduction in systolic function, or appearance of ventricular or atrial tachyarrhythmias. Indications for operation in the symptomatic neonates include severe cyanosis, GOSE of three or four with mild cyanosis, cardiothoracic ratio > 80% and severe TR. However, in older ages, operation is clearly indicated if the symptoms progress to New York Heart Association functional class III or IV and medical management has little to offer. A biventricular reconstruction is feasible if the LV is functionally normal, enough RV cavity is present and TV morphology is suitable. A 1.5 ventricle repair can be applied to the patients with the RV failure. Heart transplantation is reserved for the patients with severe biventricular dysfunction.

Some patients with cyanosis on exercise, who have a shunt at the atrial level but only mild or moderate regurgitation of the TV, may benefit from device closure to alleviate cyanosis and to prevent paradoxical emboli. Some centers commonly perform such procedures either as a staged approach or for long-term palliation [50]. The degree of TV regurgitation must be assessed carefully because closure of an ASD alone may worsen RV dysfunction.

11.3.2. *Surgical options*

A variety of surgical methods were introduced in the treatment of Ebstein's anomaly. Those treatments included a TV repair or replacement for the principle element in the treatment of Ebstein's anomaly and additional concomitant procedures for the correction of comorbid anomalies such as ablation of accessory conduction pathways, resection or plication of the atrialized right ventricle, application of 1.5-ventricular repair (bidirectional cavo-pulmonary shunt), and single-ventricle repair for advanced right ventricular dysfunction. Heart transplantation is suggested for the patients with severe left ventricular dysfunction. Neonatal operation has high operative mortality, whereas operation performed beyond infancy and into adulthood has low operative mortality. Late survival and quality of life for hospital survivors are excellent for the majority of patients in all age brackets [51–54].

12. Conclusion

Ebstein's anomaly is a complex congenital anomaly with a wide anatomic and clinical spectrum. Management is complex and must be individual because of the different anatomic and hemodynamic variables, and associated malformations, in Ebstein's anomaly. These patients

are evaluated by a cardiologist who has expertise in congenital heart disease. Developing better management strategies and survival of patients with this anomaly will continue to improve.

Author details

Sinem Altunyuva Usta¹, Ayşe İnci Yıldırım^{1*}, Aysu Türkmen Karaağaç² and Kaan Kırallı³

*Address all correspondence to: ayildirimmd@yahoo.com

1 Pediatric Cardiology, University of Health Sciences, Kartal Koşuyolu Research and Training Hospital, Istanbul, Turkey

2 Pediatrics, University of Health Sciences, Kartal Koşuyolu Research and Training Hospital, Istanbul, Turkey

3 Cardiovascular Surgery, University of Health Sciences, Kartal Koşuyolu Research and Training Hospital, Istanbul, Turkey

References

- [1] Mann RJ, Lie JT. The life story of Wilhelm Ebstein (1836-1912) and his almost overlooked description of a congenital heart disease. *Mayo Clinic Proceedings*. 1979;**54**:197-204
- [2] van Son JA, Konstantinov IE, Zimmermann V. Wilhelm Ebstein and Ebstein's malformation. *European Journal of Cardio-Thoracic Surgery*. 2001;**20**:1082-1085
- [3] Ebstein W. Ueber einen sehr seltenen Fall von Insufficienz der Valvula tricuspidalis, bedingt durch eine angeborene hochgradige Missbildung derselben. *Archives of Anatomy and Physiology*. 1866:238-255
- [4] Engle MA, Payne TP, Bruins C, Taussig HB. Ebstein's anomaly of the tricuspid valve: Report of three cases and analysis of clinical syndrome. *Circulation*. 1950;**1**:1246-1260
- [5] Soloff LA, Stauffer HM, Zatuchni J. Ebstein's disease: Report of the first case diagnosed during life. *The American Journal of the Medical Sciences*. 1951;**222**:554-561
- [6] Watson H. Natural history of Ebstein's anomaly of tricuspid valve in childhood and adolescence: An international co-operative study of 505 cases. *British Heart Journal*. 1974;**36**:417-427
- [7] Attenhofer JC, Connolly H, O'Leary P. Occurrence of left ventricular myocardial dysplasia/noncompaction in patients with ebstein's anomaly. *Mayo Clinic Proceedings*. 2005;**80**:361-368
- [8] Dearani JA, Danielson GK. Ebstein's anomaly of the tricuspid valve. In: Mavroudis C, Backer CL, editors. *Paediatric Cardiac Surgery*. 3rd ed. Philadelphia, PA: Mosby; 2003. pp. 524-536
- [9] Lev M, Liebertson RR, Joseph RH, et al. The pathologic anatomy of Ebstein's disease. *Archives of Pathology*. 1970;**90**:334-343

- [10] Dearani JA, Danielson GK. Congenital heart surgery nomenclature and database project: Ebstein's anomaly and tricuspid valve disease. *The Annals of Thoracic Surgery*. 2000;**69**(suppl):S106-S117
- [11] Lamers WH, Viragh S, Wessels A, Moorman AF, Anderson RH. Formation of the tricuspid valve in the human heart. *Circulation*. 1995;**91**:111-121
- [12] Edwards WD. Embryology and pathologic features of Ebstein's anomaly. *Progress in Pediatric Cardiology*. 1993;**2**:5-15
- [13] Rigby ML, Penny D, Wernovsk AR. Ebstein Anomaly. In: Anderson RH, Baker EJ, editors. 3rd ed. Churchill Livingstone/Elsevier; 2010:713-730
- [14] Anderson KR, Zuberbuhler JR, Anderson RH, Becker AE, Lie JT. Morphologic spectrum of Ebstein's anomaly of the heart: A review. *Mayo Clinic Proceedings*. 1979;**54**:174-180
- [15] Khositseth A, Danielson GK, Dearani JA, Munger TM, Porter CJ. Supraventricular tachyarrhythmias in Ebstein anomaly: Management and outcome. *The Journal of Thoracic and Cardiovascular Surgery*. 2004;**128**:826-833
- [16] Danielsen GK, Driscoll DJ, Mair DD, Warnes CA, Oliver WC Jr. Operative treatment of Ebstein's anomaly. *The Journal of Thoracic and Cardiovascular Surgery*. 1992;**104**:1195-1202
- [17] Jost CH A, Connolly HM, Edwards WD, Hayes D, Warnes CA, Danielson GK. Ebstein's anomaly: Review of a multifaceted congenital cardiac condition. *Swiss Medical Weekly*. 2005;**135**:269-281
- [18] Brickner ME, Hillis LD, Lange RA. Congenital heart disease in adults: Second of two parts. *The New England Journal of Medicine*. 2000;**342**:334-342
- [19] Daliento L, Angelini A, Ho SY, Frescura C, Turrini P, Baratella MC, Thiene G, Anderson RH. Angiographic and morphologic features of the left ventricle in Ebstein's malformation. *The American Journal of Cardiology*. 1997;**80**:1051-1059
- [20] Benson LN, Child JS, Schwaiger M, Perloff JK, Schelbert HR. Left ventricular geometry and function in adults with Ebstein's anomaly of the tricuspid valve. *Circulation*. 1987;**75**:353-359
- [21] Saxena A, Fong LV, Tristram M, Ackery DM, Keeton BR. Late noninvasive evaluation of cardiac performance in mildly symptomatic older patients with Ebstein's anomaly of tricuspid valve: Role of radionuclide imaging. *Journal of the American College of Cardiology*. 1991;**17**:182-186
- [22] Castaneda-Zuniga W, Nath HP, Moller JH, Edwards JE. Left-sided anomalies in Ebstein's malformation of the tricuspid valve. *Pediatric Cardiology*. 1982;**3**:181-185
- [23] Attenhofer Jost CH, Connolly HM, Warnes CA, O'Leary P, Tajik AJ, Pellikka PA, Seward JB. Noncompacted myocardium in Ebstein's anomaly: Initial description in three patients. *Journal of the American Society of Echocardiography*. 2004;**17**:677-680
- [24] Attenhofer Jost CH, Connolly HM, O'Leary PW, Warnes CA, Tajik AJ, Seward JB. Left heart lesions in patients with Ebstein anomaly. *Mayo Clinic Proceedings*. 2005;**80**:361-368

- [25] Celermajer DS, Cullen S, Deanfield JE, Sullivan ID. Congenitally corrected transposition and Ebstein's anomaly of the systemic atrioventricular valve: Association with aortic arch obstruction. *Journal of the American College of Cardiology*. 1991;**18**:1056-1058
- [26] Dekker A, Mehrizi A, Vengsarkar AS. Corrected transposition of the great vessels with Ebstein malformation of the left atrioventricular valve: An embryologic analysis and two case reports. *Circulation*. 1965;**31**:119-126
- [27] Carpentier A, Chauvaud S, Mace L, Relland J, Mihaileanu S, Marino JP, Abry B, Guibourt P. A new reconstructive operation for Ebstein's anomaly of the tricuspid valve. *The Journal of Thoracic and Cardiovascular Surgery*. 1988;**96**:92-101
- [28] Celermajer DS, Bull C, Till JA, Cullen S, Vassillikos VP, Sullivan ID, Allan L, Nihoyannopoulos P, Somerville J, Deanfield JE. Ebstein's anomaly: Presentation and outcome from fetus to adult. *Journal of the American College of Cardiology*. 1994;**23**:170-176
- [29] Miller MS, Rao PN, Dudovitz RN, Falk RE. Ebstein anomaly and duplication of the distal arm of chromosome 15: Report of two patients. *American Journal of Medical Genetics. Part A*. 2005;**139A**:141e5
- [30] Correa-Villasenor A, Ferencz C, Neill CA, et al. Fort he Baltimore-Washington infant study group. Ebstein's malformation of the tricuspid valve: Genetic and enviromental-factors. *Teratology*. 1994;**50**:137-147
- [31] Walsh R, Rutland C, Thomas R, Loughna S. Cardiomyopathy: A systematic review of disease-causing mutations in myosin heavy chain 7 and their phenotypic manifestations. *Cardiology*. 2010;**115**:49e60
- [32] Ching YH, Ghosh TK, Cross SJ, Packham EA, Honeyman L, Loughna S, et al. Mutation in myosin heavy chain 6 causes atrial septal defect. *Nature Genetics*. 2005;**37**:423-428
- [33] Matsson H, Eason J, Bookwalter CS, Klar J, Gustavsson P, Sunnegårdh J, et al. A-cardiac actin mutations produce atrial septal defects. *Human Molecular Genetics*. 2008;**17**:256e65
- [34] Wright KN. Researchers Aim to Isolate Gene for Tricuspid Valve Dysplasia. Available from: <http://www.thelabradorclub.com/uploads/file/valvedysplasia.pdf>. [Accessed: March 3, 2016]
- [35] Andelfinger G, Wright KN, Lee HS, Siemens LM, Benson DW. Canine tricuspid valve malformation, a model of human Ebstein anomaly, maps to dog chromosome 9. *Journal of Medical Genetics*. 2003;**40**:320e4
- [36] de Lonlay-Debeney P, de Blois MC, Bonnet D, Amiel J, Abadie V, Picq M, et al. Ebstein anomaly associated with rearrangements of chromosomal region 11q. *American Journal of Medical Genetics* 1998;**80**:157e9
- [37] Postma AV, van Engelen K, van de Meerakker J, Rahman T, Probst S, Baars MJ, et al. Mutations in the sarcomere gene MYH7 in Ebstein anomaly. *Circulation. Cardiovascular Genetics*. 2011;**4**:43e50
- [38] Yuan S-M. Ebstein's anomaly: Genetics, clinical manifestations, and management. *Pediatrics and Neonatology*. 2017;**58**:211e215

- [39] Benson DW, Silberbach GM, Kavanaugh-McHugh A, Cottrill C, Zhang Y, Riggs S, Smalls O, Johnson MC, Watson MS, Seidman JG, Seidman CE, Plowden J, Kugler JD. Mutations in the cardiac transcription factor NKX2.5 affect diverse cardiac developmental pathways. *The Journal of Clinical Investigation*. 1999;**104**:1567-1573
- [40] Shiina A, Seward JB, Edwards WD, Hagler DJ, Tajik AJ. Two-dimensional echocardiographic spectrum of Ebstein's anomaly: Detailed anatomic assessment. *Journal of the American College of Cardiology*. 1984;**3**:356-370
- [41] Attenhofer Jost CH, Connolly HM, Dearani JA, Edwards WD, Danielson GK. Ebstein's anomaly. *Circulation*. 2007;**115**:277-285
- [42] Shinkawa T, Polimenakos AC, Gomez-Fifer CA, Charpie JR, Hirsch JC, Devaney EJ, Bove EL, Ohye RG. Management and long-term outcome of neonatal Ebstein anomaly. *The Journal of Thoracic and Cardiovascular Surgery*. 2010;**(2)**:354-358
- [43] MacLellan-Tobert SG, Driscoll DJ, Mottram CD, Mahoney DW, Wollan PC, Danielson GK. Exercise tolerance in patients with Ebstein's anomaly. *Journal of the American College of Cardiology*. 1997;**29**:1615-1622
- [44] Driscoll DJ, Mottram CD, Danielson GK. Spectrum of exercise intolerance in 45 patients with Ebstein's anomaly and observations on exercise tolerance in 11 patients after surgical repair. *Journal of the American College of Cardiology*. 1988;**11**:831-836
- [45] Ituralde P, Nava S, Salica G, Medeiros A, Colin L, Gozaes M. Electrocardiographic characteristics of patients with Ebstein's anomaly before and after ablation of an accessory Atrioventricular pathway. *Journal of Cardiovascular Electrophysiology*. 2006;**17**:1332-1336
- [46] Hebe J. Ebstein's anomaly in adults: Arrhythmias: Diagnosis and therapeutic approach. *The Thoracic and Cardiovascular Surgeon*. 2000;**48**:214-219
- [47] Cappato R, Schluter M, Weiss C, Antz M, Koschyk DH, Hofmann T, Kuck KH. Radiofrequency current catheter ablation of accessory atrioventricular pathways in Ebstein's anomaly. *Circulation*. 1996;**94**:376-383
- [48] Chetaille P, Walsh EP, Friedman JK. Outcomes of radiofrequency catheter ablation of atrioventricular reciprocating tachycardia in patients with congenital heart disease. *Heart Rhythm*. 2004;**1**:168-173
- [49] Greason KL, Dearani JA, Theodoro DA, Porter CB, Warnes CA, Danielson GK. Surgical management of atrial tachyarrhythmias associated with congenital cardiac anomalies: Mayo Clinic experience. *Seminars in Thoracic and Cardiovascular Surgery. Pediatric Cardiac Surgery Annual*. 2003;**6**:59-71
- [50] Atiq M, Lai L, Lee KJ, Benson LN. Transcatheter closure of atrial septal defects in children with a hypoplastic right ventricle. *Catheterization and Cardiovascular Interventions*. 2005;**64**:112-116
- [51] Dearani JA, Danielson GK. Tricuspid valve repair for Ebstein's anomaly. *Operative Techniques in Thoracic and Cardiovascular Surgery*. 2003;**8**:188-192

- [52] Dearani JA, Danielson GK. Ebstein's anomaly. In: Sellke FW, del Nido PJ, Swanson SJ, editors. Sabiston and Spencer Surgery of the Chest. 7th ed. Vol. 2. Philadelphia, PA: Elsevier Saunders; 2005;2223-2235
- [53] Chauvaud S, Berrebi A, d'Attellis N, Mousseaux E, Hernigou A, Carpentier A. Ebstein's anomaly: Repair based on functional analysis. The European Journal of Cardio-Thoracic Surgery. 2003;**23**:525-531
- [54] Ullmann MV, Born S, Sebening C, Gorenflo M, Ulmer HE, Hagl S. Ventricularization of the atrialized chamber: A concept of Ebstein's anomaly repair. The Annals of Thoracic Surgery. 2004;**78**:918-924