

We are IntechOpen, the world's leading publisher of Open Access books Built by scientists, for scientists

6,900

Open access books available

185,000

International authors and editors

200M

Downloads

Our authors are among the

154

Countries delivered to

TOP 1%

most cited scientists

12.2%

Contributors from top 500 universities



WEB OF SCIENCE™

Selection of our books indexed in the Book Citation Index
in Web of Science™ Core Collection (BKCI)

Interested in publishing with us?
Contact book.department@intechopen.com

Numbers displayed above are based on latest data collected.
For more information visit www.intechopen.com



Huge Pituitary Adenomas: Dedicated Surgical Technique and Indications for Extent of Tumour Removal in the Modern Era

Mario Francesco Fraioli, Andrea Pagano,
Bernardo Fraioli and Pierpaolo Lunardi

Additional information is available at the end of the chapter

<http://dx.doi.org/10.5772/intechopen.77269>

Abstract

Transsphenoidal surgery is the most indicated approach not only for small and large pituitary adenomas but also for huge ones. A modified transsphenoidal technique to remove huge pituitary adenomas with marked suprasellar extension (4–8 cm of maximum diameter) resulted very useful in authors' experience. The technique allowed avoiding the occurrence of a precocious descent of the suprasellar cisternal plane into the sellar plane during tumor removal and its related dangerous consequences. Technique was performed opening at the beginning only the lateral parts of peritumoral dura mater, and after removal of lateral parts of the tumor, the central part of peritumoral dura mater was opened and the central intrasellar and suprasellar parts of the tumor were removed. Comparing the results to similar patients operated by the same authors with standard surgical technique, we observed that total removal was accomplished in 64% of patients treated with modified technique than 45% of patients treated with standard transsphenoidal surgery. Moreover, better results were achieved concerning intraoperative CSF leak, postoperative CSF fistula, and average time of postoperative stay in hospital. For invasive dumbbell-shaped pituitary adenomas, particular therapeutic plans are necessary.

Keywords: pituitary adenoma, transsphenoidal surgery, cerebrospinal fluid fistula, huge adenomas, cranial base reconstruction

1. Introduction

Voluminous pituitary adenomas with marked suprasellar extension can be effectively treated by transsphenoidal surgery [1], except for rare cases in which transcranial approach should

be performed [2]. Regardless tumor size, invasive or noninvasive behavior of the adenoma is a crucial factor that influences extent of tumor removal. Huge noninvasive pituitary adenomas are extra-arachnoid tumors, compressing and displacing suprasellar nervous and vascular structures, and adequate surgical technique allows total or gross total removal avoiding complications (intraoperative cerebrospinal fluid fistula, vascular damages, etc.). On the other hand, invasive dumbbell-shaped tumors pass through diaphragm sellae and arachnoid membrane without compressing or displacing but encasing vascular and nervous structures. Removal of suprasellar portions of these last tumors is very dangerous because critical structures are encountered before suprasellar portion of the tumor, differently from noninvasive tumors, which displace neurovascular structures above the tumor.

2. Main body

Out of more than 1400 pituitary adenomas operated on in our institute (by Bernardo Fraioli, Chief of Department of Neurosurgery 1991–2014 and Mario F Fraioli, Professor of Neurosurgery, University of Rome “TorVergata”) from 1993 to 2015, we selected 138 patients operated from 2005 to 2015 for huge pituitary adenoma with marked suprasellar extension (sized 4–7.5 cm of max. diam.).

2.1. Patients population and clinical data

Patients' age was between 17 and 81 years, with average age of 54.4 years; 77 were female and 61 male. All patients presented visual disturbances, consisting in bitemporal hemianopsia in all ones, visual acuity deficit in 103 patients, and abducens and oculomotor nerve palsy in 11 and 5 patients, respectively. Symptomatic hypopituitarism was registered in 69 patients, while subclinical hormonal deficits were discovered in other 45 patients; these last patients were treated with substitutive hormonal therapy before and after surgery. Normal hormonal status, although if corresponding to the inferior limits of the normal reference range, was evident in the other 24 patients.

2.2. MR tumors characteristics

At preoperative MRI, enlargement of sella turcica and suprasellar extension was present in all tumors; prevalent median extension was present in 121, while lateral extension into the temporal lobe was evident in 12 and anterior frontal extension in 5 patients; in 127 patients, optic chiasm was above displaced, while in the other 11, it was encased into the tumor. A1 tracts of anterior cerebral arteries were superiorly and laterally displaced (**Figure 1**) in 131, while in the other 7 patients, they were encased in the tumor (**Figures 2 and 3**). Unilateral and bilateral cavernous sinus invasion were evident in 39 and 6 adenomas, respectively. In invasive tumors, angio-MR images show normal position of A1 tracts of anterior cerebral arteries (**Figure 2**), differently from huge noninvasive adenomas which cause displacement of vascular (**Figure 1**) and nervous structures.

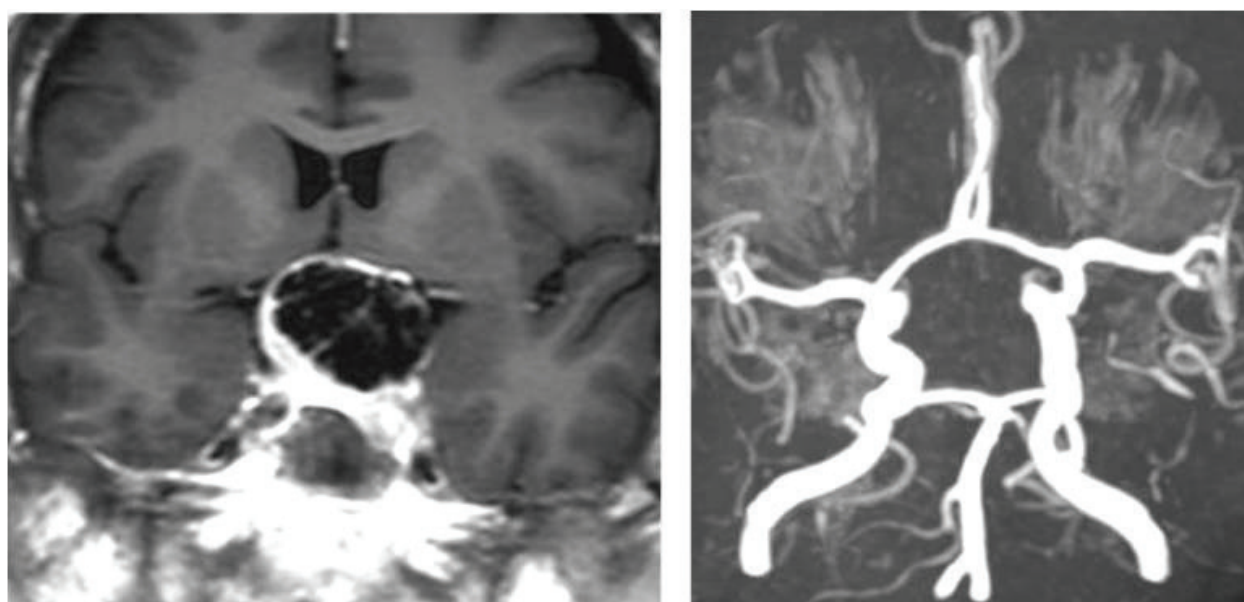


Figure 1. Invasive voluminous hemorrhagic noninvasive pituitary adenoma. Angio-MR image shows superior displacement of A1 tracts of anterior cerebral arteries.

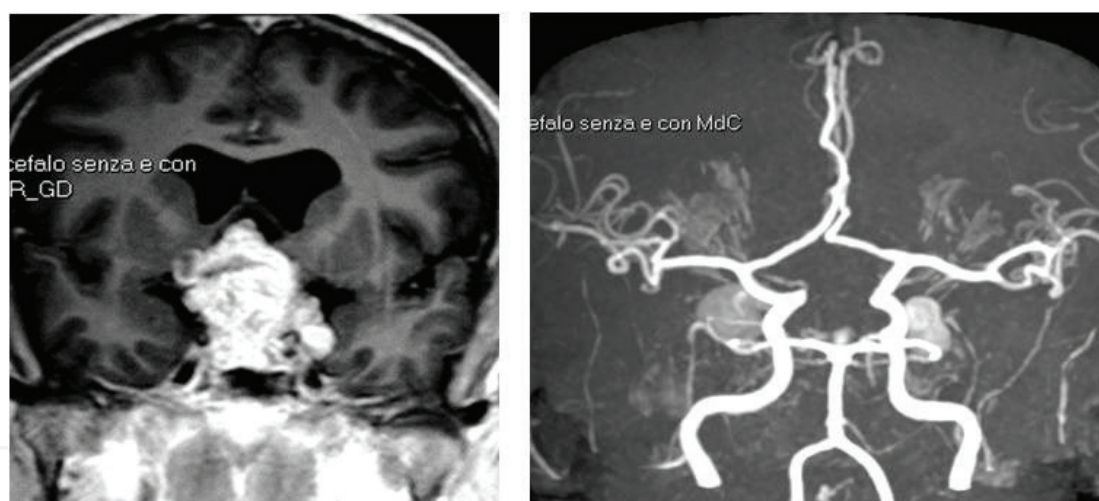


Figure 2. Invasive pituitary macroadenoma with marked suprasellar extension. Angio-MR image shows normal position of A1 tracts of anterior cerebral arteries.

2.3. Therapeutic strategy

Considering that adenomas of this series were invasive, and of large size, our therapeutic strategy was to remove tumor as most as possible, avoiding to remove invasive tumoral component strictly connected to crucial neurovascular structures, which are often encased into the tumor; hazardous maneuvers were avoided, such as other authors reported for other benign tumors of sellar-suprasellar compartment [3]. In the cases of huge invasive adenomas with involvement of optic chiasm, A1 tracts of anterior cerebral arteries and diencephalus crossed the tumors and

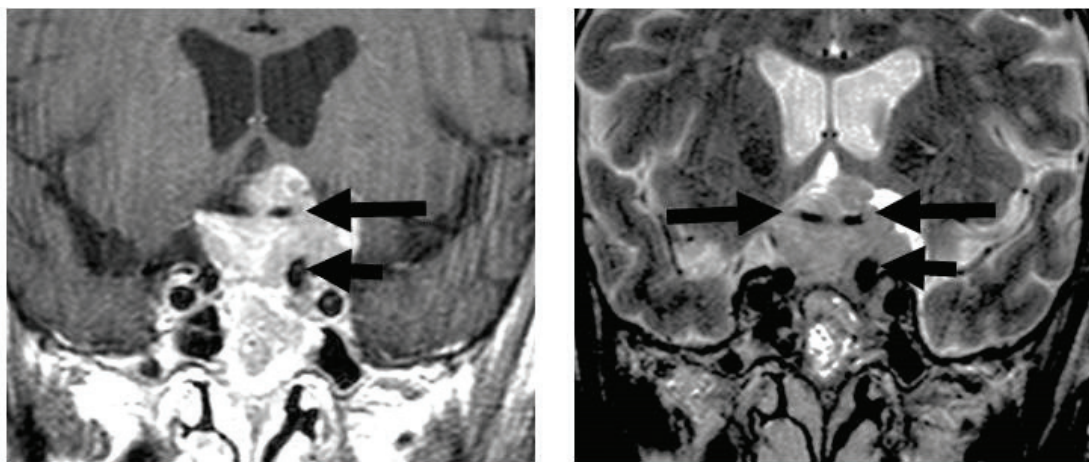


Figure 3. Invasive pituitary macroadenoma. T1 postcontrast coronal and T2 coronal images: A1 tracts of anterior cerebral arteries (long black arrows) and vestigial tract of internal carotid artery (short black arrow) are encased by the tumor.

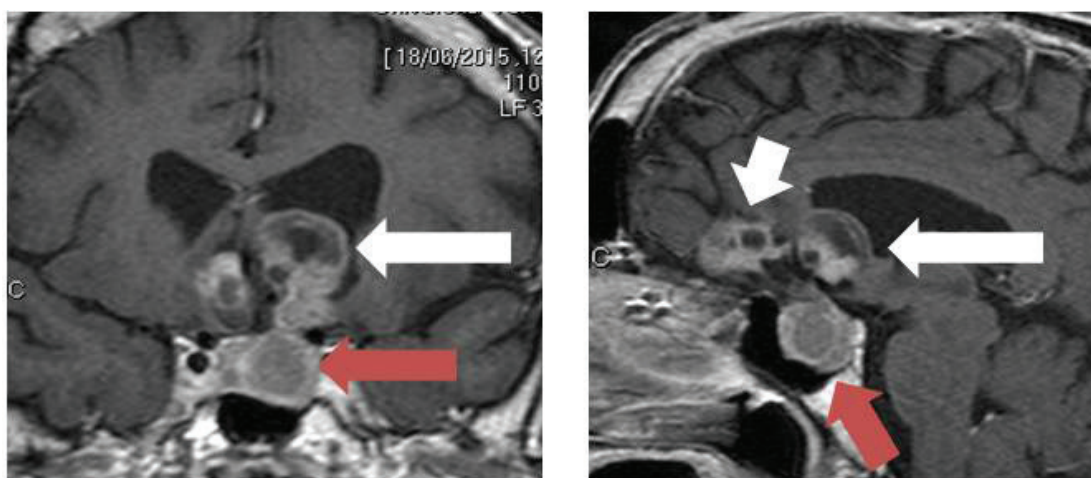


Figure 4. Invasive huge pituitary adenoma. T1 postcontrast coronal and sagittal images show intrasellar component of adenoma (red arrows), suprasellar diencephalic tumor component (long white arrows), and anterior frontal component of adenoma (short white arrow in sagittal slice).

were not above displaced (**Figures 3 and 4**): we programmed a staged transsphenoidal surgery, as other authors [4], programming the second stage when the tumor remnant would have descended into the sellar cave. In order to perform the second programmed stage, neuronavigator was employed, as previously described, because anatomical landmarks could have become unclear because of the previous operation. For pituitary adenomas invading cavernous sinuses (**Figure 5**) and for tumors with anterior or lateral extension to frontal or temporal lobe (**Figure 4**), respectively, therapeutic strategy was to remove the median intrasuprasellar part of tumor, without performing access to cavernous sinus and without performing extensive transsphenoidal approach or transcranial approach to remove frontal and temporal tumor portions. Therapy for these tumoral portions was hypofractionated stereotactic radiotherapy (HSRT).

2.4. Surgery

Transsphenoidal surgery was performed through submucosal approach through one nostril, in 38 cases with the aid of angulated endoscope.

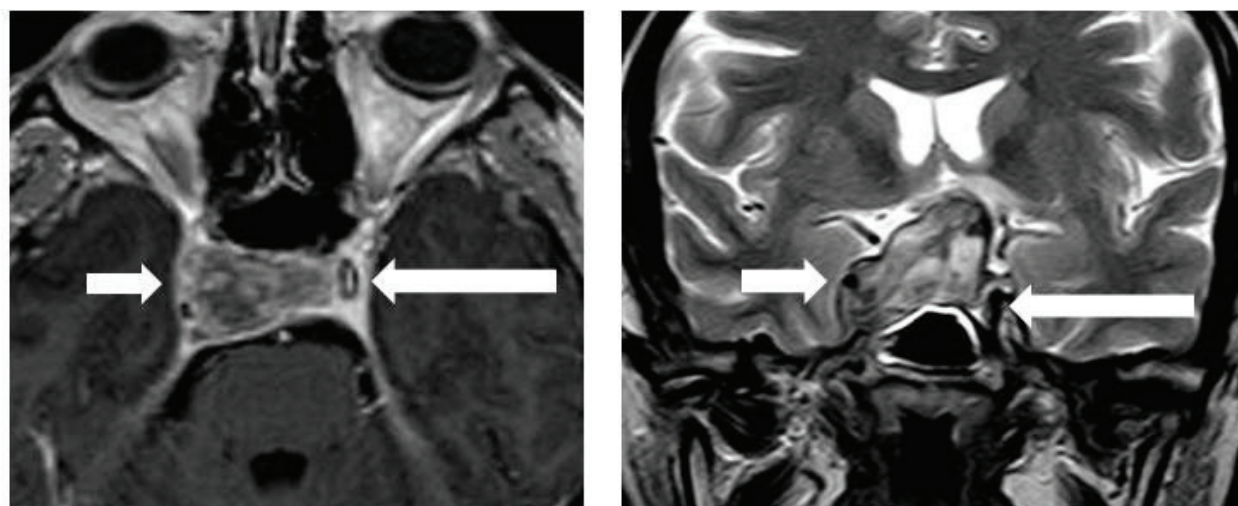


Figure 5. Hemorrhagic pituitary adenoma. T1 postcontrast Axial and T2 coronal image: invasion of right cavernous sinus (short black arrow) by adenoma is evident, while left cavernous sinus (long black arrow) is not invaded by the tumor.

The supine position [5] was used in all patients. In 71, the microsurgical approach was endoscope assisted. As previously described, in these voluminous tumors, if surgical removal starts from the central part of the adenoma, the suprasellar cisternal plane can precociously descend into the sella turcica, compressing portions of the tumor toward the lateral sides of the operative field (**Figure 6A**); therefore, these parts of tumor become difficult to remove, also with the aid of the endoscope. In this case, it is frequent damaging the suprasellar cisternal plane (intraoperative CSF leak) and the related possible complications as stretch of the optic chiasm and postoperative rhinoliquorrhea. The modified technique for these voluminous adenomas consisted in opening at the beginning only the lateral parts of peritumoral dura mater (**Figure 6B**). In this way, the central part of the dura mater remains in support of the central part of tumor and suprasellar cisternal plane. After removal of lateral parts of the tumor, the central part of peritumoral dura mater is opened and the central intrasellar and suprasellar parts of the tumor are removed [6].

Peritumoral anterior and/or posterior prepontine dura mater was infiltrated in all patients; surgical removal was conducted in each patient until the suprasellar arachnoidal plane, which was, at operative microscopic/endoscopic view, infiltrated by the tumor in 98 cases. Suprasellar arachnoidal plane was preserved in all patients but four, so that in these last patients, meticulous reconstruction of skull base defect was necessary to avoid postoperative rhinoliquorrhea. At operative view, the tumor in 39 patients invaded lateral sides of operative field that were medial wall of cavernous sinuses. Four patients were submitted, during an average period of 12 months, to two-staged transsphenoidal surgery; after first operation, because tumor remnant was voluminous and too close to optic chiasm, a second operation was performed after several months to achieve a satisfactory optic nerve decompression and possibility to perform a safe radiotherapeutic treatment. In one patient affected by macroadenoma with encasement of optic chiasm and A1 tracts of anterior cerebral arteries without displacement, the intrasellar and a quite small suprasellar portion of tumor were removed at surgery, and 6 months after surgery, the tumor remnant descended into the sellar cave.

Concerning the 12 and 5 patients presenting respectively temporal and frontal tumor extension, surgical strategy was to remove only the intrasellar and suprasellar median tumoral portion to decompress optic chiasm; MRI was performed after 1 month, and in no case, the

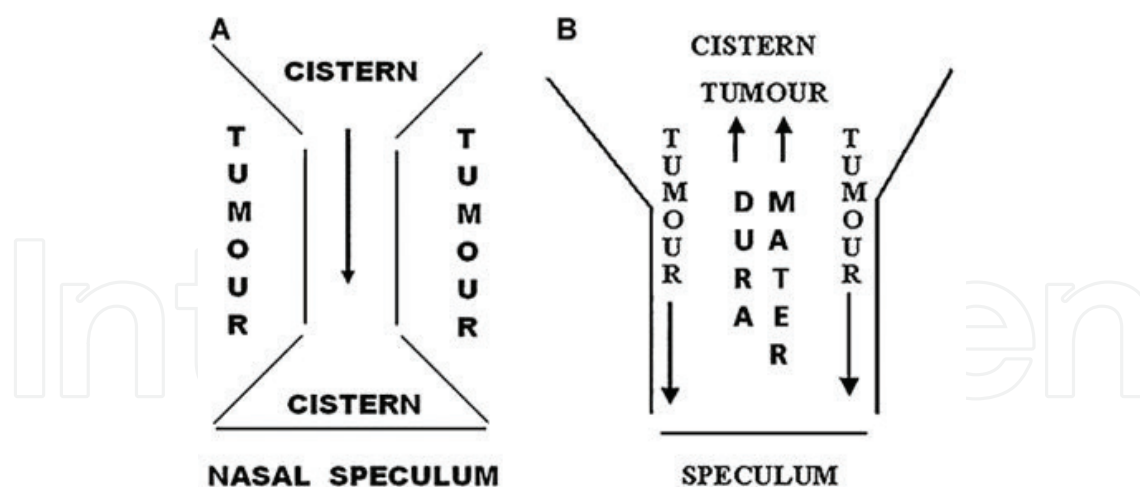


Figure 6. (A) Drawing of possible precocious intraoperative empty sella during inadequate transsphenoidal removal of huge pituitary adenomas: if tumor removal starts with the intrasellar and suprasellar central parts of the adenoma, the suprasellar cisternal plane can precociously go down into the sella turcica or even sphenoidal sinus, laterally compressing parts of the tumor, which should be difficult to be removed. (B) Drawing of the surgical technique. The lateral parts of the tumor are initially removed (long black arrows); the central part of the tumor at the beginning is left in situ in support of the cisternal plane.

lateral/frontal tumor remnant descended into the sella turcica. Hypofractionated radiotherapy was programmed also in these patients.

2.5. Postoperative radiotherapy

The treatment of choice for this series of patients was hypofractionated stereotactic radiotherapy (HSRT); the treatment was performed in all patients between 1 and 4 months after surgery. Only in one patient, radiotherapy was performed 5 years after surgery, although a clear initial regrowth had been documented after the second year of follow-up, but the patient during the years after surgery was controlled only by other specialists and the progressive tumor regrow was not well enlightened. HSRT was then performed when the tumor had become quite large and occupied the entire sellar cave but without suprasellar extension; patient preferred radiotherapy than a new operation. Radiotherapeutic centering was performed in all patients through 1.5 tesla MR images fused with CT images, and target was contoured on fused images. Relocatable stereotactic frame was employed for individuation of stereotactic coordinates; thermoplastic mask with bite was used to achieve the same head positioning at each fraction, but patient positioning was controlled through i-view system by radiographic anatomical landmarks. Organs at risk were contoured, and particular attention was paid to the dose adsorbed by optic chiasm, carotid arteries, intracavernous cranial nerves, diencephalus, and hippocampus. Radiotherapeutic dose administered was 40 Gy, delivered through 10 biweekly fractions. Concerning patients with suprasellar temporal and frontal tumor remnant, a complex radiotherapeutic treatment was planned and performed, delivering radiation dose both in the intrasellar operative field and at the anterior/lateral suprasellar tumor remnant, sparing in particular the optic chiasm between the two tumoral remnants, thanks to intensity-modulated radiotherapy (IMRT; **Figure 7**).

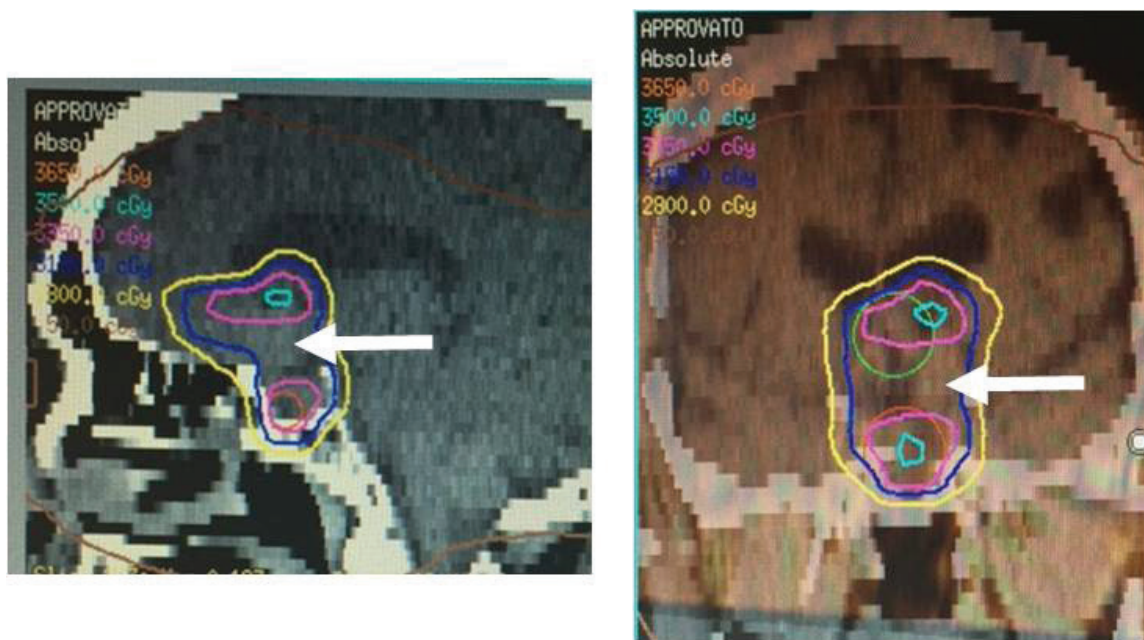


Figure 7. Complex radiotherapeutic treatment concerning case of **Figure 4**. Two targets were performed to treat intrasellar tumoral remnant and diencephalic tumor component, sparing neurovascular component.

Before radiotherapy, blood hormone dosages were assessed to test endocrinological status. Moreover, cognitive status was tested before and after radiotherapy once a year for the first 3 years and once at 2 years afterward, through neuropsychological test such as Mini-mental test, Rey-Osterrieth test (ROCF), Raven test, Stroop test, and verbal fluency test (COWAT).

Radiotherapeutic dose adsorbed by hippocampus was in all patients very low and however considerably less than the radiotherapeutic dose responsible of intellectual damages.

2.6. Results

In general, the modified technique allowed to achieve in our experience better results concerning intraoperative CSF leak (2.4% instead of 22.5%) and postoperative CSF fistula 0% instead of 7.4%), average time of postoperative stay in hospital (4.3 days instead of 8.2 days).

After surgery, all patients affected by visual acuity and campimetry impairment presented precocious improvement; out of the 16 patients affected by diplopia due to 3rd/4th/6th cranial nerve palsy, 14 patients presented total recovery during an average period of 4 weeks, one patient presented improvement and another remained unchanged. Postoperative hormonal status remained unchanged in all patients: neither improvement nor worsening than preoperative hormonal status occurred after surgery, and patients with preoperative hypopituitarism were submitted to hormonal substitutive therapy. Two patients presented rhinoliquorrhea after 2 and 5 weeks, respectively; they were treated by instillation of fibrin glue into the sphenoidal sinus under CT control [7].

One patient presented transitory sixth cranial nerve palsy with diplopia and complete recovery occurred after 2 months.

Concerning tumor removal, apparent total removal was performed in 51 patients, while in other 37, gross total removal was accomplished; tumor remnants located into the cavernous sinuses (45 cases), in frontal (5 cases), and temporal lobes (12 cases) were left in situ. During an average follow-up period of 9.7 years, after our protocol represented by conservative surgery followed by HSRT, only one patient presented a hemorrhagic tumor regrowth, 4 years after radiotherapy, with optic chiasm compression; transsphenoidal reoperation was performed and patient recovered visual deficit, and after 4 years from second surgery, no new tumor recurrence/regrow was registered. Leaving in situ small tumoral remnant adherent to suprasellar critical structures (diencephalus, A1 tracts of ACA), we often observed a progressive descent of tumoral remnant into the sellar cave (**Figure 8**), with possibility to perform a second transsphenoidal stage or radiotherapy.

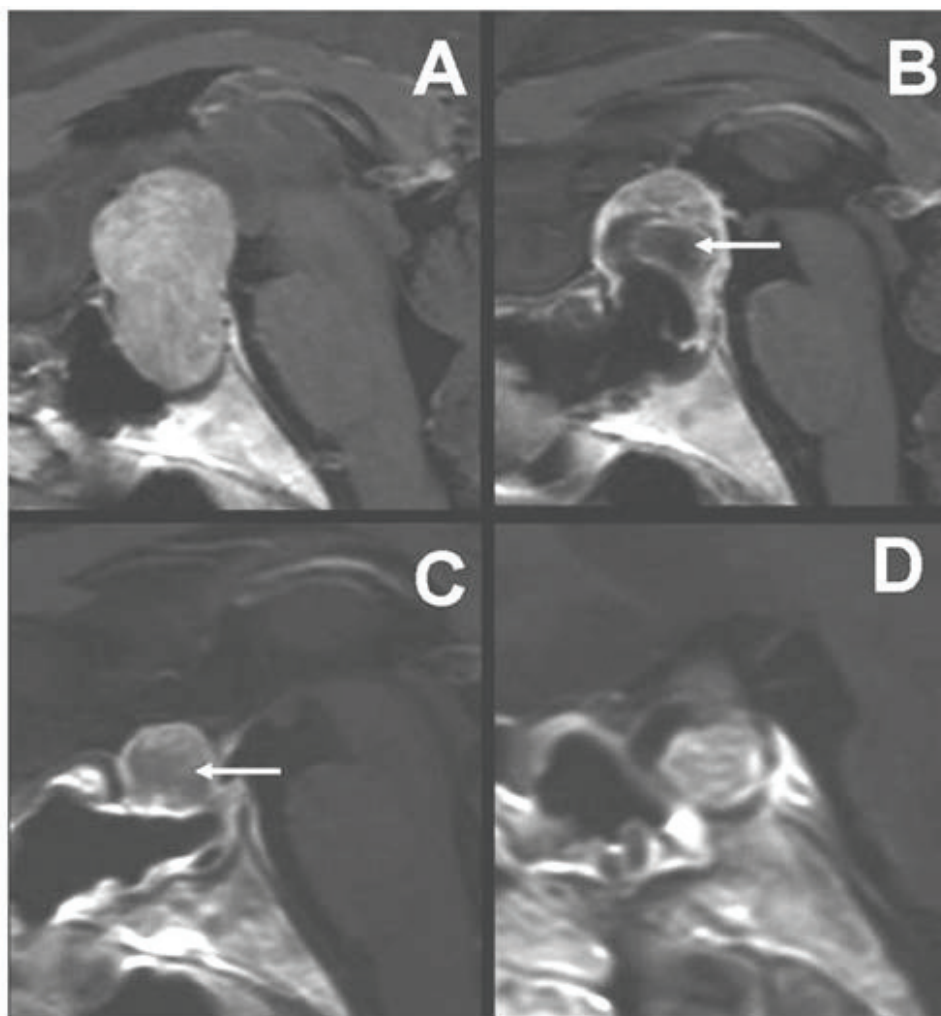


Figure 8. Case of huge pituitary adenoma with marked suprasellar extension operated on by transsphenoidal approach. In this case, a small suprasellar remnant was left in situ because it was very adherent to suprasellar structures. There was no occurrence of CSF leak during surgery, so that no particular material of apposition was put in the operative field, remaining free space under the suprasellar remnant. (A) Preoperative T1 sagittal postcontrast MRI. (B) Postoperative postcontrast MRI performed 5 days after surgery showing a small suprasellar remnant. It is noticeable a hypointensity area under the tumoral remnant (white arrow), representing free space under the tumoral remnant. (C) Postcontrast MRI performed 1 month after surgery; an initial descent of the tumoral remnant is evident and there is yet an area of hypointensity under the remnant itself (white arrow). (D) Postcontrast MRI performed 2 months after surgery: an ulterior descent into the sellar plane of the tumoral remnant is evident, with total decompression of suprasellar structures.

Concerning the 114 patients who presented preoperative hormonal deficit and therefore were under substitutive medical therapy, it should be noted that only in two of them, medical therapy with hydrocortisone was increased 6.4 and 8.1 years after HSRT; in the other, after an average follow-up period of 10.4 years, medical therapy remained unchanged, and quality of life was very satisfactory.

Regarding the 24 patients who were not affected by preoperative or postoperative hormonal deficit, in only one of them, replacement therapy with hydrocortisone and testosterone was necessary 6.7 years after HSRT. Three young female patients treated in our series 4, 6, and 7 years, respectively, after surgery and HSRT, experienced successful pregnancy.

Concerning neurocognitive status, no patient suffered from intellectual deterioration according to patients'/relatives' opinion and according to neurocognitive tests.

One patient presented rhinoliquorrhea after 2 months from radiotherapy, but he was treated conservatively with medical therapy (acetazolamide for 2 weeks), rest and life advices for 10 days with resolution.

No problems concerning trigemino-cardiac reflex [8, 9] were observed in this series.

2.7. Surgical findings vs. MR images

Concerning cavernous sinus invasion, intraoperative microsurgical/endoscopic view revealed a minor rate of cavernous sinus invasion than preoperative MR images. Moreover, operative view was the only possibility to detect dura mater infiltration and suprasellar arachnoidal infiltration by the tumor in many cases; this aspect was evident at preoperative MRI in those tumors which showed a clear invasive behavior (**Figure 4**). Intraoperative evidence of dura mater and suprasellar arachnoid infiltration significantly influenced our choice to perform postoperative hypofractionated radiotherapy.

2.8. Surgical removal of invasive pituitary adenomas

In consideration that pituitary adenomas are benign tumors, our first objective was to decompress neurological structures removing tumor as much as possible without causing new neurological deficit and without running high risks of life to remove small tumor remnants adherent to the suprasellar and laterosellar vital neurovascular structures. According to this objective, we did not perform tumor removal into the cavernous sinus and we did not perform any traction on the superior tumoral portion adherent to vital neurovascular structures (A1 tracts of anterior cerebral artery, diencephalus, optic chiasm), leaving in situ these small tumoral remnants. This conservative behavior allowed to achieve very satisfactory postoperative results in absence of neurological deficit; concerning tumoral remnant, postoperative MRI confirmed in all patients a progressive descent into the sellar cave of superior tumor remnants.

Our modified surgical technique is indicated for huge pituitary adenomas with marked suprasellar extension operated on by transsphenoidal surgery. The technique allows to prevent the occurrence of a precocious intraoperative descent of suprasellar cisternal plane and its related consequences above mentioned and to perform a tumor removal larger than

patients operated with standard technique. When intraoperative CSF leak occurs, the surgeon has to fill the sphenoidal sinus and the sella turcica with material of apposition [10, 11], and this situation precludes, or however delays, the progressive descent into the sella turcica of the suprasellar tumoral remnant in case of gross total removal when the suprasellar tumoral remnant is adherent to suprasellar structures. Moreover, intraoperative CSF leak exposes patients to the risk of a postoperative rhinoliquorrea and its related eventual complications (cephalalgia, pneumoencephalus, subdural hematoma, and meningitis). On the contrary, when intraoperative CSF leak does not occur, an eventual tumoral remnant can descend into the sella turcica after few weeks (**Figure 8**) because of the absence of excessive presence of material of apposition.

2.9. Indication to postoperative radiotherapy and side effects

Nowadays, there is not yet a unique indication and modality to perform postoperative radiotherapy [12–14]. Some centers consider immediate postoperative radiation therapy in an attempt to prevent tumor regrowth, but risk of complications such as hypopituitarism, cerebrovascular disease, potential neurocognitive dysfunction, and a low long-term risk of secondary intracranial tumors are reported. Concerning these risks, it should be noted that they are usually related to conventional radiotherapy that was performed in the past decades, and a sufficiently long follow-up period is available. Concerning our experience with hypofractionated stereotactic radiotherapy, our data show that rate of side effects is extremely low, however considering that average follow-up period after HSRT is 9.8 years. No cerebrovascular disease, neurocognitive dysfunction, or secondary intracranial tumors were registered in our experience with HSRT. Concerning hypopituitarism, first of all, we have to consider that in the presented series, a relevant part of patients presented preoperative hypopituitarism; however, only three patients needed substitutive medical therapy (hydrocortisone and levothyroxine) respectively after 3, 5, and 6.4 years after radiotherapy. Finally, we registered that three young female patients treated in our series experienced successful pregnancy. Hypofractionated stereotactic radiotherapy was preferred to radiosurgery because the first one, in our experience, allowed a very satisfactory tumor control with negligible side effects; moreover, HSRT allows to treat also tumor remnants (**Figure 7**) more voluminous than radiosurgery, in absence of damages to the critical neurovascular structures of the pituitary-diencephalic region.

Finally, concerning timing of HSRT, in our patients, we performed the treatment as soon as the MRI showed the descent of the tumor remnant into the sellar cave (between 1 and 4 months); in the cases of tumor remnant into the cavernous sinuses, HSRT was performed between 1 and 2 months. Recurrence after radiotherapy occurred in the only patient who performed HSRT 5 years after surgery, when the tumor remnant had already regrown; it is known that effect of radiotherapy is better, as well as the tumor remnant is small. Therefore, our indication is that HSRT in voluminous invasive pituitary adenomas should be performed as soon as possible, but ideally when tumor remnant has been descended into the sellar cave and optic chiasm has been decompressed.

One important aspect is the correct evaluation of postoperative MRIs after transsphenoidal surgery for huge pituitary adenomas; usually, the neurosurgeon evaluates by himself the extent of removal, and usually, MRI is significant 2–3 months after surgery. Precocious MRIs within the 2–4 weeks after surgery are not so significant for evaluation of tumor removal, because of the presence of material of apposition, because of the absence of tumor capsule collapse, etc. (Figures 9–11).

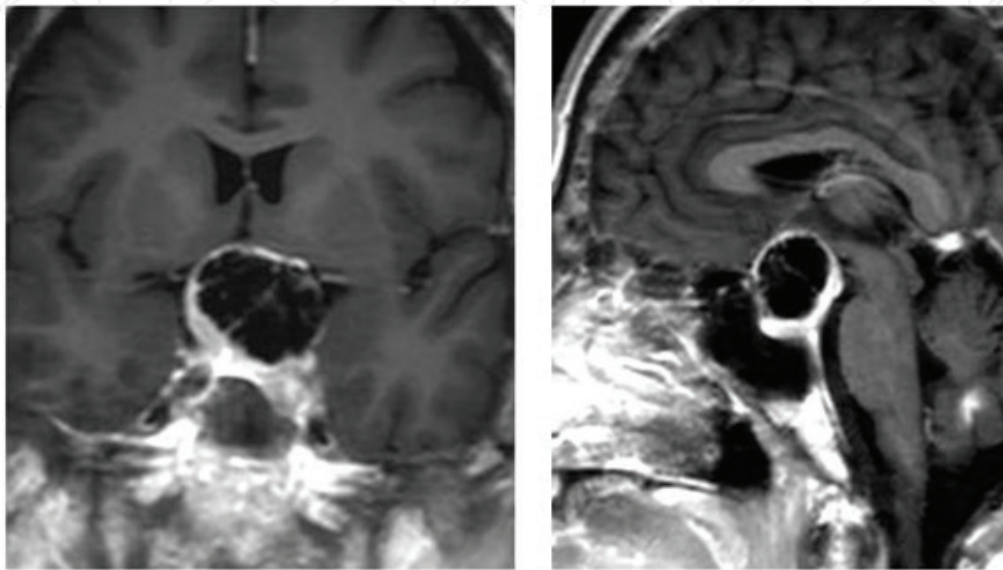


Figure 9. Preoperative MRI of hemorrhagic huge pituitary adenoma. Optic chiasm, pituitary stalk, and chiasmatic arachnoid cistern are not evident because of tumor compression.

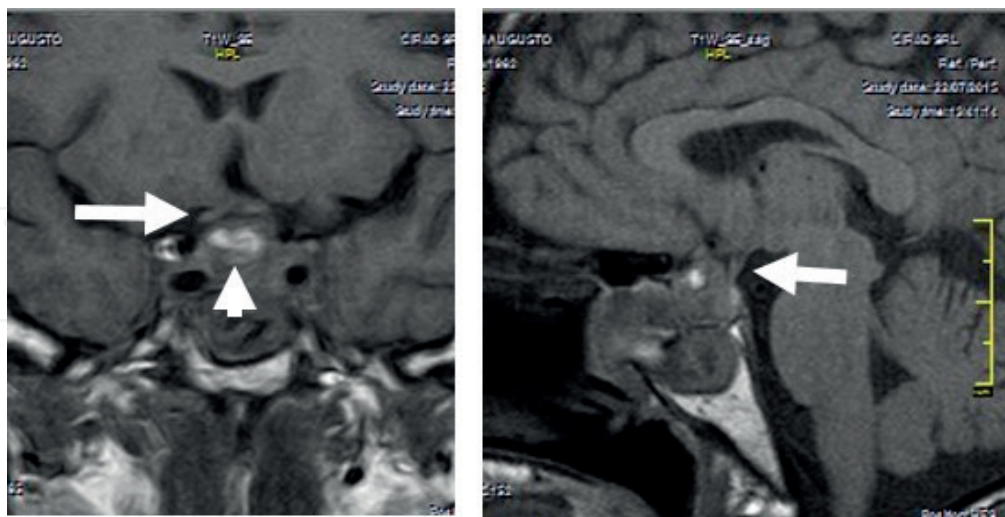


Figure 10. Precocious postoperative MRI performed 7 days after surgery. Coronal image: optic chiasm is now evident (white arrow); a slight hyperintense signal is evident (white arrow head), corresponding to hemostatic material. Sagittal image: pituitary stalk is now evident.

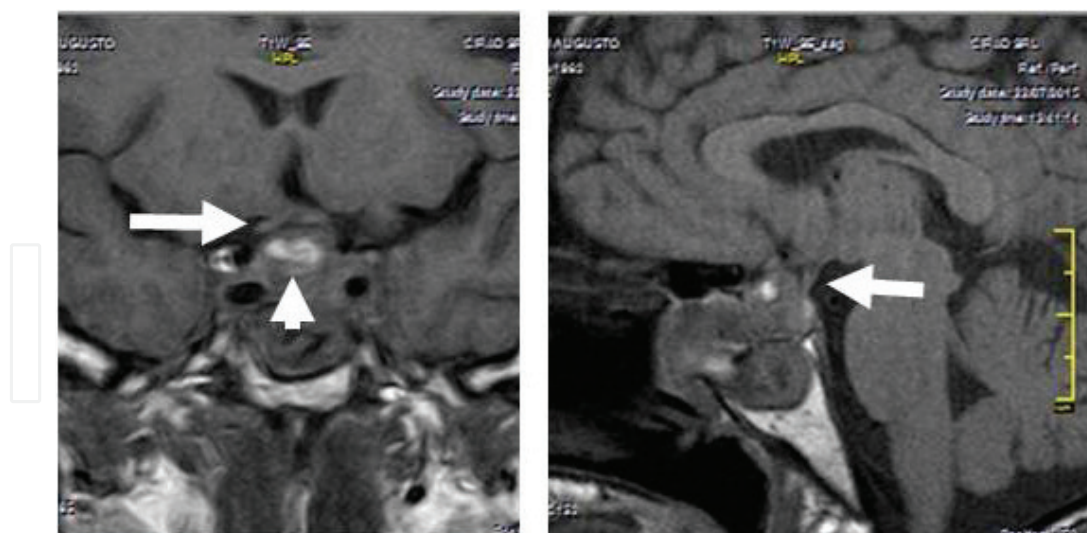


Figure 11. Postoperative MRI performed 2 months after surgery showing an optimal decompression of suprasellar structures. Coronal image: optic chiasm (long white arrow), pituitary stalk (white arrow head), and chiasmatic cistern (short white arrow) are evident and are now well visible compared to precocious postoperative MRI. Sagittal image: chiasmatic cistern is well visible (white arrow).

3. Conclusions

In our experience, the presented modified transsphenoidal microsurgical technique for removal of huge pituitary adenomas with marked suprasellar extension minimizes damages to the suprasellar cisternal plane, and therefore, intraoperative CSF leak is very rare; total removal can be achieved with higher percentage rate than patients operated with standard technique however in noninvasive adenomas. Postoperative stay in hospital is shorter, and nasal packing can be removed in the first postoperative day. For huge invasive dumbbell-shaped adenomas, personalized treatment should be performed according to the degree of neurovascular structures encasement (optic chiasm, diencephalus, cavernous sinuses, and A1 tracts of anterior cerebral arteries).

Author details

Mario Francesco Fraioli^{1*}, Andrea Pagano¹, Bernardo Fraioli² and Pierpaolo Lunardi¹

*Address all correspondence to: mff77@libero.it

1 Department of Neurosurgery, University of Rome Tor Vergata, Roma, Italy

2 Department of Radiotherapy and Radiosurgery, CIRAD Villa Benedetta, Roma, Italy

References

- [1] Couldwell WT. Transsphenoidal and transcranial surgery for pituitary adenomas. *Journal of Neuro-Oncology*. 2004;**69**(1-3):237-256

- [2] Youssef AS, Agazzi S, van Loveren HR. Transcranial surgery for pituitary adenomas. *Neurosurgery*. 2005;**57**(1 Suppl):168-175
- [3] Fraioli B, Esposito V, Liccardo G, Giuffrè R, Cantore G. The supine position for transsphenoidal surgery. *Neurosurgical Review*. 1994;**17**(4):275-276
- [4] Fraioli MF, Catena E, Lecce M, Fraioli B. Transsphenoidal removal of huge pituitary adenomas with marked suprasellar extension: Results with modified surgical technique. *Clinical Neurology and Neurosurgery*. Apr 2013;**115**(4):450-453. DOI: 10.1016/j.clineuro.2012.06.019 [Epub Jul 7, 2012]
- [5] Fraioli B, Pastore FS, Floris R, Vagnozzi R, Simonetti G, Liccardo G, et al. Computed tomography-guided transsphenoidal closure of postsurgical cerebrospinal fluid fistula: A transmucosal needle technique. *Surgical Neurology*. 1997;**48**(4):409-413
- [6] Kaptain GJ, Kanter AS, Hamilton DK, Laws ER. Management and implications of intra-operative cerebrospinal fluid leak in transnasoseptal transsphenoidal microsurgery. *Neurosurgery*. 2011;**68**(1 Suppl. Operative):144-151
- [7] Dusick JR, Mattozo CA, Esposito F, Kelly DF. Bio glue for prevention of post-operative cerebrospinal fluid leaks in transsphenoidal surgery: A case series. *Surgical Neurology*. 2006;**66**(4):371-376
- [8] Takakura K, Teramoto A. Management of huge pituitary adenomas. *Acta Neurochirurgica Supplement*. 1996;**65**:13-15
- [9] Colin P, Jovenin N, Delemer B, Caron J, Gullet H, Hecart AC, et al. Treatment of pituitary adenomas by fractionated stereotactic radiotherapy: A prospective study of 110 patients. *International Journal of Radiation Oncology, Biology, Physics*. 2005;**62**:333-341
- [10] Fahlbusch R, Honegger J, Paulus W, Huk W, Buchfelder M. Surgical treatment of cranio: Experience with 168 patients. *Journal of Neurosurgery*. 1999;**90**(2):237-250
- [11] Schaller B. Trigemino-cardiac reflex during transsphenoidal surgery for pituitary adenomas. *Clinical Neurology and Neurosurgery*. 2005;**107**(6):468-474
- [12] Schaller BJ, Filis A, Buchfelder M. Trigemino-cardiac reflex in humans initiated by peripheral stimulation during neurosurgical skull-base operations. Its first description. *Acta Neurochirurgica*. 2008;**150**(7):715-718
- [13] Giaj Levra N, Sicignano G, Fiorentino A, Fersino S, Ricchetti F, Mazzola R, Naccarato S, Ruggieri R, Alongi F. Whole brain radiotherapy with hippocampal avoidance and simultaneous integrated boost for brain metastases: A dosimetric volumetric-modulated arc therapy study. *La Radiologia Medica*. Jan 2016;**121**(1):60-69. DOI: 10.1007/s11547-015-0563-8 [Epub Aug 1, 2015]
- [14] Greene-Schloesser D, Robbins ME. Radiation-induced cognitive impairment-from bench to bedside. *Neuro-Oncology*. Sep 2012;**14**(Suppl 4):iv37-iv44. DOI: 10.1093/neuroonc/nos196 (Review)

