

# We are IntechOpen, the world's leading publisher of Open Access books Built by scientists, for scientists

6,900

Open access books available

185,000

International authors and editors

200M

Downloads

Our authors are among the

154

Countries delivered to

TOP 1%

most cited scientists

12.2%

Contributors from top 500 universities



WEB OF SCIENCE™

Selection of our books indexed in the Book Citation Index  
in Web of Science™ Core Collection (BKCI)

Interested in publishing with us?  
Contact [book.department@intechopen.com](mailto:book.department@intechopen.com)

Numbers displayed above are based on latest data collected.  
For more information visit [www.intechopen.com](http://www.intechopen.com)



---

# **Isolated Form of Left Ventricular Non-compaction Cardiomyopathy (LVNC) as a Rare Cause of Heart Failure**

---

Skopoulis Sotiris

Additional information is available at the end of the chapter

<http://dx.doi.org/10.5772/intechopen.76379>

---

## **Abstract**

Non-compaction cardiomyopathy (LVNC) is a rare, hereditary disease manifested by heart failure, thromboembolic complications and arrhythmias, which can even result in a sudden cardiac arrest. This disease is often misdiagnosed as dilated or ischemic cardiomyopathy, apical hypertrophic cardiomyopathy, or other myocardial infiltrative processes, including tumours. Due to its potentially severe complications and outcomes it should be always considered as a part of differential diagnosis.

**Keywords:** non-compaction cardiomyopathy, heart failure, trabecularisation, echocardiography, cardiomyopathy

---

## **1. Introduction**

Non-compaction cardiomyopathy (LVNC) is a rare, hereditary disease. It is believed that develops due to a defect during embryogenesis of endocardium and myocardium. In 1996 LVNC was categorised as non-classified cardiomyopathy according to the WHO classification of cardiomyopathy.

A typical image of LVNC is thickening of the apical wall in the left ventricle due to increased trabecularisation and occurrence of deep inter-trabecular recesses communicating with the left ventricle. Dilation and/or systolic dysfunction of the left ventricle (LV) is usually present [1].

The disease may manifest as an isolated myocardial disorder (an isolated form of LVNC) or in relation with congenital heart defects, such as pulmonary atresia, defects in the atrial

---

and ventricular septum, obstructions of the outflow tract of the left or right ventricle or Ebstein's anomaly.

## 2. Prevalence

The actual LVNC prevalence value is difficult to determine, because the frequency of its occurrence significantly differs in relation to the studied population.

Based on 14-year reviewing of results of echocardiographic examinations of patients, one of the available studies described 34 patients with LVNC in total, which represented prevalence of 0.014%. A different clinical study diagnosed in the course of 4.5 years 57 patients with LVNC with use of echocardiographic criteria and prevalence reached 0.14% [2, 3].

The normal value of prevalence according to other studies ranges between 0.05 and 0.24% [3, 4].

In children with LVNC it represents the third most frequent cardiomyopathy and approximately 9% of all cardiomyopathies [5].

The age of clinical manifestation of the disease symptoms is very variable—at least two cases were described in the bibliography where the diagnosis was already established in utero [6]. The oldest patient with LVNC was aged 94 when diagnosed [7, 8].

## 3. Genetics

It is not easy to explain the genetic base for the phenotype expression of LVNC, because cases of both hereditary and also sporadic forms of this disease have been described. It seems that their occurrence in childhood is related to a pronounced genetic base, which cannot be said with certainty, as concerns its occurrence in adulthood. The genes associated with the occurrence of LVNC include tafazzin, beta-dystrobrevin (DTNA), Cypher/ZASP (LDB3), lamin A/C (LMNA), SCN5A, MYH7, and MYBPC3 [9–12].

Although it is obvious that further extensive investigation is needed to describe the genetic base of this disease in detail, we may already conclude with certainty that a certain genetic heterogeneity is needed.

The percentage of cases of hereditary forms of LVNC in three large groups of patients reached 18, 25, and 33% [8, 13, 14].

Heredity of this disease is usually autosomal and dominant with incomplete penetration. LVNC with a defective gene for G4.5 that causes gonosomal hereditary Barth syndrome (dilation cardiomyopathy or LVNC in men with symptoms from childhood accompanied with neutropenia, lactic acidosis and abnormalities in lipid metabolism is an exception [15, 16].

Even though routine genetic testing of patients has not been currently recommended, according to the procedures advised by HFSA (Heart Failure Society of America) detail investigation

of the history of at least three family generations and cardiological examination of the patient's direct relatives with established LVNC is clearly recommended with regard to its prevailing occurrence in the family [17].

The benefits of screening genetic testing of all direct relatives of the patient with LVNC must also be considered in the future.

#### **4. Embryology, histology**

In the course of embryogenesis before development of coronary veins myocardium is made of a free network of intertwined trabeculae and deep recesses. Coronary vessels develop between the 5th and 8th week of intrauterine life and gradual connection of myocardial trabeculae occurs under regular conditions until the compact myocardial layer starts to prevail over the spongy layer [9]. This process runs quite fast between the 10th and 12th week of the embryonic development and proceeds from the left ventricular base towards the apex and from epicardium to endocardium, while the left ventricular myocardium is more compact than the right ventricular myocardium, which stays more trabecularised also in adulthood.

It is currently anticipated that LVNC occurs due to a disordered myocardium compaction in the course of embryogenesis that is most frequently caused due to mutation of sarcomere proteins, which leads in excessive myocardial trabecularisation that is usually localised on the apex of left ventricle and apical segments of the lateral and inferior wall [10, 11].

Anatomic criteria for determination of the LVNC diagnosis according to Burke et al. include: (1) absence of normally formed papillary muscles in the left ventricle, (2) the proportion of the overall thickness of the left ventricular wall and the layer of compact myocardium exceeds two [18].

The histochemical image is usually dominated with endocardial thickening, endocardial fibrosis to endocardial fibroelastosis, deep intertrabecular recesses and focuses of interstitial fibrosis or even microinfarctions.

#### **5. Clinical manifestation and treatment of the disease**

The onset of clinical manifestation of the symptoms in patients with an isolated form of LVNC is variable; many patients remain asymptomatic for years, while some individuals show development of the symptoms since early childhood [19].

In asymptomatic patients, the diagnosis is established during a preventive echocardiographic examination or as consequence of targeted screening due to a positive family history.

The main clinical manifestation of LVNC is left-sided heart failure that most frequently manifests with dyspnoea, stenocardia, palpitation or syncope. Other manifestations of the disease include ventricular arrhythmias and subsequent sudden cardiac death. Thromboembolic complications are frequent.

Men are affected more frequently than women [8].

Standard cardiac failure treatment procedures are applied in the case of left ventricular heart insufficiency, mainly beta-blockers, ACE inhibitors and diuretics. Aldosterone inhibitors, digoxin and vasodilators can also be used in the therapy.

Upon occurrence of ventricular arrhythmia, specifically non-sustained ventricular tachycardia, without significant LV dysfunction, treatment with beta-blockers or amiodarone is indicated. ICD implantation should be considered in patients with obvious sustained ventricular tachycardia, inexplicable syncope or in patients with left ventricular EF under 35% persisting despite adequate therapy, as a primary prevention of sudden cardiac death.

Benefit of resynchronisation therapy has been described in a group of patients with LVNC [20].

Stollberger et al. describe improvement of the systolic function in the left ventricle in the course regular control echocardiography (reduced creation of trabecularisation and improvement in the myocardial compaction) in a number of patients with LVNC after bi-ventricular pacing (follow up programme for the period of 4–68 months) [21].

In the case of patients with end stage heart failure despite adequate pharmacotherapy, the use of mechanical heart support or enlisting in a transplantation programme must be considered. Patients with dilation and significant left ventricular dysfunction are advised to use permanent anticoagulation treatment as a prevention of embolic complications [1, 8].

## 6. Diagnostics

The currently used diagnostic standard comprises a proper obtainment of family history for the last three generations, an echocardiographic examination and magnetic resonance of the heart.

In most of the patients *ECG* is manifested with non-specific changes of repolarization, bundle branch blocks and various degrees of AV blocks [1].

However, the basic diagnostic method for LVNC is *echocardiography*. A typical echocardiographic examination of LVNC describes a “layered” picture of myocardium made of a thin outer compact layer and a strong trabecularised non-compact endocardial layer with frequent deep intertrabecular recesses that are usually localised in the apical area under the level of papillary muscles and adjacent segments of the lateral and inferior walls [22–24].

In 2001, Jenni et al. proposed criteria based on an end systolic ratio of non-compacted to compacted layers above two. Segments involved are mid ventricular (especially inferior and lateral ones) and apical [25, 26].

A number of authors believe that the current diagnostic criteria have an excessively high sensitivity, which may cause overestimation of the LVNC prevalence [19].

Finsterer and Stollberger [27] proposed fusion of diagnostic criteria according to Jenni and Stollberger with subsequent classification in the following categories:

1. LVNC diagnosis is possible;

2. LVNC diagnosis is probable;
3. LVNC diagnosis is definitive.

according to the number of shown characteristics.

In 2008 Belanger et al. proposed a new scheme classifying LVNC as a non-probable, moderate, rather significant and serious disease on the basis of the numerical value of the NC/C Index (ratio of the non-compact layer to the compact layer) of 0, 1, 2 and more than 2. Another criterion should include the size of the area suffering from non-compaction [28].

**3D echocardiography or magnetic resonance of the heart (CMR)** are methods that may be used if the patient is not easily examinable upon a regular echocardiographic examination, mainly due to inability to visualise the apex of the heart. The criterion to determine the LVNC diagnosis comprises the ratio of non-compact myocardial layer (NC/C Index or NC/C Ratio) exceeding 2.3 during diastole, which distinguishes pathological non-compaction with sensitivity values of 86%, specificity of 99%, positive prediction of 75% and negative prediction of 75% [29].

**Computer tomography (CT and CT angiography)** is used less frequently in LVNC diagnostics; it enables displaying of coronary vessels and also the associated congenital anomalies (e.g. stenosis or pulmonary atresia).

**Contrast left-sided ventriculography** shows typical deep recessions and spongy appearance of the cavity [16].

## 7. Prognosis

Prognosis for the patients with LVNC differs; almost 60% of the patients described in one of the multicentral studies either died or underwent a heart transplantation within 6 years from establishment of the diagnose [4].

Mortality in the subsequent series of adult patients with LVNC reached 35% during 44 months of monitoring and half of them died suddenly [13].

## 8. Case report

Case of a patient aged 39 that has not been treated so far and was examined at an acute cardiological outpatient office of the district hospital for exertional dyspnoea lasting for already 2 months, functionally according to NYHA (New York Heart Association) classified in grade 3 and oedemas on lower limbs lasting for 3 years. Physical examination showed blood pressure (170/110 mmHg), hepatomegaly and bilateral perimalleolar oedemas. ECG at the admission also described a mild sinus tachycardia, P pulmonale in leads II, III, and aVF, descendent depression of ST sections with a negative T wave in leads II, III, and aVF. Laboratory examination revealed only a slight elevation of cardiac markers without dynamic change corresponding to an acute coronary syndrome, an elevation of natriuretic peptide type B, and a slight elevation of liver enzymes. In the course of hospitalisation was performed transthoracic

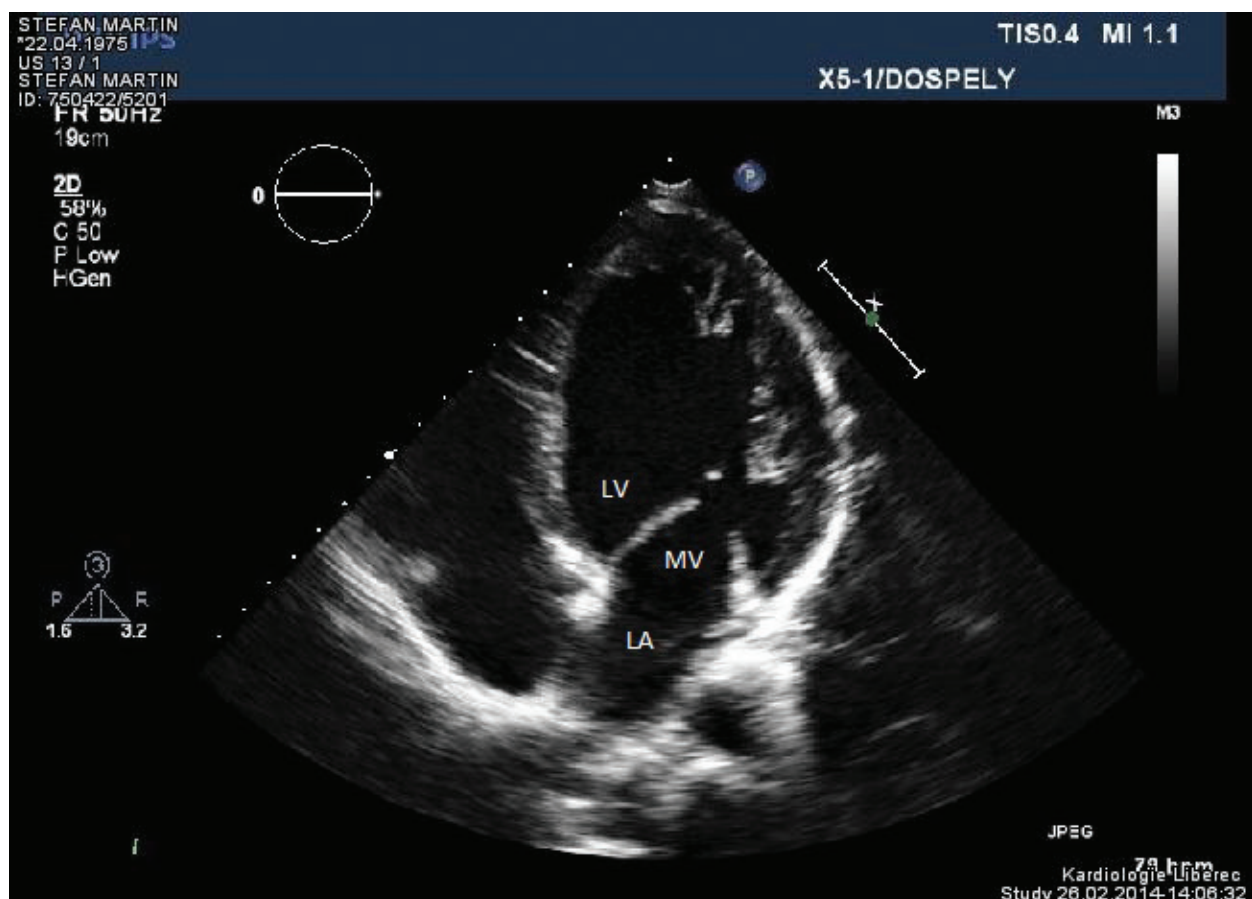


echocardiography examination (**Pictures 1** and **2**) and transesophageal echocardiographic examination (**Picture 3**). Both showed severe systolic dysfunction of the remodelled LV with EF of 20%, global hypokinesis, trabecularisation of the left ventricle, a mobile thrombus in LV and severe systolic dysfunction of dilated RV.

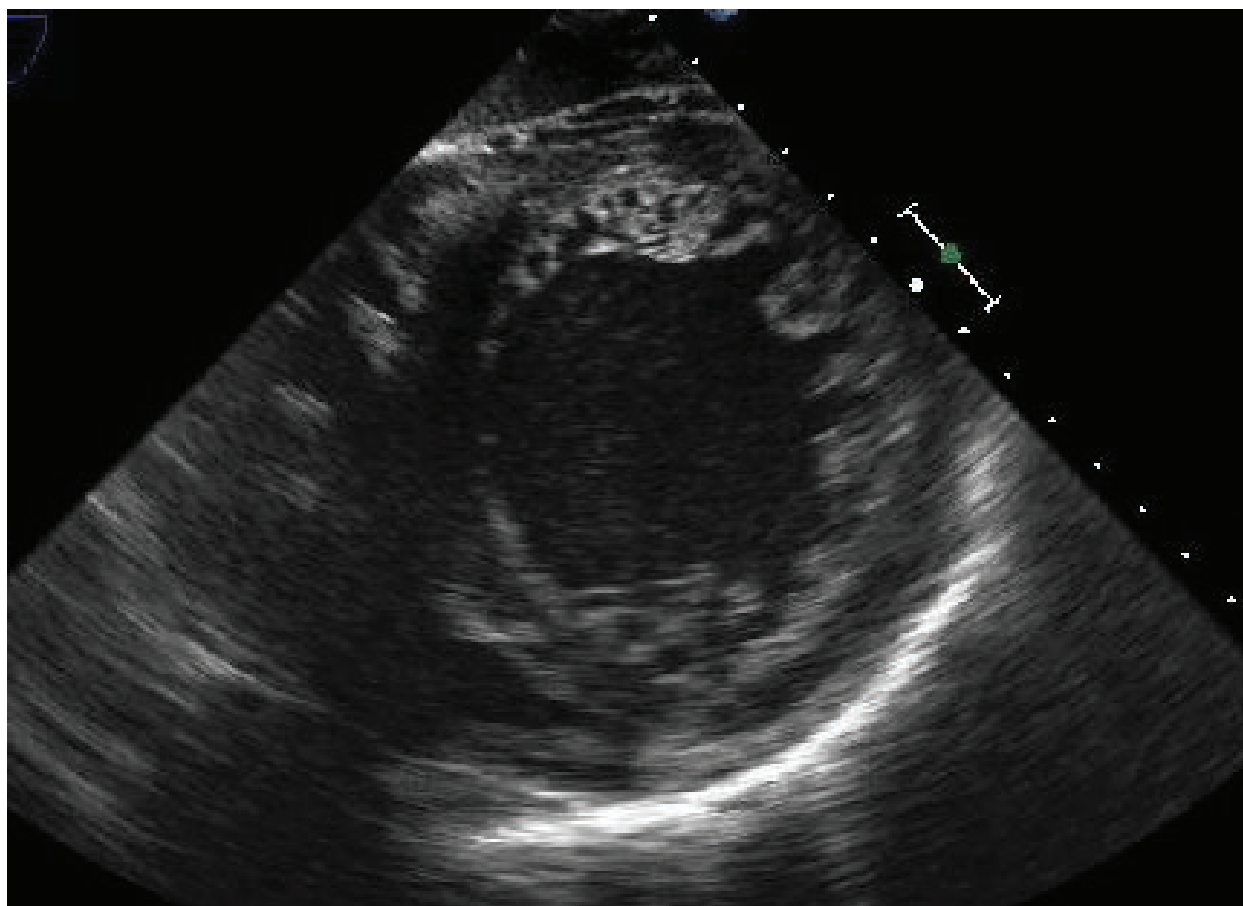
Coronary angiography only showed non-significant atherosclerosis of the coronary vessels.

Magnetic heart resonance was carried out electively and confirmed echocardiographic examination findings. The examination confirmed severe systolic LV dysfunction with EF of 16%, significant global LV hypokinesia, visible LV trabecularisation, a fluttering thrombus between trabeculae in the central LV segment, dilation of the left atrium and right-sided chambers (**Picture 4**).

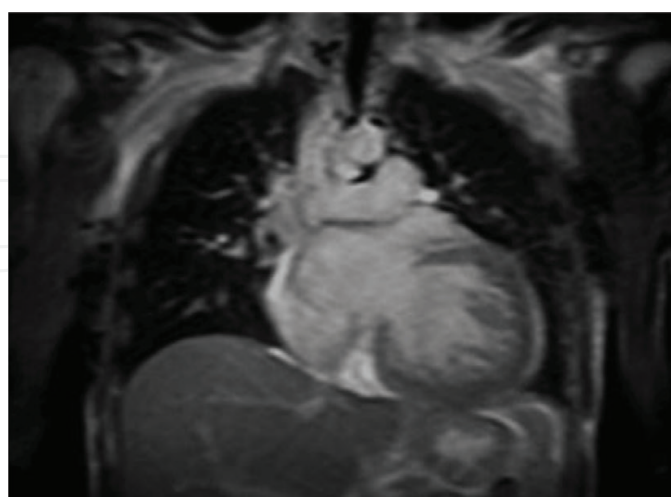
Heart failure therapy was immediately initiated. Anticoagulation therapy was added. It led to a prompt improvement of the clinical condition. Despite the adequate therapy an improvement of the systolic function of the left ventricle was not observed. The patient was referred as a candidate of ICD implantation for primary prevention of sudden cardiac death and was also enlisted as a candidate for heart transplantation.



**Picture 1.** 2D echocardiography: apical four-cavity projection. Significant trabecularisation of spherically remodelled left ventricle in different projections.

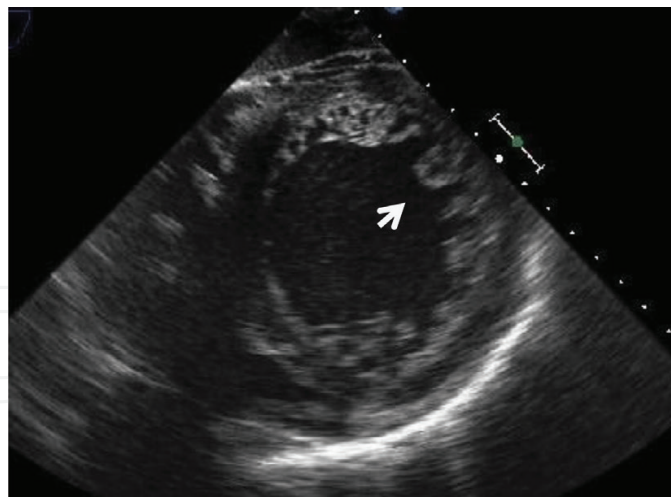


**Picture 2.** 2D echocardiography from parasternal short axis. Significant trabecularisation of spherically remodelled left ventricle in different projections.



**Picture 3.** Transesophageal echocardiography with a typical finding of trabecularised dysfunctional LV and dilation of the left atrium.





**Picture 4.** MRI scan. CMR scan supporting the standard echocardiographic examination findings.

## 9. Conclusion

Occurrence of LVNC is rare, nevertheless due to its potentially severe complications and outcomes it should be always considered as a part of differential diagnosis.

The goal for the future is to collect as much data as possible concerning the clinical course of the disease, its genetic background, diagnostics, and treatment. This strategy may positively influence interpretation of genotype-phenotype correlation, the epidemiology of the disease and clinical management.

## Author details

Skopoulis Sotiris

Address all correspondence to: s.skopulis@gmail.com

Hatzikosta General Hospital, Ioannina, Greece

## References

- [1] Kettner J, Vítovec J, Fischerová B. Kardiomyopatie, myokarditidy, onemocnění perikardu. In: Vojáček J, Kettner J, et al. *Klinická kardiologie*. 1.vydání. Ioannina, Epirus, Greece: Nucleus HK; 2009. pp. 446-488
- [2] Stollberger C, Finsterer J. Left ventricular hypertrabeculation/noncompaction. *Journal of the American Society of Echocardiography*. 2004;**17**:91-100
- [3] Stollberger C, Finsterer J, Blazek G. Left ventricular hypertrabeculation/noncompaction and association with additional cardiac abnormalities and neuromuscular disorders. *American Journal of Cardiology*. 2002;**90**:899-902

- [4] Ritter M, Oechslin E, Sutsch G, et al. Isolated noncompaction of the myocardium in adults. *Mayo Clinic Proceedings*. 1997;**72**:26-31
- [5] Nugent AW, Daubeney PE, Chondros P, et al. The epidemiology of childhood cardiomyopathy in Australia. *The New England Journal of Medicine*. 2003;**348**:1639-1646
- [6] McCaffrey F. Around Pediheart: Noncompaction of the left ventricle. *Pediatric Cardiology*. 2001;**22**:399
- [7] Winer N, Lefevre M, Nomballais MF, et al. Persisting spongy myocardium: A case indicating the difficulty of antenatal diagnosis. *Fetal Diagnosis and Therapy*. 1998;**13**:227-232
- [8] Radha JS, Chana A, Elkayam U. Left ventricular noncompaction. *Progress in Cardiovascular Diseases*. 2010;**52**:264-273
- [9] Monserat L, Hermida-Prieto M, Fernandez X, et al. Mutation in alfa-cardiac actin gene associated with apical hypertrophic cardiomyopathy, left ventricular non-compaction and septal defects. *European Heart Journal*. 2007;**28**:1953-1961
- [10] Vatta M, Mohapatra B, Jimenez S, et al. Mutations in cypher/ZASP in patients with dilated cardiomyopathy and left ventricular noncompaction. *Journal of the American Society of Cardiology*. 2003;**42**:2014-2027
- [11] Kenton AB, Sanchez X, Coveler KJ, et al. Isolated left ventricular noncompaction is rarely caused by mutations in G4.5, alfa-dystrobrevin and FK binding protein-12. *Molecular Genetics and Metabolism*. 2004;**82**:162-166
- [12] Hermida-Prieto M, Monserat L, Castro-Beiras A, et al. Familial dilated cardiomyopathy and isolated left ventricular noncompaction associated with Lamin A/C gene mutations. *The American Journal of Cardiology*. 2004;**94**:50-54
- [13] Oechslin E, Attenhofer Jost C, Rojas J, et al. Long-term follow-up of 34 adults with isolated left ventricular noncompaction: A distinct cardiomyopathy with poor prognosis. *Journal of the American College of Cardiology*. 2000;**36**:493-500
- [14] Aras D, Tufekcioglu O, Erfun K, et al. Clinical features of isolated ventricular noncompaction in adults long-term clinical course, echocardiographic properties, and predictors of left ventricular failure. *Journal of Cardiac Failure*. 2006;**12**:726-733
- [15] Ichida F, Tsubata S, Bowles KR, et al. Novel gene mutations in patients with left ventricular noncompaction and Barth syndrome. *Circulation*. 2001;**103**:1256-1263
- [16] Virtová R et al. Isolated non-compaction cardiomyopathy: A review. *Cor et Vasa*. 2013;**55**:236-241
- [17] Hershberger RE, Lindenfeld J, Mestroni L, et al. Genetic evaluation of cardiomyopathy—A Heart Failure Society of America practice guideline. *Journal of Cardiac Failure*. 2009;**15**:87-97
- [18] Burke A, Mont E, Kutys R, et al. Left ventricular noncompaction: A pathologic study of 14 cases. *Human Pathology*. 2005;**36**:403-411

- [19] Kohli SK, Pantazis AA, Shah JS, et al. Diagnosis of left-ventricular non-compaction in patients with left-ventricular systolic dysfunction: Time for a reappraisal of diagnostic criteria? *European Heart Journal*. 2008;**29**:89-95
- [20] Oginosawa Y, Nogami A, Soejima K, et al. Effect of cardiac resynchronization therapy in isolated ventricular noncompaction in adults: Follow-up of four cases. *Journal of Cardiovascular Electrophysiology*. 2008;**19**:935-938
- [21] Stollberger C, Blazek G, Bucher E, et al. Cardiac resynchronization therapy in left ventricular hypertrabeculation/non-compaction and myopathy. *EP Europace*. 2008;**10**:59-62
- [22] Caselli S, Autore C, Serdoz A, et al. Three-dimensional echocardiographic characterization of patients with left ventricular noncompaction. *Journal of the American Society of Echocardiography*. 2012;**25**:203-209
- [23] Chin TK, Perloff JK, Williams RG, et al. Isolated noncompaction of left ventricular myocardium. A study of eight cases. *Circulation*. 1990;**82**:507-513
- [24] Engberding R, Bender F. Identification of a rare congenital anomaly of the myocardium by two-dimensional echocardiography: Persistence of isolated myocardial sinusoids. *American Journal of Cardiology*. 1984;**53**:1733-1734
- [25] Jenni R, Oechslin E, Schneider J, et al. Echocardiographic and pathoanatomical characteristics of isolated left ventricular non-compaction: A step towards classification as a distinct cardiomyopathy. *Heart*. 2001;**86**:666-671
- [26] Nunez-Gil I, Feltes-Guzman G. Left ventricular non compaction. *E-journal of ESC Council for Cardiology Practice*. 2012;**10**:33
- [27] Finsterer J, Stollberger C. Letter to the editor: Definite, probable, or possible left ventricular hypertrabeculation/noncompaction. *International Journal of Cardiology*. 2008;**123**:175-176
- [28] Belanger AR, Miller MA, Donthireddi UR, et al. New classification scheme of left ventricular noncompaction and correlation with ventricular performance. *American Journal of Cardiology*. 2008;**102**:92-96
- [29] Fazio G, Visconti C, D'Angelo L, et al. Delayed MRI hyperenhancement in noncompaction: Sign of fibrosis correlated with clinical severity. *AJR American Journal of Roentgenology*. 2008;**190**:273