

# We are IntechOpen, the world's leading publisher of Open Access books Built by scientists, for scientists

6,900

Open access books available

186,000

International authors and editors

200M

Downloads

Our authors are among the

154

Countries delivered to

TOP 1%

most cited scientists

12.2%

Contributors from top 500 universities



WEB OF SCIENCE™

Selection of our books indexed in the Book Citation Index  
in Web of Science™ Core Collection (BKCI)

Interested in publishing with us?  
Contact [book.department@intechopen.com](mailto:book.department@intechopen.com)

Numbers displayed above are based on latest data collected.  
For more information visit [www.intechopen.com](http://www.intechopen.com)



---

# Starting A Peripheral Nerve Surgery Unit in an Area of Limited Resources - Our Experience

---

Chiazor U. Onyia, Ravi Sankaran and Ashok Pillai

Additional information is available at the end of the chapter

<http://dx.doi.org/10.5772/intechopen.75349>

---

## Abstract

Dedicated peripheral nerve surgery centers are few in developing countries where majority of affected patients either remain untreated or are simply palliated with just physiotherapy. In this chapter, we review our experience with surgery for peripheral nerve lesions and peripheral nerve injuries over a 5-year period. A total of 68 procedures were carried out for 58 patients with various peripheral nerve lesions and injuries. Among the 19 surgeries for adult brachial plexus injuries, 10 were for pan-brachial plexus injury, 2 procedures for lower brachial plexus injuries, and 7 procedures for upper brachial plexus injury, while 11 repair surgeries were done for pediatric brachial plexus injuries. The remaining 38 surgeries included 21 peripheral nerve sheath tumor excisions, 5 ablative procedures for chronic neuralgia, 8 procedures for non-carpal tunnel peripheral nerve entrapments, and 4 adults with upper or lower limb isolated nerve injury repairs. The patients were followed up between 6 months and 2 years post-surgery for functional outcome assessment. Overall, as many as 57.5% of the patients had significant neurologic improvement noticed at 2 years of follow-up. Despite its challenges, optimal outcomes following surgery are still possible for patients with nerve injuries, entrapments, and nerve tumors in developing countries

**Keywords:** brachial plexus injury, peripheral nerve sheath tumor, peripheral entrapment neuropathy, pattern, peculiarities

---

## 1. Introduction

The field of peripheral nerve surgery has evolved significantly over the past century, with many lessons learnt [16]. The practice of peripheral nerve surgery can be both rewarding and frustrating due to prolonged recovery times and outcomes ranging from excellent to dismal,

---

particularly for injuries involving the brachial plexus [44]. The most crucial aspect of planning surgical intervention in brachial plexus injury is selecting the timing of surgery [8]—preferably explored within 5 months after injury [8, 13]. This might be as early as 2 months for pan-plexus injuries which have demonstrated no improvement or as late as 5–6 months for distal neurotization repairs for upper plexus injuries. Generally, the armamentarium of the peripheral nerve surgeon includes (1) the initial history and examination, (2) preoperative electrophysiology, (3) preoperative rehabilitation, (4) longitudinal preoperative clinical and electrophysiological course (i.e., recovery/no recovery), (5) preoperative radiological assessment, (6) intraoperative anatomic study, (7) intraoperative electrophysiology, (8) operative procedures, and (9) postoperative rehabilitation.

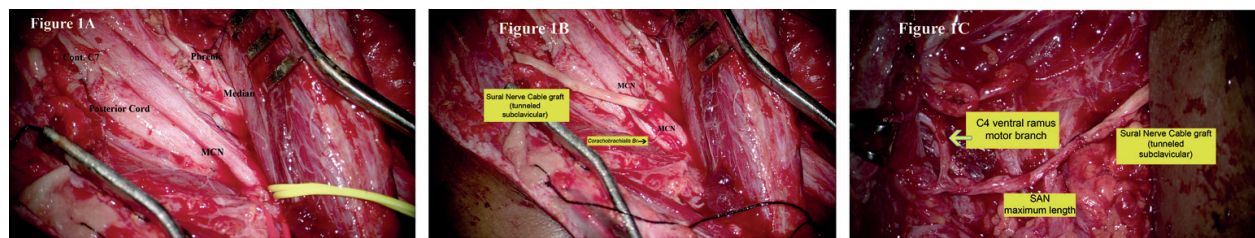
However, this ideal kind of practice is obtainable mainly in the developed countries. Dedicated neurosurgical peripheral nerve surgery centers are still quite few in India and most other developing countries where majority of these patients either remain untreated or are palliated with physiotherapy as the only intervention, mainly as a result of lack of the required expertise and the necessary facilities. In this article, we looked at the pattern and trend of these problems in our practice, and present our early experience and outcomes, along with a brief review of previously documented results on similar surgical problems in the literature. Finally, we summarize the general principles and currently accepted practice guidelines required for optimal outcomes.

## **2. Patients and methods**

The clinical and operative details of all patients who underwent peripheral nerve surgery at the neurosurgery department of Amrita Institute of Medical Sciences, Amrita University in Kochi, India over a period of 5 years from January 2010 till January 2015 were obtained from the hospital database and retrospectively reviewed. This department is a major neurosurgical referral center located in south-west of India serving both local and international patients. The senior author (AP) was responsible for the clinical and surgical management of all patients under review. The spectrum of cases ranged from nerve injuries and peripheral nerve sheath tumors to nerve entrapment syndromes. Short descriptions of the key approach and techniques which we used are briefly detailed as follows (with illustrations):

### **2.1. Nerve repair surgical technique**

All our nerve repairs involved microanastomosis with 10.0 nylon epineural sutures (1–3 per coaptation) and fibrin glue, as described in the literature [45]. Our cable graft sources included the sural nerve, medial antebrachial cutaneous nerve (MACN), and occasionally the greater auricular nerve in infants. Some of our employed techniques for the extraplexal repairs included Somsak's selective distal neurotization of the axillary nerve with branch to long head of triceps [46], posterior approach and transfer of the spinal accessory nerve to the



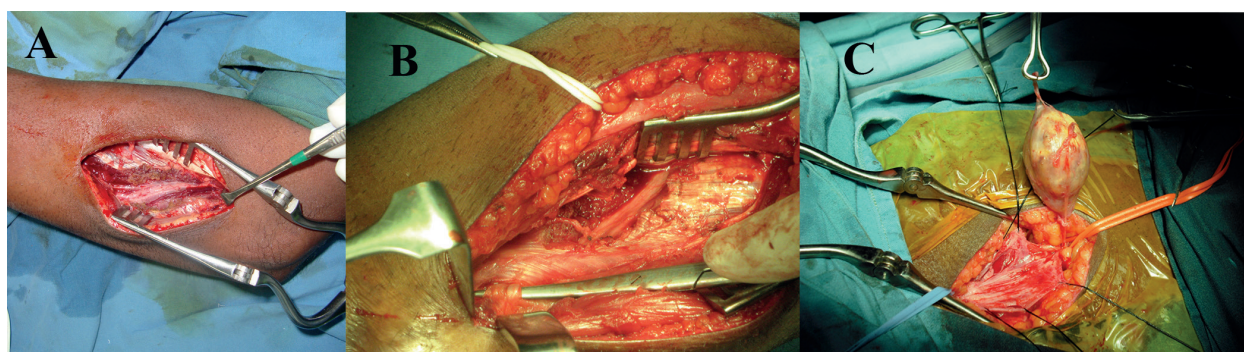
**Figure 1.** Intraoperative pictures of a sample extraplexal neurotization repair of pan-plexus injury. (A) Full-length phrenic nerve transfer to medial root of the median nerve for prehensile hand function and coaptation of contralateral C7 (Cont. C7) to the posterior cord for axillary and radial nerve functions. (B) Sural nerve cable graft in the same pan-plexus repair to neurotize the musculocutaneous nerve (MCN) from the spinal accessory nerve (SAN) for elbow flexion. The coaptation was made in the infraclavicular space into the MCN distal to the branch to the coracobrachialis. (C) Supraclavicular coaptation of ipsilateral C4 motor root and SAN as donor sources into sural nerve cable graft neurotizing the MCN.

suprascapular nerve for shoulder abduction, Oberlin I selective transfer of ulnar nerve fascicle to the musculocutaneous nerve and Oberlin II transfer of branch to brachialis with median nerve motor fascicle for elbow flexion [34]. Our extraplexal transfer techniques also used included contralateral C7 transfer with cable grafts tunneled through the prevertebral space (in 11 patients) to the posterior division of upper trunk for axillary and radial nerve reinnervation and/or the medial cord/branches in OBPI (obstetric brachial plexus injury) for hand function, and thoracoscopically harvested full length phrenic nerve transfer to medial root of median nerve for hand prehensile function (in 4 patients) (**Figure 1A–C**). Donor fascicle functional integrity and recipient nerve nonfunctionality was confirmed by the presence or absence of innervated muscle contraction in response to direct monopolar nerve stimulation. Post-operative immobilization of the affected limb was maintained for 3 weeks, and thereafter patients were commenced on a rigorous rehabilitation protocol by the second author (RS) as early as possible.

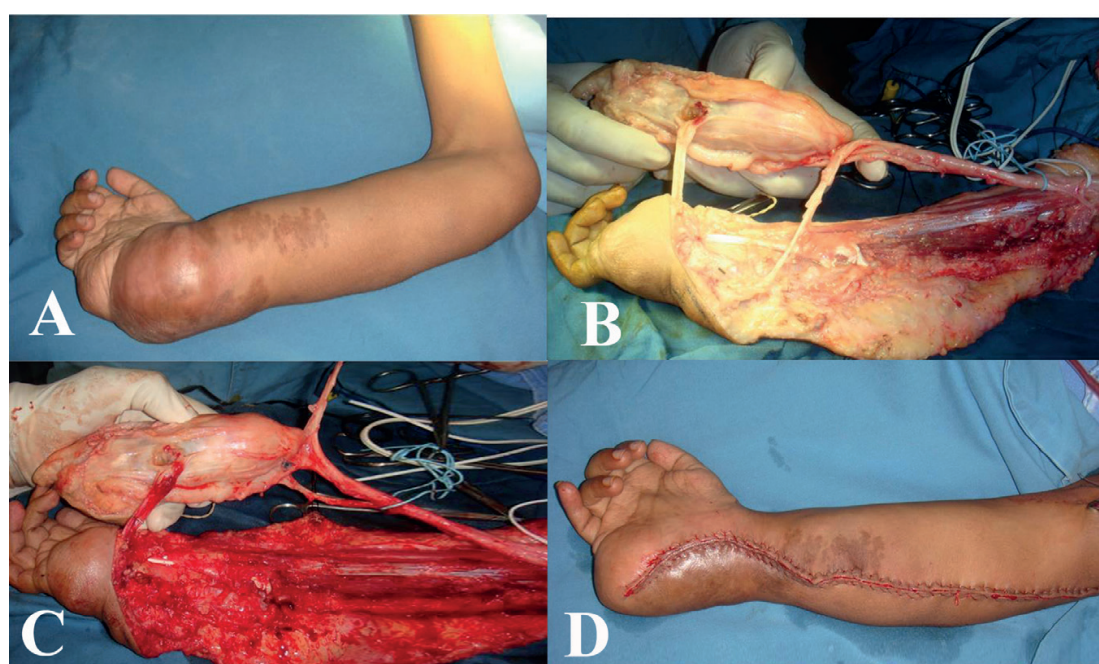
## 2.2. PNST (peripheral nerve sheath tumor) excision surgical technique

Under general anesthesia or regional anesthesia, the affected nerve segment was exposed, the epineurium was incised and tumor dissected in its subcapsular plane for PNSTs to ensure that non-involved fascicles remained functionally intact (**Figure 2c**). The entire limb was prepared and draped in order to assess all individual muscles with direct nerve stimulation as per the resection needs. Either direct NAP (nerve action potential) was recorded across the segment (2 cases) or absence of stimulation-induced target muscle twitching was ascertained before sacrificing the primary fascicle giving rise to the PNST. For malignant peripheral nerve sheath tumors (MPNSTs), an oncological wide resection at least 2–3 cm proximal and distal to the tumor, sacrificing the entire parent nerve, was done followed by functionally matched fascicular repair using sural nerve cable grafts (**Figure 3**). MPNSTs were often diagnosed preoperatively using FDG-PET (fluorodeoxyglucose positron emission tomography) scan to counsel and plan for nerve sacrifice and immediate repair.





**Figure 2.** (A–C) Excision of a benign peripheral nerve sheath tumor. The affected nerve segment was first exposed, followed by incision of the epineurium and the tumor was then dissected out complete in its subcapsular plane.

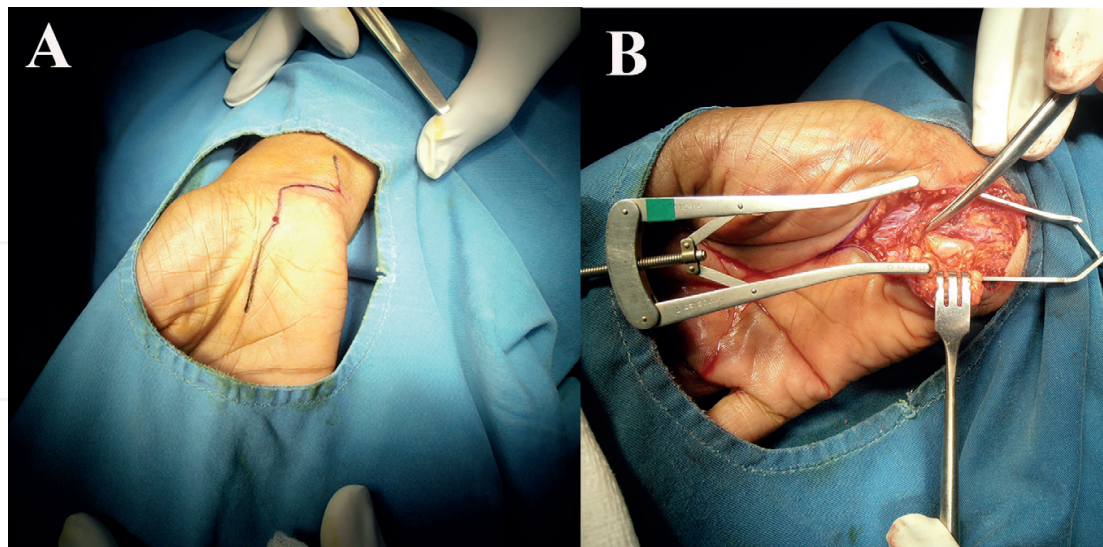


**Figure 3.** (A–D) Excision of a malignant peripheral nerve sheath tumor. Notice the extent of involvement of the affected limb. An oncological wide resection proximal and distal to the tumor was done along with excision of the involved parent nerve (C), followed by functionally matched fascicular repair using harvested cable grafts, as shown in (D).

### 2.3. Nerve entrapment release surgical technique

Nerve entrapments distal to the shoulder (cubital tunnel, PIN entrapment, Guyon's canal entrapment) were operated under regional (supraclavicular block) or local anesthesia. Previously described techniques were followed [1, 2, 21, 30] (**Figure 4A and B**).

Following surgery in each patient, the limb was immobilized with a splint for 2–3 weeks before commencing physiotherapy, to allow for epineurial healing without tension at the anastomosis. Once the concerned limb was mobilized, our primary goals were prevention of contracture and prevention of complex regional pain syndrome (CRPS) following muscle reinnervation, by starting with passive ROM (range of motion). Once a flicker of contraction was found in the concerned muscles, we began isolating and strengthening them with gravity initially, progressing to “against gravity,” and then with resistance. Once the patient could



**Figure 4.** (A, B) Guyon's canal release. Notice the extent of the skin incision to both the wrist and palmar line (A) to ensure adequate exposure and release of the ulnar nerve and artery at the level of the canal.

move against gravity, it was useful to add functional tasks into the exercise programme since motor coordination is as important as strength in recovery. With this process, the patient would gradually develop “different” ways of doing old tasks to compensate for weakness of the primary effector muscle. This was achieved by utilizing the secondary effector muscles which changed the appearance of task performance.

If there was little hope of recovering function at this point, then focusing on stabilizing the involved muscles above and below became more practical but if the chances of functional recovery were high, then training the concerned muscle to become activated at the correct time in the kinetic chain became more useful than just purely strengthening it. Once the reinnervation waiting period was over, one of three patterns would usually emerge: (1) the patient recovered function in the limb and used it, (2) the nerve failed to reach and innervate the muscle, or (3) the reinnervation occurred but disuse would have reduced cortical representation and then, the patient may not know “how to” use the muscle. Electrophysiology was quite useful in differentiating such cases, and modifying the rehabilitation plan at this stage taken into consideration depending on which of these patterns was the case.

## 2.4. Outcome analysis

Our measurement of functional outcomes following surgery was defined as follows based on the Medical Research Council (MRC) motor power grading system [4, 20].

- No improvement in power = only flicker of movement of the affected muscle groups (or affected limb) = MRC 0–1
- Slight or mild improvement in power of affected muscle groups or the involved limb = MRC 2–3
- Significant improvement in power of affected muscle groups or the involved limb = MRC 4–5



The evaluations were carried out at 6 months, 1 year and 2 years after surgery at follow-up in our outpatient clinics.

3. Results

A total of 68 surgeries were completed in 58 patients for various peripheral nerve disorders over the 5-year period. There was an average of about 13.2 surgeries per year, with an increasing frequency as the programme developed. The age of the patients ranged from 2 month to 68 years, with a sex distribution of 41 males and 17 females (ratio of 2.4:1). Overall mean time of presentation was at 18.3 months either post-injury or following onset of symptoms for non-traumatic peripheral nerve problems, with the earliest presentation being 1 day post-obstetric brachial plexus injury in a newborn at birth and the latest being 15 years in 2 patients (one with a left ulnar nerve nodule and the other with a left brachial plexus PNST respectively). The majority of the cases were for brachial plexus injuries (n = 30, 44.1%) comprising 19 adult surgeries and 11 pediatric surgeries. Among the 19 adult surgeries, there were 10 procedures for pan-brachial plexus injuries, 7 for upper brachial plexus injuries and only 2 for lower brachial plexus injuries (**Table 1**). Of the 11 pediatric surgeries, 9 were for obstetric brachial pan-plexus injuries (OBPI—Erb’s-Klumpke type) with one of the patients undergoing surgery twice while the remaining 2 were for road traffic accident traumatic injuries (**Table 1**). There were 21 excisions for peripheral nerve sheath tumors of which four were malignant, with one of these three patients requiring surgery twice (**Table 2**). There were 8 peripheral nerve entrapments comprising 3 posterior interosseous nerve entrapments, 3 cubital tunnel syndromes, 1 thoracic outlet syndrome and 1 Guyon’s canal entrapment syndrome. The remaining 9 surgeries included repair for 2 patients with penetrating ulnar nerve injury, 2 patients with iatrogenic nerve injuries from PNST surgeries done elsewhere (brachial plexus and common peroneal respectively), and procedures for chronic neuralgia (which included 3 DREZ-otomies, image-guided radiofrequency lesioning, open neurotomy of lateral cutaneous nerve of the right forearm and selective fascicular neurectomy of the left distal ulnar nerve). Among the benign lesions, 12 (57.1%) were benign schwannomas, while the remaining 42.9% consisted of various other lesions. Of note, 3 patients undergoing PNST using the fascicular-sparing subcapsular dissection technique noted post-op sensory deficits or paresthesias which were generally transient and none was noted to have any motor deficits.

	n	Percentage
Pan-brachial plexus injury (adult)	9	30.0%
Upper brachial plexus injury (adult)	7	23.3%
Lower brachial plexus injury (adult)	2	6.67%
Obstetric brachial plexus injury (OBPI)	10	33.3%
Surgically managed Non-obstetric traumatic brachial plexus injuries	2	6.67%
Total	30	100.0%

**Table 1.** Distribution of surgery for adult and pediatric brachial plexus injuries.

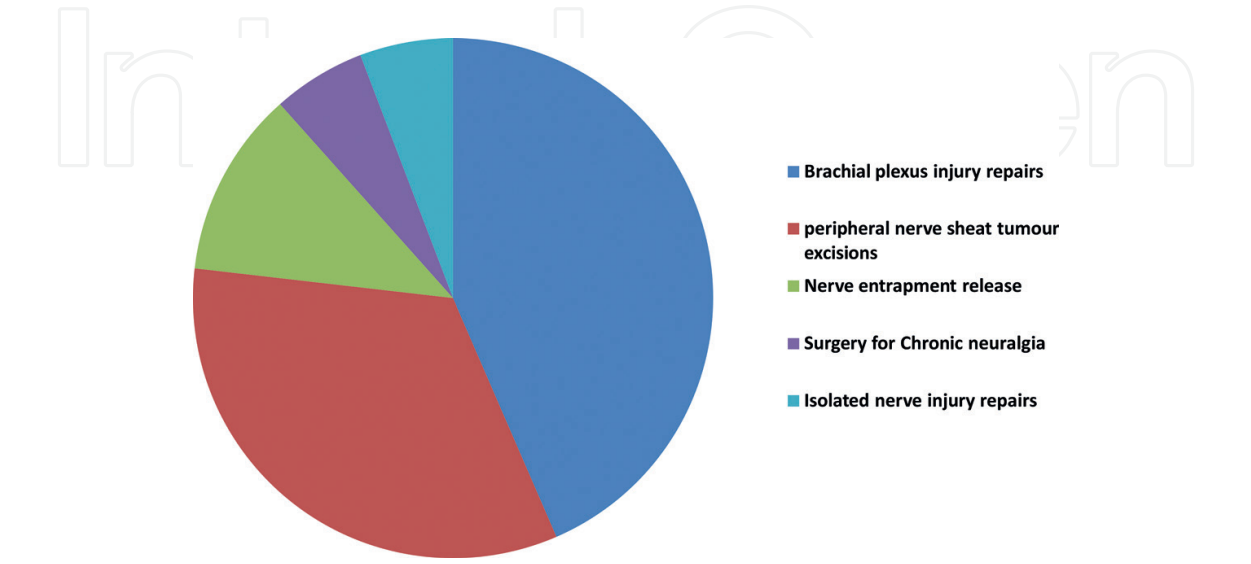
As shown in **Table 3**, the majority of the injuries were repaired with various extraplexal neurotization transfers alone (25.8%), followed by repair with various combinations of extraplexal transfers and intraplexal neurotizations (22.6%), while 19.4% had repair with only intraplexal neurotizations. **Figure 5** summaries all surgeries done over the 5 year period. Brachial plexus

	n	Percentage
Peripheral nerve sheath tumors	21	55.3%
Peripheral nerve entrapments	8	21.1%
Chronic neuralgia	5	13.2%
Common peroneal nerve injury	1	2.6%
Ulnar nerve injury	3	7.9%
Total	38	100.0%

**Table 2.** Distribution of surgery for other lesions (adults and children).

	n	Percentage
Intraplexal neurotization	6	19.4%
Extraplexal neurotization/distal nerve transfers	8	25.8%
Combined intra + extraplexal neurotizations	7	22.6%
Exploration with internal/external neurolysis	3	9.7%
Microsurgical dorsal root entry zone lesioning (DREZ-otomy)	4	12.9%
Only microsurgical exploration + neurophysiological studies	3	9.7%
Total	30	100%

**Table 3.** Breakdown of all procedures done for brachial plexus injuries.



**Figure 5.** Summary of various peripheral nerve surgeries done over the five year period under review. Brachial plexus injury repairs and PNST excisions formed the bulk of the procedures.



	6 months post-op	1 year post-op	2 year post-op
N	19 (100%)	19 (100%)	18 (95%)
No improvements in function	12 (63.2%)	3 (15.8%)	—
Slight improvement	3 (15.8%)	7 (36.8%).	3 (15.8%)
Significant improvement	2 (10.5%)	5 (26.3%)	8 (42.1%)
No follow-up	2 (10.5%)	4 (21.1%)	7 (38.9%)

**Table 4.** Summary of outcomes for the adult brachial plexus injury repair.

	6 months post-op	1 year post-op	2 years post-op
N	11 (100%)	11 (100%)	10 (91%)
No improvements in function	3 (27.2%)	—	—
Slight improvement	4 (36.4%)	3 (27.2%)	—
Significant improvement	2 (18.2%)	5 (45.5%)	8 (72.8%)
No follow-up	2 (18.2%)	3 (27.2%)	2 (18.2%)

**Table 5.** Summary of functional outcomes for the pediatric brachial plexus injuries.

Complication	n	Percentage (%)
Voice hoarseness	2	13.3
Muscle weakness (post-PNST excision)	3	20.0
Operative wound dehiscence	2	13.3
Operative wound infection	3	20.0
Severe intra-op hemorrhage	1	6.67
Apnoeic attacks	1	6.67
Malunion (following claviclectomy for access)	1	6.67
Deep venous thrombosis of affected limb	1	6.67
Post-op pleural effusion	1	6.67
<b>Total</b>	15	100.0

**Table 6.** Post-operative complications.

injury repairs and PNST excisions formed the bulk of the procedures. Outcomes at 6 month, 1 year and 2 years post-op are as summarized in **Tables 4** and **5**. Complications following surgery are as shown in **Table 6**.

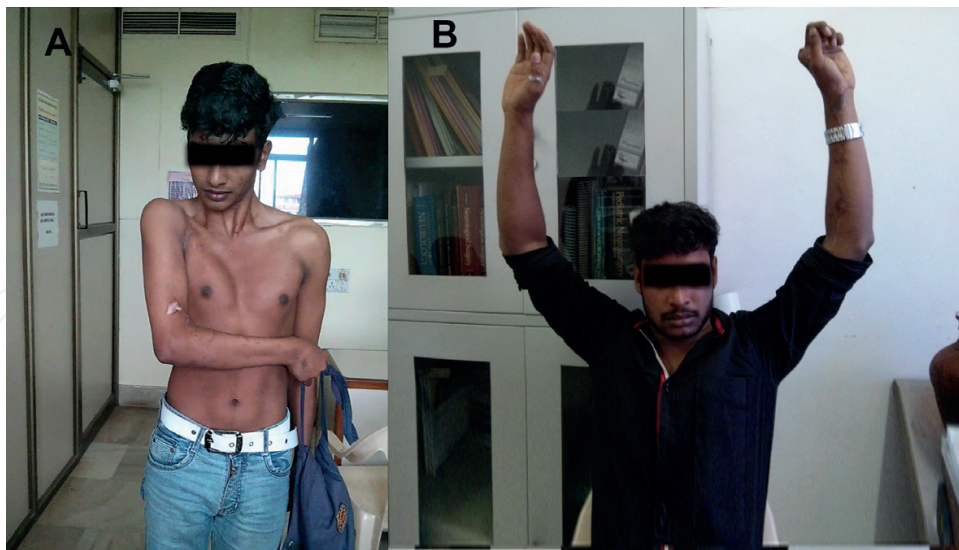## 4. Discussion

### 4.1. Perculiarities, trend, and pattern

Majority of the entire 58 patients were first seen at the out-patient clinic, while a few of them presented via the emergency room. Similar to observations in the literature, the more commonly affected anatomic side was the right side (58.5%) compared to 36.9% of the patients who had their problems on the left, with the remaining 4.6% who were mainly Neurofibromatosis-1 patients having bilateral PNSTs. There was a slight male preponderance of 2.4:1 in this study. Most other investigators similarly reported male predominance in their work (**Table 6**). From the observations as shown in the results, the majority of them were injury cases which were generally brachial plexus injuries (n = 30, 44.1%). Among the adult cases, pan-brachial plexus injuries were the commonest (n = 9; 50%), closely followed by upper brachial plexus injuries (n = 7; 38.9%) while lower brachial plexus injuries were the least (n = 2; 11.1%). Most of these presented fairly late (overall average time of presentation was 18.3 months) as a result of considerable length of time required for referral and transfer to our center following occurrence of the injury. As a result, majority of the procedures were done on elective basis instead of as emergencies. A few other factors which were probably responsible for late presentation possibly included poverty, living far away from our institution, initial visitation or consultation to other alternative healers, and sometimes delayed referral from other medical facilities. The follow-up rate at the end of the 2 year period was 95% for adults (**Table 4**) and 91% for the pediatric cases (**Table 5**) of the brachial plexus injury surgeries. The peripheral nerve sheath tumors ranked next in frequency (n = 21, 30.9%). The timing and pattern of presentation of this set of patients did not differ significantly from the nerve injury patients. Similar to the general pattern in the literature [14], the majority of the peripheral nerve tumors were benign. We had only 8 peripheral nerve entrapments while procedures for chronic neuralgia were the fewest (n = 3, 4.4%). Estimated blood loss was negligible in all surgeries except in one case of longstanding left brachial plexus PNST (**Table 6**). The post-operative complications noted in 22.1% of the patients post-operatively were mostly wound infection and post-PNST excision muscle weakness (**Table 6**).

### 4.2. Outcomes

Anyone would agree that timing of surgery is very crucial in the ultimate outcome. Yet, in spite of the fairly late presentation in the majority, it is clear from **Tables 4** and **5** that despite the relatively small number of 58 patients in our series, there was generally a steady rise in number of those with marked improvement of functional recovery, with a simultaneous decline in the proportion of “no improvements at all” over the same period. We did more of adult brachial plexus injury repairs and became less enthusiastic about pediatric cases as our practice developed because the adult cases generally benefitted from surgical repair (**Figure 6**). In our personal experience with managing 196 cases of Erb’s and Erb’s plus palsies, excellent recoveries were possible in majority of cases with just a proper rehabilitation programme consisting of cerebral retraining and judicious management of co-contraction deformities.



**Figure 6.** (A) Examination to evaluate function at 1 year post-op for extraplexal neurotization repair in a 19 year old male patient who had right brachial plexus injury involving upper and middle trunks. Notice the quite remarkable extent of power recovered particularly with elbow flexion. (B) Examination to evaluate function at 2 years after surgery for distal intraplexal neurotization repair in another 19-year-old male patient who had injury involving only the upper trunk of his right brachial plexus. Compared with the contralateral limb, he had recovery of power to almost the same level with the pre-morbid state.

### 4.3. Our challenges

Among those patients undergoing peripheral nerve procedures for pain, the outcomes were generally poor. The patient with painful neuralgia involving lateral cutaneous nerve of forearm responded only temporarily to two RF (radiofrequency) lesioning procedures, but was relieved completely by proximal neurotomy. However, the same patient eventually later developed another painful neuralgia from the medial antebrachial cutaneous nerve being entrapped in the previous neurotomy surgery scar. The patient who had selective ulnar fasciculotomy for left common palmar digital neuralgia experienced temporary relief for just 2 weeks, followed by recurrence of the same pain. Patients who had DREZ-otomy (dorsal root entry zone lesioning) had excellent initial relief with cessation of incapacitating pain attacks, but constant background neuralgic pain persisted with lesser severity than it was preoperatively. Additionally, for the brachial plexus injury patients, in spite of our meticulous techniques, the restoration of function below the elbow following either partial root avulsion or total root avulsion was our biggest challenge. The benefit of surgery over natural history was not also clear in the cases of OBPI, even despite the fact that only pan-plexus OBPI (Erb's-Klumpke type) were selected for surgical reinnervation. This explains why we did more of adult brachial plexus injury repairs and became less enthusiastic about pediatric repairs as the peripheral nerve programme went on.

Finally, among the several investigative imaging modalities required as standard pre-operative evaluation for peripheral nerve problems, one imaging modality which is emerging as a useful tool in preoperative selection and planning of peripheral nerve surgery is the MR neurogram [4, 41] but this was unavailable for investigating our patients at the time of their evaluation.

#### 4.4. Steps followed in starting and organizing our peripheral nerve unit

One of the key aspects of the practice that can often lead to discouraging results if not properly addressed especially at the initially starting phase is how to select the right cases for surgery and get them properly managed after surgery. We realized that the ability of our efforts to manage these problems individually was limited. We constituted a multidisciplinary team comprising the neurosurgeons, neurologists, physiotherapists, orthopedician and plastic surgeon to review each patient and ensure adequate and appropriate pre-operative planning. The team met once a week and, this way, we were able to prevent the possibilities of inadequate or suboptimal clinical and electrophysiological localization/understanding of the process in each patient, know of any limitations of nerve repairs per case, plan ahead for accurate and reliable intraoperative electrophysiology as well as for reconstructive procedures at the muscle and tendon level. This arrangement also helped with meeting the need for regularized and effective rehabilitation as well as for motivation & consistent follow-up. At surgery, we utilized cable grafts as much as possible to prevent tension on our repair and made use of the operating microscope to ensure adequate microanastomosis. Interestingly, we did not have to advertise our work. There was already a strong referral pattern in our institution for other neurological/neurosurgical problems, and this was further consolidated for peripheral nerve related-problems by our multidisciplinary team. Regarding the problem of getting late referrals, we could only plan surgery based on how late the presentation was. Luckily, none of the patients in our series was too late on arrival as to benefit from only free muscle transfers. Unfortunately for most of such cases, we could not be in contact with the referring physician or health facility to ensure earlier referrals for subsequent cases.

#### 4.5. Comparison with previous findings in the literature

**Table 7** shows previous publications on surgery for various peripheral nerve problems and the documented outcomes. Reports from some of these studies highlight on a few technical factors positively influencing the results post-operatively. With respect to trauma, single coaptation repair of a donor nerve to the recipient nerve (neurotization repair) without tension is thought to be generally superior than indirect repair with a cable graft [13]. Bhatia et al., clearly demonstrated faster recovery and better functional results with direct coaptation compared to nerve graft interposition in carrying out contralateral C7 transfers while in a retrospective study on the effect of combining direct repair with nerve transfer procedures on the clinical outcomes in 74 patients by Sulaiman et al., all patients who had combination of nerve transfers with direct repair using either C5 or C6 recovered elbow flexion to Medical Research Council grade 3, compared to the same extent of recovery in only 87% of those in whom only nerve transfers were done [29, 36]. This further confirms the effectiveness of bypassing the long distance of regeneration by neurotizing the injured distal nerve stumps with more proximally located dispensable donor nerves [29]. In our experience however, though we did not do any comparative assessments like these authors, we attribute our outcomes as presented to the dedicated techniques and approach along with a strict rehabilitation program. We used combinations of cable graft techniques with direct neurotization transfers for majority of the brachial injury surgeries (**Table 3**) and for the functional priorities, elbow flexion and extension were generally the most important function of target we aimed to restore, closely followed by selective reinnervation of the median nerve for prehensile hand function or pincer grip.



Authors and year	No. of patients studied	Mean age	Sex distribution (M:F)	Type of lesion/injury	Surgical techniques evaluated	Key results/outcomes	Maximum/mean follow-up
Guha et al. 2017 [35]	175	45.2 years	96:79	19 MPNSTs, 133 schwannomas, 49 neurofibromas	N/A	Less motor deficits with full resection of tumor;  Increased recurrence with subtotal resections.	29.5 months
Bhatia et al. 2017 [36]	22	23 years for direct coaptation group; 24 years for nerve graft group	19:3	Brachial plexus injuries	Contralateral C7 transfer: By direct coaptation in 12 With graft interposition in 10	Direct coaptation group = Grade 3 flexion in wrist + fingers in 10; Grade 2 flexion in 2  Nerve graft group = Grade 3 flexion in wrist + fingers in only 2; Grade 2 flexion in 7; total failure in 1	26 months for direct coaptation group; 28.5 months for nerve graft group
Sulaiman et al., 2009 [29]	74	32 years	60:14	Brachial plexus injuries; tumor; irradiation	Medial pectoral to musculocutaneous N. transfers (Group 1);  Intercostal to musculocutaneous N. transfers (Group 2)	Recovery of elbow flexion to MRC grade 3 in all (100%) who had both nerve transfer + direct repair with C5/C6 combined, but in only 87 and 22% of those who had only nerve transfers in Group 1 and Group 2 respectively	3.5 years
Badr et al., 2009 [4]	16	16 months	N/A	OBPI (2 Erbs, 6 Erbs plus, 8 Erb-Klumpke palsies)	Neurolysis; graft repairs; nerve transfers	Improvement from preoperative average biceps grade of 0 to 1/5 to average postoperative biceps grade of 2.9 and average shoulder abduction grade of 2.5	23.5 months
Sequeira and Martins, 2009 [27]	10	24.8 years	9:1	Complete brachial plexus palsy	Nerve transfers: phrenic to musculocutaneous N + spinal accessory to suprascapular N	Recovery to functional level in 7 (MRC Grade 3 in 5; Grade 4 in 2)  No clinically significant respiratory problem in all 10 cases.	3.4 years
N/A, information not available; MPNSTs, malignant peripheral nerve sheath tumors; MRC, Medical Research Council; OBPI, obstetric brachial plexus injury.							

**Table 7.** Previous publications on outcomes of various surgical techniques for peripheral nerve problems.

Regarding tumors, Guha et al., in managing 201 peripheral nerve sheath lesions (182 benign and 19 malignant) in 175 patients over a 17-year period, observed that subtotal resection was associated with the increased recurrence of the benign lesions and that the probability of motor function worsening postoperatively was much less in patients in whom the tumors were fully resected [35]. They also observed that the extent of resection in those who had schwannoma was greatly influenced by tumor location, with lesions located in the extremities being more likely to be fully resected than plexal tumors that were brachial, thoracic, or lumbosacral [35]. This was likely due to better anatomical accessibility [35]. They concluded by suggesting gross total resection for all benign lesions as much as possible [35]. In our own strategy however, we similarly dissected the tumor in its subcapsular plane for PNSTs to ensure that non-involved fascicles remained functionally intact but observed no recurrence of the benign lesions in any of our patients whereas oncological resection and not subcapsular dissection was our goal for the malignant ones (MPNST) in view of the life-threatening nature of the pathology, even at the cost of functional compromise.

#### 4.6. General principles

Detailed examination of these patients should be followed up by nerve conduction studies and radiological imaging to localize and characterize peripheral nerve lesions or associated neurologic injury [3, 5, 8, 22]. The appropriate imaging modalities for evaluation should be selected depending on the particular clinical circumstance [3, 5, 8]. Plain-film X-ray, computerized tomography myelogram (CT), magnetic resonance imaging (MRI), ultrasound (US), as well as positron emission tomography (PET) all have their various indications in the management of peripheral nerve problems [3, 40]. For instance, transverse process fractures of the cervical vertebrae on cervical spine x-rays might indicate root avulsion at the same level [3, 22] and a distal neurotization repair can be preoperatively decided upon. CT myelography can be used to define the level of nerve root injury preferably within 4 weeks of the injury [3, 22]. Ultrasound may be used in some selected situations for localizing peripheral nerve entrapment and for image guidance in percutaneous interventions [3, 10]. One imaging modality which is emerging as a useful tool in preoperative selection and planning of peripheral nerve surgery is the MR (magnetic resonance) neurogram [3, 15, 37]. Of all these modalities, MRI and CT myelogram are generally the main radiological investigations for diagnosis of problems involving the brachial plexus [3, 5, 9, 37, 40].

Electrodiagnostic studies are equally essential, particularly electromyography (EMG) and nerve conduction studies (NCS). For example, preservation of sensory nerve action potentials (SNAPs) in extensive brachial plexus injuries with severe motor deficits is highly indicative of preganglionic injury and root avulsion. Additionally, serial compound motor action potential (CMAP) studies at 6 week periods give the surgeon an estimate of the spontaneous recovery potential of an injury (i.e., the classical neuropraxia and axonotmesis injury versus neurotmesis patterns) [18, 25]. When the electrophysiology findings are combined with the longitudinal clinical evaluation of motor recovery, the surgeon can then better decide upon timing and extent of repair required.

##### 4.6.1. Brachial plexus injury repairs

Intra-operatively, the integrity of the donor nerve is a major determining factor for successful outcomes [13]. Single coaptation repair of a donor nerve to the recipient nerve (neurotization

repair) without tension is generally considered superior to indirect repair with a cable graft, since only one microanastomosis is required [13, 45]. This is particularly important for weak donor nerves such as the spinal accessory nerve [13, 51]. According to functional priorities, elbow flexion and extension are generally the most important function to restore [19, 43]. Active shoulder control and stability is then considered next most important [50], followed by abduction, external rotation, wrist extension and scapular stabilization prioritized in that order [19]. Finally, managing each patient's expectations is perhaps the most important part of pre-operative planning and preparation [19]. Patients must be made to understand the limits of the best possible outcome and the possibility that either no improvement at all or limited functional improvement may occur after surgery [19].

The workhorse of brachial plexus repair surgery is still largely the neurotization transfers and nerve grafting [5, 6, 13, 17, 19, 23, 24, 29, 38, 42, 44, 48, 50, 51]. The muscles of the shoulder and the biceps brachii have classically been the main targets for repair of brachial plexus injuries [17, 29, 38, 48]. However, there is now more importance on equally focusing on restoring at least elbow extension for functionality and even newer attempts at selective reinnervation of the median nerve for prehensile hand function or pincer grip [33, 39, 42]. For proximal upper limb functions, the two most important distal transfers are neurotization of the suprascapular nerve with spinal accessory nerve through a posterior approach for shoulder abduction and Oberlin's double fascicular transfer of ulnar and median nerve fascicles to the biceps and brachialis branches of the musculocutaneous nerve for elbow flexion [8, 19, 23, 24, 26, 31, 33, 38, 47]. Case series reports have demonstrated very low long term donor nerve functional impairment resulting from thoracoscopic full-length phrenic nerve harvest and transfers and contralateral C7 transfer [8, 12, 13, 19, 27, 28, 33, 43, 44]. Our experience with these two procedures was very similar. Microsurgical dorsal root entry zone lesioning (DREZ) has been used to effectively control the intractable pain that follows brachial plexus injuries, particularly for the refractory cases [7, 11].

#### 4.6.2. Nerve entrapments and painful neuropathies

For treatment of cubital tunnel syndrome, the anterior transposition of ulnar nerve may be done in either the subcutaneous or the intramuscular plane [30]. In situ decompression of the ulnar nerve with or without medial epicondylectomy as an alternative technique has also been well described with its pros and cons [30]. For patients with Guyon's canal syndrome, initial approach should be conservative care including immobilization, ergonomic modifications of habitual movement, and local injection of cortisone is advocated except for the refractory cases [2]. However, early motor involvement is common and one should then proceed to surgical decompression. At surgery, the skin incision should extend to both the wrist and palmar line, and the ulnar nerve and artery should be adequately freed at the level of the Guyon's canal [2] (**Figure 4A and B**). Posterior interosseous nerve (PIN) entrapment creates a functionally disabling pure motor deficit. For PIN release, the nerve must first be identified proximally between brachioradialis and extensor carpi radialis longus and distally between extensor carpi radialis brevis and extensor digitorum communis at the point where it enters the supinator, and should also include adequate division of the compressive supinator fibers.

#### 4.6.3. Tumors

The goal of surgical intervention in PNST is excision of the tumor to alleviate the symptoms caused by neural compression without incurring a sensorimotor deficit [14]. In MPNST, however, oncological resection is the goal given the life-threatening nature of the pathology, even at the cost of functional compromise. In such situations, nerve graft repair can be planned preoperatively. General, regional or local anesthesia may be used [14]. For general anesthesia, anesthetist must avoid the use of muscle relaxants since these agents would ultimately prevent the use of intraoperative stimulation and monitoring [14]. The limb should be exposed so as to monitor the distal muscle response to fascicular stimulation (**Figure 3**). The incision should be made over the involved portion of the nerve starting from 2 to 4 cm proximal to and extending 2 to 4 cm distal to the tumor [14]. The probability of malignant degeneration of a PNST to MPNST should be assessed preoperatively by (1) size, (2) presence and character of pain, (3) radiological criteria (MRI, PET), and (4) the presence of type 1 neurofibromatosis (which has a 20% propensity for MPNST). If suspicion of MPNST is low, a subcapsular enucleation of the tumor mass (usually schwannomatous) offers the best chance of gross total excision with relief of compressive symptoms and simultaneous functional preservation of the nerve fascicles. However, when any combination of these features indicate high suspicion of an MPNST, thorough preoperative planning and counseling should be done for nerve sacrifice to maintain oncologically complete resection and subsequent grafting repair. Oncologically speaking, the option of initial tumor biopsy for confirming the histology followed by total resection is not ideal since violation of soft tissue planes leads to a higher chance for adjacent tissue seeding of sarcomatous cells and even delayed distant recurrence. If a nerve graft was done, the limb should be immobilized with a splint for 2–3 weeks to allow for epineural healing without tension at the anastomosis [14]. Fortunately, the majority of peripheral nerve tumors are benign [14].

#### 4.6.4. Rehabilitation

Rehabilitation constitutes the remaining postoperative period until the patient achieves maximal functional and neurological recovery [49]. This can often be rather prolonged, and major depression related to extent of injury and surgery is a common factor that needs specific attention in order to improve outcomes. Once the concerned limb can be mobilized, the primary goals are prevention of contracture by passive ROM (range of motion) [41, 49]. This helps prevent complex regional pain syndrome (CRPS), and allows for a more useful limb once muscle reinnervation occurs. Within this time frame, orthotics is useful in preventing contractures at rest. This phase can extend up to 6–9 months post-operatively.

Once a flicker of contraction was found in the concerned muscles, we began isolating and strengthening them with gravity initially, progressing to “against gravity,” and then with resistance. Once the patient could move against gravity, it was useful to add functional tasks into the exercise programme since motor coordination is as important as strength in recovery [41]. With this process, the patient would gradually develop “different” ways of doing old tasks to compensate for weakness of the primary effector muscle. This was achieved by utilizing the secondary effector muscles which changed the appearance of task performance. It remained with the physiotherapist to track recovery and see if these different ways were



acceptable or not, followed by modification of the therapy plan as required. For example, the patient may develop “whip-like” movements to initiate shoulder abduction. If there was little hope of recovering deltoid function, then focusing on stabilizing the involved muscles above and below became more practical than utilizing electrical current to recover this muscle’s mass. If the chance of functional recovery was high, then training the concerned muscle to become activated at the correct time in the kinetic chain became more useful than just purely strengthening it. Once the reinnervation waiting period was over, one of three patterns would usually emerge: (1) the patient recovers function in the limb and uses it, (2) the nerve fails to reach and innervate the muscle, or (3) the reinnervation occurs but disuse would have reduced cortical representation and then, the patient may not know “how to” use the muscle. Electrophysiology was useful in differentiating such cases, and modifying the rehabilitation plan taken into consideration depending on which of these patterns was the case.

## 5. Present challenges with peripheral nerve surgery

In spite of a growing number of good surgical alternatives currently available such as introduction of phrenic nerve transfer to medial root of median nerve for prehensile hand function, the restoration of function below the elbow following either partial root avulsion or total root avulsion presently remains the biggest challenge in brachial plexus surgery [8, 13, 25, 33, 39, 42]. Avulsion injuries from C5 to T1 have been shown to be amenable to restoration of good shoulder and elbow function, but the restoration of satisfactory distal function is still yet to be well demonstrated [8]. However, new techniques to circumvent this problem have recently been proposed [39, 42]. For the obstetric brachial plexus injuries, another particular challenge is the restoration of abduction and external rotation in the shoulder joint [18] which is largely limited due to developmental apraxia which occurs at a cerebral level.

Regarding investigation and preoperative planning, EMG and nerve conduction studies have their own limitations [18, 25]. EMG itself only reflects the function of the individual motor units in a nerve and not really that of the entire nerve or the cerebral retraining required to establish function [25]. Also, in severe cases with a flail anesthetic arm, the absence of SNAPs often clearly indicates damage to post-ganglionic elements but cannot exclude a mixed lesion with associated root avulsion [18].

Furthermore, there are currently only limited algorithms to guide the surgeon on carrying out nerve transfers [13, 52]. The choice of which transfer to utilize in each case is largely dependent on each surgeon’s philosophy, knowledge and experience as well as patient-related factors, a clear understanding of the involved anatomy of the brachial plexus in each patient, what is uninjured and still viable for nerve transfer repair, as well as available facilities and equipment [8, 13, 52]. A combination of long and variable recovery periods, variable patterns of injury, individual patient recovery factors and lack of uniformity in rehabilitation all lead to the overall lack of objective evidence-based guidelines for management. For pediatric patients, the criteria and timing of surgical intervention also still remains controversial [4]. Some have used the absence of recovery of the biceps muscle

or shoulder function by 3 months of age as the indication for surgery in obstetric brachial plexus injury (OBPI), while others use 4 months or even 9 months as the time limit [4, 32]. In our personal experience with managing 196 cases of Erb's and Erb's plus palsies, excellent recoveries were possible in majority of cases with a proper rehabilitation programme consisting of cerebral retraining and judicious management of co-contraction deformities. Some would argue that deformities are less common with early nerve repair in OBPI, but this is yet to be proven definitively.

Finally, even though microsurgical repair of nerve injuries has advanced significantly over time, satisfactory functional recovery still remains a challenge [29]. The ultimate goal of a nerve repair should be a functional improvement that creates satisfaction for the patient in his or her daily activities and occupation and not simple improvement in the muscle power grading. This requires dedicated efforts in physical, psychological and vocational rehabilitation. Augmentation of the paralyzed limb using reanimative muscle or tendon transfer surgeries by the plastic surgeon often improves outcomes. Hence, a multidisciplinary team is ideal.

## 6. Conclusion

In this chapter, we have described the pattern and trend of peripheral nerve problems in our practice, and presented our challenges and outcomes, as well as the steps we followed to organize our peripheral nerve unit, followed by a review of general guidelines and principles of care. Peripheral nerves related problems, are unfortunately only palliated in most developing countries across the world. Although our experience in surgically treating these problems is still developing and with the few limitations as presented, the final outcomes demonstrate that surgical intervention is still better than just palliative measures alone or even nothing at all. We could still manage the problems successfully with fairly good outcomes despite few setbacks such as late presentation of patients, as well as unavailability of full investigative imaging modalities required as standard pre-operative evaluation for peripheral nerve problems. We are hopeful that this brief presentation would be a useful impetus for the introduction, development and implementation of nerve surgery programmes in other developing countries around the world.

## Competing interests

The authors declare that they have no competing interests.

## Funding/material support

None.

## Author details

Chiazor U. Onyia<sup>1</sup>, Ravi Sankaran<sup>2</sup> and Ashok Pillai<sup>3\*</sup>

\*Address all correspondence to: brashok@aims.amrita.edu

1 Neurosurgery Division, Department of Surgery, Obafemi Awolowo University Teaching Hospitals Complex, Ile-Ife, Nigeria

2 Department of Physical Medicine and Rehabilitation, Amrita Institute of Medical Sciences and Research, Kochi, Kerala, India

3 Department of Neurosurgery, Amrita College of Medicine, Ernakulam, Kerala, India

## References

- [1] Abuelem T, Ehni BL. Minimalist cubital tunnel treatment. *Neurosurgery*. 2009;**65**:A145-A149
- [2] Aguiar PH, Bor-Seng-Shu E, Fernando Gomes-Pinto F, Almeida-Leme RJ, Freitas ABR, Martins RS, et al. Surgical management of Guyon's canal syndrome—An ulnar nerve entrapment at the wrist: Report of two cases. *Arquivos de Neuro-Psiquiatria*. 2001;**59**(1):106-111
- [3] Amrami KK, Port JD. Imaging the brachial plexus. *Hand Clinics*. 2005;**21**:25-37
- [4] Badr Y, O'Leary S, Kline DG. Management of one hundred seventy-one operative and nonoperative obstetrical birth palsies at the Louisiana State University Health Sciences Center. *Neurosurgery*. 2009;**65**:A67-A73
- [5] Bhandari PS, Sadhotra LP, Bhargava P, Bath AS, Mukherjee MK, Babu P. Current trends in the management of brachial plexus injuries. *Indian Journal of Neurotrauma*. 2008;**5**(1):21-25
- [6] Bishop AT. Functioning free-muscle transfer for brachial plexus injury. *Hand Clinics*. 2005;**21**:91-102
- [7] Bonilla G, Masi GD, Battaglia D, Otero JM, Socolovsky M. Pain and brachial plexus lesions: Evaluation of initial outcomes after reconstructive microsurgery and validation of a new pain severity scale. *Acta Neurochirurgica*. 2011;**153**:171-176
- [8] Brophy RH, Wolfe SW. Planning brachial plexus surgery: Treatment options and priorities. *Hand Clinics*. 2005;**21**:47-54
- [9] Carvalho GA, Nikkhah G, Matthies C, Penkert G, Samii M. Diagnosis of root avulsions in traumatic brachial plexus injuries: Value of computerized tomography myelography and magnetic resonance imaging. *Journal of Neurosurgery*. 1997;**86**:69-76
- [10] Chien AJ, Jamadar DA, Jacobson JA, Hayes CW, Louis DS. Sonography and MR imaging of posterior interosseous nerve syndrome with surgical correlation. *AJR*. 2003;**181**:219-221

- [11] Chen HJ, Tu YK. Long term follow-up results of dorsal root entry zone lesions for intractable pain after brachial plexus avulsion injuries. *Acta Neurochirurgica. Supplement.* 2006;**99**:73-75
- [12] Chen L, Gu Y, Hu S, Xu J, Xu L, Fu Y. Contralateral C7 transfer for the treatment of brachial plexus root avulsions in children—A report of 12 cases. *The Journal of Hand Surgery.* 2007;**32**(1):96-103
- [13] Chuang DC. Nerve transfers in adult brachial plexus injuries: My methods. *Hand Clinics.* 2005;**21**:71-82
- [14] Dorsi MJ, Belzberg AJ. Peripheral nerve tumors of the extremities; in a. In: Quiñones-Hinojosa, editor. *Schmidek and Sweet Operative and Neurosurgical Techniques—Indications, Methods and Results.* 6th ed. Philadelphia: Elsevier Saunders; 2012. pp. 2319-2327
- [15] Filler A. Magnetic resonance neurography and diffusion tensor imaging: Origins, history and clinical impact of the first 50,000 cases with an assessment of efficacy and utility in a prospective 5000-patient study group. *Neurosurgery.* 2009;**65**:A29-A43
- [16] Friedman AH. An eclectic review of the history of peripheral nerve surgery. *Neurosurgery.* 2009;**65**(4):A3-A8
- [17] Fournier HD, Mercier P, Menei P. Repair of avulsed ventral nerve roots by direct ventral intraspinal implantation after brachial plexus injury. *Hand Clinics.* 2005;**21**:109-118
- [18] Harper CM. Preoperative and intraoperative electrophysiologic assessment of brachial plexus injuries. *Hand Clinics.* 2005;**21**:39-46
- [19] Kline DG, Tiel RL. Direct plexus repair by grafts supplemented by nerve transfers. *Hand Clinics.* 2005;**21**:55-69
- [20] Laurent JP, Lee R, Shenaq S, Parke JT, Solis IS, Kowalik L. Neurosurgical correction of upper brachial plexus birth injuries. *Journal of Neurosurgery.* 1993;**79**:197-203
- [21] McCarthy MJ, Varty K, Bell PRF. Experience of supraclavicular exploration and decompression for treatment of thoracic outlet syndrome. *Annals of Vascular Surgery.* 1999;**13**:268-274
- [22] Moran SL, Steinmann SP, Shin AY. Adult brachial plexus injuries: Mechanism, patterns of injury, and physical diagnosis. *Hand Clinics.* 2005;**21**:13-24
- [23] Ray WZ, Pet MA, Yee A, Mackinnon SE. Double fascicular nerve transfer to the biceps and brachialis muscles after brachial plexus injury: Clinical outcomes in a series of 29 cases. *Journal of Neurosurgery.* 2011;**114**:1520-1528
- [24] Ray WZ, Yarbrough CK, Yee A, Mackinnon SE. Clinical outcomes following brachialis to anterior interosseous nerve transfers—Report of 4 cases. *Journal of Neurosurgery.* 2012;**117**:604-609
- [25] Robert EG, Happel LT, Kline DG. Intraoperative nerve action potential recordings: Technical considerations, problems and pitfalls. *Neurosurgery.* 2009;**65**:A97-A104



- [26] Schaakxs D, Bahm J, Sellhaus B, Weis J. Clinical and neuropathological study about the neurotization of the suprascapular nerve in obstetric brachial plexus lesions. *Journal of Brachial Plexus and Peripheral Nerve Injury*. 2009;**4**:15
- [27] Sequeira MG, Martins RS. Phrenic nerve transfer in the restoration of elbow flexion in brachial plexus avulsion injuries: How effective and safe is it? *Neurosurgery*. 2009;**65**:A125-A131
- [28] Songcharoen P, Wongtrakul S, Spinner RJ. Brachial plexus injuries in the adult. Nerve transfers: The Siriraj hospital experience. *Hand Clinics*. 2005;**21**:83-89
- [29] Sulaiman OAR, Kim DD, Burkett C, Kline DG. Nerve transfer surgery for adult brachial plexus injury: A 10-year experience at Louisiana State university. *Neurosurgery*. 2009;**65**:A55-A62
- [30] Tang P, Plancher KD, Bishai SK. Anterior submuscular transposition of the ulnar nerve. *Techniques in Orthopaedics*. 2006;**21**(4):318-324
- [31] Tung TH, Novak CB, Mackinnon SE. Nerve transfers to the biceps and brachialis branches to improve elbow flexion strength after brachial plexus injuries. *Journal of Neurosurgery*. 2003;**98**:313-318
- [32] van Ouwerkerk WJR, van der Sluijs JA, Nollet F, Barkhof F, Slooff ACJ. Management of obstetric brachial plexus lesions: State of the art and future developments. *Child's Nervous System*. 2000;**16**:638-644
- [33] Xu W, Lu J, Qiu Y, Jiang S, Xu L, Xu J, et al. Hand prehension recovery after brachial plexus avulsion injury by performing a full-length phrenic nerve transfer via endoscopic thoracic surgery. *Journal of Neurosurgery*. 2008;**108**:1215-1219
- [34] Zhao X, Lao J, Hung L, Zhang G, Zhang L, Gu Y. Selective neurotization of the median nerve in the arm to treat brachial plexus palsy: Surgical technique. *JBJS*. 2004;**86A**:736-742
- [35] Guha D, Davidson B, Nadi M, Alotaibi NM, Fehlings GM, Gentili F, et al. Management of peripheral nerve sheath tumours: 17 years of experience at Toronto Western Hospital. *Journal of Neurosurgery*. 2018;**128**(4):1226-1234
- [36] Bhatia A, Doshi P, Koul A, Shah V, Brown JM, Salama M. Contralateral C7 transfer: Is direct repair really superior to grafting? *Neurosurgical Focus*. 2017;**43**(1):E3
- [37] Upadhyaya V, Upadhyaya DN, Mishra B. MR neurography in traumatic non-obstetric paediatric brachial plexopathy. *European Radiology*. 2018;**28**(6):2417-2424
- [38] Hu CH, Chang TN, Lu JC, Laurence VG, Chuang DC. Comparison of surgical strategies between proximal nerve graft and/or nerve transfer and distal nerve transfer based on functional restoration of elbow function: A retrospective review of 147 patients. *Plastic and Reconstructive Surgery*. 2018;**141**(1):68e-79e
- [39] Wu X, Cong XB, Huang QS, Ai FX, Liu YT, Lu XC, et al. Transposition of branches of radial nerve innervating supinator to posterior interosseus nerve for functional reconstruction of finger and thumb in 4 patients with middle and lower trunk root avulsion injuries of brachial plexus. *Journal of Huazhong University of Science and Technology. Medical Sciences*. 2017;**37**(6):933-937

- [40] Fuzari HKB, Dornelas de Andrade A, Vilar CF, Sayão LB, Diniz PRB, Souza FH, de Oliveira DA. Diagnostic accuracy of magnetic resonance imaging in post-traumatic brachial plexus injuries: A systematic review. *Clinical Neurology and Neurosurgery*. 2018;**164**:5-10
- [41] Bains R, Kattan A, Curtis CG, Stephens D, Borschel G, Clarke HM. Active range of motion over time in patients with obstetrical brachial plexus palsy: A 10-year analysis. *Journal of Hand Surgery American*. 2018;**43**(4):386.e1-386.e7
- [42] Abou-Al-Shaar H, Karsy M, Ravindra V, Joyce E, Mahan MA. Acute repair of traumatic pan-brachial plexus injury: Technical considerations and approaches. *Neurosurgical Focus*. 2018;**44**(Suppl1):V4
- [43] Li WJ, He LY, Chen SL, Lyu YW, Wang SF, Yong Y, et al. Contralateral C7 nerve root transfer for function recovery in adults: A meta-analysis. *Chinese Medical Journal*. 2017;**130**:2960-2968
- [44] Mathews AL, Yang G, Wan-Chu Chang K, Chung KC. A systematic review of outcomes of contralateral C7 transfer for the treatment of traumatic brachial plexus injury: An international comparison. *Journal of Neurosurgery*. 2017;**126**(3):922-932
- [45] Bahm J, Gkotsi A, Bouslama S, El-Kazzi W, Schuind F. Direct nerve sutures in (extended) upper obstetric brachial plexus repair. *Journal of Brachial Plexus and Peripheral Nerve Injury*. 2017;**12**(1):e17-e20
- [46] Jácome DT, de Alencar HFU, de Lemos MVV, Kobig RN, Rocha JFR. Axillary nerve neurotisation by a triceps motor branch: Comparison between axillary and posterior arm approaches. *Revista Brasileira de Ortopedia*. 2018;**53**(1):15-21
- [47] Chang KWC, Wilson TJ, Popadich M, Brown SH, Chung KC, Yang LJS. Oberlin transfer compared with nerve grafting for improving early supination for neonatal brachial plexus palsy. *Journal of Neurosurgery. Pediatrics*. 2018;**21**:178-184
- [48] Murison J, Jehanno P, Fitoussi F. rve transfer to biceps to restore elbow function and supination in children with obstetrical brachial plexus palsy. *Journal of Children's Orthopaedics*. 2017;**11**:455-459. DOI: 10.1302/1863-2548.11.170125
- [49] El-Shamy S, Alsharif R. fect of virtual reality versus conventional physiotherapy on upper extremity function in children with obstetric brachial plexus injury. *Journal of Musculoskeletal & Neuronal Interactions*. 2017;**17**(4):319-326
- [50] Vanaclocha V, Herrrera JM, Rivera-Paz M, Martinez-Gómez B, Vanaclocha L. Radial to axillary nerve transfer. *Neurosurgical Focus*. 2018;**44**(Suppl 1):V1
- [51] Bulstra LF, Rbia N, Kircher MF, Spinner RJ, Bishop AT, Shin AY. Spinal accessory nerve to triceps muscle transfer using autologous long nerve grafts for recovery of elbow extension in traumatic brachial plexus injuries. *Journal of Neurosurgery*. Dec 8, 2017:1-7
- [52] Pondaag W, van Driest FY, Groen JL, Malessy MJA. Early nerve repair in traumatic brachial plexus injuries in adults: Treatment algorithm and first experiences. *Journal of Neurosurgery*. Jan 26, 2018:1-7

