

# We are IntechOpen, the world's leading publisher of Open Access books Built by scientists, for scientists

6,900

Open access books available

186,000

International authors and editors

200M

Downloads

Our authors are among the

154

Countries delivered to

TOP 1%

most cited scientists

12.2%

Contributors from top 500 universities



WEB OF SCIENCE™

Selection of our books indexed in the Book Citation Index  
in Web of Science™ Core Collection (BKCI)

Interested in publishing with us?  
Contact [book.department@intechopen.com](mailto:book.department@intechopen.com)

Numbers displayed above are based on latest data collected.  
For more information visit [www.intechopen.com](http://www.intechopen.com)



---

# Supportive Periodontal Therapy for Dental Implant Patients

---

Krishna Kripal and Kavita Chandrasekaran

Additional information is available at the end of the chapter

<http://dx.doi.org/10.5772/intechopen.77950>

---

## Abstract

Some of the early indicators of future implant failure are increased plaque accumulation, bleeding upon probing, increased probing pocket depth, abscess formation, bone loss seen under radiographic, retrograde tooth wear and broken restoration. A periodic supportive periodontal treatment visit allows for early detection and intervention to provide an opportunity to salvage an ailing implant. Presence of biofilm/plaque on the implant may progress to peri-implantitis with bone resorption. Microbial challenge in the oral environment may result in pathological reactions in peri-implant tissues and thereby compromising tissue integration. The long-term success of implants depends on adequate supportive periodontal treatment visits. Prevention of disease is a key factor in the aim of preserving the supporting tissues around implants. Thus, sufficient supportive therapy during maintenance is inevitable in order to achieve optimal results in implant dentistry.

**Keywords:** implant, implant failure, peri implant mucositis, peri implantitis, supportive periodontal therapy

---

## 1. Introduction

Adequate supportive periodontal treatment visits are needed for the long-term success of implants [1]. Some percentage of implants ultimately fail and majority that fail, do so soon after placement [2]. Early indicators of future implant failure includes excessive plaque accumulation, Bleeding on probing, Increased probing depth, suppuration, radiographic bone loss, retrograde wear and broken restorations and hence supportive periodontal visits allows for early intervention to enable clinician to save an ailing implants.

Primary causes of implant failure have been suggested to be plaque, bacterial infection and traumatic occlusal forces [3]. Some of the bacterial species found to be associated with failing implants are reported to be *Aggregatibacter actinomycetemcomitans*, *Prevotella intermedia*, *Porphyromonas gingivalis*. Other species shown to be associated are Spirochetes and Fusobacterium. It has been observed that poor oral hygiene facilitates the growth of such anaerobic bacteria and in presence of plaque, the implants may clinically present with peri-implantitis with bone resorption [4]. Several studies have shown the development of the peri-implant infection progressed at a similar rate as the development of periodontitis lesion.

Implant is “any object or material, such as an alloplastic material or other tissues, which is partially or completely inserted and grafted on to the body for the diagnostic, prosthetic and experimental purposes” [5]. As defined by Glossary of Prosthodontics terms. In the late 1950s, Per Ingvar Branemark, a Swedish Professor in Anatomy, studying blood circulation in bone and marrow, developed through a serendipitous finding a historical breakthrough in medicine he predictably achieved an intimate bone to implant apposition that offered sufficient strength to cope with load transfer, he called the phenomenon as “osseointegration” [6].

In 1965 the first patient was treated by means of this approach for a law edentulous jaw. One definition of osseointegration was provided by Albrektson et al. (1981) [7] who suggested that this was a direct structural and functional connection between living bone and the surface of load carrying implants. As defined by Zarb and Albrektson “a process whereby clinically asymptomatic rigid fixation of alloplastic materials is achieved and maintained in bone during functional loading” [8].

A series of screw shaped, commercially pure titanium implants were inserted in the symphysis and left covered for a few months. Commercially pure titanium implants were inserted in the symphysis and left uncovered for a few months. The gingival and mucosal tissues were reopened and titanium abutments were placed, on top of which fixed prosthesis could be screwed. All implants appeared firmly anchored. Since that time millions of people have been treated worldwide using this technique. The implants used sometimes had different geometrics and surface characteristics.

The serendipitous finding of Branemark was that when a hole is prepared in the bone without traumatizing the tissues or overheating, an inserted biocompatible implantable would achieve an intimate bone apposition and micro movements at the interface were prevented during early healing period [6].

A successful outcome of implant therapy depends on number of factors. A satisfactory healing following implant placement is determined by biocompatibility of implant material and surgical technique. Presence of microbes and their interaction with host tissues in the oral environment may result in pathological reaction in the peri-implant tissues and thereby compromising tissue integration. Thus prevention of disease is a key factor in the aim of preserving the supporting tissues around implants.

## 2. Soft and hard tissue integration

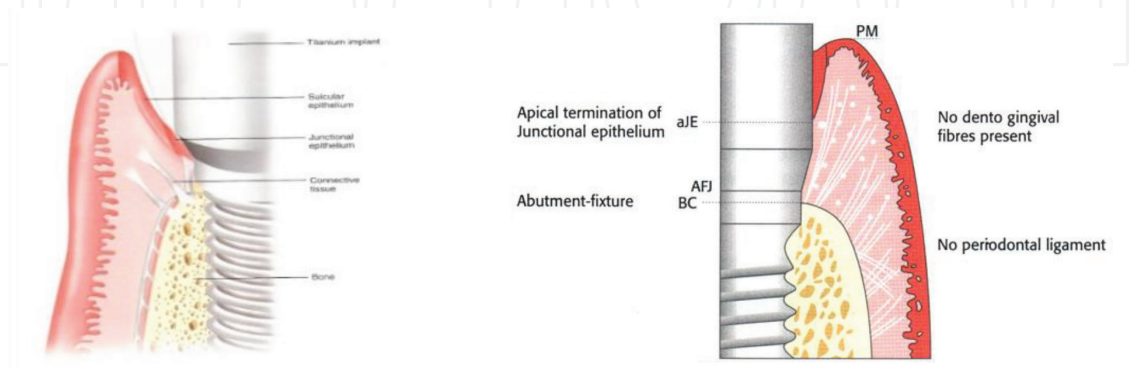
The integration of hard and soft tissues with implants is the result of wound healing process. A blood clot is formed within of the surgical procedure. After a few days, there is infiltration of the clot by vascular structures and abundant inflammatory cells to form a granulation tissue. The continuation of the healing process involves the organization of connective tissue by modification of granulation tissue. This is followed by the formation of bone which in turn results in osseointegration at the recipient site.

Formation of barrier epithelium adjacent to implants and apical to the epithelium the connective tissue that integrates with titanium surface prevents the epithelial migration. The barrier epithelium and connective tissue/implant interface establish a specific biological width of peri implant mucosa.

## 3. Peri implant mucosa and gingiva

The soft tissue that surrounds the transmucosal parts of implant is termed as peri-implant mucosa. The structure and dimension of this mucosa is similar to that of gingiva around the teeth. The concept of biological width controls the thickness of soft tissue adjacent to both teeth and implants. Some fundamental differences also exist between these two tissue types in terms of gingival fibers, periodontal fibers and periodontal ligament space.

In tooth, a layer of cementum covers the surface of root. From the cementum, the collagen fibers run in a perpendicular direction to the long axis of the tooth and insert into the surrounding hard and soft tissues. But, the implant lacks the cemental layer and, hence, collagen fibers are unable to attach to the implant surface in the same way as around the tooth. Thus, the collagen fibers are aligned in different directions and in the tissue which is in immediate lateral surface to the implant surface. The collagen fibers are orientated parallel to the long axis of the implant. Nevertheless, an effective soft tissue seal to the oral environment is provided by the biological attachment formed by the barrier epithelium and the connective tissue in the mucosa surrounding the implant (**Figure 1**).



**Figure 1.** Peri-implant mucosa.

### 3.1. Examination of peri-implant tissues

Increasing probing depth and loss of clinical attachment are pathognomonic for periodontal disease. Pocket probing is, therefore, a crucial procedure in diagnosis of the periodontium and for the evaluation of periodontal therapy. The major clinical criteria used to determine the success of periodontal treatment are reduction of probing depth and gain of clinical attachment level. The penetration of probe is greatly influenced by various factors such as the roughness of the root surface, the inflammatory state of the periodontal tissues and the firmness of the marginal cuff.

The limitations of probing are – (i) it often fails to identify the histological level of the connective tissue attachment as determined by various studies; (ii) it has a limited reproducibility; variations of 1 mm have to be expected under clinical conditions. The changes that occurred in the past are reflected by measurements of clinical attachment level. Once disease is detectable by clinical attachment level measurement, it is indicative of substantial, and possibly irreversible, tissue changes have already occurred.

Some of the advantages of probing are—the simplicity of the method and the immediate availability of the results. Also, the topographical disease patterns can also be demonstrated. The results from a histological study determining the extent of peri-implant probe penetration in dogs indicate that the density of the peri-implant tissues influences penetration depth. In inflamed tissues around one-stage non submerged implants, periodontal probes penetrated close to the bone level, whereas the probe tips tended to stop at the histological level of connective tissue adhesion if healthy tissues were present [9].

Quirynen et al. [10] found a correlation between the level of bone as seen on radiographs and the extent of peri-implant probe penetration. In the case of screw-type implants, the probe tip appeared to stop 1.4 mm coronally to the bone level. It was observed that the mean discrepancy between probe penetration and the location of the bone margin in radiographs was 1.17 mm in 100 non submerged titanium implants 1 year after implantation. [10] Microbiological studies have shown that there is a marked difference in the composition of the peri-implant microflora between implants with deep and shallow pockets.

Deeper pockets of 5 mm or more can be viewed as protected habitats for putative pathogens and indicate peri-implantitis. The penetration of the probe tip is influenced to some extent by implant shape and surface texture. In some implants, peri-implant probing is impossible due to peculiarities of the shape or design (concavities, shoulders or steps) of the implant. Lack of surface smoothness (such as plasma-coating, sandblasting or the presence of threads) may increase the resistance to probe penetration and may lead to the underestimation of pocket depth. Thus, probing around implant has not gained much acceptance among clinicians as a reliable diagnostic tool.

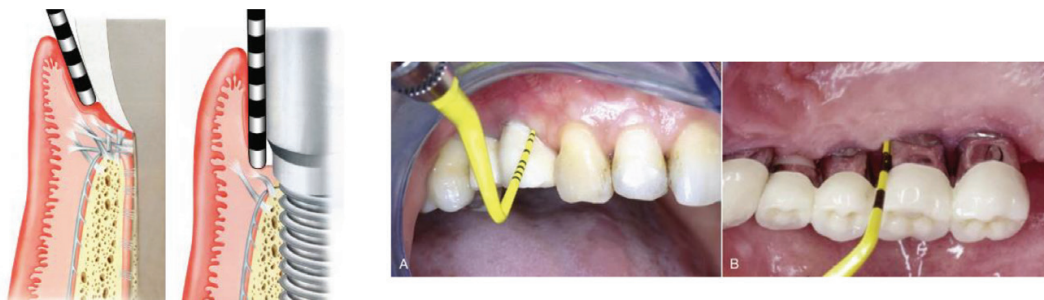
On the other hand, one may consider it a deficiency of an implant system if its design disables probing. In addition, some authors have expressed concern about the possibility of introducing bacteria into the peri-implant tissues and damaging the implant surface with a metallic periodontal probe while probing. The peri-implant probing should include a fixed reference point on the implant or its suprastructure to measure the relative attachment level.



If peri-implantitis is associated with a marginal recession, then probing depth alone may not accurately reflect peri-implant bone loss, whereas increasing loss of attachment is definitely indicative of peri-implant pathology.

The examination of peri-implant tissues is fundamental in the maintenance and follow-up of implant treated patients. The methods to be applied in the clinical examination of the tissues surrounding implants resemble those used in the examination of the periodontal tissues surrounding teeth. Thus, probing represents one of the critical assessments and includes not only the appraisal of probing pocket depth (PPD) but also the more important detection of bleeding on probing (BOP). Probing peri-implant and periodontal tissues is in most respects similar and is regarded as a predictable and reliable procedure in the effort to distinguish between healthy and diseased tissue, provided that a normal force is applied [9].

When probing healthy tissues around implants and teeth, the probe meets resistance from the peri-implant mucosa/gingiva and the apical extension of the probe into the pocket corresponds to the vertical dimension of the junctional epithelium. Probe penetration of inflamed tissues, however, is different such that the probe reaches a position apical to the epithelial extension, depending on the degree of inflammation (**Figure 2**).



**Figure 2.** Peri-implant probing.

### 3.2. Mucosal inflammation

Definition of inflammatory changes of peri-implant tissues should be based on established periodontal index systems such as the Sulcus Bleeding Index or the Gingival Index. Consequently, a modified Bleeding Index has been proposed by Mombelli et al. [11]. Also, a simplified Gingival Index was suggested by Apse et al. for the assessment of soft tissues around implants [12].

In the Gingival Index scores, two important discriminators used are the texture and color of the gingiva. However, in case of implants, these features depend on the normal appearance of the recipient tissues before implantation. They may also be influenced by the properties of the implant surface. Non-keratinized peri-implant mucosa appears redder than keratinized tissues. Therefore, a modification of the original Gingival Index was required for use on implants.

In a longitudinal study conducted by Chaytor [13], only a weak correlation between the Gingival Index scores and changes of marginal bone level was reported. In clinical practice, the reduction of the evaluation of signs and symptoms of inflammation to bleeding on gentle

probing on implants may be a reasonable extrapolation from the clinical situation around teeth. In contrast to gingivitis and periodontitis patients, this parameter has not yet been validated for implant situations.

Consequently, for peri-implant lesions, sensitivity, specificity, diagnostic accuracy and predictive values are not available. However, from a biological point of view it may be reasonable to assume that absence of bleeding on probing represents stability of the peri-implant mucosal seal in a similar way as absence of bleeding on gentle probing represents stability and health in periodontal tissue. Further research is required to fill these gaps in knowledge, of the role of this common clinical parameter as an indicator and/or predictor for health and disease (Tables 1 and 2).

3.3. Mobility

The establishment and, maintenance of intimate contact between the bone and the implant is a major requirement for implant success. An important criterion for the success of implant therapy is the absence of mobility. Clinically visible mobility of an implant after an appropriate period indicates failure to achieve osseointegration. Presence of mobility at the follow-up visit is a sign of the final stage of peri-implant pathology and indicates complete failure of osseointegration. Implants with less advanced stages of peri-implantitis may still appear immobile due to some remaining osseointegration. Thus, mobility cannot be used to detect early stages of peri-implant pathology. It is advisable to use an electronic device to interpret low degrees of mobility [9].

3.4. Definition and diagnosis of peri-implant disease

Peri-implant mucositis is described as the inflammation limited to soft tissues around a dental implant. It may result from dental plaque colonization and is a reversible inflammatory condition. It does not involve any bone loss, analogous to gingivitis around natural teeth. A diagnosis of peri-implantitis results when the inflammation spreads apically, causing progressive loss of osseointegrated supporting bone, analogous to periodontitis around natural teeth. The

Score 0	No detection of plaque
Score 1	Plaque only recognized by running a probe across the smooth marginal surface of the implant. Implants covered by plasma spray in this area always score 1
Score 2	Plaque can be seen by the naked eye
Score 3	Abundance of soft matter

Table 1. Assessment of plaque accumulation by a modified Plaque Index [11].

Score 0	No bleeding when a periodontal probe is passed along the gingival margin adjacent to the implant
Score 1	Isolated bleeding spots visible
Score 2	Blood forms a confluent red line on margin
Score 3	Heavy or profuse bleeding

Table 2. Assessment of bleeding tendency by a modified Sulcus Bleeding Index [11].

practitioners essentially require to be familiar with these diagnostic terms when assessing the long-term success of implants and peri-implant health.

It is also important to accurately identify the etiology and chronology of bone loss around implants for better diagnosis and treatment plan. Bone loss may result from surgical trauma or technique, such as pressure necrosis from inadequate osteotomy preparation or coronal bony voids from excessive counter sinking. It must be differentiated from bone loss resulting from bacterial plaque mediated by an immune-inflammatory reaction. Implants placed using a subcrestal platform position have been shown to have a deeper baseline probing depths than those placed supracrestally; thus, it is important to know the baseline probing depth after initial healing to allow monitoring for changes over time.

Various studies in literature have reported the incidence and prevalence of peri-implantitis. Berglundh et al. [14] found that the incidence of peri-implantitis was up to 14.4% and appeared to be related to the number of years for which the fixtures were in service. Additionally, Roos-Jansaker et al. [15] reported that of all implant cases which were not enrolled in a regular post treatment periodontal maintenance program, 16% demonstrated peri-implantitis by 7–9 years after implant placement. The incidence of peri-implantitis may be underestimated because only few studies exist with follow-up longer than 10 years.

Dental implants have been shown to be successful in patients with severe periodontitis. Similarity between the bacterial profile around implants and natural teeth has been demonstrated by several researchers. Moreover, dental implants may harbor a complex microbiota with a large proportion of known periodontal pathogens, which have been associated with the onset of peri-implant mucositis and peri-implantitis [16]. Additionally, long term follow-up studies that examined dental implants in patients with a history of periodontitis, have suggested a higher incidence of soft-tissue inflammation (mucositis) and peri-implantitis, as well as a slightly higher failure rate [17]. These findings suggest that the patients with dental implants require regular and careful evaluation at selected periodontal maintenance intervals to detect any clinical signs and symptoms of peri-implant disease at an early stage.

Probing depths should be recorded to detect the inflammation in the peri-implant mucosa. It helps to identify bleeding or suppuration during examination. While the probing pocket depth (PPD) may vary around implants, such assessments are secondary to bleeding on probing (BOP). Sites with PPD  $\geq 6$  mm, however, may indicate pathology and thus require meticulous examination. For peri-implantitis, bone loss can be assessed through radiographs in addition to the PPD and BOP. The radiograph for this purpose should be obtained after the delivery of the prosthesis [18].

## **4. Histopathology of peri-implant disease**

### **4.1. Mucositis**

The similarity between inflammatory lesions in peri-implant mucositis and gingivitis has been revealed by various animal experiments and analyses of human biopsy material. The development of inflammatory lesions in the connective tissue in the marginal portion of the gingiva or peri-implant mucosa as a response to microbial challenge follows the same pattern



and the composition of inflammatory cells in both the lesions. While gingivitis and mucositis are reversible conditions, periodontitis and peri-implantitis are not. The inflammatory lesion in the former conditions can be completely resolved after the institution of appropriate infection control measures [14, 19] (**Figure 3**).

4.2. Peri-implantitis

Peri-implantitis lesions differ from mucositis lesions in that they exhibit characteristics that are markedly different from their periodontal counterparts. The inflammatory lesion in periodontitis is contained within the sub-epithelial connective tissue compartment of the gingiva and is separated from the alveolar bone by a 1 mm-wide zone of dense connective tissue. Furthermore, the area of soft tissue affected with pocket formation is lined by a pocket epithelium. The epithelium in its most apical portion is in contact with the root surface and thereby effectively sheds off the biofilm of bacteria in the pocket.

In peri-implantitis, bacteria survive in the inflammatory lesion within the pocket compartment. But the entire extension of the pocket usually remains uncovered by a pocket epithelium. Thus, the apical third of the inflamed tissue in the pocket comes to lie in direct contact with the biofilm. Another dissimilarity to periodontitis is the extension of the lesion in peri-implantitis. The lesion in peri-implantitis is seen to extend to a position closer to the bone surface, while the lesion in periodontitis is usually separated from the crestal bone by a zone of connective tissue. An understanding of the difference in the lesions observed in periodontitis and peri-implantitis will help clinician to select the appropriate treatment strategy (**Figure 4**).

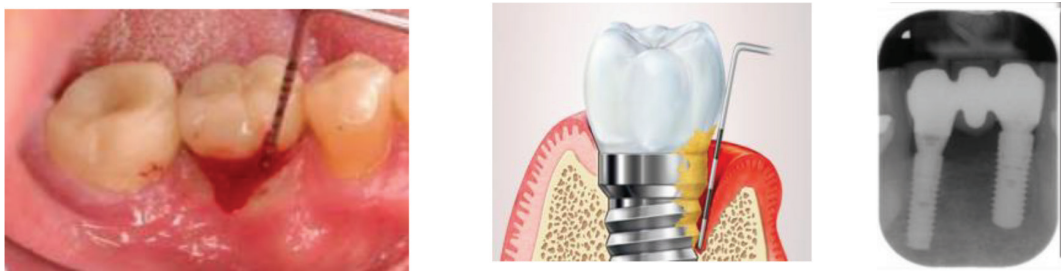

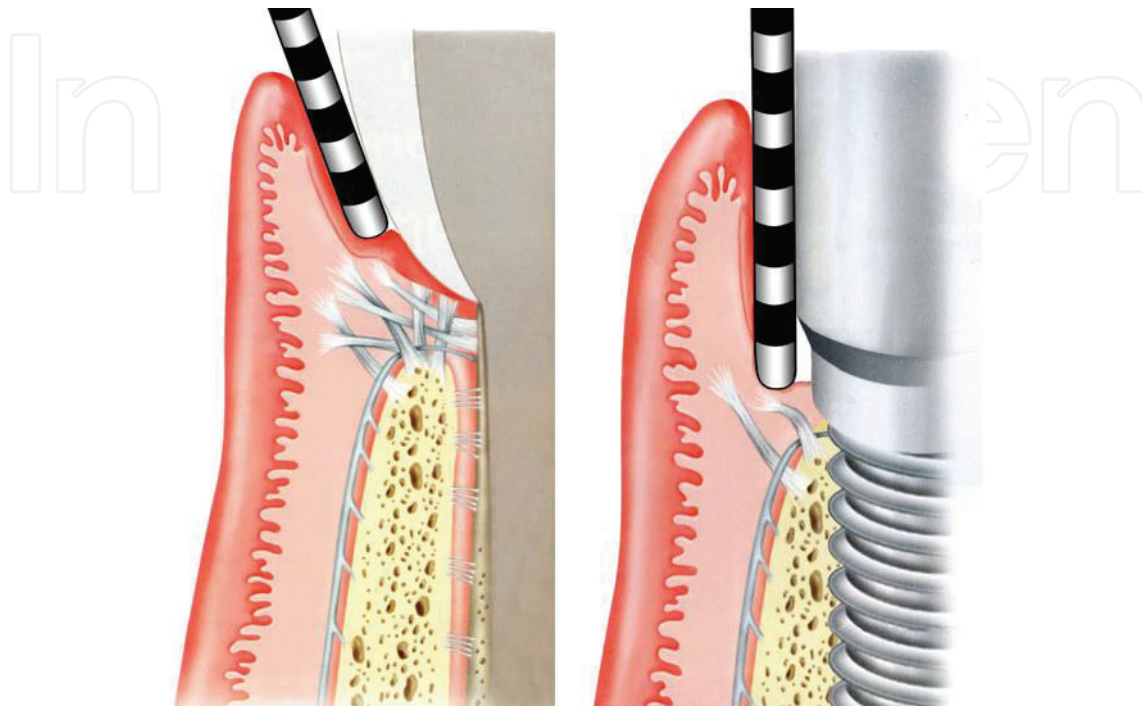
Figure 3. Peri-implant mucositis.

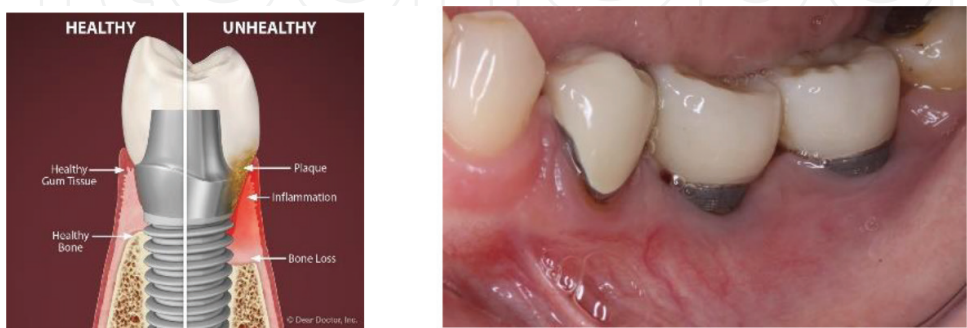

Figure 4. Peri-implantitis.

## 5. Guidelines for follow-up of implant treated patients

### 5.1. Supportive therapy: infection control



Following the completion of the surgical and prosthetic procedures in implant therapy, it is imperative to inform the patient about the self-performed infection control procedures [20]. Different types of toothbrushes and/or floss are available to suit the varying designs of the prosthetic reconstruction. The patient should be taught to use the mechanical cleaning aids properly and efficiently to clean the implant and adjacent parts of the prosthesis. The cleansing should be performed twice a day. The prosthesis should be designed in a such way as to allow access for self-performed and professional infection control [20].

### 5.2. Radiographic examination

The implant sites should be evaluated with radiographs carried out at two time points - at the time of the delivery of the prosthesis and at the one-year follow up. Any alteration in the marginal bone level should be recorded during the first year in function of an implant. This change may be associated with the remodeling of bone after implant installation. This information will serve as a baseline value for evaluation of bone level at subsequent visits.

The following radiographic parameters are in currently in use for evaluation of dental implants:

- i. Assessment of alterations in height of peri-implant bone

- ii. Computer-assisted evaluation of changes in peri-implant bone height
- iii. Assessment of quality of peri-implant bone
- iv. Photodensitometric evaluation of peri-implant bone quality
- v. Bone mineral content (dual-photon absorptiometry)

### 5.3. Clinical examination

Clinical examinations should be performed at all annual follow-up visits. Besides examining the function of the prosthesis, BOP, PPD and plaque assessment should also be carried out. If the probing indicates peri-implant disease (BOP positive and PPD  $\geq 6$  mm), a radiographic examination is called for to reveal possible bone loss. In the absence of clinical findings of pathology in peri-implant tissues, radiographic examination should be avoided.

The re-evaluation of implant-treated patients should be designed in accordance with evaluation of risk factors for peri-implant disease. Subjects with a history of severe should be recalled in every 2–6 months after the delivery of the prosthesis. Routine maintenance therapy is imperative for maintenance of the peri-implant health. Implant maintenance therapy includes considering the patient's overall health in addition to the assessment and monitoring of implant(s).

Implants fail from a loss of integration generally due to bacterial infection, occlusal overload, or a poorly designed prosthesis. The role of a dental hygienist and dentist is thus essential in preventing and controlling bacterial infection, including careful instrumentation and polishing of implant(s) once in every 3–4 months.

#### 5.3.1. Step 1: assessment of the patient's medical history

At each appointment, medical history and overall health of the patient should be updated and reviewed. Any changes in the health status of the patient can influence negatively the success of implants or treatment provided. If the diabetic status of the patient is not under good control, this can increase the risk of peri-implantitis and ultimately implant failure. Overall good general health is one of the keys to the success of the implant(s).

Implant dentistry is true interdisciplinary dentistry, requiring close collaboration with the surgical practice, the dental laboratory, and the patient's physician [20].

#### 5.3.2. Step 2: assessment of implants

Implant assessment starts with a visual soft tissue examination of the peri-mucosal seal and should be carried out at every maintenance appointment. Any signs of inflammation or bleeding or suppuration should be recorded. It is important to record any clinical symptoms present, such as pain and mobility of the implant. Obtaining accurate radiographs will enable the clinician to evaluate the crestal bone level appropriately [20].

#### *5.3.2.1. Visual assessment of soft tissue*

The soft tissue should be examined for color, texture, form, bleeding, and inflammation. The assessment and any tissue changes should be recorded and photographs should be taken. This photograph or digital image can be used to educate the patient and can be an excellent visual tool to reinforce the importance of good home care.

#### *5.3.2.2. Protocol for assessment of inflammation*

Soft tissue assessment includes redness, inflammation, or bleeding, check for the presence of calculus deposits around the implant. Peri-implant infections can progress more rapidly than infection around natural teeth. In presence of an infection, the dental hygienist or dentist will evaluate for pain, mobility. All the data that is gathered is made available to the dentist to develop a treatment plan. The plan may include shortening the interval between implant maintenance visits, possible antibiotics, a radiograph, and/or the dentist may refer the patient for an evaluation by a specialist.

#### *5.3.2.3. Examination upon probing*

Some researchers recommend not to probe around the implant, or wait for 3 months, following abutment attachment, to avoid disrupting the formed peri-mucosal seal. The peri-mucosal seal is fragile and probe penetration induces pathogens and jeopardize the success of the implant, a number of considerations and guidelines should be followed when probing the tissue surrounding an implant. A flexible plastic probe is recommended to avoid any scratching of the implant's surface and reduces the potential for trauma to the peri-mucosal seal. Secondly, the probe should be used as a measuring device for recording inflammation or to measure exposed implant threads for monitoring.

A baseline measurement should be established by identifying a monitor marker on the restoration and should be gently probed to check the clinical parameters. This information should be recorded in the patient's notes along with any signs of inflammation present at the first implant maintenance appointment (3 months following prosthesis placement).

#### *5.3.2.4. Signs of failing implant*

Presence of infection, pain, mobility, or unacceptable bone loss are the signs of failing implants. Pain or discomfort may be the important signs, before it is evident on a radiograph. In presence of pain, the dentist needs to evaluate the cause i.e. whether it is due to occlusal trauma or infection. An occlusal adjustment may be required to be performed since an implant is held in place by bone not by the periodontal ligament and does not respond like a natural tooth to occlusal trauma.

Mobility following osseointegration can occur because of a loose fixed restoration, infection, fractured abutment thread, an implant fracture or trauma. In case the mobility is due to a loose crown, it may be possible to re-cement it or rescrew it (depending on the type of abutment). If mobility of the implant itself or a broken screw, this is a greater cause for concern. A radiographic assessment is needed.



#### 5.3.2.5. *Monitoring the implant*

This final step in monitoring the dental implant(s) is the radiographic assessment using a measurable device is recommend to accurately monitor the crestal bone level around the implant(s) and to verify that the restoration is seated properly. The abutment can be visually confirmed through indentations in implant shown in the radiographs, or the screw that is clearly in focus, which should appear as a clear line. This is indicative of a properly seated abutment.

Further radiographs can be taken to determine any crestal bone loss around the implant and to measure the same if present. A measurement of 0.5–1 mm. horizontal bone loss is acceptable in the first year, with an anticipated 0.1 mm of bone loss each subsequent year. If more than 1 mm of horizontal or vertical bone loss is detected in the first year, an evaluation by the implant surgeon is recommended.

#### 5.3.3. *Step 3: instrumentation and polishing of dental implants*

Following careful assessment of implant, the dental hygienist or dentist should ascertain the presence of calculus on the implant or abutments. Minimal, or indeed no, instrumentation is required for an implant with a healthy gingival attachment. Calculus or microbial deposits are primarily supragingival and are safe for instrumentation. Care must be taken to avoid scratching or roughening the implant surface, as this may result in bacterial accumulation and subsequent inflammation [20].

##### 5.3.3.1. *Protocol for safe instrumentation*

There is a difference in instrumentation around an implant and natural tooth. Natural teeth are anchored in the bone by the periodontal ligament and sulcular epithelium, whereas the implants are osseointegrated to bone. For instrumentation of a natural tooth, the instrument blade is adapted to the tooth surface and gently inserted between the sulcular epithelium and the side of the tooth or root. To remove calculus deposits, vertical, horizontal, and oblique strokes are used.

##### 5.3.3.2. *Dental implant instrumentation*

A thorough instrumentation of implants requires the removal of microbial deposits without creating any alteration of the surface of implant or adversely affecting its biocompatibility. Scratches and gouges may be created on the surface that will affect the titanium-oxide layer, reducing the corrosion-resistant nature of a titanium implant. The implant surface may also get contaminated with trace elements from the remaining scaler material, which compromises the long-term osseointegration of the implant.

The suggested materials for use on implant surface are plastic, graphite and titanium scalers. Some studies had revealed that these instruments do not scratch or gouge implant surface. Titanium is the metal of choice because it produces instruments which are thinner than plastic or graphite instruments and provides more strength to dislodge calculus. They are also more biocompatible with other metals. This avoids leaving trace elements from a scaler on the implant surface.



According to Dmytryk, Fox and Moriarty [21], *“Although the use of a plastic curette did not significantly roughen the implant surface there was concern that some of the plastic material may have been smeared or deposited on the implant surface, perhaps altering the biocompatibility of the titanium surface.”*

The results of these research studies throw light on the fact that more studies are needed to evaluate the effects of debris left behind on the implant surface, and the biocompatibility of this debris with the titanium implant surface. Stainless steel instruments and metallic power scaler tips have been shown to gouge or scratch the implant surface and are therefore contraindicated. However power scalers and air powder abrasive systems can be used with specific tips, sleeves and powder formulated for implants. Care should be taken when using a plastic sleeve with the tip of a power scaler to prevent aspiration of the plastic tip, in case it gets dislodged [19].

#### *5.3.3.3. Plastic, graphite and titanium coated implant scalers*

Implant Prophy™ from TESS are designed from materials like polycarbonate plastic and include Gracey and Columbia designs. ImplanCare™, Hu-Friedy instruments are featured with a sturdy handle and plastic disposable tips in various designs. Premier Dental Facial implant scalers are made of non-metallic, autoclavable graphite. Titanium-coated Suvan-O’Hehir implant scoop curettes are available from G. Hartzell and Son [20].

#### *5.3.3.4. Titanium implant scalers*

An instrument called Implant Pro™ from Brasseler is available in the Langer series with titanium tips that can be replaced from time to time. Nordent makes ImplaMate™, also in the Langer series, Barnhart and universal scalers. The newest in the market are the Wingrove Series, made by Paradise Dental Technologies (PDT), which are designed with a uniquely processed titanium that will refrain from any scratches or leaving any debris behind on implants. These are available in a series of three professionally designed scalers which can be adapted to specifically meet all the challenges of maintaining an implant.

Few of the challenges include removing calculus from a variety of implants and restorative choices. Some are narrow base implants (narrow platform is used for lower incisors, congenitally missing laterals, and area with limited available bone) while others have a wide base or wide platform. There is difficulty to gain access to high water bridges as well as full-arch cement or screw retained implants. Also an instrument with small diameter is required to fit under a Hader clip bar or around O-ring ball or locator abutment that can be used for debridement of over dentures.

It is very critical to select an appropriate instrument to remove calculus deposits that will not harm the implant surface during debridement. For narrow base posterior implants or implants that replace two adjacent teeth, an instrument with a longer blade will be advantageous. It can be used under the more bulbous shaped crowns and even under the framework of a high water bridge or full arch implant retained prosthesis. The scaling stroke should be short and horizontal. The calculus present on these implants, crowns or frameworks can be dislodged effectively.

For wide base posterior implants, a universal posterior implant scaler is recommended with short vertical strokes to remove the calculus. For instrumenting any exposed implant threads; anterior or posterior, a shorter radius blade tip of an instrument is suggested which can be used carefully in a side-to-side motion, covering one thread at a time.

For patients with over denture implant abutment, the denture has to be removed to assess the O-rings or clips inside the denture for loss or wear. These O-rings or plastic retention clips should be replaced if worn out, or replaced at least once a year.

For instrumenting the abutments under an over denture, a thinner radius blade tip is adapted under a Hader clip bar in a side to side stroke. An instrument tip with a shorter radius is recommended, used with short vertical strokes around a ball or locator abutment to dislodge any calculus. It is important to understand the unique and different designs of implant and to have a proper armamentarium for the safe implant maintenance. This will allow the clinician to provide patients with ideal implant care with a predictable long-term success of their implants [20].

#### *5.3.3.5. Polishing of restorations on dental implant*

Soft rubber tip, with appropriate nonabrasive paste to polish the implants. Aluminum oxide, tin oxide, APF-free prophyl paste, and low-abrasive dentifrice are all considered acceptable polishing abrasives for implants. Coarse abrasive polishing pastes and acidulated phosphate fluoride (APF) products are contraindicated, as they may etch surface of implants.

## **6. CIST protocol for management of recurrent disease during maintenance of dental implants**

Conventional periodontal therapy should be done when inflammation develops around an implant. The therapy should include the efforts to improve patient's oral hygiene, with methods similar to those used for natural teeth. Lang et al. [22] suggested a novel, systematic stepwise approach for the prevention and treatment of peri-implant diseases. This approach is referred to as the cumulative interceptive supportive therapy (CIST) protocol.

It is based on periodic monitoring with implementation of treatment as thresholds for a particular condition are met. The first step is protocol (A), then (B) and, if conditions continue to worsen, the patient may require more advanced treatment, i.e. execution of protocol (C), and finally (D) by a specialist who has implant training for it. To control inflammation in peri-implant mucositis, that is, implants with minimal increase in pocket depth, slight (+) bleeding on probing, marginal erythema, plaque, and/or calculus, Protocol (A) is implemented.

The endpoint of the therapy is resolution of inflammation with careful mechanical debridement (using plastic curettes and rubber cup prophylaxis), swabbing with 0.12% chlorhexidine twice daily, and a review of home care and patient motivation. Protocol (B) is carried out for conditions that exhibit features similar to mucositis but with deeper pocket depths (4–5 mm) but without loss of supporting bone.

The treatment should include the therapies of protocol (A), plus locally delivered antibiotic (minocycline microspheres, doxycycline gel) at the infected implant site(s). Studies in the recent past have shown the use of minocycline microspheres may be beneficial in treatment of peri-implant mucositis and peri-implantitis. For management of early peri-implantitis,

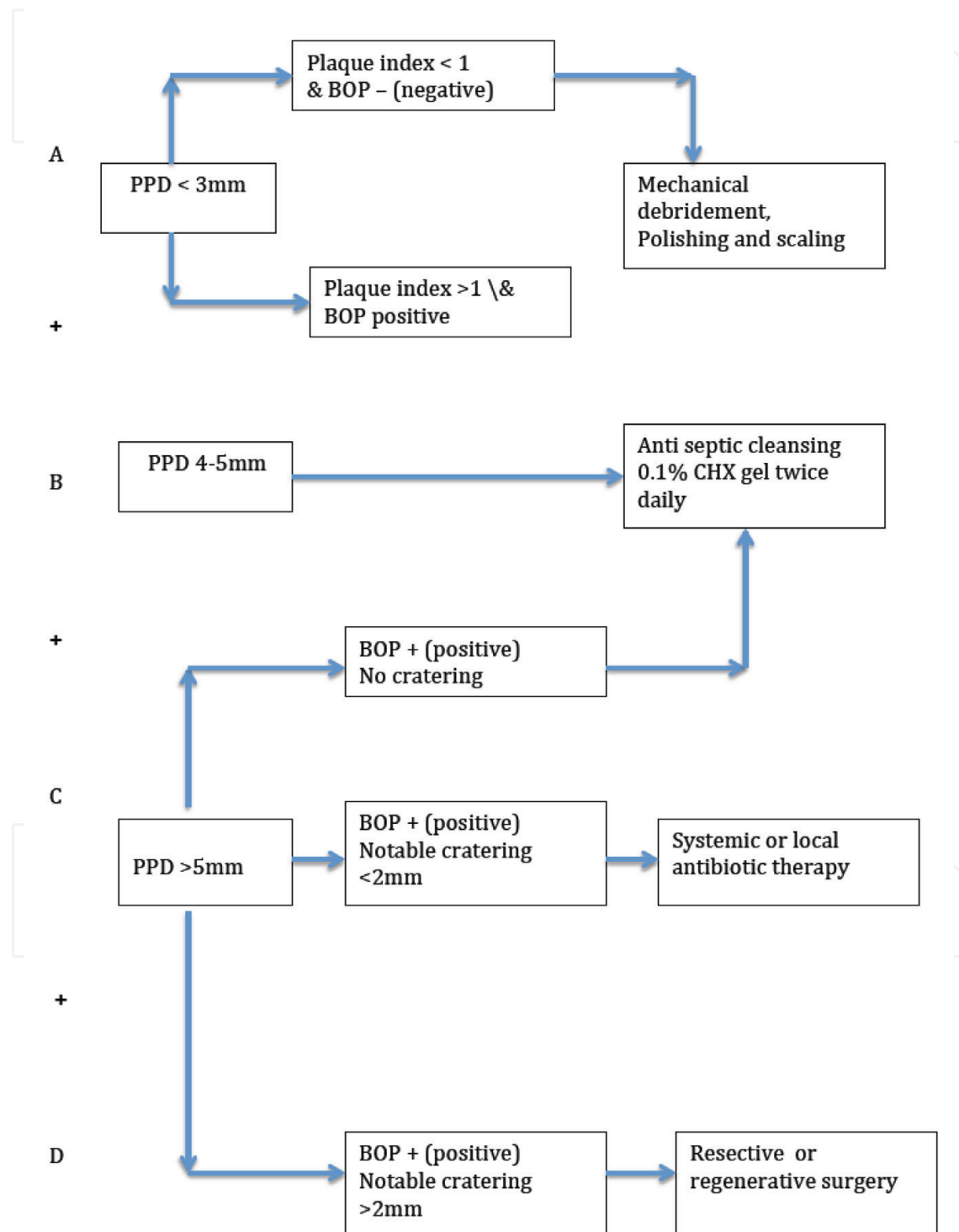


Figure 5. CIST protocol.

Protocol (C) is used, which consists of a more intensive approach and is used in conditions where there is radiographic evidence of osseointegrated bone loss of <2 mm and probing pocket depths >5 mm. The strategy should comprise a combination of the modalities for protocols (A) and (B) with the addition of systemic antibiotic therapy (metronidazole 250 mg *t.i.d.* for 7 days or amoxicillin 500 mg *t.i.d.* for 10 days).

Furthermore, periodontal surgical access for surface de- contamination (citric acid 1–2 min or tetracycline 250 mg, 5 mL for 5 min) should be considered. In cases of frank peri-implantitis that reveal probing depths (>5 mm), (+) bleeding on probing, plaque/calculus, and peri-implant bone loss of >2 mm, Protocol (D) is initiated along with other three protocols.

This treatment modality comprises periodontal surgical intervention for chemical disinfection, osseous resection, and/or guided bone regeneration (GBR). GBR is a procedure to attempt for salvaging the implant through bone regeneration techniques with the use of resorbable or nonresorbable semipermeable membranes and a bone substitute or replacement graft (such as freeze-dried bone allograft or anorganic bovine bone). In clinical practice, the protocol of CIST is targeted for early detection and methodical sequential treatment, which may help rescue and even reverse the fate of the ailing or failing endosseous dental implant [23] (**Figure 5**).

#### **The four steps are:**

1. Antiseptic therapy, CIST protocol A & B
2. Antibiotic therapy, CIST protocol A + B
3. Antibiotic therapy, CIST protocol A + B + C
4. Regenerative or resective therapy, CIST protocol A + B + C + D.

#### **Author details**

Krishna Kripal<sup>1</sup> and Kavita Chandrasekaran<sup>2\*</sup>

\*Address all correspondence to: dr.ckavita@gmail.com

1 Rajarajeswari Dental College and Hospital, Bangalore, India

2 Department of Periodontology, Rajarajeswari Dental College and Hospital, Bangalore, India

#### **References**

- [1] Albrektsson T, Dahl E, Enbom L, Engvall S, Engquist B, Eriksson AR, Feldmann G, Freiberg N, Glantz PO, Kjellman O CL, Kvint S, Kondell PA, Palmquist J, Werndahl L, htrand P. Osseointegrated oral implants— A Swedish multicenter study of 8139 consecutively inserted Nobelpharma implants. *Journal of Periodontology*. 1988;**59**:287-296

- [2] Branemark P-I, Breine U, Adell R, Hansson BO, Lindstrom J, Olsson A. Osseointegrated implants in the treatment of the edentulous jaw. Experience from a 10-year period. *Scandinavian Journal of Plastic and Reconstructive Surgery and Hand Surgery*. 1977;**2**(16): 1-132
- [3] Buser D, Hf W, Bragger U, Balsiger C. Tissue integration of one-stage IT1 implants: 3-Year results of a longitudinal study with hollow-cylinder and hollow-screw implants. *Journal of Oral & Maxillofacial Implants*. 1991;**6**:405-412
- [4] Rosenberg E, Torosian J. Slots 1. Microbial differences in 2 clinically distinct types of failures of osseointegrated implants. *Clinical Oral Implants Research*. 1991;**2**:135-144
- [5] Glossary of Prosthodontic Terms
- [6] Brånemark PI, Adell R, Breine U, Hansson BO, Lindström J, Ohlsson A. Intra-osseous anchorage of dental prostheses. I. Experimental studies. *Scandinavian Journal of Plastic and Reconstructive Surgery*. 1969;**3**(2):81-100
- [7] Albrektsson T, Brånemark PI, Hansson HA, Lindström J. Osseointegrated titanium implants. Requirements for ensuring a long-lasting, direct bone-to implant anchorage in man. *Acta Orthopaedica Scandinavica*. 1981;**52**(2):155-170
- [8] Zarb GA, Albrektsson T. Osseointegration—A requirement for the periodontal ligament? Editorial. *International Journal of Periodontics and Restorative Dentistry*. 1991;**11**:88-91
- [9] Berglundh T, Lindhe J. Dimension of the periimplant mucosa. Biological width revisited. *Journal of Clinical Periodontology*. 1996;**23**(10):971-973
- [10] Quirynen M, Van Steenb Berghe D, Jacobs R, Schotte A, Darius P. The reliability of pocket probing-around screw-type implants. *Clinical Oral Implants Research*. 1991;**2**:186-192
- [11] Mombelli A, Mac VO, Schurch E, Lang NP. The microbiota associated with successful or failing osseointegrated titanium implants. *Oral Microbiology and Immunology*. 1987;**2**:145-151
- [12] Apse F, Zarb GA, Schmitt A, Lewis DW. The longitudinal effectiveness of osseointegrated dental implants. The Toronto study: Peri-implant mucosal response. *The International Journal of Periodontics & Restorative Dentistry*. 1991;**11**:95-111
- [13] Chaytor DV. The longitudinal effectiveness of osseointegrated dental implants. The Toronto study: Bone level changes. *The International Journal of Periodontics & Restorative Dentistry*. 1991;**11**:113-125
- [14] Berglundh T, Lindhe J, Marinello C, et al. Soft tissue reaction to de novo plaque formation on implants and teeth. An experimental study in the dog. *Clinical Oral Implants Research*. 1992;**3**:1-8
- [15] Roos-Jansaker AM. Long-time follow up of implant therapy and treatment of Peri-Implantitis. *Swedish Dental Journal. Supplement*. 2007;**188**:7-66
- [16] Pontoriero R, Tonelli MP, Carnevale G, et al. Experimentally induced peri-implant mucositis. A clinical study in humans. *Clinical Oral Implants Research*. 1994;**5**(4):254-259



- [17] Roos-Jansåker AM, Renvert H, Lindahl C, et al. Nine- to fourteen-year follow-up of implant treatment. Part iii: Factors associated with peri-implant lesions. *Journal of Clinical Periodontology*. 2006;**33**(4):296-301
- [18] Lindhe J, Meyle J. Peri-implant diseases: Consensus report of the sixth European workshop on periodontology. *Journal of Clinical Periodontology*. 2008;**35**(Suppl. 8):282-285
- [19] Ericsson I, Berglundh T, Marinello C, Liljenberg B, Lindhe J. Long-standing plaque and gingivitis at implants and teeth in the dog. *Clinical Oral Implants Research*. 1992;**3**(3):99-103
- [20] Ochsenbein C. Retreatment. *Periodontology*. 1996;**2000**(12):129-132
- [21] Dmytryk JJ, Fox SC, Moriarty JD. The effects of scaling titanium implant surfaces with metal and plastic instruments on cell attachment. *Journal of the Pancreas: JOP*. 1990;**61**:491-496
- [22] Lang B, Worthington P, Lavelle W. *Osseointegration in Dentistry: An Introduction*. Chicago, IL: Quintessence; 1994. p. 121
- [23] Schumaker ND, Metcall BJ, Toscano NT, Holtzclaw DJ. Periodontal and periimplant maintenance: A critical factor in longterm treatment success. *Compendium*. 2009;**30**:2-13