

# We are IntechOpen, the world's leading publisher of Open Access books Built by scientists, for scientists

6,900

Open access books available

185,000

International authors and editors

200M

Downloads

Our authors are among the

154

Countries delivered to

TOP 1%

most cited scientists

12.2%

Contributors from top 500 universities



WEB OF SCIENCE™

Selection of our books indexed in the Book Citation Index  
in Web of Science™ Core Collection (BKCI)

Interested in publishing with us?  
Contact [book.department@intechopen.com](mailto:book.department@intechopen.com)

Numbers displayed above are based on latest data collected.  
For more information visit [www.intechopen.com](http://www.intechopen.com)



# Clinical Manifestations and Diagnosis of Malignant Tumors in Children

*Maxim Yu. Rykov*

## Abstract

Pediatric oncology is a complex specialty, requiring the involvement of various specialists—pediatric oncologists, pathomorphologists, radiation diagnosticians, and surgeons. The patient's life depends, first of all, on the timeliness of the diagnosis, since the earlier the specialized treatment is started, the higher the probability of achieving remission. Of particular relevance is the problem of early detection of malignant neoplasms. The complexity of solving this problem is related to the atypical nature of the oncological diseases and their rarity, which leads to the lack of “oncological alertness” of primary care physicians—district pediatricians. It is from pediatricians that timely diagnosis of malignant neoplasms depends. This lecture is devoted to the clinical manifestations and diagnosis of malignant neoplasms in children: hemoblastosis and solid tumors.

**Keywords:** pediatric oncology, malignant tumors, solid tumors, hemoblastoses, diagnostics, clinical symptoms

## 1. Introduction

The problems of treating children with oncological diseases are relevant all over the world. Successes associated with the introduction of intensive protocols of chemotherapy, bone marrow transplantation, organ-preserving treatment can achieve remission in a significant number of patients.

It is known that the earlier a specialized treatment is started, the higher the probability of a favorable outcome. Thus, treatment started in the early stages of the disease with nephroblastoma allows to achieve remission in 95% of patients, in osteosarcoma—in 70%, in Ewing sarcoma—in 65%, in rhabdomyosarcoma—in 59%. If the disease is found in common stages, this indicator is significantly lower. For example, for the abovementioned nosologies, it is 25, 6, 7, and 8%, respectively [1].

In this connection, the problem of early detection of malignant neoplasms is of particular urgency. The complexity of solving this problem is related to the atypical nature of the oncological diseases and their rarity, which, in turn, leads to the lack of “oncological alertness” of pediatricians.

A pediatrician, like a doctor of any other specialty, rarely has to deal with children affected by malignant tumors. For his medical practice, the average pediatrician meets about eight children with true tumors. It is with this that possible

errors in diagnosis and, as a consequence, in treatment are connected. The patient’s life depends, first of all, on the timely diagnosis, therefore, directly from the “oncological alertness” of the pediatrician.

2. Epidemiology of malignant tumors

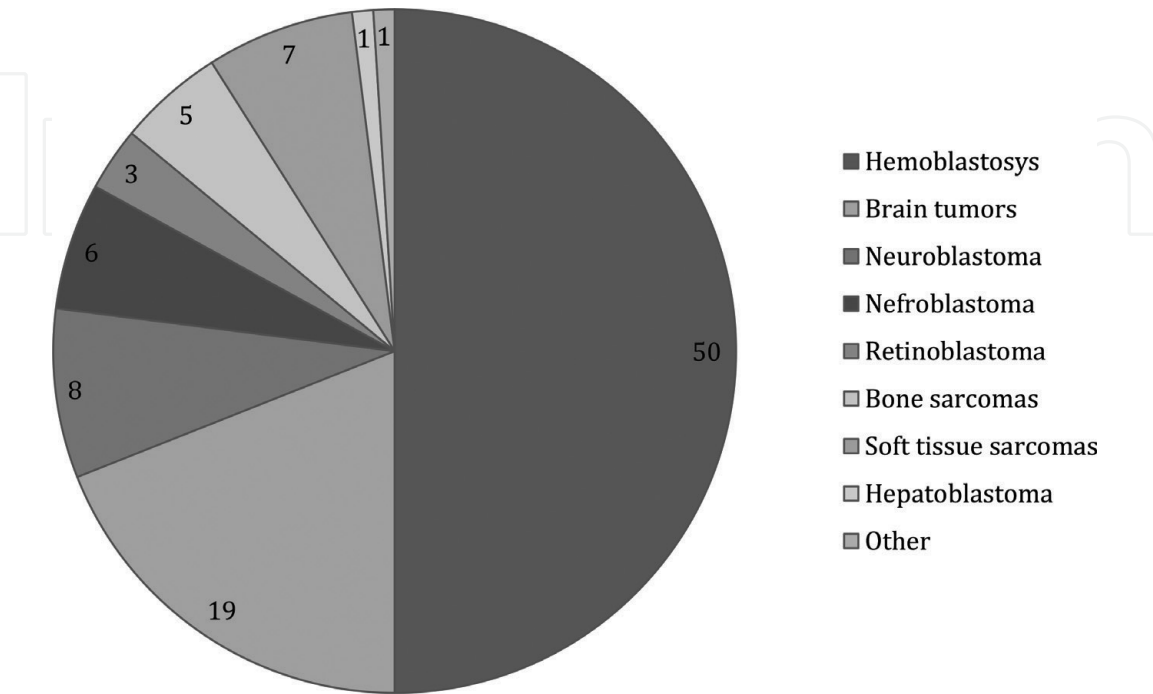
In the structure of malignant tumors in children on the first place are hemoblastoses, then tumors of the brain and spinal cord, neuroblastoma, tumors of bones and soft tissues, kidneys, eyes, liver. It follows that most solid tumors are specific for children, whereas adults are found in very rare cases (**Diagram 1**).

Difficulties in diagnosing malignant neoplasms in children are explained not only by the rarity of these pathologies but also by the peculiarities of their clinical course: the prevalence of tumors of “hidden localizations,” the set of “masks,” which mask the manifestations of malignant tumors, the predominance of common symptoms in the clinical picture over local symptoms. The age of patients determines understandable difficulties in clarifying complaints and anamnesis of the disease.

3. Primary tumor symptom complex

Common signs of malignant tumors appear in some cases earlier than local ones, they are united by the terms “primary tumor symptom complex” or “paraneoplastic syndrome” and although they are not specific, should alert the doctor and encourage him to make an in-depth examination of the patient to exclude or confirm malignant neoplasms [2].

Primary tumor symptom complex is a variety of pathological manifestations, caused by the indirect effect of the tumor process on the metabolism, immunity and functional activity of the body’s regulatory systems.



**Diagram 1.**  
*Structure of malignant tumors in children (%).*

Primary tumor symptom complex most often includes hypodynamia, lack of appetite, weight loss, lethargy, weakness, fatigue, capriciousness, anemia, subfebrile condition, and dermatitis.

These manifestations are caused by nonspecific reactions on the part of organs and systems or by ectopic production of a biologically active substance (hormones, proteins, growth factors, cytokines, antibodies), which causes a pathological increase in cell activity and forms certain manifestations, for example, Cushing's syndrome, fever, and erythrocytosis.

In the pathogenesis of the development of the primary tumor symptom complex, the response of the immune system is important in response to the presence of a tumor, an immunologically foreign antigen. This is the basis for the development of clinical symptoms of dermatomyositis, rheumatoid arthritis, autoimmune hemolytic anemia, and other systemic manifestations.

In some cases, the primary tumor symptom complex precedes the local symptoms of the tumor, whereas in others, it manifests simultaneously with them, sometimes will be added after the verification of the tumor process. The greatest difficulties arise in cases when the manifestations of the primary tumor symptom complex are treated as independent diseases or syndromes, which lead to the appointment of unjustified treatment and detection of malignant neoplasms at later stages.

Primary tumor symptom complex in the verification of malignant neoplasms is observed in 15% of patients, 50% of its manifestations develop during treatment, 35% in the late stages of the disease. Regression of the manifestations of the primary tumor symptom complex correlates with the tumor response to the therapy [2].

*Leukemia* is the most common tumor disease of childhood, which occurs mainly in the first 5–7 years of life. Among all leukemias in children, unlike adults, the vast majority (more than 95%) falls on acute forms.

Acute leukemias (AL) are clonal diseases that arise from a single mutated hematopoietic cell, which refers either to very early ones or to the cells of predecessors committed to different hematopoiesis lines. Thus, AL is a malignant tumor that originates from blast cells. The diagnosis of AL is established in the event that the number of blast cells in the bone marrow exceeds 25% [3].

AL in children of morphological origin is divided into acute lymphoblastic (80%) and acute nonlymphoblastic (20%) leukemia, which differ from each other both biologically and clinically, but in all cases, the clinical course is characterized by a high rate of increase in symptoms leading to rapid death of the patient [3, 4].

Clinical manifestations. In the clinical picture of AL, it is usually noted the presence of various symptomatic complexes, the most frequent among which are:

1. Intoxicative-inflammatory syndrome, which is manifested by lethargy, lethargy, loss of appetite, loss of body weight, unaccountable fever. This is a consequence, first of all, of reducing immunity due to a decrease in the number of leukocytes of the granulocyte germ (in the first place—neutrophils). These children have frequent recurrent inflammatory diseases over short time intervals;
2. Anemia syndrome, the main manifestations of which are a decrease in the level of hemoglobin, erythrocytes, pallor of the skin and mucous membranes, dyspnea, tachycardia due to hemic hypoxia;
3. Hemorrhagic syndrome, in which there are polymorphic hemorrhages in the skin of the body and mucous membranes, bleeding (nasal, gastrointestinal,

renal, etc.). This is due to the replacement of the megakaryocyte germ with blast cells and, as a consequence, a decrease in the number of platelets in the blood to critical digits;

4. Hyperplastic syndrome, which is caused by leukemia infiltration and is represented by systemic lymphadenopathy (enlarged lymph nodes of almost all groups, painless, of small size), hepatosplenomegaly, and ossalgia. The latter are the result of massive infiltration of bone marrow by the blast cells of long tubular bones, which leads to increased intraosseous pressure and the occurrence of pain. In addition, the massive proliferation of blast cells leads to their exit beyond the bone marrow canal under the periosteum, which is also the reason for the appearance of a clinical picture similar to that of acute hematogenous osteomyelitis (AHO). In this case, it is extremely difficult to conduct differential diagnosis of these two diseases (AL and AHO) in the early stages of development, only the results of sowing and cytology of the bone marrow make it possible to correctly diagnose;
5. Meningeal and hypertensive syndromes that are characterized by headache, vomiting, stiff neck muscles, Kernig symptom, Brudzinsky's symptom, convulsions of clonic-tonic character, and the like. This is a consequence of the development of neuroleukemia, when the tumor metastasizes into the membranes of the brain and spinal cord. Often, such manifestations simulate a clinical picture of meningitis or encephalitis. However, such children do not have an epidemiological component in the anamnesis. Often, the diagnosis is established by the results of a sociological study of cerebrospinal fluid.

In addition to these symptom complexes, others may be present, but it is important to understand that the presence of two or more of them is an obvious indication for the urgent and active exclusion of the diagnosis of acute leukemia and, first of all, for referring the patient to a general blood test.

#### *Diagnosis of AL:*

1. The general analysis of blood, in the study of which, as a rule, hemoglobin, erythrocytes, platelets, change in the number of leukocytes are observed, blasts may also appear;
2. Puncture of the bone marrow (usually from the pelvic bones, no less than three points on each side) followed by its Romanovsky-Giemsa coloring and cytological examination. In this case, the number of blast cells is more than 25%, a violation of normal cell ratios, a decrease or absence of megakaryocytes;
3. Cytochemical examination of the bone marrow (reaction to peroxidase and chloroacetate esterase, lipid content, granular distribution of material in the SHC reaction in the form of purple granules on the periphery of the cytoplasm, acidic phosphatase activity);
4. Immunophenotyping (detection of differentiation antigens on the membrane of blast cells);
5. Cytogenetic study of the bone marrow with the search for typical chromosomal abnormalities for various variants of AL;



6. Molecular-biological studies (PCR diagnostics) of the bone marrow with the search for more subtle variants of breakdowns of the information apparatus (DNA) of cells;
7. Lumbar puncture (diagnosis of neuroleukemia).

*Malignant lymphomas (ML)* are a group of malignant neoplasms of blood that are characterized by a primary tumor lesion of the lymphatic system. These include Hodgkin's disease (or lymphoma) (previously—lymphogranulomatosis) and non-Hodgkin's lymphomas.

Hodgkin's lymphoma (LH) most often occurs during adolescence. Moreover, if in children under 15 years of age, its share in the overall structure of oncological morbidity does not exceed 7–8%, at the age of 15–18 years—more than 20%.

Non-Hodgkin's lymphomas (NHL) are a polymorphic group of tumors, the most common of which are B- and T-cell lymphomas. NHL, as a rule, are diagnosed in children aged 5–7 years.

It should be emphasized that ML is almost never found in infants [4].

Clinical manifestations. For these diseases, the presence of a lymphoproliferative symptom complex is common. In contrast to AL, in these diseases, as a rule, not all groups of lymph nodes increase, but several located in the immediate vicinity. Common to them is the possible presence of a symptom of general intoxication, which occurs as a result of the effects of cytokines secreted by Hodgkin cells:

1. Fever;
2. Night profuse sweat;
3. Weight loss of more than 10% in the previous 6 months.

With LH in children, as a rule, there is an increase in cervical and cervico-supraclavicular (60–80%), intrathoracic (paratracheal, tracheobronchial, bronchopulmonary, less often in the front group) (40–75%) lymph nodes. The defeat of lymph nodes of other groups (axillary, inguinal, femoral) LH in children is rare, but in adolescents, it is not casuistry.

The most common clinical defeat of lymph nodes in this disease begins with the increase of one of them (more often—on the neck), with the gradual involvement of the other lymph nodes. Characteristic is the manifestation of local lymphadenopathy, which reveals a “package” of enlarged lymph nodes of various sizes, reaching 5 cm or more in diameter, uncoated, painless, with unchanged skin above them. The most precise and clear definition and description of this is the term “potato symptom in the bag,” which was introduced by the Russian pediatrician A.A. Kissel in the beginning of twentieth century. The development of this symptom is gradual and, given the absence of pain, even with visually defined neck asymmetry, patients do not actively go to the doctor.

With exceptionally squeezed development of the disease, the signs of bronchial obstruction appear without any obvious signs of inflammation. NHL quite often have clinical manifestations, characteristic of LH, but the rate of development of the disease is rapid. A feature of the development of B-cell lymphomas is that they develop, as a rule, from lymphoid tissue located in the abdominal cavity and retroperitoneal space. Therefore, their signs are manifestations of intestinal obstruction, including intussusception, swelling in the abdomen, constipation that has arisen without an obvious cause, and so on.

*Diagnosis of ML:*

1. Clinical blood test (typical normochromic anemia, neutrophilic leukocytosis, lymphopenia, eosinophilia, monocytosis, increased ESR);
2. Biochemical blood test (possible increase of lactate dehydrogenase, SRP, ceruloplasmin, haptoglobin, fibrinogen);
3. Biopsy of lymph nodes with histological and immunohistochemical examination;
4. Radiography or computed tomography of the chest in 2–5 projections (an increase in the thymus occurs in 20%, lung damage is also in 20%);
5. Ultrasound examination of the abdominal cavity (spleen lesion—30%);
6. Radioisotope diagnosis of lymphatic tissue with gallium-67 citrate;
7. Positron emission tomography with 18FDG;
8. Bone marrow puncture (with suspicion of NHL);
9. Lumbar puncture (with suspicion of NHL).

*Tumors of the brain and spinal cord (TBSM)* are a heterogeneous group of tumors that are localized in the structures of the brain and spinal cord and differ in histological structure and degree of malignancy.

TBSM occupy the second place in the structure of malignant neoplasms in pediatrics, accounting for 16–20% and are the most common solid tumors in children; on 95%, they are represented by brain tumors (BT). Tumors of the spinal cord (TSC) in children account for 5% of all TBSM. Incidence of TBSM is 4 cases per 100,000. The incidence rate is higher in boys (4.2 per 100,000) compared with girls (3.8 per 100,000) [5].

There are two peaks in the incidence of TSC. The first peak with a small predominance of boys is noted in the first decade of life, the second is observed from the third to the fourth decade and reaches a maximum by 60 years. The structure of the first peak is dominated by embryonic neoplasms of the brain and piloid astrocytoma. Since the third decade, the incidence of TSC has increased sharply, typical of adults—supratentorial gliomas.

Clinical manifestations. The leading symptoms in the brain tumor clinic are symptoms of increased intracranial pressure, which are manifested by morning headaches, vomiting, strabismus, or other visual disorders. Headache occurs in the morning, when getting out of bed, it is facilitated by vomiting and decreases during the day. Vomiting is observed in 80% of patients with a brain tumor. Examination of the fundus reveals signs of edema of the optic disc.

At the very beginning of the disease, rare vomiting in the morning, which brings relief, parents are associated with inaccuracy in nutrition and do not consult a doctor. Repeated vomiting in patients with TSC in the absence of focal neurological symptoms is often the cause of erroneous diagnoses, such as gastritis and gastroduodenitis, helminthic invasion, meningitis. Pediatricians and gastroenterologists observe patients for a long time and treat for a gastroenterological disease or infection.

The headache is also not associated for some time with the tumor disease, and doctors, including neurologists, treat for overfatigue, vegetovascular dystonia, and

other diseases. Only the increase in the intensity and frequency of headaches is the reason for the examination.

In young children, the symptoms of intracranial hypertension lead to macrocephaly.

With tumors of the posterior cranial fossa, the clinical picture is dominated by symptoms of increased intracranial pressure. In tumors in the cerebellum, there is also a violation of gait and balance.

Tumors of the cerebral hemispheres are characterized by focal symptoms—seizures, loss of visual fields, neuropathy or dysfunction of the cortico-spinal tract.

Middle-located supratentorial tumors can cause endocrine disorders—diencephalic syndrome (developmental lag and cachexia).

About 15–45% of primary TSC (embryonic tumors, ependymal and germinative cell tumors) metastasize to other parts of the central nervous system (CNS). Neurologic disorders in metastases sometimes neutralize the symptoms of the primary tumor.

The clinical symptoms of BT are back pain (in 50% of cases), resistance to flexing of the trunk, spasm of paravertebral muscles, deformity of the back (progressive scoliosis), gait disturbance, lowering of reflexes in the upper extremities and an increase in the lower extremities, impaired sensitivity depending on the level of lesion, a positive symptom of Babinsky, disruption of the sphincter of the bladder and/or anal. Symptoms of compression of the spinal cord increase in the supine position and decrease in the sitting position.

#### *Diagnostics of TBSM:*

1. Magnetic resonance imaging of the brain and/or spinal cord with contrast;
2. Investigation of serum alpha-fetoprotein level in tumors of the pineal region and/or chiasmatic-sellar region and/or subcortical structures;
3. Investigation of the level of chorionic gonadotropin in the blood serum for tumors of the pineal region and/or chiasmatic-sellar region and/or subcortical structures;
4. Study of alpha-fetoprotein in the cerebrospinal fluid for tumors of the pineal region and/or chiasmatic-sellar region and/or subcortical structures (in the absence of intracranial hypertension);
5. Investigation of the level of chorionic gonadotropin in the cerebrospinal fluid in tumors of the pineal region and/or chiasmatic-sellar region and/or subcortical structures (in the absence of intracranial hypertension).

*Retinoblastoma (RB)* is the most common intraocular malignant tumor of neuroepithelial origin, affecting the retina of the eye.

It occurs mainly in childhood and is 2.5–4.5% of malignant tumors in children. Its frequency is 0.29–0.31 per 100,000. There is no significant dependence of the incidence on sex. The average age of detection of RB is 21.2 months, with a bilateral lesion of 14.6 months, with a one-sided lesion of 23.5 months.

RB occurs in two forms:

1. Genetic (congenital, 40%), in which there is a bilateral multifocal lesion, is a consequence of chromosome mutations of germ cells;
2. Sporadic (60%) is characterized by the presence of one tumor node in one eye.



In the first variant, the risk of developing RB in other children in the family and in subsequent generations exceeds 50%, at the second—6%. The risk of inheritance of a unilateral RB increases if the patient has a predisposing mutation to the disease.

**Clinical manifestations.** The clinical course of the RB is characterized by rapid growth. Due to insufficient blood supply, the tumor quickly necrotic, in the necrosis zones calcifications are formed.

Metastases with lymphogenous and hematogenous pathways in the parotid, submandibular, cervical groups of lymph nodes, in the skull bones, tubular bones, and liver.

Initially, the tumor is located within the retina, then spreads to the vascular membrane and the vitreous. The first clinical sign is leucocoria—a whitish-yellow glow of the pupil due to the reflection of light from the surface of the tumor. As one grows, a node (one or more) is formed of grayish-whitish color of rounded form, which goes into the vitreous body. Visual acuity decreases, and strabismus appears. As a result of the destruction and germination of the trabecular apparatus of the eye, the outflow of the intraocular fluid is disturbed, and the intraocular pressure increases. There is pain in the eye, stagnant infection, corneal edema, dilated pupil and lack of its response to light. Extensive dystrophic changes and necrosis of the tumor tissue lead to the onset of inflammatory processes (uveitis, iridocyclitis). Exophthalmos arises from the edema of the cellulose of the orbit or when the tumor grows into the orbit. When the tumor spreads through the optic nerve, a headache, nausea, and vomiting occur in the cranial cavity.

#### *Diagnostics RB:*

1. Ophthalmological examination with medial mydriasis and application of the retinal chamber;
2. Ultrasound examination of orbits and eyes;
3. Computer tomography and/or magnetic resonance imaging of orbits and brain with contrast;
4. Computed tomography of thoracic organs;
5. Ultrasound of the organs of the abdominal cavity, retroperitoneal space, cervical lymph nodes.

*Neuroblastoma (NBL)* is an embryonic malignant tumor that originates from the ganglia of the border sympathetic trunk and chromaffin tissue.

It is mainly localized in the retroperitoneal space (more than 66%), less often in the posterior mediastinum (15%), it can also be located on the neck, face, and so on.

In the vast majority of cases, NBL is detected in children aged in the first 2 years of life. In the structure of malignant tumors, it accounts for about 7%. The global average incidence of neuroblastoma is 0.68 per 100,000, and boys are more likely to fall ill [6].

**Clinical manifestations.** Initial clinical manifestations of NBL have no specificity. However, unexplained bouts of sweating, pallor of the skin, diarrhea, and hypertension should alert the pediatrician. These symptoms may be manifestations of catecholamine intoxication, which is characteristic of NBL, cells of which produce catecholamines (adrenaline, norepinephrine, dopamine) and their metabolites (vanillylmandal and homovanilic acids).

The unfolded clinical picture of NBL is determined by its localization:

- The NBL of the retroperitoneal space is palpated through the anterior abdominal wall in the form of a tuberos, nondisplaced tumor node;
- NBL of the small pelvis causes violations of the act of bowel movement and urination;
- Mediastinal NBLs are usually detected by chance during chest X-ray; at a high location of the node, Horner's syndrome can be noted;
- With the spread of NBL through the intervertebral foramen to the spinal canal (a tumor of the "hourglass" or "dumbbell-like" form) and compression of the spinal cord, the flaccid paralysis of the lower limbs and pelvic organs develop.

In addition, the NBL is characterized by two specific syndromes:

1. Myoclonus-optosilonus syndrome with polymyoclonia, cerebellar ataxia, gait disorder and opselonus is most often observed with the localization of NBL in the chest;
2. Profuse watery diarrhea caused by the fact that NBL cells produce a vasoactive intestinal peptide.

It should be noted that in 50% of patients at the time of diagnosis, there are already metastases that can manifest as pain in the bones, eye socket proptosis or flu-like syndrome.

#### *Diagnosis of NBL:*

1. Morphological examination of the tissue of the primary tumor and/or foci suspicious for metastatic;
2. Ultrasound examination of the abdominal cavity organs and retroperitoneal space and the area of the primary tumor focus;
3. Magnetic resonance imaging with intravenous contrast of the primary tumor zone and/or computed tomography of the primary tumor lesion;
4. Radioisotopic bone diagnosis and/or magnetic resonance imaging of the entire body;
5. Computed tomography of thoracic organs;
6. Radioisotope diagnostics with 123-iodine-metaiodobenzylguanidine (MIBG);
7. NSE level;
8. NMYC amplification;
9. Morphological examination of bone marrow points from three points.

*Nephroblastoma* (NB) is a high-quality embryonic tumor that originates from developing kidney tissues—a metanephrogenetic germ.

In the structure of oncological pathology in children is 7%. Her frequency is 0.6 per 100 thousand. In girls, NB occurs somewhat more often (1.12) than in boys (0.8).

The average age of children with NB is 3.5 years. As a rule, it is detected earlier, but sometimes it is diagnosed in older children, very rarely in adults [7].

Clinical manifestations. NB in children for a long time is almost clinically not apparent. The syndrome of small signs of a tumor (general malaise, lethargy, subfebrile fever, intermittent abdominal pain, gastrointestinal disorders, and hypertension) is present in most patients; however, as a rule, neither parents nor doctors attach much importance to them. Quite often, an increase in the size of the abdomen, sweating, and irritability of children is treated by pediatricians as rickets.

Usually the first, though not the earliest, clinical sign of the disease is a palpable tumor in the abdomen, which parents (less often doctors) discover by chance. It is smooth, sometimes coarse-grained, dense, and painless. Macrogematuria occurs less than in a quarter of patients and is a manifestation of tumor germination in the calyx-calcaneous kidney system. Quite often (in 25%), the examination reveals an arterial hypertension (secondary), which develops due to hyperreninaemia or the spread of a tumor thrombus in the lower vena cava down to the right atrium.

Occasionally, subcapsular tumor ruptures occur, under which the clinical picture of the “acute abdomen” develops. Differential diagnosis is usually performed with other tumors of the abdomen and retroperitoneal space, as well as kidney anomalies (hydronephrosis, polycystosis, and dystopia).

Diagnostic algorithm includes, in addition to general clinical examination, the following methods:

1. Laboratory studies to identify anemia, hematuria, renal failure, the level of catecholamines in the urine (for differential diagnosis with NBL);
2. X-ray—excretory urography and chest X-ray. The first allows to reveal the characteristic deformations of the cup-and-pelvis system and to assess the functional ability of both kidneys. Radiography of the chest is performed to identify metastases in the lungs;

Using ultrasound, the tumor size is measured, which will allow us to evaluate the effectiveness of treatment in the future, tumors in the renal and hollow veins are detected.

#### *Diagnosis of NB:*

1. Morphological examination of the tissue of the primary tumor and/or foci suspicious for metastatic;
2. Magnetic resonance tomography with intravenous contrast and/or computed tomography with intravenous contrasting of the abdominal cavity and retroperitoneal space;
3. Ultrasound examination of the abdominal cavity and retroperitoneal space;
4. Computed tomography of thoracic organs;
5. Renoscintigraphy.

*Hepatoblastoma (HB).* Primary liver tumors in children are relatively rare pathologies: 1–4% of all neoplasms occurring in childhood. This pathology is

characterized by a slow development of the tumor process and the absence of specific complaints for this disease.

HB is the most common malignant liver tumor that develops from an embryonic pluripotent bookmark.

HB has a unique age distribution. There are two age-specific peak incidences: the first occurs at birth or in the first month of life, the second occurs during the 16th–18th months of life. GB occurs in adults, although extremely rare. GB in children older than 5 years, usually has a more aggressive course, and has the characteristics of hepatocellular cancer. It is more common in boys: the sex ratio is from 1.5:1 to 2:1 [8].

Clinical manifestations. HB do not have specific clinical symptoms. Usually, thrombocytosis is noted; in addition, it has been established that the serum alpha-alpha-protein level is the primary marker of the tumor, which plays an important role in diagnosis. The normal level—up to 20 ng/ml—can increase several thousand times.

Most HB often metastasizes to the lungs and bones. Regional lymphonoduses of the liver are extremely scarce.

#### *Diagnostics of HB:*

1. Magnetic resonance imaging with intravenous contrasting of the abdominal cavity and retroperitoneal space and/or computed tomography of the abdominal cavity and retroperitoneal space;
2. Ultrasound examination of the abdominal cavity and retroperitoneal space;
3. Computed tomography of thoracic organs;
4. Morphological examination of the tissue of the primary tumor and/or foci suspicious for metastatic disease.

*Germinogenic tumors (GT)* constitute no more than 3% of ZNO, occur in 1 case for 30,000–40,000 newborns. Malignant forms at the birth of a child are only 2%, but with age, the specific weight of them is rapidly increasing and by the age of 6 months, their share in the total structure has increased to 50–70%.

According to the histological picture (WHO classification, 1985), GT can be represented by cells of the same type—seminoma, disgerminoma, spermatocytic tumor (only in testicles), embryonic cancer, yolk sac tumor (endodermal sinus), polyembryoma, choriocarcinoma, or several of the listed types in different combinations. All of them, with the exception of teratom, are malignant or immature (potentially malignant).

Clinical manifestations. The clinical picture depends on the location of the tumor and its morphological structure. The sacrococcygeal region is the end point of the settling of primordial pluripotent germ cell cells, so it is in this region that the GT is most often localized. Most often, they are represented by mature teratomas and consist of mature tissues, derivatives of all three embryonic leaflets (skin and its appendages, bones, parts of various organs, etc.). In the event that one of the tumor components is represented by an immature tissue (areas of neuroblastoma, rhabdomyosarcoma, etc.), the teratoma is called immature. If the focal points of the yolk sac tumor are determined in the teratoma, it refers to tumors of a complex structure. As a rule, these tumors are located anterior to the sacrum and coccyx, and at large sizes they spread from the cavity of the small pelvis outwards between the coccyx and the anus.

Tumors of the ovaries clinically manifest mainly in abdominal pain, which can take the form of acute when twisting the legs or rupturing the tumor. With large



tumor sizes, the abdomen increases in size, and in some cases of histological structure (dysherminoma, a complex tumor), signs of premature sexual development or, vice versa, they are absent at the age when they should already be. Symptoms of tumor intoxication (lethargy, pale skin, decreased appetite, etc.) appear only when the tumor process is disseminated.

The main sign of testicular tumors is the presence of palpable formation in the scrotum.

*Diagnosis of GT:*

1. Magnetic resonance imaging with intravenous contrast of the pelvic organs and abdominal cavity and retroperitoneal space;
2. Ultrasound examination of the pelvic organs and abdominal cavity and retroperitoneal space and primary tumor focus;
3. Computed tomography of thoracic organs;
4. Radioisotope diagnosis of bones;
5. Study of the level of alpha-fetoprotein in the blood serum;
6. Investigation of the level of chorionic gonadotropin in the blood;
7. Investigation of the level of lactate dehydrogenase in the blood;
8. Morphological examination of the tissue of the primary tumor and/or foci suspicious for metastatic disease.

*Bone tumors* in children make up about 10% of all malignant neoplasms, found mainly in the second decade of life. Between 50% and 70% of all malignant bone tumors are osteosarcoma, the main nosological unit in this group of diseases. Second place in the frequency of occurrence in children is Ewing's sarcoma (25%).

*Osteosarcoma* (OS)—the most common primary tumor of brachi in children, ranks sixth in frequency among all malignant tumors of childhood. The tumor originates from the primitive bone-forming mesenchyme is characterized by the production of osteoid with malignant proliferation of the spindle stroma. The peak of the incidence falls on the second decade of life. In boys, the incidence of the disease is higher, whereas at an earlier age, girls are predominantly ill (who have more bone ages in this period than boys) [9].

**Clinical manifestations.** The main clinical sign of OS is pain over the affected area. The pain is dull, constant, with a gradual increase in intensity. A characteristic symptom is nocturnal pain. Three-fourths of patients may have a soft tissue component. The extremity is enlarged in volume, often looks edematous. Pain and volume increase lead to impaired function. The duration of the anamnesis is, on average, 3 months. The metaphysis of long tubular bones is characteristic. The most frequent localization (50%) is the area of the knee joint—the distal part of the thigh and the proximal part of the tibia. Often the proximal part of the humerus and femur, the middle third of the femur, is also affected. The defeat of flat bones, especially the pelvis, occurs in childhood less than 10%.

OS has a significant tendency to develop hematogenous metastases. At the time of diagnosis, 10–20% of patients have macrometastases in the lungs, which are detected by X-ray. About 80% of patients at the time of diagnosis are



micrometastases in the lungs, not detectable by roentgenograms, sometimes visible in computed tomography.

Since the bones do not have a developed lymphatic system, early dissemination of the OS to regional lymph nodes is rare, but if this occurs, it is a poor prognostic sign.

Other areas of metastasis—bone, pleura, pericardium, kidney, and CNS. The disease also has local aggressive growth, it can spread to the epiphysis and the nearby joint (most often the knee and shoulder joints), spreading along the intraarticular structures, through the articular cartilage, through the pericapsular space, or directly, due to pathological transformation, and form not adjacent to it foci-satellites—“skip”—metastases.

*Ewing's sarcoma (ES)* consists of small round cells with scant cytoplasm, a round nucleus containing a gentle chromatin and poorly visible basophilic nucleols. Unlike OS, it does not produce an osteoid. This tumor is rare in children younger than 5 years and in adults over 30 years. The peak incidence falls on 10–15 years.

In contrast to OS, ionizing radiation is not associated with the occurrence of ES [10].

Clinical manifestations. Clinical signs of ES are increased pain, swelling over the affected area with a violation of limb function. The tumor is usually painful on palpation, rapidly increasing in size. The defeat of peripheral nerves can cause the appearance of neurological symptoms. There may be fever of varying degrees. The soft tissue component of the tumor is often more pronounced than the bony focus. In the tumor often, there are hemorrhages and necrosis, which cause an increase in local temperature, erythema and mimics nonspecific inflammation, which makes diagnosis difficult. Such a symptomatology allows, first of all, to assume the presence of osteomyelitis.

The most common localization of ES is pelvic bone, femur, tibia, fibula, ribs, scapula, vertebrae, and humerus. ES is most often affected by flat bones.

In tubular bones, the tumor localizes primarily in the diaphysis and tends to spread to the bone epiphyses. In 91%, the tumor is located intramedullary, and the spread along the medullary canal is often greater than in the bone.

#### *X-ray signs of ES:*

- Bone destruction (“moth-eaten”) without clear boundaries, with a tendency to spread along the medullary canal;
- “Bulbous periostitis”—a multilayered linear periostitis, which can combine with needle;
- A pathological fracture is revealed in 5%. With localization of the tumor in the proximal area of the femoral bone, a pathological fracture occurs much more often (more than 70%);
- When radiography of soft tissues reveals a clear soft tissue component of a homogeneous structure;
- Rib injuries often combine with pleurisy.

However, X-ray signs are not absolutely pathognomonic. It is necessary to carry out differential diagnostics with other pathological processes in the bones—first of all with osteomyelitis, trauma, other malignant tumors (rhabdomyosarcoma, synovial sarcoma, lymphoma, and NBL).

*Diagnosis of bony sarcomas:*

1. Morphological examination of the tissue of the primary tumor and/or foci suspicious for metastatic;
2. Magnetic resonance imaging with intravenous contrast of the affected bone and adjacent joints;
3. Radioisotopic examination of bones of the skeleton and soft tissues and/or magnetic resonance imaging of the whole body;
4. Ultrasound examination of the primary tumor zone and regional lymph nodes and abdominal cavity and retroperitoneal space;
5. Computed tomography of the chest, affected bone, and adjacent joints;
6. Morphological examination of bone marrow points from three points;
7. Radiography of the affected bone in two projections (frontal and lateral) with scale markings.

*Soft tissue sarcoma (STS)* is a heterogeneous group of malignant tumors primarily located in soft tissues and having a mesenchymal origin. In the structure, the incidence of STS is the fourth place and make up 6–8% of all malignant tumors of childhood. In newborns and children younger than 1 year, this type of tumors is observed in 10–12% of cases. In 50% of cases, RMS is located in the head and neck region, whereas in 25–37% of cases, it is located in the trunk and extremities.

The most common in children are: rhabdomyosarcoma (61%); extraangular Ewing's sarcoma and peripheral neuroectodermal tumor (8%); synovial sarcoma (7%); neurofibrosarcoma, angiosarcoma (4%); fibrosarcoma (3%), and leiomyosarcoma (2%), as well as extra-osseous chondrosarcoma and osteosarcoma, epithelioid sarcoma, malignant fibrotic histiocytoma, malignant hemangio-periatomy, malignant mesenchymoma, malignant schwannoma, liposarcoma, and sarcoma without additional characteristics.

**Clinical manifestations.** A visually identifiable or palpable tumor is one of the earliest symptoms of the disease, in some cases discovered by chance.

The clinical picture is mainly determined by the localization of the process.

- **Torso and limbs.** The tumor is located in the thickness of the muscles, shifts in the transverse direction, can grow into the underlying bone, and the tumor becomes not shiftable. Palpator tumor is painless, often smooth, but can be also tuberos, and the temperature above it is usually slightly increased. The skin above the tumor is not changed, however, in the case of large lesions, it can thin out, acquire a purplish-cyanotic shade, shine, and a vascular pattern. As the growth or localization in the distal parts of the limbs appears pain syndrome, due to compression or germination of nerve trunks. Persistent local soreness appears when the tumor grows into the bone, the contracture of the joint—when it grows into its membranes.
- **Head and neck.** When localizing SMT in the area of the orbit in the early stages of the tumor process, there is swelling, exophthalmos. As growth grows, the formation can fill the orbit cavity, germinate into the eyeball, causing a decrease in vision until complete loss.

- **Nasopharynx.** One of the first symptoms—violation of nasal breathing—accompanied by mucopurulent discharge with an unpleasant odor, nasal voice. Pain syndrome, as a rule, occurs when the bones are damaged, and the tumor masses are filled with maxillary sinuses, sprouting into cells of the latticed labyrinth. Serous otitis can also be attached.
- **Middle ear.** One of the first manifestations is pain syndrome, localized in the ear. When obturating with a tumor of the ear canal, loss of hearing is added. In addition, it can be determined swelling in the behind-eye area, paralysis of the facial nerve, mucopurulent discharge from the auditory canal.
- **The oropharynx.** One of the earliest are symptoms of impaired swallowing, respiratory function.
- **The vagina.** In the initial stages, it proceeds with symptoms characteristic of vulvitis, vaginitis, condyloma, polyps: discharge from the genital tract (yellowish color, bloody, with an admixture of pus and unpleasant odor) itching in the vagina, pain in the external genital area. As the urethra becomes obturated, symptoms of difficulty urinating, dysuric phenomena, are added. On examination, neoplasms of red color are sometimes found.
- **Bladder.** Most often localized in the region of the neck or triangle of Little. The tumor is characterized by rapid exophytic growth, the walls of the bladder germinate, the prostate gland. There is frequent urge to urinate, tenesmus without urination. It can join hematuria, including profuse. When joining a secondary infection, pyuria develops, which is accompanied by an increase in dysuria, a painful urination. A partial or complete retention of urine resulting from obturation with a tumor of the neck of the bladder may develop.
- **Testicle.** It shows a painless seal with uneven contours in the tissue area of the organ. As the tumor grows, the size of the testicle increases, its compaction, swelling of the scrotum, and suprapubic region.
- **Thoracic and abdominal cavity, retroperitoneal space.** With these localizations, the symptoms are due to the growth of the tumor in the surrounding tissue and compression of the main and central veins, arteries. With compression of the superior vena cava, shortness of breath, acrocyanosis, dizziness is noted. Symptoms of intestinal obstruction, pain syndrome, dyspeptic phenomena, and melena can also be added.

#### *Diagnosis of STS:*

1. Morphological examination of the tissue of the primary tumor and/or foci suspicious for metastatic;
2. Magnetic resonance imaging with intravenous contrast of the primary tumor focus;
3. Ultrasound examination of the primary tumor zone and regional lymph nodes and abdominal cavity and retroperitoneal space;
4. Computed tomography of thoracic organs;

5. Radioisotopic examination of bones of the skeleton and soft tissues and/or magnetic resonance imaging of the whole body;
6. Morphological examination of bone marrow points from three points.

#### **4. Conclusion**

Despite the apparent scarcity of pathology, pediatricians should have basic knowledge in diagnosis and differential diagnosis of cancer and similar pathological conditions in children and orient themselves in certain subtleties of therapeutic and diagnostic tactics in them [11].

#### **Author details**


Maxim Yu. Rykov<sup>1,2\*</sup>

1 Institute of Pediatric Oncology and Hematology N.N. Blokhin, Medical Research Center of Oncology of the Ministry of Health of the Russian Federation, Moscow, Russian Federation

2 I.M. Sechenov First Moscow State Medical University, Moscow, Russian Federation

\*Address all correspondence to: wordex2006@rambler.ru

#### **IntechOpen**

© 2018 The Author(s). Licensee IntechOpen. This chapter is distributed under the terms of the Creative Commons Attribution License (<http://creativecommons.org/licenses/by/3.0>), which permits unrestricted use, distribution, and reproduction in any medium, provided the original work is properly cited. 

## References

- [1] Rykov MY, Baybarina EN, Chumakova OV, Kupeeve IA, Karavaeva LV, Polyakov VG. Improvement of the organizational and methodological approaches to healthcare delivery for children with cancer. *Onkopediatriya*. 2017;**4**(2): 91-104. DOI: 10.15690/onco.v4i2.1703
- [2] Alieva MD, Polyakova VG, Mentkevicha GL, Mayakovoy SA, editors. *Pediatric Oncology. National Leadership*. M.: Izdatel'skaya gruppa RONTs; 2012. 681 p
- [3] Aleskerova GA, Shervashidze MA, Popa AV, Valiev TT, Kurdyukov BV, Batmanova NA, Mentkevich GL. Results of treatment of acute lymphoblastic leukemia in children by protocol ALL IC-BFM 2002. *Onkopediatriya*. 2016; **3**(4):302-308. DOI: 10.15690/onco.v3i4.1635
- [4] Gevorgyan AG, Morozova EV, Kazantsev IV, Punanov YA, Safonova SA, et al. High-dose polychemotherapy with transplantation of autologous hematopoietic stem cells in children with malignant tumors of the central nervous system. *Onkopediatriya*. 2016; **3**(1):24-35. DOI: 10.15690/onco.v3i1.1526
- [5] Louis D, Ohgaki H, Wiestler OD, Cavenee WK. *WHO Classification of Tumours of the Central Nervous System*. Revised 4th ed. 2016. 408 pp
- [6] Cheung NK, Dyer MA. Neuroblastoma: Developmental biology, cancer genomics and immunotherapy. *Nature Reviews. Cancer*. 2013;**13**(6): 397-411. DOI: 10.1038/nrc3526
- [7] Kieran K, Williams MA, McGregor LM, Dome JS, Krasin MJ, Davidoff AM. Repeat nephron-sparing surgery for children with bilateral Wilms tumor. *Journal of Pediatric Surgery*. 2014;**49**: 149-153
- [8] Yuan XJ, Wang HM, Jiang H, Tang MJ, Li ZL, Zou X, et al. Multidisciplinary effort in treating children with hepatoblastoma in China. *Cancer Letters*. 2016;**375**(1):39-46
- [9] Whelan JS, Bielack SS, Marina N. EURAMOS-1, an international randomised study for osteosarcoma: Results from pre-randomisation treatment. *Annals of Oncology*. 2015;**26**: 407-414
- [10] Bacci G, Forni C, Longhi A. Long-term outcome for patients with non-metastatic Ewing's sarcoma treated with adjuvant and neoadjuvant chemotherapies. 402 patients treated at Rizzoli between 1972 and 1992. *European Journal of Cancer*. 2004; **40**(1):73-83. DOI: 10.1016/j.ejca.2003.08.022
- [11] Rykov MY, Baybarina EN, Chumakova OV, Turabov IA. The results of the external audit of medical care for children with cancer in one of the regions of the Russian Federation. *Onkopediatriya*. 2016;**3**(2):67-79. DOI: 10.15690/onco.v3i2.154