

We are IntechOpen, the world's leading publisher of Open Access books Built by scientists, for scientists

6,900

Open access books available

186,000

International authors and editors

200M

Downloads

Our authors are among the

154

Countries delivered to

TOP 1%

most cited scientists

12.2%

Contributors from top 500 universities



WEB OF SCIENCE™

Selection of our books indexed in the Book Citation Index
in Web of Science™ Core Collection (BKCI)

Interested in publishing with us?
Contact book.department@intechopen.com

Numbers displayed above are based on latest data collected.
For more information visit www.intechopen.com



Desquamative Gingivitis: Early Sign of Mucous Membrane Pemphigoid and Pemphigus Vulgaris

Hiroyasu Endo, Terry D. Rees, Hideo Niwa,
Kayo Kuyama, Maya Oshima, Tae Serizawa,
Shigeo Tanaka, Morio Iijima, Masamichi Komiya and
Takanori Ito

Additional information is available at the end of the chapter

<http://dx.doi.org/10.5772/intechopen.77258>

Abstract

Early signs and symptoms of autoimmune bullous diseases such as mucous membrane pemphigoid (MMP) or pemphigus vulgaris (PV) develop in the oral cavity in almost all cases. Desquamative gingivitis (DG) is a clinical manifestation common to several diseases or disorders and is frequently associated with autoimmune bullous diseases. This is a retrospective study of 37 patients with MMP (24 cases) or PV (13 cases) including 10 males and 27 females with a mean age of 58.4 years. The study indicates that DG is an early sign of autoimmune bullous diseases such as MMP or PV. About 70.3% of the oral lesions were confined only to the gingiva, and DG was the only manifestation of the diseases. Since some lesions remain limited to the oral cavity for a long period of time, patients diagnosed with MMP or PV should be closely followed because they must be immediately referred to other experts when they develop lesions on parts of their body other than the oral cavity. The oral healthcare provider should collaborate with other healthcare experts including dermatologists, ophthalmologists, and otolaryngologists to evaluate and manage patients with autoimmune bullous diseases in the oral cavity.

Keywords: gingival diseases/pemphigus/pemphigoid, benign mucous membrane/autoimmune diseases/mouth diseases

1. Introduction

Early signs and symptoms of autoimmune bullous diseases such as mucous membrane pemphigoid (MMP) or pemphigus vulgaris (PV) develop in the oral cavity in almost all cases. MMP

is the most commonly recognized, followed by PV [1]. MMP is one of a group of autoimmune, subepithelial blistering diseases that predominantly affect the mucous membranes. MMP is considered to be a disease phenotype related to one or more different anti-basement membrane zone (BMZ) autoantibodies. Various components in the hemidesmosomes have been recognized as the target antigens of MMP, including bullous pemphigoid antigen 2 (BP180), bullous pemphigoid antigen 1 (BP230), laminin 332, type VII collagen, and $\beta 4$ or $\alpha 6$ integrin subunits [2–5]. Most MMP patients are in the fifth or sixth decade of life, and the majority of them are women [6–8]. Oral lesions are observed in almost all cases, and the primary lesion often appears in the oral cavity [6–10]. PV is an autoimmune bullous disease characterized by acantholysis and suprabasilar separation in the epithelium of skin and/or mucous membranes. The main target antigen of PV is desmoglein (Dsg) 3, which is a constituent of desmosomes on the keratinocyte [11, 12]. Almost all PV patients with lesions limited to the oral mucosa have circulating autoantibodies to Dsg3 [12–15]. PV patients with lesions in the oral mucosa and skin also have Dsg1 autoantibodies, the main antigen of pemphigus foliaceus [12, 14, 15]. PV can develop at any age, but is most commonly observed in middle-aged and elderly individuals [16–19]. Early signs and symptoms of PV develop in the oral cavity in about 80% of patients [19].

Since patients with MMP or PV frequently experience only oral symptoms of pain and discomfort, they often visit the dentist or periodontist before other health care workers [20–22]. Desquamative gingivitis (DG) is a condition characterized by painful erythematous gingiva not resulting from dental plaque, sloughing of gingival tissues, erosions and ulcerations of the gingival epithelium and bulla formation on the gingiva [23–26]. It is a clinical manifestation common to several diseases or disorders [23–26]. Most DG patients are caused by mucocutaneous diseases. The differential diagnoses include oral lichen planus, MMP, and PV [24]. MMP is responsible for 35–48% and PV for 3–15% of DG [26]. Contact allergic reactions to various oral hygiene products, dental materials, or food flavoring and preservatives have also been reported in the differential diagnosis of DG [23, 24]. Gingival desquamation is a prominent clinical feature, and Nikolsky's sign often shows a positive reaction in DG caused by autoimmune bullous diseases [21]. This sign involves the application of a firm sliding or rubbing force on normal-appearing gingiva, inducing epithelial desquamation [21, 27].

Although an accurate diagnosis of oral mucosal disease or disorder causing DG is required to provide proper treatment, it is almost impossible to do so based solely on clinical appearance. Therefore, histopathological examination and direct immunofluorescence (DIF) testing are often required to establish the final diagnosis [24]. The specific disease or disorder causing DG, the severity of the DG lesions, the presence or absence of extraoral lesions, and the medical history of the patient are the key factors in determining the selection of a topical or systemic treatment [10, 23, 24]. In some patients, DG can be successfully managed with moderate to very high-potency topical corticosteroids combined with effective plaque control. Patients with severe and/or multiple oral lesions, or recalcitrant lesions, may need aggressive systemic treatment. The presence of extraoral lesions also may require systemic treatment for effective management. Although scarring with MMP is rarely a feature of the oral mucosa, conjunctival scarring may lead to blindness if not treated aggressively [28, 29]. Airway obstruction due to laryngeal scarring is a rare condition, but it may occasionally be a fatal complication [30, 31]. PV is a life-threatening condition if left untreated [32], so it is important to diagnose and

treat it in its early stages. This study describes in detail the clinical and diagnostic findings of MMP or PV as a common oral manifestation of autoimmune bullous diseases.

2. Materials and methods

This is a retrospective study of 37 patients with MMP (24 cases) or PV (13 cases) who were seen by the authors at Nihon University, School of Dentistry at Matsudo between 2001 and 2017. Patients participating in the study included 10 males and 27 females, aged 24–83 years, with a mean age of 58.4 years. The medical records included information on each patient's clinical features, intraoral site involvement, presence or absence of extraoral lesions, duration from the onset of symptoms until presentation for diagnosis, and diagnostic information provided to the patient. A biopsy was obtained that included perilesional tissue and was then submitted for routine histopathology and DIF study for each of the 37 patients. DIF study was performed using conjugates for immunoglobulin (Ig) G, IgA, IgM, complement C3, and fibrinogen. Patients were diagnosed with MMP or PV through clinical examination supported by histologic diagnosis and DIF testing [24, 25, 33]. Some of the 37 patients presented in this study have been previously reported [9, 13, 14, 21, 34]. The current study was approved by the institutional review board (Ethics Committee Approval no. EC14-011-1).

3. Results

The results summarizing the intraoral involvement in 37 patients are shown in **Table 1**. All 37 patients described DG lesions including erythema, erosions, ulcerations, and epithelial desquamation (**Figures 1–4**). The oral lesions were confined to gingiva in 70.3% of patients. In a small number of patients, ulcers and erosions were also observed in the buccal mucosa, soft palate or tongue (**Figures 5–7**). **Table 2** summarizes the diagnostic pattern in the 37 patients. Diagnosis delays of more than 6 months were experienced by 30.8% of the PV patients and 54.2% of the MMP patients. 16.7% of patients with MMP were delayed for more than 12 months from onset to diagnosis. The results summarizing the characteristics of the biopsy

Site	MMP (n = 24)	PV (n = 13)	Total (n = 37)
Gingiva only	17 (70.8%)	9 (69.2%)	26 (70.3%)
Gingiva + buccal mucosa + tongue	1 (4.2%)	2 (15.4%)	3 (8.1%)
Gingiva + buccal mucosa + soft palate	0 (0%)	1 (7.7%)	1 (2.7%)
Gingiva + buccal mucosa	2 (8.3%)	1 (7.7%)	3 (8.1%)
Gingiva + soft palate	3 (12.5%)	0 (0%)	3 (8.1%)
Gingiva + tongue	1 (4.2%)	0 (0%)	1 (2.7%)

Table 1. Intraoral site involvement in 37 patients.

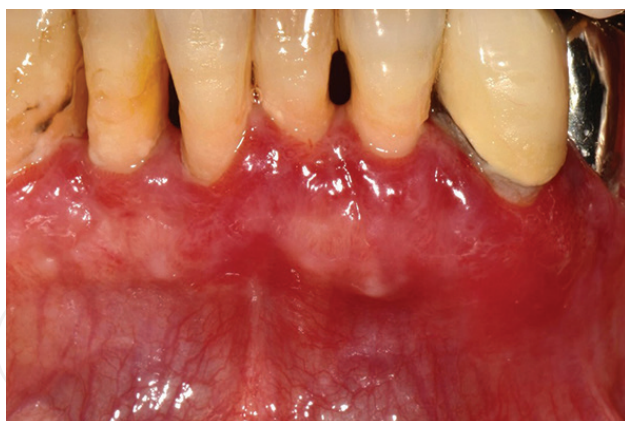

Figure 1. Desquamative gingivitis associated with mucous membrane pemphigoid. Diffuse erythematous lesions on the gingiva.

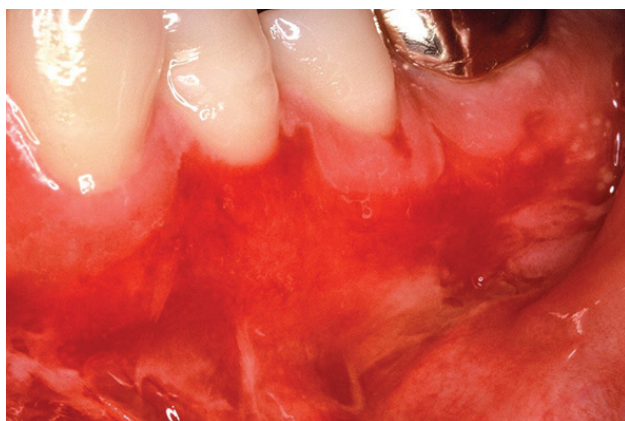


Figure 2. Desquamative gingivitis associated with pemphigus vulgaris. Patchy erythematous lesions were found on the gingiva.

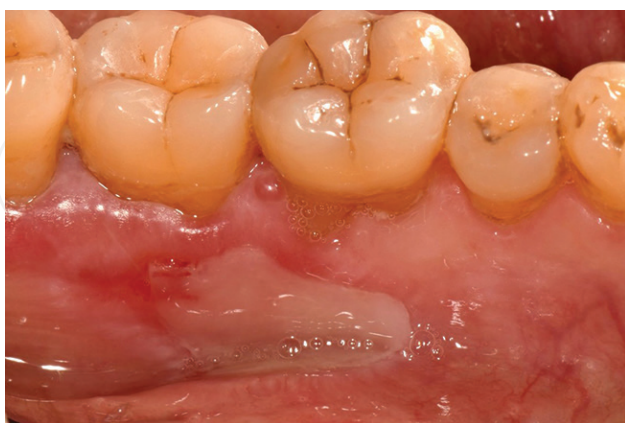

Figure 3. Pseudomembrane-covered erosion of the gingiva associated with mucous membrane pemphigoid.

findings in these 37 patients are shown in **Table 3**. Subepithelial separation was observed in the H&E-stained section in 20 patients with MMP (**Figure 8**). Three MMP samples showed nonspecific inflammation, and one MMP sample was nondiagnostic because of a total lack

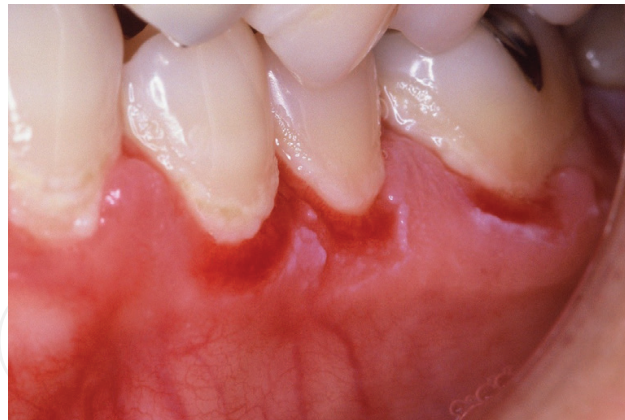

Figure 4. Localized erosions of the gingiva associated with pemphigus vulgaris.

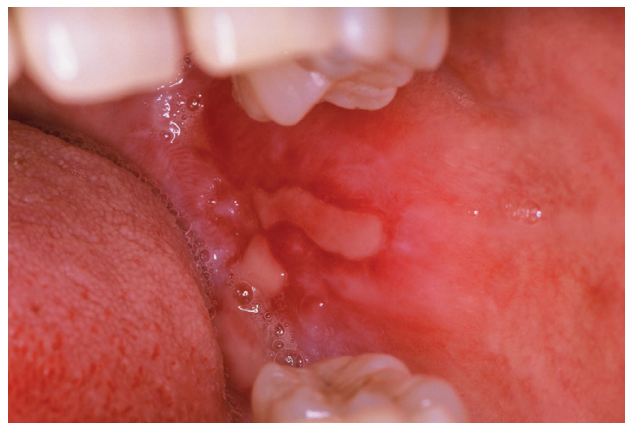

Figure 5. Pseudomembrane-covered erosion of the buccal mucosa associated with mucous membrane pemphigoid.

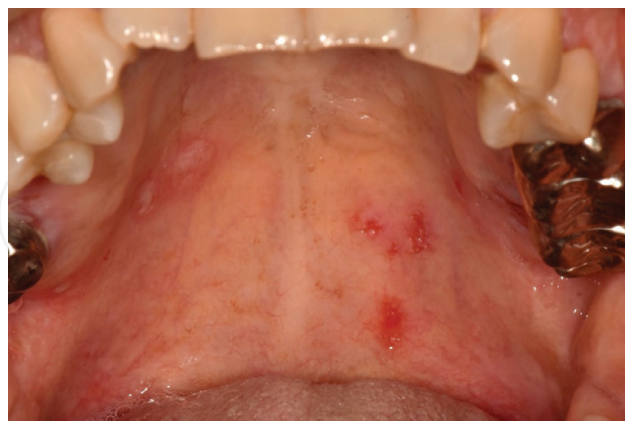

Figure 6. Localized erosions of the palatal mucosa associated with pemphigus vulgaris.

of the epithelium in the H&E-stained section. In contrast, acantholysis and a suprabasilar separation in the epithelium were observed in the H&E-stained section in all 13 PV patients (**Figure 9**). In the DIF testing, all 37 samples showed positive staining at the BMZ (MMP **Figure 10**) or at the intercellular space (PV **Figure 11**).

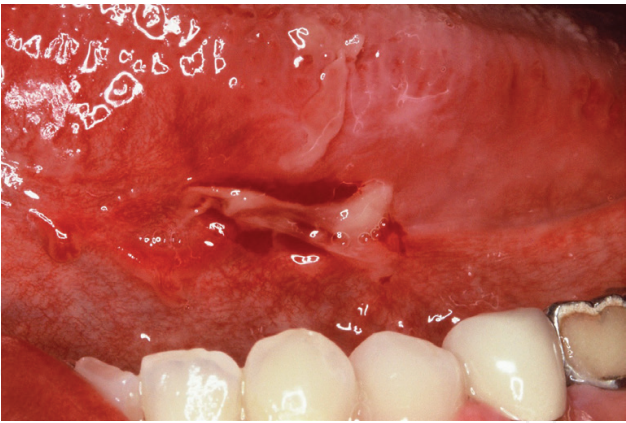


Figure 7. Desquamative lesion of the tongue associated with pemphigus vulgaris.

Diagnostic delay	Diagnosis		
	MMP (n = 24)	PV (n = 13)	Total (n = 37)
≤6 months	11 (45.8%)	9 (69.2%)	20 (54.1%)
7–12 months	9 (37.5%)	4 (30.8%)	13 (35.1%)
>12 months	4 (16.7%)	0 (0%)	4 (10.8%)

Table 2. Diagnostic pattern in 37 patients.

	MMP (n = 24)	PV (n = 13)
<i>Histopathology</i>		
Subepithelial separation	20	0
Acantholysis and suprabasilar separation	0	13
Non-specific	3	0
Non-diagnostic	1	0
<i>Direct immunofluorescence</i>		
Positive	24*	13**
Negative	0	0

*A linear BMZ deposition of varying combinations of IgG, IgA, fibrinogen and complement C3.

**An epithelial intercellular deposition of IgG and complement C3.

Table 3. Biopsy findings in 37 patients.

After a diagnosis of MMP or PV, patients were advised to confirm the presence or absence of extraoral lesions by a dermatologist, otorhinolaryngologist, and ophthalmologist. Eleven (eight patients with MMP and three patients with PV) of the 37 patients (29.7%) confirmed the presence of extraoral lesions. The sites where clinical involvement was found were skin (5 patients), upper airway (10 patients), and eye (2 patients). Multiple extraoral mucosal involvements were

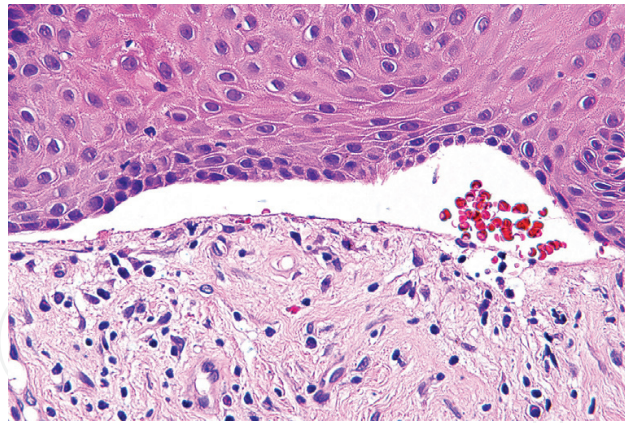


Figure 8. Hematoxylin-eosin-stained section of mucous membrane pemphigoid. A subepithelial separation was found.

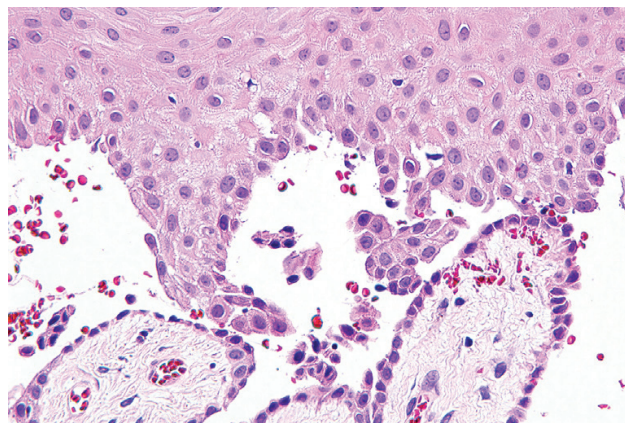


Figure 9. Hematoxylin-eosin-stained section of pemphigus vulgaris. Acantholysis and a suprabasilar separation in the epithelium were observed.

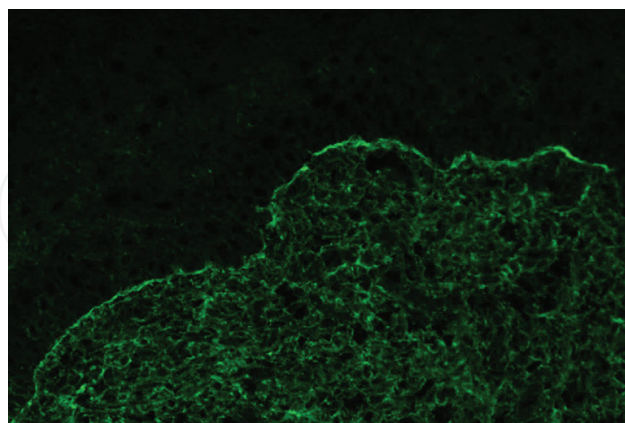


Figure 10. Direct immunofluorescence of the mucous membrane pemphigoid. A linear deposition of IgG at the basement membrane zone was recognized.

found in four patients with MMP and two patients with PV. All patients with extraoral involvement were managed by medical specialists with systemic treatment with or without hospitalization (**Figure 12a and b**). Patients with exclusively oral lesions were managed at the authors'

hospital using a topical corticosteroid combined with effective plaque control. Patients were carefully monitored at 2–3 week intervals, and complete remission or minimalization of symptoms was achieved (Figure 13a and b).

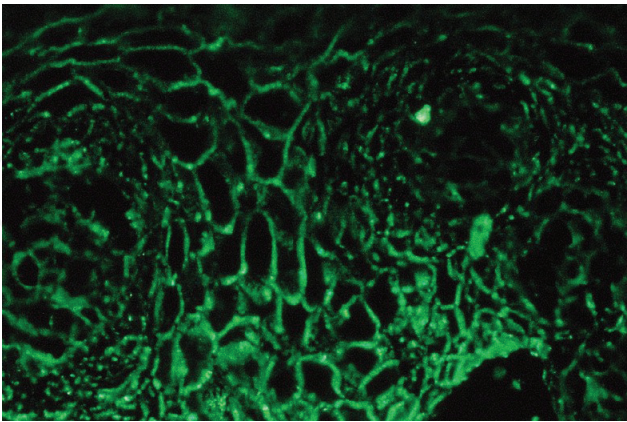


Figure 11. Direct immunofluorescence of pemphigus vulgaris. An intercellular deposition of IgG was evident.

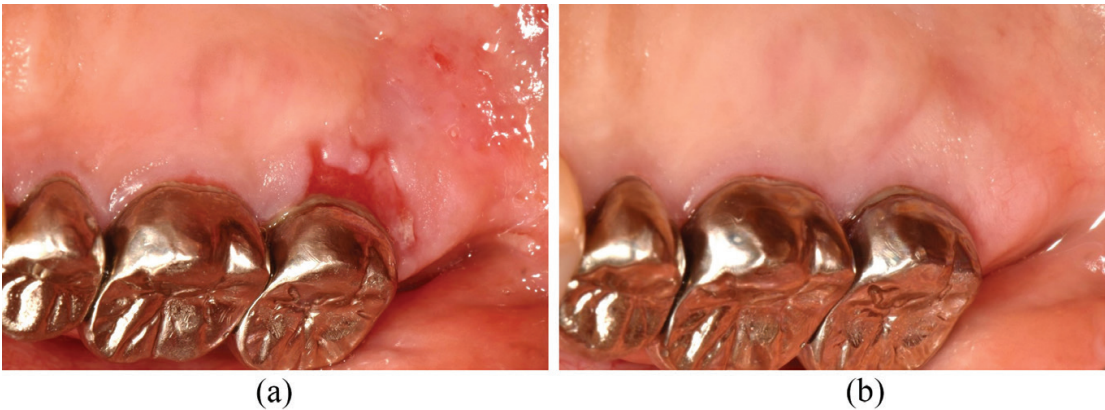

Figure 12. (a) Desquamative gingivitis associated with pemphigus vulgaris. Localized erosion was observed on the palatal mucosa. Lesions were also found on the skin and upper airway. (b) Treatment response. The patient was managed by dermatologists with systemic treatment with hospitalization.

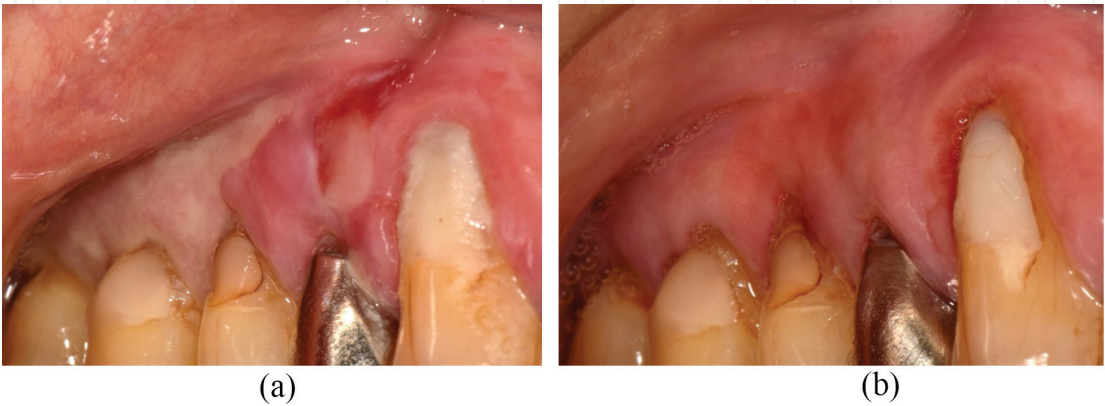

Figure 13. (a) Desquamative gingivitis associated with mucous membrane pemphigoid. (b) Treatment response. Desquamative gingivitis was successfully managed using a topical corticosteroid combined with effective plaque control.

4. Discussion

The results of this study indicate that DG is an early sign of autoimmune bullous diseases such as MMP or PV. Although multiple oral sites were affected in some patients, 70.3% of the oral lesions were confined only to the gingiva, and DG was the only manifestation of the diseases. Data from this study indicate 70.8% of MMP patients had oral lesions confined only to the gingiva. This figure agrees with other reports [8, 25]. In contrast, in the present study, the frequency of oral lesions limited to the gingiva in PV patients is higher (69.2%) than previous reports (3–30%) [17–19, 25, 35]. The oral lesions of PV are usually multiple, typically in the buccal mucosa and soft palate [17, 18]. This disparity may be due to the selected bias due to an author's speciality (periodontist), as the patients may have been presenting for treatment of gingival lesions. Another limitation is that the number of PV cases is limited.

Nearly half (45.9%) of the patients in this study had experienced diagnostic delays longer than 6 months, indicating that early diagnosis of autoimmune bullous diseases in the oral cavity was still difficult. According to the survey of Sirois et al. [19] diagnostic delays greater than 6 months were common in oral PV, but 100% of cutaneous PV patients were correctly diagnosed within 6 months. Mobini et al. [36] reported that the mean period from onset of the disease until diagnosis was 7.57 months in patients with MMP. In this study, diagnosis was delayed more than 1 year for 16.7% of the MMP patients. This may be related to the characteristics of MMP. The initial symptoms of MMP often tend to undergo repeated episodes of onset and remission, and spontaneous remission was also observed in a few MMP patients. Furthermore, obtaining diagnostic biopsies from MMP patients is technically challenging. An inadequate surgical technique or surgical site selection, or improper tissue handling may easily lead to the loss of the gingival epithelium [25, 34, 37]. Four of the patients diagnosed with MMP at the author's clinic were previously biopsied at other facilities, but diagnosis was not rendered. This may be because the intact epithelium was not retained in those specimens. To avoid this problem, the authors reported a stab-and-roll biopsy technique designed to maintain the gingival epithelium for patients with DG [25, 34]. In this technique, more than 90% of biopsies were obtained exhibiting successful retention of intact epithelium, and all biopsies offered diagnostic support [34]. This biopsy technique may facilitate early diagnosis and treatment of diseases causing DG.

To establish a correct diagnosis of DG-associated diseases, conventional microscopic examination and DIF testing are essential. In particular, DIF testing is the gold standard used to diagnose autoimmune bullous diseases and is required for a definitive diagnosis [25, 33, 38]. In this study, all 37 autoimmune bullous diseases showed positive DIF staining. In H&E findings, acantholysis and a suprabasilar separation in the epithelium was observed in all 13 patients with PV. In contrast, a subepithelial separation was observed in 20 patients with MMP (83.3%). Since epithelial acantholysis is quite distinctive, it may be possible that correct diagnosis to be rendered based on H&E findings alone [38]. In contrast, the subepithelial separation, which is a characteristic of MMP patients, is a nondiagnostic finding as it is also found in other vesiculobullous diseases. Therefore, the international expert consensus on MMP does not consider results from conventional microscopic studies as an absolute criterion for the diagnosis [2].

In this study, extraoral lesions were confirmed in 11 of the 37 cases (29.7%) at the time of diagnosis. Since the oral cavity is the site of most problematic lesions, the patients came to

the author's hospital first. Concomitant extraoral lesions were more common in MMP, and the patients tended to be affected in multiple mucosal sites or skin. Multiple target antigens of MMP were identified in BMZ components by the appearance of circulating autoantibodies in the patients' serum [2–5]. Therefore, it is currently believed that MMP is not a single entity but has distinct clinical subsets. For example, some MMP patients have involvement limited to the conjunctiva. They are referred to as having ocular cicatricial pemphigoid [39, 40]. Similarly, Mobini et al. [36] proposed that the MMP lesions confined only to the oral cavity are called "oral pemphigoid." In these clinical subsets, other mucous membranes and/or skin are not involved at long-term follow-up [4, 36, 41]. Di Zenzo et al. [42] pointed out in their review that it is important to know whether the exclusive oral lesion is only a stage of the course of MMP or if it represents the phenotype of a distinct clinical entity. In some long-term studies, MMP patients with exclusively oral lesions show that lesions do not develop in other mucous membranes and/or skin during follow-up [4, 36, 41]. In contrast, other studies indicate that MMP patients with initial oral lesions have a risk of developing ocular involvement with a calculated incidence rate from 0.03 to 0.05 persons per year [28, 29]. Several authorities suggest that early diagnosis of ocular MMP lesions is essential to successful management yet early signs of MMP may not be readily evident to other healthcare workers. Consequently, it may be advisable to refer any MMP patient to an ophthalmologist for immediate and long-term follow-up. Although there is a possibility that the clinical subset of MMP is classified based on the antibody profiles in their serum [3], at present, there is no known correlation between antigen-specific autoantibodies and the prognosis of disease [2].

PV frequently begins with oral lesions and later progresses to skin lesions [19]. Patients with PV with exclusively oral lesions should be followed closely and referred to other experts immediately if they develop signs or symptoms of lesions elsewhere on the body. Although the necessity of systemic therapy is decided with reference to the circulating anti-Dsg antibody titer in some cases, the therapeutic approach to PV is largely based on expert opinion rather than empirical evidence [43–46]. The monitoring of PV disease activity is mainly based on clinical findings at the present moment [43, 45, 46]. In any case, PV limited to oral cavity should be followed for a long period of time and perhaps indefinitely.

5. Conclusion

DG is an early sign of autoimmune bullous diseases such as MMP or PV in the oral cavity. In this study, about 70% of the oral lesions are confined to the gingiva, and DG was the only manifestation of the diseases. To establish a correct diagnosis of DG caused by autoimmune bullous diseases, conventional microscopic examination and DIF testing are essential. In particular, DIF testing is the gold standard used to diagnose of MMP or PV. Since some lesions remain limited to the oral cavity for a long period of time, patients diagnosed with MMP or PV should be closely followed because they must be immediately referred to other experts when they develop lesions on parts of their body other than the oral cavity. The oral healthcare provider should collaborate with other healthcare experts including dermatologists, ophthalmologists, and otolaryngologists to evaluate and manage patients with autoimmune bullous diseases in the oral cavity.

Acknowledgements

This study was supported by a Grant-in-Aid for Young Researcher Scientists, Nihon University School of Dentistry at Matsudo (2015). The authors report no conflicts of interest related to this study.

Author details

Hiroyasu Endo^{1*}, Terry D. Rees², Hideo Niwa³, Kayo Kuyama⁴, Maya Oshima⁵,
Tae Serizawa⁵, Shigeo Tanaka⁵, Morio Iijima⁶, Masamichi Komiya⁵ and Takanori Ito¹

*Address all correspondence to: endo.hiroyasu@nihon-u.ac.jp

1 Department of Oral Diagnosis, School of Dentistry at Matsudo, Nihon University, Japan

2 Department of Periodontics, Texas A&M College of Dentistry, Dallas, TX, USA

3 Department of Head and Neck Surgery, School of Dentistry at Matsudo, Nihon University, Japan

4 Department of Oral Pathology, School of Dentistry at Matsudo, Nihon University, Japan

5 Department of Oral Surgery, School of Dentistry at Matsudo, Nihon University, Japan

6 Department of Removable Prosthodontics, School of Dentistry at Matsudo, Nihon University, Japan

References

- [1] Casiglia J, Woo SB, Ahmed AR. Oral involvement in autoimmune blistering diseases. *Clinics in Dermatology*. 2001;**19**:737-741
- [2] Chan LS, Ahmed AR, Anhalt GJ, et al. The first international consensus on mucous membrane pemphigoid: Definition, diagnostic criteria, pathogenic factors, medical treatment, and prognostic indicators. *Archives of Dermatology*. 2002;**138**:370-379
- [3] Rashid KA, Gurcan HM, Ahmed AR. Antigen specificity in subsets of mucous membrane pemphigoid. *The Journal of Investigative Dermatology*. 2006;**126**:2631-2636. DOI: 10.1038/sj.jid.5700465
- [4] Calabresi V, Carrozzo M, Cozzani E, et al. Oral pemphigoid autoantibodies preferentially target BP180 ectodomain. *Clinical Immunology*. 2007;**122**:207-213. DOI: 10.1016/j.clim.2006.10.007
- [5] Bernard P, Antonicelli F, Bedane C, et al. Prevalence and clinical significance of anti-laminin 332 autoantibodies detected by a novel enzyme-linked immunosorbent assay in

- mucous membrane pemphigoid. *JAMA Dermatology*. 2013;**149**:533-540. DOI: 10.1001/jamadermatol.2013.1434
- [6] Ahmed AR, Hombal SM. Cicatricial pemphigoid. *International Journal of Dermatology*. 1986;**25**:90-96
- [7] Hanson RD, Olsen KD, Rogers RS 3rd. Upper aerodigestive tract manifestations of cicatricial pemphigoid. *The Annals of Otology, Rhinology, and Laryngology* 1988;**97**:493-499
- [8] Lamey PJ, Rees TD, Binnie WH, Rankin KV. Mucous membrane pemphigoid. Treatment experience at two institutions. *Oral Surgery, Oral Medicine, Oral Pathology, and Oral Radiology*. 1992;**74**:50-53
- [9] Endo H, Rees TD, Kuyama K, Kono Y, Yamamoto H. Clinical and diagnostic features of mucous membrane pemphigoid. *The Compendium of Continuing Education in Dentistry*. 2006;**27**:512-516 quiz 517-518
- [10] Endo H, Rees TD, Niwa H, Kuyama K, Yamamoto H, Ito T. Desquamative gingivitis as an oral manifestation of mucous membrane pemphigoid: Diagnosis and treatment. In: Vega JP, editor. *Advances in Dermatology Research*. New York, USA: Nova Science Publishers; 2015. pp. 73-86. ISBN: 978-1-63482-226-8. Available from: https://www.nova-publishers.com/catalog/product_info.php?products_id=54901 Accessed: 2017-09-23
- [11] Amagai M, Klaus-Kovtun V, Stanley JR. Autoantibodies against a novel epithelial cadherin in pemphigus vulgaris, a disease of cell adhesion. *Cell*. 1991;**67**:869-877
- [12] Amagai M, Tsunoda K, Zillikens D, Nagai T, Nishikawa T. The clinical phenotype of pemphigus is defined by the anti-desmoglein autoantibody profile. *Journal of the American Academy of Dermatology*. 1999;**40**:167-170
- [13] Endo H, Rees TD, Matsue M, Kuyama K, Nakadai M, Yamamoto H. Early detection and successful management of oral pemphigus vulgaris: A case report. *Journal of Periodontology*. 2005;**76**:154-160. DOI: 10.1902/jop.2005.76.1.154
- [14] Endo H, Rees TD, Hallmon WW, et al. Disease progression from mucosal to mucocutaneous involvement in a patient with desquamative gingivitis associated with pemphigus vulgaris. *Journal of Periodontology*. 2008;**79**:369-375. DOI: 10.1902/jop.2008.070258
- [15] Amagai M. Autoimmunity against desmosomal cadherins in pemphigus. *Journal of Dermatological Science*. 1999;**20**:92-102
- [16] Chams-Davatchi C, Valikhani M, Daneshpazhooh M, et al. Pemphigus: Analysis of 1209 cases. *International Journal of Dermatology*. 2005;**44**:470-476. DOI: 10.1111/j.1365-4632.2004.02501.x
- [17] Lamey PJ, Rees TD, Binnie WH, Wright JM, Rankin KV, Simpson NB. Oral presentation of pemphigus vulgaris and its response to systemic steroid therapy. *Oral Surgery, Oral Medicine, and Oral Pathology*. 1992;**74**:54-57

- [18] Scully C, Paes De Almeida O, Porter SR, Gilkes JJ. Pemphigus vulgaris: The manifestations and long-term management of 55 patients with oral lesions. *The British Journal of Dermatology*. 1999;**140**:84-89
- [19] Sirois DA, Fatahzadeh M, Roth R, Ettlin D. Diagnostic patterns and delays in pemphigus vulgaris: Experience with 99 patients. *Archives of Dermatology*. 2000;**136**:1569-1570
- [20] Suresh L, Neiders ME. Definitive and differential diagnosis of desquamative gingivitis through direct immunofluorescence studies. *Journal of Periodontology*. 2012;**83**:1270-1278. DOI: 10.1902/jop.2012.110627
- [21] Endo H, Rees TD, Niwa H, et al. Desquamative gingivitis as the initial presentation of autoimmune bullous diseases. In: Karpinski TM, editor. *Health and Diseases of Oral Cavity*. Poznan, Poland: JBooks; 2017. pp. 2-21. DOI: 10.5281/zenodo.918266. Available from: <http://books.tmkarpinski.com/10-Karpinski-2017.pdf> [Accessed: 2017-09-23]
- [22] Rees TD. Vesiculo-ulcerative diseases and periodontal practice. *Journal of Periodontology*. 1995;**66**:747-748
- [23] Endo H, Rees TD. Diagnosis and management of desquamative gingivitis. In: Panagakos FS, Davies RM, editors. *Gingival Diseases—Their Aetiology, Prevention and Treatment*. Rijeka, Croatia: InTech; 2011. pp. 171-188. DOI: 10.5772/22864 Available from: <http://www.intechopen.com/articles/show/title/diagnosis-and-management-of-desquamative-gingivitis> [Accessed: 2017-02-09]
- [24] Endo H, Rees TD, Niwa H, et al. Desquamative gingivitis. In: Manakil JF, editor. *Insights into Various Aspects of Oral Health*. Rijeka, Croatia: InTech; 2017. pp. 3-27. DOI: 10.5772/intechopen.69268. Available from: [Bhttps://www.intechopen.com/books/insights-into-various-aspects-of-oral-health/desquamative-gingivitis](https://www.intechopen.com/books/insights-into-various-aspects-of-oral-health/desquamative-gingivitis) [Accessed: 2017-09-23]
- [25] Rees TD, Burkhart N. Desquamative Gingivitis [Internet]. 2016. Available from: <https://www.dentalcare.com/en-us/professional-education/ce-courses/ce481> [Accessed: 2017-02-09]
- [26] Lo Russo L, Fedele S, Guiglia R, et al. Diagnostic pathways and clinical significance of desquamative gingivitis. *Journal of Periodontology*. 2008;**79**:4-24. DOI: 10.1902/jop.2008.070231
- [27] Mignogna MD, Fortuna G, Leuci S, Ruoppo E, Marasca F, Matarasso S. Nikolsky's sign on the gingival mucosa: A clinical tool for oral health practitioners. *Journal of Periodontology*. 2008;**79**:2241-2246. DOI: 10.1902/jop.2008.080217
- [28] Higgins GT, Allan RB, Hall R, Field EA, Kaye SB. Development of ocular disease in patients with mucous membrane pemphigoid involving the oral mucosa. *The British Journal of Ophthalmology*. 2006;**90**:964-967. DOI: 10.1136/bjo.2006.092528
- [29] Thorne JE, Anhalt GJ, Jabs DA. Mucous membrane pemphigoid and pseudopemphigoid. *Ophthalmology*. 2004;**111**:45-52. DOI: 10.1016/j.opthta.2003.03.001

- [30] Alexandre M, Brette MD, Pascal F, et al. A prospective study of upper aerodigestive tract manifestations of mucous membrane pemphigoid. *Medicine (Baltimore)*. 2006;**85**: 239-252. DOI: 10.1097/01.md.0000231954.08350.52
- [31] Higgins TS, Cohen JC, Sinacori JT. Laryngeal mucous membrane pemphigoid: A systematic review and pooled-data analysis. *The Laryngoscope*. 2010;**120**:529-536. DOI: 10.1002/lary.20763
- [32] Nair PS, Moorthy PK, Yogiragan K. A study of mortality in dermatology. *Indian Journal of Dermatology, Venereology and Leprology*. 2005;**71**:23-25
- [33] Rees TD. Desquamative gingivitis/mucocutaneous diseases commonly affecting the gingiva. In: Harpenau LA, Kao RT, Lundergan WP, Sanz M, editors. *Hall's Critical Decisions in Periodontology and Dental Implantology*. 5th ed. Shelton, Connecticut: People's Medical Publishing House; 2013. pp. 68-73
- [34] Endo H, Rees TD, Allen EP, et al. A stab-and-roll biopsy technique to maintain gingival epithelium for desquamative gingivitis. *Journal of Periodontology*. 2014;**85**:802-809. DOI: 10.1902/jop.2014.130428
- [35] Mignogna MD, Lo Muzio L, Bucci E. Clinical features of gingival pemphigus vulgaris. *Journal of Clinical Periodontology*. 2001;**28**:489-493
- [36] Mobini N, Nagarwalla N, Ahmed AR. Oral pemphigoid. Subset of cicatricial pemphigoid? *Oral Surgery, Oral Medicine, Oral Pathology, Oral Radiology, and Endodontology*. 1998;**85**:37-43
- [37] Sano SM, Quarracino MC, Aguas SC, et al. Sensitivity of direct immunofluorescence in oral diseases. Study of 125 cases. *Medicina Oral, Patología Oral y Cirugía Bucal*. 2008; **13**:E287-E291
- [38] Rinaggio J, Crossland DM, Zeid MY. A determination of the range of oral conditions submitted for microscopic and direct immunofluorescence analysis. *Journal of Periodontology*. 2007;**78**:1904-1910. DOI: 10.1902/jop.2007.070095
- [39] Hoang-Xuan T, Robin H, Demers PE, et al. Pure ocular cicatricial pemphigoid. A distinct immunopathologic subset of cicatricial pemphigoid. *Ophthalmology*. 1999;**106**:355-361
- [40] Chan LS, Yancey KB, Hammerberg C, et al. Immune-mediated subepithelial blistering diseases of mucous membranes. Pure ocular cicatricial pemphigoid is a unique clinical and immunopathological entity distinct from bullous pemphigoid and other subsets identified by antigenic specificity of autoantibodies. *Archives of Dermatology*. 1993; **129**:448-455
- [41] Malik M, Gurcan HM, Christen W, Ahmed AR. Relationship between cancer and oral pemphigoid patients with antibodies to alpha6-integrin. *Journal of Oral Pathology & Medicine*. 2007;**36**:1-5. DOI: 10.1111/j.1600-0714.2006.00483.x
- [42] Di Zenzo G, Carrozzo M, Chan LS. Urban legend series: Mucous membrane pemphigoid. *Oral Diseases*. 2014;**20**:35-54. DOI: 10.1111/odi.12193

- [43] Amagai M, Tanikawa A, Shimizu T, et al. Japanese guidelines for the management of pemphigus. Committee for guidelines for the management of pemphigus disease. The Journal of Dermatology. 2014;**41**:471-486. DOI: 10.1111/1346-8138.12486
- [44] McMillan R, Taylor J, Shephard M, et al. World workshop on oral medicine VI: A systematic review of the treatment of mucocutaneous pemphigus vulgaris. Oral Surgery, Oral Medicine, Oral Pathology, Oral Radiology. 2015;**120**:132-142.e61. DOI: 10.1016/j.oooo.2015.01.022
- [45] Harman KE, Albert S, Black MM. Guidelines for the management of pemphigus vulgaris. The British Journal of Dermatology. 2003;**149**:926-937
- [46] Mimouni D, Nousari CH, Cummins DL, Kouba DJ, David M, Anhalt GJ. Differences and similarities among expert opinions on the diagnosis and treatment of pemphigus vulgaris. Journal of the American Academy of Dermatology. 2003;**49**:1059-1062. DOI: 10.1016/S0190

IntechOpen

