

We are IntechOpen, the world's leading publisher of Open Access books Built by scientists, for scientists

6,900

Open access books available

185,000

International authors and editors

200M

Downloads

Our authors are among the

154

Countries delivered to

TOP 1%

most cited scientists

12.2%

Contributors from top 500 universities



WEB OF SCIENCE™

Selection of our books indexed in the Book Citation Index
in Web of Science™ Core Collection (BKCI)

Interested in publishing with us?
Contact book.department@intechopen.com

Numbers displayed above are based on latest data collected.
For more information visit www.intechopen.com



Biliary Tract Injuries

Marko Zelic, Veronika Lekic, Edo Bazdulj and
Goran Hauser

Additional information is available at the end of the chapter

<http://dx.doi.org/10.5772/intechopen.76328>

Abstract

Injuries of the biliary system are rare. They can broadly be divided into traumatic biliary injuries and iatrogenic biliary injuries. Former are usually part of associated abdominal trauma, blunt or penetrating, and latter are consequence of surgical, endoscopic or invasive radiological diagnostic or therapeutic procedures done in various liver, pancreatic or disorders or the part of upper gastrointestinal system. They occur more commonly than traumatic injuries but still are rare. Those injuries represent important aspect in healthcare system because of their complexity and diversity in management, associated morbidity and mortality and expenditure in healthcare systems. This chapter will put focus on those injuries, including their classification, etiology and mechanism of occurrence, clinical presentation, diagnosis, treatment options, postoperative complications, and, when iatrogenic injuries are concerned, methods for prevention of those injuries.

Keywords: bile duct injuries, blunt abdominal trauma, penetrating abdominal trauma, iatrogenic bile duct injury, biliary leak, biloma, hemobilia, laparoscopic cholecystectomy, open cholecystectomy, endoscopic retrograde cholangiopancreatography (ERCP), magnetic resonance cholangiopancreatography (MRCP), percutaneous transhepatic cholangiography (PTC), hepatobiliary iminodiacetic acid (HIDA), choledohojunostomy, hepaticojunostomy

1. Introduction

Isolated traumatic injuries of the biliary tract are extremely rare. They can be divided into intrahepatic, which can further be arbitrarily subdivided into central or peripheral intrahepatic depending on their location within the liver, and extrahepatic biliary tract injuries which involve right and left hepatic duct, common hepatic duct, common bile duct, cystic

duct and gallbladder. Intrahepatic biliary injuries are invariably associated with liver trauma and should be viewed and managed through that spectrum while extrahepatic biliary injuries can be solitary or, more commonly, also associated with other organ injuries, mainly liver, pancreas and duodenum, in blunt or penetrating abdominal trauma. Injuries can also be combined requiring different approach in diagnosis and treatment. Treatment should be multidisciplinary, involving surgeon, interventional gastroenterologist and interventional radiologist and decisions should be made according to the clinical presentation and concurrent injuries since, to date, there is no treatment algorithm for these injuries.

Iatrogenic biliary injuries are most often caused during laparoscopic cholecystectomy, open cholecystectomy, other surgical procedures involving organs of upper gastrointestinal tract or rarely during other procedures, namely endoscopic retrograde cholangiopancreatography (ERCP) or percutaneous transhepatic cholangiography (PTC). Bile leak is common for all these injuries. Other symptoms and clinical presentation varies greatly depending on the mechanism of injury and associated trauma. Also there are different treatment approaches which are dictated by the symptoms, diagnosis and clinical presentation. In this chapter injuries will be divided in categories mainly for academic purposes because most treatment options are somewhat similar, and secondarily, for early recognition, specificities and treatment modalities since they can overlap and individualized approach is necessary in proper diagnosis and management.

2. Classification

Traumatic injuries to the biliary system can be intrahepatic or extrahepatic. Intrahepatic can be further arbitrarily subdivided into central (those involving the proximal right and left hepatic or segmental ducts within 5 cm of the hepatic duct confluence) and peripheral (those within the hepatic parenchyma more than 5 cm from the hepatic duct confluence) [1]. Extrahepatic biliary injuries are those of right and left hepatic duct, common hepatic duct, common bile duct, cystic duct and gallbladder. They can be isolated, combined or, which is most common, also associated with trauma of other organs, mainly liver, pancreas and duodenum. Since intrahepatic biliary injuries cannot be distinguished from liver parenchyma injuries Organ Injury Scaling (OIS) from American Association for the Surgery of Trauma (AAST) classification of those injuries should be used (**Table 1**) [2]. For extrahepatic injuries AAST extrahepatic biliary tree injury scale should be used (**Table 2**) [3]. Management options should be weighted according this classification system, patient's general condition, and associated trauma.

Classification of iatrogenic biliary tract injuries is more complex and there are numerous classification systems and none of them is commonly accepted. Classification systems are those of Bismuth, Strasberg, Stewart-Way, Siewert, Amsterdam, Lau, Csendes, Neuhaus, Hanover and others. Most widely used are those from Strasberg in which Bismuth classification system is included (type E injuries) and classification from Stewart-Way. Some of them are summarized in tables (**Tables 3–8**). **Table 9** shows all classifications systems by year of their publication. In **Pictures 1** and **2** most used classification systems are depicted.

Grade ^a	Injury description
I Hematoma	Subcapsular, less than 10% of the surface area
Laceration	Tear of the capsule, less than 1 cm parenchymal depth
II Hematoma	Subcapsular, from 10 to 50% surface area; intraparenchymal, less than 10 cm in diameter
Laceration	1–3 cm parenchymal depth, <10 cm in length
III Hematoma	Subcapsular, less than 50% surface area or expanding; ruptured subcapsular or parenchymal hematoma
Laceration	Intraparenchymal hematoma >10 cm or expanding > 3 cm parenchymal depth
IV Laceration	Parenchymal disruption involving from 25 to 75% of hepatic lobe or 1–3 Couinaud's segments within a single lobe
V Laceration	Parenchymal disruption involving more than 75% of hepatic lobe or >3 Couinaud's segments within a single lobe
Vascular	Injuries around veins; i.e., retrohepatic vena cava/central major hepatic veins
VI Vascular	Avulsion of the liver

^aAdvance one grade for multiple injuries, up to grade III.

Table 1. Liver injury scale.

Grade ^a	Injury description
I	Contusion of the gallbladder Contusion of the portal triad
II	Partial gallbladder avulsion from liver bed; cystic duct intact Laceration or perforation of the gallbladder
III	Complete gallbladder avulsion from liver bed Cystic duct laceration/transection
IV	Partial or complete right hepatic duct laceration Partial or complete left hepatic duct laceration Partial common hepatic duct laceration (≤ 50%) Partial common bile duct laceration (≤ 50%)
V	> 50% Transection of common hepatic duct > 50% Transection of common bile duct Combined right and left hepatic duct injuries Intraduodenal or intrapancreatic bile duct injuries

^aAdvance one grade for multiple injuries, up to grade III.

Table 2. Extrahepatic biliary tree injury scale.

Type	Bile duct injury
A	Injuries of the cystic or of the small bile ducts of the liver bed
B	Occlusion of an aberrant hepatic duct, of a part of the biliary tree, most commonly the right aberrant right hepatic duct
C	Sectioning without ligation of an aberrant right hepatic duct
D	Lateral injury of the primary bile duct
E1	Injury of the common hepatic duct more than 2 cm from the confluence
E2	Injury of the common hepatic duct less than 2 cm from the confluence
E3	Injury in the hepatic hilum with preservation of the confluence
E4	Injury in the hilum with involvement of confluence and loss of communication between the right and left hepatic ducts
E5	Injury to an aberrant right sectorial hepatic duct alone or associated with a concomitant injury to the primary hepatic duct

Table 3. Bismuth-Strasberg classification.

Class	Bile duct injury
I	Incision (incomplete transection) of the common bile duct
II	Lateral damage to the common hepatic duct with electrocautery or clip
III	Transection of the common bile duct or common hepatic duct
IV	Injury to or transection of the right hepatic duct or right segmental hepatic duct

Table 4. Stewart-Way classification.

Type	Criteria
A	Cystic duct leaks or leakage from aberrant or peripheral hepatic radicles
B	Major bile duct leaks with or without concomitant biliary strictures
C	Bile duct strictures without bile leakage
D	Complete transection of the duct with or without excision of some portion of the biliary tree

Table 5. Amsterdam classification.

Type	Criteria
1	Leaks from cystic duct stump or small ducts in liver bed
2	Partial CBD/CHD wall injuries without (2A) or with (2B) tissue loss
3	CBD/CHD transection without (3A) or with (3B) tissue loss
4	Rt/Lt hepatic duct or sectorial duct injuries without (4A) or with (4B) tissue loss
5	Bile duct injuries associated with vascular injuries

Table 6. Lau classification.

Type	Criteria
A	Peripheral bile leak (in communication with the common bile duct)
A1	Cystic duct leak
A2	Bile leak from the liver bed
B	Occlusion of the common bile duct (or right or left hepatic duct)
B1	Incomplete
B2	Complete
C	Lateral injury of the common bile duct
C1	Small lesion (< 5 mm)
C2	Extended lesion (> 5 mm)
D	Transection of the common bile duct (or right hepatic duct)
D1	Without structural defect
D2	With structural defect
E	Stenosis of the common bile duct
E1	Short stenosis of the common bile duct (< 5 mm)
E2	Long stenosis of the common bile duct (> 5 mm)
E3	Stenosis at the confluence
E4	Stenosis of the right hepatic duct or segmental duct

Table 7. Neuhaus classification.

Type	Criteria
A	Peripheral bile leak (there is a reconnection to the main bile duct system)
A1	Leak from the cystic duct
A2	Leak of the gallbladder bed
B	Stenosis of the main bile duct, no injury
B1	Incomplete
B2	Complete
C*	Tangential injury of the common bile duct
C1	Small punctiform lesion (< 5 mm)
C2	Extensive lesion (> 5 mm) below hepatic bifurcation
C3	Extensive lesion at the level of the hepatic bifurcation
C4	Extensive lesion above the level of the hepatic bifurcation
D	Complete transection of bile duct
D1	Without defect below the hepatic bifurcation
D2	With defect below the hepatic bifurcation
D3	At hepatic bifurcation level (with or without defect)
D4	Above the hepatic bifurcation level (with or without defect)

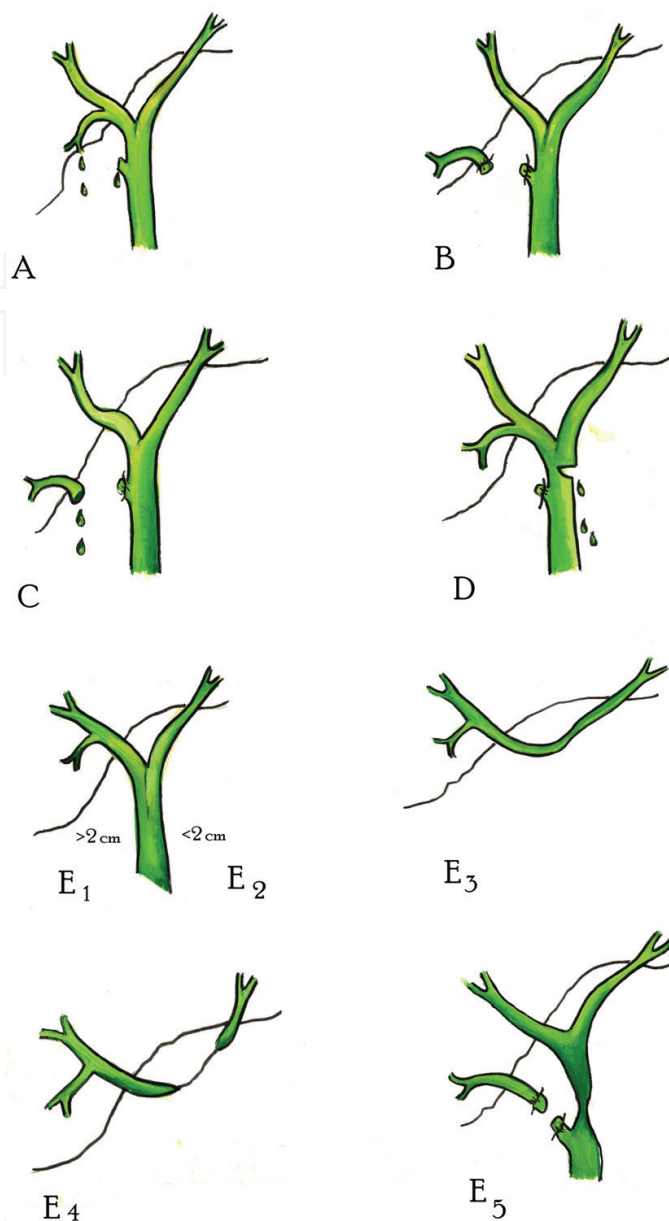
Type	Criteria
E	Strictures of the main bile duct
E1	Main bile duct short circular (< 5 mm)
E2	Main bile duct longitudinal (> 5 mm)
E3	Hepatic bifurcation
E4	Right main bile duct/segmental bile duct
*with vascular lesions (i.e. C1d, C2, etc.): d, right hepatic artery; s, left hepatic artery; p, proper hepatic artery; com, common hepatic artery; c, cystic artery; pv, portal vein.	

Table 8. Hanover classification.

Name	Year
Bismuth classification	1982
Siewert classification	1994
McMahon classification	1995
Strasberg classification	1995
Amsterdam classification	1996
Neuhaus classification	2000
Csendes classification	2001
Stewart-Way classification	2004
Sandha classification	2004
Lau classification	2007
Hannover classification	2007
Kapoor classification	2008
Li classification	2010
Cannon classification	2011
ATOM	2013

Table 9. Classification system based on publication year.

Bismuth classification predates laparoscopic era and it defined the type of stricture based on the anatomic location with respect to the hepatic bifurcation and level at which healthy tissue is available for surgical reconstruction. Strasberg updated this classification because with advent of laparoscopic technique, injuries became more complex. (Current surgical therapy). Some classifications systems, like Hanover, implement concomitant injury of nearby vascular structures. Schematic representation of Bismuth-Strasberg and Stewart-Way classification is given in **Pictures 1** and **2**. In response of myriad of classification systems presented in literature, the European Association for Endoscopic Surgery held a consensus conference on iatrogenic bile duct injury in 2011 with a goal of devising comprehensive system to be used as the

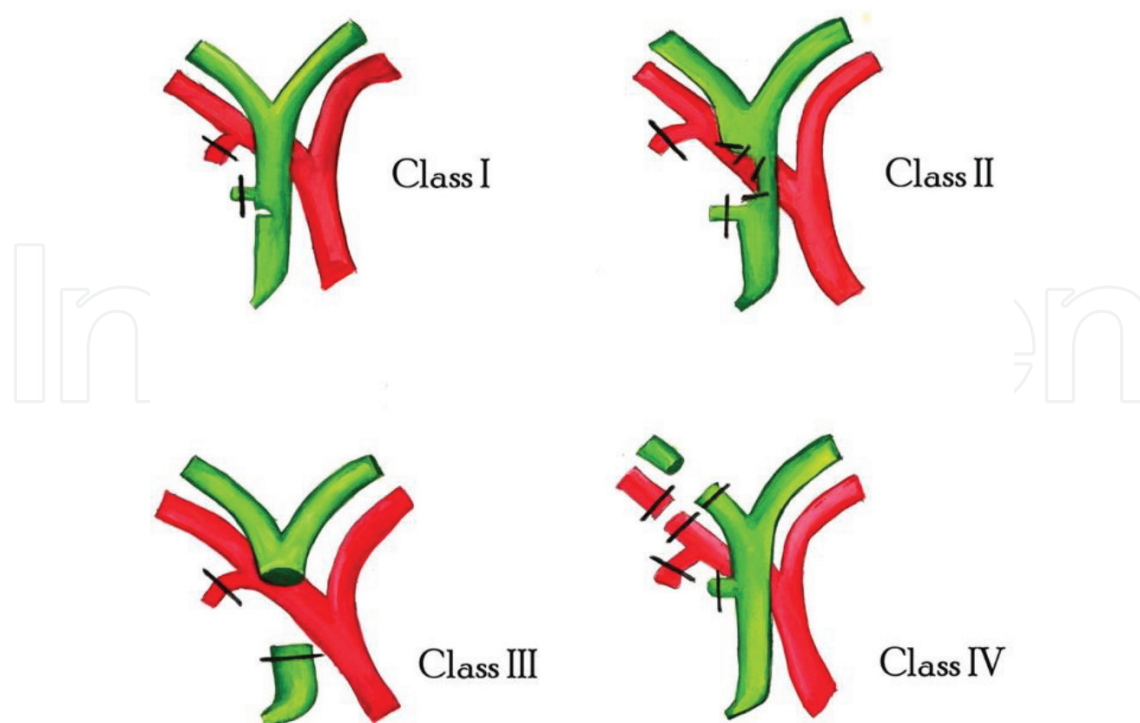


E.L.

Picture 1. Bismuth-Strasberg classification of bile duct injuries. Images are attributed to Emanuela Lekić.

universally accepted classification. The result was organized into three categories: anatomic, time of injury, and mechanism (ATOM) [4].

In the future, it is important to establish universal classification system for traumatic as well as iatrogenic injuries and this classification system has to include the site of injury, the extent of injury, the type of injury and mechanism of injury so it could give the basis for establishing universal treatment options which would then be dependent on the type of the classification. This is obviously hard to accomplish since there are so many classification systems available. ATOM classification can be the right step in establishment of universally accepted classification system which then would form a basis of therapeutic options and algorithms for optimal treatment which are lacking.



Picture 2. Stewart-way classification of bile duct injuries. Images are attributed to Emanuela Lekić.

3. Etiology and mechanism of injuries

Injuries to the liver, biliary tree and pancreas are commonly referred to as the “surgical soul”. They can be deadly and challenging to treat and they demand multidisciplinary approach in establishing correct diagnosis which then will provide best treatment plan, and as a result, have optimal treatment outcome.

Traumatic biliary tract injuries are rare. Intrahepatic injuries occur in association with hepatic injuries in blunt (crushing injuries, direct blow to the abdomen, falls from heights, motor vehicle accidents) or penetrating (stabbing and gunshot wounds) abdominal trauma. Incidence of bile leaks, i.e. biliary injuries in liver trauma is estimated between 4 and 23% [5]. They are suspected upon identification of bile within the peritoneal cavity. Mechanism of blunt injuries is that of acceleration/deceleration. Since liver is intraperitoneal organ which is fixed at certain points in the abdominal cavity (falciform ligament, coronary ligament, left and right triangular ligament) sudden change in movement which happens in these injuries can lead to tear, rupture or avulsion of liver parenchyma and subsequently to the injury of intrahepatic biliary tree. Mechanism of extrahepatic biliary injuries is similar. They occur in 3 to 5% of all abdominal trauma victims, with 85% resulting from penetrating wounds. Of the remaining 15%, resulting from blunt trauma, the vast majority, 85%, involve the gallbladder alone [6]. There are very few reports in the literature of isolated extrahepatic biliary tract injuries. Some report isolated injuries of gallbladder and in literature it is said that gallbladder is the site

of injury in about 85% of cases in isolated extrahepatic biliary tract traumatic injuries. Since gallbladder is anatomically well protected it is postulated that sole injury to the gallbladder in blunt abdominal trauma occurs if the gallbladder is distended prior to injury. It is also thought that thin walled healthy gallbladders are more prone to injury than gallbladders with chronic inflammation with thick wall. Direct blows to the abdomen probable play the major role in its injury. Gallbladder is much more frequently injured in penetrating abdominal trauma. Injuries to the gallbladder can be classified as contusions, avulsions or lacerations as is mentioned in AAST classification system (**Table 2**). Almost all patients with injuries to the gallbladder have associated intra-abdominal injuries, and nearly 50% of patients are hemodynamically unstable on admission [7]. Solitary injuries of the extrahepatic bile ducts are even more rare. Only 125 such cases are found in literature in 1989 review. [8] Mechanism of injury is similar to those in gallbladder injury. Injuries can include right or left hepatic duct, common hepatic duct, cystic duct and common bile duct. Result of an injury can be partial laceration or complete transection of ducts. It is interesting to note when concerning common bile duct injuries that associated injuries to other structures in portal triad (proper hepatic artery and portal vein) does not happen as frequently as common bile duct injury. Probable explanation is that portal vein is valves and hepatic artery tortuotic hence they are less prone to shearing force unlike common bile duct which has points of fixation. Another fact that can be drawn from case reports of those injuries is that very large number of them is situated in most distal

Trauma, mostly abdominal

- blunt trauma
- penetrating trauma

Abdominal surgery

- Cholecystectomy (open or laparoscopic)
- Pancreatobiliary resection
- Biliary reconstruction
- Hepatic resections
- gastric and duodenal surgical procedures

Endoscopic procedures

- ERCP

Percutaneous procedures

- PTC
 - Liver biopsy
 - Stricture dilatation
 - Radiofrequency tumor ablation
 - Embolization
-

Table 10. Etiological factors in biliary injuries, traumatic and iatrogenic.

part of common bile duct, behind the head of the pancreas where common bile duct is fixed. Reports of isolated injuries of right and left hepatic duct are extremely rare. Injuries of cystic duct should be viewed and treated as gallbladder injuries and if there is no other injury treatment after correct preoperative or intraoperative diagnosis is made, is straightforward and it consists of cholecystectomy.

Iatrogenic injuries occur mostly during laparoscopic cholecystectomy. The rate of clinically relevant bile leaks after conventional open cholecystectomy ranges between 0.1 and 0.3%. In contrast, biliary leakages have increased in the era of laparoscopic cholecystectomy by up to 3%. There are multiple factors which can cause those injuries such as inexperience of the surgeon, endoscopist or radiologist, anatomical variations in the region which are common, inflammation of gallbladder and surrounding tissue which is the most usual factor causing error, and as consequence injury to the bile duct. Injuries to the biliary tree, whether traumatic or iatrogenic manifest themselves as bile leak. **Table 10** summarizes etiological factors of injuries of biliary tract.

4. Diagnosis and presentation

Imaging modalities are very important in establishing the diagnosis, delineating the extent of injury and planning appropriate intervention. Those include cholecystigraphy, computed tomography (CT), Ultrasonography (US), magnetic resonance cholangiopancreatography (MRCP), endoscopic retrograde cholangiopancreatography (ERCP), percutaneous transhepatic cholangiography (PTC), hepatobiliary iminodiacetic acid (HIDA scan) and fluoroscopy. Each of these techniques has different advantages and limitations and many patients undergo several imaging studies for diagnostic evaluation. Cholescintigraphy has high accuracy for the detection of bile leaks but it has poor utility in localization of the site of ductal injury. CT and US can depict fluid collections, biliary duct dilatation and associated arterial injuries. CT has higher sensitivity than US for detection of those injuries. Some authors suggest using HIDA scan before CT when bile leak is suspected since CT imaging has inadequate sensitivity for detecting biliary tract disruption [9]. MRCP provides excellent delineation of the biliary anatomy proximal and distal to the level of injury, unlike ERCP and PTC. It can give functional assessment of the biliary tract for detection and localization of bile leaks. ERCP evaluates biliary tract distal to the level of injury and is more invasive than MRCP. Advantage of ERCP is that it allows simultaneous therapeutic interventions such as the placement of biliary stents and drainage catheters which are standard for treating injuries. The main limitation of ERCP is that it does not allow evaluation of the part of the biliary tract proximal to a major duct transection or ligation and its utility is limited after surgical bilioenteric anastomosis. PTC is the method of choice when interventions such as percutaneous transhepatic biliary drainage are indicated. It is superior to ERCP for evaluation of proximal bile duct injuries, common bile duct transection or ligation and transection of the aberrant hepatic ducts.

Intrahepatic biliary injuries can be diagnosed immediately during damage control surgery which should be done for associated liver trauma in hemodynamic unstable patient. In those

patients priority is to stop hemorrhage which is done by liver packing so naturally eventual intrahepatic biliary injuries can be missed. After hemodynamic stability is achieved abdomen is closed. It is important to put a drain near liver, usually in subhepatic or subphrenic space or both. Mortality of patients is dependent on extensiveness of concomitant injuries. If the patient survives initial injury diagnosis of intrahepatic biliary injury will usually be evident by bilious content in abdominal drain placed on initial operation. This diagnosis is apparent. If there is no drainage from abdomen or abdominal drains are not placed or are removed because natural course of disease, biliary injury can be missed. Clinical course can be insidious and delay in diagnosis is not uncommon. Patients usually present with unspecific systemic and local symptoms like abdominal distension, increasing pain, involuntary guarding, nausea, vomiting, elevated body temperature, icterus, acholic stools and bilirubin in urine. Similar symptoms also appear if injury is that of extrahepatic biliary system. High degree of suspicion is necessary in establishing a correct diagnosis in those cases. Treatment options depend on type, location and extent of injury. When iatrogenic injury occurs, it can be spotted intraoperatively or intraprocedural or have late presentation. Late presentation is somewhat similar to traumatic injuries. Course of treatment is largely dependent on timing of establishing the diagnosis.

5. Treatment options

Traumatic biliary tract injuries are not common so there can be a challenge and difficulty in their diagnosis. If they are recognized late and thus, managed inappropriately they can have fatal consequences. The approach to the treatment is dependant primarily on the hemodynamic status of the patient. The principles of operative management in the unstable patient follow the guidelines of damage control surgery [10]. Following blunt hepatic trauma, biliary complications have been reported in 2.8 to 7.4% of patients [11].

Depending on the type of injury, treatment of these injuries in hemodynamically stable patient can be endoscopic, percutaneous or surgical. It is important to note that percutaneous and endoscopic interventions may be performed as definitive treatment or as an adjunct to definitive surgical repair. Optimal treatment is achieved with a multidisciplinary approach. The right treatment option depends on establishment of correct diagnosis (type of injury, its extensiveness and its anatomical site). Also, there is an importance in timing of the diagnosis. As mentioned above some biliary tract injuries can go unnoticed and manifest themselves days, months or even years later. Main sign of biliary tract injuries is bile leakage. It can be classified as minor or major. Major biliary leaks are those draining >400 mL/day or persistent drainage >14 days [12]. Importance of this classifications lays in fact that minor bile leaks can be treated conservatively with drainage only while major bile leaks require more aggressive treatment (usually ERCP with stent placement and sphincterotomy).

Initial management of bile duct injuries focuses on stabilizing the patient's status after which bilomas should be drained and visualization of the injury with cholangiography should be

obtained. Collections which are suspected to be bilomas should be promptly drained because of the risk of development of complications such re sepsis, cholangitis or abscess formation if drainage is not done. If there is complete ligation of the ducts or their transection PTC is usually required for placement of drains which achieves biliary decompression and diversion. Complications of percutaneous biliary interventions can be classified as major or minor [13]. They are shown in **Table 11**.

Advantage of ERCP is that it is as diagnostic also a therapeutic tool. Most biliary leaks, if the injury is not complete transection of common bile duct or hepatic duct, can be treated successfully with ERCP. Treatment consists of putting biliary stent with or without sphincterotomy (there are contrary reports in literature whether sphincterotomy is necessary). The goal of the treatment is establishment of biliary decompression and biliary drainage to the upper digestive system. Stent can then be removed in following ERCP procedure. Timing of removal is also matter of controversy and most authors suggest removal of stent 3 to 8 weeks after placement. Some even suggest prolonged time for stent removal explaining that this can reduce formation of stricture formation which is usual complication of biliary tract injuries. Treatment of the injuries of the gallbladder is cholecystectomy, independent of mechanism of injury. Exception is when the first operative procedure is of damage control type. In those situations cholecystostomy can be made for biliary drainage and cholecystectomy should be done in second operation after achieving hemodynamic stability of the patient and after treatment of life threatening concomitant injuries.

Surgical therapy consists mainly on Roux-en-Y hepaticojejunostomy [14]. Available data suggests that these injuries, if surgical therapy is mandated, it should be managed by a hepatobiliary surgeon with extensive expertise in biliary reconstructions as outcomes

Major complications
<ul style="list-style-type: none">• Sepsis• Cholangitis• Bile leakage• Major venous and arterial hemobilia• Hemoperitoneum and subcapsular liver hematoma• Pleural complications (pneumothorax, hemothorax, bilous effusion)• Death
Minor complications
<ul style="list-style-type: none">• Pain• Minor bleeding• Bacteremia• Transient hyperamylasemia

Table 11. Complications of Percutaneous Biliary interventions.

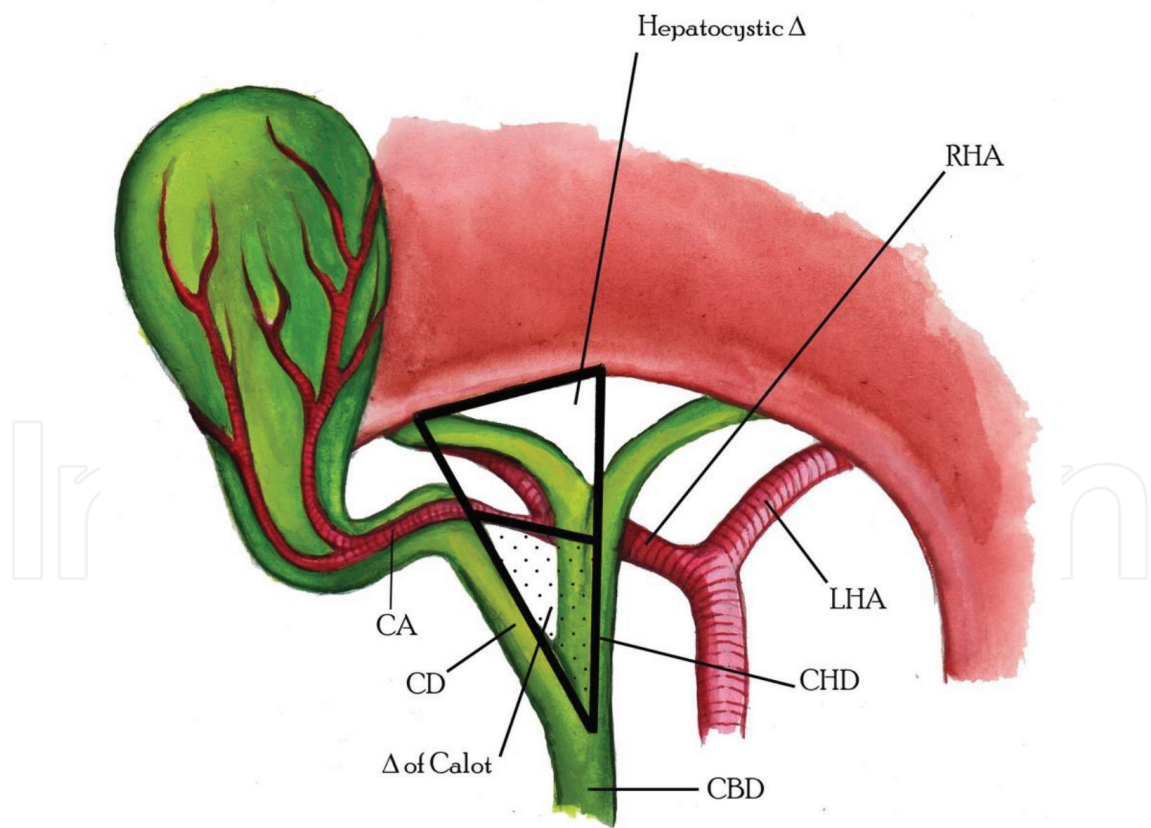
can be excellent. Because of the fact that management of these injuries often requires an experienced multidisciplinary team, they are best handled in tertiary referral center. If immediate repair is possible by an experienced surgeon, even a completely transected bile duct can be primarily reconstructed as an end-to-end ductal anastomosis by employing simple interrupted absorbable monofilament sutures. Several conditions must be met for this to succeed: the anastomosed edges should be healthy, there should be no inflammation, ischemia or fibrosis, and the anastomosis should be tension-free and properly vascularized [15]. Refreshing the proximal and distal stumps as far as the tissues are healthy and without inflammations should be performed. End-to-end ductal anastomosis can be recommended for patients when the maximal loss of length of the bile duct is 4 cm. Approximation of both ends is possible by means of a wide Kocher maneuver. The need of insertion of T-tube after such reconstruction is controversial. In the setting where a two-step approach has to be undertaken because either the injury was not identified at initial surgery or an experienced surgeon was not available, the goal of surgical repair should be the establishment of a tension-free, mucosa-to-mucosa duct enteric anastomosis, which in the majority of the cases will be an end-to-side Roux-en-Y choledochojejunostomy or, more commonly, a Roux-en-Y hepaticojejunostomy. In the cases of strictures involving the bifurcation or left or right hepatic ducts, bilateral hepaticojejunostomy may be necessary [16]. Isolated injuries to the right or left hepatic ducts could be treated by simple ligation if the primary repair is impossible or biliodigestive anastomosis is not feasible because of hemodynamic instability of the patient [17]. Nonoperative management of bile duct injury, if there are no complete transections of bile duct, is effective with success rate ranging from 90 to 94% [18]. In summary, the key to successful treatment of iatrogenic bile duct injuries is early recognition, control of intraabdominal bile ascites and inflammation, nutritional repletion, and repair by a surgeon with expertise in biliary reconstruction. If these requirements are met, patients can have successful repair with long-term success in more than 90% of cases [19]. Traumatic biliary injury is a rare but important consequence of abdominal trauma, and good outcomes are possible when a major trauma center and hepatopancreaticobiliary service is present. Cholecystectomy is the gold standard for treatment of gallbladder injuries. Drainage with or without stenting will resolve majority of intrahepatic and partial biliary injuries. Hepaticojejunostomy is the gold standard for complete extrahepatic biliary disruption [20]. Regardless of the type of biliary injuries management, wide drainage is essential [21].

6. Prevention of iatrogenic biliary tract injuries

Cholecystectomy is one of the most frequent surgeries done in the world. Since the rise of laparoscopy most of these procedures are done laparoscopically. The consequence of laparoscopic cholecystectomy is increase in the incidence of iatrogenic injuries to the extrahepatic biliary tract. This is the reason why it is important to establish measures to decrease the incidence of these injuries. There are many proposals in literature how to accomplish

that, form education in laparoscopy to anatomical landmarks which can guide the surgeon during procedure and changing the surgical technique itself. There is great emphasis on identifying the structures in, so called, Calot triangle [22], and hepatocystic triangle, **Picture 3**, which is bordered by liver surface, common hepatic duct and cystic duct. It should be always identified during laparoscopic cholecystectomy. Misidentification of the bile ducts is the leading cause of biliary injury. To avoid this, the “critical view of safety” technique should be employed with utmost care. Inexperienced surgeons should be cautious about using the single-incision technique, as this may increase the risk of biliary injury in difficult cases. If biliary injury is identified intraoperatively, reconstruction should only be undertaken by experienced hepatobiliary surgeons. In the postoperative period, any deviation from the expected clinical course of recovery should alert the surgeon to suspect biliary injury and take a proactive approach to diagnosis and proper management [23].

In order to decrease the chance of biliary injury a group of authors formed Delphi consensus [24] which outlined factors and proposed actions during surgical procedure in order to minimize and decrease the incidence of iatrogenic lesions. Those are summarized in **Table 12**.



Picture 3. Hepatocystic triangle and triangle of Calot. Images are attributed to Emanuela Lekić.

When to stop

- Extensive and dense adhesion to surrounding organs and/or greater momentum
- Impacted gallstone in the confluence of the cystic, common hepatic, and common bile duct (included in the expanded classification of Mirizzi syndrome)
- Severe fibrosis and scarring in Calot's triangle due to inflammation
- Severe fibrosis and scarring in gallbladder bed due to inflammation (includes sclero-atrophic gallbladder)
- Anomalous bile duct
- Extensive operative time
- Extensive blood loss

Where to stop

- Rouviere's sulcus
- Sentinel lymph node (cystic lymph node of Lund)
- Base of segment IV (hilar plate)
- Calot's triangle area
- Infundibulum-cystic duct junction (so-called elephant trunk sign)
- Sclero-atrophic gallbladder (so-called hump sign)
- Critical view of safety
- SS inner layer

How to prevent

- Decompression of a distended gallbladder with needle aspiration
- Effective retraction of the gallbladder to develop a plane in the Calot's triangle area and identify its boundaries (countertraction)
- Starting dissection from the posterior leaf of the peritoneum covering the neck of the gallbladder and exposing the SS inner layer above Rouviere's sulcus
- Maintaining the plane of dissection within the SS layer (i.e. exposing the SS inner layer) throughout laparoscopic cholecystectomy
- Dissection the lower part of the gallbladder bed (at least one-third) to obtain the critical view of safety
- Always obtaining the critical view of safety
- For persistent hemorrhage, achieving hemostasis primarily by compression and avoiding extensive use of electrocautery or clipping
- Intraoperative cholangiography
- Intraoperative ultrasound
- Intraoperative indocyanine green fluorescent imaging

What are the alternatives

- Open conversion
 - Fundus-first (dome-down)
 - Subtotal (partial) cholecystectomy
 - Cholecystectomy (drainage only)
-

Table 12. Summarized key results in Delphi consensus on avoidance of biliary duct injuries.

7. Postoperative management and complications

Patients with injuries of biliary tract, after successful initial management can have complications which can be serious in nature. Most common complication following the management of these injuries is development of biliary stenosis if the primary repair was done for incomplete rupture of ducts and after removal of previously placed stent or complication can be in the formation of chronic biliary fistula. Strictures can also develop after hepaticojejunostomy. Cholangitis is also frequently described complication. These complications must be discussed with the patient and the patient must be informed of possible occurrence of symptoms of these complications (jaundice, abdominal pain, fever, malaise, nausea, vomiting) before discharge after management of initial trauma and injury. Chronic strictures can be managed by dilatation with either an endoscopic or percutaneous approach [25]. Surgical approach, revision and repair may be needed in patients with unsuccessful endoscopic or percutaneous treatment. Biliary fistulas may develop if primary repair was incomplete, if there is prolonged external drainage through T tube or drain site and if the injuries are missed. For fistulas that do not close, surgical intervention by an experienced biliary surgeon may be required. Postoperative follow up is not required. Repeated imaging diagnostic (CT, ERCP or other) should be based on patient's symptoms and laboratory findings. Recent data shows that there is no significant difference in health related quality of life in long-term follow up after successful repair of biliary tract injuries [26].

8. Conclusion

Biliary tract injuries, whether they are traumatic or iatrogenic, are rare and literature coverage of the subject is scarce in reporting traumatic injuries. Intrahepatic biliary injuries are always associated with liver trauma. Acute treatment options are focused on achieving hemodynamic stability if the patient is unstable due to hemorrhage from liver trauma so missed initial diagnosis of intrahepatic biliary injuries is not uncommon. Those patients usually have abdominal drains placed and diagnosis of such injury is suspected by contents of abdominal secretion from drain. Delayed diagnosis of intrahepatic biliary injuries is very frequent, mainly because symptoms are unspecific and with gradual onset. High index of suspicion is necessary for that diagnosis. Patients usually present with nausea, vomiting, icterus, acholic stools and with bile in urine. Abdominal distension and gradual increase in involuntary guarding and muscle rigidity is common. Treatment plan is molded depending on correct diagnostics. It is important to identify a site of biliary leakage and its dynamic and, based on those information's, plan treatment options accordingly. Main complications of intrahepatic biliary tract injuries are hemobilia and biloma formation. In most cases simple drainage (preferably percutaneous) is suffice. Natural history of bile duct injuries is spontaneous closure within 3 weeks if the biliary drainage is maintained. Conservative management of those injuries is safe option if the abdominal cavity is drained and remains afebrile.

Extrahepatic biliary tract trauma as a solitary entity is extremely rare. Injuries of the extrahepatic biliary tree are usually accompanied with injuries to the adjacent organs, i.e., liver, duodenum, pancreas. Solitary extrahepatic biliary traumatic injury is reported mostly as case reports and selected reviews of those reports in literature. It is usually result of a blunt abdominal trauma. As with intrahepatic lesions which are missed during initial patient workup because of concomitant trauma, extrahepatic biliary injuries are often missed. After initial shock from trauma recovery ensues and after initial quiet period symptoms usually arises third to tenth post injury day. They are similar as those described above in intrahepatic injuries since the pathophysiological mechanism behind symptomatology is the same. It is important to emphasize the achievement of correct diagnosis since the treatment options, which can be more or less aggressive (surgical, endoscopic, percutaneous) larger if not solely are dependent on establishing the correct diagnosis, meaning correct site of injury, extent of injury and associated injuries. Treatment options are ERCP with stent placement with or without sphincterotomy, percutaneous transhepatic biliary drainage, transabdominal biliary drainage or surgical approaches which usually consist of Roux n Y bilioenteric anastomosis or primary repair. All treatment options have the same goal: decompression of bile flow and establishment of biliary drainage into digestive system.

Iatrogenic biliary tract injuries are consequence of surgical, endoscopic or percutaneous techniques on biliary tract or adjacent organs. There is an increase in incidence of those injuries with advent of laparoscopic procedures comparing to open surgery. Vast majority of those injuries are consequence of laparoscopic cholecystectomy. Most important aspect of those injuries is early (intraoperative, intraprocedural) recognition. Delayed presentation resembles the injuries of traumatic nature with late recognition. Management plans is largely dependent on type of injury and correct diagnosis. Most widely used technique is hepaticojejunal Roux-en-Y anastomosis. Prevention of iatrogenic injuries is important and literature reports numerous recommendations to avoid such injuries during procedures. One of the most important is Delphi consensus.

Author details

Marko Zelic^{1*}, Veronika Lekic¹, Edo Bazdulj² and Goran Hauser³

*Address all correspondence to: marko.zelic@uniri.hr

1 Departement of Abdominal Surgery, Abdominal Surgery Resident, University Hospital Rijeka, Croatia

2 Departement of Abdominal Surgery, Abdominal Surgeon, University Hospital Rijeka, Croatia

3 Departement of Gastroenterology, Gastroenterologist, University Hospital Rijeka, Croatia

References

- [1] Burmeister S et al. Endoscopic treatment of persistent thoracobiliary fistulae after penetrating liver trauma. *HPB: The Official Journal of the International Hepato Pancreato Biliary Association*. 2009 Mar;**11**(2):171-175
- [2] Moore EE et al. Organ injury scaling: Spleen and liver (1994 revision). *The Journal of Trauma*. 1995 Mar;**38**(3):323-324
- [3] Moore EE et al. Organ injury scaling. VI: Extrahepatic biliary, esophagus, stomach, vulva, vagina, uterus (nonpregnant), uterus (pregnant), fallopian tube, and ovary. *The Journal of Trauma*. 1995 Dec;**39**(6):1069-1070
- [4] Fingerhut A et al. ATOM, the all-inclusive, nominal EAES classification of bile duct injuries during cholecystectomy. *Journal of Physical Chemistry Letters*. 2013 Jun 6;**4**(11):1933-1942
- [5] Cogbill TH et al. Severe hepatic trauma: A multi-center experience with 1,335 liver injuries. *The Journal of Trauma*. 1988 Oct;**28**(10):1433-1438
- [6] Ivatury RR et al. The morbidity of injuries of the extra-hepatic biliary system. *The Journal of Trauma*. 1985 Oct;**25**(10):967-973
- [7] Ball CG et al. A decade of experience with injuries to the gallbladder. *Journal of Trauma Management and Outcomes*. 2010 Apr 15;**4**:3
- [8] Bourque MD et al. Isolated complete transection of common bile duct due to blunt trauma in a child, and review of the literature. *Journal of Pediatric Surgery*. 1989 Oct;**24**(10):1968-1970
- [9] Kulayat AN et al. Traumatic bile leaks from blunt liver injury in children: A multidisciplinary and minimally invasive approach to management. *Journal of Pediatric Surgery*. 2014 Mar;**49**(3):424-427
- [10] Balzarotti R et al. Isolated extrahepatic bile duct rupture: A rare consequence of blunt abdominal trauma. Case report and review of the literature. *World Journal of Emergency Surgery*. 2012 May 24;**7**(1):16
- [11] Bala M et al. Complications of high grade liver injuries: Management and outcome with focus on bile leaks. *Scandinavian Journal of Trauma, Resuscitation and Emergency Medicine*. 2012 Mar 23;**20**:20
- [12] Hommes M et al. Management of biliary complications in 412 patients with liver injuries. *Journal of Trauma and Acute Care Surgery*. 2014 Sep;**77**(3):448-451
- [13] Thompson CM et al. Management of iatrogenic bile duct injuries: Role of the interventional radiologist. *Radiographics*. 2013 Jan-Feb;**33**(1):117-134
- [14] Renz BW et al. Bile duct injury after Cholecystectomy: Surgical therapy. *Visceral Medicine*. 2017 Jun;**33**(3):184-190

- [15] Jablonska B. End-to-end ductal anastomosis in biliary reconstruction: Indications and limitations. *Canadian Journal of Surgery*. 2014 Aug;**57**(4):271-277
- [16] Karanikas M et al. Biliary tract injuries after lap cholecystectomy-types, surgical interventions and timing. *Annals of Translational Medicine*. 2016 May;**4**(9):163
- [17] Howdieshell TR et al. Management of blunt hepatic transection by ligation. *Southern Medical Journal*. 1990 May;**83**(5):579-583
- [18] Spinn MP et al. Successful endoscopic therapy of traumatic bile leaks. *Case Reports in Gastroenterology*. 2013 Jan;**7**(1):56-62
- [19] Stewart L. Iatrogenic biliary injuries: Identification, classification, and management. *Surgics Clinics of North America*. 2014 Apr;**94**(2):297-310
- [20] Thomson BN et al. Management of blunt and penetrating biliary tract trauma. *Journal of Trauma and Acute Care Surgery*. 2012 Jun;**72**(6):1620-1625
- [21] Palmer Schecter W et al. Injuries to the liver and biliary tract. In: Blumgart's Surgery of the Liver, Biliary Tract and Pancreas. 6th ed. Amsterdam, Netherlands: Elsevier Inc.; Chapter 122. 2017:1889-1897
- [22] Abdalla S et al. Calot's triangle. *Clinical Anatomy*. 2013 May;**26**(4):493-501
- [23] Abbasoglu O et al. Prevention and acute management of biliary injuries during laparoscopic cholecystectomy: Expert consensus statement. *Ulus Cerrahi Derg*. 2016 Dec 1; **32**(4):300-305
- [24] Iwashita Y et al. Delphi consensus on bile duct injuries during laparoscopic cholecystectomy: An evolutionary cul-de-sac or the bith pangs of a new technical framework? *Journal of Hepato-Biliary-Pancreatic Sciences*. 2017 Nov;**24**(11):591-602
- [25] Costamagna G et al. Long-term results of endoscopic management of postoperative bile duct strictures with increasing numbers of stents. *Gastrointestinal Endoscopy*. 2001 Aug;**54**(2):162-168
- [26] Ejaz A et al. Long-term health-related quality of life after iatrogenic bile duct injury repair. *Journal of the American College of Surgeons*. 2014 Nov;**219**(5):923-932 e10

