

# We are IntechOpen, the world's leading publisher of Open Access books Built by scientists, for scientists

6,900

Open access books available

186,000

International authors and editors

200M

Downloads

Our authors are among the

154

Countries delivered to

TOP 1%

most cited scientists

12.2%

Contributors from top 500 universities



WEB OF SCIENCE™

Selection of our books indexed in the Book Citation Index  
in Web of Science™ Core Collection (BKCI)

Interested in publishing with us?  
Contact [book.department@intechopen.com](mailto:book.department@intechopen.com)

Numbers displayed above are based on latest data collected.  
For more information visit [www.intechopen.com](http://www.intechopen.com)



---

# Robotic Hysterectomy for Cancer and Benign Pathology

---

Adrian Kohut, Leah Goldberg and  
Alexandre Buckley De Meritens

Additional information is available at the end of the chapter

<http://dx.doi.org/10.5772/intechopen.76466>

---

## Abstract

The da Vinci Surgical System is an innovative technology that has advanced the laparoscopic treatment of benign and malignant diseases in gynecology. In this chapter, we will discuss the da Vinci Surgical System technology, including its history, utilization, surgical technique for benign and oncologic hysterectomy, future directions and surgical complications. Through a review of the literature, we aim to chronicle the current trends of application in both benign and oncologic gynecologic conditions and describe the current standards of care in this innovative and evolving operative technology. Although the future utility of robotic surgeries and robotic hysterectomies necessitates further research, the potential application of this surgical method affords great promise.

**Keywords:** robotic hysterectomy, gynecologic oncology, benign gynecologic surgery

---

## 1. History

The initial da Vinci robotic surgical system (Intuitive Surgical, Sunnyvale, CA) was released in Europe in 1999 and received FDA approval in 2000 [1]. In 2005, the FDA approved the da Vinci robotic system for gynecological surgeries. The first system consisted of two robotic operating arms and one camera holder. Since its emergence in the surgical arena, there have been four updates to the system, each of which has increased its overall capability within various surgical subspecialties and overall maneuverability of instrument use. The latest version termed the da Vinci Xi was released in 2014 and includes 3D HD vision, four quadrant mounting, and instruments capable of moving in seven degrees of motion while performing complex surgical techniques including clamping, cutting, coagulating, dissecting, suturing and manipulating tissue [2].

---

In 2002, Diaz-Arrastia et al. published a series of 11 patients undergoing uncomplicated da Vinci assisted total laparoscopic hysterectomy and bilateral salpingo-oophorectomy demonstrating feasibility for its use in gynecologic surgery [3]. Subsequently, Lambaudie et al. published a report of 28 patients undergoing various da Vinci assisted surgical procedures for gynecologic cancer including total hysterectomy, bilateral oophorectomy, and pelvic and/or para-aortic lymphadenectomy. The authors found that the use of robot-assisted laparoscopy led to less intraoperative blood loss, less postoperative pain and shorter hospital stays compared with those treated with more traditional surgical approaches such as laparoscopy and laparotomy [4]. The following year the FDA approved the use of the da Vinci robotic system for use in gynecologic oncology surgery.

## 2. Introduction

Over the past 12 years, the da Vinci assisted approach to laparoscopic hysterectomy has taken a more prominent role in the surgical management of a multitude of benign and oncologic gynecologic conditions. Multiple meta-analyses and literature reviews have shown that the use of robotic surgery offers the advantage of decreased blood loss and length of stay when compared to open surgical techniques [5]. When compared to traditional laparoscopic methods outcomes appear to be equivocal, but a case can be made for the advantages of robotic surgery to treat obese patients [6]. The main disadvantages of robotic gynecologic surgery include increased intraoperative time and cost-effectiveness questionability. Such issues may be mitigated as operator proficiency increases. Future projections of advancement in robotic gynecologic surgery highlight the use of minimal incisions and single site approaches [7].

Hysterectomy is one of the most frequently performed surgical procedures in the United States. Common benign indications include symptomatic uterine leiomyomas (51.4%), abnormal uterine bleeding (41.7%), endometriosis (30%), and prolapse (18.2%) [8, 9].

The American College of Obstetricians and Gynecologists favors vaginal hysterectomy as the preferred method among women undergoing hysterectomy for benign disease [10]. A 2015 Cochrane Database Systematic Review indicated that vaginal hysterectomy appears to be superior to both laparoscopic hysterectomy and abdominal hysterectomy as it is associated with faster return to normal activities [11]. However, in cases involving factors such as adnexal pathology, severe endometriosis, adhesions, or an enlarged uterus, vaginal hysterectomy may not be appropriate [10]. Compared to abdominal hysterectomy, laparoscopic hysterectomy is associated with decreased risk of perioperative complications, faster return to normal activity, decreased length of hospital stay, decreased risk of readmission, decreased risk of surgical site infection, decreased blood loss and need for blood transfusion, and improved postoperative quality of life [11]. Though current evidence demonstrates a less significant difference between robot-assisted laparoscopic hysterectomy and conventional laparoscopic hysterectomy, potential benefits of the robotic-assisted approach include decreased complication rate, decreased length of hospital stay, decreased blood loss and need for blood transfusion, and decreased risk of conversion to exploratory laparotomy for surgically complicated cases and obese patients [9, 12–19]. With an increasing number of both academic institutions

and community hospitals offering robotic surgery, there is a national uptrend in rates of the robotic-assisted approach. Of all benign hysterectomies, robotic-assisted surgery increased from 0.5% in 2007 to 9.5% in 2010 [9, 13, 18, 20–27].

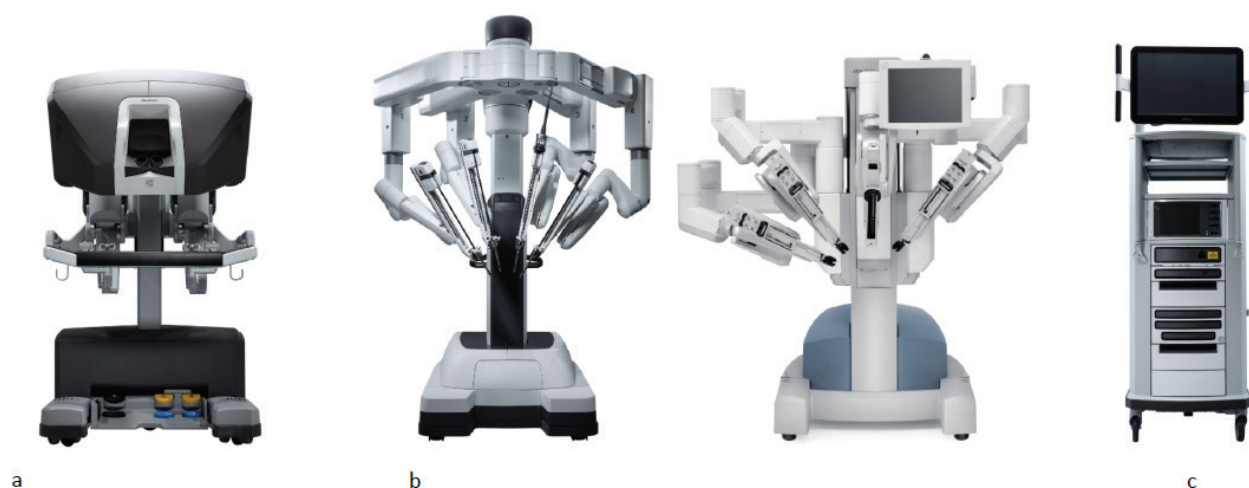
In the context of gynecologic oncology, common indications for hysterectomy include cancers of the endometrium, cervix, ovary or fallopian tube. The 2017 NCCN Clinical Practice Guidelines in Oncology for Uterine Neoplasm state that “Minimally invasive hysterectomy is now the preferred approach when technically feasible” [28]. The randomized controlled trial LAP2 showed short-term surgical benefits of laparoscopy over laparotomy for uterine cancer staging, and follow-up data showed equivalent oncologic outcomes [29]. In the case of cervical cancer, even though we do not have phase III data supporting the use of minimally invasive surgery, there is a body of literature demonstrating feasibility and suggesting equivalent oncologic outcomes compared to abdominal hysterectomy [30–32].

Robotic surgery has taken center stage in becoming the standard of care in patients with early-stage endometrial and cervical cancer. When comparing robotic-assisted surgery with conventional laparoscopy for endometrial cancer, robotic surgery has been found to have decreased length of stay, reduced operating time, decreased blood loss, and more rapid post-surgical recovery [6]. Furthermore, robotic surgery has even been shown to result in high lymph node count as compared to conventional laparoscopy when performed in obese women with endometrial cancer [33]. In comparing robot-assisted surgery with abdominal surgery for endometrial cancer, robotic surgery is associated with decreased blood loss, reduced length of stay, increased operation duration, and equal number of lymph node counts [20, 34–40]. In analyzing total cost of care for endometrial cancer patients, robotic surgery has been shown to be significantly cheaper (\$8212.00 versus \$12,943.60,  $P = .001$ ) due to its association with a decreased length of stay [20, 34, 41]. In patients with early cervical cancer, robotic-assisted and conventional laparoscopic radical hysterectomy have both been shown to be superior to exploratory laparotomy due to decreased blood loss, decreased complication rates, reduced the length of stay, and increased lymph node count. In such patients, there is conflicting data showing the advantage of the robotic approach over conventional laparoscopy [36, 42–58]. There is currently limited data on the use of robotics in the setting of advanced ovarian cancer, and thus its use is not recommended at this time [3, 4, 59–63].

In this chapter, we will describe the technology behind the robotic-assisted surgery, patient preparation, surgical technique for simple and radical hysterectomy and complications.

### 3. The technology

Robot-assisted laparoscopy is an innovative advancement in gynecologic laparoscopic surgery. The robotic approach enhances traditional laparoscopy by providing three-dimensional optics, advanced ergonomics, improved vision and precision, tremor filtration, and 7° of motion with advanced dexterity [2]. There are currently four generations of the da Vinci Surgical System: The “standard”, the S, the Si, the X and the Xi system. The components of the da Vinci Surgical System include the surgeon console, the patient side cart, and the vision system [2] (**Figure 1**).



**Figure 1.** (a) Surgeons console; (b) patients side-cart; and (c) vision tower.

The surgeon operates seated at the console while viewing a 3D high-definition image inside the patient's body. The surgeon's fingers grasp the master controls below the display which converts the surgeon's hand, wrist and finger movements into precise, simultaneous movements of surgical instruments [2].

The patient-side cart is where the patient is positioned during surgery. Attached to the side cart are four robotic arms that facilitate the surgeon's commands by moving around fixed pivot points which allow for less force on the abdominal wall than laparoscopy [2]. The vision system is equipped with a 3D, high-definition endoscope and image processing equipment for visualization of the patient's anatomy [2]. A view of the operating field is available to the entire OR team on a large viewing monitor (vision cart) [2].

A full range of EndoWrist instruments (Intuitive Surgical, Sunnyvale, CA) is available to the surgeon while operating. Most instruments are modeled after the human wrist, offering a greater range of motion than the human hand. Each instrument is designed for a particular task, such as clamping, cutting, coagulating, dissecting, suturing and manipulating tissue. EndoWrist Instruments feature 7° of freedom, 90° of articulation, natural motion and fingertip control, motion scaling and tremor reduction [2]. Energy instruments include da Vinci monopolar and bipolar cautery instruments (electrical energy), the da Vinci Harmonic™ ACE (mechanical energy), the da Vinci PK™ Dissecting Forceps (advanced bipolar), and laser [2]. Grasping instruments allow handling thin, delicate tissues as well as thicker and stronger tissues. Needle drivers provide the ability to suture with fine and thick needles. SutureCut™ Needle Drivers include a cutting blade for efficient cutting of suture after knot tying [2].

## 4. Indications

Robotic hysterectomy may be employed for a wide spectrum of benign pathologies including leiomyoma, abnormal uterine bleeding, endometriosis, adenomyosis, adnexal mass, pelvic



pain, and pelvic organ prolapse. Common malignant pathologies necessitating hysterectomy include primary cancers of the uterus, ovary, cervix, fallopian tubes, and peritoneum; as well as nongynecologic metastases of urologic, colorectal, breast, gastrointestinal, renal, pulmonary, melanomatous, or lymphatic origin.

## 5. Technique

After induction of general endotracheal anesthesia and insertion of an orogastric tube, the patient is placed in dorsal lithotomy position using yellowfin stirrups with careful padding of pressure points. Both arms are padded and tucked to the sides. The patient is placed in steep Trendelenburg position (27–30°) to allow mobilization of the small bowel out the pelvic area and exposing the aorta if in need to perform lymph node dissection. She is prepped and draped in the standard sterile fashion. Foley catheter is inserted, and a uterine manipulator such as a V-care manipulator (ConMed Endosurgery, Utica, NY) or the Advincula Arch uterine manipulator (Cooper Surgical, Trumbull, CT) is placed. The uterine manipulator allows demarcation of the cervicovaginal junction necessary to perform the colpotomy.

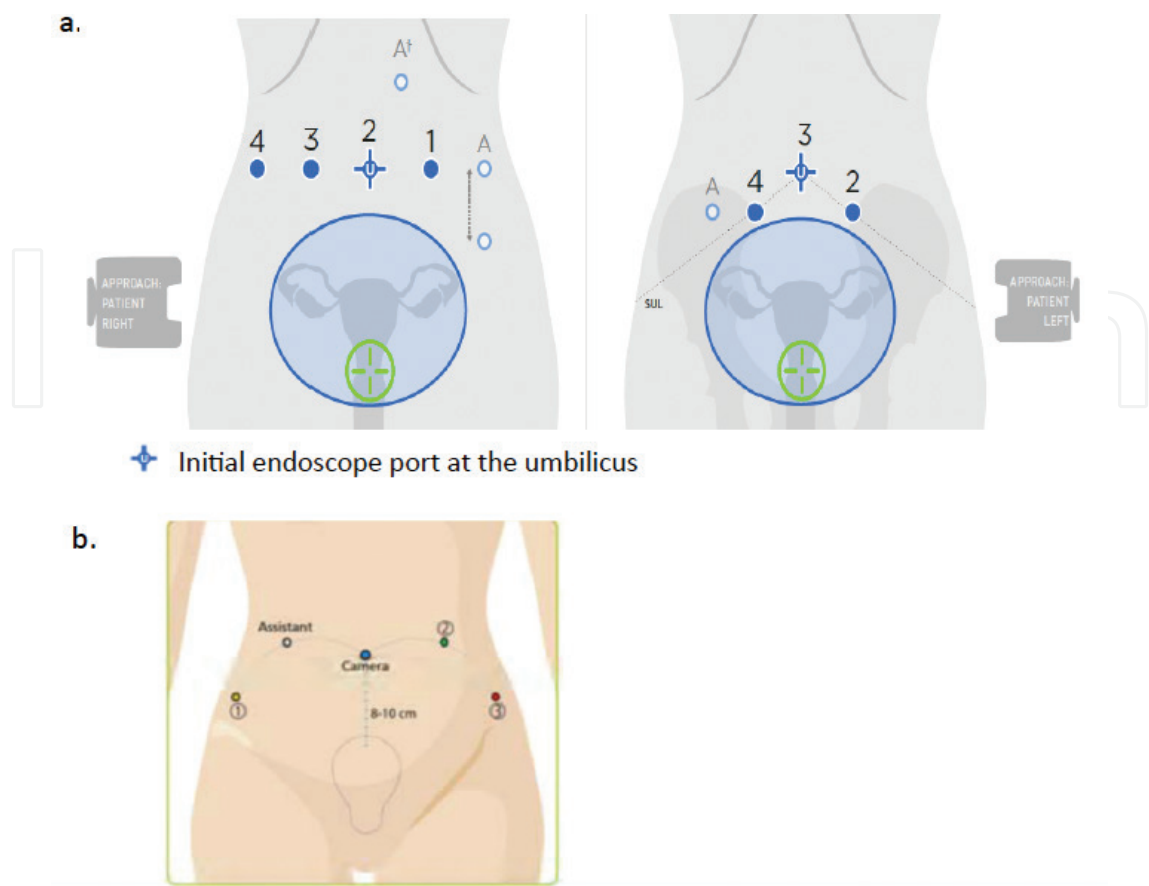
### 5.1. Port placement

Port placement can differ based on uterine size, the need to do lymph node dissection, using 2 or 3 operative arms and the da Vinci system used (**Figure 2**). The endoscope port is the reference port for all other ports. If not doing lymph node dissection and with a small uterus, the camera port can be placed 8–10 cm above the fundus which ends up being at the umbilicus. For oncologic surgery, we place the camera port 20–25 cm above the pubic bone [64]. When using the S or Si system we place a 10–12 mm laparoscopic port for the camera and when using the Xi system we place the 8 mm da Vinci camera trocar. The ports need to be 6–10 cm apart to allow triangulation and avoid arms collision. When using three operative arms, the surgeon can decide to place the third arm either at the right or left hemi-abdomen. Placing the third operative arm on the right will result in controlling both arms with the surgeon's right hand and vice versa if placed on the left hemi-abdomen.

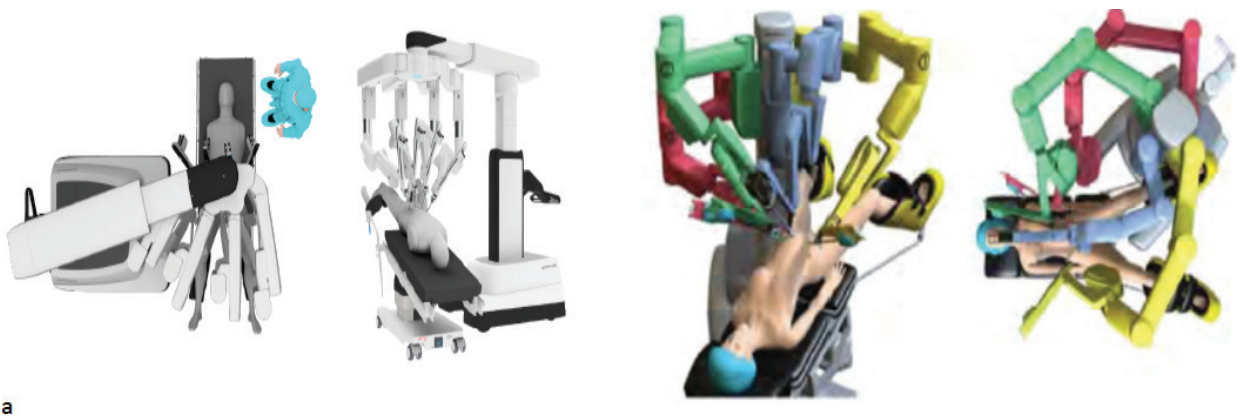When using the Xi system the operative ports can be placed in a straight line at the level of the umbilicus but all ports can be shifted up for a large uterus or for lymph node dissection. The assist port is usually placed 2–3 cm under the left rib cage over the mid-clavicular line (Palmer point) but can be placed in the lower quadrants. Careful placement should be done to avoid placing the assistant port in a straight line with the target anatomy and an operative port. This would result in difficult access to the surgical field for the assistant. We like using either a 5 or 8 mm Airseal trocar for the assist port (ConMed Utica, NY). When using the S or Si systems operative ports should be placed 8–10 cm apart and keeping 10–20 cm distance to the target anatomy.

### 5.2. Docking the patient-side cart

For gynecologic surgery, docking can be done either between the patient's legs or from the side (**Figure 3**). We like side docking because it allows for an assistant to occupy the space between



**Figure 2.** (a) Port placement for the Xi system showing 3 operative arms and 2 operative arms configuration and (b) port placement for the S and Si systems.



**Figure 3.** Side docking. Side docking with the Xi and S system.

the legs and use the uterine manipulator and deliver specimens through the vagina without difficulty. When using the S system, the robotic column is positioned at a 45° acute angle relative to the cephalad/caudal axis of the patient. When using the Xi system the patient-side

cart can be approached in almost any angle to the bed and the arms are rotated to fix their position.

### 5.3. Simple hysterectomy technique

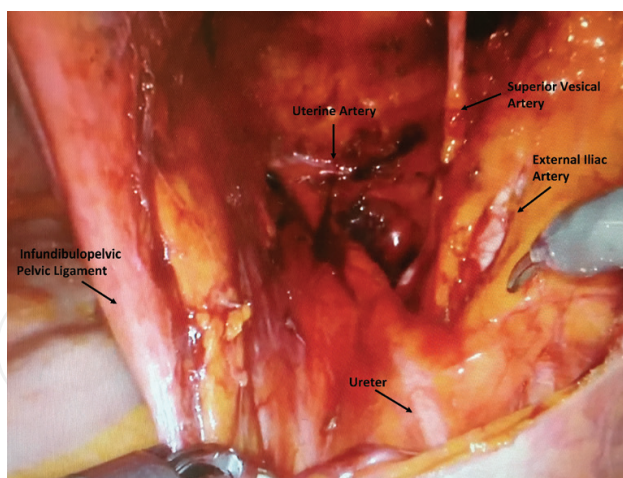
A survey of the entire abdominal cavity is performed laparoscopically. Once the robotic column is successfully docked bipolar forceps are inserted into the left-sided instrument port, monopolar scissors are inserted into the right-sided instrument port, and a grasper inserted into the rightmost port. The assistant seated at the left upper quadrant assistant port starts the procedure with a suction irrigator, laparoscopic bowel grasper, laparoscopic Maryland, and laparoscopic scissors all on hand.

The pelvic peritoneum is incised parallel to the infundibulopelvic ligament. The external iliac artery is identified and traced down to the bifurcation of the common iliac artery. The ureter is found entering the pelvis at the level of the bifurcation. At this point, the ovarian vessels contained in the infundibulopelvic ligament are isolated from the ureter by creating a window in the posterior sheet of the broad ligament. Either the ovarian vessels are clamped, cauterized and transected if a salpingo-oophorectomy is intended or the utero-ovarian ligament. The posterior sheet of the broad ligament is extended in the direction of the uterosacral ligament skeletonizing the uterine artery. The round ligament is then clamped, cauterized and transected. The anterior sheet of the broad ligament is opened in the direction of the vesicouterine peritoneal reflexion. After performing this procedure bilaterally, the bladder is mobilized off of the upper vagina to expose the cervicovaginal junction marked by the colpotomizer of the uterine manipulator. The uterine vessels are then clamped, cauterized and transected at a 90° angle at the cervico-uterine junction. The cardinal ligament is then clamped, cauterized and transected medially to the uterine vessel pedicle and parallel to the cervix. After performing the colpotomy, the specimen is delivered through the vagina. A sterile glove filled with a lap sponge is inserted into the vagina once the specimen is successfully extracted to maintain adequate pneumoperitoneum. The vaginal cuff is then closed using either one polysorb or v-lock suture.

### 5.4. Radical hysterectomy

The surgical technique is similar to the traditional Type III abdominal radical hysterectomy. The avascular spaces (pararectal, paravesical and obturator spaces) are developed to identify the ureters, the major vessels (external and interior iliac arteries, the superior vesical and uterine arteries), the obturator nerve and the genitofemoral nerve (**Figure 4**). The uterine artery is cauterized and transected at its origin and mobilized medially to expose the ureter. Complete ureterolysis is performed to the canal of Wertheim, and the ureter is then unroofed allowing to mobilize both the ureter and the bladder away from the upper third of the vagina. The peritoneum between both uterosacral ligaments is incised, and the paravesical space is bluntly developed, thus allowing transection of the uterosacral ligament at its origin. The paracolpos is then clamped, cauterized and transected parallel to the vagina allowing to perform the upper vaginectomy.





**Figure 4.** Right retroperitoneal pelvic sidewall anatomy.

## 6. Future robotic surgery

### 6.1. Multiport and single port

Single port laparoscopy is a relatively new advancement in minimally invasive surgery. Da Vinci surgery with Single-Site has been approved for cholecystectomy, hysterectomy, and salpingo-oophorectomy in benign conditions. Traditional or robotic-assisted single port laparoscopy for hysterectomy and other gynecologic procedures such as myomectomy and adnexal surgery has been reported in the literature with favorable outcomes [65–67]. Known advantages include improved cosmetic appearance as there is only one incision, decrease postoperative pain and wound infection, and minimization of potential damage to vasculature during port placement [68, 69]. However, single port laparoscopy has technical difficulties including instrument crowding leading to increased collision between instruments and limited degree of movement. There is also an increased risk of an incision-site hernia with single-port surgery. The da Vinci with Single-site technology for a hysterectomy requires a multichannel access port with an insufflation valve and space for four cannulas. Two curved ports are for the robotic controlled instruments, one port holds the endoscope, and the final one is the designated assistant port. In the current literature, there are only retrospective study designs that compare single port laparoscopy with multiport while using the da Vinci robotic system. Paek et al. compared surgical outcomes of single robotic site ( $n = 25$ ) and laparoendoscopic single-site total hysterectomy ( $n = 442$ ) for benign disease states [70]. The study found that the robotic group had a lower complication rate, and less operative bleeding, however, there was significantly longer operating times when compared to the laparoscopic group. Lopez et al. also found an increase in total operative time (approximately 25 min) while using the robotic-assisted single site compared to laparoscopic single site [71]. In this study, there was a significant decrease in length of hospital stay by 8 h in the robotic arm. Gungor et al. compared the operative time, perioperative and early operative complication rate, conversion to another technique rate, postoperative pain, and recovery time, and found that there were no significant differences between single site laparoscopy vs. robotic hysterectomy for benign disease [72]. Single site robotic and laparoscopic surgery was deemed to be safe and feasible techniques for

total hysterectomy. In the hands of an experienced robotic surgeon, the learning curve of robotic laparoendoscopic single site surgery is fast, requiring 13 cases significantly decrease operative time [73]. While single port robotic-assisted hysterectomy seems promising, a Cochrane review reports that there is a lack of evidence of any benefit of a single port or robot-assisted hysterectomy when compared to traditional multi-port laparoscopic hysterectomy [11]. Future randomized control trials are needed to evaluate the potential advantages of robotic single site surgery.

## 7. Surgical complications

New causes of complication have been introduced with robotic-assisted surgery, but the overall incidence of complications is similar to those of conventional laparoscopic surgery. The FDA database reports 21% of injuries attributed to operator-related error and 14% to technical system failure [74]. The main drawback from robotic-assisted surgery is the loss of tactile feedback that can result in complications from poor tissue handling, blunt dissection of dense adhesions or inappropriate tying of sutures [75]. Other causes of complications in robotic-assisted surgery are not keeping the instruments in view, defects in protective sheaths of the shears, collision of instruments, poor positioning of the patient, port and trocar placement, vaginal vault dehiscence and cuff infection, and lack of communication within the team.

Steep Trendelenburg is often required to expose the pelvic anatomy and the para-aortic area during oncologic surgery. Prolonged Trendelenburg can result in mild head contusion, subcutaneous ecchymosis, orbital pain and peri-orbital edema, corneal abrasion, visual loss, laryngeal edema, nerve injuries. Reducing operative time or reversing Trendelenburg after 4–5 h, restrictive fluid replacement, adequate padding at pressure points can prevent some of these complications [75].

Specific organ injuries during robotic-assisted surgery have a similar incidence than during laparoscopic surgery. A systematic review of the literature comparing robotic surgery to laparotomy and conventional laparoscopy for cervical cancer shows comparable risk of urologic injuries (less than 1% bladder injuries and less than 3% ureteric injuries) [76]. Urologic injuries can be prevented by thoroughly identifying the ureter and careful surgical technique avoiding excessive devascularization of the ureter and excessive use of the cautery. The use of prophylactic stents in conventional laparoscopy and laparotomy has not shown to be cost effective for the prevention of urologic injury and has not been studied in robotic-assisted gynecologic surgery [77, 78]. Bowel and vascular injuries have a low incidence and similar causes than conventional laparoscopic surgery. Some preventive measures can be used to reduce injury during entrance to the abdominal cavity but no specific technique (veress needle, open technique) has shown to be superior to prevent injuries. Good surgical technique with good exposure and correct use of electric energy are important to prevent injuries. The majority of bowel injuries are recognized intra-operatively (87%) and repaired by minimally invasive approach (58%) [79]. Nerve injuries can occur due to poor patient positioning but also during lymph node dissection (genitofemoral nerve, obturator nerve) and parametrial dissection (para-sympathetic plexus) during radical hysterectomy. Although vaginal cuff dehiscence is uncommon, it is more prevalent in robotic surgery than conventional laparoscopy,

laparotomy and vaginal surgery. It is reported in up to 1.5% of hysterectomies done for benign disease and up to 2.5% for oncologic disease [80, 81]. Several measures are recommended to limit the incidence of vaginal cuff dehiscence like the use of cutting mode electrocautery during the colpotomy to reduce thermal injury, incorporating 5 mm of healthy tissue from the vaginal edge, incorporating the posterior peritoneum and uterosacral ligaments for better support and avoiding vaginal trauma (intercourse, tampons, Valsalva) for 6–12 weeks [75]. In a review of the United States Food and Drug Administration (FDA) Manufacture and User Device Experience (MAUDE) Database reporting of gynecologic robotic procedures (the majority of which consisted of robotic hysterectomy) for the year 2012, risk of major operative injury was 0.08% and the risk of death was 0.007% [82].

## 8. Information for patients

Patients should be provided instructions regarding perioperative information and expectations. Patients should remain NPO starting at the 12 am hour before surgery. Bowel preparation is not necessary unless bowel resection is anticipated. Prior to proceeding to the operating room patients will review and sign procedure consents with their surgeon. Detailed information regarding possible intraoperative complications is detailed above in Section 7. In general patients should be made aware that risks of robotic assisted laparoscopic hysterectomy include but not be limited to vascular injury, hemorrhage, infection, injury to bowel, bladder, ureters, nerves, and other structures adjacent to the operative field. Patients should be informed that the risk of major morbidity and death are both small (approximately <1% and <0.01% respectively) [82]. In some cases reoperation with additional surgical interventions such as bowel resection with reanastomosis and/or diversion and ureteral reimplantation may be necessary. Major causes of postoperative morbidity include sepsis and venous thromboembolism. Prophylactic antibiotics and pharmacologic anticoagulation are often administered to minimize these risks. The majority of patients undergoing robotic hysterectomy are discharged home within 24–48 h of surgery, with a large portion of patients going home on the same day as surgery.

## 9. Conclusion

The da Vinci Surgical System is an innovative technology that has advanced the laparoscopic treatment of benign and malignant diseases in gynecology. Da Vinci assisted laparoscopic hysterectomy has advantages over open, traditional laparoscopic, and even vaginal approaches in some cases. This surgical technique is proliferating and being adopted by university and community hospitals across the country. As the literature on the benefits of da Vinci assisted hysterectomy continues to grow, so does operator proficiency and its use in operating rooms. The newer da Vinci models have increased movement efficiency and visual capacity. Although the future utility of robotic surgeries and robotic hysterectomies necessitates further research, the potential application of this surgical method affords great promise.

## Author details

Adrian Kohut<sup>1</sup>, Leah Goldberg<sup>1</sup> and Alexandre Buckley De Meritens<sup>1,2\*</sup>

\*Address all correspondence to: ab1641@cinj.rutgers.edu

1 Department of Obstetrics, Gynecology, and Reproductive Sciences, Rutgers Robert Wood Johnson Medical School, Robert Wood Johnson University Hospital, New Brunswick, NJ, United States

2 Division of Gynecologic Oncology, Rutgers Cancer Institute of New Jersey, Robert Wood Johnson University Hospital, New Brunswick, NJ, United States

## References

- [1] Ballantyne GH, Moll F. The da Vinci telerobotic surgical system: The virtual operative field and telepresence surgery. *The Surgical Clinics of North America*. 2003;**83**(6):1293-1304 vii
- [2] Intuitive Surgical, I. The da Vinci Surgical System. 2017. Available from: [https://intuitive-surgical.com/products/davinci\\_surgical\\_system/](https://intuitive-surgical.com/products/davinci_surgical_system/) [cited 2017]
- [3] Diaz-Arrastia C et al. Laparoscopic hysterectomy using a computer-enhanced surgical robot. *Surgical Endoscopy*. 2002;**16**(9):1271-1273
- [4] Lambaudie E et al. Robot-assisted laparoscopy in gynecologic oncology. *Surgical Endoscopy*. 2008;**22**(12):2743-2747
- [5] Lauterbach R, Matanes E, Lowenstein L. Review of robotic surgery in gynecology – The future is here. *Rambam Maimonides Medical Journal*. 2017;**8**(2):1-12
- [6] Gala RB et al. Systematic review of robotic surgery in gynecology: Robotic techniques compared with laparoscopy and laparotomy. *Journal of Minimally Invasive Gynecology*. 2014;**21**(3):353-361
- [7] Moukarzel LA, Fader AN, Tanner EJ. Feasibility of robotic-assisted laparoendoscopic single-site surgery in the gynecologic oncology setting. *Journal of Minimally Invasive Gynecology*. 2017;**24**(2):258-263
- [8] Whiteman MK et al. Inpatient hysterectomy surveillance in the United States, 2000-2004. *American Journal of Obstetrics and Gynecology*. 2008;**198**(1):34e1-34e7
- [9] Wright JD et al. Robotically assisted vs laparoscopic hysterectomy among women with benign gynecologic disease. *JAMA*. 2013;**309**(7):689-698
- [10] Committee on Gynecologic, P. Committee Opinion No 701: Choosing the Route of Hysterectomy for Benign Disease. *Obstetrics and Gynecology*. 2017;**129**(6):e155-e159
- [11] Aarts JW et al. Surgical approach to hysterectomy for benign gynaecological disease. *Cochrane Database of Systematic Reviews*. 2015;**8**:CD003677



- [12] Ho C et al. In Robot-Assisted Surgery Compared with Open Surgery and Laparoscopic Surgery: Clinical Effectiveness and Economic Analyses. Ottawa, ON: Canadian Agency for Drugs and Technologies in Health. 2011
- [13] Landeen LB et al. Clinical and cost comparisons for hysterectomy via abdominal, standard laparoscopic, vaginal and robot-assisted approaches. *South Dakota Medicine*. 2011;**64**(6):197-199, 201, 203 passim
- [14] Geppert B, Lonnerfors C, Persson J. Robot-assisted laparoscopic hysterectomy in obese and morbidly obese women: Surgical technique and comparison with open surgery. *Acta Obstetrica et Gynecologica Scandinavica*. 2011;**90**(11):1210-1217
- [15] Lim PC et al. Multicenter analysis comparing robotic, open, laparoscopic, and vaginal hysterectomies performed by high-volume surgeons for benign indications. *International Journal of Gynaecology and Obstetrics*. 2016;**133**(3):359-364
- [16] Scandola M et al. Robot-assisted laparoscopic hysterectomy vs traditional laparoscopic hysterectomy: Five metaanalyses. *Journal of Minimally Invasive Gynecology*. 2011;**18**(6):705-715
- [17] Orady M et al. Comparison of robotic-assisted hysterectomy to other minimally invasive approaches. *JSLs*. 2012;**16**(4):542-548
- [18] Rosero EB et al. Comparison of robotic and laparoscopic hysterectomy for benign gynecologic disease. *Obstetrics and Gynecology*. 2013;**122**(4):778-786
- [19] Surgical I. da Vinci Xi Surgical System. 2017. Available from: <https://www.intuitivesurgical.com/products/da-vinci-xi/> [cited 9/29/2017]
- [20] Committee opinion no. 628: Robotic surgery in gynecology. *Obstetrics and Gynecology*. 2015;**125**(3):760-7
- [21] Sarlos D et al. Robotic hysterectomy versus conventional laparoscopic hysterectomy: Outcome and cost analyses of a matched case-control study. *European Journal of Obstetrics, Gynecology, and Reproductive Biology*. 2010;**150**(1):92-96
- [22] Matthews CA et al. Evaluation of the introduction of robotic technology on route of hysterectomy and complications in the first year of use. *American Journal of Obstetrics and Gynecology*. 2010;**203**(5):499e1-499e5
- [23] Payne TN, Dauterive FR. A comparison of total laparoscopic hysterectomy to robotically assisted hysterectomy: Surgical outcomes in a community practice. *Journal of Minimally Invasive Gynecology*. 2008;**15**(3):286-291
- [24] Kilic GS et al. Comparison of perioperative outcomes of total laparoscopic and robotically assisted hysterectomy for benign pathology during introduction of a robotic program. *Obstetrics and Gynecology International*. 2011;**2011**:683703
- [25] Shashoua AR, Gill D, Locher SR. Robotic-assisted total laparoscopic hysterectomy versus conventional total laparoscopic hysterectomy. *JSLs*. 2009;**13**(3):364-369
- [26] Nezhat C et al. Laparoscopic hysterectomy with and without a robot: Stanford experience. *JSLs*. 2009;**13**(2):125-128



- [27] Yamasato K et al. Effect of robotic surgery on hysterectomy trends: Implications for resident education. *Journal of Minimally Invasive Gynecology*. 2014;**21**(3):399-405
- [28] Network NCC. NCCN Clinical Practice Guidelines in Oncology: Uterine Neoplasms. 2016
- [29] Walker JL et al. Recurrence and survival after random assignment to laparoscopy versus laparotomy for comprehensive surgical staging of uterine cancer: Gynecologic Oncology Group LAP2 Study. *Journal of Clinical Oncology*. 2012;**30**(7):695-700
- [30] Zhao Y et al. Laparoscopic radical hysterectomy in early stage cervical cancer: A systematic review and meta-analysis. *Journal of Laparoendoscopic & Advanced Surgical Techniques. Part A*. 2017;**27**(11):1132-1144
- [31] Bogani G et al. Laparoscopic versus open abdominal management of cervical cancer: Long-term results from a propensity-matched analysis. *Journal of Minimally Invasive Gynecology*. 2014;**21**(5):857-862
- [32] Liu Z et al. Superiority of robotic surgery for cervical cancer in comparison with traditional approaches: A systematic review and meta-analysis. *International Journal of Surgery*. 2017;**40**:145-154
- [33] Gehrig PA et al. What is the optimal minimally invasive surgical procedure for endometrial cancer staging in the obese and morbidly obese woman? *Gynecologic Oncology*. 2008;**111**(1):41-45
- [34] Bell MC et al. Comparison of outcomes and cost for endometrial cancer staging via traditional laparotomy, standard laparoscopy and robotic techniques. *Gynecologic Oncology*. 2008;**111**(3):407-411
- [35] Lim PC, Kang E, Park DH. Learning curve and surgical outcome for robotic-assisted hysterectomy with lymphadenectomy: Case-matched controlled comparison with laparoscopy and laparotomy for treatment of endometrial cancer. *Journal of Minimally Invasive Gynecology*. 2010;**17**(6):739-748
- [36] Magrina JF et al. Robotic surgery for endometrial cancer: Comparison of perioperative outcomes and recurrence with laparoscopy, vaginal/laparoscopy and laparotomy. *European Journal of Gynaecological Oncology*. 2011;**32**(5):476-480
- [37] Seamon LG et al. Comprehensive surgical staging for endometrial cancer in obese patients: Comparing robotics and laparotomy. *Obstetrics and Gynecology*. 2009;**114**(1):16-21
- [38] DeNardis SA et al. Robotically assisted laparoscopic hysterectomy versus total abdominal hysterectomy and lymphadenectomy for endometrial cancer. *Gynecologic Oncology*. 2008;**111**(3):412-417
- [39] ElSahwi KS et al. Comparison between 155 cases of robotic vs. 150 cases of open surgical staging for endometrial cancer. *Gynecologic Oncology*. 2012;**124**(2):260-264
- [40] Subramaniam A et al. A cohort study evaluating robotic versus laparotomy surgical outcomes of obese women with endometrial carcinoma. *Gynecologic Oncology*. 2011;**122**(3):604-607

- [41] Barnett JC et al. Cost comparison among robotic, laparoscopic, and open hysterectomy for endometrial cancer. *Obstetrics and Gynecology*. 2010;**116**(3):685-693
- [42] Boggess JF et al. A case-control study of robot-assisted type III radical hysterectomy with pelvic lymph node dissection compared with open radical hysterectomy. *American Journal of Obstetrics and Gynecology*. 2008;**199**(4):357e1-357e7
- [43] Soliman PT et al. Radical hysterectomy: A comparison of surgical approaches after adoption of robotic surgery in gynecologic oncology. *Gynecologic Oncology*. 2011;**123**(2):333-336
- [44] Cantrell LA et al. Survival outcomes for women undergoing type III robotic radical hysterectomy for cervical cancer: A 3-year experience. *Gynecologic Oncology*. 2010;**117**(2):260-265
- [45] Geisler JP et al. Robotically assisted laparoscopic radical hysterectomy compared with open radical hysterectomy. *International Journal of Gynecological Cancer*. 2010;**20**(3):438-442
- [46] Nam EJ et al. A case-control study of robotic radical hysterectomy and pelvic lymphadenectomy using 3 robotic arms compared with abdominal radical hysterectomy in cervical cancer. *International Journal of Gynecological Cancer*. 2010;**20**(7):1284-1289
- [47] Holloway RW et al. Comparison of total laparoscopic and abdominal radical hysterectomy for patients with early-stage cervical cancer. *Obstetrics and Gynecology*. 2007;**110**(5):1174, author reply 1174-5
- [48] Magrina JF. Robotic surgery in gynecology. *European Journal of Gynaecological Oncology*. 2007;**28**(2):77-82
- [49] Puntambekar SP et al. Laparoscopic total radical hysterectomy by the Pune technique: Our experience of 248 cases. *Journal of Minimally Invasive Gynecology*. 2007;**14**(6):682-689
- [50] Obermair A et al. A phase III randomized clinical trial comparing laparoscopic or robotic radical hysterectomy with abdominal radical hysterectomy in patients with early stage cervical cancer. *Journal of Minimally Invasive Gynecology*. 2008;**15**(5):584-588
- [51] Estape R et al. A case matched analysis of robotic radical hysterectomy with lymphadenectomy compared with laparoscopy and laparotomy. *Gynecologic Oncology*. 2009;**113**(3):357-361
- [52] Fanning J, Fenton B, Purohit M. Robotic radical hysterectomy. *American Journal of Obstetrics and Gynecology*. 2008;**198**(6):649e1-649e4
- [53] Kim YT et al. Robotic radical hysterectomy with pelvic lymphadenectomy for cervical carcinoma: A pilot study. *Gynecologic Oncology*. 2008;**108**(2):312-316
- [54] Maggioni A et al. Robotic approach for cervical cancer: Comparison with laparotomy: A case control study. *Gynecologic Oncology*. 2009;**115**(1):60-64
- [55] Nezhat FR et al. Robotic radical hysterectomy versus total laparoscopic radical hysterectomy with pelvic lymphadenectomy for treatment of early cervical cancer. *JSLs*. 2008;**12**(3):227-237

- [56] Persson J et al. Robot assisted laparoscopic radical hysterectomy and pelvic lymphadenectomy with short and long term morbidity data. *Gynecologic Oncology*. 2009;**113**(2): 185-190
- [57] Sert BM, Abeler VM. Robotic-assisted laparoscopic radical hysterectomy (Piver type III) with pelvic node dissection—Case report. *European Journal of Gynaecological Oncology*. 2006;**27**(5):531-533
- [58] Sert B, Abeler V. Robotic radical hysterectomy in early-stage cervical carcinoma patients, comparing results with total laparoscopic radical hysterectomy cases. The future is now? *International Journal of Medical Robotics*. 2007;**3**(3):224-228
- [59] Field JB et al. Computer-enhanced robotic surgery in gynecologic oncology. *Surgical Endoscopy*. 2007;**21**(2):244-246
- [60] Kho RM et al. Robotic hysterectomy: Technique and initial outcomes. *American Journal of Obstetrics and Gynecology*. 2007;**197**(1):113e1-113e4
- [61] van Dam PA et al. Robotic-assisted laparoscopic cytoreductive surgery for lobular carcinoma of the breast metastatic to the ovaries. *Journal of Minimally Invasive Gynecology*. 2007;**14**(6):746-749
- [62] Bandera CA, Magrina JF. Robotic surgery in gynecologic oncology. *Current Opinion in Obstetrics & Gynecology*. 2009;**21**(1):25-30
- [63] Choi SB et al. Early experiences of robotic-assisted laparoscopic liver resection. *Yonsei Medical Journal*. 2008;**49**(4):632-638
- [64] Nadeem R, Abu-Rustum RRB, Douglas A. Levine, *Atlas of Procedures in Gynecologic Oncology*. 3rd ed. CRC Press Taylor and Francis Group, Third Edition; 2013. p. 472
- [65] Jung YW et al. The feasibility of scarless single-port transumbilical total laparoscopic hysterectomy: Initial clinical experience. *Surgical Endoscopy*. 2010;**24**(7):1686-1692
- [66] Kim YW et al. Single-port laparoscopic myomectomy using a new single-port transumbilical morcellation system: Initial clinical study. *Journal of Minimally Invasive Gynecology*. 2010;**17**(5):587-592
- [67] Kim TJ et al. Single port access laparoscopic adnexal surgery. *Journal of Minimally Invasive Gynecology*. 2009;**16**(5):612-615
- [68] Ramirez PT. Single-port laparoscopic surgery: Is a single incision the next frontier in minimally invasive gynecologic surgery? *Gynecologic Oncology*. 2009;**114**(2):143-144
- [69] Fader AN, Escobar PF. Laparoendoscopic single-site surgery (LESS) in gynecologic oncology: Technique and initial report. *Gynecologic Oncology*. 2009;**114**(2):157-161
- [70] Paek J et al. Robotic single-site versus laparoendoscopic single-site hysterectomy: A propensity score matching study. *Surgical Endoscopy*. 2016;**30**(3):1043-1050
- [71] Lopez S, Mulla Z, Hernandez L, Garza DM, Payne TN, Farnam RW. A comparison of outcomes between robotic-assisted, single-site laparoscopy versus laparoendoscopic single site for benign hysterectomy. *Journal of Minimally Invasive Gynecology*. 2016;**23**(1)

- [72] Gungor M et al. Single-port hysterectomy: Robotic versus laparoscopic. *Journal of Robotic Surgery*. Mar 2018;**12**(1):87-92
- [73] Buckley de Meritens A et al. Feasibility and learning curve of robotic laparoendoscopic single-site surgery in gynecology. *Journal of Minimally Invasive Gynecology*. 2017; **24**(2):323-328
- [74] Manoucheri MAUDE: analysis of robotic-assisted gynecologic surgery. *Journal of Minimally Invasive Gynecology*. Jul-Aug 2014;**21**(4):592-595
- [75] Tse KY et al. Robot-assisted gynaecological cancer surgery-complications and prevention. *Best Practice and Research Clinical Obstetrics and Gynaecology*. Nov 2017;**45**:94-106
- [76] Park DA, Yun JE, Kim SW, et al. Surgical and clinical safety and effectiveness of robot-assisted laparoscopic hysterectomy compared to conventional laparoscopy and laparotomy for cervical cancer: A systematic review and meta-analysis. *European Journal of Surgical Oncology*. Sep 2016;**42**(9):1303-14
- [77] Merritt AJ, Crosbie EJ, Charova J, et al. Prophylactic pre-operative bilateral ureteric catheters for major gynaecological surgery. *Archives of Gynecology and Obstetrics*. 2013;**288**:1061-1066
- [78] Han L, Cao R, Jiang JY, et al. Preset ureter catheter in laparoscopic radical hysterectomy of cervical cancer. *Genetics and Molecular Research*. 2014;**13**:3638-3645
- [79] Picerno T, Sloan NL, Escobar P, et al. Bowel injury in robotic gynecologic surgery: Risk factors and management options. A systematic review. *American Journal of Obstetrics and Gynecology*. 2017;**216**:10-26
- [80] Landeen LB, Hultgren EM, Kapsch TM, Mallory PW. Vaginal cuff dehiscence: A randomized trial comparing robotic vaginal cuff closure methods. *Journal of Robotic Surgery*. 2016;**10**(4):337-341
- [81] Drudi L, Press JZ, Lau S, et al. Vaginal vault dehiscence after robotic hysterectomy for gynecologic cancers: Search for risk factors and literature review. *International Journal of Gynecological Cancer*. 2013;**23**:943-950
- [82] Shields K, Minion L, Sumner D, Monk B. Ten year food and drug administration reporting of robot-assisted laparoscopy complications, deaths, and device malfunctions in gynecologic surgery. *Gynecologic Oncology*. 2014;**135**(2):402. DOI: 10.1016/j.ygyno.2014.07.061