

# We are IntechOpen, the world's leading publisher of Open Access books Built by scientists, for scientists

6,900

Open access books available

186,000

International authors and editors

200M

Downloads

Our authors are among the

154

Countries delivered to

TOP 1%

most cited scientists

12.2%

Contributors from top 500 universities



WEB OF SCIENCE™

Selection of our books indexed in the Book Citation Index  
in Web of Science™ Core Collection (BKCI)

Interested in publishing with us?  
Contact [book.department@intechopen.com](mailto:book.department@intechopen.com)

Numbers displayed above are based on latest data collected.  
For more information visit [www.intechopen.com](http://www.intechopen.com)



---

# Diagnosis and Treatment of the Meso-Acromion of the Shoulder

---

William B. Stetson, Stephanie Morgan, Brian Chung,  
Nicole Hung, Genevieve Mazza and Alex McIntyre

Additional information is available at the end of the chapter

<http://dx.doi.org/10.5772/intechopen.76267>

---

## Abstract

The failed fusion between two acromial apophyses, called an os acromiale, is often asymptomatic and found incidentally during evaluation for unrelated shoulder pathology. Though this is frequently not the primary pain source, a mobile os acromiale fragment can cause inflammation at the pseudarthrosis site, rotator cuff impingement, or AC joint arthritis. Varying operative techniques exist with good to satisfactory results for symptomatic patients. Several operative techniques have been described including open excision, open reduction-internal fixation (ORIF), arthroscopic acromioplasty or subacromial decompression, and arthroscopic excision. Open excision of a meso-acromion can lead to persistent pain and deltoid weakness and atrophy. The management of a meso-acromial fragment with ORIF can also result in persistent pain and deltoid weakness and atrophy with non-union of the fragments. Arthroscopic excision of the meso-acromion is described as a viable alternative for surgical candidates.

**Keywords:** shoulder arthroscopy, os acromiale, meso-acromion, surgical technique, acromion

---

## 1. Introduction

An os acromiale is usually found incidentally during the evaluation for unrelated shoulder pathology as most patients are often asymptomatic for this condition [1]. The acromial apophysis develops from four main classification centers: (1) the pre-acromion, (2) the meso-acromion, (3) the meta-acromion and (4) the basi-acromion [2]. The os acromiale represents a failure of fusion between two of these apophyses [2]. The types of os acromiale are defined by

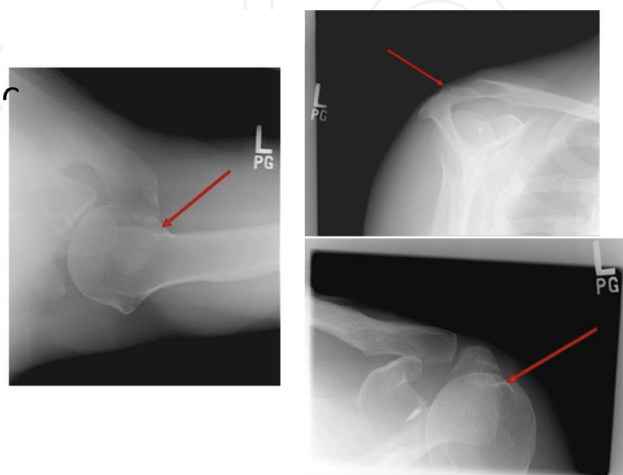
the unfused segment immediately anterior to the site of nonunion [3]. For example, failed fusion between the meta-acromial and meso-acromion ossification centers is called a meso-acromiale [3]. Although the reported prevalence of os acromiale in skeletally mature shoulders has ranged from 1.3 to 30% [2–4], it is not frequently diagnosed as a cause of pain [2, 4, 5]. The great majority of os acromiale are meso-acromions (**Figure 1**). Pre-acromial fragments occur much less frequently and a meta-acromiale is rare [3].

A mesotype of os acromion is uncommon shoulder pathology but when symptomatic, presents the surgeon with a diagnostic dilemma with inconsistent outcome treatment options with various surgical techniques. It is not frequently diagnosed as a cause of pain [2, 4, 5] but when other factors have been ruled out, such as impingement or other shoulder pathology, what is the best treatment option is dependent on the age of the patient and their activity level.

The condition can be symptomatic secondary to pain or inflammation at the pseudarthrosis site from the mobile fragment impinging on the rotator cuff [5, 6] or arthritic changes of the acromioclavicular joint due to hypermobility of the os [2]. The diagnosis of a symptomatic os acromiale can be difficult but can be made by the presence of pain and local tenderness over the anterior acromion and the nonunion site [3, 5] a hyper-mobile fragment at the anterior acromion [3], positive impingement signs [5, 7], and positive local injection tests [3].

The area of fibrous union or non-union of the os acromiale fragment may become painful after the patient has minor trauma [1] or from repetitive overhead activities of the shoulder. The persistent pain may be due to acromioclavicular (AC) joint arthropathy as a result of motion of the os acromiale site or from local inflammation at the non-union site [5]. Because there are multiple potential causes of shoulder pain, it is important to rule out other sources of shoulder pain. A thorough clinical examination is needed to define the source of the pain.

When non-surgical treatment fails, surgical management is warranted. A number of surgical techniques have been widely described such as open fragment excision [8], arthroscopic acromioplasty [1, 7, 9, 10], open reduction and internal fixation (ORIF) [2, 3, 5, 6, 11–13], or arthroscopic excision [14, 15]. The excision of a pre-acromion arthroscopically or open is



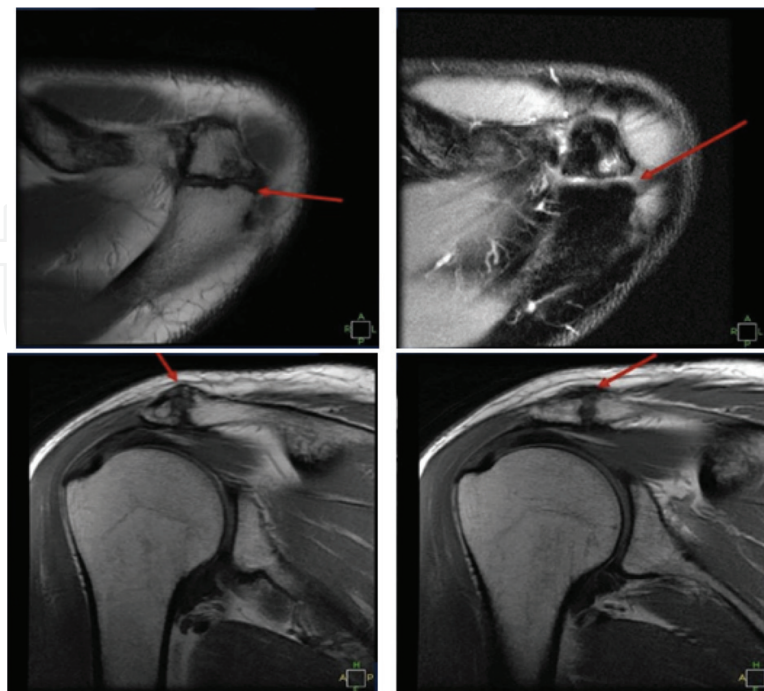
**Figure 1.** Radiograph views showing a meso-acromion: axillary lateral (A), supraspinatus outlet (B), and anterior-posterior view of the glenohumeral joint.

usually satisfactory [14, 15]. However, open excision of a symptomatic meso-acromion has led to poor results with residual pain, weakness, and deltoid dysfunction [5, 8, 16]. Arthroscopic subacromial decompression has led to good results in many studies, but the satisfaction rate has ranged from 0 to 85% [1, 7, 9, 10]. However, in those studies many of the patients had subacromial impingement and the os acromiale was asymptomatic. ORIF has also led some mixed results with many different surgical techniques described [2, 3, 5, 6, 11–13, 17]. Hardware complications, nonunion, and the need for hardware removal are common after ORIF even when radiographic union has occurred [1–3, 5, 11, 13].

There are some patients who are not candidates for open reduction and internal fixation or for arthroscopic subacromial decompression because of many reasons including concomitant AC joint osteoarthritis, history of previous arthroscopic subacromial decompression with recurrence of pain, or advanced age and the risk of nonunion or the unwillingness to undergo a second surgery for hardware removal, which is very common after ORIF. Arthroscopic excision of the meso-acromion is described as a viable alternative for surgical candidates.

## 2. Diagnostic imaging

Plain radiographs are the mainstay of diagnostic imaging. An axillary view should be made routinely to diagnose and confirm the presence of an os acromiale. More frequently, the diagnosis is made incidentally. Lee and colleagues [18] described the double-density sign on a standard anteroposterior radiograph of the shoulder and a cortical irregularity on the supraspinatus outlet view which was highly suggestive of an os acromiale (**Figure 1**). MRI or



**Figure 2.** MRI left shoulder that shows an intact rotator cuff, healing of the previous SLAP repair, moderate AC joint osteoarthritis, and a meso-acromion with sclerotic changes and soft tissue swelling at the meso-acromion site.

CT scan can also be used to confirm an os acromiale and to determine if there are any sclerotic or inflammatory changes at the site which may be indicative of degeneration or symptomatic findings. Bone scans may help illustrate the inflammatory response at the non-union site [5]. MRI and MR arthrogram are also helpful to determine if there is any other intra-articular (SLAP lesion) or other pathology (partial or full thickness rotator cuff tear) which may be a source of pain (**Figure 2**).

### 3. Nonsurgical management

Nonsurgical treatment for an isolated symptomatic os acromiale is generally recommended as the initial approach [19]. Rest and restriction of activities accompanied by a structured physical therapy program along with a course of nonsteroidal anti-inflammatory medications similar to a typical impingement protocol is a reasonable approach [19]. A subacromial corticosteroid injection can also be used and may help or eliminate the pain due to impingement or subacromial bursitis.

A selective injection into the os acromiale site with lidocaine (lidocaine injection test of 5 cc's of 1% lidocaine with reexamination 10 min later) as a diagnostic tool or with a corticosteroid can also help to determine whether or not the os acromiale is the source of the pathology and may also help relieve the symptoms and surgery may not be necessary.

### 4. Surgical options

Once the os acromiale or, in particular, the meso-acromion, has been determined to be the source of pain and non-operative treatment options have failed, there are a number of different surgical options ranging from acromioplasty to open resection, open reduction and internal fixation, and arthroscopic resection. The results in the literature vary considerably and are controversial. Depending on the type of os acromiale, the age of the patient, and their activity level, the best surgical options vary for each individual patient. For the sake of this discussion and review for surgical options, we will only address the most common type of os acromiale: the meso-acromion.

#### 4.1. Open excision

Open fragment excision of the symptomatic meso-acromion has had mixed results in the literature due to residual deltoid weakness and dysfunction post-operatively [19]. Mudge and colleagues [8] reported on 6 patients with an os acromiale who underwent open fragment excision but all of them also had associated rotator cuff tears which were repaired with an open technique. Four had excellent results, but two had poor results which may have been due to the severity of the rotator cuff tear or possibly due to the excision of the os acromiale. It is also unclear from their research what type of os acromiale was present as the pre-acromion



represents only a small portion of the os acromiales whereas the meso-acromion represents a much larger portion.

The results of an open excision for a meso-acromion from other authors are poor. Armengol and colleagues [20] reported on a case series of 41 patients with an os acromiale in conjunction with rotator cuff tears. Five patients had open fragment excision and all five had poor results. Warner and colleagues [5] reported on 3 patients who underwent fragment excision, one with a pre-acromion who had an excellent result, but the other two had meso-acromions, which were openly excised. These two patients had poor results with persistent weakness and pain. It is likely that the pain and weakness they had after surgery was due to the loss of the normal acromial fulcrum for function of the deltoid. Open fragment excision has limited indications and is recommended for a symptomatic pre-acromion with a relatively small fragment or as a salvage procedure after a failed ORIF [19].

#### **4.2. Open reduction and internal fixation**

There are many studies that deal with open reduction and internal fixation of symptomatic meso-acromions using different techniques including the use of tension-band wires, sutures, or cannulated screws with or without bone graft. Internal fixation is technically difficult and has led to frequent nonunion rates and often requires hardware removal as a result of postoperative irritation [12]. Aboud and colleagues [1] reported on 19 patients with a meso-acromion, 8 (42%) which were treated with open reduction and internal fixation. Even though all 8 patients achieved union of the fragment, only 3 of these 8 (38%) patients achieved a satisfactory result.

Peckett and colleagues [13] reviewed 26 patients with symptomatic meso os acromiale that were treated with either K-wires or screws and a tension band. If bone stock was adequate, local bone graft was placed in the pseudarthrosis site but there was no mention in how many cases this was performed. The rate of union was 96% (25 of 26) and 24 of 26 were satisfied with their results. However, no objective or subjective shoulder scores were reported. There were two postoperative fractures and eight patients had postoperative pain that was subsequently relieved by wire or screw removal.

Ryu and colleagues [17] reported on 4 patients with symptomatic meso-acromions treated with diagnostic arthroscopy followed by open reduction and internal fixation using partially threaded, 3.5 mm cannulated screws, such that compression could be achieved across the fibrous union site. All of the patients reported complete satisfaction with the procedures with an average postoperative UCLA rating score of 35, a maximum score of 35 indicates that patients were pain-free and had returned to their previous activities without restriction. All regained full range of motion and full strength without any complications or reoperations for symptomatic hardware.

Warner and colleagues [5] reported on 11 patients (12 shoulders) who underwent ORIF with iliac crest bone grafting comparing two fixation techniques. Each technique incorporated debridement of the nonunion site with incorporation of iliac crest autograft spanning the debrided nonunion site. Five shoulders in 4 patients underwent ORIF with a tension-band procedure including the use of pins and wires. Four of these 5 shoulders (80%) resulted in

persistent nonunion. The other 7 patients had an ORIF using cannulated screws and an 18-gauge wire passed through the screws in a figure of 8 fashion. Six of 7 were successful unions. Nine of the 12 shoulders treated with ORIF required hardware removal. Two patients who failed ORIF had open excision of a grossly unstable meso-acromion with persistent pain and weakness following the procedure.

Hertel and colleagues [21] reported on 15 shoulders in 12 patients who underwent ORIF for unstable os acromiale fragments using tension band wiring with the use of bone grafting. Two surgical approaches were used. An anterior deltoid-off approach was used on 7, whereas the other 8 shoulders were approached trans-acromially to preserve the deltoid origin. Union occurred in 3 of 7 cases approached anteriorly and in 7 of 8 shoulders repaired without detachment of the deltoid. The investigators concluded that fusion was more successful when the vascularity of the acromial epiphysis was maintained, likely through the acromiale branch of the thoracoacromial artery.

The techniques and approaches associated with the most successful types of ORIF include those with rigid internal fixation and preservation of the blood supply of the os acromiale fragment [21]. However, even in cases of successful union, patients may still have hardware discomfort requiring hardware removal [19].

#### **4.3. Arthroscopic subacromial decompression and acromioplasty**

Arthroscopic subacromial decompression and acromioplasty is used primarily when impingement with or without a rotator cuff tear is present and the nonunion site of the os acromiale is nontender and considered to be incidental [19]. As with other treatment options, the results are variable. Wright and colleagues [7] reported on 13 patients following an arthroscopic acromioplasty of a meso-acromion and found no decrease in anterior deltoid strength and no occurrence of deltoid detachment. None of these patients had pre-operative symptoms or signs localized to the os acromiale pseudo-arthritis site. Good or excellent results were found in 11 of the 13 cases with an average UCLA shoulder rating scale of 31.

Hutchinson and colleagues [9] reported on 3 cases of impingement syndrome with an associated os acromiale treated with arthroscopic subacromial decompression. Each had good or excellent results in the early post-operative period but the pain returned each case requiring additional surgical intervention. Repeat arthroscopic debridement and excision of the fragment resulted in a good result in one patient while the other two patients the os acromiale was not removed. Both patients had residual pain with impingement like symptoms and pain with overhead activities following the second procedure.

#### **4.4. Arthroscopic excision**

Arthroscopic excision can be a better option with a larger os acromiale such as a meso-acromion. Campbell and colleagues [14] reported on 28 patients with 31 os acromiale. Three patients had a pre-acromion and 28 patients had a meso-acromion. After failing conservative management, the patients were taken to surgery and arthroscopic excision of the pre-acromions and meso-acromions was performed in 14 shoulders (45%) using a 4.5 mm flat

acromionizer burr, leaving the periosteal sleeve and deltoid attachment. A rotator cuff tear was identified in 16 (52%) of the 31 shoulders. Arthroscopic repair was performed in 9 shoulders and a mini open repair (lateral deltoid splitting) in 7 shoulders. Eighty-nine percent had good or excellent results with little difference in deltoid strength and in subjective or objective change in the appearance or contour of the anterior deltoid in those patients in which the meso-acromion was removed.

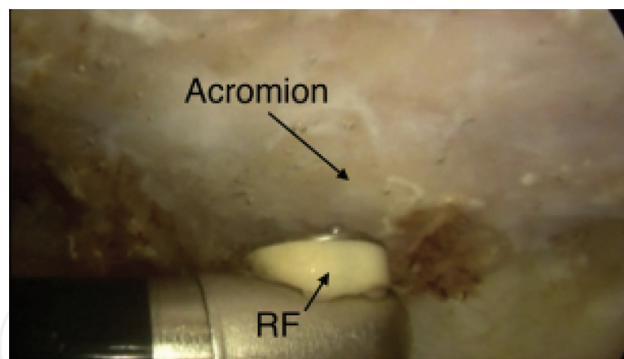
Pagnani and colleagues [15] reported on 12 patients (14 shoulders) with persistent shoulder pain that interfered with athletic participation. Symptoms included impingement-like pain with overhead activity and weight lifting, night pain, and an inability to sleep on the affected side. All had tenderness at or near the meso-acromion. All were males between the age of 18 to 25 years and all were engaged in competitive athletics. Eleven of the twelve patients were elite collegiate or professional athletes. Nine patients (11 shoulders) were treated with arthroscopic excision of the anterior acromial fragment. Using an arthroscopic technique, the acromial fragment was carefully shelled out and the deltoid fascia insertion onto the remaining acromion was preserved to prevent deltoid disruption. With a minimum of two-year follow-up with a range of 2–6.5 years and an average follow-up of 3.72 years, all patients were able to return to full athletic participation by 14 weeks after surgery. No deltoid function was compromised by the procedure and there was no evidence of deltoid weakness or cosmetic deformity post-operatively.

Reviewing the literature, the studies of Pagnani [15] and Campbell [14] are the only ones dealing with the arthroscopic excision of symptomatic meso-acromions. The surgical technique requires no special instrumentation and may be reproducibly performed by those familiar with arthroscopic techniques of the shoulder. The advantages include more rapid rehabilitation, better range of motion and shorter surgical times [12]. There is also no need for a second surgery for symptomatic metal removal. Even though both studies reported excellent results, most orthopedic surgeons are reluctant to recommend or perform an arthroscopic excision for fear of resultant muscle weakness, cosmetic deformity and/or perhaps the technical difficulty of performing such a procedure.

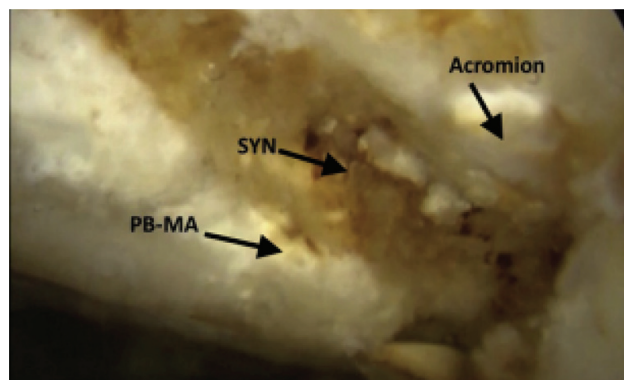
#### *4.4.1. Surgical technique for arthroscopic excision*

A shoulder diagnostic arthroscopy should be performed in the lateral decubitus position while the patient is under general anesthesia. A 15-point diagnostic arthroscopy of the glenohumeral joint is performed, addressing any intra-articular pathology including loose body removal, labral debridement or repair, capsular release, and evaluation and debridement of the articular side of the rotator cuff. The subacromial space is entered into and the arthroscopic shaver is introduced through a separate lateral incision. Then, the subacromial space is examined, addressing bursitis, impingement, and bursal sided rotator cuff tears. The soft tissues are then taken off of the undersurface of the acromion and the coracoacromion (CA) ligament is released but not cut. A radiofrequency device is preferred versus a shaver as it causes less bleeding and allows for better visualization (**Figure 3**). The anterior and lateral edges of the acromion are then identified along with the pseudoarthrosis or synchondrosis site of the meso-acromion (**Figure 4**).





**Figure 3.** Viewing anteriorly from the posterior portal in a left shoulder in the lateral decubitus position, a radiofrequency device (RF) (Arthrocare 90 degrees wand) is inserted into the sub-acromial space through a lateral portal. This device is used to strip all the soft tissues off the undersurface of the acromion.

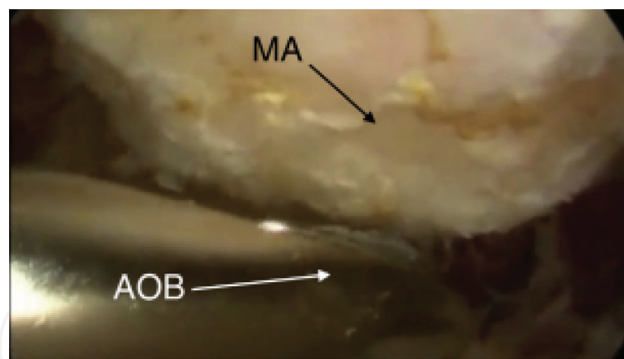


**Figure 4.** Viewing the subacromial space anteriorly from the posterior portal in a left shoulder in the lateral decubitus position, the radiofrequency device has removed all the soft tissues from the undersurface of the acromion. The posterior border of the meso-acromion (PB-MA), the synchondrosis site (SYN), and the acromion are all visualized.

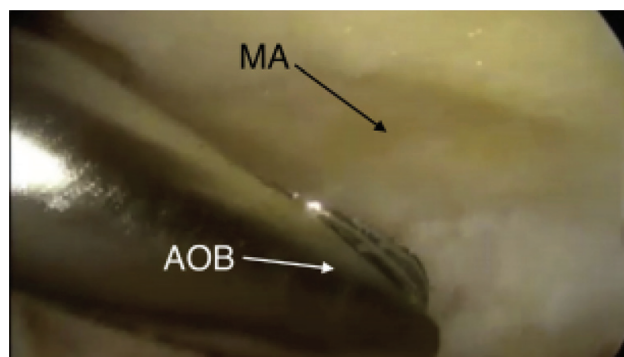
The entire meso-acromion should be identified and stripped of all soft tissues, using an oval burr via the lateral portal while viewing posteriorly (**Figure 5**). Arthroscopic excision using a burr is performed with careful attention not to damage or disrupt the deltoid fibers, which are attached to the remaining portion of the acromion. Meticulous technique is required to prevent disruption of the deltoid fibers (**Figure 6**). Once this is completed, co-planning of the distal aspect of the clavicle should be performed if there is any evidence of arthritis. The soft tissue shaver can then be reinserted to debride any residual soft tissue and ensure complete removal of the meso-acromion. (**Figure 7**).

#### 4.4.2. Post-operative care for arthroscopic excision

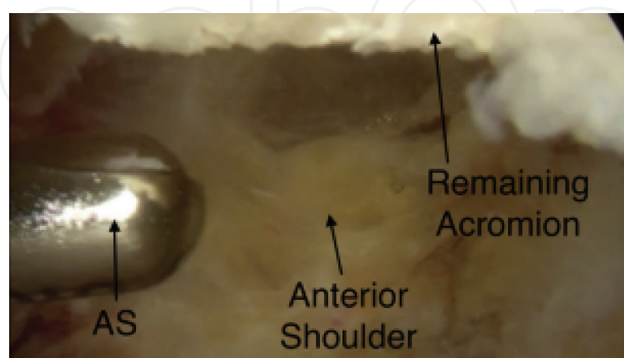
X-rays should be taken post-operatively to assure adequate resection of the meso-acromial fragment (**Figure 8**). Patients should be placed into a sling for 2 weeks to allow the incisions to heal and are instructed on active elbow flexion and extension exercises, active gripping exercises of a small exercise ball with gentle, pendulum exercises. After 2 weeks, the patient's sling should be discontinued and are placed into an aggressive physical therapy program for active assisted range of motion, followed by a strengthening program. Post-operative visits should be



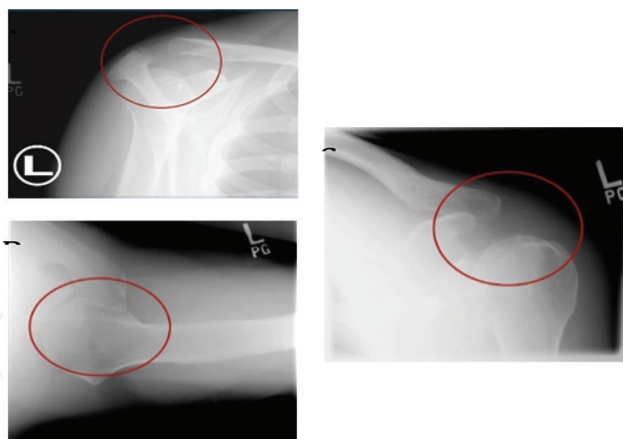
**Figure 5.** Viewing the subacromial space anteriorly from the posterior portal in a left shoulder in the lateral decubitus position, the arthroscopic oval burr (AOB) (4.5 mm Dyonics; Smith & Nephew) is inserted through the lateral portal. The meso-acromion (MA) can be visualized superior to the burr.



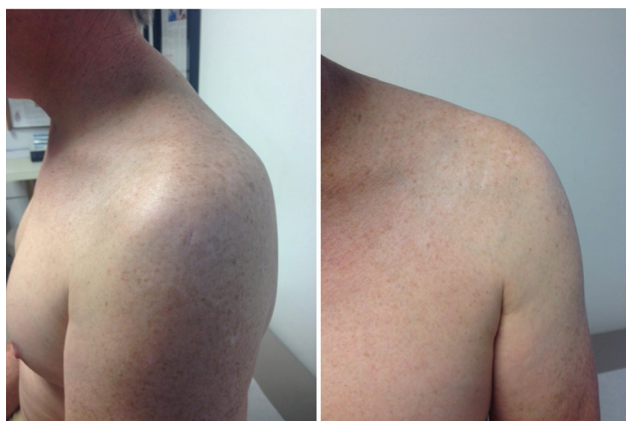**Figure 6.** Viewing the subacromial space anteriorly from the posterior portal in a left shoulder in the lateral decubitus position with the burr in the lateral portal, arthroscopic burring is performed by sweeping the arthroscopic oval burr (AOB) along the undersurface of the meso-acromion (MA) from posterior to anterior with meticulous technique to prevent disruption of the deltoid fibers.



**Figure 7.** Viewing the subacromial space anteriorly from the posterior portal in a left shoulder in the lateral decubitus position, the arthroscopic shaver (AS) is introduced through the lateral portal to remove any residual soft tissues from the remainder of the acromion and to make sure that the entire meso-acromion has been removed. The remaining acromion can be visualized superiorly.



**Figure 8.** Post-operative X-rays showing complete excision of the meso-acromion: supraspinatus outlet (A), axillary lateral (B), and AP of the glenohumeral joint (C).



**Figure 9.** A (left) and B (right) shows no evidence of any cosmetic deformity from resection of the meso-acromion.

regularly scheduled, assessing improvement in range of motion and strength. Particular attention should be focused on the deltoid, looking for evidence of weakness or atrophy. After the patient is fully recovered, the cosmetic appearance of the shoulder should not be appreciably different (**Figure 9**).

#### 4.5. Author's indications for surgery and preferred technique

The senior author (WBS) has been treating shoulder patients for over 20 years. As discussed here in this chapter, many meso-acromions are incidental findings on x-ray and are asymptomatic and should be left alone. If there is ever a question of whether the meso-acromion is the source of a patient's shoulder pain, we prefer the technique of a local injection of 5 cc's of 1% lidocaine into the synchondrosis of the meso-acromion and if that gives pain relief, it is usually diagnostic for a symptomatic meso-acromion that needs to be addressed surgically. We will also often follow the local lidocaine injection with a corticosteroid injection into the area as this can give some patients long lasting pain relief.

Once the meso-acromion has been determined to be the cause of the pain, the senior author recommends arthroscopic excision using the techniques described in this book chapter. At the time of surgery, the meso-acromion is most often loose and the synchondrosis is easily identified arthroscopically and removed. In our experience, we have not seen any evidence of deltoid weakness or atrophy in the patients we have treated with arthroscopic excision and all have been able to resume normal overhead activities with virtually no pain and no subjective or objective evidence of weakness.

## 5. Summary and conclusions

Symptomatic os acromiale are uncommon shoulder pathology but have several management options. When conservative management fails, operative management is warranted. Arthroscopic excision is a much better option than open resection or even ORIF. ORIF of meso-acromial fragments has led to mixed results [1, 2, 5, 13] and is not a good option in patients who are older or who have AC joint osteoarthritis. We prefer arthroscopic excision of the os acromiale/meso-acromion fragment and have found it to be a reliable technique that gives good long term patient satisfaction with no loss of strength. Future studies need to be done to address and analyze the surgical option of the arthroscopic excision of symptomatic os acromiale and in particular, meso-acromion, in certain patient populations. This could lead to a better understanding and treatment options of this difficult and challenge clinical shoulder problem.

## Conflict of interest

The authors have no conflicts of interest to report.

## Author details

William B. Stetson<sup>1,2\*</sup>, Stephanie Morgan<sup>1</sup>, Brian Chung<sup>1,2</sup>, Nicole Hung<sup>1</sup>, Genevieve Mazza<sup>1</sup> and Alex McIntyre<sup>1,2</sup>

\*Address all correspondence to: [wbstetsonmd@gmail.com](mailto:wbstetsonmd@gmail.com)

1 Stetson Powell Orthopedics and Sports Medicine, USA

2 Department of Orthopaedic Surgery, Keck School of Medicine at the University of Southern California, USA

## References

- [1] Abboud JA, Silverberg D, Pepe M, et al. Surgical treatment of os acromiale with and without associated rotator cuff tears. *Journal of Shoulder and Elbow Surgery*. 2006;15(3): 265-270. DOI: 10.1016/j.jse.2005.08.024

- [2] Atoun E, van Tongel A, Narvani A, Rath E, Sforza G, Levy O. Arthroscopically assisted internal fixation of the symptomatic unstable os acromiale with absorbable screws. *Journal of Shoulder and Elbow Surgery*. 2012;**21**(12):1740-1745. DOI: 10.1016/j.jse.2011.12.011
- [3] Kurtz CA, Humble BJ, Rodosky MW, Sekiya JK. Symptomatic os acromiale. *The Journal of the American Academy of Orthopaedic Surgeons*. 2006;**14**(1):12-19
- [4] Sammarco VJ. Os acromiale: Frequency, anatomy, and clinical implications. *The Journal of Bone and Joint Surgery. American Volume*. 2000;**82A**(3):394-400. DOI: 10.1097/00003086-197507000-00005
- [5] Warner J, Beim GM, Higgins L. The treatment of symptomatic os acromiale. *The Journal of Bone and Joint Surgery. American Volume*. 1998;**80A**(9):1320-1326
- [6] Demetracopoulos CA, Kapadia NS, Herickhoff PK, Cosgarea AJ, McFarland EG. Surgical stabilization of os acromiale in a fast-pitch softball pitcher. *The American Journal of Sports Medicine*. 2006;**34**(11):1855-1859. DOI: 10.1177/0363546506288305
- [7] Wright RW, Heller MA, Quick DC, Buss DD. Arthroscopic decompression for impingement syndrome secondary to an unstable os acromiale. *Arthroscopy*. 2000;**16**(6):595-599. DOI: 10.1053/jars.2000.9239
- [8] Mudge MK, Wood VE, Frykman GK. Rotator cuff tears associated with os acromiale. *The Journal of Bone & Joint Surgery*. 1984;**66**(3):427-429
- [9] Hutchinson MR, Veenstra MA. Arthroscopic decompression of shoulder impingement secondary to os acromiale. *Arthroscopy*. 1993;**9**(1):28-32. DOI: 10.1016/S0749-8063(05)80341-X
- [10] Trenhaile SW, Field LD, Savoie FHI. Arthroscopic management of the mesoacromion. *Techniques in Shoulder & Elbow Surgery*. 2002;**3**(2):82
- [11] Jehmlich S, Holovacs TF, Warner JJP. Treatment of the symptomatic os acromiale. *Techniques in Shoulder & Elbow Surgery*. 2004;**5**(4):214
- [12] Ortiguera CJ, Buss DD. Surgical management of the symptomatic os acromiale. *Journal of Shoulder and Elbow Surgery*. 2002;**11**(5):521-528. DOI: 10.1067/mse.2002.122227
- [13] Peckett WRC, Gunther SB, Harper GD, Hughes JS, Sonnabend DH. Internal fixation of symptomatic os acromiale: A series of twenty-six cases. *Journal of Shoulder and Elbow Surgery*. 2004;**13**(4):381-385. DOI: 10.1016/S1058274604000400
- [14] Campbell PT, Nizlan NM, Skirving AP. Arthroscopic excision of os acromiale: Effects on deltoid function and strength. *Orthopedics*. 2012;**35**(11):e1601-e1605. DOI: 10.3928/01477447-20121023-16
- [15] Pagnani MJ, Mathis CE, Solman CG. Painful os acromiale (or unfused acromial apophysis) in athletes. *Journal of Shoulder and Elbow Surgery*. 2006;**15**(4):432-435. DOI: 10.1016/j.jse.2005.09.019
- [16] Neer CS, Marberry TA. On the disadvantages of radical acromionectomy. *The Journal of Bone & Joint Surgery*. 1981;**63**(3):416-419



- [17] Ryu RK, Fan RS, Dunbar WH. The treatment of symptomatic os acromiale. *Orthopedics*. 1999;**22**(3):325-328
- [18] Lee DH, Lee KH, Lopez-Ben R, Bradley EL. The double-density sign: A radiographic finding suggestive of an os acromiale. *The Journal of Bone & Joint Surgery*. 2004;**86-A**(12):2666-2670
- [19] Johnston PS, Paxton ES, Gordon V, Kraeutler MJ, Abboud JA, Williams GR. Os acromiale: A review and an introduction of a new surgical technique for management. *The Orthopedic Clinics of North America*. 2013;**44**(4):635-644. DOI: 10.1016/j.ocl.2013.06.015
- [20] Armengol J, Brittis D, Pollock RG, Flatow EL, Self EB. The association of an unfused acromial epiphysis with tears of the rotator cuff: A review of 42 cases. *Journal of Shoulder and Elbow Surgery*. 1994;**17**:975-976
- [21] Hertel R, Windisch W, Schuster A, Ballmer FT. Transacromial approach to obtain fusion of unstable os acromiale. *Journal of Shoulder and Elbow Surgery*. 1998;**7**(6):606-609

