

# We are IntechOpen, the world's leading publisher of Open Access books Built by scientists, for scientists

6,900

Open access books available

186,000

International authors and editors

200M

Downloads

Our authors are among the

154

Countries delivered to

TOP 1%

most cited scientists

12.2%

Contributors from top 500 universities



WEB OF SCIENCE™

Selection of our books indexed in the Book Citation Index  
in Web of Science™ Core Collection (BKCI)

Interested in publishing with us?  
Contact [book.department@intechopen.com](mailto:book.department@intechopen.com)

Numbers displayed above are based on latest data collected.  
For more information visit [www.intechopen.com](http://www.intechopen.com)



---

## Third-Generation Percutaneous Forefoot Surgery

---

Jorge Javier Del Vecchio, Miky Dalmau-Pastor and  
Mauricio Esteban Ghioldi

Additional information is available at the end of the chapter

<http://dx.doi.org/10.5772/intechopen.76235>

---

### Abstract

Hallux valgus is one of the most common diseases that affects the foot. The primary symptom of this disease is usually pain. Although non-operative treatment should be attempted, some patients eventually need surgical treatment. There are numerous surgical procedures for correction of HV deformities. Some of these surgeries may be performed through open or percutaneous surgery (MIS). Distal metatarsal chevron osteotomy is an excellent treatment option in mild-to-moderate deformities, providing good results in the correction of deformities and symptoms. This technique can also be done by percutaneous or MIS surgeries; the set of these surgeries are called Third generation procedures. They have been showed to be useful, effective and (maybe) easier than open procedures.

**Keywords:** percutaneous, minimal invasive surgery, forefoot, third generation

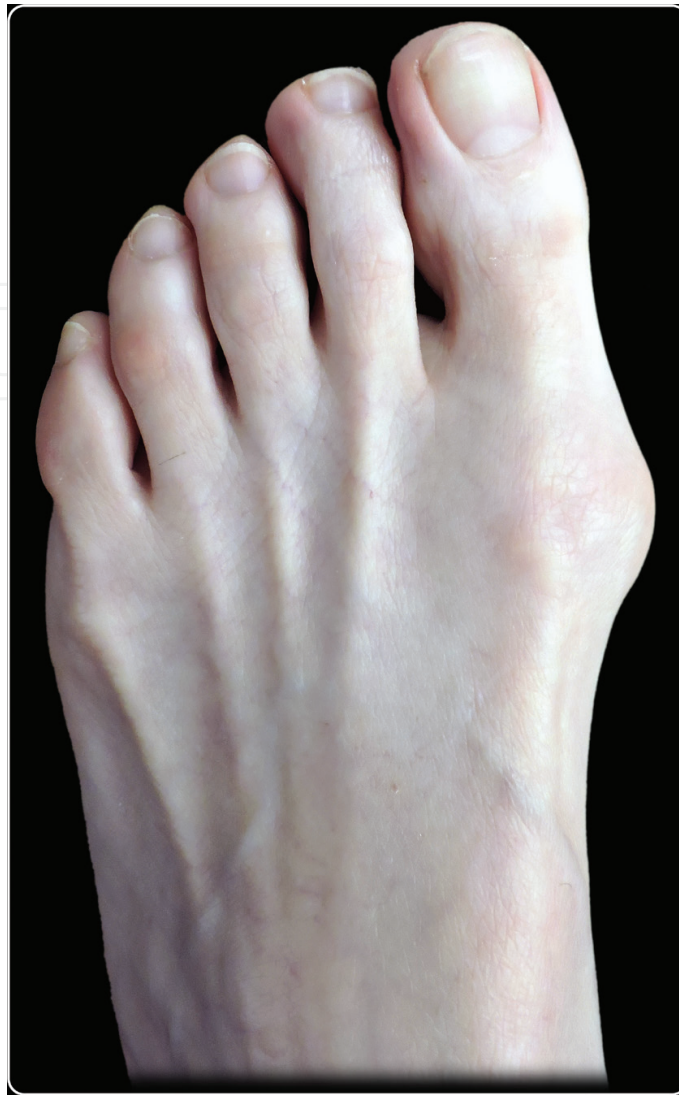---

## 1. Introduction

### 1.1. Definition and incidence

Hallux valgus is one of the most common disease that affects the foot (**Figure 1**) [1, 2]. It has been estimated that this condition affects around 3% of the population [3]. It takes place when the hallux has a lateral deviation, and the first metatarsal (1MT) deviates medially [4]. This condition has a clear predominance in women. According to different series, this entity is around nine times more frequent in women than in men [4–6].

Different causes have been proposed as etiological factors of this deformity: genetic predisposition and intrinsic and extrinsic causes. While some studies have indicated [7, 8] that intrinsic



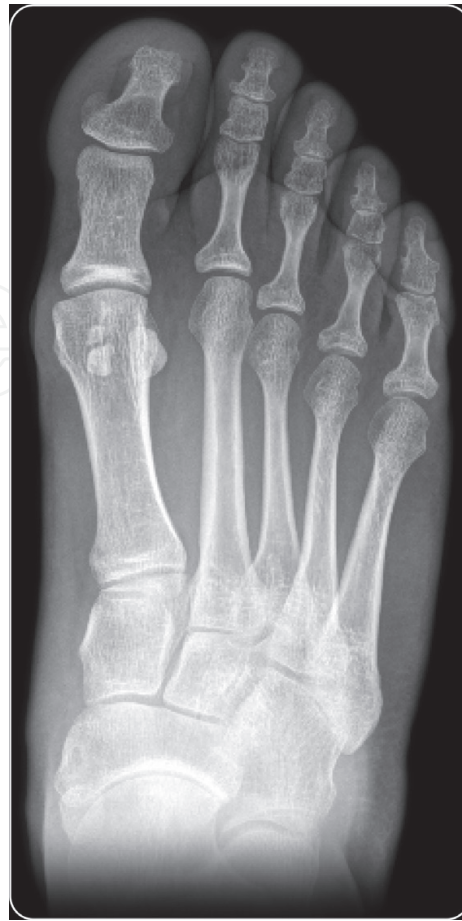**Figure 1.** Hallux valgus deformity.

factors (pes planus) play a major role in the etiology, others suggested that this plays a minor role in the development. The most important extrinsic cause is constricting footwear; it has been suggested that this pathology almost exclusively affects shoe-wearing societies [9–11]. Genetic predisposition has been implicated as a cause of hallux valgus in adults [12, 13].

### **1.2. Symptoms and physical examination**

The primary symptom of hallux valgus is pain. It is often located in medial eminence because of bursal inflammation or skin irritation. Pressure from footwear is the most frequent cause of this discomfort.

Physical examination should be performed with the patient standing and sitting. The deformity is often accentuated when the patient is standing bearing weight. The magnitude of the deformity should be recognized, as is any pronation of the hallux is present. The range of



**Figure 2.** AP X-ray. Moderate hallux valgus.

motion (passive and active) of the metatarsophalangeal joint should be noted [14]. If pain and crepitus are present when evaluating the metatarsophalangeal joint, it often indicates that degenerative injuries are present, and this could change the choice of the surgical technique. Some authors have stated that around 5% of the patients have hypermobility of the metatarsocuneiform joint (mobility of more than 9 mm), and this should be assessed as well as the neurovascular status [15, 16]. Lesser toe deformities are often associated and could be a cause of discomfort, and this should be evaluated.

### 1.3. Radiological examination

Plain radiographs (AP and lateral) should be taken with the patient bearing weight (**Figure 2**). Angular measurement includes assessing of the hallux valgus angle (HVA), the first-second intermetatarsal angle (IMA), the distal metatarsal articular angle (DMAA), and the proximal phalangeal articular angle. The presence of osteoarthritis, joint congruity, and the amount of sesamoid subluxation are examined. All angular measurements should be made according to the guidelines set by the AOFAS Ad Hoc Committee on Angular Measurements [17]. The severity of the deformity can be classified as mild, moderate, or severe deformity [13].

## 2. Treatment

### 2.1. Conservative

Non-operative treatment should be attempted. Symptoms are often relieved by reducing friction over the prominent medial eminence. Recommendations about patient's footwear could be helpful; sometimes, a simple change in the type of shoes or size may reduce symptoms substantially [18]. Despite non-operative measures, some patients eventually need surgical treatment.

### 2.2. Operative correction

There are numerous surgical procedures for correction of HV deformities, which indicates that there is not only one procedure that is universally applicable for all patients. Usually, the choice of the procedure depends upon how rigorous the deformity is and where it is located. Options include proximal, shaft, or distal metatarsal osteotomies (associated or not to lateral release). Osteotomies of the cuneiform, arthrodesis of the metatarsophalangeal joint, and excisional arthroplasty have also been described. Some of the aforementioned surgeries may be performed through open or percutaneous surgery (MIS).

#### 2.2.1. Chevron osteotomy: open surgery

Distal metatarsal chevron osteotomy is an excellent treatment option in mild-to-moderate deformities, providing good results in the correction of deformity and symptoms [19–21]. The radiographic indications are hallux valgus angle less than  $40^\circ$  and first-second intermetatarsal angle less than  $20^\circ$ . With this procedure, a resection of the medial eminence, a distal metatarsal osteotomy, and a medial capsuloplasty are used to realign the great toe. Johnson et al. [22] and others [23–25] have reported good to excellent results with this procedure. After this osteotomy, the average correction of the HVA has been reported to be  $12\text{--}13^\circ$ , and the average correction of the IMA has been  $4\text{--}5^\circ$  [26].

This type of metatarsal osteotomy has some advantages: is stable, has a wide contact surface, has the ability to allow corrections of the DMAA, and admits weight bearing immediately after surgery [27]. However, it has some weakness due to a small power of deformity correction. To overcome this issue, an Akin phalangeal osteotomy and lateral soft tissue release can be added to augment angular correction [28, 29].

Lateral soft tissue release can be achieved through different procedures (open or MIS, through a medial or dorsal approach). The goals of this surgical gesture are to eradicate the lateral deforming forces and allow a better realignment of the first metatarsophalangeal joint by cutting the latero-plantar capsule, the transverse metatarsal ligament, the adductor tendon, and the lateral metatarsosesamoid ligament [27].

Several complications have been described with the chevron osteotomy: undercorrection and recurrence of the deformity are the most frequent ones. Recurrence could happen when the surgical indications are not respected in terms of angular values, and more severe deformities are treated. Undercorrection can be caused by a secondary displacement at the osteotomy

site. This was more frequent when no internal fixation was used, as the original technique described by Austin and Leventen [30]. Nowadays, internal fixation has shown to reduce the rate of loss of correction [22, 25].

Shortening is another complication to consider, and it may occur when too much bone had been removed. Postoperative transfer metatarsalgia has been reported as a result of this complication [31].

The most critical complication after a chevron osteotomy is an avascular necrosis (AVN) of the 1MT head. Some reports have shown an increased risk of AVN when lateral soft tissue release is combined with a distal chevron osteotomy [32, 33], although other studies state that this is a rare complication [34, 35]. The reported incidence of avascular necrosis (AVN) ranges between 0 and 20% [36, 37].

### 3. Percutaneous or minimally invasive surgery (MIS) of the forefoot

#### 3.1. Definition

Percutaneous surgery of the foot, also known as minimal incision surgery or *minimally invasive surgery* (MIS), allows interventions to be carried out through extremely small incisions without direct exposure of deep tissues, thus causing minimal injury [38]. This is done with the help of tactile sensation combined with radioscopy.

#### 3.2. History and generations

The applications of percutaneous surgery in hallux valgus correction were first introduced in the 1970s and 1980s [39]. It has since evolved into endoscopic, minimum-incision, and percutaneous techniques. In the last 10 years, there has been a growing interest in percutaneous techniques for HV correction especially in Italy and Spain, at the beginning. First-generation percutaneous technique was described by Isham [39] in which no internal fixation was needed. The second-generation technique was a distal transverse osteotomy of the 1MT stabilized with an axial wire [40, 41]. Recently, some comparative studies evaluating these procedures received a degree of recommendation C (poor-quality evidence for or against recommending intervention), although these results are being reviewed due to the omission of relevant studies [41–44]. The third-generation (TG) MIS involves procedures based on the design of chevron osteotomies with the need of screw fixation that has added extra stability and minor complications [45, 46].

#### 3.3. Current situation and indications

Forefoot MIS has experienced a vertiginous and sustained growth especially in the last decade. Clinical series and comparative studies have been published [47–50]. Additionally, cadaveric results [51, 52], technique reports [53], and radiological validations [54, 55] have been described. Despite the fact that for some authors percutaneous surgery of the forefoot lacks scientific support [56–58], recently two systematic reviews published support its indication in hallux valgus surgery [43–59].

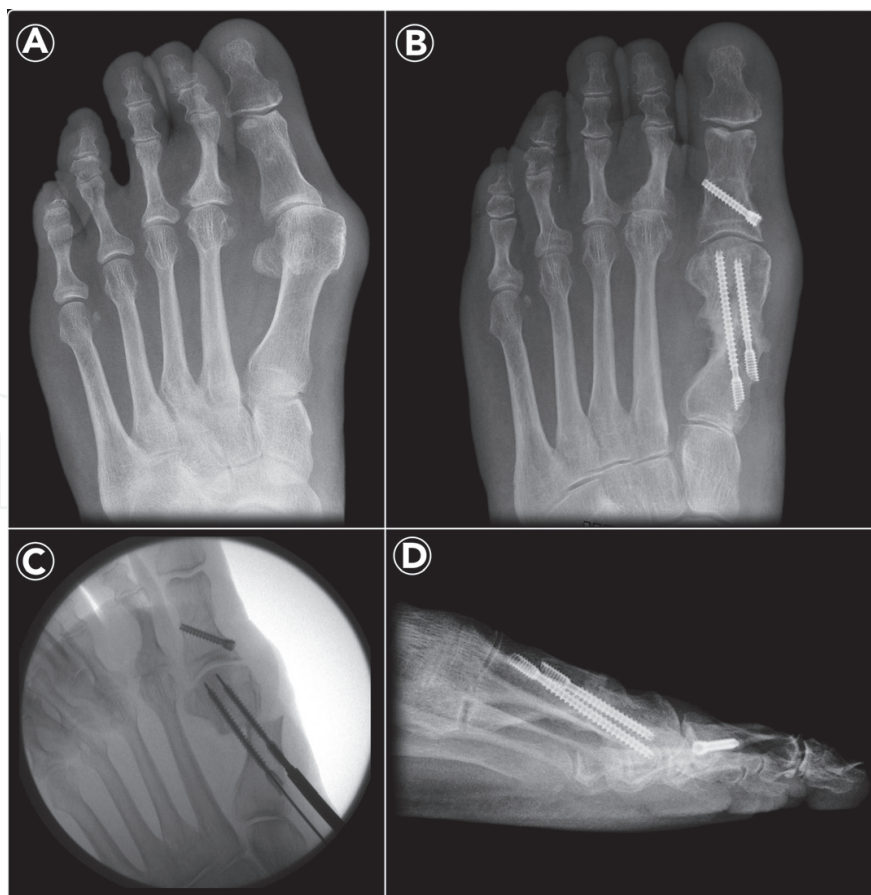

#### 4. Third-generation forefoot MIS

Considering the indications and potential advantages of percutaneous surgery, some authors experienced with osteotomies similar to the open chevron, although with conceptual differences. They can be divided into intra- or extra-articular osteotomies.

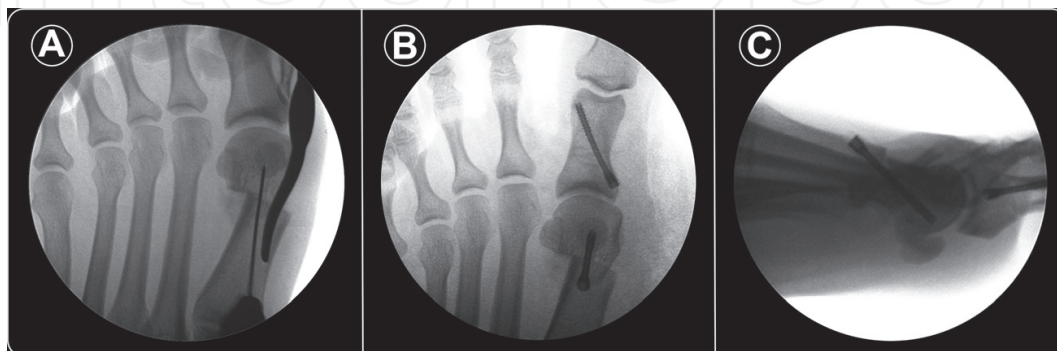Some examples of those performed proximal to the joint capsule (extracapsular) are as follows:

- **MICA** (*minimally invasive chevron Akin*) is performed at the neck of the first metatarsal (extra-articular) and requires two screws for the stabilization of the osteotomy associated with an Akin osteotomy. According to the authors, the development of this fixation (MICA) allows it to be used in severe HV deformity (maximum displacement of 100%) and truly marries the perceived advantages of an extracapsular first metatarsal osteotomy in which the soft tissue envelope is preserved with rigid internal fixation. As a result of evidenced movement of the osteotomy in some cases, the fixation technique was modified (tricortical fixation with proximal screw) to successfully avoid this problem. In 50–60% of cases, a percutaneous Akin osteotomy of the hallux proximal phalanx is also performed with percutaneous screw fixation. It showed good to excellent results, and around 90% of patients are satisfied or very satisfied with the results. The authors mentioned that the outcomes thus far suggest that the MICA technique may be associated with a lower risk of infection, less stiffness, and less pain. No reports exist of osteonecrosis with the MICA technique (**Figure 3**) [60–63].



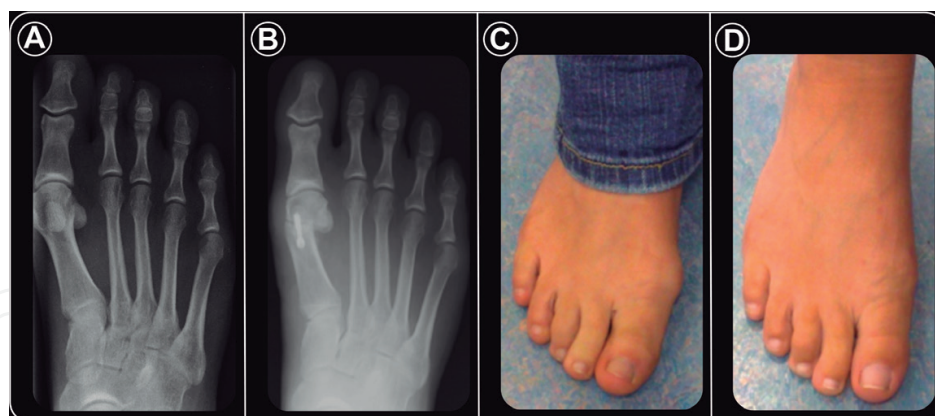
**Figure 3.** (A) AP view. Incongruous moderate hallux valgus. (B) MICA technique. (C) Intraoperative radioscopic. (D) Final lateral X-ray (courtesy of Dr. Vernois, Joel).

- **PERC** (*percutaneous, extra-articular reverse-L chevron osteotomy*): that is also performed on the metaphysis of the first metatarsal (1MT), and the main difference with other techniques is that the osteotomy is stabilized with a dorsal-to-plantar screw. In a case series (38 patients, 45 procedures), this technique showed an improvement of the AOFAS score of 62.5 (30–80) preoperatively to 97.1 (75–100) postoperatively. A total of 37 patients (97%) were satisfied. At the last follow-up, there was a statistically significant decrease in the HVA, the IMA, and the proximal articular set angle. The range of movement of the first metatarsophalangeal joint improved significantly. An additional percutaneous Akin osteotomy was performed in 82%, and percutaneous lateral capsular release was performed in 48%. According to the authors, this technique is reliable and reproducible and maintains an excellent range of movement (**Figures 4–6**) [46].
- **PECA** (*percutaneous chevron/akin*): technically, this is identical to MICA that showed comparable outcomes of the new technique (equated to open Scarf/Akin). Surgeries were done by a non-developer group (MICA). Regarding patient satisfaction, this technique showed excellent (84%) and good (16%) results in a comparative series. The PECA showed statistically significant superiority regarding the pain level in the early postoperative phase compared to open Scarf. There were no wound complications, and 24% of patients required removal of the screws because of prominence under the skin (**Figure 7**) [49].
- **Third-generation MIS technique**: described by Brogan et al., it needs one screw and K-wire to provide stability. In the initial series (45 ft), there was a statistically significant improvement in all three domains of the MOXFQ, proper correction of angular values (HVA and IMA), and overall toe length decreased by only 2 mm (range –11 to 13 mm). It showed no avascular necrosis (AVN), infection, hallux varus, nonunion, dorsal malunion of the distal fragment, metatarsalgia and/or incidence of recurrence. Other infrequent complications were described: screw backout, prominent metalwork, etc. [45]. In a comparative study (chevron MIS and open chevron), there were no significant differences. Clinical and radiologic postoperative scores in all domains were substantially improved in both groups. There were no significant differences in complications between the two groups. The third-generation MIS technique proved that it is a safe procedure (MIS) with good clinical outcomes for symptomatic mild-to-moderate hallux valgus at midterm results [64].

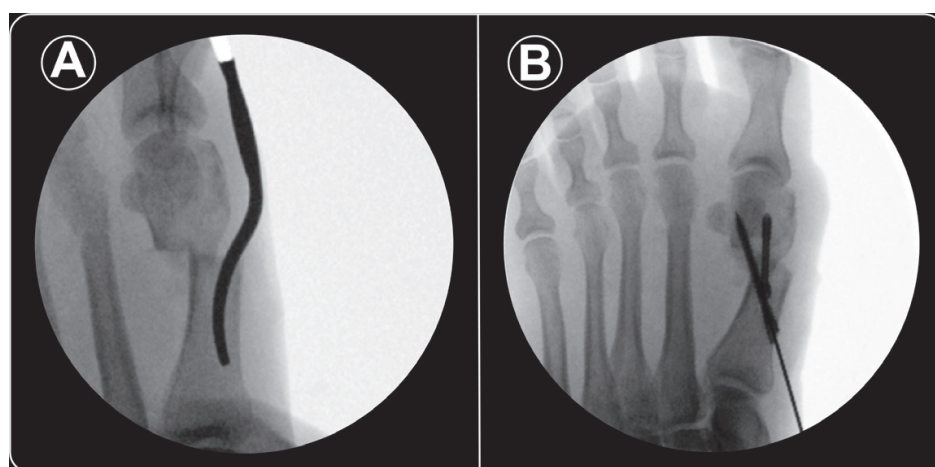


**Figure 4.** (A) Upon completion of the osteotomy, a designed 'pry bar' is introduced into the proximal canal via the site of the osteotomy to translate the metatarsal head in a lateral and plantar direction. (B) AP view. Final correction and fixation of the PERC and percutaneous Akin osteotomy. (C) Lateral radioscopic view. Obliquity of the fixation and MTT position (courtesy of Dr. Laffenêtre, Olivier).

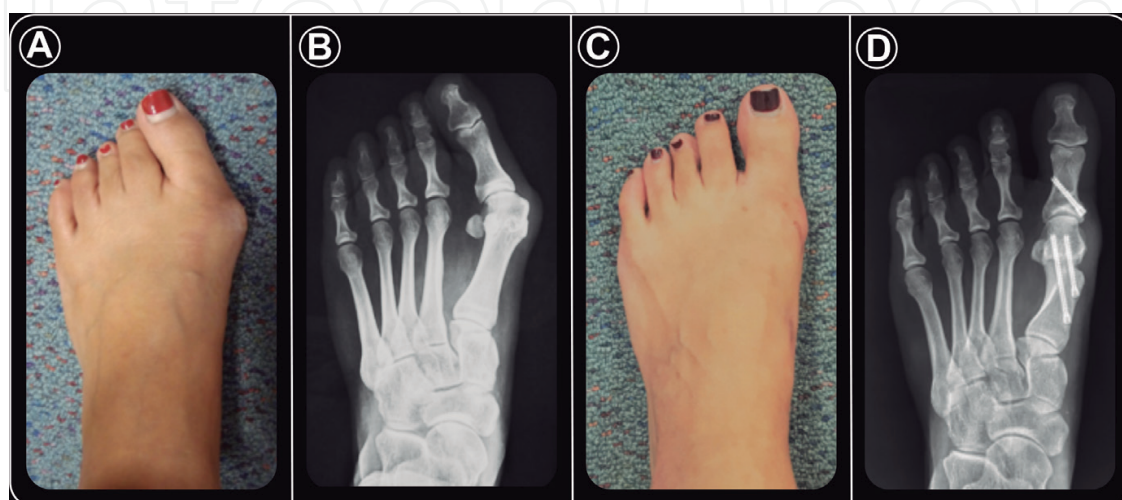




**Figure 5.** (A and B) AP view. Mild-to-moderate HV. Correction achieved. (C and D) Clinical images. Pre and postop (courtesy of Dr. Laffenêtre, Olivier).



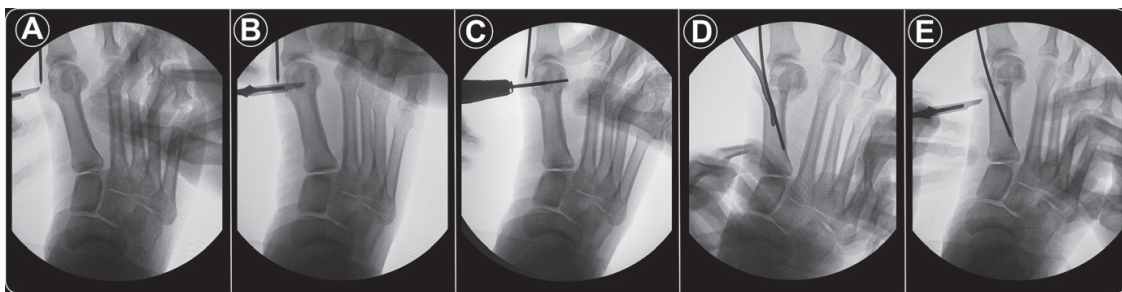
**Figure 6.** (A) Displacement of the metatarsal head. (B) Fixation with two screws; new technique and unpublished data (authorization of Dr. Laffenêtre, Olivier).



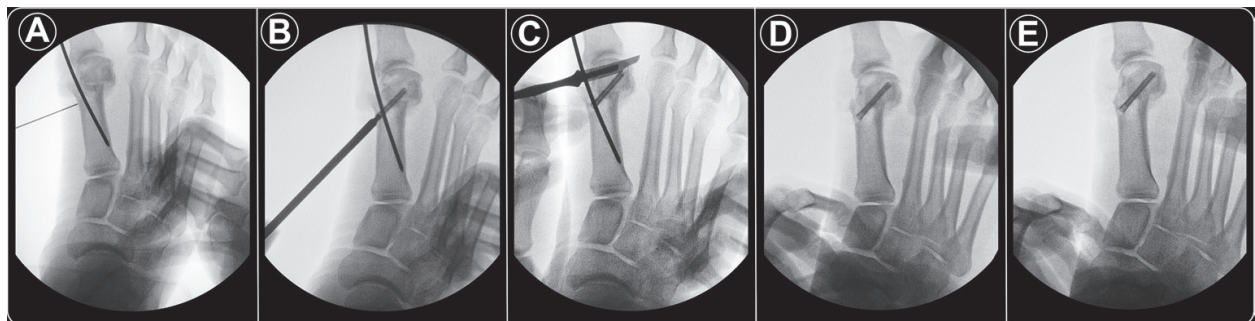
**Figure 7.** (A and B) Moderate HV. (C and D) Correction achieved with the PECA technique (courtesy of Lam, Peter).

An intra-articular technique has recently been described:

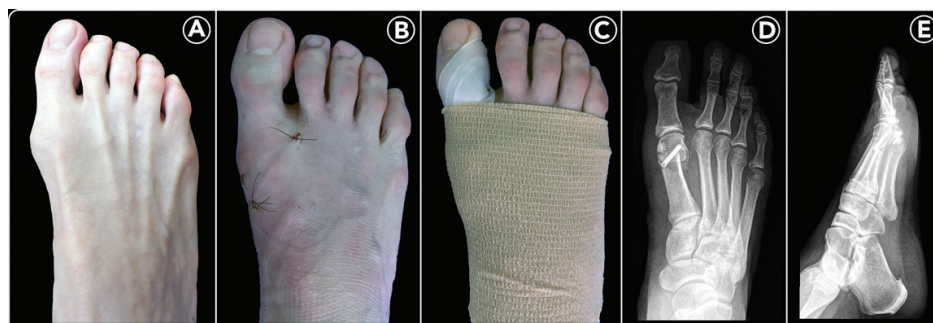- **PICO** (*percutaneous, intra-articular, chevron osteotomy*): the authors evaluated the radiological outcomes of 21 patients (24 ft) in a population of moderate hallux valgus. It showed a mean preoperative IMA of  $12.46^\circ$  (range  $11\text{--}15^\circ$ ) and a postoperatively (POP) of  $8.13^\circ$  (range  $5\text{--}10^\circ$ ; SD 1.16), with an average angular correction of  $4.33^\circ$ . The mean HVA was  $33.96^\circ$  ( $20\text{--}40^\circ$ ) before surgery, and the average POP was  $8.16^\circ$  (range  $3\text{--}15^\circ$ ), thus obtaining an average improvement of  $25.86^\circ$ . No metatarsal shortening or recurrence was observed (**Figures 8–10**) [54]. PICO offers theoretical advantages over other TG techniques described since it does not need fixation with two screws (only one is enough) and/or additional K-wire, which results in a shorter surgical time and complication rate, and also decrease costs. In addition, as it is done on the head of the 1MT, it offers greater stability and involves fewer surgical steps. Nevertheless, this novel



**Figure 8.** (A) Medial portal (P1). (B) Dorsal partial capsular detachment. (C) Entry point and perpendicular orientation of the Shannon burr. (D) Displacement of the metatarsal head using the 'Bosch method'. (E) Location of P2.



**Figure 9.** (A) Orientation of K-wire. (B) 3.0 mm conic screw insertion. (C) Lateral release portal (P3). (D and E) Remnant medial exostosis and its resection.



**Figure 10.** (A) Symptomatic mild hallux valgus. (B) PICO technique. One week postoperative (POP). (C) POP bandage correction. (D and E) Week 8 POP. AP and Lateral view.

technique needs a clinical and functional validation to be accepted as a valid and reproducible procedure, and this is what the other procedures have shown so far.

## 5. Possible concerns

The 'third-generation' (TG) chevron techniques reliably mimics the open chevron procedure with all its known virtues while it does not reproduce its disadvantages and complications. There is no doubt that this group of techniques reflects the future of percutaneous hallux valgus surgery. In relation to the results shown, we can mention that TG techniques are useful, effective, and (maybe) easier than open procedures. We emphasize that percutaneous surgery has an extensive learning curve, and therefore it may be difficult to imitate the results shown on already-published data.

## Author details

Jorge Javier Del Vecchio<sup>1\*</sup>, Miky Dalmau-Pastor<sup>2,3</sup> and Mauricio Esteban Ghioldi<sup>1</sup>

\*Address all correspondence to: javierdv@mac.com

1 Foot and Ankle Section, Department of Orthopaedics and Traumatology, Fundación Favaloro—Hospital Universitario, Buenos Aires, Argentine

2 Human Anatomy and Embryology Unit, Faculty of Medicine and Health Sciences, University of Barcelona, Barcelona, Spain

3 Faculty of Health Sciences, University of Vic-Central University of Catalonia, Manresa, Barcelona, Spain

## References

- [1] Coughlin MJ. Juvenile hallux valgus. In: Coughlin MJ, Mann RA, editors. *Surgery of the Foot and Ankle*. 7th ed. St. Louis: Mosby Year Book; 1999. pp. 270-319
- [2] Mann RA, Coughlin MJ. Adult hallux valgus. In: Mann RA, Coughlin MJ, editors. *Surgery of the Foot and Ankle*. 7th ed. St. Louis: C.V. Mosby; 1999. pp. 159-269
- [3] Myerson M. *Foot and Ankle Disorders, Hallux Valgus*. Philadelphia: WB Sanders Co; 1999. pp. 213-289
- [4] Coughlin MJ. Hallux valgus. *Journal of Bone and Joint Surgery*. 1996;**78-A**:932-966
- [5] Coughlin MJ. Hallux valgus. Causes, evaluation, and treatment. *Postgraduate Medicine*. 1984;**75**:174-187
- [6] Sim-Fook L, Hodgson AR. A comparison of foot forms among the non-shoe and shoe-wearing Chinese population. *The Journal of Bone and Joint Surgery. American Volume*. 1958;**40-A**(5):1058-1062



- [7] Inman VT. Hallux valgus: A review of etiologic factors. *The Orthopedic Clinics of North America*. 1974;**5**:59-66
- [8] Hohmann G. Der Hallux valgus und die ubrigen Zehenverkrummungen. *Ergebnisse der Chirurgie und Orthopädie*. 1925;**18**:308-376
- [9] Mann RA, Coughlin MJ. Hallux valgus—etiology, anatomy, treatment and surgical considerations. *Clinical Orthopaedics and Related Research*. 1981;**157**:31-41
- [10] Coughlin MJ, Roger A. Mann Award. Juvenile hallux valgus: Etiology and treatment. *Foot & Ankle International*. 1995;**16**(11):682-697
- [11] Kilmartin TE, Wallace WA. The significance of pes planus in juvenile hallux valgus. *Foot and Ankle*. 1992;**13**:53-56
- [12] Coughlin MJ, Shurnas PS. Hallux valgus in men. Part II: First ray mobility after bunionectomy and factors associated with hallux valgus deformity. *Foot & Ankle International*. 2003;**24**:73-78
- [13] Coughlin MJ, Jones CP. Hallux valgus: Demographics, etiology, and radiographic assessment. *Foot & Ankle International*. 2007;**28**(7):759-777
- [14] Smith RW, Reynolds JC, Stewart MJ. Hallux valgus assessment: Report of research committee of American Orthopaedic Foot and Ankle Society. *Foot and Ankle*. 1984;**5**:92-103
- [15] Klaue K, Hansen ST, Masquelet AC. Clinical, quantitative assessment of first tarsometatarsal mobility in the sagittal plane and its relation to hallux valgus deformity. *Foot & Ankle International*. 1994;**15**(1):9-13
- [16] Mann R, Coughlin MJ. Adult hallux valgus. In: Mann RA, Coughlin MJ, editors. *Surgery of the Foot and Ankle*. 6th ed. Mosby-Year Book: St. Louis; 1993. pp. 167-296
- [17] Coughlin MJ, Saltzman CL, Nunley JA II. Angular measurements in the evaluation of hallux valgus deformities: A report of the ad hoc committee of the American Orthopaedic Foot and Ankle Society on angular measurements. *Foot & Ankle International*. 2002;**23**: 68-74
- [18] Coughlin MJ, Thompson FM. The high price of high-fashion footwear. In: *Instructional Course Lectures, the American Academy of Orthopaedic Surgeons*. Vol. 44. Rosemont: The American Academy of Orthopaedic Surgeons; 1995. pp. 371-377
- [19] Donnelly RE, Saltzman CL, Kile TA, Johnson KA. Modified chevron osteotomy for hallux valgus. *Foot & Ankle International*. 1994;**15**(12):642-645
- [20] Potenza V, Caterini R, Farsetti P, Forconi F, Savarese E, Nicoletti S, Ippolito E. Chevron osteotomy with lateral release and adductor tenotomy for hallux valgus. *Foot & Ankle International*. 2009;**30**(6):512-516
- [21] Schneider W, Aigner N, Pinggera O, Knahr K. Chevron osteotomy in hallux valgus. Ten-year results of 112 cases. *Journal of Bone and Joint Surgery. British Volume (London)*. 2004;**86**(7):1016-1020
- [22] Johnson KA, Cofield RH, Morrey BF. Chevron osteotomy for hallux valgus. *Clinical Orthopaedics*. 1979;**142**:44-47

- [23] Hattrup SJ, Johnson KA. Chevron osteotomy: Analysis of factors in patients' dissatisfaction. *Foot and Ankle*. 1985;**5**:327-332
- [24] Leventen EO. The chevron procedure. *Orthopedics*. 1990;**13**:973-976
- [25] Pochatko DJ, Schlehr FJ, Murphey MD, Hamilton JJ. Distal chevron osteotomy with lateral release for treatment of hallux valgus deformity. *Foot & Ankle International*. 1994;**15**(9):457-461 Review
- [26] Coughlin MJ. Hallux valgus. *The Journal of Bone and Joint Surgery. American Volume*. 1996;**78**:932-966
- [27] Lee HJ, Chung JW, Chu IT, Kim YC. Comparison of distal chevron osteotomy with and without lateral soft tissue release for the treatment of hallux valgus. *Foot & Ankle International*. 2010;**31**:291-295
- [28] Mitchell LA, Baxter DE. A Chevron-akin double osteotomy for correction of hallux valgus. *Foot Ankle*. 1991;**12**:7-14
- [29] Juan M, Arauz Y, Del Vecchio J, Eksarho A, Ghioldi M, Escobar G, Arauz MEY. Cirugía "híbrida" del hallux valgus moderado: Resultados radiológicos a mediano plazo. *Tobillo y Pie*. 2015;**7**(1):43-47
- [30] Austin DW, Leventen EO. A new osteotomy for hallux valgus: A horizontally directed "V" displacement osteotomy of the metatarsal head for hallux valgus and primus varus. *Clinical Orthopaedics*. 1981;**157**:25-30
- [31] Klosok JK, Pring DJ, Jessop JH, Maffulli N. Chevron or Wilson metatarsal osteotomy for hallux valgus. A prospective randomised trial. *Journal of Bone and Joint Surgery*. 1993;**75-B**(5):825-829
- [32] Granberry WM, Hickey CH. Hallux valgus correction with metatarsal osteotomy: Effect of a lateral distal soft tissue procedure. *Foot & Ankle International*. 1995;**16**:132-138
- [33] Neary MT, Jones RO, Sunshein K, Van Manen W, Youngberg R. Avascular necrosis of the first metatarsal head following Austin osteotomy: A follow-up study. *The Journal of Foot and Ankle Surgery*. 1993;**32**:530-535
- [34] Mann RA, Pfeffinger L. Hallux valgus repair. *Clinical Orthopaedics*. 1991;**272**:213-218
- [35] Mann RA, Rudicel S, Graves SC. Repair of hallux valgus with a distal soft-tissue procedure and proximal metatarsal osteotomy. A long term follow-up. *Journal of Bone and Joint Surgery*. 1992;**74-A**:124-129
- [36] Blum JL. The modified Mitchell osteotomy-bunionectomy: Indications and technical considerations. *Foot & Ankle International*. 1994;**15**:103-106
- [37] Bonney G, Macnab I. Hallux valgus and hallux rigidus; a critical survey of operative results. *Journal of Bone and Joint Surgery*. 1952;**34-B**:366-385
- [38] De Prado M, Ripoll PL, Golano P. Cirugía percutánea del pie: Técnicas quirúrgicas, indicaciones, bases anatómicas. Masson, editor. 1 edición, Barcelona; 2003



- [39] Isham S. The Reverdin-Isham procedure for the correction of hallux abducto valgus. A distal metatarsal osteotomy procedure. *Clinics in Podiatric Medicine and Surgery*. 1991;**8**:81-94
- [40] Bosch P, Wanke S, Legenstein R. Hallux valgus correction by the method of Bosch: A new technique with a seven-to-ten-year follow-up. *Foot and Ankle Clinics*. 2000;**5**:485-498
- [41] Magnan B, Pezze L, Rossi N, et al. Percutaneous distal metatarsal osteotomy for correction of hallux valgus. *The Journal of Bone and Joint Surgery. American Volume*. 2005;**87**:1191-1199
- [42] Bauer T, de Lavigne C, Biau D, De Prado M, Isham S, Laffenetre O. Percutaneous hallux valgus surgery: A prospective multicenter study of 189 cases. *The Orthopedic Clinics of North America*. 2009;**40**:505-514
- [43] Bia A, Guerra-Pinto F, Pereira BS, Corte-Real N, Oliva XM. Percutaneous osteotomies in hallux valgus: A systematic review. *The Journal of Foot and Ankle Surgery*. Jan-Feb 2018;**57**(1):123-130
- [44] Maffulli N, Longo UG, Oliva F, Denaro V, Coppola C. Bosch osteotomy and scarf osteotomy for hallux valgus correction. *The Orthopedic Clinics of North America*. 2009;**40**: 515-524
- [45] Brogan K, Voller T, Gee C, Borbely T, Palmer S. Third-generation minimally invasive correction of hallux valgus: Technique and early outcomes. *International Orthopaedics*. 2014;**38**(10):2115-2121
- [46] Lucas y Hernandez J, Golanó P, Roshan-Zamir S, Darcel V, Chauveaux D, Laffenêtre O. Treatment of moderate hallux valgus by percutaneous, extra-articular reverse-L Chevron (PERC) osteotomy. *Bone Joint Journal*. 2016;**98-B**(3):365-373
- [47] Bauer T, Biau D, Lortat-Jacob A, Hardy P. Percutaneous hallux valgus correction using the Reverdin-Isham osteotomy. *Orthopaedics & Traumatology, Surgery & Research*. 2010;**96**(4):407-416
- [48] Biz C, Fosser M, Dalmau-Pastor M, Corradin M, Rodà MG, Aldegheri R, Ruggieri P. Functional and radiographic outcomes of hallux valgus correction by mini-invasive surgery with Reverdin-Isham and akin percutaneous osteotomies: A longitudinal prospective study with a 48-month follow-up. *Journal of Orthopaedic Surgery and Research*. 2016;**11**(1):157
- [49] Lee M, Walsh J, Smith MM, Ling J, Wines A, Lam P. Hallux valgus correction comparing percutaneous chevron/akin (PECA) and open scarf/akin osteotomies. *Foot & Ankle International*. 2017;**38**:838-846. DOI: 10.1177/1071100717704941
- [50] Radwan YA, Mansour AM. Percutaneous distal metatarsal osteotomy versus distal chevron osteotomy for correction of mild-to-moderate hallux valgus deformity. *Archives of Orthopaedic and Trauma Surgery*. 2012;**132**(11):1539-1546
- [51] Dhukaram V, Chapman AP, Upadhyay PK. Minimally invasive fore foot surgery: A cadaveric study. *Foot & Ankle International*. 2012;**33**:1139-1144

- [52] Yañez Arauz JM, Del Vecchio JJ, Codesido M, Raimondi N. Minimally invasive Akin osteotomy and lateral release: Anatomical structures at risk—A cadaveric study. *Foot (Edinb)*. 2016;**27**:32-35
- [53] Redfern D, Vernois J. Minimally invasive chevron akin (MICA) for correction of hallux valgus. *Techniques in Foot & Ankle Surgery*. 2016;**15**:1
- [54] del Vecchio JJ, Ghioldi ME, Raimondi N. Osteotomía en tejadillo (Chevron) con técnica mínimamente invasiva en la región distal del primer metatarsiano. Evaluación radiológica. *La Revista de la Asociación Argentina de Ortopedia y Traumatología* 2017;**82**(1):19-27
- [55] Huang PJ, Lin YC, Fu YC, Yang YH, Cheng YM. Radiographic evaluation of minimally invasive distal metatarsal osteotomy for hallux valgus. *Foot & Ankle International*. 2011;**32**(5):S503-S507
- [56] Roukis TS. Percutaneous and minimum incision metatarsal osteotomies: A systematic review. *The Journal of Foot and Ankle Surgery*. 2009;**48**:380-387
- [57] Maffulli N, Longo UG, Marinozzi A, et al. Hallux valgus: Effectiveness and safety of minimally invasive surgery. A systematic review. *British Medical Bulletin*. 2001;**97**:149-167
- [58] Trnka HJ, Krenn S, Schuh R. Minimally invasive hallux valgus surgery: A critical review of the evidence. *International Orthopaedics*. 2013;**37**(9):1731-1735
- [59] Caravelli S, Mosca M, Massimi S, Costa GG, Lo Presti M, Fuiano M, Grassi A, Zaffagnini S. Percutaneous treatment of hallux valgus: What's the evidence? A systematic review. *Musculoskeletal Surgery*. 28 Oct 2017
- [60] Jowett CRJ, Bedi HS. Preliminary results and learning curve of the minimally invasive chevron akin operation for hallux valgus. *The Journal of Foot and Ankle Surgery*. 2017;**56**(3):445-452
- [61] Redfern D, Gill I, Harris M. Early experience with a minimally invasive modified chevron and akin osteotomy for correction of hallux valgus. *Journal of Bone and Joint Surgery. British Volume (London)*. 2011;**93**(Suppl IV):482
- [62] Vernois J, Redfern D. Percutaneous chevron: The union of classic stable fixed approach and percutaneous technique. *Fub Sprunggelenk*. 2013;**11**:70-75
- [63] Walker R, Redfern D. Minimally invasive hallux valgus correction: The MICA technique. *Journal of Bone and Joint Surgery. British Volume (London)*. 2012;**94**(suppl XXII):38
- [64] Brogan K, Lindisfarne E, Akehurst H, Farook U, Shrier W, Palmer S. Minimally invasive and open distal chevron osteotomy for mild to moderate hallux valgus. *Foot & Ankle International*. 2016;**37**(11):1197-1204