Chapter 8

Urinary Tract Tuberculosis

Gerardo Amaya-Tapia and
Guadalupe Aguirre-Avalos

Additional information is available at the end of the chapter

http://dx.doi.org/10.5772/intechopen.76063

Abstract

Urinary tract tuberculosis (UTTB) is an insidious disease with non-specific constitutional symptoms that are often unrecognized and lead to delayed diagnosis. Advanced UTTB may cause loss of kidney function. In the majority of literature, UTTB is reviewed together with genital tuberculosis because often both sites are involved simultaneously; "Genitourinary tuberculosis" (GUTB) is the most common term used in the literature. However, the term may cause confusion because the clinical presentation and diagnosis approach is very different, and does not always occur simultaneously. UTTB is the term used here as we encountered tuberculosis involvement of urinary tract only. This book chapter is a comprehensive review of the epidemiology, pathophysiology, clinical presentation, diagnosis approach, and current treatment of this disease.

Keywords: tuberculosis, urinary tract infection, renal tuberculosis, extra-pulmonary tuberculosis, genitourinary tuberculosis

1. Introduction

Throughout history, tuberculosis (TB) has been identified as a respiratory disease, with prominent symptoms as cough, fever, and wasting. Current clinical experience reveals that the lungs are involved in 80–90% of all TB patients not infected by human immunodeficiency virus (HIV). Extra-pulmonary forms are more common in people co-infected with HIV where genitourinary tuberculosis (GUTB) represents 27% [1].

GUTB is a term coined by Wildbolz in 1937 [2]; it is a worldwide disease, but shows a more destructive behavior in developing countries. The kidney is the most common site of GUTB [3], and it usually affects adults between the second and fourth decades of life and is reported

as being rare in children [4, 5]. Clinical renal TB is a chronic process that can start many years after the initial lung infection [6].

Renal involvement in TB can be part of a disseminated infection or a localized GUTB disease. With renal disease progression, extensive areas of papillary necrosis can cause formation of cavities that destroy the renal parenchyma and can migrate into the collecting system. Advanced disease may cause obstructive uropathy, bladder defects, and loss of kidney function [7].

UTTB is underdiagnosed in most health care centers; the clinicians must have a high degree of suspicion for UTTB in patients presenting with non-specific symptoms, culture-negative, pyuria, and for whom imaging studies show some typical findings of UTTB. Acid fast bacilli (AFB) microscopy and Lowenstein Jensen (LJ) culture are the tests most used in health institutions. AFB stain has a poor sensitivity and false positive can result from mycobacteria external genital colonization or by the presence of precipitates that resemble AFB. Although, LJ cultures have a better sensitivity, it may require around 8 weeks to obtain growth and identification [8]. In addition to other forms of extra-pulmonary tuberculosis, the amplification tests of deoxyribonucleic acid (DNA) have been used with good results, increasing the sensitivity, specificity and shortening the time to obtain the results. However, UTTB diagnostic requires a comprehensive approach and not just the use of a single test.

The initial treatment for TB in adults consists of the association of three or four different drugs, an intensive phase of 2 months of isoniazid (INH), rifampin (RIF), pyrazinamide (PZA), and ethambutol (EMB) followed by a continuation phase of 4 months of INH and RIF [9].

2. Epidemiology

The 2017 edition of the World Health Organization global TB report includes data available from 201 countries and territories that account for over 99% of the world's population. In 2016, a total of 6.3 million new cases of TB were reported and extra-pulmonary TB represented 15% of the cases notified, ranging from 8% in the Western Pacific Region to 24% in the Eastern Mediterranean Region [10]. According to other registers, of the total TB cases reported, the most frequent types of extra-pulmonary TB were lymphatic (14.8–40.4%), pleural (7.8–19.8%), bones and/or joints (3.5–11%), and GUTB (1.7–6.5%) [11, 12]. Involvement of the kidneys is the most common form of tuberculosis of the genitourinary tract [13].

In UTTB, a history of pulmonary TB is present in 17.7–25.8% [14–16]. The time interval between the onset of primary pulmonary TB and development of GUTB has a mean interval of 3–10 years in more than 50% of patients [14, 15]. In frequency, renal involvement is the most common finding following by ureteric and bladder involvement [16]. Simultaneous involvement of kidney, ureter, and bladder has been reported until a 25.8% [15, 16]. The incidence of active pulmonary TB concurrent with UTTB varied from 10 to 25.8%.

The proportion of immune-compromising conditions, such as malignancy, diabetes mellitus, chronic renal failure, and immunosuppressive drug use, are found as 46.7% [14]. The incidence of TB has been estimated to be as much as 10-fold higher among renal failure patients than among the general population [17].

3. Pathogenesis

Pulmonary infection is the primary focus in most cases of TB. After exposition, the bacilli remain stored in macrophages, where they slowly multiply, UTTB is the result of hematogenous spread from the lungs. Once the bacilli reach the circulation system, it can be distributed to all parts of the body, especially those sites with adequate conditions for its multiplication and with local immune deficiencies [18, 19]. The lymphatic nodes, encephalus, and urinary tract are some of the most frequent sites involved [20, 21].

The kidneys, and possibly the prostate and seminal vesicles, are often the primary sites of GUTB. All other genital organs, including the epididymis and bladder, become involved by ascent or descent of *Mtb* from a source elsewhere in the genitourinary tract [22]. *Mtb* bacilli are shed into the urine; they spread into the urinary tract, involving the renal pelvis, ureters and bladder; the urinary tract mucosa may be ulcerated, thin and without contractility [4]. In most patients, acquired cellular immunity develops and there is inhibition of bacilli multiplication and containment of the disease by the formation of microscopic granulomas, leading caseous necrosis with local tissue destruction [18].

The infection occurs initially in the medullary region, where granulomatous lesions can occur. If, in the course of primary infection, cell-mediated immunity develops and the proliferation of organisms is limited by competitive macrophages, this results in the formation of granulomas in which dormant bacilli can be maintained for long periods, leading caseous necrosis with local tissue destruction. When the bacilli are spilling down into the nephrons, they are trapped in the loop of Henle, establishing new foci of infection [18]. The multiple focus of microscopic necrosis lead macroscopic lesions that rapidly involve the renal papilla, causing fibrosis that can cause ureteral damage, with dilations intercalated with strictures, which constitutes an important TB sign on the pyelogram [23].

Sites of the urinary tract where there are natural narrow strictures, such as the calyceal neck, the pelvi-ureteric junction, and the uretero-vesical junction are the sites that suffer strictures more frequently. Steroid therapy may be useful in the early stages of scarring and could reduce the risk of stenosis that can lead to urinary obstruction and irreversible kidney damage [24]. A mass lesion may result from massive destruction and coalescence of granulomas, if they do not rupture into the adjoining calyx [25].

Hypercalcemia may occur, usually secondary to abnormal cortisol production by granulomatous tissue [26]. Although calcification is unusual in the early stages of the disease, nearly every end-stage tuberculosis kidney contains calcification. Hydronephrosis or hydrocalicosis may be the final stage, and may lead to a non-functioning, calcified kidney of any size; this process is called autonephrectomy [24].

4. Clinical presentation

UTTB has an insidious onset, no specific symptoms with atypical presentations [27], which lead to difficulty and delay the diagnosis in most health care centers [19, 20, 22, 28]. The majority

Ref	Author, country	Year*	Patients no.	Fever	Flank pain	Dysuria	Hematuria	Pyuria	Renal failure
[13]	Krishnamoorthy, India	2017	110	NR	27.3	25.5	11	NR	1.8
[14]	Altiparmak, Turkey	2015	79	43	38	51	79.1	67.1	19
[15]	Wagaskar, India	2016	31	29	45.1	32	19.4	NR	35.4
[16]	Zhang, China	2016	120	22.5	49.1	60.8	25	NR	NR
[35]	García-Rodríguez, Spain	1994	81	34.6	56.8	67.9	4.9	19.8	1.2
[36]	Gokce, Turkey	2002	174	19.5	43.5	43.1	39.6	NR	NR
[37]	Ye, China	2016	193	NR	49.2	61.1	63.2	19.2	NR

*Year of publication; NR, not reported.

Table 1. Clinical and laboratory features in UTTB (percent).

of patients present local symptoms such as frequent voiding, dysuria, pyuria, pain (back, flank or abdominal), and microscopic or macroscopic hematuria [4, 28–31]. Systemic symptoms of fever, night sweats, weight loss, and anorexia are less common [4, 29–31].

In a series of 115 cases with GUTB, the most common symptoms were reported to be flank pain, nicturia, frequent voiding and dysuria [32]. Figueiredo and Lucon [33] reported that storage symptoms (urinary frequency, urgency, urgency incontinence, nocturia), dysuria, and hematuria were the most common symptoms on admission, affecting 50.5, 37.9 and 35.6% of cases, respectively. Loin pain and fever were reported less frequent (34.4 and 21.9%, respectively).

Lower urinary symptoms occur whenever the disease spreads down to the ureters and bladder. Urinary symptoms suggestive of urinary tract infection, accompanied by pyuria and hematuria with no bacterial growth, suggest UTTB [7, 21, 34]. Pyuria and/or microscopic hematuria are present in more than 90% of cases. Heavy proteinuria and cellular casts are not generally seen and the plasma creatinine concentration is usually normal [21]. Advanced disease may cause obstructive uropathy, bladder defects, and loss of kidney function [7]. **Table 1** summarized the most frequent findings in large recent series of UTTB.

5. Case report

A 43-year-old woman was admitted to the hospital for fever, dysuria, and gross hematuria. She has a history of 2 years with progressive malaise, weight loss, and recurrent episodes of fever and dysuria that were treated with different antibiotics. Renal TB was diagnosed 1.5 years prior, receiving treatment during 6 months, improving her clinical conditions. However, despite anti-TB therapy, she continued having recurrent episodes of fever and dysuria. She also reports having intermittent diarrhea for 1 year and fever with flank pain for 3 months. Her physical examination revealed a chronically ill woman with fever and oral candidosis. Cardiothoracic examination was normal with the exception of tachycardia. Abdominal examination revealed diffuse abdominal tenderness with flank pain, and lower limb edema was noted. Laboratory

studies revealed urinalysis with pyuria and hematuria. Two serologies for antibodies to HIV were positive. The smear of urine staining with Ziehl-Neelsen (ZN) demonstrated AFB, and mycobacteria cultures were performed. Her chest x-ray showed diffuse bilateral infiltrates consistent with pulmonary tuberculosis (**Figures 1** and **2**). Renal ultrasonography (USG) showed both kidneys enlargement with marked dilation of renal pelvis and calyces. The findings on conventional urography were stricture sites of the ureters and renal pelvis with severe hydronephrosis and ureter distortion (**Figures 3** and **4**). An abdominal computed tomography (CT) showed a large abscess in psoas muscle (**Figures 5** and **6**). Initial empiric antimicrobial therapy with ceftriaxone, ciprofloxacin, and anti-TB therapy were started. The abscess was aspirated by external incision with complete drainage. Cultures for pyogenic bacteria of the psoas abscess and urine were both negatives. A polymerase chain reaction (PCR) test for *Mtb* in urine was positive (**Figure 7**). The patient was discharged home after 8 days of hospital stay.

The patient was re-admitted to the hospital 6 days after home stay. She continues with fever and abdominal discomfort. On the hospital day seven, her condition started to deteriorate

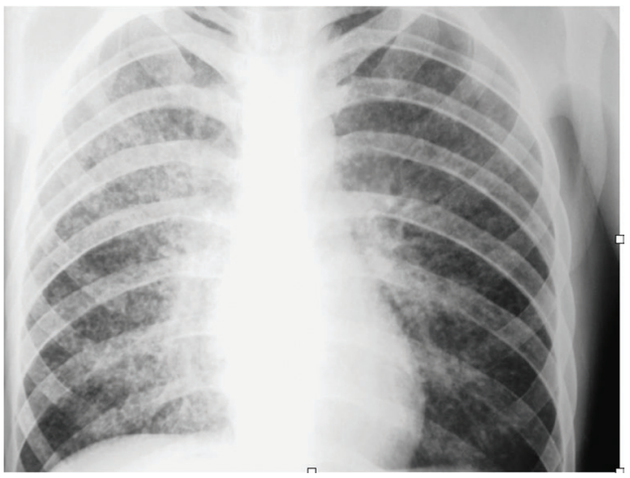

Figure 1. Chest radiograph showing diffuse micro-nodular infiltrates in both lung fields.

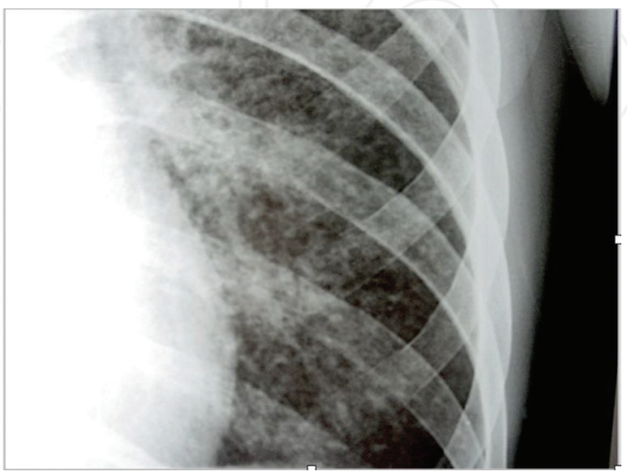

Figure 2. Magnified view of the left down lobe shows multiple micro-nodular infiltrates.

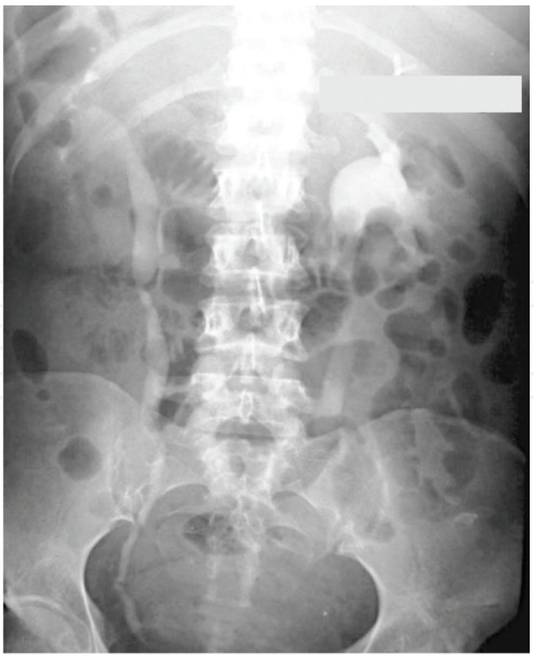

Figure 3. Intravenous urography revealing a non-functioning left kidney. Important deformity and dilatation of the collecting system, with ureteral tortuosity.

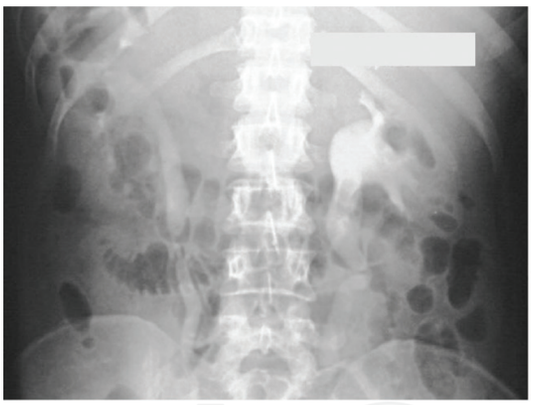

Figure 4. Left renal pelvis with severe hydronephrosis and ureteral distortion.

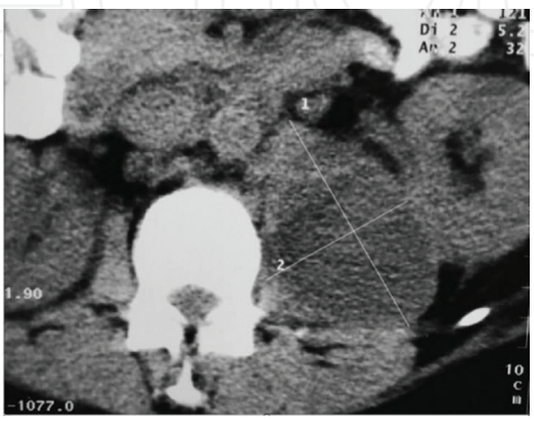

Figure 5. Axial CT revealing involvement of left psoas muscle and para-aortic space with displacement of the left kidney.

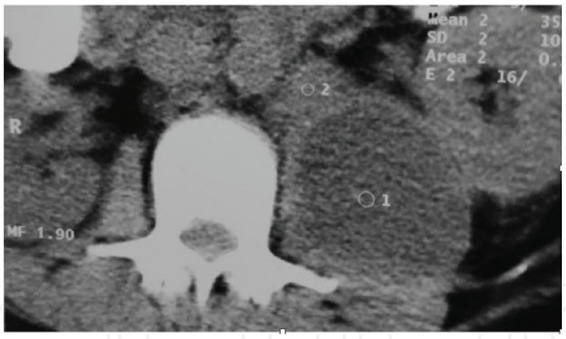

Figure 6. Axial CT revealing left psoas muscle abscess of 7 × 5 cm (1) and para-aortic lymph nodes (2).

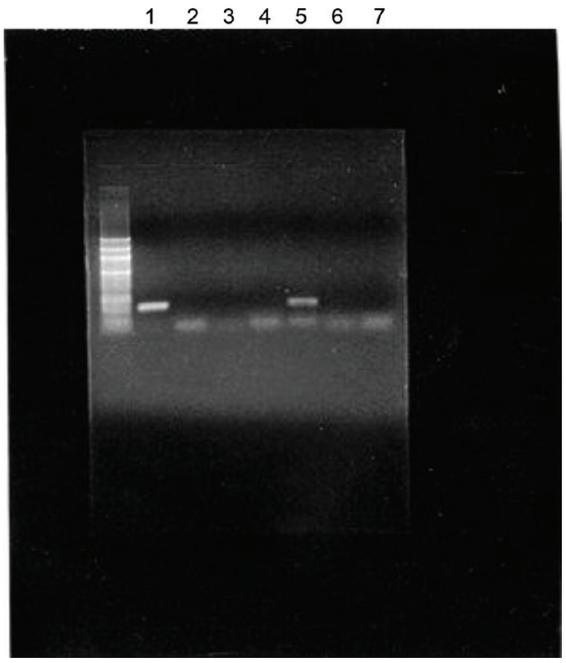

Figure 7. A representative image of PCR showing a DNA product of 200 base pairs for the first amplification. A positive control on the first line with a positive test on line 5.

and she died despite aggressive support Mycobacterial culture media subsequently yielded *Mtb* susceptible to all primary anti-TB drugs.

6. Diagnostic approach

The diagnosis of UTTB is a challenge owing to the insidious onset of UTTB with few and non-specific symptoms, technical difficulties to isolate *Mtb* and the long time required to confirm the diagnosis by classical conventional methods of cultivation, lack of awareness of physicians, and poor care-seeking behavior [33, 38].

The diagnosis of UTTB is usually performed in patients with clinical manifestations or abnormal urinalysis with findings that suggest UTTB. Urinalysis may vary from mild changes, such

as proteinuria and leukocyturia, to extreme pyuria, sometimes accompanied by hematuria. There are some characteristics in urine examination that suggest a diagnosis of renal TB, such as acid pH, leukocyturia and/or hematuria, associated with negative urine culture for the usual bacteria that causes urinary tract infection [23].

There are several diagnostic methods for this entity. Here, we review the most common procedures used: (1) ZN staining and cultures isolation for *Mtb* in urine, (2) PCR for *Mtb*, (3) imaging studies, and (4) histopathological evidence for TB [14].

6.1. ZN stain and cultures for *Mtb* in urine

AFB can be seen in centrifuged urine by ZN staining, but it has low sensitivity when only few bacilli are seen. Also, it can be the result of urine contamination by non-pathogenic *Mycobacterium* spp., which can lead to false positive results [21].

Culture and identification provide a specific diagnosis, but might not be available for 2–3 weeks or longer. Multiple samplings should be obtained to increase test sensitivity; at least three different samples on LJ solid culture medium are recommended to maximize the likelihood of a positive result. Urine cultures are regularly negative, unless there is severe bladder dysfunction. Among patients with active renal TB, 30–40% of single urine specimens will be positive by *Mycobacterium* culture [39, 40]. BACTEC showed to be a better culture method compared to LJ, with a sensitivity of 37.5% and a specificity of 100% and the mean detection time for *Mtb* was 24.0 days by L-J medium culture versus only 12.8 days by BACTEC [41, 42].

6.2. Polymerase chain reaction for *Mtb*

The PCR assay has been extensively used as diagnosis in many forms of extra-pulmonary TB [43, 44], including some UTTB case reports [45, 46].

As a rapid and sensitive diagnostic method, PCR for *Mtb* identification in the urine has become the ideal diagnostic tool in recent years. It allows to make a diagnosis even when there are few bacilli and AFB detection is not possible. The sensitivity of AFB detection by ZN technique is between 42.1 and 52.1%. The sensitivities of culture methods vary from 10 to 90% while PCR in detecting *Mtb* in urine have a sensitivity that varies from 25 to 93% and a high specificity of 95–100% [38, 47–50]. In a prospective study in 42 patients where PCR was used, it showed a better sensitivity than the urine culture (80.9% against 30.9%); the author concludes that the PCR is far superior diagnosis technique for UTTB with high sensitivity and specificity, avoiding the retard of the start of therapy [51].

In the recent years, there has been important effort to increase the PCR for *Mtb* detection capacity, to avoid false positives by contamination and to determine his utility in different clinical samples [52–54]. In comparison with the traditional PCR of a single amplification, nested PCR consists of performing a second DNA step in order to increase sensitivity. According to the amount of DNA that is obtained, the nested PCR can enhance the sensitivity in approximately 1000 times than the PCR of a single amplification [55–57].

In a study with 417 clinical samples (including 28 of urine), the nested PCR for *Mtb* had a sensitivity of 97% and a specificity of 92% including positive results in some patients with negative

culture. The authors concluded that the nested PCR is superior in sensitivity and rapidity than the traditional methods [57]. Nested PCR display a better sensitivity than the first DNA amplification, increasing the detection limit from 10 pg to 10 fg that is equivalent to two cells in the second amplification. The great amount of DNA in the second step of the nested PCR make easy the detection; it has been reported that during the first amplification, many positive samples gave a relatively weak or doubtful band. In contrast, in the second amplification a a strong positive band was observed [57].

6.3. Imaging studies

Although it is usually stated that imaging studies are only suggestive of the disease and should not be used for the confirmation or exclusion of UTTB [58], the intravenous urography (IVU) has been the image study more used for this entity; anatomical alterations of the collecting system can be seen with some facility. USG, CT, and magnetic resonance imaging (MRI) are less invasive methods that are better for detecting lesions in organs and tissues, including tumors, abscesses and calcifications; these can be done in addition to the IVU [59].

6.3.1. Plain radiograph

UTTB commonly results from hematogenous spread from a pulmonary focus; nevertheless, only 36.5% of patients with UTTB have a previous diagnosis of TB or abnormal imaging studies [5]. Chest radiograph will be normal in half the patients [60]. But, only 10% of chest radiograph will show signs of active TB [60, 61].

The greatest use of simple radiography is to demonstrate calcifications that can represent infections in extra-pulmonary sites, such as lymph nodes, liver, and spleen. Also, simple radiography can identify psoas abscesses and abnormalities of the spine [4, 62]. In UTTB, calcified lesions are mainly located in renal and upper collector system in 24–44% of cases [61], and this finding may be the first sign that TB is present [60]. Fine calcifications that were previously unidentifiable are now much better seen with CT [59].

Calcifications can be small calcifications, multiple, or large single calcifications [63]. These are usually amorphous calcifications located in the renal parenchyma or can take the form of the collecting system where they lodge and tend to be granular or curvilinear [22, 64]. The calcified caseous tissue in the kidneys may look like ground glass, known as "putty kidney". Premkumar et al. [65] termed "putty kidney" if the uniform calcification was greater than 1 cm in diameter.

Apperson et al. [66] emphasized the difficulty of differentiating calcifications from calculi in renal TB. In their cases of renal TB, 9.3% had discrete calculi and 8.7% had parenchymal calcification.

6.3.2. Intravenous urography

IVU has been considered the radiographic procedure of choice due to its ability to show the collector system like no other, and less frequently modern techniques such as computerized axial tomography and magnetic resonance are also used [67]. Early findings are best demonstrated on contrast-enhanced tomography which is replacing IVU as the investigation of choice in that situation. In a retrospective study conducted in Spain, IVU guided the diagnosis

in 28/32 cases (87.5%), with calculus lesions, bladder alterations, hydronephrosis, calcifications and ureteral stenosis as the most common alterations [68]. However, 10–15% of patients with active UTTB may have normal urographic findings [69].

Early alterations of UTTB are located mainly in calyces, UVI can show minimal calyceal dilation and loss of calyceal sharpness [61]. Although the calyceal damage is an early sign of UTTB, papillary necrosis could be the first sign observed [59]. As the disease progresses, the irregularity of the calices increases and may have a moth-eaten appearance [4, 25]. Other advanced manifestations include extensive cavitation, fibrotic strictures, cortical scars, mass lesions, calcification, autonephrectomy, perinephric abscess, and fistula formation [60].

6.3.3. Ultrasonography

USG is a readily available technique for demonstrating the various morphologic abnormalities found in renal TB [18, 70] and is a convenient method for guiding needles for fine-needle aspiration cytology (FNAC) [71, 72]. USG has convenient, low-priced, and non-invasive advantages; a disadvantage is that a mass may be missed if its echogenicity is similar to the renal parenchyma.

Traditionally, USG has been considered of less value than IVU or CT in UTTB cases [6, 73]. USG has limitations in detecting subtle urothelial lesions, as well as isoechoic parenchymal masses and is not useful for evaluating renal function [65, 69]. However, a well-detailed study can provide valuable information. In a large retrospective study, the coincidence rate of USG in the diagnosis of renal TB was 58.9% [74]. As the disease progresses, both an infiltrative pattern affecting the tissues and a pattern that affects the collecting system can be observed. In the first case, papillary destruction, calcifications, infected debris, hypoechoic masses or abscesses can be observed, in the second case dilated calyces, small renal pelvis, hydronephrosis, distortion of renal morphology, deformity of the ureters, and bladder atrophy can be found [75, 76].

On the USG, renal abscess is presented as a semi-solid echogenicity and a thick ill-defined wall that can extend and drain, causing perinephric abscess that later may cause a cutaneous fistula [21, 68].

6.3.4. Computed tomography

CT is useful both in the diagnosis of renal TB and in assessing its severity in terms of loss of renal function and involvement of other organs in the abdomen [77]. It directly visualizes the renal parenchyma, irrespective of renal function and, in addition, assesses extrarenal spread of the disease. The CT nephrogram is not as dependent on renal function as is an IVU. CT is also useful in identifying renal scars, mass lesions, and urothelial thickening, all of which are common findings in renal TB [78].

In general, CT shows more details of pathologic anatomy due to the availability of axial images for review and is superior to retrograde pyelography, IVU, and USG in detecting multiple small urothelial lesions [79]. It can detect calcification with greater accuracy, precision, and sensitivity [61] and is the most sensitive modality for identifying renal calcifications, which occur in over 50% of cases of GUTB [80]. CT is also the best modality for demonstrating the extent, nature, and distribution of calcification within the abnormal kidney [65]. The

implementation of CT urography with multidetector technology improves the assessment of renal and urinary tract lesions using reformatted images [17].

The disadvantages of CT include its inability to identify very early changes of TB such as small parenchymal and subtle papillary necrosis. UTTB is characterized by a vast presentation that is of great diagnostic value [19, 62, 81]. In early disease, CT can detect obstruction of a single major or a group of minor calyces as well as abnormalities in the collector system (dilatation or contraction of the renal pelvis). In advance disease, the kidneys are small with replacement of parenchyma by one or more low density areas. Parenchyma or calyces calcifications are seen at 37% [81]. Newer scanners, if used meticulously, may be able to identify small granulomas. The needs to use contrast and radiation issues, especially in young patients, are other limitations of CT studies that are not encountered on USG [78].

6.3.5. Magnetic resonance imaging

MRI provides morphological details of the kidneys as well as excellent delineation of the ureters [67]. It allows characterization of various renal masses and can provide valuable information contributing to their clinical management [82, 83]. It is particularly useful in pediatric or pregnant patients or when ionizing radiation and iodinated contrast cannot be administered. Non-contrast MRI is especially useful in patients with renal failure [67].

Magnetic resonance urography (MRU) comprises an evolving group of techniques with the potential for optimal non-invasive evaluation of urinary tract abnormalities. Both static-fluid (non-contrast, heavily T2W sequences) and excretory MRU (performed during the excretory phase of enhancement after intravenous gadolinium) can be combined with conventional MRI for comprehensive evaluation of the urinary tract. MRU demonstrates the ureters in their entirety and is useful for confirming the presence of stenosis [84]. It is most successful in patients with moderately to severely dilated or obstructed collecting systems and in impaired renal function situations [84, 85]. MRU performed with a distended urinary bladder allows better visualization of the upper urinary tract [86]. Time-resolved dynamic contrast-enhanced MRU has been used in the evaluation of ureteral peristalsis in GUTB [87]. In view of the possibility of nephrogenic systemic, fibrosis/nephrogenic, fibrosing dermopathy, caution should be exercised while administering gadolinium in patients with compromised renal function [88]. There are very few articles available in the literature on MRU in renal TB and hence the appearance of the same is still not widely known.

6.3.6. Fine-needle aspiration cytology

Sonographically guided FNAC is useful as a means of diagnosing of renal and genital (epididymitis and epididymo-orchitis) abscess or masses, and is of value in defining the granulomatous nature of sonographically visible lesions [72]. Histologic findings of renal or genital TB are similar to those of TB elsewhere in the body (granuloma formation, non-specific inflammatory infiltrate). The granulomas appear with central Langerhans cells surrounded by lymphocytes, fibrocytes, and epithelioid cells, which later progress to central caseous formation and varying degrees of fibrosis and calcification. AFB may be detected on FNAC smears in up to 60% of these patients [72, 89].

The advantages of USG-guided FNAC are that it is rapid, inexpensive, versatile, does not require the injection of any contrast medium, and can be easily repeated when necessary [90]. USG-guided FNAC is now widely accepted as a safe diagnostic procedure in various neoplastic and non-neoplastic disorders [91, 92].

7. Treatment

A multidisciplinary approach with infectious disease and urology teams is crucial to provide optimal patient care; tuberculosis medications remain the cornerstone of treatment and surgical management is reserved for specific indications. There is lack of standardized treatment regimen for UTTB, it is accepted that pulmonary and extra-pulmonary TB should be treated with the same regimens.

The objectives of TB therapy are (1) to rapidly reduce the number of actively growing bacilli in the patient, thereby decreasing severity of the disease and preventing death (2) to eradicate populations of persisting bacilli in order to achieve durable cure (prevent relapse) after completion of therapy; and (3) to prevent acquisition of drug resistance during therapy.

7.1. Medical treatment

Clinical judgment and the index of suspicion for TB are critical in making a decision to initiate treatment [9, 14]. Therapy should be initiated promptly even before the results of AFB smear microscopy, molecular tests, and mycobacterial culture are known. It is particularly important in cases admitted with episodes of cystitis concomitant with sterile pyuria and progressive renal parenchymal damage not related to other clinical diseases [14]. If the diagnosis has been made while renal function still remains, it may be possible to arrest the fall in glomerular filtration rate or even produce improvement, using a combination of anti-TB treatment and corticosteroids [21].

Fibrotic alterations can be decreased by use of corticosteroids in association with anti-TB drugs. However, despite these strategies, patients with advanced disease or those with a delayed diagnosis might require surgery [93]. The use of corticosteroids in addition to stenting for ureteral obstruction is discussed in the literature, and its efficacy in this setting remains unclear [94].

Regarding the duration of the UTTB treatment, the expert recommendation is that a standard daily 6-month regimen is adequate [12, 29, 31, 95, 96]. In countries where new cases of tuberculosis are resistant to organisms (resistant to isoniazid ≥4%), it is recommended to use four drugs in the intensive phase: INH, RIF, PZA, and EMB [97–101].

Two regimens can be used. The first-line regimen, which is used for 6 months, is with INH, RIF, PZA, and EMB administered daily or 5 days per week for 2 or 3 months, followed by INH and RIF daily or 5 days per week for 3 or 4 months [93]. The second-line regimen, which is recommended for TB caused by drug-susceptible organisms when directly observed therapy (DOT) is difficult to achieve, it consist of INH, RIF, PZA, and EMB daily or 5 days per week for 2 or 3 months, followed by INH and RIF 3 times a week, for 3 or 4 months (**Tables 2** and **3**) [9].

Intensive phase		Continuation phase		
Drugs	**Interval and dose (minimum duration)**	**Drugs**	**Interval and dose (minimum duration)**	**Range of total doses**
INH RIF PZA EMB	7 d/wk for 56 doses (8 wk), or 5 d/wk for 40 doses (8 wk)	INH RIF	7 d/wk for 126 doses (18 wk), or 5 d/wk for 90 doses (18 wk)	182–130

DOT, directly observed therapy; EMB, ethambutol; INH, isoniazid; PZA, pyrazinamide; RIF, rifampin.

Table 2. Recommended drug regimen for tuberculosis caused by drug-susceptible organisms.

Intensive phase		Continuation phase		
Drugs	**Interval and dose (minimum duration)**	**Drugs**	**Interval and dose (minimum duration)**	**Range of total doses**
INH RIF PZA EMB	7 d/wk for 56 doses (8 wk), or 5 d/wk for 40 doses (8 wk)	INH RIF	3 times weekly for 54 doses (18 wk)	110–94

DOT, directly observed therapy; EMB, ethambutol; INH, isoniazid; PZA, pyrazinamide; RIF, rifampin.

Table 3. Recommended drug regimen for tuberculosis caused by drug-susceptible organisms when DOT is difficult to achieve.

Pyridoxine (vitamin B6) is given with INH to all persons at risk of neuropathy (e.g., pregnant women; breastfeeding infants; persons infected with HIV; patients with diabetes, alcoholism, malnutrition, or chronic renal failure; or those who are of advanced age) [102, 103]. Although there is no studies that compare 5 with 7 daily doses, experts believe that the treatment of intensive phase with 5-days-a-week is as effective as 7-days-a-week [9].

Some authors propose that prolonged anti-TB treatment effectively sterilizes caseous and calcified masses of the involved kidney, whereas others believe that the sequestered caseous material should be removed to shorten the duration of medical therapy and to prevent late TB reactivation [28, 104].

Adequately controlled, randomized studies specific to UTTB comparing different treatment regimens have not been performed. Such studies would establish if short-course therapies are adequate to ensure eradication of UTTB, including patients with prostatic infection. There is little information about the vigilance and follow-up of patients with UTTB that may include at least monthly function renal tests, urine ZN smear, and *Mtb* cultures. ADN amplification tests for *Mtb* and imaging studies should be used on clinical judgment and probably performed at the end of both intensive and continues phases. Response to treatment may be difficult to assess and should be based on clinical, radiologic, and eradication of *Mtb* on subsequent cultures [94].

To maximize completion of therapy, management strategies should utilize a broad range of approaches. Among these, DOT is the practice of observing the patient swallow their anti-TB drugs and has been widely used as the standard of practice in many TB programs. DOT can be advantageous for early recognition of adverse drug reactions and treatment irregularities. DOT remains the standard of practice in the majority of TB programs in the United States [105, 106] and Europe [107].

Gastrointestinal and skin disorders adverse reactions are common; the frequency can reach up to 30% especially early in therapy. Less frequent adverse events are muscle-joints disorders, fever, headache, hepatic problems, and even death [108, 109]. Four-drug fixed-doses therapy may reduce the incidence of gastrointestinal adverse effects and the use of antacids or proton pump inhibitors for reducing gastrointestinal can contribute to better tolerance with minor impact on drugs absorption [110]. INH, RIF, and PZA can cause drug-induced liver injury that is the most frequent serious adverse event [111]. It is necessary to promote some strategies that improve the quality of patient care and to control TB safely, treating preexisting diseases or dysfunctions, such as diabetes and alcoholism. These strategies may improve the patient adherence to treatment and therapeutic outcome.

7.2. Invasive procedures

Invasive procedures or surgery are indicated in certain situations: hydronephrosis drainage (ureter dilation or percutaneous nephrostomy), abscesses and collection drainage, definitive treatment of renal TB (partial nephrectomy), superior urinary tract reconstruction, bladder dilation, ureter reconstruction and others [112]. In a study of 4298 patients with GUTB, 2364 (37%) underwent surgery: remove or preserve an organ and reconstruction surgery were the most frequent interventions. Other surgical modalities included ureteral neoimplantation using intestinal transplants (ileocystoplasty, sigmoidocystoplasty, and cecocystoplasty) [113].

Other surgical intervention can be double-J stenting use and percutaneous nephrostomy for hydronephrosis cases, drainage of abscesses, partial or polar nephrectomy, reconstruction of the upper urinary tract, and bladder augmentation with ileum replacement [114].

The standard treatment for a unilateral nonfunctional kidney secondary to renal TB is a nephrectomy combined with anti-TB therapy [16]. The patients that end up in nephrectomy have an advanced stage [13, 37]. Nephrectomy is recommended only in cases of secondary sepsis, bleeding, pain, uncontrollable hypertension, and continued positive urinary cultures for *Mtb* [38].

Radical or reconstructive surgical interventions are recommended be carried out in the first 2 months of intensive GUTB therapy [115].

7.3. Treatment of special situations

7.3.1. Patients with HIV infection

HIV and TB create a deadly synergy, speeding the progression of both diseases. HIV enhances the reactivation and progression of latent TB to overt TB disease. The treatment represents a challenge were the most significant concern is to avoid drug-drug interactions and the control

of adverse events. Whenever possible, the use of combination formulations, both antituberculous and ARV drugs, is recommended in order to simplify the treatment.

The recommendation for HIV-infected patients receiving ARV and initial TB disease with susceptible *Mtb* is a short course of 6 months of therapy. During the first 2 months of daily regimen (initial phase), patients should be treated with INH, RIF, PZA, and EMB. This is followed by a continuation phase of 4 months of INH plus RIF thrice-weekly regimen. HIV-infected patients that still do not receive ARV; the recommendation is to extend the continuation phase with INH and RIF for additional 3 months (i.e., a continuation phase of 7 months in duration, corresponding to a total of 9 months of therapy) [9].

Once a week, TB continuation phase regimen can be safe and effective treating pulmonary TB in HIV-negative patients without cavitation on chest radiography [116]. However, relapses and rifamycin monoresistant tuberculosis occurs among HIV infected patients treated with a once-weekly isoniazid/rifapentine during continuation phase regimen [117]. A study with 169 HIV-infected patients and pulmonary TB, nine (5.3%) had failure or relapse, eight of these nine isolates were detected with acquired rifamycin resistance, low CD4 lymphocyte counts and the use of twice-weekly therapy during intensive phase were the most important factors associated [118]. Lower plasma rifabutin and INH concentrations are associated with acquiring rifamycin resistance [119].

HIV/TB co-infected patients treated during continuation phases with thrice-weekly anti-TB regimen showed a higher risk of relapse and death as well as emergence of rifamycin resistance compared with HIV-uninfected patients. ARV therapy reduces but does not eliminate the risk of these complications [120]. A prompt diagnosis of HIV, earlier ARV initiation, and avoiding intermittent TB treatment regimens could prevent relapses and drug resistance emergence. Rifabutin can be substituted for RIF to decrease drug interactions with drugs used in the treatment of HIV infection (protease inhibitors and transcriptase reverse non-nucleoside inhibitors) [9].

Immune reconstitution inflammatory syndrome (IRIS) is a paradoxical clinical worsening of a known or new condition occurring shortly after initiating ARV therapy, mainly in patients with low CD4+ cell counts [121]. *Mtb* is among the most frequently reported pathogen associated with IRIS; signs may include high fever, lymphadenopathy, worsening of respiratory symptoms, new pulmonary infiltrates, and pleural effusions. Extra-pulmonary presentations are also possible expanding to central nervous system, intra-abdominal abscesses, osteomyelitis, and others [122]. For more severe cases of IRIS, treatment with corticosteroids is effective. In a placebo-controlled trial of prednisone for patients with moderate IRIS, prednisone 1.25 mg/kg/day significantly reduced the need for hospitalization or surgical procedures [123].

7.3.2. Renal failure

Renal TB can result in acute or chronic renal failure with an incidence of 24%. If renal TB progresses to chronic kidney disease (CKD), it has effects in the immune system too. The alterations on systemic immunity included persistent systemic inflammation and acquired immunosuppression state [124]. The mechanisms associated with end-stage renal disease include obliterative endarteritis, renal amyloidosis, and obstructive uropathy [7, 93].

The patients with CKD by other etiology are at increased risk of TB than those with normal renal function. Drug-induced hepatitis and all-cause mortality are more common among TB patients with CKD [125]. One of principal factors to consider in TB treatment with CKD included drug pharmacokinetics, drugs removed by hemodialysis that should be dosed after dialysis [126]. INH, RIF, and EMB are not significantly dialyzed. However, PZA is removed by hemodialysis and should be administered after hemodialysis [127]. Other factors included co-existent illnesses, dosage adjustment, drug interactions, and drug accumulate predisposing to toxicities. Initial regimen with standard doses and no more than three times weekly for PZA, EMB, and aminoglycosides is recommended [128].

The fluoroquinolones used for TB treatment are levofloxacin, moxifloxacin, and gatifloxacin. According to degree of renal impairment, levofloxacin dosage adjustment is required. Nevertheless, neither hemodialysis nor continuous ambulatory peritoneal dialysis removed levofloxacin [129]. Moxifloxacin may be administered at the normal dosage even with severe renal failure [130].

7.3.3. Advanced age

Age over 60 years is significantly associated with serious adverse events related to INH, PZA, and RIF, with greater frequency of hepatitis episodes and gastrointestinal intolerance [131, 132]. However, the risk of hepatotoxicity in advanced age might not increase after 12 weeks with standard treatment containing INH and RIF [133]. The severity of INH-induced hepatitis has been associated with higher mortality in this patient population [131]. Dose adjustments or alternative regiments should be considered to avoid stopping the treatment, increasing the probability of failure and mortality [9, 134]. The duration of TB treatment depends of initial regimen during the intensive phase [9].

Author details

Gerardo Amaya-Tapia[1,2]* and Guadalupe Aguirre-Avalos[1,3]

*Address all correspondence to: gamaya@cencar.udg.mx

1 Centro Universitario Ciencias de la Salud at Universidad de Guadalajara, Guadalajara, Jalisco, Mexico

2 Infectious Diseases Department at Hospital General de Occidente, Guadalajara, Jalisco, Mexico

3 Intensive Care Unit at Hospital Civil de Guadalajara "Fray Antonio Alcalde", Guadalajara, Jalisco, Mexico

References

[1] Rieder HL, Snider DE Jr, Cauthen GM. Extrapulmonary tuberculosis in the United States. The American Review of Respiratory Disease. 1990;**141**:347-351

[2] Gupta NP. Genitourinary tuberculosis. Indian Journal of Urology. 2008;**24**:355

[3] Naidich DP, Garay SM, Leitman BS, McCauley DI. Radiographic manifestations of pulmonary disease in the acquired immunodeficiency syndrome (AIDS). Seminars in Roentgenology. 1987;**22**:14-30

[4] Tonkin AK, Witten DM. Genitourinary tuberculosis. Seminars in Roentgenology. 1979;**14**:305-318

[5] Wise GJ. Urinary tuberculosis: Modern issues. Current Urology Reports. 2009;**10**:313-318

[6] Merchant SA. Tuberculosis of the genitourinary system. The Indian Journal of Radiology and Imaging. 1993;**3**:253-274

[7] Daher Ede F, Silva Junior GB, Damasceno RT, Santos GM, Corsino GA, Silva SL, Gutierrez-Adrianzén OA. End-stage renal disease due to delayed diagnosis of renal tuberculosis: A fatal case report. The Brazilian Journal of Infectious Diseases. 2007;**11**:169-171

[8] Jonas V, Alden MJ, Curry JI, Kamisango K, Knott CA, Lankford R, et al. Detection and identification of *Mycobacterium tuberculosis* directly from sputum sediments by amplification of rRNA. Journal of Clinical Microbiology. 1993;**31**:2410-2441

[9] Nahid P, Dorman SE, Alipanah N, Barry PM, Brozek JL, Cattamanchi A, et al. Official American thoracic society/centers for disease control and prevention/infectious diseases society of America Clinical Practice Guidelines: Treatment of drug-susceptible tuberculosis. Clinical Infectious Diseases. 2016;**63**:853-867

[10] Global Tuberculosis Report. Geneva: World Health Organization; 2017. Licence: CC BY-NCSA 3.0 IGO; 2017

[11] Peto HM, Pratt RH, Harrington TA, LoBue PA, Lori R, Armstrong LR. Epidemiology of extrapulmonary tuberculosis in the United States, 1993-2006. CID. 2009;**49**:1350-1357

[12] Lam TB, Van der Werf MJ, Richter C, Borgdorff MW. Extrapulmonary tuberculosis by nationatily, the Netherlands. Emerging Infectious Diseases. 2006;**12**(9):1375-1382

[13] Krishnamoorthy S, Palaniyandi V, Kumaresan N, Govindaraju S, Rajasekaran J, Murugappan I, et al. Aspects of evolving genito urinary tuberculosis-A profile of genito urinary tuberculosis (GUTB) in 110 patients. Journal of Clinical and Diagnostic Research. 2017;**11**:1-5

[14] Altiparmak MR, Trabulus S, Balkan II, Yalin SF, Denizli N, Aslan G, et al. Urinary tuberculosis: A cohort of 79 adult cases. Renal Failure. 2015;**37**(7):1157-1163

[15] Wagaskar VG, Chirmade RA, Baheti VH, Tanwar HV, Patwardhan SK, Gopalakrishnan G. Urinary tuberculosis with renal failure: Challenges in management. Journal of Clinical and Diagnostic Research. 2016;**10**:1-3

[16] Zhang S, Luo Y, Wang C, Xiong H, Fu SJ, Yang L. Open surgery versus retroperitoneal laparoscopic nephrectomy for renal tuberculosis: A retrospective study of 120 patients. Peer J. 2016;**29**:e2708

[17] Gaudiano C, Tadolini M, Busato F, Vanino E, Pucci S, Corcioni B, et al. Multidetector CT urography in urogenital tuberculosis: use of reformatted images for the

assessment of the radiological findings. A pictorial essay. Abdominal Radiology. 2017;**42**:2314-2324

[18] Hartman DS, Stagg PL. Diagnosis please. Case 3: Renal tuberculosis. Radiology. 1998;**209**: 69-72

[19] Wang LJ, Wong YC, Chen CJ, Lim KE. CT features of genitourinary tuberculosis. Journal of Computer Assisted Tomography. 1997;**21**:254-258

[20] Muttarak M, ChiangMai WN, Lojanapiwat B. Tuberculosis of the genitourinary tract: Imaging features with pathological correlation. Singapore Medical Journal. 2005;**46**: 568-574

[21] Eastwood JB, Corbishley CM, Grange JM. Tuberculosis and the kidney. Journal of the American Society of Nephrology. 2001;**12**:1307-1314

[22] Engin G, Acunaş B, Acunaş G, Tunaci M. Imaging of extrapulmonary tuberculosis. Radiographics. 2000;**20**:471-488

[23] Daher Ede F, Da Silva GB Jr, Barros EJ. Review: Renal tuberculosis in the modern era. The American Journal of Tropical Medicine and Hygiene. 2013;**88**(1):54-64

[24] Merchant S, Bharati A, Merchant N. Tuberculosis of the genitourinary system-urinary tract tuberculosis: Renal tuberculosis–Part I. Indian Journal of Radiology and Imaging. 2013;**23**(1):46-63

[25] Vijayaraghavan SB, Kandasamy SV, Arul M, Prabhakar M, Dhinakaran CL, Palanisamy R. Spectrum of high-resolution sonographic features of urinary tuberculosis. Journal of Ultrasound in Medicine. 2004;**23**:585-594

[26] Pouchot J, Dreyfuss D, Gardin JP, Mier L, Rémy P, Esdaile JM, et al. Ectopic production of 1,25-dihydroxyvitamin D3 in tuberculosis. Nephrology, Dialysis, Transplantation. 1993;**8**:560-562

[27] Wise GJ, Shteynshlyuger A. An update on lower urinary tract tuberculosis. Current Urology Reports. 2008;**9**:305-313

[28] Gibson MS, Puckett ML, Shelly ME. Renal tuberculosis. Radiographics. 2004;**24**:251-256

[29] Christensen WI. Genitourinary tuberculosis: Review of 102 cases. Medicine (Baltimore). 1974;**53**:377-390

[30] Narayana A. Overview of renal tuberculosis. Urology. 1982;**19**:231-237

[31] Simon HB, Weinstein AJ, Pasternak MS, Swartz MN, Kunz LJ. Genitourinary tuberculosis. Clinical features in a general hospital population. The American Journal of Medicine. 1977;**63**:410-420

[32] Fanning A. Tuberculosis: 6. Extrapulmonary disease. CMAJ. 1999;**160**(11):1597-1603

[33] Figueiredo AA, Lucon AM. Urogenital tuberculosis: Update and review of 8961 cases from the world literature. Revista de Urología. 2008;**10**(3):207-217

[34] Wechsler H, Westfall M, Lattimer JK. The earliest signs and symptoms in 127 male patients with genitourinary tuberculosis. The Journal of Urology. 1960;**83**:801-803

[35] García-Rodríguez JA, García-Sánchez JE, Muñoz-Bedillo JL, Montes-Martínez I, Rodríguez-Hernández J, Fernández- Gorostarzu J, et al. Genitourinary tuberculosis in Spain: Review of 81 cases. CID. 1994;**18**:557-561

[36] Gokce G, Kilicarslan H, Ayan S, Tas F, Akar R, Kaya K, et al. Genitourinary tuberculosis: A review of 174 cases. Scandinavian Journal of Infectious Diseases. 2002;**34**:338-340

[37] Ye Y, Hu X, Shi Y, Zhou J, Zhou Y, Song X, et al. Clinical features and drug-resistance profile of urinary tuberculosis in south-western China: A cross-sectional study. Medicine (Baltimore). 2016;**95**:e3537

[38] Ghaleb K, Afifi M, El-Gohary M. Assessment of diagnostic techniques of urinary tuberculosis. Mediterranean Journal of Hematology and Infectious Diseases. 2013;**5**(1):e2013034

[39] Berta M, Sturm G, Juri L, Cosiansi MC, Barzón S, Barnes AI, Rojo SC. Bacteriological diagnosis of renal tuberculosis: An experience at the regional tuberculosis laboratory in Córdoba Province, Argentina. Revista Argentina de Microbiología. 2011;**43**(3):191-194

[40] Pais VM, Dionne-Odom J, von Reyn CF, Curhan G, Baron EL, Sheridan AM. Renal Disease in Tuberculosis. UpToDate. 2015. Available at: http://www.uptodate.com

[41] Hillemann D, Richter E, Rüsch-Gerdes S. Use of the BACTEC mycobacteria growth indicator tube 960 automated system for recovery of mycobacteria from 9,558 extrapulmonary specimens, including urine samples. Journal of Clinical Microbiology. 2006;**44**:4014-4017

[42] Wang SX, Tay L. Evaluation of three nucleic acid amplification methods for direct detection of *Mycobacterium tuberculosis* complex in respiratory specimens. Journal of Clinical Microbiology. 1999;**37**:1932-1934

[43] Portillo GL, Morris S, Panduro A. Rapid and efficient detection of extrapulmonary *Mycobacterium tuberculosis* by PCR analysis. The International Journal of Tuberculosis and Lung Disease. 2000;**4**:361-370

[44] Piersimoni C, Scarparo C, Piccoli C, Rigon A, Ruggiero G, Nista D, Bornigia S. Performance assessment of two commercial amplification assays for direct detection of *Mycobacterium tuberculosis* complex from respiratory and extrapulmonary specimens. Journal of Clinical Microbiology. 2002;**40**:4138-4142

[45] Van Volle HP, Heyns CF, de Beer PM, Whitaker P, van Helden PD, Victor T. Polymerase chain reaction in the diagnosis of urinary tract tuberculosis. Urological Research. 1996;**24**:107-111

[46] Missirliu A, Gasman D, Vogt B, Poveda JD, Abbou CC, Chopin D. Genito-urinary tuberculosis: Rapid diagnosis using the polymerase chain reaction. European Urology. 1996; **30**(4):523

[47] Ferrie BG, Rundle JS. Genito-urinary tuberculosis in Glasgow 1970 to 1979: A review of 230 patients. Scottish Medical Journal. 1985;**30**(1):30-34

[48] Mortier E, Pouchot J, Girard L, Boussougant Y, Vinceneux P. Assessment of urine analysis for the diagnosis of tuberculosis. BMJ. 1996;**312**(7022):27-28

[49] Moussa OM, Eraky I, El-Far MA, Osman HG, Ghoneim MA. Rapid diagnosis of genitourinary tuberculosis by polymerase chain reaction and non-radioactive DNA hybridization. The Journal of Urology. 2000;**164**(2):584-588

[50] Kafwabulula M, Ahmed K, Nagatake T, Gotoh J, Mitarai S, Oizumi K, Zumla A. Evaluation of PCR-based methods for the diagnosis of tuberculosis by identification of mycobacterial DNA in urine samples. The International Journal of Tuberculosis and Lung Disease. 2002;**6**:732-737

[51] Hemal AK, Gupta NP, Rajeev TP, Kumar R, Dar L, Seth P. Polymerase chain reaction in clinically suspected genitourinary tuberculosis: Comparison with intravenous urography, bladder biopsy, and urine acid fast bacilli culture. Urology. 2000;**56**(4):570-574

[52] Yuen KY, Yam WC, Wong LP, Seto WH. Comparison of two automated DNA amplification systems with a manual one-tube nested PCR assay for diagnosis of pulmonary tuberculosis. Journal of Clinical Microbiology. 1997;**35**:1385-1389

[53] Montenegro SH, Gilman RH, Sheen P, Cama R, Caviedes L, Hopper T, et al. Improved detection of *Mycobacterium tuberculosis* in Peruvian children by use of a heminested IS6110 polymerase chain reaction assay. Clinical Infectious Diseases. 2003;**36**:16-23

[54] Honore S, Vincensini JP, Hocqueloux L, Noguera ME, Farge D, Lagrange P, Herrmann JL. Diagnostic value of a nested polymerase chain reaction assay on peripheral blood mononuclear cells from patients with pulmonary and extra pulmonary tuberculosis. The International Journal of Tuberculosis and Lung Disease. 2001;**5**(8):754-762

[55] Pierre C, Lecossier D, Boussougant Y, Bocart D, Joly V, Yeni P, Hance AJ. Use of reamplification protocol improves sensitivity of detection of *Mycobacterium tuberculosis* in clinical samples by amplification of DNA. Journal of Clinical Microbiology. 1991;**29**:712-717

[56] Amaya-Tapia G, Portillo-Gómez L, Aguirre-Avalos G, Rodríguez-Toledo A, Sosa-Iglesias EG, Aguilar-Benavides S. DNA amplification for *M. tuberculosis* detection in patients with suspected urinary tract tuberculosis. In: 43th Annual Meeting of Infectious Diseases Society of America (IDSA) San Francisco; 2005. abstract #228

[57] Miyazaki Y, Koga H, Kohno S, Kaku M. Nested polymerase chain reaction for detection of *Mycobacterium tuberculosis* in clinical samples. Journal of Clinical Microbiology. 1993;**31**:2228-2232

[58] Caskurlu T, Resim S, Bayraktar Z, Taşçi AI, Sevin G. Urinary tuberculosis in a two-year-old boy. International Urology and Nephrology. 1998;**30**:525-528

[59] Becker JA. Renal tuberculosis. Urologic Radiology. 1988;**10**:25-30

[60] Kollins SA, Hartman GW, Carr DT, Segura JW, Hattery RR. Roentgenographic findings in urinary tract tuberculosis. A 10 year review. The American Journal of Roentgenology, Radium Therapy, and Nuclear Medicine. 1974;**121**:487-499

[61] Elkin M. Urogenital tuberculosis. In: Pollack HM, editor. Clinical Urography. Philadelphia: WB Saunders; 1990. pp. 1020-1052

[62] Pastsernak MS, Rubin RH. Urinary tract tuberculosis. In: Schrier RW, editor. Diseases of the Kidney and Urinary Tract. 7th ed. Philadelphia: Lipincott Williams and Wilkins; 2001. pp. 1017-1037

[63] Modesto A, Marty L, Suc JM, Kleinknecht D, de Frémont JF, Marsepoil T, et al. Renal complications of intravesical bacillus Calmette-Guérin therapy. American Journal of Nephrology. 1991;**11**:501-504

[64] Harisinghani MG, Mc Loud TC, Shepard JA, Ko JP, Shroff MM, Mueller PR. Tuberculosis from head to toe. Radiographics. 2000;**20**:449-470

[65] Premkumar A, Lattimer J, Newhouse JH. CT and sonography of advanced urinary tract tuberculosis. AJR. American Journal of Roentgenology. 1987;**148**:65-69

[66] Apperson JW, Wechsler H, Lattimer JK. The trequent occurrence of both renal calculi and renal calcifications in tuberculous kidneys. The Journal of Urology. 1962;**87**:643-646

[67] Kapoor R, Ansari MS, Mandhani A, Gulia A. Clinical presentation and diagnostic approach in cases of genitourinary tuberculosis. Indian Journal of Urology. 2008;**24**:401-405

[68] Navarro-Vilasaró M, Font B, Sala M, Prera A, Malet A, Mariscal D, et al. Genitourinary mycobacteriosis: Retrospective study of 45 cases in a general hospital. Enfermedades Infecciosas y Microbiología Clínica. 2008;**26**:540-545

[69] Kenney PJ. Imaging of chronic renal infections. AJR. American Journal of Roentgenology. 1990;**155**:485-494

[70] Schaffer R, Becker JA, Goodman J. Sonography of tuberculous kidney. Urology. 1983;**22**:209-211

[71] Juul N, Torp-Pedersen S, Grønvall S, Holm HH, Koch F, Larsen S. Ultrasonically guided fine needle aspiration biopsy of renal masses. The Journal of Urology. 1985;**133**:579-581

[72] Das KM, Vaidyanathan S, Rajwanshi A, Indudhara R. Renal tuberculosis: Diagnosis with sonographically guided aspiration cytology. AJR. American Journal of Roentgenology. 1992;**158**(3):571

[73] Qunibi WY, al-Sibai MB, Taher S, Harder EJ, de Vol E, al-Furayh O, et al. Mycobacterial infection after renal transplantation—Report of 14 cases and review of the literature. The Quarterly Journal of Medicine. 1990;**77**:1039-1060

[74] Rui X, Li XD, Cai S, Chen G, Cai B. Ultrasonographic diagnosis and typing of renal tuberculosis. International Journal of Urology. 2008;**15**:135-139

[75] Browne RF, Zwirewich C, Torreggiani WC. Imaging of urinary tract infection in the adult. European Radiology. 2004;**14**:E168-E183

[76] Papanicolaou N, Pfister RC. Acute renal infections. Radiologic Clinics of North America. 1996;**34**:965-995

[77] Lu P, Li C, Zhou X. Significance of the CT scan in renal tuberculosis. Zhonghua Jie He He Hu Xi Za Zhi. 2001;**24**:407-409

[78] Merchant S, Bharati A, Merchant N. Tuberculosis of the genitourinary system—Urinary tract tuberculosis: Renal tuberculosis – Part II. Indian Journal of Radiology and Imaging. 2013;**23**(1):64-77

[79] McCarthy CL, Cowan NC. Multidetector CT urography (MD-CTU) for urothelial imaging (abstr). Radiology. 2002;**225**(P):137

[80] Leder RA, Low VH. Tuberculosis of the abdomen. Radiologic Clinics of North America. 1995;**33**:691-705

[81] Goldman SM, Fishman EK, Hartman DS, Kim YC, Siegelman SS. Computed tomography of renal tuberculosis and its pathological correlates. Journal of Computer Assisted Tomography. 1985;**9**:771-776

[82] Pedrosa I, Sun MR, Spencer M, Genega EM, Olumi AF, Dewolf WC, et al. MR imaging of renal masses: Correlation with findings at surgery and pathologic analysis. Radiographics. 2008;**28**:985-1003

[83] Verswijvel G, Oyen R. Magnetic resonance imaging in the detection and characterization of renal diseases. Saudi Journal of Kidney Diseases and Transplantation. 2004;**15**:283-299

[84] Leyendecker JR, Barnes CE, Zagoria RJ. MR urography: Techniques and clinical applications. Radiographics. 2008;**28**:23-46

[85] Khanna PC, Karnik ND, Jankharia BG, Merchant SA, Joshi AR, Kukreja KU. Magnetic resonance urography (MRU) versus intravenous urography (IVU) in obstructive uropathy: A prospective study of 30 cases. The Journal of the Association of Physicians of India. 2005;**53**:527-534

[86] Buckley O, Colville J, Torreggiani WC, Leyendecker JR. Re: MR urographic techniques. Radiographics. 2008;**28**:907 author reply 907-8

[87] Kim S, Jacob JS, Kim DC, Rivera R, Lim RP, Lee VS. Time-resolved dynamic contrast-enhanced MR urography for the evaluation of ureteral peristalsis: Initial experience. Journal of Magnetic Resonance Imaging. 2008;**28**:1293-1298

[88] Sadowski EA, Bennett LK, Chan MR, Wentland AL, Garrett AL, Garrett RW, et al. Nephrogenic systemic fibrosis: Risk factors and incidence estimation. Radiology. 2007; **243**:148-157

[89] Baniel J, Manning A, Leiman G. Fine needle cytodiagnosis of renal tuberculosis. The Journal of Urology. 1991;**146**(3):689-691

[90] Porter B, Karp W, Forsberg L. Percutaneous cytodiagnosis of retroperitoneal masses by USG guided FNAB. Acta Radiologica. 1981;**22**:663-668

[91] Kedar RP, Patel VH, Merchant SA, Aggarwal V, Pandit AA. Ultrasound guided aspiration cytology—A valuable diagnostic aid. Journal of Postgraduate Medicine. 1991;**37**:84-87

[92] Mangal N, Sharma VK, Verma N, Agarwal AK, Sharma SP, Aneja S. Ultrasound guided fine needle aspiration cytology in the diagnosis of retroperitoneal masses: A study of 85 cases. Journal of Cytology. 2009;**26**:97-101

[93] Wise GJ, Marella VK. Genitourinary manifestations of tuberculosis. The Urologic Clinics of North America. 2003;**30**:111-121

[94] Centers for Disease Control and Prevention. Treatment of tuberculosis, American Thoracic Society, CDC, and Infectious Diseases Society of America. MMWR. 2003; 52(No. RR-11)

[95] Gow JG. Genito-urinary tuberculosis. A study of the disease in one unit over a period of 24 years. Annals of the Royal College of Surgeons of England. 1971;**49**:50-70

[96] Skutil V, Varsa J, Obsitnik M. Six-month chemotherapy for urogenital tuberculosis. European Urology. 1985;**11**:170-176

[97] Amaya-Tapia G, Martín-Del Campo L, Aguirre-Avalos G, Portillo-Gómez L, Covarrubias-Pinedo A, Aguilar-Benavides S. Primary and acquired resistance of *Mycobacterium tuberculosis* in westerns México. Microbial Drug Resistance. 2000;**6**:143-145

[98] LoBue PA, Moser KS. Isoniazid- and rifampin-resistant tuberculosis in San Diego County, California, United States, 1993-2002. The International Journal of Tuberculosis and Lung Disease. 2005;**9**:501-506

[99] Hoopes AJ, Kammerer JS, Harrington TA, Ijaz K, Armstrong LR. Isoniazid monoresistant tuberculosis in the United States, 1993 to 2003. Archives of Internal Medicine. 2008;**168**:1984-1992

[100] Jenkins HE, Zignol M, Cohen T. Quantifying the burden and trends of isoniazid resistant tuberculosis, 1994-2009. PLoS One. 2011;**6**(7):e22927

[101] Yuen CM, Jenkins HE, Rodriguez CA, Keshavjee S, Becerra MC. Global and regional burden of isoniazid-resistant tuberculosis. Pediatrics. 2015;**136**:e50-e59

[102] Snider DE Jr. Pyridoxine supplementation during isoniazid therapy. Tubercle. 1980;**61**: 191-196

[103] Visser ME, Texeira-Swiegelaar C, Maartens G. The short-term effects of antituberculosis therapy on plasma pyridoxine levels in patients with pulmonary tuberculosis. The International Journal of Tuberculosis and Lung Disease. 2004;**8**:260-262

[104] Wang LJ, Wu CF, Wong YC, Chuang CK, Chu SH, Chen CJ. Imaging findings of urinary tuberculosis on excretory urography and computerized tomography. The Journal of Urology. 2003;**169**(2):524-528

[105] Chaulk CP, Kazandjian VA. Directly observed therapy for treatment completion of pulmonary tuberculosis: Consensus statement of the public health tuberculosis guidelines panel. JAMA. 1998;**279**:943-948

[106] Liu SY, Li JH, Schluger NW. DOT and timely treatment completion among Asian-born immigrant tuberculosis patients. The International Journal of Tuberculosis and Lung Disease. 2005;**9**:884-889

[107] Migliori GB, Zellweger JP, Abubakar I, Ibraim E, Caminero JA, De Vries G, et al. European Union standards for tuberculosis care. The European Respiratory Journal. 2012;**39**: 807-819

[108] Gravendeel JM, Asapa AS, Becx-Bleumink M, Vrakkin HA. Preliminary results of an operational field study to compare side-effects, complaints and treatment results of a single-drug short-course regimen with a four-drug fixed-doses combination (4FDC) regimen in South Sulawesi, Republic of Indonesia. Tuberculosis (Edinburgh, Scotland). 2003;**83**:183-186

[109] Zaka-Ur-Rehman Z, Jamshaid M, Chaudhry A. Clinical evaluation and monitoring of adverse effect for fixed multidose combination against single drug therapy in pulmonary tuberculosis patiens. Pakistan Journal of Pharmaceutical Sciences. 2008;**21**:185-194

[110] Lin MY, Lin SJ, Chan LC, Lu YC. Impact of food and antacids on the pharmacokinetics of anti-tuberculosis drugs: Systematic review and meta-analysis. The International Journal of Tuberculosis and Lung Disease. 2010;**14**:806-818

[111] Navarro VJ, Senior JR. Drug-related hepatotoxicity. The New England Journal of Medicine. 2006;**354**:731-739

[112] Small PM, Fujiwara PI. Management of tuberculosis in the United States. The New England Journal of Medicine. 2001;**345**:189-200

[113] Mochalova TP, Starikova IY. Reconstructive surgery for treatment of urogenital tuberculosis: 30 years of observation. World Journal of Surgery. 1997;**21**(5):511

[114] Krishnamoorthy S, Gopalakrishnan G. Surgical management of renal tuberculosis. Indian Journal of Urology. 2008;**24**(3):369-375

[115] Cek M, Lenk S, Naber KG, Bishop MC, Johansen TE, Botto H, et al. EAU guidelines for the management of genitourinary tuberculosis. European Urology. 2005;**48**:353-362

[116] Benator D, Bhattacharya M, Bozeman L, Burman W, Cantazaro A, Chaisson C, et al. Rifapentine and isoniazid once a week versus rifampicin and isoniazid twice a week for treatment of drug-susceptible pulmonary tuberculosis in HIV-negative patients: A randomised clinical trial. Lancet. 2002;**360**:528-534

[117] Vernon A, Burman W, Benator D, Khan A, Bozeman L. Acquired rifamycin monoresistance in patients with HIV-related tuberculosis treated with once weekly rifapentine and isoniazid. Tuberculosis Trials Consortium. Lancet. 1999;**353**:1843-1847

[118] Burman W, Benator D, Vernon A, Khan A, Jones B, Silva C, et al. Acquired rifamycin resistance with twice-weekly treatment of HIV-related tuberculosis. American Journal of Respiratory and Critical Care Medicine. 2006;**173**:350-356

[119] Weiner M, Benator D, Burman W, Peloquin CA, Khan A, Vernon A, et al. Association between acquired rifamycin resistance and the pharmacokinetics of rifabutin and isoniazid among patients with HIV and tuberculosis. Clinical Infectious Diseases. 2005;**40**:1481-1491

[120] Narendran G, Menon PA, Venkatesan P, Vijay K, Padmapriyadarsini C, Ramesh Kumar S, et al. Acquired rifampicin resistance in thrice-weekly antituberculosis therapy: Impact of HIV and antiretroviral therapy. Clinical Infectious Diseases. 2014;**59**:1798-1804

[121] Luetkemeyer AF, Kendall MA, Nyirenda M, Wu X, Ive P, Benson CA, et al. Tuberculosis immune reconstitution inflammatory syndrome in A5221 STRIDE timing, severity,

and implications for HIV-TB programs. Journal of Acquired Immune Deficiency Syndromes. 2014;**65**:423-428

[122] Meintjes G, Lawn SD, Scano F, Maartens G, French MA, Worodria W, et al. Tuberculosis-associated immune reconstitution inflammatory syndrome: Case definitions for use in resource-limited settings. The Lancet Infectious Diseases. 2008;**8**:516-523

[123] Meintjes G, Wilkinson RJ, Morroni C, Pepper DJ, Rebe K, Rangaka MX, et al. Randomized placebo-controlled trial of prednisone for paradoxical tuberculosis-associated immune reconstitution inflammatory syndrome. AIDS. 2010;**24**:2381-2390

[124] Kurts C, Panzer U, Anders HJ, Rees AJ. The immune system and kidney disease: Basic concepts and clinical implications. Nature Reviews Immunology. 2013;**13**:738-753

[125] Baghaei P, Marjani M, Tabarsi P, Moniri A, Rashidfarrokhi F, Ahmadi F, et al. Impact of chronic renal failure on antituberculosis treatment outcomes. The International Journal of Tuberculosis and Lung Disease. 2014;**18**:352-356

[126] Malone RS, Fish DN, Spiegel DM, Childs JM, Peloquin CA. The effect of hemodialysis on cycloserine, ethionamide, para-aminosalicylate, and clofazimine. Chest. 1999; **116**:984-990

[127] Malone RS, Fish DN, Spiegel DM, Childs JM, Peloquin CA. The effect of hemodialysis on isoniazid, rifampin, pyrazinamide, and ethambutol. American Journal of Respiratory and Critical Care Medicine. 1999;**159**(5 pt 1):1580-1584

[128] Alsultan A, Peloquin CA. Therapeutic drug monitoring in the treatment of tuberculosis: An update. Drugs. 2014;**74**:839-854

[129] Fish DN, Chow AT. The clinical pharmacokinetics of levofloxacin. Clinical Pharmacokinetics. 1997;**32**:101-119

[130] Launay-Vacher V, Izzedine H, Deray G. Pharmacokinetic considerations in the treatment of tuberculosis in patients with renal failure. Clinical Pharmacokinetics. 2005;**44**:221-235

[131] Saukkonen JJ, Cohn DL, Jasmer RM, Schenker S, Jereb JA, Nolan CM, et al. An official ATS statement: Hepatotoxicity of antituberculosis therapy. American Journal of Respiratory and Critical Care Medicine. 2006;**174**:935-952

[132] Yee D, Valiquette C, Pelletier M, Parisien I, Rocher I, Menzies D. Incidence of serious side effects from first-line antituberculosis drugs among patients treated for active tuberculosis. American Journal of Respiratory and Critical Care Medicine. 2003;**167**:1472-1477

[133] Chang KC, Leung CC, Yew WW, Lau TY, Tam CM. Hepatotoxicity of pyrazinamide: Cohort and case-control analyses. American Journal of Respiratory and Critical Care Medicine. 2008;**177**:1391-1396

[134] Cruz-Hervert LP, García-García L, Ferreyra-Reyes L, Bobadilla-Del-Valle M, Cano-Arellano B, Canizales-Quintero S, et al. Tuberculosis in ageing: High rates, complex diagnosis and poor clinical outcomes. Age and Ageing. 2012;**41**:488-495

IntechOpen