

We are IntechOpen, the world's leading publisher of Open Access books Built by scientists, for scientists

6,900

Open access books available

186,000

International authors and editors

200M

Downloads

Our authors are among the

154

Countries delivered to

TOP 1%

most cited scientists

12.2%

Contributors from top 500 universities



WEB OF SCIENCE™

Selection of our books indexed in the Book Citation Index
in Web of Science™ Core Collection (BKCI)

Interested in publishing with us?
Contact book.department@intechopen.com

Numbers displayed above are based on latest data collected.
For more information visit www.intechopen.com



Clinical and Radiological Assessment of Acetabular Fracture

Balaji Zacharia, Dhiyaneswaran Subramaniam and
Muhammed Ayyub

Additional information is available at the end of the chapter

<http://dx.doi.org/10.5772/intechopen.76114>

Abstract

Acetabular fractures are one of the rare injuries. They are usually occurring following a high energy trauma. The type of acetabular fractures is mainly depend on the position of the femoral head at the time of injury. The acetabular fracture are usually associated with visceral and neurovascular injuries. There can be anterior, posterior or central fracture dislocation associated with this injury. A closed degloving injury of the subcutaneous tissue which is detached from the underlying fascia-Morel-Lavelle lesion is also common feature. The sciatic nerve injury can be associated with posterior wall or column injuries. The most commonly used investigation are anteroposterior, Judet views and 2D/3D computerized tomography. Most commonly used classification is modified Judet and Letournel classification. They divided acetabular fractures into five simple fracture patterns and five associated fracture pattern. The Orthopedic trauma association modified Letournel classification and gave computerized coding. In this chapter, we are describing the clinical features and classification of acetabular fracture in a simple and vivid manner.

Keywords: acetabular fractures, Judet and Letournel classification, Morel-Lavelle lesion, Judet views, spur sign

1. Introduction

Acetabular fractures are one of the rare injuries. The incidence of acetabular fracture is about 3 per 1 lakh population. There are bimodular pattern of occurrence of acetabular fractures. In elderly patients, it is usually produced by low energy trauma and in younger patients it is produced by high energy trauma. The pattern of fracture is mainly determined by the

position of femoral head at the time of injury, force vector and quality of bone. This fracture are usually associated visceral and neurovascular injuries. In this chapter, we are going to describe the clinical feature and classification of acetabular fractures.

2. Clinical features

The most common cause of injury in acetabular fractures is road traffic accidents and fall from a height [1, 2]. Usually acetabular fractures are associated with other major visceral injuries. There are very few literature available on the relationship of non-orthopedic injuries associated with acetabular fractures. Even though most of the acetabular fractures are caused due to axial compression along the femur, driving the femoral head into the acetabulum [3]. In a study on patients with combined pelvic and acetabular fractures, Dalal et al. reported 27% with traumatic brain injuries, even though there was relatively low rate of abdominal injuries [4]. According to him, some of the causative energy of the injury pattern is distributed to long bones before it reaches pelvis and torso, thus producing lower extremity fractures. Most of the posterior wall or column fractures are caused by axial forces transmitted to the acetabulum by knee and femur with the hip in adducted and flexed position—Dashboard injury. The other fracture pattern is caused by direct lateral compression force transmitted through the trochanter or indirect axial force along the femur in extended position of hip joint [5, 6]. In yet another study, it was noted that axial load pattern of injuries were associated with lung injury, retroperitoneal haematoma, traumatic brain injury and lower extremity fractures whereas incidence of genito-urinary injury, hepatic and splenis injury, pelvic vascular injury are more associated with lateral compressive type of acetabular fracture [7].

Life threatening injuries like head injury, abdominal and other visceral injury must get priority in the initial evaluation of acetabular fracture. Other skeletal injuries, like fractures of patella-ipsilateral shaft of femur, tibial plateau fractures and knee ligamentous injury are also looked into. The lower limb will be flexed, adducted and internally rotated in posterior dislocation of hip which is usually associated with posterior wall or column fracture whereas it will be in abducted, extended and externally rotated in anterior dislocation. Lateral displacement of the anterior superior iliac spine on the affected side might give clue regarding central fracture dislocation of hip. Local injuries including skin, open acetabular fractures and perineum and scrotal injury must be excluded. A closed degloving injury of the subcutaneous tissue which is detached from the underlying fascia—Morel-Lavele lesion must be looked into because of the risk of high infection and wound healing in post-operative period. These lesions are not apparent initially but become evident later [8]. A careful neurological examination to rule out sciatic and common peroneal nerve injury should be done. There are isolated reports of injury to iliofemoral artery associated with high anterior column fracture and superior gluteal artery injury in displaced fracture into the greater sciatic notch. Hence, high index of suspicion should be there to rule out vascular injury of the ipsilateral lower limb [9, 10].

Sometimes acetabular fracture can produce profuse bleeding and shock. According to Letournel and Judet “the cause of shock relates to severity of trauma and to hemorrhage from the fracture site and often from other visceral lesions. The respective part played by the various elements producing the shock may be difficult to apportion” [4]. According to Dalal et al. patients with

acetabular fractures needed lower transfusion rate than with pelvic fractures. But in yet another study out of 16 acetabular fracture, 2 fracture required embolization compared to 9 of the 100 pelvic fractures. The transverse and posterior wall fractures often require blood transfusion. Both column fractures, T-shaped fracture, fracture with extension into the sciatic notch and those fracture associated with pelvic injury are more likely to have greater blood loss and may need blood transfusion [11].

3. Radiological anatomy

Accurate classification of acetabular injury is important for its proper treatment. Various classification system have been suggested because of the complex anatomy of the acetabulum. Judet and Letournel classification is the most widely accepted and commonly used classification. Radiograph provides most of the essential information for classifying acetabular fractures. Computerized tomography with 3D reconstruction imaging is also useful in classifying acetabular fractures [12–16].

The acetabulum is an incomplete hemispherical socket with an inverted horseshoe shaped articular surface surrounding the non-articular cotyloid fossa. The articular socket is composed of and supported by two lamda [λ] shaped columns as described by Judet and Letournel (**Figure 1**). The anterior and posterior walls are extensions of the respective column and forms the cup of the acetabulum [16–18]. The anterior column is longer and larger and composed of

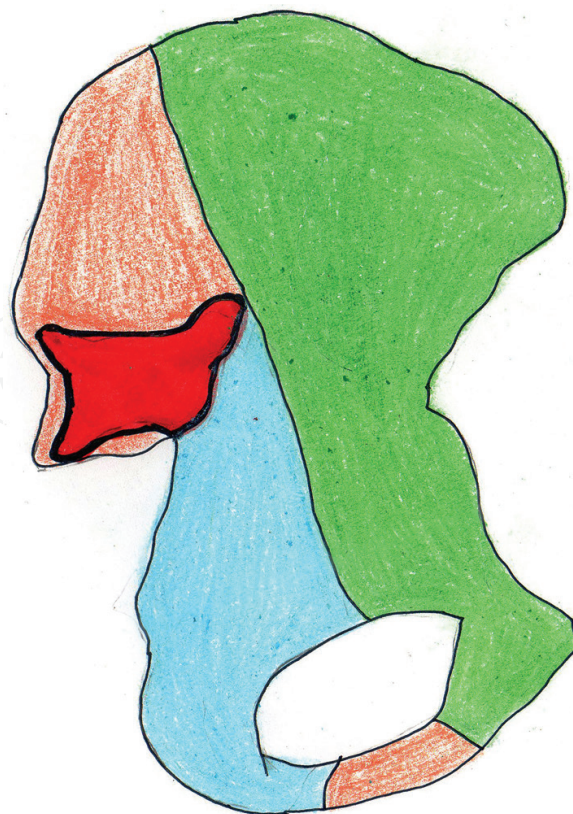

Figure 1. Columns of acetabulum. Blue—Posterior column. Green—Anterior column. Red—Sciatic buttress.

iliac crest, iliac spine, anterior half of the acetabulum and pubis. The posterior column extends superiorly from the ischiopubic ramus and consists of ischium, ischial spine and the posterior half of the acetabulum and the dense bone forming the sciatic notch. The anterior and the posterior columns meet at the sciatic buttress. The sciatic buttress extends posteriorly from anterior and posterior column to become the articular surface of the sacroiliac joint thus connecting the columns with the axial skeleton. The roof (dome) of the acetabulum is the weight bearing area that supports the femoral head. The quadrilateral plate is flat thin bone which is forming the medial wall of acetabulum. The iliopectineal eminence is the prominent part in the anterior column that lies directly over the femoral head.

4. Radiological evaluation

The radiographic evaluation of the acetabulum includes an antero-posterior (AP) view and Oblique (Judet) views [19]. Minimal individual variations of the normal articular area can be visualized by comparing the anatomical landmarks of both hips. For example, comparison of the medial clear space between the head and tear drop will give a clue regarding femoral head subluxation. The iliopectineal line represents the anterior column and ilioischial line represents the posterior column. A line joining the lateral edge of sourcil to lateral edge of the inferior tear drop represents the anterior wall and a line representing the lateral edge of superior acetabulum to the lateral sclerotic area in the inferior margin of acetabulum represents the posterior wall [20].

In the AP radiograph, we have to look into certain radiological landmarks.

1. Iliopectineal line.
2. Ilioischial line.
3. Tear drop (formed laterally by inner wall of acetabulum and medially by quadrilateral plate).
4. Roof.
5. Anterior wall.
6. Posterior wall.

The iliac oblique view will clearly show anterior wall and posterior column, quadrilateral surface and posterosuperior roof arc. The obturator oblique view will show posterior wall, anterior column and anterosuperior roof arc. The obturator ring represents parts of both columns, and fracture of the obturator ring may be associated with other pelvic injuries like lateral pelvic compression injury or sacral fracture.

Evaluation of the acetabular fracture is made easier by both 2D and 3D CT scan [21]. The entire pelvis is usually included in the tomogram to avoid missing a fracture and comparison of the opposite side. The newer spiral CT scan of 1.5 mm and continuous bone section through the pelvis and acetabulum can be obtained. The 3D reconstruction view will help the surgeon to understand the fracture pattern and its anatomical location inter-operatively. Fracture lines in sagittal and coronal planes, marginal impaction, intra-articular loose fragments, concentricity

of the reduction, rotation of the articular fragment and other associated pelvic injuries can be very well visualized in CT scan. Fracture lines in the sagittal plane represent transverse and wall fractures. Fracture lines in the coronal plane represent column fracture and the vertical limb of T-fracture. Magnetic resonance imaging (MRI) has no value in the immediate evaluation or classification, but is useful in determining the vascularity of femoral head at a later date [22].

5. Classification

The universally accepted classification of acetabular fracture was described by Judet and Letournel in 1964 and later modified by Letournel [12, 14]. This classification helps the surgeon to approach acetabular fracture in a more anatomical and fracture biomechanics. The Orthopaedic Trauma Association (OTA) modified Letournel classification and gave computerized coding according to AO comprehensive classification of fractures of long bones [23]. According to Judet and Letournel classification, acetabular fractures are divided into two basic groups: simple fracture type and complex fracture type. Each group consists of five types. The simple fracture pattern includes isolated anterior and posterior wall fractures, isolated anterior and posterior column fractures and transverse fracture (**Figure 2**). The Associated fracture pattern includes T-type fracture, combined fractures of posterior column and wall, transverse fracture with posterior wall fracture, anterior column with posterior hemitransverse fracture and bicolumnar

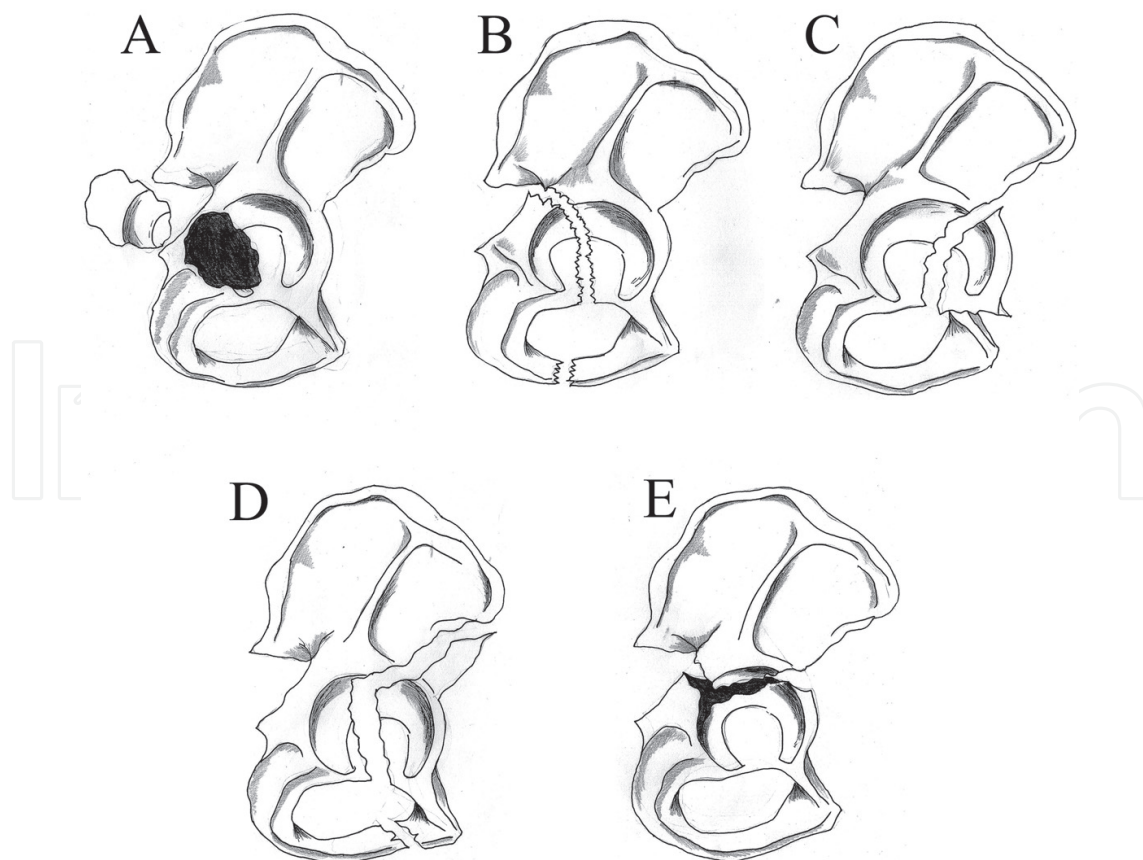


Figure 2. Simple acetabular fractures. (A) Posterior wall fracture (B) Posterior column fracture (C) Anterior wall fracture (D) Anterior column fracture (E) Transverse fracture.

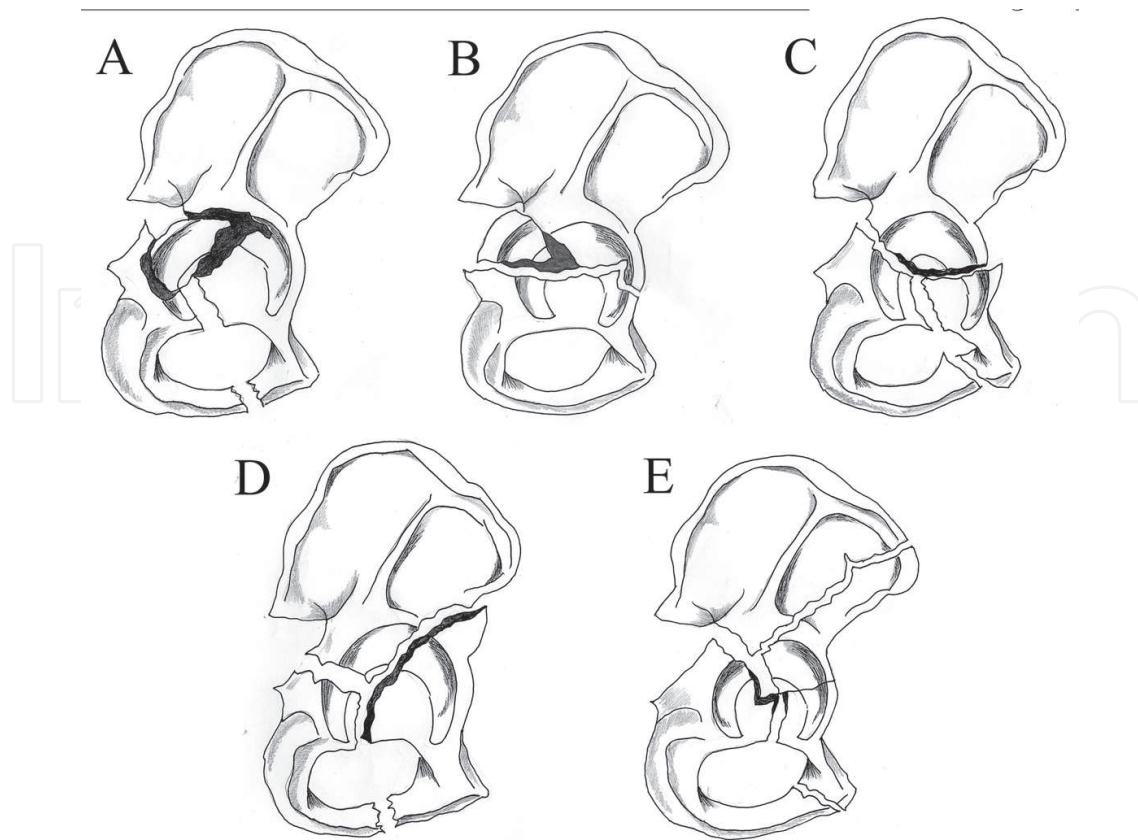


Figure 3. Associated fractures. (A) Posterior wall with posterior column fracture (B) Transverse with posterior wall fracture (C) T shaped fracture.(D) Anterior column with posterior hemitransverse fracture.(E) Bicolumn fracture.

fracture (**Figure 3**). There is one exception in each group. The transverse fracture in the simple group involves both columns and the anterior column with posterior hemitransverse fracture involves only one column in complex group [24].

6. Simple fractures

6.1. Posterior wall fracture

This is the most common type of acetabular fracture. It involves disruption of the posterior wall which can be single or multifragmentary. There can be marginal impaction or acetabular depression fracture commonly associated with the posterior dislocation of the hip joint and radiologically identifiable disruption of the posterior wall with break in the sagittal plane of CT scan.

6.2. Posterior column fracture

Characterized by disruption of the ischial portion of the pelvis and fracture line usually extends through the sciatic buttress. The fracture line usually extends from obturator foramen to greater sciatic notch through weight bearing dome of the acetabulum. The iliac oblique view shows

break in the ilioischial line and displaced articular cartilage along with posterior segment with an intact portion of roof, creating an image resembling a flying bird (Gull sign) [11]. In CT scan, fracture line will be seen in the posterior column in the coronal plane of axial section.

6.3. Anterior wall fractures

It involves disruption of anterior wall. The radiograph demonstrate disruption in the iliopectineal line which is best seen in iliac oblique view. CT scan demonstrates fracture in sagittal plane of axial cut.

6.4. Anterior column fracture

The fracture disrupts iliopectineal line. The fracture line extends from anterior iliac crest to superior pubic ramus disrupting the obturator foramen. Obturator oblique view will show fracture line disrupting the anterior column. In high or intermediate anterior column fractures, the roof segment usually displaces medially. CT scan shows fracture in coronal plane in the anterior column of axial section.

6.5. Transverse fracture

This fracture separates acetabulum into two segments transversely. It involves both columns with intact obturator foramen. This fracture is subdivided into three types according to the level of fracture, namely infratectal, juxtatectal and supratectal [11] (**Figure 4**). Radiographically, both iliopectineal and ilioischial lines will be disrupted. In CT scan, it is characterized by sagittal-oriented fracture line extending through both columns.

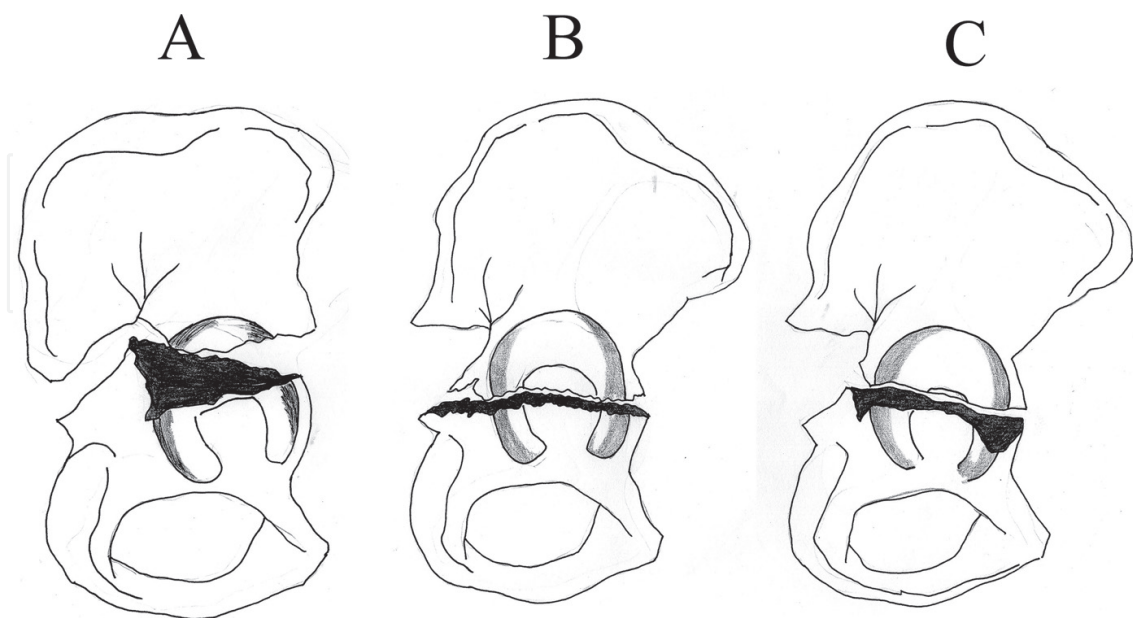


Figure 4. Types of transverse fractures. (A) Supratectal fracture (B) Transtectal fracture (C) Infratectal fracture.

7. Associated Fracture Patterns

7.1. T-shaped acetabular fractures

T-shaped fracture is a combination of transverse acetabular fracture with vertical extension into obturator ring disrupting it. Sometimes there is extension of fracture into pubic ramus and ischium. The vertical fracture component differentiates this fracture from transverse fracture. But the superior extension of the fracture does not involve the iliac wing which is an important point to differentiate this fracture from both column fracture. On the radiograph, both iliopectineal and ilioischial lines will be disrupted in both Judet views. On the CT scan, the transverse component will be seen in sagittal plane of axial image.

7.2. Both column fracture

There are many fracture patterns which involve both column like transverse, T-shaped fracture, transverse with posterior wall but all these fractures have to be differentiated from both column fracture. It is one of the commonest acetabular fracture pattern [13]. This fracture is differentiated from all other fracture patterns in that articular surface is completely detached from the remaining portion of the iliac wing which articulates to the sacrum. The anterior and posterior columns separate from each other. It is actually a fracture involving anterior and posterior columns with fracture line extension into the obturator ring and iliac wing. Obturator ring and iliac wing involvement is a must for diagnosing this fracture pattern. Sometimes, CT scan is the only investigation to identify this fracture type. The pathognomonic sign of both column fracture is the presence of spur sign in obturator oblique view, which means the remaining portion of the ilium attached to the sacrum with sciatic buttress is seen projected lateral to the medially displaced acetabulum. Central dislocation of the femoral head is usually seen in the AP view. CT scan shows fracture involving both the columns with disruption of obturator ring and inferior pubic ramus. The main fracture line extending superiorly from the acetabulum into the iliac wing is seen in the coronal plane.

7.3. Transverse fracture with posterior wall

This fracture pattern has the characteristics of both transverse and posterior wall fractures described above. It will not disrupt the obturator foramen. In the radiograph both iliopectineal and ilioischial lines will be disrupted. Additional fracture in the posterior wall will also be seen. Obturator oblique views and CT scan will help to identify the posterior wall fracture.

7.4. Anterior column with posterior hemitransverse fracture

The fracture line usually extends from antero-inferior iliac spine and passes inferiorly through the cotyloid fossa exiting at the superior ramus disrupting the obturator foramen. A pure transverse fracture of the posterior column alone is seen with it. It is sometimes referred as reverse T-fracture. Usually the transverse component will be undisplaced. The iliopectineal line will be always disrupted. Obturator oblique view is the most ideal view to pick up this fracture in radiograph. CT scan helps to distinguish it from transverse and T-fractures.

7.5. Posterior column with posterior wall fracture

The fracture line will extend from the sciatic notch to the obturator ring through the cotyloid fossa. The AP view shows disruption of ilioischial line. The obturator view shows posterior wall fracture and iliac oblique view shows posterior column fracture.

Comprehensive classification has been developed to standardize the nomenclature world-wide. An alpha-numeric classification system was developed by AO group for acetabular fractures based on its severity.

Type A-Fracture involving single wall or column.

Type B-Fracture involving both anterior and posterior columns (T-type and transverse fracture).

Type C-Fracture involving both anterior and posterior columns, but all articular segments including the roof are detached from *the* remaining segment of intact ilium (Both column fracture).

The evaluation and classification of acetabular fractures based on Judet and Letournel can be concluded like this:

A. Acetabular fracture with intact obturator ring. The possibilities are:

1. Anterior wall fracture (iliopectineal line alone disrupted with anterior wall disruption).
2. Posterior wall fracture (posterior wall disruption).
3. Transverse fracture (Both iliopectineal and ilioischial lines disrupted).
4. Transverse with posterior wall fracture (both iliopectineal and ilioischial lines with posterior wall disruption).

B. Acetabular fractures with obturator ring disrupted are:

1. Anterior column fracture (iliopectineal line disruption).
2. Anterior column with posterior hemitransverse (both iliopectineal and ilioischial line disruption).
3. Posterior column fracture (Ilioischial line disruption).
4. Posterior column with posterior wall fracture (Ilioischial and posterior wall disruption).
5. T-shaped fracture (both iliopectineal and ilioischial line disruption).

C. Acetabular fracture with obturator foramen disruption with fracture line extending to the iliac wing.

1. Bicolumn Fracture (Spur Sign).

AO comprehensive classification of the fractures acetabulum.

Type A: Partial articular, one column involved.

A₁-Posterior wall fracture.

A₂-Posterior column fracture.

A₃-Anterior wall or anterior column fracture.

Type B: Partial articular fracture.

B₁-Transverse fracture.

B₂-T shaped fracture.

B₃-Anterior column + posterior hemitransverse fracture.

Type C: Complete articular fracture.

C₁-Both column fracture, high variety.

C₂-Both column fracture, low variety.

C₃-Both column fractures involving the sacroiliac joint.

In a review of 229 patients with acetabular fractures by Herman et al. found certain fracture patterns, which cannot be included in any one of the Judet and Letournel classification. They have proposed a newer classification system based combination between the displacement vector of the fractures and the specific fracture architectural structures. But further studies are required to evaluate the utility of the proposed classification [25].

8. Principles of treatment

The aim of treatment of any acetabular fracture is to get anatomical reduction and stable fixation and early mobilization and delayed weight bearing. This can be achieved either by operative or non-operative treatment. In displaced fracture more than 2 mm, the roof arc angle $<30^\circ$, Failure to achieve and maintain concentric reduction by closed methods, incarcerated or impacted intra-articular fragments are indication for open reduction. If there is vascular or sciatic nerve injury developing following a closed manipulation such situation warrants emergency ORIF. In patients with poor bone quality, late presentation, medical contraindication, severely comminuted fracture, secondary congruency can be treated non operatively. Most of the fractures are reduced using the principle of ligamentotaxis. Interfragmentary screws are used for rigid fixation which should be protected using reconstruction plate in the neutralization mode [26].

Contributions

All authors helps in collecting data, analysis, statistics, writing and editing the manuscript. We have no conflict of interest for this manuscript and we have not accepted any financial assistance from within or outside of our institution for collecting data, writing manuscript and for its publications

Author details

Balaji Zacharia*, Dhiyaneswaran Subramaniyam and Muhammed Ayyub

*Address all correspondence to: balaji.zacharia@gmail.com

Department of Orthopedics, Govt. Medical College, Kozhikkode, Kerala, India

References

- [1] Hanschen M, Pesch S, Huber-Wagner S, Biberthaler P. Management of acetabular fractures in the geriatric patient. *SICOT-Journal*. 2017;**3**:37
- [2] Mesbahi SAR, Ghaemmaghami A, Ghaemmaghami S, Farhadi P. Outcome after surgical management of acetabular fractures: A 7-year experience. *Bulletin of Emergency & Trauma*. 2018;**6**(1):37-44
- [3] Letournel E, Judet R, Elson AR. Mechanics of acetabular fractures. In: *Fractures of the Acetabulum*. New York, NY: Springer-Verlag; 1993
- [4] Dalal SA, Burgess AR, Siegel JH, et al. Pelvic fracture in multiple trauma: Classification by mechanism is key to pattern of organ injury, resuscitative requirements, and outcome. *The Journal of Trauma*. 1989;**29**:981-1000
- [5] Liebergall M, Mosheiff R, Safran O, Peyser A, Segal D. The floating hip injury: Patterns of injury. *Injury*. 2002;**33**:717-722
- [6] Papadakos N, Pearce R, Bircher M. Low energy fractures of the acetabulum. *Annals of The Royal College of Surgeons of England*. 2014;**96**(4):297-301
- [7] Porter SE, Schroeder AC, Dzugas SS, Graves ML, Zhang L, et al. Acetabular fracture patterns and their associated injuries. *Journal of Orthopaedic Trauma*. 2008;**22**:165-170
- [8] CL1 S, Trentz O, L2 L. Management of Morel-Lavallee Lesion Associated with pelvic and/or Acetabular fractures. *European Journal of Trauma and Emergency Surgery*. 2008 Dec;**34**(6):554-560
- [9] JL1 F, Reimer BL, Raves JJ. Traumatic iliofemoral arterial injury: An association with high anterior acetabular fractures. *Journal of Vascular Surgery*. 1989 Aug;**10**(2):198-201
- [10] Richard A, Ruffin J, Marsh L. Superior gluteal artery disruption with pelvic and acetabular fractures. *The Iowa Orthopaedic Journal*. 1989;**9**:55-57
- [11] RA M, Tressler MA, Obremskey WT, Kregor PJ. Predicting blood loss in isolated pelvic and acetabular high-energy trauma. *Journal of Orthopaedic Trauma*. 2007 Oct;**21**(9):603-607
- [12] Judet R, Judet J, Letournel E. Fractures of the acetabulum: Classification and surgical approaches for open reduction - preliminary report. *The Journal of Bone and Joint Surgery. American Volume*. 1964;**46**:1615-1646

- [13] Goulet JA, Bray TJ. Complex acetabular fractures. *Clinical Orthopaedics and Related Research*. 1989;**240**:9-20
- [14] Letournel E, Judet R. *Fractures of the Acetabulum*. 2nd ed. Heidelberg, Germany: Springer-Verlag; 1993
- [15] Harris JH Jr, Coupe KJ, Lee JS, Trotscher T. Acetabular fractures revisited. Part 2. A new CT-based classification. *AJR*. 2004;**182**:1367-1375
- [16] Brandser E, Marsh JL. Acetabular fractures: Easier classification with a systematic approach. *AJR*. 1998;**171**:1217-1228
- [17] Martinez CR, Di Pasquale TG, Helfet DL, Graham AW, Sanders RW, Ray LD. Evaluation of acetabular fractures with two- and three-dimensional CT. *Radiographics*. 1992;**12**:227-242
- [18] Hunter JC, Brandser EA, Tran KA. Pelvic and acetabular trauma. *Radiologic Clinics of North America*. 1997;**35**:559-590
- [19] Ohashi K, El-Khoury GY, Abu-Zahra KW, Berbaum KS. Interobserver agreement for letournel acetabular fracture classification with multidetector CT: Are standard Judet radiographs necessary? *Radiology*. 2006;**241**(2):386-391
- [20] Borrelli J Jr, Peelle M, McFarland E, Evanoff B, Ricci WM. Computer-reconstructed radiographs are as good as plain radiographs for assessment of Acetabular fractures. *The American Journal of Orthopedics*. 2008;**37**(9):455-460
- [21] Tosun HB, Serbest S, Gümüştas SA, Uludag A, Celik S. Learning curve for surgical treatment of Acetabular fractures: A retrospective clinical study of a practical and theoretical training course. *Medical Science Monitor*. 2017 Nov 2;**23**:5218-5229
- [22] Jarrod Durkee N, Jacobson J, Jamadar D, Karunakar MA, Morag Y, Hayes C. Classification of common acetabular fractures: Radiographic and CT appearances. *American Journal of Roentgenology*. 2006;**187**(4):915-925
- [23] Marsh JL et al. Fracture and dislocation classification compendium – 2007. Orthopaedic Trauma Association classification, database and outcomes Committee. *Journal of Orthopaedic Trauma*. November–December 2007
- [24] Scheinfeld MH, Dym AA, Spektor M, Avery LL, Joshua Dym R, Amanatullah DF. Acetabular fractures: What radiologists should know and how 3D CT can aid classification. *Radiographics*. 2015;**35**(2):555-577
- [25] Herman A, Tenenbaum S, Ougortsin V, Shazar N. There is no column: A new classification for Acetabular fractures. *The Journal of Bone and Joint Surgery. American Volume*. 2018 Jan 17;**100**(2):e8(1-10)
- [26] Thakkar CJ, Magu NK. Principles of management of acetabular fractures. *Indian Journal of Orthopaedics*. 2002;**36**:13-16