

# We are IntechOpen, the world's leading publisher of Open Access books Built by scientists, for scientists

6,900

Open access books available

185,000

International authors and editors

200M

Downloads

Our authors are among the

154

Countries delivered to

TOP 1%

most cited scientists

12.2%

Contributors from top 500 universities



WEB OF SCIENCE™

Selection of our books indexed in the Book Citation Index  
in Web of Science™ Core Collection (BKCI)

Interested in publishing with us?  
Contact [book.department@intechopen.com](mailto:book.department@intechopen.com)

Numbers displayed above are based on latest data collected.  
For more information visit [www.intechopen.com](http://www.intechopen.com)



---

# The Use of Platelet-Rich Plasma in Dry Eye Disease

---

Marina Viegas Moura Rezende Ribeiro,  
Eurica Adélia Nogueira Ribeiro and  
Luiz Feliciano Ribeiro

Additional information is available at the end of the chapter

<http://dx.doi.org/10.5772/intechopen.76090>

---

## Abstract

Dry eye affects 35% of population, and it is a cause of chronic pain and discomfort. The conventional treatment with lubricants is often not sufficient in moderate to severe cases, which can lead to complications such as keratopathies, corneal opacities, ocular perforations, and visual loss. Platelet-rich plasma (PRP) eyedrops have already been used in ocular surface diseases due to their role in epithelialization and the presence of growth factors and vitamins that are similar to human tears. We intend to make a literature review of the use of platelet-rich plasma in dry eye disease, and present the results of a 13 case series, of diabetic severe dry eye patients that used this alternative treatment.

**Keywords:** dry eye, platelet-rich plasma, wound healing

---

## 1. Introduction

In this chapter we will cover a brief literature review on the use of platelet concentrate in dry eye, especially in moderate and severe cases that are generally refractory to conventional treatment, and we will cite some results of its use in other areas of medicine by several authors.

## 2. Dry eye: definition and classification

The tear has several important functions to the ocular surface, such as lubrication, transport of oxygen, carbon dioxide and other metabolites, immunological actions, and maintenance a stable corneal surface, among others. It is rich in immunoglobulins, growth factors, and vitamin A. It

---

is separated in three layers: the lipid layer, which protects the tear against evaporation and is secreted by Moll, Meibomian, and Zeiss glands [1]; the mucin layer produced by Manz glands, Henle crypts, and corneal and conjunctival cells—this one stays between the hydrophobic ocular surface and the hydrophilic tear film [2]; and the last and the most prevalent layer, the aqueous layer, produced by Wolfring and Krause glands [3].

The most recent definition of dry eye is that it is a multifactorial disease of the tears and ocular surface, which is accompanied by ocular symptoms, in which tear film instability and hyperosmolarity, ocular surface inflammation and damage, and neurosensory abnormalities play etiological roles [4]. The inflammation of the ocular surface can be both the cause and the consequence of dry eye: dysfunction of the lacrimal glands alters the tear composition, leading to hyperosmolarity that stimulates more inflammation [5], and another factor recognized in dry eye pathogenesis is oxidative stress [6].

There are several risk factors for dry eye, all of them are controversial. These are female sex, menopause therapy, omega-3 deficiency, refractive surgeries; use of some medications as antihistaminic drugs, antihypertensive drugs, diuretics, antidepressants, and others; hepatitis C; radiation therapy; Asian race; HIV and HTLV infection; chemotherapy; isotretinoic acid use; large facetectomy incisions; low humidity environments; ovarian dysfunction; and sarcoidosis [7].

This disease is actually classified into two primary categories: these are tear-deficient and evaporative categories. The tear-deficient dry eye group generally can be due to Sjogren's syndrome or non-Sjogren's syndrome. Sjogren's syndrome is an exocrinopathy in which lacrimal secretion deficiency occurs due to an autoimmune process that affects the lacrimal glands, salivary glands, and other organs of the body [8]. Non-Sjogren's syndrome is caused by lacrimal diseases or lacrimal obstruction and by reflex alterations, without autoimmune factor role. Some causes are age-related dry eye, congenital alacrima, familial dysautonomia, sarcoidosis, lymphoma, AIDS (acquired immunodeficiency disease syndrome), gland denervation, lacrimal obstruction as in pemphigus, trigeminal injury, diabetes, neurotrophic keratopathy, use of contact lenses, and motor reflex block due to VII pair injury [9, 10]. The evaporative causes of dry eye disease are due to oil deficit, lid changes, use of contact lenses, or ocular surface diseases, as allergic conjunctivitis, and some of the iatrogenic dry eye that occurs after the use of systemic or topical medications or after surgeries or nonsurgical procedures [8, 11].

Dry eye can be also classified according to severity. One of the schemes is proposed by Delphi Panel [8, 12]. This classification in grades 1–4 (mild to severe) is based on the frequency or intensity of the dry eye symptoms and discomfort, the blurred vision and visual symptoms, conjunctival injection or redness, conjunctival staining, corneal staining, changes in the cornea and tear as in ocular surface, alterations in the glands and lids, tear film break-up time (TFBUT), and Schirmer's test values.

### 3. Epidemiology

Dry eye disease affects from 5 to 50% of population; this discrepancy is probably observed due to the absence of a consensus on the diagnosis of dry eye and the lack of standardization

in its classification [13]. It is more frequently in women [14], probably because of the hormone effects in the ocular surface and eye glands [4].

It is more common in Asia and Europe, with only one study showing the prevalence in South of Equator [4], and it seems to be also more frequent in older people, possibly because of the aging alterations in the lids, glands, ocular surface, and adnexal tissue [15].

#### 4. Diagnosis and treatment

Diagnosis is controversial, and literature shows the lack of correlation between some objective tests and symptoms; this is probably due to the difficulty in understanding dry eye pathophysiology [16].

There are some guidelines in this theme, and one of them is the American Academy of Ophthalmology that relates that dry eye diagnosis is obtained after a clinical approach that include asking the patient about exposition to dry eye risk factors and the most common symptoms and signs like redness, itching, photophobia, dryness, foreign body sensation, or pain. It is also important to ask the patient about the exposition to some kind of pollutant, if he is a smoker, if he has any systemic disease (like dermatological, allergic, or rheumatic diseases), checking the hygiene of eyelashes and eyelids, use of medications, eyedrop use, previous ocular surgeries [17], and use of a screening questionnaire as the OSDI (Ocular Surface Disease Index) [18]. The clinical history is followed by a complete ophthalmological exam, including evaluating the eyelids, skin, nerves, visual acuity, and biomicroscopy, and some specific tests like tear breakup time, tear film osmolarity determination, and ocular surface staining with fluorescein lissamine green [4]. The assessment of the tear meniscus (less than 0.35 mm is abnormal) can be performed, verifying if the blink rate is decreased and evaluate the quality of the tear (if there are mucus and debris) and corneal topography [3].

Management of dry eye disease will depend on the cause of this condition and its severity. There is currently no cure for dry eye, and any causal factors that are amenable to treatment should be treated. It includes modifications of the environment; suspension of topical or systemic medications, associated with worsening when possible; artificial tear lubrication; and eyelid hygiene [19].

Generally, the conventional treatment is the lubricants, but it does not resolve all the cases. There are a wide variety of artificial tears, like 1% sodium hyaluronate, hypotonic solutions, those that contains lipids or substances with bioadhesive properties and formulas that have substances that protects the cell's stress; but none of them has the natural tear properties [20, 21].

Other therapies are topical cyclosporine and corticosteroids [22], but these have some disadvantages such as eye irritation and ocular pressure elevation and cataract, respectively [23, 24]. In moderate cases we can also use systemic supplements with omega-3 and linoleic acids and the increased consumption of water, lacrimal occlusion, and glasses use. In severe dry eye, in addition to all these treatments, we can take another measure like systemic cholinergic agonists, systemic anti-inflammatory agents, mucolytic agents, contact lenses, correction of

palpebral alterations, permanent lacrimal punctal occlusion, tarsorrhaphy, and, finally, the autologous serum tears [17].

The Ebers Papyrus 1534 BC is the first reference in the history of a blood derivative in the eye. In 1975, Ralph et al. used it in dry eye [25]. Fox et al. and later Tsubota related the use of autologous serum as an alternative treatment of severe dry eye cases [26, 27]. During many years of study, fetal bovine serum, allogenic serum, and umbilical cord serum have been used; however, they are heterologous, the risks of infections or allergic reactions are increased, and their use is not possible in any center [28]. It does not have preservative, and it is rich in vitamins, fibronectin, growth factors, and cytokines and has biomechanical properties similar to natural tear film, and they do not have preservative which is common in artificial tears [29]. Epidermal growth factors and vitamin A are important for proliferation, differentiation, and maturation of the ocular surface epithelium [30]. Fibroblast growth factor-beta is also involved in epithelial healing, fibronectin promotes cell migration, albumin has antiapoptotic activity, alpha-2-macroglobulin has anti-collagenase action, platelet-derived growth factor promotes hepatocytes growth factor, and substance P and insulin-like growth factor aid in the migration and adhesion of epithelium to the stroma [31]. The serum also maintains intracellular ATP at acceptable levels and cell membrane integrity [32–35].

Some authors related the use of autologous serum drops in dry eye with some promising results [35, 36].

Kojima et al. in 2005 described increased TFUT in treated group comparing to control group (using artificial tears) [37]. Lee and Chen studied the use of autologous serum in 23 patients by 18 months and found improvements in symptoms and corneal staining pattern in approximately 75% of patients [38].

Other indications for the use of autologous serum have been the epithelial defects [39], graft-versus-host disease [40], neurotrophic keratopathy [41], trabeculectomy ampoules [42], after refractive surgery [43, 44], Mooren's ulcer [45], and other keratitis [46].

Tananuvat et al., in a randomized prospective study, found that control eyes had improvement in symptoms, signs, and rose bengal staining compared with the baseline. However, some advantages neither Schirmer's test results nor tear breakup time improved in treated group [34].

Urzua et al. described in a double-blind crossover clinical trial 12 severe dry eye syndrome patients in which autologous serum treatment showed a statistically significant higher OSDI decrease (50%) versus conventional treatment (22%). There were no significant changes in objective parameters (Oxford corneal staining and TBUT) [47]. A review to evaluate autologous serum efficacy compared to lubricants, in dry eye disease, concluded that there is a great heterogeneity considering the preparation and storage of the eyedrops, as well as the adequate use of this therapy, and that new studies that standardize these items would be necessary [19].

Another alternative, platelet-rich plasma (PRP), can be used in severe dry eye. It is prepared in double centrifugation of total plasma. Some of the important growth factors this hemoderivate has are platelet-derived angiogenesis factor, platelet-derived epithelial growth factor, and platelet factor 4 [48].

The epidermal growth factor accelerates the healing process and epithelial migration in the cornea, besides stimulating the DNA synthesis of the epithelial cells, and is also associated



with the production of mucin 1 by some conjunctival cells. Transforming growth factor b1 (TGF-b1) has an increased levels in the epithelium during corneal stromal repair processes; it stimulates the production of collagen, fibronectin, and proteoglycans and together with the platelet-derived growth factor (PDGF) has an important anti-inflammatory action [49]. Vitamin A is one of the major epitheliotropic factors in autologous serum; it is 100 times more concentrated than in natural tear and prevents squamous epithelial metaplasia [50].

Fibronectin is an important protein to corneal reepithelization, promoting healing and phagocytosis [51]. Annexin A5 has been investigated as an alternative to fibronectin eyedrops. It interacts with some integrins and stimulates the secretion of plasminogen activator-type urokinase, whose expression is increased in epithelial defects. Albumin is one of the most important proteins in the blood. It reduces the natural degradation of cytokines and growth factors in areas of tissue injury and shows antiapoptotic activity [39, 52, 53]. Alpha-2-macroglobulin neutralizes proteolytic enzymes. It is useful in ocular burns and marginal ulcers [32, 39]. Fibroblast growth factor-beta is a factor that promotes corneal healing, increasing cell proliferation and motility [54].

The insulin-like growth factor helps epithelial cell migration [55]. Neural growth factor (NGF) is the most well-known neurotrophin. It restores the function of injured neurons and can be effective in trophic ulcers [56].

One of the PRP advantages is that it has not cytokines derived from leucocytes and monocytes, which are present in autologous serum and can be deleterious in patients with immune diseases [57]. PRP also regulates expression of several genes in the cellular differentiation improving biological activity of the corneal epithelial cells when compared with autologous serum [58].

The PRP protects the ocular surface from scar formation more than autologous serum, because of reduction of myofibroblasts. It has been observed in PRK where patients who had done this surgery has a decreased incidence of haze [59]. PRP causes reduction in inflammation by indirect action, through the reduction of osmolarity, thus, diluting the pro-inflammatory factors existing in the ocular surface. This also occurs because of the presence of the growth factor-rich plasma interleukin-1 receptor antagonist as well as the presence of metalloproteinase [60].

Platelets have a lot of important functions that are repairing tissue damage; coagulation prevents blood loss, secreting proteins, cytokines, and other mediators; inducing tissue regeneration by cell migration, proliferation, and angiogenesis, and preventing infections because of its antibiotic action. They also have an anti-inflammatory and analgesic action [61].

## 5. The use of PRP in medicine and odontology

Platelet-rich plasma has been used in several medical and dental areas. The platelet-rich plasma has approximately 1 million/ml platelets [62], and it has been used to the revitalization of necrotic pulp teeth [63], in periodontitis [64], in revascularization of young teeth [65], and in other oral conditions [66].

Platelet-rich plasma has been used in orthopedic therapies like cartilage repair [67], also in bone regeneration, and in tendons, ligaments, and articular lesions [68].

In dermatology, PRP has been used for wound healing of acne scars [69], vitiligo [70], venous ulcers [71], alopecia [72], skin rejuvenation [73], and some cases of lichen sclerosus [74].

In gynecology, there are studies where PRP had been used in cases of infertility [75], in uterine prolapse [76], in inducing endometrium proliferation [75], and in scars of cesarean sections [77].

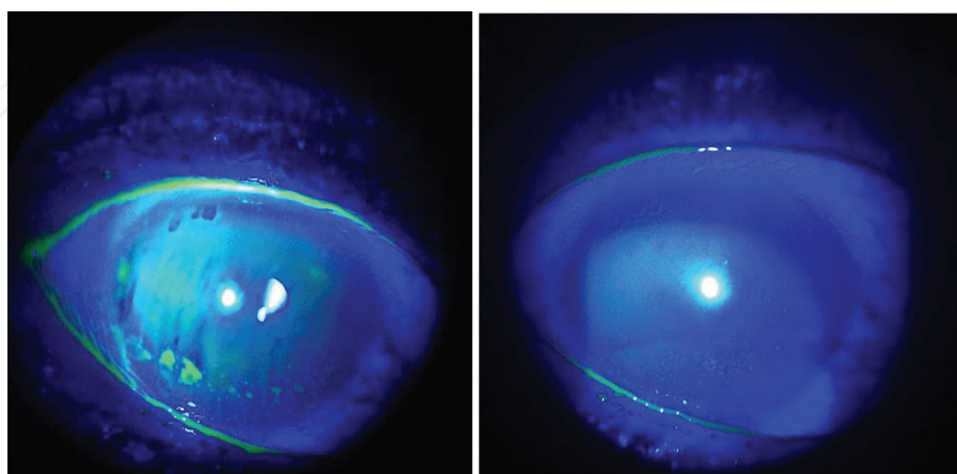
It has also been used in otolaryngology [78], in urinary diseases [79], and in other medical specialties.

## 6. The use of PRP in ophthalmology

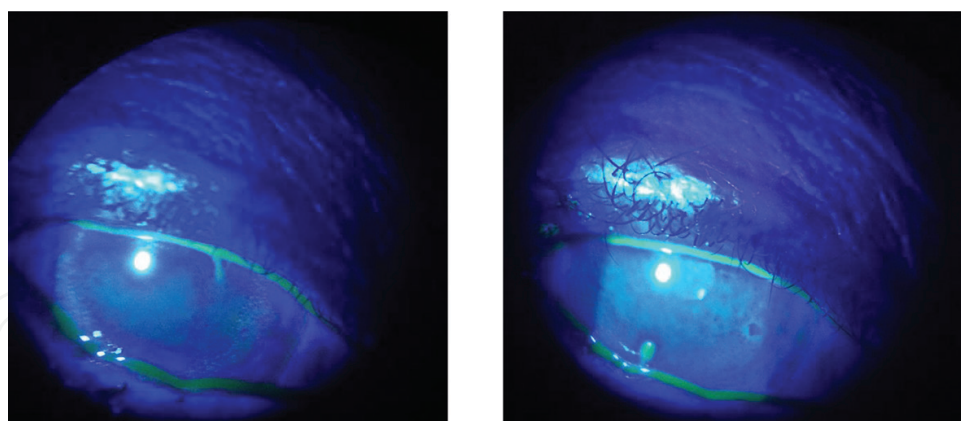
PRP has been reported in corneal ulcers [80–82], in chemical burns [83, 84], in restoration of lacrimal function [85], in blepharoplasties surgeries [86], in ocular surface syndrome after refractive surgeries [44], and in graft-versus-host disease [87].

In dry eye, there are few studies reporting the use of PRP. Alio et al., in 2007, evaluated 18 symptomatic patients that used this treatment for 1 month and observed that symptoms of dry eye improved in 89% of patients, that conjunctival injection was present in 38.9% of patient, that 86% of the symptoms decreased, that lachrymal meniscus improved in 56% of the cases, and that corneal staining also decreased. In impression cytology increase in conjunctival goblet cells was observed [88].

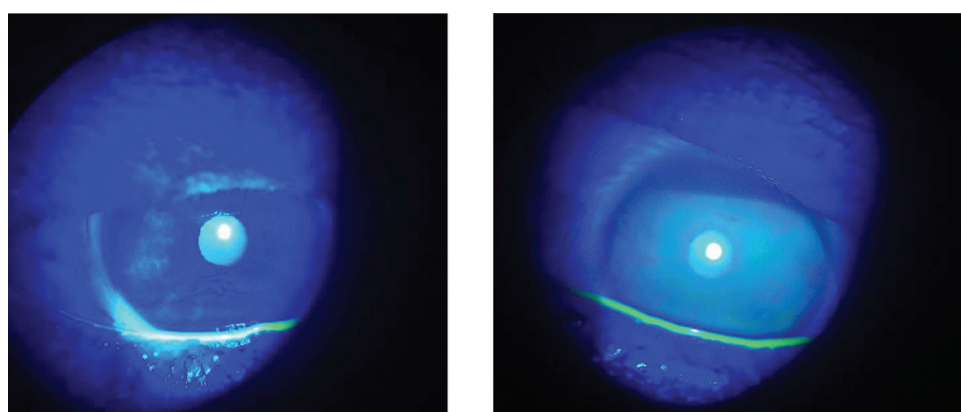
Ribeiro et al., had studied about diabetic dry eye patient. They evaluated 12 patients with grades 2–4 of severity [8, 12]; 41.67% had a reduction in Schirmer's gradation, 58.33% had an increase in TFBUT (tear film breakup time), visual acuity improved in 41.66% of patients, and OSDI questionnaire score significantly improved in 100% of patient. The authors also found that before treatment, 91.67% had severe dry eye and after treatment, 50% were classified as normal, 25% as mild dry eye, 16.66% as moderate dry eye, and just one patient had instead a severe dry eye (**Figures 1–5**) [89].



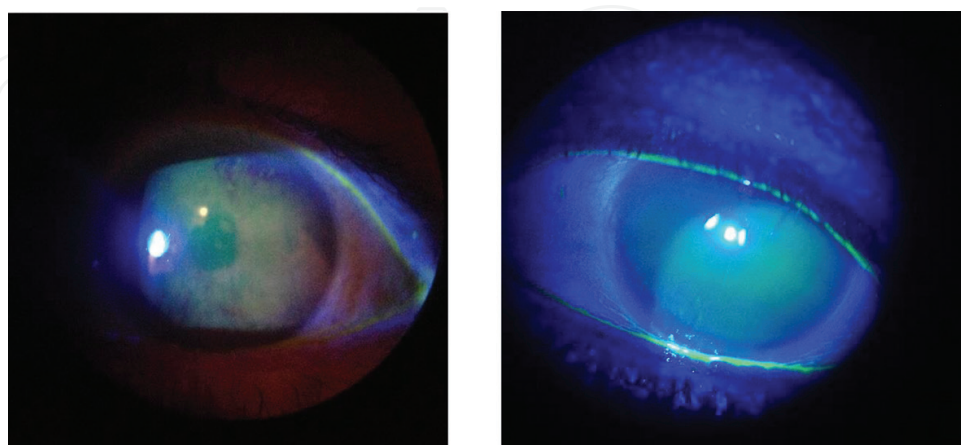
**Figure 1.** Before and after treatment with PRP in patient with diabetic dry eye.



**Figure 2.** Before and after treatment with PRP in patient with diabetic dry eye.

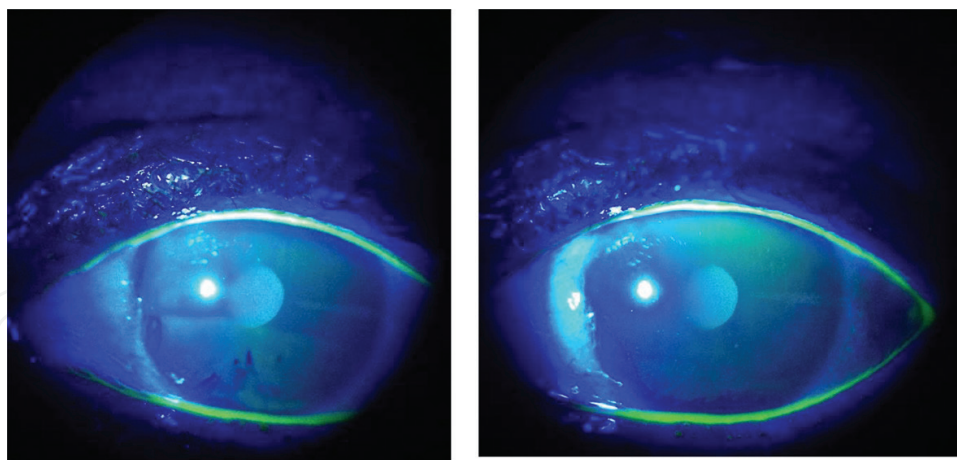


**Figure 3.** Before and after treatment with PRP in patient with diabetic dry eye.



**Figure 4.** Before and after treatment with PRP in patient with diabetic dry eye.





**Figure 5.** Before and after treatment with PRP in patient with diabetic dry eye.

Recently, in 2017, Alio reported a 368-patient prospective, interventional nonrandomized study, where moderate to severe dry eye was included. The results were as follows: Schirmer's test value had a significant improvement, subjective symptoms had an improvement in 87.5% of patients, OSDI scores were statistically significant, 28.8% experienced an increase of one or more lines of vision, decrease in corneal fluorescein staining was observed in 76.1% of patients, and only one patient reported intolerance to the use of PRP due to discomfort at the time of instillation [90].

Another alternative that has been reported in dry eye treatment is the plasma rich in growth factors (PRGF). Lopez-Plandolit et al. observed that PRGF treatment was associated with improvement in score dry eye questionnaire values and as results from impression cytology. In 75% of patients, no further medication was required. But squamous metaplasia did not reduce significantly [49]. It is very similar to PRP; however, there are no researches in human use compared to all the hemoderivates in dry eye.

## 7. The methods of obtaining platelet-rich plasma

The two main methods of obtaining platelets are by autologous donation and by the technique of platelet apheresis. The advantage of the apheresis technique is that the platelet concentration is higher in the final concentrate and should contain at least  $5.5 \times 10^{10}$  platelets, while its disadvantage is the cost that is extremely superior to the autologous total donation technique [48].

In the apheresis technique for platelet collection, Rezende et al. used the Haemonetics MCS + 9000 automatic cell separator and the 995-E apheresis-specific kit (Haemonetics Corp.). In that system, by means of a venipuncture, the blood of the patient himself is drained to a separation device. An optical refraction analyzer separates the platelet layer, and the remaining blood is completely returned to the patient, determining the end of a cycle. Sodium citrate can be used as an anticoagulant in the ratio of 1 to every 9 ml of whole blood processed. In 2 cycles, 72 ml of platelet concentrate was collected; the hematimetric indices of the patient and also the platelet concentrate indices are evaluated before and after the procedure (Coulter AcT Diff) [81].

Platelet growth factors were generally obtained in a ranked room; hence, the handling of platelet concentrate was performed within a Category II-Type A biological safety cabinet. Then, 2800 microliters of 10% calcium chloride was added, and the final product was maintained at +37°C for approximately 30 min. Subsequently, the unit was subjected to centrifugation (900G), and the supernatant serum, which contained the platelet growth factors, was transferred to four 50 ml falcon-type tubes (Becton-Dickinson) and maintained at -80°C (Revco). Research of bacteria, aerobic and anaerobic, and fungal agents was performed in a systematic way.

The release of serum with platelet growth factors in the study by Rezende et al. was done as follows: weekly, thawed Falcon tube containing approximately 10 ml of autologous serum with platelet growth factors that was transferred to flasks, and the patient is advised to keep the biological medicine at a temperature below -10°C (freezer) and to unfreeze it naturally immediately before each use [81].

Alio et al. used the autologous donation technique to obtain platelets, when patients were submitted to venipuncture and 80–100 ml of blood were collected in sterile 10 ml tubes containing 1 ml of sodium citrate to avoid coagulation. These tubes were left at room temperature for 10 min, and only the supernatant (upper tube fraction) was collected as the final product. The platelet concentrate was then prepared under sterile conditions in a laminar flow room. Two to three milliliters of this concentrate was then placed in sterile eyedrops. The eyedrops were kept at -20°C, and only when the patient was going to use an eyedrop bottle, thaw it and then keep it at +4°C, discarding that bottle at the end of a week, when a new one is thawed. The patients were advised to use these eyedrops four times a day for 1 month [88].

Both methods require the patient to perform an autologous blood donation. Autologous blood does not transmit disease; there is no occurrence of hemolytic (alloimmunization), allergic, immunological (immunomodulation), or acute lung injury by transfusion and common complications in heterologous donations [91].

The contraindications for autologous donations are anemia or other types of pathological hemodilution; conditions that lead to oxygen saturation and hemoglobin saturation (less than 11 mg/dl); hepatopathies; nephropathies; coagulopathies; hemoglobinopathies; decompensated heart diseases; and presence of infectious diseases such as Chagas, syphilis, HIV, HTLV, hepatitis B and C, and others transmissible by blood considered as “relative” contraindications, since the patient will receive the same, but there may be contamination of the health team in the handling of that blood. In HIV, there may be reactivation of the virus when reinfused [91, 92].

Complications of autologous donation are those inherent to a donor, such as hypotension, anemia, angina, and contamination of the material of the blood bags [91].

## 8. Conclusions

It can be concluded from these studies that the therapeutic response with PRP was actually satisfactory in severe or moderate dry eye cases which do not respond to conventional

therapy. However, randomized clinical trials are needed so that standardized protocols for the production, storage, and use of this therapy should be created. Prospective studies should also be conducted to evaluate these long-term outcomes.

## Conflict of interest

The authors declare no conflict of interest in this subject.

## Author details

Marina Viegas Moura Rezende Ribeiro<sup>1\*</sup>, Eurica Adélia Nogueira Ribeiro<sup>2</sup> and Luiz Feliciano Ribeiro<sup>3</sup>

\*Address all correspondence to: dra.marinaribeiro@gmail.com

1 Centro Universitário Tiradentes de Alagoas, Universidade Federal de Alagoas, Maceió, Brazil

2 Universidade Federal de Alagoas, Maceió, Brazil

3 Instituto de Olhos de Maceió, Maceió, Brazil

## References

- [1] Yang H-Y et al. Lacrimal punctal occlusion for the treatment of superior limbic keratoconjunctivitis. *American Journal of Ophthalmology*. 1997;**124**(1):80-87
- [2] Xu K-P et al. Tear function index: A new measure of dry eye. *Archives of Ophthalmology*. 1995;**113**(1):84-88
- [3] Fridman D. Associação Entre Hipoestesia Corneana, Olho Seco e Outros Fatores Em Portadores de Diabetes Melito Tipo 2. Tese de Mestrado—Porto Alegre: Universidade Federal do Rio Grande do Sul; 2004
- [4] Nelson JD et al. TFOS DEWS II introduction. *The Ocular Surface*. 2017;**15**:269-275
- [5] Fonseca EC, Arruda GV, Rocha EM. Olho seco: Etiopatogenia e tratamento. *Arquivos Brasileiros de Oftalmologia*. 2010;**73**(2):197-203
- [6] Wakamatsu TH, Dogru M, Tsubota K. Tearful relations: Oxidative stress, inflammation and eye diseases. *Arquivos Brasileiros de Oftalmologia*. 2008;**71**(6):72-79
- [7] Dry Eye Workshop. The epidemiology of dry eye disease: Report of the epidemiology Subcommittee of the International dry eye WorkShop. *The Ocular Surface*. 2007;**5**(2): 93-107

- [8] Dry Eye Workshop. The definition and classification of dry eye disease: Report of the definition and classification Subcommittee of the International dry eye WorkShop. The Ocular Surface. 2007;**5**(2):75-92
- [9] Moss SE, Klein R, Klein BE. Prevalence of and risk factors for dry eye syndrome. Archives of Ophthalmology. 2000;**118**(9):1264-1268
- [10] Schein Oliver D et al. Dry eye and dry mouth in the elderly: A population-based assessment. Archives of Internal Medicine. 1999;**159**(12):1359-1363
- [11] Fujishima H et al. Allergic conjunctivitis and dry eye. British Journal of Ophthalmology. 1996;**80**(11):994-997
- [12] Behrens A et al. Dysfunctional tear syndrome: A Delphi approach to treatment recommendations. Cornea. 2006;**25**(8):900-907
- [13] Brewitt H, Sistani F. Dry eye disease: The scale of the problem. Survey of Ophthalmology. 2001;**45**:S199-S202
- [14] Galor A et al. Prevalence and risk factors of dry eye syndrome in a United States veterans affairs population. American Journal of Ophthalmology. 2011;**152**(3):377-384
- [15] Schaumberg DA et al. Prevalence of dry eye syndrome among US women. American Journal of Ophthalmology. 2003;**136**(2):318-326
- [16] Alves M et al. Comparison of diagnostic tests in distinct well-defined conditions related to dry eye disease. PLoS One. 2014;**9**(5):e97921
- [17] American Academy of Ophthalmology. Dry Eye Syndrome Preferred Practice Pattern: Preferred Practice Pattern. Estados Unidos: AAO; 2013. Disponível em: <http://www.aao.org/preferred-practice-pattern/dry-eye-syndrome-ppp-201>
- [18] Schiffman RM et al. Reliability and validity of the ocular surface disease index. Archives of Ophthalmology. 2000;**118**(5):615-621
- [19] Pan Q et al. Autologous serum eye drops for dry eye. Cochrane Database of Systematic Reviews. 2013;**8**
- [20] Aragona P et al. Effects of amino acids enriched tears substitutes on the cornea of patients with dysfunctional tear syndrome. Acta Ophthalmologica. 2013;**91**(6)
- [21] Klenkler B, Sheardown H, Jones L. Growth factors in the tear film: Role in tissue maintenance, wound healing, and ocular pathology. The Ocular Surface. 2007;**5**(3):228-239
- [22] Pflugfelder SC. Antiinflammatory therapy for dry eye. American Journal of Ophthalmology. 2004;**137**(2):337-342
- [23] Blomquist PH, Palmer BF. Ocular complications of systemic medications. The American Journal of the Medical Sciences. 2011;**342**(1):62-69
- [24] Wang Y et al. Ocular surface and tear functions after topical cyclosporine treatment in dry eye patients with chronic graft-versus-host disease. Bone Marrow Transplantation. 2008;**41**(3):293

- [25] Ralph RA, Doane MG, Dohlman CH. Clinical experience with a mobile ocular perfusion pump. *Archives of Ophthalmology*. 1975;**93**(10):1039-1043
- [26] Tsubota K et al. Surgical reconstruction of the ocular surface in advanced ocular cicatricial pemphigoid and Stevens-Johnson syndrome. *American Journal of Ophthalmology*. 1996;**122**(1):38-52
- [27] Fox RI et al. Beneficial effect of artificial tears made with autologous serum in patients with keratoconjunctivitis sicca. *Arthritis & Rheumatology*. 1984;**27**(4):459-461
- [28] Yoon K-C et al. Comparison of autologous serum and umbilical cord serum eye drops for dry eye syndrome. *American Journal of Ophthalmology*. 2007;**144**(1):86-92
- [29] Liu L et al. An optimised protocol for the production of autologous serum eyedrops. *Graefe's Archive for Clinical and Experimental Ophthalmology*. 2005;**243**(7):706-714
- [30] Woost PG et al. Growth factors and corneal endothelial cells: I. Stimulation of bovine corneal endothelial cell DNA synthesis by defined growth factors. *Cornea*. 1992;**11**(1):1-10
- [31] Oftalmología, Aplicaciones Del Suero Autólogo En. Use of autologous serum in ophthalmic practice. *Archivos de la Sociedad Española de Oftalmología*. 2007;**82**:9-20
- [32] Poon AC et al. Autologous serum eyedrops for dry eyes and epithelial defects: Clinical and in vitro toxicity studies. *British Journal of Ophthalmology*. 2001;**85**(10):1188-1197
- [33] Koffler BH. Autologous serum therapy of the ocular surface with novel delivery by platelet concentrate gel. *The Ocular Surface*. 2006;**4**(4):188-195
- [34] Tananuvat N et al. Controlled study of the use of autologous serum in dry eye patients. *Cornea*. 2001;**20**(8):802-806
- [35] Young HJ, Lee YJ, Yun P-Y. Management of ocular surface inflammation in Sjögren syndrome. *Cornea*. 2007;**26**:S13-S15
- [36] Noble BA et al. Comparison of autologous serum eye drops with conventional therapy in a randomised controlled crossover trial for ocular surface disease. *The British Journal of Ophthalmology*. 2004;**88**(5):647-652
- [37] Kojima T et al. The effect of autologous serum eyedrops in the treatment of severe dry eye disease: A prospective randomized case-control study. *American Journal of Ophthalmology*. 2005;**139**(2):242-246
- [38] Lee GA, Chen SX. Autologous serum in the management of recalcitrant dry eye syndrome. *Clinical & Experimental Ophthalmology*. 2008;**36**(2):119-122
- [39] Tsubota K et al. Treatment of persistent corneal epithelial defect by autologous serum application. *Ophthalmology*. 1999;**106**(10):1984-1989
- [40] Mixon B et al. Autologous serum eye drops for severe dry eye syndrome in a patient with chronic graft-versus-host disease: A case report. *International Journal of Pharmaceutical Compounding*. 2013;**18**(5):370-377



- [41] Matsumoto Y et al. Autologous serum application in the treatment of neurotrophic keratopathy. *Ophthalmology*. 2004;**111**(6):1115-1120
- [42] Matsuo H et al. Topical application of autologous serum for the treatment of late-onset aqueous oozing or point-leak through filtering bleb. *Eye*. 2005;**19**(1):23
- [43] Noda-Tsuruya T et al. Autologous serum eye drops for dry eye after LASIK. *Journal of Refractive Surgery*. 2006;**22**(1):61-66
- [44] Javaloy J et al. Effect of platelet-rich plasma in nerve regeneration after LASIK. *Journal of Refractive Surgery*. 2013;**29**(3):213-219
- [45] Mavrakanas A, Kiel R, Dosso AA. Autologous serum application in the treatment of Mooren's ulcer. *Klinische Monatsblätter für Augenheilkunde*. 2007;**224**(4):300-302
- [46] López-García JS et al. Autologous serum eyedrops in the treatment of aniridic keratopathy. *Ophthalmology*. 2008;**115**(2):262-267
- [47] Urzua CA, Vasquez DH, Huidobro A, Hernandez H, Alfaro J. Randomized double-blind clinical trial of autologous serum versus artificial tears in dry eye syndrome. *Current Eye Research*. 2012;**37**(8):684-688
- [48] Razouk FH, Edna R. Characterization, production and indication of the principal blood components. *Revista Brasileira de Hematologia e Hemoterapia*. 2004;**26**(2):126-134
- [49] López-Plandolit S et al. Efficacy of plasma rich in growth factors for the treatment of dry eye. *Cornea*. 2011;**30**(12):1312-1317
- [50] Geerling G, MacLennan S, Hartwig D. Autologous serum eye drops for ocular surface disorders. *British Journal of Ophthalmology*. 2004;**88**(11):1467-1474
- [51] Mai PT et al. Topical fibronectin in an alkali burn model of corneal ulceration in rabbits. *Archives of Ophthalmology*. 1991;**109**(3):414-419
- [52] Unterlaufft JD et al. Albumin eye drops for treatment of ocular surface diseases. *Der Ophthalmologe: Zeitschrift der Deutschen Ophthalmologischen Gesellschaft*. 2009;**106**(10):932-937
- [53] Shimmura S et al. Albumin as a tear supplement in the treatment of severe dry eye. *British Journal of Ophthalmology*. 2003;**87**(10):1279-1283
- [54] Jens LA, Ehlers N. Chemotaxis of human keratocytes is increased by platelet-derived growth factor-BB, epidermal growth factor, transforming growth factor-alpha, acidic fibroblast growth factor, insulin-like growth factor-I, and transforming growth factor-beta. *Current Eye Research*. 1998;**17**(1):79-87
- [55] Yamada N et al. Role of the c domain of IGFs in synergistic promotion, with a substance P-derived peptide, of rabbit corneal epithelial wound healing. *Investigative Ophthalmology & Visual Science*. 2004;**45**(4):1125-1131

- [56] Matsuura N et al. Predominance of infiltrating IL-4-producing T cells in conjunctiva of patients with allergic conjunctival disease. *Current Eye Research*. 2004;**29**(4-5):235-243
- [57] Gomes B et al. Signs and symptoms of ocular surface disease in patients on topical intraocular pressure-lowering therapy. *Arquivos Brasileiros de Oftalmologia*. 2013;**76**(5):282-287
- [58] Freire V et al. In vitro effects of three blood derivatives on human corneal epithelial cells blood derivatives in human corneal epithelial cells. *Investigative Ophthalmology & Visual Science*. 2012;**53**(9):5571-5578
- [59] Eduardo A et al. Plasma rich in growth factors (PRGF-Endoret) stimulates corneal wound healing and reduces haze formation after PRK surgery. *Experimental Eye Research*. 2013;**115**:153-161
- [60] Alio JL et al. Use of autologous platelet-rich plasma in the treatment of dormant corneal ulcers. *Ophthalmology*. 2007;**114**(7):1286-1293
- [61] Amable PR, Carias RBV, Teixeira MVT, da Cruz Pacheco Í, Corrêa do Amaral RJF, Granjeiro JM, Borojevic R. Platelet-rich plasma preparation for regenerative medicine: Optimization and quantification of cytokines and growth factors. *Stem Cell Research & Therapy*. 2013;**4**(3):67
- [62] Brass L. Understanding and evaluating platelet function. Hematology/the Education Program of the American Society of Hematology American Society of Hematology Education Program. 2010;**2010**:387-396
- [63] Torabinejad M, Turman M. Revitalization of tooth with necrotic pulp and open apex by using platelet-rich plasma: A case report. *Journal of Endodontia*. 2011;**37**(2):265-268
- [64] Banchs F, Trope M. Revascularization of immature permanent teeth with apical periodontitis: New treatment protocol? *Journal of Endodontics*. 2004;**30**(4):196-200
- [65] Jadhav G, Shah N, Logani A. Revascularization with and without platelet-rich plasma in nonvital, immature, anterior teeth: A pilot clinical study. *Journal of Endodontics*. 2012;**38**(12):1581-1587
- [66] Shah N, Logani A, Bhaskar U, Aggarwal V. Efficacy of revascularization to induce apexification/apexogenesis in infected, nonvital, immature teeth: A pilot clinical study. *Journal of Endodontia*. 2008;**34**(8):919-925
- [67] Xie X, Zhang C, Tuan RS. Biology of platelet-rich plasma and its clinical application in cartilage repair. *Arthritis Research & Therapy*. 2014;**16**(1):204
- [68] Brossi PM et al. Platelet-rich plasma in Orthopedic therapy: A comparative systematic review of clinical and experimental data in equine and human musculoskeletal lesions. *BMC Veterinary Research*. 2015;**11**:98
- [69] Gawdat HI, Hegazy RA, Fawzy MM, Fathy M. Autologous platelet rich plasma: Topical versus intradermal after fractional ablative carbon dioxide laser treatment of atrophic acne scars. *Dermatologic Surgery*. 2014;**40**(2):152-161

- [70] Abdelghani R, Ahmed NA, Darwish HM. Combined treatment with fractional carbon dioxide laser, autologous platelet-rich plasma, and narrow band ultraviolet B for vitiligo in different body sites: A prospective, randomized comparative trial. *Journal of Cosmetic Dermatology*; 2017
- [71] Cervelli V, Gentile P, Grimaldi M. Regenerative surgery: Use of fat grafting combined with platelet-rich plasma for chronic lower-extremity ulcers. *Aesthetic Plastic Surgery*. 2009;**33**(3):340
- [72] Trink A, Sorbellini E, Bezzola P, Rodella L, Rezzani R, Ramot Y, Rinaldi F. A randomized, double-blind, placebo-and active-controlled, half-head study to evaluate the effects of platelet-rich plasma on alopecia areata. *British Journal of Dermatology*. 2013;**169**(3): 690-694
- [73] Kim DH, Je YJ, Kim CD, Lee YH, Seo YJ, Lee JH, Lee Y. Can platelet-rich plasma be used for skin rejuvenation? Evaluation of effects of platelet-rich plasma on human dermal fibroblast. *Annals of Dermatology*. 2011;**23**(4):424-431
- [74] Casabona F, Priano V, Vallerino V, Cogliandro A, Lavagnino G. New surgical approach to lichen sclerosus of the vulva: The role of adipose-derived mesenchymal cells and platelet-rich plasma in tissue regeneration. *Plastic and Reconstructive Surgery*. 2010;**126**(4):210e-211e
- [75] Chang Y, Li J, Chen Y, Wei L, Yang X, Shi Y, Liang X. Autologous platelet-rich plasma promotes endometrial growth and improves pregnancy outcome during in vitro fertilization. *International Journal of Clinical and Experimental Medicine*. 2015;**8**(1):1286
- [76] Chrysanthopoulou EL, Pergialiotis V, Perrea D, Kourkoulis S, Verikokos C, Doumouchtsis SK. Platelet rich plasma as a minimally invasive approach to uterine prolapse. *Medical Hypotheses*; 2017
- [77] Tehranian A, Esfehiani-Mehr B, Pirjani R, Rezaei N, Heidary SS, Sepidarkish M. Application of autologous platelet-rich plasma (PRP) on wound healing after caesarean section in high-risk patients. *Iranian Red Crescent Medical Journal*. 2016;**18**(7):e34449
- [78] Stavrakas M, Karkos PD, Markou K, Grigoriadis N. Platelet-rich plasma in otolaryngology. *The Journal of Laryngology and Otology*. 2016;**130**(12):1098-1102
- [79] Nikolopoulos KI, Pergialiotis V, Perrea D, Doumouchtsis SK. Restoration of the pubourethral ligament with platelet rich plasma for the treatment of stress urinary incontinence. *Medical Hypotheses*. 2016;**90**:29-31
- [80] Kim KM, Shin Y-T, Kim HK. Effect of autologous platelet-rich plasma on persistent corneal epithelial defect after infectious keratitis. *Japanese Journal of Ophthalmology*. 2012;**56**(6):544-550
- [81] Rezende MSVM et al. Uso do concentrado de plaquetas em doença da superfície ocular. *Revista Brasileira de Oftalmologia*. 2007;**66**(4):257-261

- [82] Alio JL, Rodriguez AE, Wróbel Dudzinska D. Eye platelet-rich plasma in the treatment of ocular surface disorders. *Current Opinion in Ophthalmology*. 2015;**26**(4):325-332
- [83] Marquez DADCR, De EEIM. Subconjunctival application of regenerative factor-rich plasma for the treatment of ocular alkali burns. *European Journal of Ophthalmology*. 2009;**19**(6):909-915
- [84] Panda A et al. Topical autologous platelet-rich plasma eyedrops for acute corneal chemical injury. *Cornea*. 2012;**31**(9):989-993
- [85] Avila MY. Restoration of human lacrimal function following platelet-rich plasma injection. *Cornea*. 2014;**33**(1):18-21
- [86] Vick VL et al. Use of autologous platelet concentrate in blepharoplasty surgery. *Ophthalmic Plastic & Reconstructive Surgery*. 2006;**22**(2):102-104
- [87] Pezzotta S et al. Autologous platelet lysate for treatment of refractory ocular GVHD. *Bone Marrow Transplantation*. 2012;**47**(12):1558
- [88] Alio JL et al. Symptomatic dry eye treatment with autologous platelet-rich plasma. *Ophthalmic Research*. 2007;**39**(3):124-129
- [89] Ribeiro MVMR et al. Platelet-rich plasma in diabetic dry eye disease. *Revista Brasileira de Oftalmologia*. 2016;**75**(4):308-313
- [90] Alio JL et al. Treatment of dry eye disease with autologous platelet-rich plasma: A prospective, interventional, non-randomized study. *Ophthalmology and therapy*. 2017:1-9
- [91] Vane LA, Ganem EM. Doação homóloga versus autóloga e substitutos da hemoglobina. *Medicina Perioperatória*. 2006:292-306
- [92] Hospital Sírio Libanês. Guia de Condutas Hemoterápicas. São Paulo: Hospital Sírio Libanês; 2010