

We are IntechOpen, the world's leading publisher of Open Access books Built by scientists, for scientists

6,900

Open access books available

186,000

International authors and editors

200M

Downloads

Our authors are among the

154

Countries delivered to

TOP 1%

most cited scientists

12.2%

Contributors from top 500 universities



WEB OF SCIENCE™

Selection of our books indexed in the Book Citation Index
in Web of Science™ Core Collection (BKCI)

Interested in publishing with us?
Contact book.department@intechopen.com

Numbers displayed above are based on latest data collected.
For more information visit www.intechopen.com



Choledochal Cyst (CDC)

Raashid Hamid, Nisar A. Bhat, Mansoor Ahmad and
Balvinder Singh

Additional information is available at the end of the chapter

<http://dx.doi.org/10.5772/intechopen.72938>

Abstract

Choledochal cysts are congenital bile duct anomalies. These cystic dilatations of the biliary tree can involve the extrahepatic biliary radicles, the intrahepatic biliary radicles, or both. The etiology remains unknown, but choledochal cysts are likely to be congenital in nature. Cyst excision is the definitive treatment of choice for choledochal cyst because of the high morbidity and high risk of carcinoma after internal drainage, a commonly used treatment in the past. CDC is a congenital anomaly involving cystic dilatation of various ducts of biliary tree. The precise etiology of extrahepatic cysts continues to remain unclear. The most commonly accepted theory is an anomalous pancreatobiliary duct junction (APBDJ) and abnormal function of the sphincter of Oddi. Proper imaging plays an essential role in preoperative planning. Proper diagnosis evaluation and management is essential for optimal management. Type I cysts are the most frequently encountered. Choledochal cysts can have variable presentations. Hepatobiliary ultrasound and MRCP are the present day standards for imaging; early diagnosis should be the norm to avoid possible late complications of cholangitis, cirrhosis, hepaticolithiasis and spontaneous perforation. Excision of the cyst with hepaticojejunostomy is the best approach.

Keywords: choledochal cyst, abnormal pancreatobiliary duct junction, common bile duct

1. Introduction

Choledochal cyst (CDC) is the congenital dilatation of the bile ducts. The condition is a relatively rare abnormality with an estimated incidence of 1 in 13,000–15,000 in Western populations. However, this condition is far more common in the East, with an incidence of 1 per 1000 in Japan [1, 2]. The etiology remains unknown, but choledochal cysts are likely to be congenital in nature.

Other proposed theories include distal obstruction, Abnormal Pancreatico-biliary Duct Junction (APBDJ), sphincter oddi dysfunction. The pathologic features of the CDC frequently include an anomalous junction of the pancreatic and common bile ducts pancreaticobiliary malunion (PBMU), intrahepatic bile duct dilatation, and various degrees of hepatic fibrosis. Anatomically choledochal cysts are usually classified into three groups. However, based on the cholangiographic findings of intrahepatic ducts or pancreaticobiliary malunion (PBMU), the so-called long common channel, other forms and subgroups have been described. Left untreated, choledochal cysts can undergo malignant transformation and promote progressive hepatic fibrosis. About 20% case present during adulthood [3]. The gallbladder or bile duct malignancy has been reported as 6–20% and 15–20% in the United States and Japan, respectively [4, 5]. Therefore, treatment includes complete excision of the cysts with Roux-en-Y hepatojejunostomy and close surveillance.

2. Aetiopathogenesis

The etiology of choledochal cystic disease remains ill-defined; however, these malformations are considered congenital because they occur in fetuses and in newborns. The most commonly accepted theory for choledochal cysts is based on the observation that they are frequently associated with an anomalous pancreatobiliary duct junction (APBDJ). The “long common channel theory” explained that APBDJ allows reflux of pancreatic enzymes into the common bile duct. The reflux of pancreatic juice results in dissolution of the ductal wall and obstruction at distal end of cyst due to edema/fibrosis [6].

Another theory proposed that this disease results from derangement in normal embryologic remodeling of ducts and causes varying degrees of destructive inflammation and segmental dilatation [7, 8]. Kusunoki et al. demonstrated suboptimal number of ganglion cells in the narrow portion of the common bile duct in patients with a choledochal cyst, as compared with controls [9, 10]. Based on an experimental study in which cystic dilatation of the common bile duct was produced by ligation of the distal end of the common bile duct in the neonatal lamb, an obstructive factor in the early developmental stage was described as a causative factor.

APBJ is defined as a junction between the pancreatic and bile ducts and is located outside of the duodenal wall [11]. Babbitt analyzed that most choledochal cysts were complicated by APBJ [12]. APBJ is classified into two types (P-C and C-P type) by analyzing the fusion pattern between the pancreatic and bile ducts. In the P-C type, the main pancreatic duct joins the common bile duct, while the common bile duct appears to join the main pancreatic duct in the C-P type [13].

In 1991, Komi et al. classified APBJ into three groups type I, II, and III according to the running of the accessory pancreatic duct and dilatation of the common channel. Types I and II correspond to the C-P type, P-C type and type III was named as complex type of APBJ [14]. The incidence of type I, II, and III APBJ was 35.3, 21.6, 43.1%, respectively (**Figures 1 and 2**).

In 2003, Tashiro et al. analyzed 1627 patients of CDC and found patients with APBJ overlapped with that in normal cases. Furthermore, reflux of the pancreatic juice was reported in patients without APBDJ. Considering the conditions similar to APBJ, APBJ should be defined as when the long common channel with out any relation to sphincter of Oddi contraction [15].

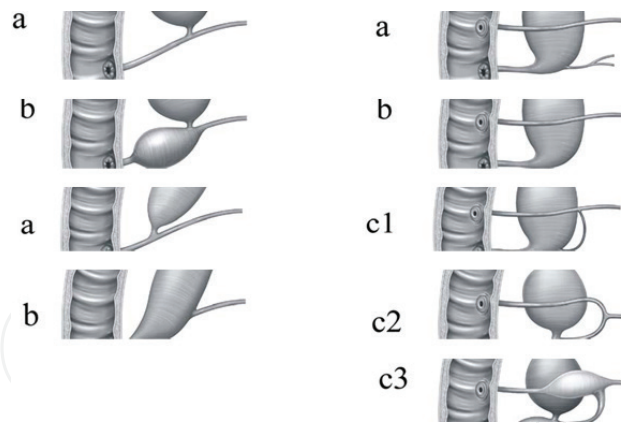


Figure 1. Classification of anomalous union between pancreatic and bile ducts.

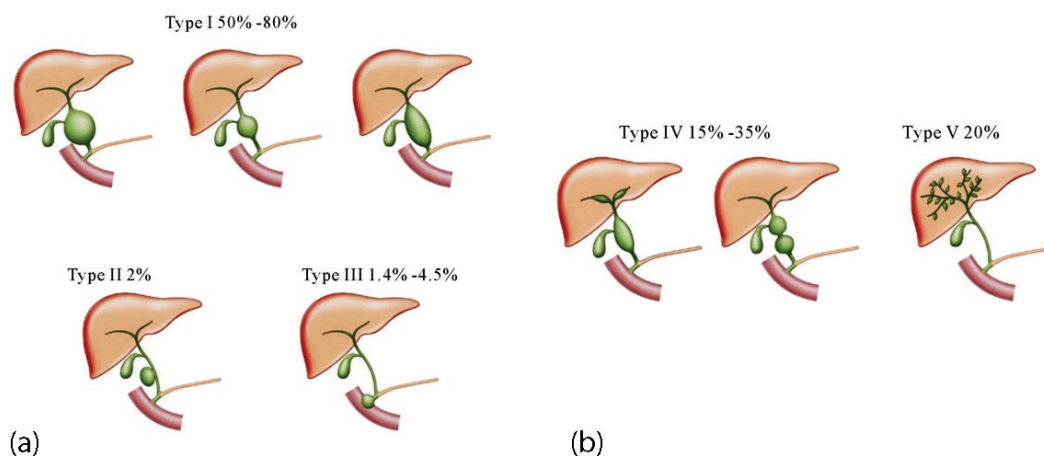


Figure 2. a & b; Different types of CDC.

3. Classification of choledochal cyst

Based on the site of cystic changes five types of CDC have been described by Todani and colleagues Type I–V (**Figure 2**). **Type I** constitutes about 50–80% of all CDC, **Type II** (2%), **Type III** (1.4–4%), Type IV (15–35% of all CC) and **Type V** or Caroli's disease(20%) [16].

Type I cysts typically appear as anechoic cystic lesions, which communicate with the biliary tract. Type 1 is further divided into; (1A, 1B, or 1C). In type 1A, the gallbladder arises from the choledochal cyst and a dilated extrahepatic biliary tree is seen while the intrahepatic ducts are normal in size and appearance. Type 1B an isolated dilatation of the most distal aspect of the CBD. In Type 1C a smooth fusiform dilatation of the common hepatic duct (CHD) and CBD is associated with pancreaticobiliary malunion.

Type II cysts are diverticula of CBD which appear as anechoic cyst juxtaposed to CBD with CHD. Type II cysts appear as anechoic cysts juxtaposed to the CBD with a normal appearing gallbladder and CHD. Cholangiography demonstrates opacification of a true diverticulum arising from the CBD and can resemble gallbladder duplication.

Type III cysts, or choledochoceles, comprise 1–4% of CC and are characterized by their intra-duodenal location at the pancreaticobiliary junction. Type III cysts are also more likely to be diagnosed using ERCP and are associated with a much lower incidence of malignant transformation (2.5%). Additionally, APBD is less commonly seen in choledochoceles in comparison with other types of CDC.

Type IV CDC can include both intrahepatic and extra-hepatic duct involvement. Type IVA CDC dilatation extends from the CBD and CHD into the intrahepatic biliary tree. Type IVB CC consists of multiple dilations of the extrahepatic biliary tree. **Finally, type V CC, or Caroli's disease** is the intrahepatic saccular or fusiform dilatation with no underlying obstruction or extrahepatic biliary tree involvement. Type V CDCs are at times associated with polycystic kidney disease, an autosomal recessive inherited condition associated with mutation in PKD1 gene [17]. Investigators note the different clinical courses, management, and complication rates of the 5 types of CC, thus have challenged the modified Todani classification.

Forme Fruste Choledochal Cyst (FFCC); FFCC is characterized by non-specific changes of bile duct mucosa such as mucosal ulceration/sloughing, fibrosis, and inflammatory cell infiltration. Patients with FFCC may be at a high risk for carcinogenesis in the extrahepatic bile duct. These changes are similar to that seen in cystic or fusiform type choledochal cysts [18].

Pathologic changes in the liver including portal fibrosis, central venous dilatation, parenchymal inflammation, and bile duct proliferation. Furthermore, fibrosis of cyst wall lined by columnar epithelium, lymphocytic infiltration and mucosal dysplasia is also seen. Histologic appearances in Type I (and sometimes type IV) CDC is lack biliary mucosa; type II CDC closely resemble gallbladder duplication. Type III cysts are lined by duodenal mucosa, while type V cysts can have extensive hepatic fibrosis [19]. In the walls of CC there is increasing rate of epithelial metaplasia and biliary intraepithelial neoplasia with advancing age. Although the incidence of malignancy at diagnosis of CDC increases with age at diagnosis, the risk of developing a future malignancy in an existing benign CDC during one's remaining lifetime likely decreases with advancing age. Carcinogenesis is thought to occur via multistep genetic events where early K-ras and p53 mutations are seen in more than 60% of CC-related carcinomas, followed by a late occurring DPC-4 gene inactivation [20].

Gallbladder carcinoma is identified in 10–25% of CDC-related malignancies. Malignancy is most commonly associated with types I and IV cysts, while types II, III, and V CC have minimal neoplastic risk. Most reported cases of malignant transformation are cholangiocarcinoma. The presence of an APBDU is thought to play a role in carcinogenesis and hepatocellular damage due to reflux of pancreatic contents into the bile duct [21].

4. Clinical features

4.1. Prenatal diagnosis

Choledochal cysts are being diagnosed with increasing frequency on prenatal sonography. Ultrasound typically reveals a cyst at the porta hepatis. The differential diagnosis of a cyst in the porta hepatis includes duodenal atresia, mesenteric or omental cysts, hepatic cysts, intestinal

duplication, gallbladder duplication, and ovarian cysts [27]. Because choledochal cysts are rare anomalies, prenatal diagnosis can be challenging. Sensitivity and specificity of prenatal ultrasound for choledochal cysts increases if sonologist performing the prenatal ultrasound is experienced MRI does not add significantly to the information found on ultrasound, but both imaging techniques may be complementary to each other.

Choledochal cysts historically presented in two broad categories:

- (1) The infantile form, indicated by obstructive jaundice.
- (2) The adult form, generally presenting with obstructive jaundice, pancreatitis, or ascending cholangitis.

4.1.1. Infantile form

The infantile form present as obstructive jaundice. Jaundice in choledochal cyst is often intermittent because the obstruction is rarely complete unlike in biliary atresia. Character of jaundice is an important ominous symptom in differentiating obstructive jaundice due to biliary duct cystic dilatation from obstructive jaundice due to biliary atresia. Many of these neonates may have choledochal cysts in conjunction with complete or nearly complete biliary obstruction. Some authors report these patients as having biliary atresia in association with choledochal cyst, whereas others may term these patients as having surgically correctable biliary atresia. Distinguishing between cystic biliary atresia (CBA) and CDC is important because delayed therapy in CBA results in irreversible long-term sequelae. Unlike BA, CDC and CBA can typically be identified with prenatal ultrasound; however, these lesions are often all thought to be CC until surgical intervention [25]. On ultrasound, CBA on USG appears smaller with less dilatation of intrahepatic ducts [28].

Those with an infantile form need surgical excision and reconstruction within the first several weeks of life to avoid potential complications of cholangitis and hepatopathy. It is recommended to perform operation for asymptomatic choledochal cysts diagnosed prenatally within the first year of life. Congenital anomalies Associated with CC include double common bile duct, sclerosing cholangitis, congenital hepatic fibrosis, pancreatic cyst, and annular pancreas. Thirty one percent of pediatric patients with CDC have congenital cardiac anomaly and are most commonly manifested in infancy [29, 30].

However, CBA patients are symptomatic at earlier ages (less than 3 months old), and one-third of CBA patients develop liver failure or require liver transplantation. Triangular cord sign (a thickness of the echogenic anterior wall of the right portal vein just proximal to the right portal vein bifurcation) and the presence of biliary sludge are characteristic features suggestive of CBA rather than CDC.

4.1.2. Adult form

Common presentations in children in adults include abdominal pain, jaundice, and right upper quadrant mass and are most commonly seen in pediatric patients. The classic triad of abdominal pain, right upper quadrant mass, and obstructive jaundice, although still rare is seen in the pediatric population.

Adults are more likely to present with biliary or pancreatic symptoms and abdominal pain. Abdominal mass and Jaundice are feature sin childhood [26]. Adults with CC may present with symptomatic gallstones or acute cholecystitis, both of which are attributed to biliary stasis. Pain similar to recurrent pancreatitis has been described by some patients [22]. However, these patients may truly be having pancreatitis as a result of mucous plugging in the APBDJ.

Complications in Choledochal cysts in adults include development of cholelithiasis, liver cirrhosis, portal hypertension, hepatic abscess, and biliary carcinoma [23]. Thus, the incidence of postoperative complications is quite high even after primary cyst excision.

5. Imaging

5.1. Ultrasonography

Ultrasonography is a preliminary imaging modality for detecting choledochal cysts, which shows a cystic mass in the right upper quadrant apart from the gallbladder. The sensitivity of Ultrasonography for diagnosing choledochal cysts is 71–97%. In recent years, the number of patients who are diagnosed by antenatal ultrasonography is increasing. This method also clearly demonstrates IHBD dilatation and the state of the liver parenchyma. Caroli's disease, polycystic liver disease and primary sclerosing cholangitis have similar in radiographic appearance. Cysts in polycystic liver disease do not communicate with the biliary tree, while primary sclerosing cholangitis is associated with a distal biliary obstruction and inflammatory bowel disease. A CBD measuring greater than 10 mm in an adults is an indication for further imaging in order to differentiate type I cysts from type IVA disease. Other features suggestive of CDC are a right upper quadrant cyst separate from the gallbladder and presence of a direct communication between the biliary tree and the cystic duct [24].

5.2. HIDA scan

If a choledochal cyst is suspected on ultrasound. The Technetium-99 HIDA scan has varying sensitivities, with 100% for type I cysts and 67% for type IV. It is particularly useful for showing continuity with bile ducts and diagnosis of cyst rupture in patients with choledochal cysts. Hepatobiliary scintigraphy complements other diagnostic tools in the diagnosis of choledochal cysts in pediatric patients [31]. A HIDA scan is be helpful for distinguishing between choledochal cyst and biliary atresia. Choledochal cyst will have contrast entering the duodenum, whereas in patients with biliary atresia will lack of contrast emptying into the duodenum.

5.3. CT scanning

CT scanning is a useful imaging tool for detecting choledochal cysts, but it is difficult to delineate pancreatic and bile duct union. Multidetector computed tomography (MDCT) provides detailed information on the pancreatic and bile ducts. In patients with suspected APBJ. Intrahepatic ducts, distal common bile ducts, and the pancreatic duct, are reliably identified on CT scan, thus useful in identifying type IV and type V cysts. CT cholangiography is

now a historical imaging modality in CDC. The sensitivity of CT cholangiography is 90% for diagnosing choledochal cysts, and only 64% for characterizing the pancreatic duct [31]. The obvious drawbacks of CT or CT cholangiography are nephrotoxicity or hepatotoxicity and radiation exposure. Because of better investigations the use of CT is now very limited.

5.4. Magnetic resonance cholangiopancreatography (MRCP)

MRCP being a noninvasive investigation provides excellent delineation of pancreatobiliary ducts. It can replace ERCP as a diagnostic method for evaluation of biliary- pancreatic tract. MRCP reliably identifies APBDJ. Sensitivity and specificity of MRCP in diagnosing CDC is (70–100%) and (90–100%), respectively [32]. Although MRCP is limited in its ability to detect minor ductal abnormalities or small choledochoceles. 88 Magnetic resonance Cholangiopancreatography cannot be used for therapeutic purposes; therefore its utility remains limited as a diagnostic tool. Another advantage of MRCP over ERCP is that the pancreatic duct can be visualized upstream to an obstruction [33].

5.5. ERCP, PTC, intraoperative cholangiography

Invasive imaging studies also play a role in diagnosis and evaluation of the biliary anatomy. These modalities include cholangiography through endoscopic retrograde cholangiopancreatography (ERCP), percutaneous transhepatic cholangiography (PTC), and intraoperative cholangiogram. Endoscopic retrograde cholangiopancreatography (ERCP) is the gold standard for diagnosis of APBJ. ERCP is a type of invasive direct cholangiography, which may be associated with significant morbidity and mortality. ERCP can be challenging with respect to cannulization of the ampulla, due to recurrent inflammation and scarring. Cholangiography will delineate the anatomy and PBM and filling defects caused by stones, stenosis, or carcinomas. ERCP can be challenging with respect to cannulization of the ampulla. Cholangitis and pancreatitis after invasive cholangiography is higher than in the general population. A high volume of dye load is often required for adequate visualization, especially in the setting of large cysts [34].

6. Management

The surgical treatment of choledochal cystic disease has evolved and been refined over the past century. Aspiration and marsupialisation were the earliest forms of surgical therapy, the development of external biliary fistulae. Complete cyst excision and internal drainage by hepaticoduodenostomy (McWhorter in 1924) however, unacceptable mortality rates were encountered. Gross advocated internal drainage by choledochocystoduodenostomy in 1933 because of unacceptably high risk of cyst excision at that time. Subsequent patient evaluation, however, revealed morbidity rates approaching 50%, primarily a result of cholangitis from duodenal reflux. The transection level of the common hepatic duct and currently, complete excision of a cyst with cholecystectomy and Roux-en-Y hepaticojejunostomy reconstruction (RYHJ) is the standard therapy in Types I and IV-A cysts [39]. Although the overall morbidity was diminished, the risk of malignant degeneration within the cystic remnant was recognized. Persistent, although markedly diminished episodes of cholangitis in RYHJ reconstructions

led to the development of a valved jejunal interposition. No studies have independently confirmed the efficacy of valved intestinal conduits in the prevention of reflux-induced cholangitis. Pericystic inflammation may prevent safe complete-cyst excision. An internal approach, as described by Lilly, requires mucosectomy of the inner epithelial lining prior to reconstruction, but avoids the danger of a difficult posterior dissection.

7. Cyst excision

A laparotomy through a high transverse or oblique right upper quadrant incision gives excellent exposure. The appearance of the liver, spleen, and pancreas is noted. If the anatomy has not been clearly defined preoperatively, an intraoperative cholangiogram should be performed. Aspirated the bile from the cyst and send it for culture and measurement of amylase/lipase. With large cysts, dye should be injection directly into the lower end of the common bile duct and into the common hepatic duct using a butterfly needle. Direct injection into a large cyst may obscure filling of the distal duct, it is important to try to identify the junction of the pancreatic and bile ducts [35]. If the cyst is extremely inflamed and adhesions are very dense, mucosectomy of the cyst should be performed rather than full-thickness dissection to minimize the risk of injuring the surrounding structures such as portal vein and hepatic artery (**Figure 3**). Where the bile duct begins to narrow down inferiorly, it is dissected circumferentially and encircled. The distal common bile duct is dissected to just within the head of the pancreas and transected. Common channel should be cleared with combination of saline irrigation, balloon catheters and, when possible. Intraoperative endoscopy helps removing plugs. Distal bile duct stump is transfixed with an absorbable suture [36] (**Figure 4**).

After dissection of GB and cyst, the portal vein is exposed. At times the right hepatic artery crosses in front of the cyst and is adherent to its wall and in this situation right hepatic artery must be carefully freed and preserved. The common hepatic duct is divided at the level of the bifurcation, where it should appear healthy and well vascularised (**Figure 5**).

To allow a wider bilio-enteric anastomosis, left duct is incised 5–10 mm. Anastomosis to a narrow common hepatic duct should be avoided because of the long-term risk of stricture. The duodenojejunal flexure is identified and the Roux loop jejunum anastomosed at duct bifurcation using fine, interrupted, absorbable monofilament sutures (6/0 or 7/0 PDS) (**Figure 6**).

Dilatation of the peripheral portion of the IHBD is associated with late complications which include recurrent cholangitis, stone formation, and anastomotic stricture. Intrahepatic cystenterostomy, or balloon dilatation of the stenosis at the time of cyst excision are options for dilatation of IHD.

Type II cysts: Excision of the diverticulum and repair of the common bile duct is performed in type II a satisfactory procedure for this rare variety of choledochal cyst.

Type III cysts: Large choledochoceles can be removed transduodenally. Sphincteroplasty or endoscopic sphincterotomy are the two options for smaller choledochoceles with no pancreatobiliary malunion.

Type V cysts: If multiple cysts are confined to one side of the liver, hepatic lobectomy may be curative. Recurrent cholangitis and stone formation are common if multiple cysts are distributed throughout the liver. Antibiotics and drainage procedures are helpful in such cases, but liver transplantation should be considered in progressive cases.

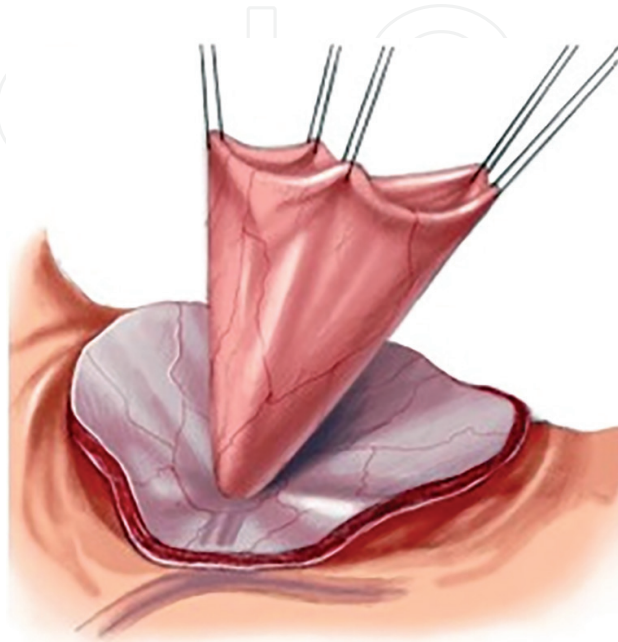


Figure 3. Mucosectomy of distal portion of choledochal cyst.

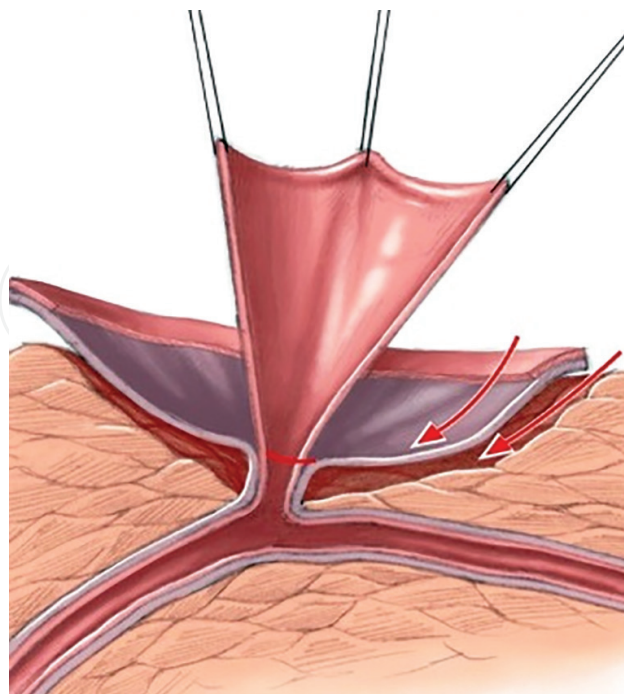


Figure 4. Intrapancreatic dissection of terminal bile duct.

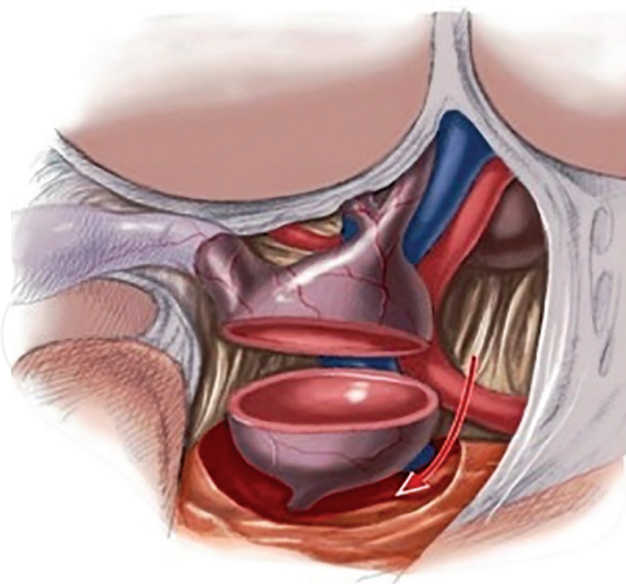


Figure 5. The common hepatic duct is transected at the level of distinct caliber change.

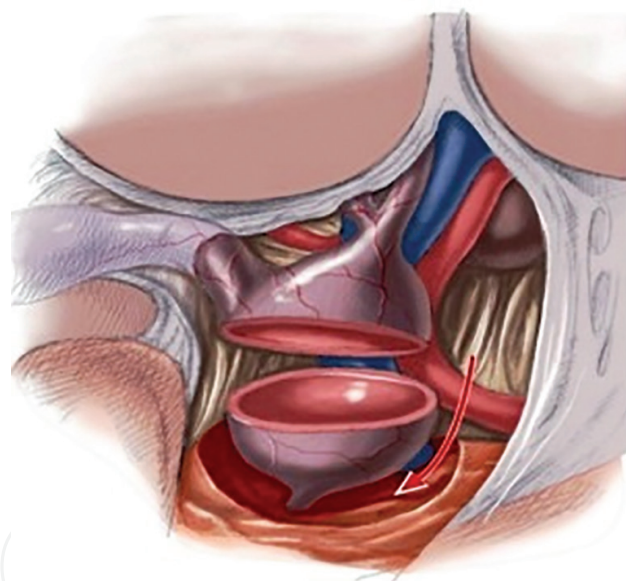


Figure 6. Roux-en-Y (RY) hepaticojejunostomy at the time of cyst excision.

The prognosis of choledochal cyst is excellent if the diagnosis is made expediently prior to the development of irreversible liver disease or malignancy. The common late complications are cholangitis, obstructive jaundice, pancreatitis, stone formation, and portal hypertension [37]. Long-term outcomes after excision and hepaticojejunostomy reconstruction for choledochal cysts have been reported in different series. Most of these show that with standard treatment of excision and drainage, these patients will have no significant sequelae from this treatment.

The congenital hepatic fibrosis coexistent in patients with type V CCD, it predisposes patient to portal hypertension. The incidence of cholelithiasis due to bile stasis is around 37.5–74%.

Hepatolithiasis is most often associated with type IV-A CCD and is related to the presence of membranous or septal stenosis [38]. Total cyst excision reduces the risk of malignancy. However, sporadic malignancy has been reported after the excision of cysts. Cholangiocarcinoma developing after total resection of choledochal cysts after 10 to 34 years has been previously reported [39].

Biliary tract malignant tumor were associated in 80 patients (9.9%); 40 had bile duct cancer (50.0%), 35 had gallbladder cancer (43.8%), 3 had periampullary cancer, synchronous gallbladder and bile duct cancer was found in 2 patients. With a median follow-up duration of 51.8 months, 26.3% had a recurrence [40].

Incidence of hepato-biliary cancer in TYPE I, TYPE III, Type Iva, unknown was reported to be 71, 1.3, 22.5 and 5%. Significantly more patients classified with type IVa had bile duct cancer and significantly more patients classified with type I had gallbladder cancer ($P = .03$) [41].

In a review of 200 children who had cyst excision. Primary cyst excision was performed in 176, 19 had cyst excision converted from other biliary surgery. The mean follow-up period was 10.9 years. In 188 patients Roux-en-Y hepaticojejunostomy was performed, 11 had standard hepaticoduodenostomy, and one had a jejunal interposition hepaticojejunostomy. There was no operative mortality. Eighteen (9.0%) patients had complications including cholangitis, choledochus calculi, pancreatitis, and small bowel obstruction. Fifteen of the 18 children required surgical interventions such as revision of the hepaticoenterostomy. There was no occurrence of malignancy [42].

8. Conclusion

CDC is a congenital anomaly of hepatobiliary ducts. Various theories have been proposed including congenital origin, APBDJ, and defects in canalization during embryogenesis. CDC has been divided into five types depending on location of cyst. Choledochal cysts can have variable presentations ranging from infantile Cholestasis to pain abdomen jaundice and abdominal lump in adults. MRCP is the main investigation for diagnosis early diagnosis and treatment avoids possible late complications of cholangitis, cirrhosis, hepatolithiasis and spontaneous perforation. Excision of the cyst with Roux-N Y hepaticojejunostomy is the best approach.

Author details

Raashid Hamid^{1*}, Nisar A. Bhat², Mansoor Ahmad³ and Balvinder Singh⁴

*Address all correspondence to: drRaashidhamid@gmail.com

1 Department of Paediatric Surgery Govt Medical College Srinagar, Srinagar, Jammu and Kashmir, India

2 Department of Paediatric and Neonatal Surgery Skims, Srinagar, Jammu and Kashmir, India

3 Department of Surgery Govt Medical College Srinagar, Srinagar, Jammu and Kashmir, India

4 Government Medical College, Srinagar, Jammu and Kashmir, India

References

- [1] Lee HK, Park SJ, Yi BH, et al. Imaging features of adult choledochal cysts: A pictorial review. *Korean Journal of Radiology*. 2009;**10**:71-80. [Pub Med: 19182506]
- [2] Sato M, Ishida H, Konno K, et al. Choledochal cyst due to anomalous pancreatobiliary junction in the adult: Sono-graphic findings. *Abdominal Imaging*. 2001;**26**:395-400. [PubMed: 11441552]
- [3] Miyano T. Choledocal cyst. In: Stringer M, Oldham K, Mouriquand P, editors. *Pediatric Surgery and Urology Long-Term Outcomes*. 2nd ed. Cambridge: Cambridge University Press; 2006. pp. 465-479
- [4] Tashiro S, Imaizumi T, Ohkawa H, et al. Pancreaticobiliary maljunction: Retrospective and nationwide survey in Japan. *Journal of Hepato-Biliary-Pancreatic Surgery*. 2003;**10**:345-351. DOI: 10.1007/s00534-002-0741-7 [14]
- [5] Edil BH, Cameron JL, Reddy S, et al. Choledochal cyst disease in children and adults: A 30-year single-institution experience. *Journal of the American College of Surgeons*. 2008;**206**:1000-1005; discussion 1005-1008. DOI: 10.1016/j.jamcollsurg.2007.12.045
- [6] Lam WW, Lam TP, Saing H, et al. MR cholangiography and CT cholangiography of pediatric patients with choledochal cysts. *American Journal of Roentgenology*. 1999;**173**:401-405
- [7] Howard ER. Choledochal cysts. In: Howard ER, editor. *Surgery of Liver Disease in Children*. Oxford: Butterworth-Heinemann; 1991. pp. 78-90
- [8] Kasai M, Asakura Y, Taira Y. Surgical treatment of choledochal cyst. *Annals of Surgery*. 1970;**172**:844-851. DOI: 10.1097/00000658-197011000-00009
- [9] Kusunoki M, Saitoh N, Yamamura T, Fujita S, Takahashi T, Utsunomiya J. Choledochal cysts: Oligoganglionosis in the narrow portion of the choledochus. *Archives of Surgery*. 1988;**123**:984-986
- [10] Shimotake T, Iwai N, Yanagihara J, Inoue K, Fushiki S innervation patterns in congenital biliary dilatation. *European Journal of Pediatric Surgery*. 1995;**5**:265-270
- [11] The Japanese Study Group on Pancreaticobiliary Mal-junction. Diagnostic criteria of pancreaticobiliary maljunction. *Journal of Hepato-Biliary-Pancreatic Surgery*. 1994;**1**:219-221. DOI: 10.1007/BF02391070
- [12] Babbitt DP. Congenital choledochal cysts: New etiological concept based on anomalous relationships of the common bile duct and pancreatic bulb. *Annales de Radiologie (Paris)*. 1969;**12**:231-240
- [13] Miyano T. Choledocal cyst. In: Stringer M, Oldham K, Mouriquand P, editors. *Pediatric Surgery and Urology Long-Term Outcomes*. 2nd ed. Cambridge: Cambridge University; 2006

- [14] Komi N, Takehara H, Kunitomo K, et al. Does the type of anomalous arrangement of pancreaticobiliary ducts influence the surgery and prognosis of choledochal cyst? *Journal of Pediatric Surgery*. 1992;**27**:728-731. DOI: 10.1016/S0022-3468(05)80102-2
- [15] Tashiro S, Imaizumi T, Ohkawa H, et al. Pancreaticobiliary maljunction: Retrospective and nationwide survey in Japan. *Journal of Hepato-Biliary-Pancreatic Surgery*. 2003;**10**:345-351. DOI: 10.1007/s00534-002-0741-7
- [16] Todani T, Watanabe Y, Toki A, et al. Carcinoma related to choledochal cysts with internal drainage operations. *Surgery, Gynecology & Obstetrics*. 1987;**164**:61-64
- [17] Parada LA, Hallen M, Hagerstrand I, et al. Clonal chromosomal abnormalities in congenital bile duct dilatation (Caroli's disease). *Gut*. 1999;**45**:780-782. [PubMed: 10517920]
- [18] Puri P, Höllwarth ME. *Pediatric Surgery*. Berlin, Heidelberg: Springer; 2006
- [19] Masetti R, Antinori A, Coppola R, et al. Choledochoceles: Changing trends in diagnosis and management. *Surgery Today*. 1996;**26**:281-285. [PubMed: 8727951]
- [20] Shimotake T, Aoi S, Tomiyama H, Iwai N. DPC-4 (Smad-4) and K-ras gene mutations in biliary tract epithelium in children with anomalous pancreaticobiliary ductal union. *Journal of Pediatric Surgery*. 2003;**38**:694-697. [PubMed: 12720172]
- [21] Bismuth H, Krissat J. Choledochal cystic malignancies. *Annals of Oncology*. 1999;**10**:94-98. [PubMed: 10436795]
- [22] Shah OJ, Shera AH, Zargar SA, et al. Choledochal cysts in children and adults with contrasting profiles: 11-year experience at a tertiary care center in Kashmir. *World Journal of Surgery*. 2009;**33**:2403-2411. [PubMed: 19701664]
- [23] Sajjad Z, Oxtoby J, West D, et al. Biliary imaging by spiral CT cholangiography – A retrospective analysis. *The British Journal of Radiology*. 1999;**72**:149-152 [68]
- [24] Lam WW, Lam TP, Saing H, et al. MR cholangiography and CT cholangiography of pediatric patients with choledochal cysts. *American Journal of Roentgenology*. 1999;**173**:401-405
- [25] Caponcelli E, Knisely AS, Davenport M. Cystic biliary atresia: An etiologic and prognostic subgroup. *Journal of Pediatric Surgery*. 2008;**43**:1619-1624. [PubMed: 18778995]
- [26] Zhou LY, Guan BY, Li L, et al. Objective differential characteristics of cystic biliary atresia and choledochal cysts in neonates and young infants: Sonographic findings. *Journal of Ultrasound in Medicine*. 2012;**31**:833-841. [PubMed: 22644679]
- [27] de Vries JS, de Vries S, Aronson DC, et al. Choledochal cysts: Age of presentation, symptoms, and late complications related to Todani's classification. *Journal of Pediatric Surgery*. 2002;**37**:1568-1573. DOI: 10.1053/jpsu.2002.36186
- [28] Buyukyavuz I, Ekinici S, Ciftci AO, et al. A retrospective study of choledochal cyst: Clinical presentation, diagnosis and treatment. *The Turkish Journal of Pediatrics*. 2003;**45**:321-325

- [29] Murphy AJ, Axt JR, Lovvorn HN 3rd. Associations between pediatric choledochal cysts, biliary atresia, and congenital cardiac anomalies. *The Journal of Surgical Research*. 2012;**177**:e59-e63. [PubMed: 22572617]
- [30] Suzuki T, Hashimoto T, Hussein MH, et al. Biliary atresia type I cyst and choledochal cyst [corrected]: Can we differentiate or not? *Journal of Hepato-Biliary-Pancreatic Sciences*. 2013;**20**:465-470. [PubMed: 23579998]
- [31] Lam WW, Lam TP, Saing H, et al. MR cholangiography and CT cholangiography of pediatric patients with choledochal cysts. *American Journal of Roentgenology*. 1999;**173**:401-405
- [32] Miyazaki T, Yamashita Y, Tang Y, et al. Single-shot MR cholangiopancreatography of neonates, infants, and young children. *American Journal of Roentgenology*. 1998;**170**:33-37
- [33] Sugiyama M, Baba M, Atomi Y, et al. Diagnosis of anomalous pancreaticobiliary junction: Value of magnetic resonance cholangiopancreatography. *Surgery*. 1998;**123**:391-397. DOI: 10.1016/S0039-6060(98)70159-X
- [34] Park DH, Kim MH, Lee SK, et al. Can MRCP replace the diagnostic role of ERCP for patients with choledochal cysts? *Gastrointestinal Endoscopy*. 2005;**62**:360-366. [PubMed: 16111952]
- [35] Miyano T, Yamataka A, Kato Y, et al. Hepaticoenterostomy after excision of choledochal cyst in children: A 30-year experience with 180 cases. *Journal of Pediatric Surgery*. 1996;**31**(10):1417-1421
- [36] Edil BH, Cameron JL, Reddy S, et al. Choledochal cyst disease in children and adults: A 30-year single-institution experience. *Journal of the American College of Surgeons*. 2008;**206**:1000-1005. discussion 1005-1008. [PubMed: 18471743]
- [37] Todani Y, Watanabe M, Narusue KT, Okajima K. Congenital bile duct cysts. Classification, operative procedures, and review of thirty-seven cases including cancer arising from choledochal cyst. *The American Journal of Surgery*. 1977;**134**(2):263-269
- [38] Ninan VT, Nampoory MRN, Johnny KV, et al. Caroli's disease of the liver in a renal transplant recipient. *Nephrology, Dialysis, Transplantation*. 2002;**17**(6):1113-1115
- [39] Shimamura K, Kurosaki I, Sato D, et al. Intrahepatic cholangiocarcinoma arising 34 years after excision of a type IV-A congenital choledochal cyst: Report of a case. *Surgery Today*. 2009;**39**:247-251. DOI: 10.1007/s00595-008-3825-4
- [40] Ng WT. Bile duct carcinogenesis after excision of extrahepatic bile ducts in pancreaticobiliary maljunction. *Surgery*. 2000;**128**(3):492-494
- [41] Tashiro S, Imaizumi T, Ohkawa H, et al. Committee for registration of the Japanese study group on pancreaticobiliary maljunction. pancreaticobiliary maljunction: Retrospective and nationwide survey in Japan. *Journal of Hepato-Biliary-Pancreatic Surgery*. 2003;**10**(5):345-351
- [42] Puri P, Höllwarth ME. *Pediatric Surgery*. Berlin, Heidelberg: Springer; 2006. pp. 545-555 DOI: 10.1007/978-3-540-69560-8