

We are IntechOpen, the world's leading publisher of Open Access books Built by scientists, for scientists

6,900

Open access books available

186,000

International authors and editors

200M

Downloads

Our authors are among the

154

Countries delivered to

TOP 1%

most cited scientists

12.2%

Contributors from top 500 universities



WEB OF SCIENCE™

Selection of our books indexed in the Book Citation Index
in Web of Science™ Core Collection (BKCI)

Interested in publishing with us?
Contact book.department@intechopen.com

Numbers displayed above are based on latest data collected.
For more information visit www.intechopen.com



Contemporary Surgical Options for the Aortic Root

Ziv Beckerman and Edward P. Chen

Additional information is available at the end of the chapter

<http://dx.doi.org/10.5772/intechopen.75816>

Abstract

Aortic root pathology is diverse, and it is the most common cause of aortic valve incompetence in the United States. Aortic root surgery is undergoing continuous development and refinements. From the original description of Bentall on aortic root replacement, many advances have been made in the field of aortic root surgery. The surgical armamentarium available today provides advanced repair options as well as replacement options for the aortic root. The aim of this chapter is to provide an insight into the basics of aortic root surgery as well as to further describes the current up-to-date solutions for aortic valve and aortic root pathologies.

Keywords: aortic root replacement, aortic valve repair, aortic root, aortic operation

1. Introduction

Aortic root pathology is diverse, and it is the most common cause of aortic valve incompetence in the developed countries. The aortic root serves three main purposes: (1) being the outflow tract of the left ventricle, (2) a conduit for coronary perfusion, and (3) path for blood flow to the end-organs.

Current conventional treatment for significant aortic incompetence (AI) caused by a dilated, aneurysmal aortic root is replacement of the ascending aorta using a synthetic graft, replacement of the aortic valve with a prosthesis (the graft and prosthesis are usually combined as a “composite graft”), and reimplantation of the coronary arteries, i.e., the Bentall procedure. The options for both root and valve replacement vary, and each option entails its pros and cons.

This chapter will discuss the different contemporary surgical options for replacement and repair of the aortic root.

2. Historical perspective

The first successful replacement of a fusiform ascending aortic aneurysm was reported by Cooley and De Bakey in 1956 [1]. That first report was made possible thanks to the introduction of cardiopulmonary bypass to aortic aneurysm surgery. Following, several surgeons forged ahead and described similar experiences with similar pathologic entities.

Handling of the aortic root, below the sinotubular junction was first reported in 1964, when Wheat reported his team's efforts to replace the entire ascending aorta [2]. Although the procedure performed may not have involved the entire aorta as the title claimed, its legacy was secured as a description of how to handle pathology extending proximal to the coronary ostia. Their approach to the displaced coronary ostia was to resect the aorta 1.5–2 cm proximal to this level, while leaving a tongue of tissue surrounding the two coronary takeoffs. In this way, they maintained the integrity of the ostia and ensured the sutures were far enough from the coronary arteries.

While others continued to work tirelessly, the group at Oregon, including Drs. Herr and Starr, were diligently at work devising mechanical valves that would eventually be used for Bentall's historic procedure [3, 4]. In 1968, they published their ongoing clinical experience and engineering progress. Their ingenuity to use a composite valve-graft prosthesis was a major step in the progression of aortic root surgery, and the composite valve-graft, whether using a mechanical (as originally done) or tissue valve, is still considered the gold standard today [5].

Following, new concepts evolved for sparing the aortic valve and replacing the aortic root only. The first was developed by Sir Yacoub, and had been used in his practice since 1979 [6, 7]. The procedure, which he designed, later became referred to as the "remodeling technique." The functional focus was to preserve the native valve, while recreating the aortic sinuses. This goal was achieved by fashioning a scalloped Dacron® graft such that three tongues extended to replace the intrinsic sinuses. Interposed between these three extensions, native tissue was left intact at the attachment of the cusps. Once the graft was attached, the coronary arteries would be mobilized and anastomosed to the neoaorta.

In the late 1980s, David and his colleagues at the University of Toronto developed an alternative class of valve-sparing procedures [8]. Their procedure went through numerous iterations and variations, but classically the technique became referred to as the "reimplantation technique." [9, 10] This approach had the benefit of stabilizing the aortic annulus by sewing the native valve directly into a Dacron® graft of a fixed circumference.

3. Surgery of the aortic root

There are several indications to repair the aortic root and the ascending aorta. The most frequent one is the aneurysmal dilation of the aortic root \pm ascending aorta that is associated with aortic valve dysfunction (in general regurgitation). In this case, the aortic valve leaflets may be fundamentally normal. This may lead to insufficient coaptation of the leaflets and

therefore cause valve-regurgitation. In other patients, the aortic valve leaflets may be abnormal because of bicuspid morphology and the disease is associated with an enlarged ascending aorta. When the primary indication to operate on the patient is the aortic valve disease or myocardial revascularization, the ascending aorta is usually replaced very liberally (this means if the diameter is larger than 4.5 cm). Another situation that calls for the repair of the aortic root and ascending aorta is the patient that presents with severe aortic valve stenosis (either bicuspid or tricuspid aortic valve) and with post-stenotic dilation of the ascending aorta. In this category of patients, if the sinotubular junction is maintained and the aortic root diameter at the level of sinuses of Valsalva does not exceed 4 cm, it is generally accepted that a separate aortic valve replacement and supracoronary replacement of the ascending aorta with a prosthetic graft can be performed.

During the last decade, the authors have been increasingly aggressive in the replacement of the complete ascending aorta and base of the aortic arch using a short period of antegrade cerebral perfusion, performing the distal anastomosis without aortic cross clamp.

Contemporary surgical options for the aortic root include either a full aortic root replacement (biological or mechanical), or valve sparing aortic root replacement. Different graft options and/or valve options exist and are further discussed below.

3.1. Graft and valve options for aortic root surgery

The aortic root can be replaced with either a synthetic material (usually Dacron) or a biologic prosthesis. Biologic options come in the form of xenografts or homografts. Synthetic graft options include expanded poly (ethylene terephthalate) (Dacron) or poly(tetrafluoroethylene) (ePTFE), and represent the most widely employed vascular substitutes in cardiovascular surgery. Dacron grafts can come in a straight tubular shape or in a specifically designed form that, on implantation and pressurization, generates pseudosinuses of Valsalva.

3.1.1. Xenografts

Xenografts can come in the form of stented or stentless valve. Some of the stentless valves present as a full root products and can either be implanted as a full root replacement and/or as a valve replacement alone. The stented valves may be used for valve replacement alone, or may be composed to any graft type in order to be served for full root replacement.

Some options for stentless valves include the following:

3.1.1.1. Freestyle™ porcine aortic root bioprosthesis (medtronic)

This third-generation device presents as the complete porcine aortic root with thin polyester covering of the septal myocardium. The tissue is glutaraldehyde fixed using the physiologic root pressure technique: there is zero net pressure applied to the valve cusps to preserve collagen crimp while the aorta is distended to normal configuration. The graft may be implanted as a valve replacement in the subcoronary position, as an inclusion root cylinder, or as a full aortic root replacement.

3.1.1.2. *Toronto SPV glutaraldehyde-preserved porcine xenograft (St. Jude Medical)*

The aortic tissue is removed from all three sinuses, and the graft is covered with a thin coat of polyester. It can only be implanted as a subcoronary valve replacement. It has no antimineralization treatment. Hemodynamic performance has been excellent and equivalent to the Medtronic Freestyle device.

3.1.1.3. *Edwards Prima (Edwards Lifesciences)*

The Prima device is a low-pressure glutaraldehyde-fixed porcine aortic root similar to the Freestyle device. It has a thin cloth reinforcement over the muscle bar. The porcine coronaries were excised in the earlier version but preserved in the later version without ligation. The **Prima Plus** is a low-pressure fixed valve with proprietary XenoLogiX treatment for calcium mitigation.

3.1.1.4. *CryoLife-O'Brien (CryoLife International)*

Stentless porcine aortic valve is a manufactured composite of the noncoronary sinus and cusp from three porcine aortic roots. It is designed to be implanted below the coronary arteries in a supra-annular position in the sinuses of Valsalva by a single suture line.

The tissue is fixed in glutaraldehyde but there is no specific antimineralization treatment of this valve. Experience is limited to a few centers, and the technical aspects of implantation may be more difficult than with other stentless bioprostheses.

3.1.1.5. *Pericarbon Freedom (Sorin Group).*

The Pericarbon Freedom stentless valve is composed of two sheets of bovine pericardium sewn together to produce a cylindrical shape and fixed with glutaraldehyde.

3.1.1.6. *Biocor stentless (Biocor Industria e Pesquisas LTDA)*

Biocor stentless (Biocor Industria e Pesquisas LTDA) is a porcine aortic valve treated with the No-React (Shellhigh Inc., Union, NJ) process.

3.1.2. *Allografts*

3.1.2.1. *Cryopreserved aortic allograft*

Human donor aortic valve allografts are presented as the complete aortic root, ascending aorta, and some or all of the aortic arch. The anterior leaflet of the mitral valve typically remains attached.

3.1.2.2. *Pulmonary autograft*

Pulmonary autograft, the patient's own pulmonary trunk, including the pulmonary valve, may be used to replace the aortic valve, usually as a full aortic root replacement. The pulmonary

trunk is then replaced with a cryopreserved pulmonary allograft as described earlier. This operation (Ross procedure) is hemodynamically superior to other procedures for replacing the aortic valve, because the patient's own pulmonary valve is properly sized to accept cardiac output with little or no pressure gradient.

3.1.3. Straight tubular grafts

Straight tubular Dacron grafts of different manufacturers can be used for a full aortic root replacement when combined with either a stented or a stentless biological valve, and/or a mechanical valve. The advantages/disadvantages of straight tubular grafts versus grafts incorporating pseudosinuses of Valsalva are discussed in the following paragraph.

3.1.4. Grafts incorporating pseudosinuses of Valsalva

The native aortic root is not a stiff tube but rather a highly dynamic structure that accommodates to changes in the pressure-volume relationship in a very subtle way. During the early 1990s, Robicsek described the dynamic function of the aortic root and especially the sinuses of Valsalva [11]. The sinuses of Valsalva reduce the shear stress on the cusps of the aortic valve and promote optimal coronary blood flow during diastole [11, 12]. Another important aspect is of the facilitation of vortex formation that seems to help in smooth valve closure with less bending deformation in the longitudinal direction, and reduce the stress on the coronary anastomosis [12–15]. All the above factors can affect the durability and performance and longevity of the aortic bio-prosthetic valves.

Many attempts had been made by both surgeons and commercial companies to create a graft that resembles in shape and function of the native aortic root. The Valsalva graft is a Dacron graft with a specific design that, on implantation and pressurization, it generates three independent pseudosinuses. It is commonly used either in aortic-valve sparing procedures or in aortic root replacements when it is combined with a stented or stentless biological valve.

3.1.5. Composite grafts

Combination of either a tubular or a pseudosinuses-graft, with a biological (stented or non-stented) or mechanical valve, will create a composite graft.

Various such combinations are clinically common. The clinical differences stem mainly from the type of valve used, and in cases a pseudosinuses-graft is used, its potential benefits can be added to that of the valve it is combined with.

3.2. Composite versus valve sparing root replacement

The question of whether to replace the aortic root with a composite graft or to perform a valve-sparing operation is dependent on multiple patient characteristics as well as the surgeon preference. Over the last decade surgeons have debated which technique provides the best peri-operative and long-term results. The etiology of the aortic root disease, as well as individual patient preferences, must be taken into account so the correct procedure is performed for each patient.

Patients with connective tissue disorders, bicuspid valves, or history of valve infection may be best served with Bentall-type replacement rather than valve-sparing reconstruction. Despite the surgical complexity, long-term experience with VSRR among bicuspid and/or patients with connective tissue disorders are associated with excellent outcomes [16].

The current literature still lacks a definite answer to that question. Different authors publish very promising short, intermediate and long-term outcomes with both types of surgery. One recent large series published by Girardi et al. describes the outcomes of 890 patients (289 mechanical composites, 421 biological composites, and 180 VSRR). Operative mortality was 0.2% (0% in the VSRR group); the incidence of major postoperative complications was less than 0.5%. Predictors of adverse in-hospital outcome were age, nonelective operation, renal status, reoperation, New York Heart Association class, ejection fraction, and concomitant procedures. Five-year survival was 89.4%. In the propensity-matched groups, the type of operation performed did not affect in-hospital and late outcome. Aortic reintervention rates at 5 years were 0% for the mechanical composite valved graft group, 2.4% for the biologic composite valved graft group, and 7.3% for the valve-sparing reconstruction series. The authors concluded that in the current era, aortic root replacement can be performed with low perioperative risk in high-volume aortic centers. The type of operation performed does not affect early or late survival. Although the mechanical composite valved graft remains the gold standard for durability, the biologic composite valved graft and valve-sparing reconstruction are excellent options for those who cannot take or want to avoid long-term anticoagulation.

Another recent paper by David et al. was looking into the outcomes of a young (<70 years) patients group (total of 616 patients); and used propensity matching to compare valve-sparing root replacement to mechanical composite root replacement. The mean age at the work was 46 ± 14 years, mean follow up was 9.8 ± 5.3 years. Their outcomes showed reduced cardiac mortality among the valve-sparing group, the authors concluded that valve-sparing surgery should be the operation of choice for young patients with aortic root aneurysm and normal or near-normal aortic cusps [17].

4. Surgical technique

4.1. Aortic root replacement

4.1.1. Aortic root replacement with a composite graft

This operation is frequently referred to as the Bentall procedure, regardless of whether the composite is a mechanical or biological. Construction of the composite graft can be done either before opening the chest, or during the surgery itself, depending on the surgeon's preference. Constructing a biological composite with a graft and a stentless valve (i.e., Valsalva graft and Freestyle valve), might require more time than when using a stented valve and a tubular Dacron graft, and in these cases it is preferable to construct the composite before opening the chest.

CPB is established at 34°C using a single two-stage venous cannula and left atrial vent. The aorta is occluded just proximal to the brachiocephalic artery. Cardioplegia is given. The ascending aorta is opened transversely in its midportion. The patient's aortic root is dissected from the surrounding tissues. Traction stitches are placed above each aortic valve commissure to expose the aortic root. The aortic valve is excised. The coronary arteries are mobilized, retaining a generous button of sinus aorta. A limited dissection of the coronary artery is sufficient to ensure that excision of the coronary artery is complete and that the coronary button will move easily up to the composite prosthesis without kinking or creating undue tension on the artery. The remaining sinus aorta is removed. Diameter of the annulus is calibrated, and an appropriately sized composite prosthesis is chosen. Stitches are placed through the annulus of the aortic valve and brought up through the sewing ring of the prosthesis preferably using single interrupted braided sutures. It is the authors' preference to implant the valve in the vascular graft 2–3 mm above the lower end of the graft, and to place the root stitches through the graft itself and not through the valve ring itself. Doing so, provides the future option of explanting the valve itself if need be for replacement without disrupting the entire root. The composite valve is brought down, and sutures are tied down. Next, a direct anastomosis of the coronary ostia to the graft is made.

The distal end of the graft is then shortened to approximate the distal end of the aorta. The anastomosis is constructed using continuous stitches of 4–0 or 5–0 polypropylene, depending on the thickness and strength of the aorta.

It is the author's preference to use a composite graft constructed from a 27 to 29 mm Freestyle MS valve (Medtronic) sutured into a 28–30 mm Gelweave Valsalva prosthesis (Sulzer Vascutek, Renfrewshire, Scotland) as the choice when implanting a biological tissue valve. This composite requires 30–40 min preparation time, but provides the patient with the potential benefits of: (1) avoiding the need for anticoagulation, (2) excellent hemodynamic performance of stentless valves, (3) incorporation of sinuses of Valsalva into the neo-aortic root can improve the function and longevity of stentless valves.

4.1.2. Aortic root replacement with an allograft

This is typically performed in the setting of an aortic root infection. An aortic allograft may be used to replace the patient's aortic root completely. The initial steps of the surgery are similar to those mentioned in Section 4.1.2. Typically, the allograft is used intact and in natural anatomic orientation, with only the excess of septal myocardium and the anterior leaflet of the mitral valve removed. Size match is not nearly as important as it is for freehand sub-coronary valve replacement, but if the aortic annulus is more than 3 mm larger in diameter than the largest available aortic allograft, the patient's aortic root should be narrowed to approximate the size of the allograft. This can be done conveniently by placing a pledgeted mattress stitch through the aortic annulus alongside the commissures so that when tied, the intercusp triangle below the commissure is obliterated. The allograft is attached to the LVOT at the aortic annulus and below the commissures by simple interrupted stitches of 3–0 or 4–0 polypropylene.

The allograft is slipped over the sutures into the desired position in the LVOT. The sutures are then tied down. Incorporating a felt strip within the suture loops or using pledged sutures has been advocated by some authors, however, it was not found to be necessary in our experience.

The remainder of the operation proceeds as described for aortic root replacement with a composite graft.

4.1.3. Aortic root replacement with an autograft

The aortic valve may be replaced with the patient's own pulmonary valve (pulmonary autograft) and a pulmonary/aortic allograft used to replace the pulmonary valve. This operation was devised by Ross and carries his name. The detailed surgical technique is described elsewhere. The operation has the advantage of placing autogenous tissue in the high pressure aortic position that theoretically should last indefinitely. The allograft tissue is placed in the low-pressure pulmonary position, where even if it should fail, valve regurgitation is tolerated for a long time.

One main surgical pitfall of this technique entails potential coronary injury, separating the pulmonary trunk from the RVOT above the infundibular septum.

4.2. Valve sparing aortic root replacement

The exact surgical details of the remodeling and reimplantation procedures are beyond the scope of this chapter, but the main differences are discussed below.

The remodeling operation consists of removing the sinus aorta except for a small rim of aortic tissue around the coronary ostia and a rim of about 5 mm of aortic wall above the aortic valve annulus. Commissures are positioned to achieve good coaptation of the aortic valve cusps. An appropriately trimmed Dacron graft is sutured to the aortic root along the valve circumference (**Figure 1**). It is recommended that when aortic root remodeling procedures, such as the Yacoub operation, are performed in patients with Marfan syndrome, or when the aortic annulus is dilated, an aortic annuloplasty should be performed.

Reimplantation Procedure, in this procedure, the aortic valve is reimplanted within a polyester tubular graft. The graft is secured to a level plane in the LVOT just below the valve, except in the one sixth of the circumference occupied by the conduction system. This fixes the diameter of the LVOT, but one may reduce the diameter if necessary. The aortic valve is attached (reimplanted) to the inside of the prosthetic graft. The graft determines the diameter of the sinotubular junction.

The reimplantation procedure has undergone a number of modifications by both David and other surgeons. However, the basic concept has been retained (**Figure 1**).

The graft is usually 30–32 mm in diameter, although 28- or 34-mm grafts are occasionally used.

A classification schema beyond simply calling a procedure reimplantation versus remodeling can be seen in **Table 1**. David's classic reimplantation procedure using a cylindrical tube graft is described as David-I, while Yacoub's classic remodeling procedure is described as a David-II. In this system, David-III referred to a remodeling variation where a synthetic strip is placed over the fibrous portion of the left ventricular outflow tract, achieving a narrowing

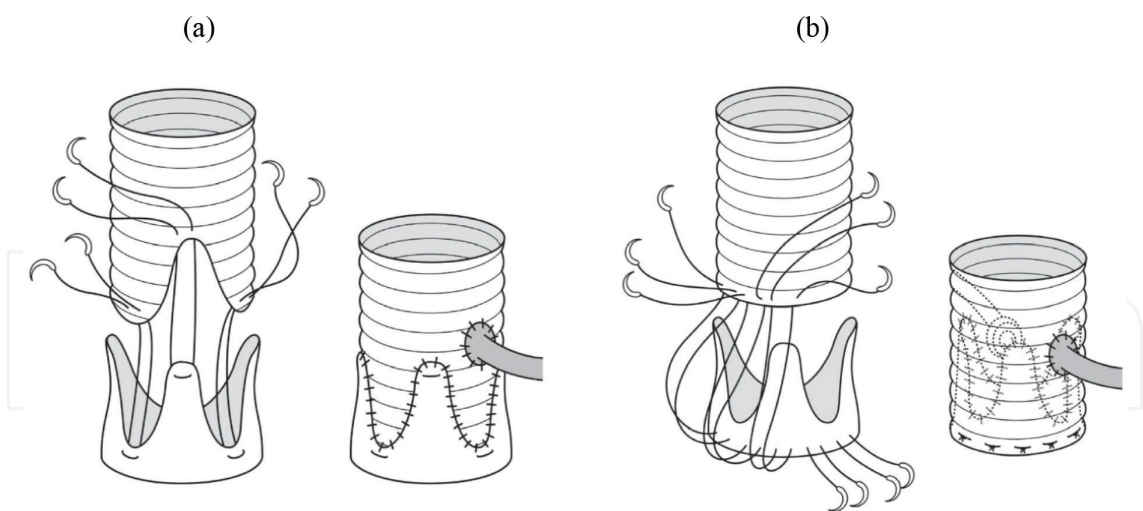


Figure 1. Schema of valve-sparing aortic root repair. (a) Remodeling and (b) reimplantation [18].

Type	#	Modification
Reimplantation	I	Classic
Remodeling	II	Classic
Remodeling	III	Adding an external synthetic strip over the fibrous portion of the LVOT
Reimplantation	IV	Adding a graft plication (diameter + 4 mm) at the sinotubular junction
Reimplantation	V	Adding a graft plication (diameter + 6–8 mm) at both the sinotubular junction and basal ring to create pseudosinuses

Table 1. David classification by Millar for valve-sparing aortic root replacement surgery.

and reinforcing annuloplasty. The final two methods identified are variations on reimplantation. David-IV refers to the technique of using a graft 4 mm larger than the annulus to allow for plication, and David-V employs an even larger graft (6–8 mm larger than the diameter) in order to facilitate the creation of pseudosinuses. Thus, David-I, -IV, and -V are variations on reimplantation, whereas David-II and -III are variations on the remodeling technique originally devised by Yacoub. In the late 1990s through the present day, attention shifted to focus on the finest details in technique, such as cusp reinforcement, graft sizing to allow for billowing, and plication as a means to recreate sinuses.

Dr. Cameron and the group at Johns Hopkins have published some of the largest series on elective repair of patients with connective tissue disorders in need of aortic root surgery [19]. Although a “classic” Bentall (i.e., composite valve-graft replacement) remains the gold standard in their practice, over the years they have introduced valve-sparing procedures when possible.

Their initial valve-sparing approach focused on preservation of sinuses with a remodeling procedure, but it soon became apparent that recurrent aortic insufficiency and annular dilation occurred in a significant number of patients soon after their initial procedure. At their center, as these results began to bear out, they transitioned to the reimplantation technique. This transition coincided with the newly approved De Paulis Valsalva graft and this combination became their exclusive procedure for valve-sparing operations [20].

4.3. Reoperation of the aortic root

Structural failure of the root, pseudoaneurysms, or infection may necessitate redo aortic root replacement. This is an operation that typically carries a higher risk of mortality and morbidity. Some special considerations include: calcified homografts or stentless valves, coronary artery length, and infection.

In patients with a heavily calcified neo-aortic wall it is often extremely difficult to dissect out the wall and redo the root as it becomes very adherent to the adjacent structures and pulmonary artery and coronaries can be injured. Replacing just the aortic valve within the calcified root is an option. With the advent of transaortic valve implantation (TAVI), this may be an option in high risk patients. El-Hamamsy et al. compared the Freestyle graft with homograft aortic root replacement in a prospective, randomized trial, and showed an improved age of survival, lower rate of reoperation, and echocardiographically less signs of valvular deterioration in the Freestyle group [21].

There can be difficulty with mobilizing the coronary buttons and placing them into the new root or they can be damaged. The Cabrol technique should then be deployed, where a graft is sutured end to end to both the right and left coronary buttons then sutured side to side to the aorta. A second option is to place an interposition vein graft between the coronary buttons and the graft. This is the author's preferred method as we find the grafting to be easier. Lastly bypass-grafting can be done with ligation of the coronary arteries. This is typically a last resort when bleeding and technical difficulties with the anastomosis are encountered.

Infected roots pose a major problem because of the amount of debridement and reconstruction that is required. The same surgical principles apply of removal of all infected and foreign tissue. Results have been promising using homograft replacements as demonstrated in perioperative and with long-term follow-up studies.

5. Conclusion

The anatomic complexity and serious pathology that affect the aortic root challenge the cardiac surgeon. In the 61 years since De Bakey and Cooley first replaced an ascending aneurysm with the aid of cardiopulmonary bypass, a number of surgeons' devised innovative steps to improve patient outcomes. Leaders in the field of cardiac surgery such as Bono, Bentall, Yacoub, and David have contributed greatly to our surgical armamentarium for treatment of aortic root pathology.

The design of the De Paulis Valsalva graft is another great addition to the surgeon's arsenal and reinforces the need to continue analyzing and improving surgical techniques based on the dynamic physiologic environment of the aortic root during aortic valve sparing procedures. While it is common to hear surgeons refer to aortic root replacements as a "Bentall," the procedures currently employed have undergone an evolution, enough so that what is done now does not resemble the aortic inclusion and side-to-side coronary anastomosis technique.

Conflict of interest

None.

Author details

Ziv Beckerman and Edward P. Chen*

*Address all correspondence to: edward.p.chen@emory.edu

Division of Cardiothoracic Surgery, Department of Surgery, Emory University School of Medicine, Atlanta, GA, USA

References

- [1] Cooley DA, De Bakey ME. Resection of entire ascending aorta in fusiform aneurysm using cardiac bypass. *Journal of the American Medical Association*. 1956;**162**:1158-1159. DOI: 10.1001/jama.1956.72970290003013a
- [2] Wheat MW Jr, Wilson JR, Bartley TD. Successful replacement of the entire ascending aorta and aortic valve. *Journal of the American Medical Association*. 1964;**188**:717-719. DOI: 10.1001/jama.1964.03060340015004
- [3] Starr A, Edwards ML, McCord CW, Griswold HE. Aortic replacement: Clinical experience with a semirigid ball-valve prosthesis. *Circulation*. 1963;**27**:779-783. DOI: 10.1161/01.CIR.27.4.779
- [4] Herr RH, Starr A, Pierie WR, Wood JA, Bigelow JC. Aortic valve replacement: A review of six years' experience with the ball-valve prosthesis. *Annals of Thoracic Surgery*. 1968;**6**:199-218. DOI: 10.1016/S0003-4975(10)66015-8
- [5] Bentall H, De Bono A. A technique for complete replacement of the ascending aorta. *Thorax*. 1968;**23**:338-339. DOI: 10.1136/thx.23.4.338
- [6] Yacoub M. Valve-conserving operation for aortic root aneurysm or dissection. *Operative Techniques in Thoracic and Cardiovascular Surgery*. 1996;**1**:57-67. DOI: 10.1016/S1085-5637(07)70081-5
- [7] Yacoub MH, Gehle P, Chandrasekaran V, Birks EJ, Child A, Radley-Smith R. Late results of a valve-preserving operation in patients with aneurysms of the ascending aorta and root. *Journal of Thoracic and Cardiovascular Surgery*. 1998;**115**:1080-1090. DOI: 10.1016/S0022-5223(98)70408-8
- [8] David TE. Remodeling the aortic root and preservation of the native aortic valve. *Operative Techniques in Thoracic and Cardiovascular Surgery*. 1996;**1**:44-56. DOI: 10.1016/S1085-5637(07)70080-3

- [9] David TE, Armstrong S, Ivanov J, Feindel CM, Omran A, Webb G. Results of aortic valvesparing operations. *Journal of Thoracic and Cardiovascular Surgery*. 2001;**122**:39-46. DOI: 10.1067/mtc.2001. 112935
- [10] Fazel SS, David TE. Aortic valve-sparing operations for aortic root and ascending aortic aneurysms. *Current Opinion in Cardiology*. 2007;**22**:497-503. DOI: 10.1097/HCO.0b013e3282efa0f4
- [11] Robicsek F. Leonardo da Vinci and the sinuses of Valsalva. *Annals of Thoracic Surgery*. 1991;**52**:328-335
- [12] De Paulis R, Tomai F, Bertoldo F, et al. Coronary flow characteristics after a Bentall procedure with or without sinuses of Valsalva. *European Journal of Cardio-Thoracic Surgery*. 2004;**26**:66-72
- [13] Kvitting JP, Ebbers T, Wigstroem L, Engvall J, Olin C, Bolger F. Flow patterns in the aortic root and the aorta studied with time-resolved, 3-dimensional, phase-contrast magnetic resonance imaging: Implications for aortic valve-sparing surgery. *Journal of Thoracic and Cardiovascular Surgery*. 2004;**127**:1602-1607
- [14] Beck A, Thubrikar MJ, Robicsek F. Stress analysis of the aortic valve with and without the sinuses of Valsalva. *Journal of Heart Valve Disease*. 2001;**10**:1-11
- [15] Katayama S, Umetani N, Sugiura S, Hisada T. The sinus of Valsalva relieves abnormal stress on aortic valve leaflets by facilitating smooth closure. *Journal of Thoracic and Cardiovascular Surgery*. 2008;**136**:1528-1535
- [16] Klotz S, Stock S, Sievers HH, Diwok M, Petersen M, Stierle U, et al. Survival and reoperation pattern after 20 years of experience with aortic valve sparing root replacement in patients with tricuspid and bicuspid valves. *The Journal of Thoracic and Cardiovascular Surgery*. 2018;**155**(4):1403-1411
- [17] Ouzounian M, Rao V, Manlhiot C, Abraham N, David C, Feindel CM, et al. Valve-sparing root replacement compared with composite valve graft procedures in patients with aortic root dilation. *Journal of the American College of Cardiology*. 2016;**68**:1838-1847
- [18] Shimizu H, Yozu R. Valve-sparing aortic root replacement. *The Annals of Thoracic Surgery*. 2011;**17**(4):330-336
- [19] Cameron DE, Alejo DE, Patel ND, Nwakanma LU, Weiss ES, Vricella LA, et al. Aortic root replacement in 372 Marfan patients: Evolution of operative repair over 30 years. *Annals of Thoracic Surgery*. 2009;**87**:1344-1349. DOI: 10.1016/j.athoracsur.2009.01.073
- [20] Patel ND, Williams JA, Barreiro CJ, Bethea BT, Fitton TP, Dietz HC, et al. Valve-sparing aortic root replacement: Early experience with the De Paulis Valsalva graft in 51 patients. *Annals of Thoracic Surgery*. 2006;**82**:548-553. DOI: 10.1016/j.athoracsur.2006.03.073
- [21] El-Hamamsy I, Clark L, Stevens LM, Sarang Z, Melina G, Takkenberg JJM, Yacoub MH. Late outcomes following freestyle versus homograft aortic root replacement: Results from a prospective randomized trial. *Journal of the American College of Cardiology*. 2010 Jan 26;**55**(4):368-376. DOI: 10.1016/j.jacc.2009.09.030