

We are IntechOpen, the world's leading publisher of Open Access books Built by scientists, for scientists

6,900

Open access books available

185,000

International authors and editors

200M

Downloads

Our authors are among the

154

Countries delivered to

TOP 1%

most cited scientists

12.2%

Contributors from top 500 universities



WEB OF SCIENCE™

Selection of our books indexed in the Book Citation Index
in Web of Science™ Core Collection (BKCI)

Interested in publishing with us?
Contact book.department@intechopen.com

Numbers displayed above are based on latest data collected.
For more information visit www.intechopen.com



Breast and Cervix Uteri: Rare Locations for *Mycobacterium Tuberculosis* Infections and Complications-Cases Report and Literature Review

Manuela Cristina Russu, Șerban Nastasia,
Daniela Degeratu and Ruxandra Viorica Stănculescu

Additional information is available at the end of the chapter

<http://dx.doi.org/10.5772/intechopen.75044>

Abstract

Breast and cervix uteri are rare locations for *Mycobacterium tuberculosis* (*MbT*) infection and *MbT* association to cervical cancer is more rare in European countries. This chapter analyses two cases of rare locations of tuberculosis (TB) in young Romanian women. The first patient presented a chronic primary TB breast abscess, non-pregnancy related with periods of apparent healing and repeated areolar fistula formation. In the second case, the unexpected discovery of secondary TB endocervical granulomatous inflammation with caseous necrosis on a radical hysterectomy specimen, performed after chemoradiotherapy for squamous non-keratinizing cell carcinoma is presented. Worldwide incidence, risk factors, hypothetic mechanisms of primary/secondary breast and cervix uteri *MbT* infection, the association to high-risk HPV, microbiological diagnosis difficulties, the differentials to pyogenic abscesses, other chronic granulomas and breast cancer treatment issues are presented in the reviewed literature, focusing on the peculiarities of these rare locations and complications. It is recalled an old concept of “therapeutic antitubercular” test when all other assessments steps are usefulness.

Keywords: tuberculosis, breast abscess, cervical caseous granuloma, carcinoma

1. Introduction

Tuberculosis (TB) is an old disease, known since 5000BC, and contemporary professional and scientific communities are challenged by the WHO's “*Global Tuberculosis Report 2017*” showing 6.3 million new cases of TB in 2016, with about 16% expected to die due to TB by 2020.

These data may be connected to the lack of an effective vaccine, and of sensitive and rapid diagnostic tests, to the appearance of multidrug resistant strains of *Mycobacterium tuberculosis* (*MbT*) [1, 2]. Low income, immunosuppressive disorders, worldwide travels and immigration are associated to TB globalization [3]. Breast and uterine cervix are rare locations for *MbT* even in TB endemic countries [1]. This chapter analyses two cases of rare locations of TB in young women from Romania, a middle-income country. The first case is a chronic, non-pregnancy-related primary breast abscess, with areolar fistula formation between periods of apparent healing. The second case is an association of secondary endocervical tuberculosis to a squamous cervical carcinoma in a young woman with a previous lung tuberculosis, without activation during/after specific cervical cancer therapy. In Europe, there are few papers in the form of case reports on breast or cervix uteri tuberculosis. Breast and cervix uteri tuberculosis are uncommon diseases with non-specific clinical, imagistic and or cytological/histological findings. Misdiagnosis or the diagnosis after many negative assessments for these rare TB locations are common, because biopsy specimens are paucibacillary, and other investigations such as microscopy and culture are frequently negative, as it is the PCR for *MbT*. *MbT* can simulate cervical carcinoma in premenopause and postmenopause [4, 5] due to abnormal vaginal bleeding at clinical presentation.

We intent to review and refresh the theories/hypothesis on the epidemiology, pathophysiology, diagnosis and therapeutic issues on these rare *MbT* locations and complications. In countries like Romania, where TB is non-endemic and the diagnosis for extra pulmonary tuberculosis is a surprise, the golden standard of microbiological evidence of *MbT* is rare, even with the new molecular techniques. It is reconsidered the “old concept of the therapeutic test” with antitubercular drugs, which was proved to be active in pulmonary tuberculosis.

2. Cases presentation

First case: A 31 years old Caucasian woman, higher studies and salaried, married, nuligesta, on combined oral contraceptives, no family or personal history of tuberculosis or known exposure to a person with tuberculosis, no mammary surgery, is presenting in December 2014 with nipple retraction and inversion, skin redness and thickening, over a breast inflammatory tumor of 2 × 1 cm size, in the internal upper quadrant of the right breast, freely mobile and a fistula at areola level, with no axillary or cervical lymphadenopathy, and normal left breast. The systemic examination is non-contributory, and no associated constitutional symptoms, as fever, no weight and appetite loss are registered.

The patient had three previous similar episodes, since 2007, with a fistula of the right breast abscess, sterile cultures for aerobic/anaerobic germs, and yeasts in the nipple purulent discharge.

Routine hematological and biochemical investigations, and serum prolactin levels are normal, HIV test is negative. Breast sonography reveals skin thickening, nipple retraction and dilated terminal ducts and ill-defined thick-walled cystic mass of 2.9 cm diameter.

The cytological examination after Giemsa stain from the fistula's purulent discharge shows a rich cellular smear, with many polymorphs background, lymphohistiocytic aggregates and Langhans type multinuclear giant cells, fibrin debris and rare epithelial cells, which conducted to the conclusion of a chronic breast inflammatory granuloma.

It is decided and incision-excision of the inflammatory mammary gland tissue was performed, with large drainage of the remaining cavity, samples collection for pathology/microbiology and no other unwanted events as shock or toxemia.

In January 2015, a new fistula occurred on the opposite on the opposite area of the right nipple, with discharge of purulent material, without fever or other general symptoms, as she never presented at each previous medical consultations (**Figure 1**).

The cultures for aerobic/anaerobic germs and yeasts are sterile, the pathological examination discovers rare epithelial cells of squamous type, lymphocytes, plasma cells, histiocytes, multinuclear giant cells of Langhans type and a multitude of blood vessels. The Ziehl Neelsen stain for acid-fast bacilli and PCR for *MbT* from sample collected at excision biopsy are negative (**Figure 2(A, B)**).

The chest X-ray examination is normal and the PPD skin test is 10 mm.

In March 2015, a 6 months antitubercular treatment (ATT) with three drugs was recommended: isoniazid, rifampicin and ethambutol with intensive therapy for the first 3 months is administered. The follow up from May 2015 (after 2 months of intensive therapy) shows remission of the fistulas, heal of the skin, the persistency of the nipple retraction and a 2 kg weight gain. The patient had a total 9 months ATT (**Figure 3**).

The final diagnosis is primary non-gestational breast tuberculosis abscess.

The second case: A 29 years merchandise by occupation, smoker of five cigarettes per day, non-alcoholic, married since 10 years is presenting for repeated postcoital abnormal vaginal bleeding and blood-stained discharge since 6 months. History: physiology: the menarche:

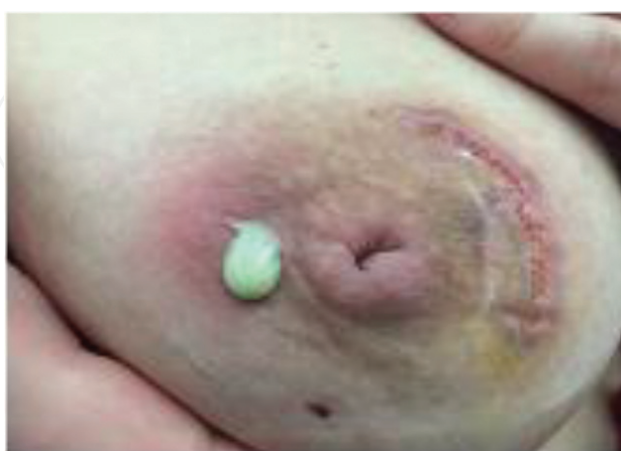

Figure 1. Photograph of the scar from slowly-healing post-incision/excision-drainage wound of the right breast, and the new fistula on the opposite part of the right areola and purulent discharge.

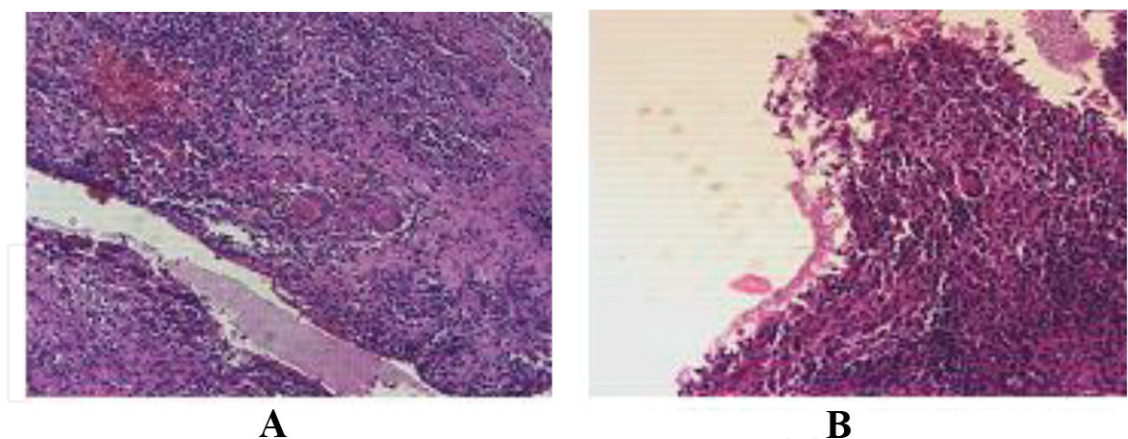


Figure 2. Pathological images (**A.** Hematoxylin & Eosin, 40X; **B.** Hematoxylin & Eosin, 20X): Inflammatory granulomatous lesions: Rich chronic inflammatory infiltrate, with many histiocytes (with epithelioid aspect) and frequent multinuclear giant cells Langhans-type. Collection of Degeratu Daniela, “Dr I. Cantacuzino” Laboratory of Pathology.

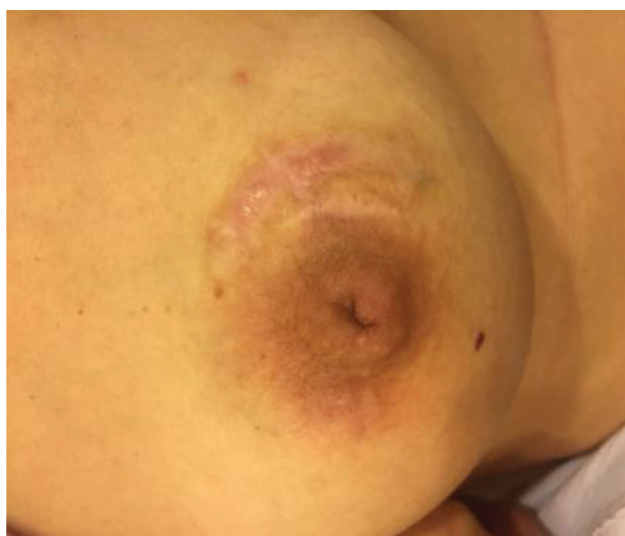

Figure 3. Photograph of the right breast after two months of intense active antitubercular treatment. Patient in recumbent position with healed wound, without sinuses of the areola, and inverted nipple.

14 years; 2 full-term spontaneous deliveries; 1 abortion; pathology: pulmonary tuberculosis (treated and considered healed in 2002); no surgical illness. LMP: August 20, 2008, immunological pregnancy and HIV tests: negative. General physical examination was essentially normal; abdominal examination revealed no mass, no ascites, no hepatosplenomegaly and no other abnormality.

Vaginal speculum examination: an irregular, cauliflower-like tumor of 4 cm in the largest size on the anterior cervical ridge, spontaneously bleeding, and on touch; normal vaginal walls and bilateral fornices.

Vaginal bimanual examination: anteverted uterus of normal shape, and volume, firm, mobile and no adnexal mass.

Per-rectal examination: smooth rectal mucosa, and freely mobile, no induration or nodularity of both parametria.

Pap smear: epithelioid-like cell clusters with atypia. Colposcopic examination increased vascularity on the posterior cervical ridge, acetowhite on the anterior cervical ridge, with negative iodine stain with precise contour around the previously described cauliflower-like tumor.

Provisional diagnosis of carcinoma cervix stage I B was kept, and after preliminary investigations, patient was posted for multiple cervical biopsies—the tumor and from other four cardinal points in the vicinity.

The histopathological diagnosis came out to be squamous non-keratinizing cell carcinoma (**Figure 4**), and the specific tests for viral infection had revealed the presence of genotype 33 HPV.

Hematological test: low degree anemia (Hb: 11.0 mg/dL, Ht; 34%), leukocytosis and thrombocytosis.

Biochemical and coagulation tests: normal.

Chest radiography showed fibrous and fibro-nodular sequelae of pulmonary tuberculosis.

After 4 weeks of radiotherapy (tele-radiation and 2 cures of brachytherapy) plus chemotherapy (cisplatin), the patient is proposed for surgery, which is accepted and it is done a Wertheim's radical hysterectomy with bilateral pelvic node dissection. The post-surgery pathological examination showed a cervix with large areas of ulceration, polymorph inflammatory infiltrate and multinuclear giant cells of foreign body type, micro-calcifications and small islands of squamous non-keratinizing cancer cells. The endocervix presents a granulomatous inflammation with caseous necrosis and Langhans multinuclear giant cells. The vaginal part and the lateral part of the cervix have no neoplastic invasion. The endometrium is atrophic, the ovaries have albicans bodies, the tubes have hypoplastic mucosa, and the examination of 10 lymphnodes shows their reactive aspect, lipo-dystrophy and micro-calcifications.

PCR for *MbT* was performed on archived tissue (formalin-fixed paraffin embedded uterine tissue) following detection of cervical TB by pathology, was positive in the cervix. The patient

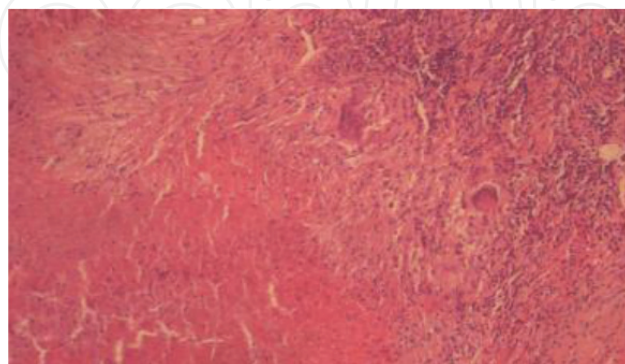


Figure 4. Two confluent epithelioid caseous granulomas with Langhans-type giant multinuclear cells and lymphocytic inflammatory infiltrate at the periphery, HE stain, 10 x. Collection of Degeratu Daniela, "Dr I. Cantacuzino" Laboratory of Pathology.

has a normal evolution post-radio, chemotherapy and post-surgery, without any reactivation of the pulmonary tuberculosis.

3. Epidemiology: risk factors

3.1. Epidemiology of breast tuberculosis

Breast TB was first described in a very young woman by Sir Astley Cooper in 1829 as “scrofulous swelling of the bosom”, and the location of *MbT* in the cervix uteri was first described 2 years later by Renaud (1831). Extrapulmonary TB was reported in nearly 18% of cases in USA [6], and TB location in the breasts is extremely rare in Western populations from 0.025 to 0.1% of all surgically treated breast diseases. In the last 20 years, the Southern European countries such as Greece, Turkey, Italy and Spain reported rare such cases, and 0.64–3.59% of all mammary treatable conditions are in developing countries from Asia [7], where the overall incidence of histological confirmed breast TB is 0.4% per year [8]. In India, the incidence of breast TB is five times less common than carcinoma of the breast [8]. There are described fluctuations in the incidence of generally breast TB, with the highest incidence in Southern Turkey in 2007 [10], and in the last 8 years (**Table 1**) the reported cases with primary breast TB have an increasing incidence all over the world, as it is the Romanian case, which had the first episode in 2007. Mammary involvement is nearly equal in frequency in the right and left (40.0 vs. 44.0%) [10], bilateral disease is rare [11, 12], as it is the infra-mammary location of tuberculosis [13]. Breast tuberculosis is affecting women in the reproductive age,

Continent	Number of cases since the year 2000 (00)																
	00	01	02	03	04	05	06	07	08	09	10	11	12	13	14	15	16
Europe	1 It	0	0	1 Gr	0	1 T	1 T	1 Ch	0	3 T	0	0	0	0	0	1 R	0
Africa	0	1 Mo	1 Mo	0	0	0	0	0	0	0	0	0	1 Mo	0	0	0	0
Asia	8 In		1 In	0	0	0	35 In	0	1 In	0	2 In Tw	3 Ir In	8 In	2 In	8 Ir In	0	0
North America	0	0	0	0	0	0	0	0	0	0	0	0	1 Mx	0	0	0	1 US
South America	0	0	3 Br	0	0	1 Br	0	0	0	1 Br	0	0	0	1 Co	0	0	0
Australia	0	0	0	0	0	0	38	0	0	0	0	0	0	0	0	0	0
New Zealand																	
It, Italy; Gr, Greece; T, Turkey; Ch, China; R, Romania; Mo, Morocco; In, India; Tw, Taiwan; Ir, Iran; Br, Brasil; Mx, Mexico; Co, Columbia; US, United States of America.																	

Table 1. Annual worldwide published cases with primary breast tuberculosis (last 16 years medical literature - Google scholar, Medline, web of science).

21–30 years, predominantly, a case being reported during pregnancy [14], and rarely in prepubescent [15] and elderly postmenopausal women [16], the last category being more affected in the early twentieth century, and in the last years it is discovered in women and men [17, 18]. None of the recognized risk factors (multiparity, lactation, trauma, past history of suppurative mastitis, breast surgery/breast reconstruction [19, 20], silicon breast introduction or AIDS [21] was present in the Romanian reported case.

3.2. Epidemiology of cervix uteri tuberculosis

In developing countries like India, TB is a major socioeconomic burden, afflicting 14 million people mostly in the reproductive age group (15–45 years). Regarding the genital tract, fallopian tubes are involved in almost all the cases of pelvic tuberculosis, endometrium in 50–60% and ovaries in 20–30% [22]. Cervical tuberculosis accounts for 0.1–0.65% of all cases of the disease and 5–24% of genital tract [23].

4. Pathophysiology

4.1. Pathophysiology of breast tuberculosis

The breast was considered an organ that offers resistance to the survival and multiplication of the tubercle bacillus [24], like other organs such as spleen, skeletal muscle or cervix uteri, and this property is one of the reasons for the uncommon diagnosis of breast TB, and in countries like India it is supposed that the breast TB is confused to carcinoma [25], or to a pyogenic breast abscess [26], or to other diseases [27], tubercular mastitis being a “great masquerader” [28]. In contrast to this quality, when breast is infected with *MbT*, it was proved that BRCA 1/2 network is suppressed during infection suggesting that breast cell proliferation suppression is a feature of Koch bacilli survival [29].

Breast TB is described to be primary or isolated, and secondary. The primary breast TB is appreciated when the breast infection is the only manifestation of the disease, no demonstrable tuberculous focus exists elsewhere in the body [30], and the infection is through abrasions or through the openings of the ducts in the nipple. Primary breast TB is rare in comparison to secondary to lung or extrapulmonary, and the authors consider that the Romanian case is among primary breast tuberculosis. The secondary type is appreciated when a pre-existing lesion is located elsewhere in the body. Secondary *MbT* can spread by three routes such as hematogenous, lymphatic or directly from the primary location such as lung, pleura, ribs, mediastinum and articular lesions. It is supposed that the patient had acquired the *MbT* during a plain long distance travel, some previous years ago, when she claimed the first episode of breast inflammation; extensive travels seem to be responsible for tuberculosis globalization, statement common to others’ physicians [3], which is an explanation for a primary men’s breast tuberculosis, as it the case of a 44 years old Lithuanian man living in UK [18]. In countries where TB is endemic, young lactating women are more prone to develop breast tuberculosis, being described an incidence that can vary in the limits of 7–33% [31–33]. All

types of *Mycobacterium spp.*, and other types of antigens or foreign bodies, as milk during pregnancy or lactational period, are met by a vigorous cell-mediated hypersensitivity reaction involving macrophages, epithelioid and giant cells, Th1 lymphocytes, and their cytokines, which are activated and are developing the granulomas [34].

In Romania, like in countries with endemic tuberculosis as India, Pakistan, China, Iran and Korea, tubercular infection is seen more frequent secondary to a tubercular focus such as lungs, pleura or lymph nodes, which very frequently actually may not be detected clinical or radiological [26]. The breast infection is acquired usually from lungs by many routes (hematogenous, lymphatic via tracheobronchial, paratracheal, mediastinal lymph trunks or internal mammary nodes), by spread from contiguous structures and by ductal infection [8]. *MbT* is affecting differently breast structures, according to route of contamination: the epithelium of the ducts (primary) or of the lobules (secondary) with loss of acinar structures; and the entire epithelial lining of the lobules is destroyed, caseating necrosis appearing in the center of the lesion, and the destructive mechanisms are progressing and involving the skin, which may ulcerate and create fistula/sinuses; in other cases, specially in elder women, the mechanisms of repair/restoration are developing excessive dense fibrous tissue.

4.2. Pathophysiology of cervix uteri tuberculosis: Hypothesis on the association to cervical cancer

Pelvic organs are infected from a primary focus, elsewhere in the body, most commonly from lungs, by hematogenous spread. The cervix may be infected, as a part of this process, by lymphatic dissemination from the infected tube, or by direct extension from the endometrium. It is discussed a cervical infection from the sexual partner/partners with tuberculous epididymitis, being discussed the increased risk when there are multiple sexual male partners, especially in China [35]. It is discussed a relative immunity of the cervix to *MbT* as it was shown previously for other organs, which is probably connected to the inability of the bacillus to penetrate the squamous epithelium of *portio vaginalis*, and to cervical mucus resistance, but in rare cases, cervical TB may be a primary infection, *MbT* being introduced by a partner with tuberculous epididymitis or other genitourinary disease [36], but the sexual partner of the reported patient was negative for pulmonary TB. It was suggested the role of the sputum used as a sexual lubricant [22].

In the nineteenth century, it was a controversy as whether tuberculosis and cancer can coexist in the same organ; Carl von Rokitansky (1855) was the first to propose the view that there is a definite antagonism between the two, meaning that tuberculosis and cancer cannot be present in the same organ, but after the influences of Votta J Paul work and through his own further experience, Rokitansky later changed his previous generally accepted view, and admitted that tuberculosis and carcinoma can coexist, but that this coexistence is rather rare. The Romanian report on this pathological association is done for its rarity in Europe, and to the best of authors' knowledge, in the last 45–50 years, two similar cases in Romania (Iași) by Luchian et al. [37] and one case in Poland [38] are described. The question is whether tuberculosis is before cancer, or the presence of the viral infection made possible the secondary location of the *MbT*. The pathological exams of the reported case did not revealed extensive granulomatous

reaction, or cancer metastases in the endometrium, tubes, ovaries and lymph nodes. Since many years from the first description of the association of these two life-threatening pathologies, host response as the basic mechanism of specific defense against infection and tumor factors that enable such a response are also discussed since long time [39], being not completely known/understood, they may benefit from the host's previously compromised immunity: *MbT* and HPV can potentate each other.

The *MbT* is a facultative intracellular parasite that grows well in non-activated macrophages. When large numbers of these bacilli have grown intracellularly within such macrophages, a cytotoxic immune response, herein called tissue-damaging delayed-type hypersensitivity kills the macrophages, forming the caseous center of the tubercle, where the tubercle is surviving; such a delayed-type hypersensitivity was first described for the pulmonary tuberculosis [40], and this patient have suffered from pulmonary tuberculosis 7 years earlier. The progression of cervical dysplasias to invasive, lethal cervical cancers has been attributed to diverse factors such as immune, hormonal, and nutritional status, or co-infection with other sexually transmitted agents, supporting data being equivocal [41].

The contemporary professional societies are sure on primary immune defense system deficiency or incapacities to some infections, bacterial and viral, which were demonstrated in the systemic circulation and in some bodies locations – in the cervix uteri or in the breast. In North America [42], Western Europe [43, 44] and recently in China [45], it was proved the shifted balance between T helper 1 (Th1)-type and Th2-type cytokines in cervical dysplasia [42, 46], the involvement and increase of invariant natural killer T (iNKT) cells (which are in small number in condyloma acuminatum, in mild and moderate dysplasias [47]), and the cytokines production from cervical keratinocytes [48] the main targets of HPV infection as the stratified epithelium cells, and the main source of cytokines [49], as type I interferon (IFN)- γ , tumoral necrosis factor (TNF)- α , transforming growth factor (TGF)- α , interleukin-1 (IL-1), interleukin-6 (IL-6), interleukin –8 (IL-8) expressions are involved in immune system modulation (all of them being parts of innate immune system), in the evolution from persistent high-risk HPV-infected cells to the development of high-grade cervical intraepithelial neoplasia and cervical cancer, because the keratinocytes cannot destroy the fact high-risk HPV, and that may work also on *MbT* infection evolution, and complications. Parallel to these conditions, it is the individual cellular system of defense [50], involved in early phases of infection [51, 52]. Flow cytometry is revealing an increased level of CD3+ T, CD + 4 cells [53, 54] among both epithelium and stromal layers of the cervical tissues, contributing to the suppression of local immunity. In conjunction to these details is the presence of the population of monocytes/macrophages in the endocervix, with increasing number in cervical high-grade lesions with the parallel decrease in Langerhans cells, in contrary to what occurs in non-infected tissues [55]. All these facts contribute to the escape of HPV to tissue innate and acquired immune system, which is also influenced by the viral epitopes E6 and E7 [56], and evolution from less invasive to more advanced invasive cervical HPV-induced carcinoma is associated to a higher number of T and B lymphocytes, macrophages and induced nitric oxide synthase-expressing cells in the peritumoral stroma, so cell migration being proportional to the progression of the lesion [54]. Some studies show that these high number of inflammatory cells and compounds may open the way to bacterial infections, being additional mediators [57].

Insertional mutagenesis by HPV is another proposed tumor-promoting mechanism, but recent studies have not supported this hypothesis [58]. No common, recurring genetic alterations that cooperate with HPV to promote cervical cancer progression have been identified since Harald Zur Hausen first identified HPV as the causal transmissible agent of cervical cancer nearly 40 years ago [59]. To the pressing question to the biological basis of cervical cancer progression which is to be resolved since long time, the discover of the loss of a major tumor suppressor *LKB1* [60, 61] or somatically acquired mutations in this tumor suppressor *LKB1* [62], which is considered to be similar to p53. When *LKB1* deficiency/mutations, a primary cervical tumor confined to the cervix at the time of diagnosis has a bad prognosis: early metastasis and patient death, after the initial diagnosis despite aggressive therapy including radiation treatment. These abnormalities were first discovered in connection to Peutz-Jeghers Syndrome [63] and pulmonary cancer [64]. The *MbT* was proved to reduce host's immunity to high-risk HPV types for cervical cancer. The Chinese study "Shanxi Province Cervical Cancer Screening Study I" [36] showed an increasing magnitude of effect of *MbT* with increasing severity of disease in an isolated women population from rural China, as is demonstrated by the increasing odds ratios from 1.68 for HPV positivity to 1.75 for persistent HPV and then 2.08 for CIN3+. Associated to these findings, it was showed that TB and cervical inflammation were diagnosed in 1% of the women, and associated with 90% higher odds of oncogenic HPV infection and 113% higher odds of persistent HPV infection. The authors of the "Shanxi Province Cervical Cancer Screening Study I" are considering that their results are consistent with the novel hypothesis that TB may provide an immunological profile that is associated with an increased susceptibility to HPV infection. In conjunction to this hypothesis, we can speculate like that *MbT* is associated to the loss/mutations in *LKB1* tumor suppressor, because persistence of small islands of squamous non-keratinizing cancer cells after radiation and chemotherapies.

5. Diagnosis

Regarding the diagnosis, one must consider the clinical presentation, physical examination, laboratory results, specially the microbiological ones and imagistic tools, and after the difficulties of the Romanian first published case of breast tubercular abscess on must reconsider an old concept of diagnosis—the "therapeutic" test.

5.1. Clinical presentation: physical examinations

5.1.1. Clinical presentation of breast TB

Clinical presentation of breast TB is variable regarding symptoms/signs: swelling of the breast 48.1% [65]; painless hard lump in approximately 60% cases [66], or pain is revealed as the first complain of some patients [67, 68] or up to 18.5% of cases [65]; rarely are recorded multiple lumps, the lump being with irregular borders, sometimes with skin fixation or to the underlying muscle or even chest wall, clinical findings imposing differential to breast carcinoma [69], situation which is much more suggested by the presence of an isolated breast mass, sometimes skin fixated "peau d'orange" sign, and without an associated sinus tract; abscess, unique or

multiples; skin thickening; and skin sinus/fistula/multiple discharge sinuses [70], nipple retraction or inversion, nipple hyperpigmentation or focal discoloration –when the disease is long time duration [69], breast shape and sizes change, axillary lymphadenopathy (axillary lymph nodes are found in one-third of cases with breast TB [33]. Constitutional symptoms as fever, weight loss, night sweats or a failing of general health are infrequently encountered [71, 72].

5.1.2. Clinical diagnosis of cervix uteri tuberculosis

Irregular vaginal and postcoital bleeding with different aspects could occur at the cervix speculum examination such as exophytic-cauliflower aspect, tumoral-granulomatous, ulcerative and polypoid endocervical [73]. In many countries, even where tuberculosis is endemic, the majority of cases remain asymptomatic, but infected, and are discovered incidentally or remain undiscovered [22, 74]. Cervical examination of cases with cervical tuberculosis is normal in 90% cases, and the rest presents non-specific macroscopic changes, ulcerative/hypertrophic nodular lesions like proliferative cauliflower growth or fistulas/sinuses, or friable papillary growth covering almost the entire ectocervix. All these aspects may simulate invasive cervical cancer, or a miliary appearance [75–77]. There are reported cases with entire genital tract involvement, with myometrial alterations [78, 79], and association with tuberculosis of vulva and vagina [80].

5.2. Laboratory assessment

Current hematological and biochemical analysis are minimally influenced in cases with these *MbT* locations. It is cited a high level of white blood cells, and of ESR [77].

5.2.1. Bacteriological diagnosis

The golden standard for TB diagnosis is to detect acid-fast bacilli (AFB) in the infected tissue, but it is well known how difficult is the Ziehl-Neelsen stain or the cultures for BK to become positive [67, 72, 81], because the necessity of a high number *MbT* in the smear (more than 10,000 bacilli/mL), and the slow growth of all mycobacterial species, including *MbT*, fact that partially explains the delay of TB diagnosis. It was recommended scanning with high-power oil immersion because these diagnosis difficulties, but the practice proved that scanning with a X 40 objective should suffice in most cases. There were proposed alternative stains to the conventional Ziehl-Neelsen stain, such as auramine/auramine-rhodamine using fluorescence technique [82], which in association to a higher power examination (x 600) may have better detection for *MbT* [83].

It is known that biopsy specimens that are cultured on Löwenstein-Jensen medium at room temperature yield pigmented mycobacterial colonies in 2–4 weeks. In the literature of bacteriology, it is very important the place for sampling, and leveling that may affect the sensitivity of a stain in the detection of rare organisms as *Mycobacterium spp.* or fungi. On the other side, for a better discovery for *MbT*, it is recommended to examine at least two blocks of biopsy instead of one [84]. In India, it is reported that are possible positive cultures of nipple discharge for *Staphylococcus aureus* associated with positivity for *MbT* [85].

Actually many infections are detected by immunological assays proving the host competence, but for TB this aim is still a future desire; a very recently study of North American Universities' Microbiology and Pathology Laboratories [86] have confirmed the limitations of serodiagnosis for active tuberculosis, including poor sensitivity and increased reactivity with *non-tuberculous mycobacterium*-positive patients.

5.2.1.1. Bacteriological diagnosis of breast tuberculosis

The molecular diagnosis from clinical specimens is the aim of modern diagnosis of *MbT*, since many years, and this may be accomplished by nuclear acid amplification (NAA). The used methods allow the detection of mycobacterial DNA or RNA directly from the specimens, before the culture results are available [87]. Food and Drug Administration had accepted since the year 2000, two types of NAA, which were initially used for pulmonary tuberculosis, and later in extrapulmonary cases. The NAA is usually recommended when the smear evaluation is negative for AFB, and when clinical suspicion is very high, or when TB is endemic, but there are controversies on the specificity, sensitivity of the methods regarding the origin of specimen from respiratory tract or other sites [88]. The recommended tests are the enhanced *MbT* Direct Test (E-MTD; Gen-Probe, San Diego, CA) and Amplicor *MbT* Test (Amplicor; Roche Diagnostic Systems, Inc., Branchburg, NJ), and associated to these tests there were many studies about each value, specially for differential to granulomatous mastitis [12, 83, 89] or for the value of polymerase chain reaction (PCR) for real time *MbT* to compare to formalin-fixed, paraffin-embedded histologic specimens [90].

The real-time PCR for *MbT* on paraffin-embedded tissue is available with a high specificity of 99%, but low sensitivity of 65% for breast tissue in contrast to other types of specimens such as cerebral spinal fluid, urine and bronchoalveolar lavage, where sensitivity of more than 90% is reported, with comparable specificity [91, 92].

In the Romanian case, the molecular test—PCR for *MbT* on paraffin-embedded breast tissue was negative, and there are some researches [83, 93, 94] sustaining that molecular tests are not always relevant for the diagnosis of TB in smear-negative specimens. It is appreciated that real-time PCR for *MbT* is useful if positive, and confirms the presence of *MbT*, but if negative does not rule out the possibility of an infection [83]. Breast TB is paucibacillary and consequently tests such as microscopy, culture and NAA tests such as PCR techniques do not have the same diagnostic utility as they do in pulmonary tuberculosis [95]. There are some explanations for the negativity of the described tests for BK identification. One old explanation [84] is that the microorganisms have been killed and/or removed by the inflammatory process. Other explanation for PCR negativity is the existence of *non-tuberculous* infections such as *Corynebacterium* spp. [96], or *non-tuberculous mycobacterium*, which are now more common than tuberculosis in Western countries, and therefore would not be detected by this assay.

5.2.1.2. Bacteriological diagnosis in cervical tuberculosis

The demonstration of the presence of *MbT* in the cervix uteri with the Ziehl-Neelsen staining was proved to be difficult in many reported cases all over the world, even in India and China

[97]. In the Romanian case, *MbT* presence in the endocervix was confirmed by PCR for *MbT* performed on archived tissue (formalin-fixed paraffin-embedded uterine tissue).

5.3. Cytological diagnosis

5.3.1. Cytological diagnosis of breast tuberculosis

Actually fine needle aspiration cytology (FNAC) is considered a minimally invasive diagnosis method for breast pathology [98], including TB, because is revealing chronic granulomatous inflammation with caseating necrosis, presence of Langhans giant cell, and lymphocytic aggregates [99–101], but some studies are showing that in one quarter of cases FNAC is negative for breast tuberculosis diagnosis [71], because tissue samples collected at FNAC are not usually adequate for evaluation, or because caseating necrosis can be absent on the specimen. The absence of necrosis on breast specimen from FNAC does not exclude tuberculosis, which is sustained by other histological abnormalities [102]. In these situations, the next step for the diagnosis of mammary TB is the pathologic evaluation of specimens collected at open surgical biopsy [71], as it was done in the Romanian case, after the evaluation of the smear from fistula discharge.

5.3.2. Cytological diagnosis of cervix uteri tuberculosis

The Pap smear, a non-invasive procedure, may help in the diagnosis by the discover of epithelioid and multinucleated histiocytic cells, described since many years ago and rediscuss actually [103–105], fact that prompts further investigation. The epithelioid cells are elongated cells with pale eosinophilic cytoplasm, indistinct cell borders having large oval/elongated nuclei with a delicate chromatin pattern in singles/clusters. Multinucleated histiocytic cells, typical of Langhan's cells type, have large number of delicate, often ovoid nuclei, some overlapping, arranged peripherally and often in horseshoe fashion. The presence of those multinucleated histiocytic giant cells may help to differentials to herpes virus infection—the cells have epithelial origin, but lower number of nuclei, and show characteristic crowding/molding without overlapping with eosinophilic inclusion in nuclei and cytoplasm, and also in post radiotherapy of postmenopausal women smears, where the cells have bad outline, and may contain some phagocytosed debris with radiation-induced changes [104]. In countries with endemic tuberculosis, it is appreciated that the Papanicolaou smear is helping very much the staff, the Ziehl-Neelsen stain of cervical smear, and fluorescent technique and culture are confirming later [105]. The Romanian woman was not postmenopausal, a viral infection with high-risk HPV was clearly demonstrated, by genotyping of the cervix after surgery, but these type of cells were absent in the smear.

5.4. Pathological diagnosis of *MbT* infection

5.4.1. Pathological diagnosis in breast *MbT* infection

There are known two pathological classifications of breast tuberculosis: an old one—McKeown and Wilkinson [106] cited by Bahoroon [107], and a recent one—Tewari and Shukla [7].

McKeown and Wilkinson [106] had classified breast tuberculosis into five pathological varieties: (1) nodular—the most common variety presenting as a localized mass, with extensive caseation, and little fibrosis; (2) diffuse or disseminated—second most common variety, involving the entire breast with multiple intercommunicating foci of tubercles within the breast, which caseate leading to ulceration and discharging sinuses; (3) sclerosing—extensive fibrosis rather than caseation is present, suppuration is rare, the entire breast is hard, the nipple is retracted/inverted, category which is often mistaken for breast carcinoma; (4) tuberculous mastitis obliterans, characterized by duct infection producing proliferation of the lining epithelium, and marked epithelial and periductal fibrosis; and occlusion of the ducts, with appearance of cystic spaces, and all these resemble “cystic mastitis” and (5) acute miliary tuberculous mastitis, which occurs as a part of generalized miliary tuberculosis. The last two entities have only historical importance, being rarely described in the recent medical literature.

The Indian pathologists [108] have introduced a new pathological classification of breast tuberculosis, with three categories: (1) nodulo-caseous tubercular mastitis; (2) disseminated/confluent tubercular mastitis and (3) tubercular breast abscess.

There are some controversial discussions about the “granulomatous mastitis”, diagnosed during childbearing period, usually in parous women, in early 1930s, which are frequently misdiagnosed as tuberculosis or carcinoma [108], with negative culture for *MbT*, and with cytological and immunocytochemical findings definitely for differential diagnosis from breast tuberculosis at fine needle aspiration cytology [109] or at open surgery. The pathological changes induced by *MbT* in breast make the differences to other breast pathology, “idiopathic granulomatous mastitis”, which is also a “masquerader” [25, 28]. Tuberculous mastitis is often considered a form of “granulomatous mastitis” secondary to breast *MbT* infection, and some authors reserve the term of “granulomatous mastitis” to “idiopathic granulomatous mastitis”, a chronic breast inflammatory entity [110]. Granuloma is a defense mechanism against antigens, which stay in many organs without inactivation. The granulomatous lesions are classified into infectious, vasculitis, immunological, chemicals and neoplasia [35], or the recent classification is more simple: infectious and non-infectious granulomas, with the prove from new studies that pathogenic microorganism are suspected to be a cause of granuloma in non-inflammatory diseases [111].

The etiology of “granulomatous mastitis” is unclear, being postulated, and sometimes proved, the autoimmune factors [112], sarcoidosis, fat necrosis, undetected organisms (as blastomycosis, actinomycosis, cryptococcosis, histoplasmosis, filarial infection and corynebacterium), Wegener’s granulomatosis, reaction to childbirth, and use of oral contraceptives, ductular ectasis [113] the last two factors are present in the reported case. “Granulomatous mastitis” was the first diagnosis in authors’ mind at the beginning of investigations, and this is partially an explanation of the delay in diagnosis, and late specific antitubercular treatment, as in other cases from literature in the last years [12]. These breast pathologies – tuberculosis and “idiopathic” granulomatous mastitis are considered “masquerader” [28] or “imitator” [89].

There are described some pathological characteristics [107, 114, 115], which make the differentiation between the “idiopathic “granulomatous mastitis”—first described by Kessler and Wolloc [113], and breast TB. TB is affecting all breast structures (lobules, ducts, fat; some pathologists consider that ducts are specially affected), and the tubercular granulomas are

associated to caseating necrosis which makes the name of “caseating granulomas”, and the difference from “idiopathic “granulomatous mastitis [107, 116], which was named “lobular non caseous granuloma” (Table 2). The isolation of *MbT* in the central necrosis increases the sensitivity of the diagnosis.

There are mentioned some other types of “necrositing granulomas” in which infections-inflammation are frequently associated, and are proved with special stains (as Ziehl-Neelsen or Grocott Methamine Silver), and/or by cultures, and other granulomas with infection-inflammatory aspect, but without associated infections as eosinophylic necrosis or basophilic necrosis [83], as is Wegener’s granulomatosis, and less commonly rheumatoid nodule, necrotizing sarcoid granulomatosis, infarct and lymphomatoid granulomatosis [83]. The granulomas with eosinophilic necrosis have regular rounded contour, the rim being formed of epithelioid histiocytes with multinucleated giant cells, and the center may have coagulative type of necrosis, which is like an infarct. The Wegener’s granulomatosis is characterized by ‘dirty’ basophilic necrosis with irregular geographic necrosis; the necrosis is rimmed by palisading histiocytes and scattered multinucleated giant cells, with hyperchromatic nuclei and peripheral to the necrosis is the necrotizing vasculitis in vessels. The vessels display transmural fibrinoid necrosis, and the necrosis of the media with admixed necrotic neutrophils, which contributes to the diagnosis with true necrotizing vasculitis. The granuloma of the Romanian case has multiple normal vessels. The parenchymal necrosis of the necrotizing

Characteristic	“Idiopathic” granulomatous mastitis	Tubercular mastitis
Macroscopic characteristic		
Isolated or multiple breast masses	Common	Common
Multiple sinuses or fistulas	Absent	Present
Abscess	Common	Uncommon
Focal discoloration of areola	Absent	Present
Microscopic characteristic		
Structure affected	Mammary lobules from one breast, rarely bilateral	All mammary structures: ducts, lobules, fat, commonly bilateral
Type of lesion	Granulomas of the lobules	Granulomas of all mammary structures
Histological components of breast’s granulomas	Epithelioid histiocytes, Langhans giant cells, lymphocytes, plasma cells, and occasionally eosinophils	Epithelioid histiocytes, Langhans giant cells, lymphocytes, rare plasma cells, and eosinophils
Foamy cells	Absent	Present
Caseating necrosis	Absent	Present
Fibrosis	Present	Present
Fat necrosis	Present	Present

Table 2. Macroscopic and microscopic characteristics of “idiopathic” granulomatous mastitis and tubercular mastitis (modified from Akcan et al. [114]; Baslaim et al. [115]; Bahoroon [107]; Lacambra et al. [109]).

sarcoid granulomatosis is variable, usually eosinophilic but can be irregular and basophilic, mimicking Wegener's granulomatosis.

The pathological characteristics of the "idiopathic" lobular non-caseating granulomas and of tuberculosis caseating granuloma of the breast are listed in **Table 2**, and it is considered [83] that no single histological feature may distinguish infectious necrotizing granulomas from other specific disorder as Wegener's granulomatosis or sarcoidosis, being necessary a combination of multiple pathological features to establish the specific diagnosis.

The first reported case of this chapter is a primary breast TB, with no personal history, or other focus on the systemic physical/radiological examinations for TB. The diagnosis of breast TB must follow the general principles: clinical and laboratory. The clinical presentation of breast TB is variable regarding symptoms/signs: swelling of the breast—48.1% [10]; painless hard lump—approximately 60% cases, or pain is revealed as the first complain of some patients [67, 68] or up to 18.5% of cases [10]; rarely are recorded multiple lumps, with irregular borders, sometimes with skin fixation or areola fixation, or to the underlying muscle or even chest wall, clinical findings imposing differential to breast carcinoma [69], situation which is much more suggested by the presence of an isolated breast mass, sometimes skin fixated—"peau d'orange" sign, and without an associated sinus tract; ulceration of areola [117], or of the skin covering the mammary gland [118]; abscess, unique or multiples [85]; skin thickening and skin sinus/fistula/multiple discharge sinuses [70], nipple retraction or inversion, nipple hyperpigmentation or focal discoloration—when the disease is long time duration [69], or destruction of nipple-areola region [19], breast shape and sizes are changed, axillary lymphadenopathy (axillary lymph nodes are found in one-third of cases with breast TB). Constitutional symptoms as fever, weight loss, night sweats or a failing of general health are infrequently encountered [71, 72].

5.4.2. Pathological diagnosis of cervical tuberculosis

The cervical tuberculosis diagnosis is commonly established by the Papanicolaou smear without any dysplasia, positivity for acid-fast bacilli, and the cervical biopsy (punch, loop excision biopsy) showing granulomatous inflammation with caseous necrosis, facts that were absent in the Romanian case. The presence of the viral infection is clearly proved by genotyping of the cervix after surgery. The endocervical curettage which has the possibility to diagnose associated endocervical tuberculosis was not done, because they believe that exocervical lesion was the only cause of abnormal bleeding. The pulmonary tuberculosis was 7 years previously registered, and the genital location was diagnosed in the endocervical glands, on the specimen collected at hysterectomy—after radiotherapy and chemotherapy. The presence of the endocervical tubercle bacillus was indirectly diagnosed by the pathologic examination the presence of caseous necrosis and Langhans multinuclear giant cells, and by PCR for *MbT*. The diagnosis of TB depends also upon the isolation of the *MbT* on microscopy, and culture, and by the PCR. Culture of *MbT* and acid-fast staining was not done, the cervical granulomas were noted at pathological examination after surgery, on a formalin-fixed specimen. The presence of characteristic, typical caseous granuloma was appreciated sufficient to make the diagnosis [77, 119], but many researchers consider that it

is very important to distinguish between the granulomatous reaction and tuberculosis by more specific methods [120]. The presence of stroma caseous necrosis was sufficient for the positive diagnosis of cervical TB in the Romanian authors' opinion. The granuloma diagnosis is a microscopic diagnosis. The microscopy of the cervical specimen after radical hysterectomy reveals an aggregate of immune cells, appearing as epithelioid macrophages, and if a foreign body or a parasite is not observed inside the granuloma, stains for acid-fast bacilli, and fungi are ordered as mycobacteria and fungi (such as *Cryptococcus*, *Blastomyces*, *Coccidioides* and *Aspergillus* can be seen on hematoxyline-eosine, preferentially in the area of necrosis rather than the surrounding viable area) are frequently the cause of this type of inflammation [31]. In cases with samples fixed in formalin the detection of the infectious agent is recommended to be done by molecular analysis, PCR for *MbT* in the Romanian case [91, 118].

5.5. Imaging diagnosis of rare tuberculosis locations

5.5.1. Radiological imaging of breast tuberculosis

Radiological imaging of breast tuberculosis is appreciated not to be diagnostic, and the described mammographic images are in connection to three patterns of breast tuberculosis: nodular, disseminated and sclerosing patterns [121]. Some radiological characteristics are common for all patterns, like the change in shape, and outline of the breast mass—seen in the standard views, the reduction in size of the affected breast, skin thickening, nipple retraction and ill-defined breast mass [122]. In previous radiological studies, the skin bulge and sinus tract sign, which connects the breast density to a localized skin thickening or to the skin bulge are the radiological features strongly suggestive for tubercular breast abscess [66].

In the Romanian case, the mammography was not recommended, because authors thinking was dominated by a chronic inflammation with repeated episodes of recurrence, as a granulomatous mastitis or a plasma cell mastitis.

Some clinicians [123] recommend computed tomography scan, when are doubtful cases, for the differentiation of primary and secondary lesions, to evaluate accompanying pulmonary disease, if it is present or to detect the continuity of the breast lesions with the thoracic wall or pleura, and associated lesions of the lungs.

5.5.2. Ultrasonography for breast tuberculosis

In the literature, there are controversies about the value of ultrasonography for breast TB diagnosis. On one side, it is mentioned no specificity of the ultrasound examination [121]: the breasts' lesions may appear as heterogeneous, hypoechoic, irregularly or ill-bordered masses of different sizes, but usually small sizes, with internal echoes or thick-walled cystic lesions, some mass may present posterior acoustic enhancement, in association to the fistula formation, and the thickening of Cooper's ligaments and subcutaneous tissues, as it was revealed in the Romanian case. On the other side, it is mentioned an unique finding strongly suggestive for breast TB: the presence of a dense sinus tract connecting an ill-defined breast mass to localized skin thickening and bulge [14].

Regarding the vascularisation of the breast tubercular masses, the blood flow was not observed within the lesions, while increased circumferential vascularization was seen in the color Doppler ultrasound, and the spectral evaluation shows a low resistance monophasic flow pattern [121].

5.5.3. Magnetic resonance imaging (MRI) for breast/cervix uteri tuberculosis diagnosis

If on recommend MRI imaging for breast TB, it is possible to detect parenchymal asymmetry with enhancement, micro-abscesses, and peripherally enhanced masses. MRI may reveal lymphadenopathy along the pelvic walls, with an abnormal signal to the entire body of the uterus and sometimes when the entire uterus is infected by *MbT*, the endometrial cavity, myometrium, and junctional zone could not be differentiated and thus the radiological appearance was consistent with Asherman's syndrome [77].

5.6. Antitubercular therapeutic test for rare location tuberculosis diagnosis

There are cases with pulmonary and extrapulmonary TB with negative molecular test—PCR for *MbT* from clinical specimens or it is not possible to recommend and use the rapid very efficient modern molecular NAA for detection of mycobacterial DNA or RNA directly from the specimens as it was previously discussed. In countries with endemic TB, it is since long time discussed and recently it is recalled an empirical antitubercular therapy even in the absence of positive acid-fast bacilli, and without culture—positive results, or when it is the suspicion of TB or when the “idiopathic” granulomatous mastitis is found and it is not responding to metothrexate or corticosteroids [108, 117].

TB is considered to be actually under-diagnosed in Romania, and the Romanian health history had a similar management in cases which are mentioned before, and in these conditions, the final diagnosis of the case with primary recurrent non-gestational breast abscess was done after the antitubercular “therapeutic” test, which was efficient after the first two months. More details are in the subsection 8 on “Treatment”.

6. Differential diagnosis

6.1. Differentials for breast tuberculosis

The breast tuberculosis can be confused with breast carcinoma, specially in elder women [27, 28, 69, 124], who present an isolated ill defined, irregular, occasionally hard breast lump without sinuses/fistula, but pain is present more frequently in the tuberculous lump than in carcinoma. Involvement of the nipple and areola is rare in tuberculosis, but fixation of the lump to the skin may be present as a part of the inflammatory process, which is present in both pathological entities. A high index of suspicion needs to be maintained if a breast lump is associated with a sinus or indolent lump in an immigrant women if this is encountered in the western countries. The coexistence of tubercular axillary lymphadenitis with breast carcinoma can falsely over-stage the disease [125], and is reported an association of the metastasis of

breast carcinoma and axillary tuberculous lymphadenitis [126]. In postmenopausal women is considered that the diagnosis of breast TB does not exclude a concomitant cancer [3], situation that was first reported by Pilliet and Piatot in (cited by [27]).

In cases with discharging sinuses associated to a breast lump it is necessary to make the differentiation from actinomycosis by the absence of sulfur granules in the discharge and by fungal culture [9].

For women from countries with endemic tuberculosis from Asia and Africa, or immigrated from that countries, the association of breast carcinoma and tuberculosis must be thought, specially when the data are confusing [3, 127, 128], as it is when on records tuberculosis of axillary lymph nodes with primary breast cancer [129], or axillary lymph nodes with granulomas and a breast carcinoma [72, 130].

Beside carcinoma there are other misdiagnosis risks as “idiopathic” granulomatous mastitis (**Table 2**, for pathological differential), or plasma cell mastitis (which may mimic histological the tuberculosis by the presence of foreign body giant cells, epithelioid cells which are arranged in tubercles, besides plasma cells, polymorphs, lymphocytes and few foamy macrophages, but is missing the caseation which makes the differential from tuberculosis- [131], lupus mastitis [132], eritema nodosus [133].

In the last years there are described recurrent breast abscess to be more frequent due to non-tuberculous mycobacterial infection [20, 134], cases with similar clinical presentation, with granulomas.

6.2. Differentials for cervix uteri tuberculosis

When women's complaints are present, and cervical examination shows cervical changes it is considered to think about both pathologies, separately or associated in countries with high risks for these pathologies. There are discussed other viral cervical infections as HIV, herpes virus simplex, other sexual transmitted (*Treponema pallidum*, *Trichomonas vaginalis*, *Neisseria gonorrhea*) or parasitic diseases as schistosomal, amoebic, brucella, tularaemia which may induce chronic cervical granulomas, sarcoidosis, and foreign body reaction [77], or more rare an epithelioid granulomas in Hodgkin's disease [39].

7. Complications of breast/cervix uteri tuberculosis

When not adequate treated, TB mastitis is followed by abscesses, which can penetrate the retromammary space [135], or to the ribs [136], formation of sinuses, and nipple retraction, and irreversible inversion, recurrences even with surgical drainage/excision, and breast mutilation [26].

In the case with the association of two severe immunosuppressive diseases as tuberculosis and cancer there are risks for reactivating the lung tuberculosis, for lung metastases from cervical cancer, and of high mortality in patients with coexistent disease [137, 138].

8. Treatment of breast/cervix uteri tuberculosis

Treatment may cure the disease with antitubercular drugs, and surgery is rarely required, being used in cases resistant to medical treatment. The specific antitubercular treatment was delayed in the Romanian case with breast abscess as is frequently mentioned in literature [24], because the difficulties of the positive and differential diagnosis, and because tuberculosis is under-diagnosis in contemporary Romania, but the attitude regarding tuberculosis was similar in the Romanian health history to that from tuberculosis endemic countries: to recommend empirical antitubercular therapy even in the absence of positive AFB, and without positive culture results, when it is a suspicion of TB or when the granuloma is found. In many cases, the decision for the antitubercular treatment is taken after the failure of corticoids and methotrexate therapy for “idiopathic” granulomatous mastitis [108, 117, 139].

Based on patient profile, clinical features and lack of response to usual antibiotic therapy, it is recommended a four-drug (isoniazid, rifampin, ethambutol and pyrazinamide) 6-month course of Directly Observed Therapy Short-Term (DOTS) - Category I [117], but the response to treatment is variable and not dramatic. There are reported excellent results with such management [101].

There are no specific available guidelines for chemotherapy of breast TB, and the therapy generally follows guidelines that are used for pulmonary TB. The regimen consists of a 2 month intensive phase (isoniazid, rifampicin, pyrazinamide and ethambutol), followed by a 4 month continuation phase (isoniazid and rifampin). It is recommended another regimen with extension of continuation therapy for a longer period to 7 months [9, 140–142] or more up to 12–18 months [140], because the wish to lower the relapse rate. There is also a regimen which combines first and second lines antitubercular drugs, including kanamycin, ofloxacin, ethionamide, para-amino salicylic acid (PAS), pyrazinamide and isoniazid, with the reason of the risk of multidrug resistant strains [143]. The breast lesions and tenderness are steadily improved after 2 months of intensive therapy the breast lesions and tenderness are steadily improved [83] (Table 3).

Treatment duration	Initial phase treatment (intensive therapy)	Continuation treatment
6 months*	2 months of: 300 mg isoniazid, 600 mg rifampin, 1500 mg pyrazinamide, 1000 mg ethambutol or streptomycin 1 g per day	4 months of isoniazid, rifampin
9 months**	2 months of: 300 mg isoniazid, 600 mg rifampin, 1500 mg pyrazinamide, 1000 mg ethambutol per day	7 months of isoniazid, rifampin

*Al-Marri et al. [122]; Jalali et al. [102]; Mirsaeidi et al. [6], Bahoroon [107]; Gon et al. [28]; Singal, et al. [13].

**Daali et al. [141]; Khanna et al. [9]; Kumar et al. [143].

Table 3. Breast antitubercular regimens.

In the Romanian primary recurrent non-gestational breast abscess was recalled as the old concept of the “antitubercular therapeutic” test, for the final diagnosis and it was proved to be efficient after the first 2 months, and the association of isoniazid and rifampin was continued with excellent results up to 9 months.

Surgery was imposed in the Romanian case because of abscess complications in the conditions of *MbT* late diagnosis. It was a minimal surgical intervention required for drainage and excision biopsy of abscesses' wall. Surgery is commonly reserved for selected cases, in particular situations, and in different manner:

- According to the presence of breast masses/lump and abscesses with fistula: simple or segmental mastectomy or quadrantectomy or drainage of abscess with large excision of the necrotic tissue of the breast and excision of the axillary lymph nodes when involved [25].
- Breast abscesses with negative bacteriological tests in order to diagnose by excision biopsy of the abscess wall and drainage of abscess with fistula [16, 21, 67].
- In cases refractory to medication [69].
- Residual lumps after antitubercular therapy, excision of sinus [9, 10].
- Mastectomy when is severe breast destruction [14].

A special mention is for the percutaneous treatment with drainage controlled by CT and specific antibiotic antitubercular drugs [123], especially when resistance to ATT is discovered [144], as it is done for pulmonary TB and for abdominal collections [145].

The ATT are usually recommended for cervix uteri tuberculosis for minimum 6 months [146], healing being proved by repeated biopsy. The chemo and radiotherapy, and the radical surgical intervention done in the Romanian case were imposed by the initial diagnosis of squamous non-keratinized cervical carcinoma stage IB, tubercular cervicitis being a postoperative surprise, and it was decided to avoid a new cure of AAT because the postoperative assessments for *MbT* lung or general reactivation were negative.

9. Conclusions

- Breast tuberculosis should be considered as a differential diagnosis of breast inflammatory disease or masses, all over the world, not only where tuberculosis is endemic.
- Tuberculosis must be suspected in recurrent breast inflammatory disease with negative current cultures, and negative tests as Ziehl-Neelsen stain, culture and PCR for *MbT*.
- The pathologic examination of the open biopsy in the reported case is suggesting the diagnosis of a granulomatous mastitis, and the multinuclear giant cells of Langhans type presence ensure the diagnosis of tubercular granulomatous mastitis even in the absence of the characteristic caseous necrosis.

- The final diagnosis of breast TB was established by specific antitubercular drugs, which represents a Tuberculosis Diagnosis Test, and may avoid or delay breast characteristic mutilations when treatment is not adequate.
- The cervix uteri tuberculosis presence and its association to ecto/endocervical cancer is to be suspected not only in developing countries with endemic tuberculosis and high rates of HPV/HIV infections, in patients with primary lung/other organs tuberculosis.

Author details

Manuela Cristina Russu^{1*}, Șerban Nastasia², Daniela Degeratu³ and Ruxandra Viorica Stănculescu⁴

*Address all correspondence to: manuela_russu@yahoo.com

1 “Dr. I. Cantacuzino” Clinical Hospital, “Carol Davila” University of Medicine and Pharmacy, Bucharest, Romania

2 “Dr. I. Cantacuzino” Clinic of Obstetrics and Gynaecology, “Carol Davila” University of Medicine and Pharmacy, Bucharest, Romania

3 “Dr. I. Cantacuzino” Laboratory of Pathology, Bucharest, Romania

4 Department of Pathological Obstetrics, Emergency “St Pantelimon” Clinical Hospital, “Carol Davila” University of Medicine and Pharmacy, Bucharest, Romania

References

- [1] World Health Organization. Global Tuberculosis Report 2017. Geneva, Switzerland: Licence CCBY-NC-SA0IGO. Available from: <http://apps.who.int/iris>
- [2] Prezzemolo T, Guggino G, Pio La Manna M, Di Liberto D, Dieli F, Caccamo N. Functional signatures of human CD4 and CD8 T cell responses to *Mycobacterium tuberculosis*. *Frontiers in Immunology*. 2014;5:180
- [3] Bouti K, Soualhi M, Marc K, Zahraoui R, Benamor J, Bourkadi E, Iraqi G. Postmenopausal breast tuberculosis – Report of 4 cases. *Breast Care (Basel)*. 2012;7(5):411-413
- [4] Micha JP, Brown JV 3rd, Birk C, Van Horn D, Retenmaier MA, Golstein BH. Tuberculosis mimicking cervical carcinoma-case report. *European Journal of Obstetrics & Gynecology*. 2007;28(4):316-318
- [5] Agrawal S, Madan M, Leekha N, Raghunandan C. A rare case of cervical tuberculosis simulating carcinoma cervix. *Cases Journal*. 2009;2:161
- [6] Mirsaeidi SM, Masjedi MR, Mansouri SD, Velayati AA. Tuberculosis of the breast: Report of 4 clinical cases and literature review. *Eastern Mediterranean Health Journal*. 2007;13(3):670-676

- [7] Tewari M, Shukla HS. Breast tuberculosis: Diagnosis, clinical features, and management. *The Indian Journal of Medical Research*. 2005;**122**:103-110
- [8] Al-Marri MR, Almosleh A, Almoslmani Y. Primary tuberculosis of the breast in Qatar: Ten year experience and review of the literature. *The European Journal of Surgery*. 2000;**166**:687-690
- [9] Khanna R, Prasanna GV, Gupta P, Kumar M, Khanna S, Khanna AK. Mammary tuberculosis: Report on 52 cases. *Postgraduate Medical Journal*. 2002;**78**(921):422-424
- [10] Tanrikulu AC, Abakay A, Abakay O, Kapan M. Breast tuberculosis in Southeast Turkey: Report of 27 cases. *Breast Care (Basel)*. 2010;**5**(3):154-157
- [11] Kant S, Dua R, Goel MM. Bilateral tubercular mastitis: A case report. *Lung India*. 2007;**24**:90-93
- [12] Ruiz-Moreno JL, Peña-Santos G. Bilateral tuberculous mastitis nulliparous patient, initially treated as idiopathic granulomatous mastitis. *Ginecología y Obstetricia de México*. 2012;**80**(3):228-231
- [13] Singal R, Bala J, Gupta S, Goyal S, Mahajan NC, Chawla A. Primary breast tuberculosis presenting as a lump: A rare modern disease. *Annals of Medical and Health Sciences Research*. 2013;**3**(1):110-112. DOI: 10.4103/2141-9248.109470
- [14] Bani Hani KE, Yaghan RJ, Matalka IL, Mazahrish TS. Tuberculous mastitis: A disease not to be forgotten. *The International Journal of Tuberculosis and Lung Disease*. 2005;**9**(8):920-925
- [15] Chellaoui M, Taleb A, Chat L, Achaabane E, Alami D, Najid A, Benamour-Ammar H. Tuberculosis of the breast: A case report. *Journal de Radiologie*. 2002;**83**(6 Pt 1):742-744
- [16] Gupta R, Singal R, Gupta A, Singal S, Shahi S, Singal R. Primary tubercular abscess of the breast-an unusual entity. *Journal of Medicine and Life*. 2012;**5**:98-100
- [17] Jaideep C, Kumar M, Khanna AK. Male breast tuberculosis. *Postgraduate Medical Journal*. 1997;**73**:428-429. DOI: 10.1136/pgmj.73.861.428
- [18] Brown S, Thekkinkattil KD. Tuberculous cold abscess of breast: An unusual presentation in a male patient. *Gland Surgery*. 2016 Jun;**5**(3):361-365. DOI: 10.21037/g.s.2016.01.02
- [19] Rimmer J, Hamilton S, Gault D. Recurrent mycobacterial breast abscesses complicating reconstruction. *British Journal of Plastic Surgery*. 2004;**57**(7):676-678
- [20] Atallah D, El Kassis N, Araj G, Nasr M, Nasnas R, Veziris N, Sarkis D. Mycobacterial infection of breast prosthesis—a conservative treatment: A case report. *BMC Infectious Diseases*. 2014;**14**:238
- [21] Gupta PP, Gupta KB, Yadav RK, Agarwal D. Tuberculous mastitis. A review of seven consecutive cases. *The Indian Journal of Tuberculosis*. 2003;**50**:47-50
- [22] Chowdhury NNR. Overview of tuberculosis of the female genital tract. *Journal of the Indian Medical Association*. 1996;**94**:345-361

- [23] Carter JR. Unusual presentations of genital tract tuberculosis. *International Journal of Gynaecology and Obstetrics*. 1990;**33**:171-176
- [24] Lin TL, Chi SY, Liu JW, Chou FF. Tuberculosis of the breast: 10 years' experience in one institution. *The International Journal of Tuberculosis and Lung Disease*. 2010;**14**(6):758-763
- [25] Daryanani A, Sundeep P, Rodrigues G, Kumar S, Kudva R. Tuberculosis mastitis masquerading as carcinoma breast. *The internet. Journal of Tropical Medicine*. 2002;**1**(2)
- [26] Chowdri NA, Parray FQ, Dar RA, Malik AA, Mushtaque M, Malik RA. Tubercular mastitis – A rare presentation. *International Journal of Surgery*. 2010;**8**(5):398-400
- [27] Morino GF, Rizzardi G, Gobbi F, Baldan M. Breast tuberculosis mimicking other diseases. *Tropical Doctor*. 2007;**37**(3):177-178
- [28] Gon S, Bhattacharyya A, Majumdar B, Kundu S. Tubercular mastitis - a great masquerader. *Turkish Journal of Pathology*. 2013;**29**(1):61-63
- [29] Kaewseekhao B, Naranbhai V, Rovtrakul S, Namwat W, Paemance A, Lulitanond V, Chaiprasert A, Faksri K. Comparative proteomics of activated THP-1 cells infected with *Mycobacterium tuberculosis* identifies putative clearance biomarkers for tuberculosis treatment. *PLoS One*. 2015;**10**(7):e0134168. Published online 2015 Jul 27. DOI: 10.1371/journal.pone.0134168
- [30] Yanamandra U, Pathak N, Naithani N, Grover N, Nair V. Tuberculosis of breast: Unusual manifestation of tuberculosis. *Journal of Infection and Chemotherapy*. 2011;**18**(1):109-111. DOI: 10.1007/s10156-011-0296-0. Epub 2011 Aug 31
- [31] Banerjee SN, Ananthakrishnan N, Mehta RB, et al. Tuberculous mastitis: A continuing problem. *World Journal of Surgery*. 1987;**11**:105-109. DOI: 10.1007/BF01658471
- [32] Shinde SR, Chandawarkar RY, Deshmukh SP. Tuberculosis of the breast masquerading as carcinoma: A study of 100 patients. *World Journal of Surgery*. 1995;**19**:379-381. DOI: 10.1007/BF00299163
- [33] Mehta G, Mittal A, Verma S. Breast tuberculosis-clinical spectrum and management. *The Indian Journal of Surgery*. 2010;**72**:433-437. DOI: 10.1007/s12262-010-0166-5
- [34] James DG. A clinicopathological classification of granulomatous disorders. *Postgraduate Medical Journal*. 2000;**76**:457-465
- [35] Zhao FH, Varanasi AP, Cunningham CA, Graubars DI, Hu SY, Chen F, Barrett CJ, Qiao YL, Forman MR. Tuberculosis and oncogenic HPV: Potential co-infections in women at high-risk of cervical cancer in rural China. *Asian Pacific Journal of Cancer Prevention*. 2011;**12**(6):1409-1415
- [36] Richards MJ, Angus D. Possible sexual transmission of genitourinary tuberculosis. *International Journal of Tuberculosis and Lung Disease (IJTLD)*. 1998;**2**:439
- [37] Luchian N, Dobreanu N, Cordon Tăărăbuță G, Costăchescu G. Considerations on 2 cases of association between cancer and tuberculosis of the uterine cervix. *Revista Medico-Chirurgicală a Societății de Medici și Naturaliști din Iași*. 1967;**71**:1025-1028

- [38] Sabilinska B, Szufladowicz R. Tuberculosis of the cervix uteri after radiation therapy of uterine cervix cancer. *Ginekologia Polska*. 1971;**43**(1):85-87
- [39] O'Connell MJ, Schimpff SC, Kirschner RH, Abt AB, Wiernik PH. Epithelioid granulomas in Hodgkin's disease. *JAMA*. 1975;**233**:886-889
- [40] Dannenberg AM Jr. Roles of cytotoxic delayed-type hypersensitivity and macrophage-activating cell-mediated immunity in the pathogenesis of tuberculosis. *Immunobiology*. 1994;**191**(4-5):461-473
- [41] Steben M, Duarte-Franco E. Human papillomavirus infection: Epidemiology and pathophysiology. *Gynecologic Oncology*. 2007;**107**:S2-S5
- [42] Scott M, Nakagawa M, Moscicki A-B. Cell-mediated immune response to human papillomavirus infection. *Clinical and Diagnostic Laboratory Immunology*. 2001;**8**(2):209-220
- [43] Stanley M. HPV-immune response to infection and vaccination. *Infectious Agents and Cancer*. 2010;**5**(1):19 <http://www.infectagentscancer.com/content/5/1/19>
- [44] Bais AG, Beckmann I, Lindemans J, Ewing PC, Meijer CJLM, Snijders PJF, Helmerhorst TJM. A shift to a peripheral Th2-type cytokine pattern during the carcinogenesis of cervical cancer becomes manifest in CIN III lesions. *Journal of Clinical Pathology*. 2005;**58**:1096-1100
- [45] Hu T, Yang P, Zhu H, Chen X, Xie X, Yang M, Liu S. Accumulation of invariant NKT cells with increased IFN- γ production in persistent high-risk HPV-infected high-grade cervical intraepithelial neoplasia. *Diagnostic Pathology*. 2015;**10**:20. DOI: 10.1186/s13000-015-0254-8
- [46] Spellberg B, Edwards JE. Type1/type 2 immunity in infectious diseases. *Clinical Infectious Diseases*. 2001;**32**:76-102
- [47] Satam MN, Suraiya JN, Nadkarni JJ. Natural killer and antibody-dependent cellular cytotoxicity in cervical carcinoma patient. *Cancer Immunology, Immunotherapy*. 1986;**23**:56-59
- [48] Woodworth CD, Simpson S. Comparative lymphokine secretion by cultured normal human cervical keratinocytes, papillomavirus-immortalized, and carcinoma cell lines. *The American Journal of Pathology*. 1993;**142**:1544-1555
- [49] Schröder JM. Cytokine networks in the skin. *Journal of Investigative Dermatology*. 1995;**105**:20S-24S
- [50] Witkin SS, Giraldo P, Linhares I, Ledger WJ. Individual immunity and susceptibility to female genital tract infection. *American Journal of Obstetrics and Gynecology*. 2000;**183**: 252-256
- [51] Banks L, Moreau F, Vousden K, et al. Expression of the human papillomavirus E7 oncogene during cell transformation is sufficient to induce susceptibility to lysis by activated macrophages. *Journal of Immunology*. 1991;**146**:2037-2042
- [52] Barnard P, McMillan NA. The human papillomavirus E7 oncoprotein abrogates signaling mediated by interferon-alpha. *Virology*. 1999;**259**:305-313

- [53] Hohn H, Pilch H, Gunzel S, Neukirch C, Hilmes C, Kaufmann A, Seliger B, Maeurer MJ. CD4⁺ tumor-infiltrating lymphocytes in cervical cancer recognize HLA-DR-restricted peptides provided by human papillomavirus-E7. *Journal of Immunology*. 1999;**163**:5715-5722
- [54] Da Silva CS, Michelin MA, Etchehere RM, Adad SJ, Murta FC, et al. Local lymphocytes and nitric oxide synthase in the uterine cervical stroma of patients with grade III cervical intraepithelial neoplasia. *Clinics (São Paulo, Brazil)*. 2010;**65**(6):575-581
- [55] Parr MB, Parr EL. Mucosal immunity in the female and male reproductive tract. In: Ogra PL et al., editors. *Handbook of Mucosal Immunology*. San Diego: Academy Press; 1996. pp. 677-689
- [56] Stanley M, Coleman N, Chamberst M. The Host Response to Lesions Induced by Human Papillomavirus. *Vaccine against Virally Induced Cancers*. Vol. 187. Wiley, Chichester: Ciba Foundation Symposium; 1994. pp. 21-44
- [57] Ben-Baruch A. Inflammation-associated immune suppression in cancer: The roles played by cytokines, chemokines and additional mediators. *Seminars in Cancer Biology*. 2006;**16**:38-52
- [58] Dall KL, Scarpini CG, Roberts I, Winder DM, Stanley MA, et al. Characterization of naturally occurring HPV16 integration sites isolated from cervical keratinocytes under noncompetitive conditions. *Cancer Research*. 2008;**68**:8249-8259
- [59] Zur Hausen H. Condylomata acuminata and human genital cancer. *Cancer Research*. 1976;**36**:794
- [60] Gurumurthy S, Hezel AF, Berger JH, Bosenberg MW, Bardeesy N. LKB1 deficiency sensitizes mice to carcinogen-induced tumorigenesis. *Cancer Research*. 2008;**68**:55-63
- [61] Hezel AF, Bardeesy N. LKB1; linking cell structure and tumor suppression. *Oncogene*. 2008;**27**:6908-6919
- [62] Wingo SN, Gallardo TD, Akbay EA, Liang M-C, Contreras CM, Castrillon D. Somatic LKB1 mutations promote cervical cancer progression. *PLoS One*. 2009;**4**(4):e5137
- [63] Esteller M, Avizienyte E, Corn PG, Lothe RA, Baylin SB, et al. Epigenetic inactivation of LKB1 in primary tumors associated with the Peutz-Jeghers syndrome. *Oncogene*. 2000;**19**:164-168
- [64] Ji H, Ramsey MR, Hayes DN, Fan C, McNamara K, et al. LKB1 modulates lung cancer differentiation and metastasis. *Nature*. 2007;**448**:807-810
- [65] Tanrikulu AC, Abakay A, Abakay O, Kapan M. Breast tuberculosis in Southeast Turkey: Report of 27 cases. *Breast Care (Basel)*. 2010;**5**(3):154-157. Epub 2010 May 11
- [66] Mankanjuola D, Murshid K, Al Sulaimani S, Al Saleh M. Mammographic features of breast tuberculosis: The skin bulge and sinus tract sign. *Clinical Radiology*. 1996;**51**(5):354-358
- [67] Harris SH, Khan MA, Khan R, Haque F, Sved A, Ansari MM. Mammary tuberculosis: Analysis of thirty-eight patients. *ANZ Journal of Surgery*. 2006;**76**(4):234-237. DOI: 10.1111/j.1445-2197.2006.03692

- [68] Khodabakhshi B, Mehravar F. Breast tuberculosis in Northeast Iran: Review of 22 cases. *BMC Womens Health*. 2014;**14**:72
- [69] Maroulis I, Spyropoulos C, Zolota V, Tzorakoleftherakic E. Mammary tuberculosis mimicking breast cancer: A case report. *Journal of Medical Case Reports*. 2008;**2**:34
- [70] Singal R, Dalal AK, Dalal U, Attri AK. Primary tuberculosis of the breast presented as multiple discharge sinuses. *The Indian Journal of Surgery*. 2013;**75**:66-67
- [71] Akçay MN, Saglam L, Polat P, Erdogan F, Albayrak Y, Povoski SP. Mammary tuberculosis – Importance of recognition and differentiation from that of a breast malignancy: Report of three cases and review of the literature. *World J. Surgical Oncology*. 2007;**5**:67
- [72] Alzaara A, Dalal N. Co-existence of carcinoma in tuberculosis in one breast. *World Journal of Surgical Oncology*. 2008;**6**:29
- [73] Singhal SR, Chaudhry P, Nanda S. Genital tuberculosis with predominant involvement of cervix: A case report. *Clinical Reviews and Opinions*. 2011;**3**(5):55-56
- [74] Wadhwa N, Singh UR, Saith SA. Report of two unsuspected cases of cervical tuberculosis. *Indian Journal of Pathology & Microbiology*. 2005;**3**:390-392
- [75] Jyotima A, Gupta JK. Female genital tuberculosis: A retrospective clinicopathologic study of 501 cases. *Indian Journal of Pathology & Microbiology*. 1993;**4**:389-397
- [76] Chakraborty P, Roy A, Bhattacharya S, Addhya S, Mukherjee S. Tuberculous cervicitis: A clinicopathological and bacteriological study. *Journal of the Indian Medical Association*. 1995;**5**:167-168
- [77] Lamba H, Byrne M, Goldin R, Jenkins C. Tuberculosis of the cervix: Case presentation and a review of the literature. *Sexually Transmitted Infections*. 2002;**78**:62-63
- [78] Sinha R, Gupta D, Tuli N. Genital tract tuberculosis with myometrial involvement. *International Journal of Gynaecology and Obstetrics*. 1997;**57**:191-192
- [79] Sachan R, Patel ML, Gupta P, Verma AK. Genital tuberculosis with variable presentation: A series of three cases. *MI Case Report*. 2012:bcr2012006665. DOI: 10.1136/bcr-2012-006665
- [80] Akhlaghi F, Hamed AB. Postmenopausal tuberculosis of the cervix, vagina and vulva. *International Journal of Gynecology & Obstetrics*. 2004;**3** Online publication
- [81] Morsad F, Ghazli M, Boumzgou K, et al. Mammary tuberculosis: A series of 14 cases. *Journal de Gynecologie, Obstetrique et Biologie de la Reproduction (Paris)*. 2001;**30**:331-337
- [82] Woodard BH, Rosenberg SI, Farham R, et al. Incidence and nature of primary granulomatous inflammation in surgically removed material. *The American Journal of Surgical Pathology*. 1982;**6**:119-129
- [83] Aubry MC. Necrotizing granulomatous inflammation: What does it mean if your special stains are negative? *Modern Pathology*. 2012;**25**(Suppl 1):S31-S38
- [84] Ulbright TM, Katzenstein AA. Solitary necrotizing granulomas on the lung. *The American Journal of Surgical Pathology*. 1980;**4**:13-28

- [85] Tauro LF, Martis JS, George C, Kamath A, Lobo G, Hegde BR. Tuberculous mastitis presenting as breast abscess. *Oman Medical Journal*. 2011;**26**:53-55
- [86] She CR, Litwin MC. Performance of a tuberculosis serologic assay in various patient populations. *American Journal of Clinical Pathology*. 2015;**144**:240-246
- [87] Soini H, Musser JM. Molecular diagnosis of mycobacteria. *Clinical Chemistry*. 2001;**47**:809-814
- [88] Wiener RS, Della-Latta P, Schluger NW. Effect of nucleic acid amplification for *Mycobacterium tuberculosis* on clinical decision making in suspected extrapulmonary tuberculosis. *Chest*. 2005;**128**:102-107
- [89] Ruiter AM, Vegting IL, Nanayakkara PW. Idiopathic granulomatous mastitis: A great imitator? *MBJ Case Report*. 2010;**03**:28-44
- [90] Park DY, Kim JY, Choi KU, Lee JS, Lee CH, Sol MY, Suh KS. Comparison of polymerase chain reaction with histopathologic features for diagnosis of tuberculosis in formalin-fixed, paraffin-embedded histologic specimens. *Archives of Pathology & Laboratory Medicine*. 2003;**127**(3):326-330
- [91] Buckwalter SP, Wengenack NL. Detection of mycobacteria in paraffin-embedded tissue using lightcycler PCR. *American Society for Microbiology*. 104th General Meeting; New Orleans, LA; 23-27 May, 2004
- [92] Nyendak MR, Lewinsohn DA, Lewinsohn DM. New diagnostic methods for tuberculosis. *Current Opinion in Infectious Diseases*. 2009;**22**:174-182
- [93] Katoch VM. Newer diagnostic techniques for tuberculosis. *The Indian Journal of Medical Research*. 2004;**120**:418-428
- [94] Veziris V. Bacteriological diagnosis of tuberculosis. *La Revue du Praticien*. 2012;**62**(4):490-492
- [95] Pai M, Riley LW, Colford JM Jr. Interferon-gamma assays in the immunodiagnosis of tuberculosis: A systematic review. *The Lancet Infectious Diseases*. 2004;**4**:761
- [96] Taylor GB, Paviour SD, Msaad S, Jones WO, Holland DJ. A clinicopathological review of 34 cases of inflammatory breast disease showing an association between corynebacteria infection and granulomatous mastitis. *Pathology*. 2003;**35**:109-119
- [97] Saichandran S, Vijayan S, Thirunavukkarasu AB, Sankuppa FS, Singh DA. Rare case of cervical tuberculosis which simulated carcinoma of the cervix. *Journal of Clinical and Diagnostic Research*. Jun 2013;**7**(6):1189-1190
- [98] Yu YH, Wei W, Liu JL. Diagnostic value of fine-needle aspiration biopsy for breast mass: A systematic review and meta-analysis. *BMC Cancer*. 2012;**12**:41
- [99] Thompson SK, Donzelli J, Jensen JA, Pachucki C, Eng AM, Reyes VC. Breast and cutaneous mycobacteriosis: Diagnosis by fine-needle aspiration biopsy. *Diagnostic Cytopathology*. 1997;**17**(1):45-49

- [100] Kakkar S, Kapila K, Singh MK, Verma K. Tuberculosis of the breast. A cytomorphologic study. *Acta Cytologica*. 2000;**44**:292-296
- [101] Mehrota R. Fine needle aspiration diagnosis of tuberculous mastitis. *Indian Journal of Pathology & Microbiology*. 2004;**47**(3):377-380
- [102] Jalali U, Rasul S, Khan A, Baig N, Khan A, Akhter R. Tuberculous mastitis. *Journal of the College of Physicians and Surgeons–Pakistan*. 2005;**15**:234-237
- [103] Misch KA, Alison S, Deirdre T, O'Sullivan JC, Onuigbo W. Tuberculosis of the cervix: Cytology as an aid to diagnosis. *Journal of Clinical Pathology*. 1976;**29**:313-316
- [104] Samantaray S, Parida G, Rout N, Giri SK, Kar R. Cytologic detection of tuberculous cervicitis. *Acta Cytologica*. 2009;**5**:594-596
- [105] Kalyani R, Sheela S, Rajini M. Cytological diagnosis of tuberculous cervicitis: A case report with review of literature. *Journal of Cytology*. 2012 Jan;**29**(1):86-88
- [106] McKeown KC, Wilkinson KW. Tuberculosis of the breast. *The British Journal of Surgery*. 1952;**39**:420-429
- [107] Bahoroon S. Tuberculosis of the breast. *Annals of Thoracic Medicine*. 2008;**3**(3):110-114
- [108] Sriram KB, Moffatt D, Stapledon R. Tuberculosis infection of the breast mistaken for granulomatous mastitis: A case report. *Cases Journal*. 2008;**1**:273
- [109] Lacambra M, Thai TA, Lam CC, Tse GM, et al. Granulomatous mastitis: The histological differentials. *Journal of Clinical Pathology*. 2011;**64**:405-411
- [110] Bakaris S, Yuksel M, Ciragil P, Guven A, Ezberci F, Bulbuloglu E. Granulomatous mastitis including breast tuberculosis and idiopathic lobular granulomatous mastitis. *Canadian Journal of Surgery*. 2006;**49**(6):427-430
- [111] Inoue Y, Suga M. Granulomatous disease and pathogenic microorganism. *Kekkaku*. 2008;**83**(2):115-130
- [112] Altintoprak F, Karakece E, Kivilcim T, Dikicier E, Celebi F, Ciftci IH. Clinical study. Idiopathic granulomatous mastitis: An autoimmune disease? *The Scientific World Journal*. 2013;**5**. Article ID 148727. DOI: 10.1155/2013/148727
- [113] Kessler E, Wolloc Y. Granulomatous mastitis: A lesion clinically simulating carcinoma. *American Journal of Clinical Pathology*. 1972;**58**(6):642
- [114] Akcan A, Akyildiz H, Deneme MA, Akgun H, Aritas Y. Granulomatous lobular mastitis: A complex diagnostic and therapeutic problem. *World Journal of Surgery*. 2006;**30**:1403-1409
- [115] Baslaim MM, Khayat HA, Al-Amoudi SA. Idiopathic granulomatous mastitis: A heterogeneous disease with variable clinical presentation. *World Journal of Surgery*. 2007;**31**:1677-1681
- [116] Belaabidia B, Essadki O, el Mansouri A, Squalli S. Idiopathic granulomatous mastitis: Apropos of 8 cases and review of the literature. *Gynécologie, Obstétrique & Fertilité*. 2002;**30**(5):383-389

- [117] De Sousa R, Patil R. Breast tuberculosis or granulomatous mastitis: A diagnostic dilemma. *Annals of Tropical Medicine and Public Health*. 2011;**4**:122-125
- [118] Guarner J. Detection of microorganisms in granulomas that have been formalin-fixed: Review of the literature regarding use of molecular methods. *Scientifica (Cairo)*. 2012;494571
- [119] Falk V, Ludviksson K, Agren G. Genital tuberculosis in women. Analysis of 187 newly diagnosed cases from 47 Swedish hospitals during the ten-year period 1968 to 1977. *American Journal of Obstetrics and Gynecology*. 1980;**138**:974-977
- [120] Carneiro PC, Graudenz MS, Zerbini MC, de Menezes Y, dos Santos LR, Ferraz AR. Granulomatous reaction associated with metastatic epidermoid cancer. The importance of using multiple methods in diagnostic pathology. *Revista do Hospital das Clinicas; Faculdade de Medicina da Universidade de Sao Paulo*. 1989;**44**:29-32
- [121] Kervancioğlu S, Kervancioğlu R, Oźkur A, Sirikçi A. Primary tuberculosis of the breast. *Diagnostic and Interventional Radiology*. 2005;**11**(4):210-212
- [122] Al-Marri MR, Aref E, Omar AJ. Mammographic features of isolated tuberculous mastitis. *Saudi Medical Journal*. 2005;**26**:646-650
- [123] Romero C, Carreira C, Cereceda C, Pinto J, Lopez R, Bolaños F. Mammary tuberculosis: Percutaneous treatment of a mammary tuberculous abscess. *European Radiology*. 2000;**10**(3):531-533
- [124] Khandelwal R, Jam I. Breast tuberculosis mimicking a malignancy falsely over-stage the disease a rare case report with review of literature. *Breast Disease*. 2013;**34**(2):53-55
- [125] Munjal K, Jain KV, Agrawal A, Bandi KP. Co-existing tubercular axillary lymphadenitis with breast carcinoma can falsely over-stage the disease. Case series. *The Indian Journal of Tuberculosis*. 2010;**57**:104-107
- [126] Robinson A, Horne C, Weaver A. Coexistence of axillary tuberculous lymphadenitis with lymph node metastases from a breast carcinoma. *Clinical Oncology*. 2001;**1**(3):144-147
- [127] Tulasi NR, Raju PC, Damodaran V, Randhika TS. A spectrum of coexistent tuberculosis and carcinoma in the breast and axillary lymph nodes: Report of five cases. *Breast*. 2006;**15**(3):437-439
- [128] Balasubramanian SP, Rao MP, Jayaram S, Bose SM. Coexisting mammary tuberculosis and malignant disease. *Canadian Journal of Surgery*. 2001;**44**:224-225
- [129] Fujii T, Kimura M, Yanagita Y, Koida T, Kuwano H. Tuberculosis of axillary lymph nodes with primary breast cancer. *Breast Cancer*. 2003;**10**:175-178
- [130] Khurram M, Tariq M, Shahid P. Breast cancer with associated granulomatous axillary lymphadenitis: A diagnostic and clinical dilemma in regions with high prevalence of tuberculosis. *Pathology, Research and Practice*. 2007;**203**(10):699-704
- [131] Naragam AP, Tati YS, Dara H, Kumar VA, Jada M, Shekhar Y, Dara H, Kawathekar P. Plasma cell mastitis mimicking as carcinoma of the breast: A case report and review of the literature IOSR. *Journal of Dental and Medical Sciences*. 2014;**13**(2):28-31. Ver. III

- [132] Diallo R, Frevel T, Poremba C, Cirkel U, Metze D, Dockhom-Dworniczak B. Lupus vulgaris as the etiology of tuberculous mastitis. *Pathologie*. 1997;**18**(1):67-70
- [133] Kao PT, Tu MY, Tang SH, Ma HK. Tuberculosis of the breast with erythema nodosum: A case report. *Journal of Medical Case Reports*. 2010;**4**:124
- [134] Yoo H, Choi SH, Kim YJ, Cho YU, Choi SJ. Recurrent bilateral breast abscess due to nontuberculous mycobacterial infection. *Journal of Breast Cancer*. 2014;**17**(3):295-298
- [135] Yukawa M, Watatani M, Isona S, Inoue M, et al. Management of granulomatous mastitis: A series of 13 patients who were evaluated for treatment without corticosteroids. *International Surgery*. 2015;**100**(5):774-782
- [136] Challa VR, Srivastava A, Dhar A. Scrofulous swelling of the bosom masquerading as cancer. *Indian Journal of Medical Microbiology*. 2014;**32**(1):82-84
- [137] Inaki J, Rodriguez V, Bodey GP. Causes of death in cancer patients. *Cancer*. 1974;**33**:568-573
- [138] Chen YM, Chao JY, Tsai CM, Lee PY, Perng RP. Shortened survival of lung cancer patients initially presenting with pulmonary tuberculosis. *Japanese Journal of Clinical Oncology*. 1996;**26**:322-327
- [139] Sheybani F, Sarvghad M, Naderi HR, Gharib M. Treatment for and clinical characteristics of granulomatous mastitis. *Obstetrics and Gynecology*. 2015;**125**(4):801-807
- [140] O'Reilly M, Patel KR, Cummins R. Tuberculosis of the breast presenting as carcinoma. *Military Medicine*. 2000;**165**:800-802
- [141] Daali M, Hssaida R, Hda A. Primary tuberculosis of the breast. *Presse Médicale*. 2001;**30**:431-433
- [142] Gupta V, Mohan H, Jain P, Singh S, Singla N. Tuberculous mastitis: A report of two cases in elderly females. *Japanese Journal of Infectious Diseases*. 2006:279-280
- [143] Kumar P, Sharma N. Primary MDR -TB of the breast. *The Indian Journal of Chest Diseases & Allied Sciences*. 2003;**45**:63-65
- [144] Imperiale A, Zandrino F, Calabrese M, Parodi G, Massa T. Abscesses of the breast. US-guided serial percutaneous aspiration and local antibiotic therapy after unsuccessful systemic antibiotic therapy. *Acta Radiologica*. 2001;**42**(2):161-165
- [145] Mehendiratta V, Mccarty BC, Gomez L, Graviss AE, Musher MD. Computerized tomography (CT)-guided aspiration of abscesses. Outcome of therapy at a tertiary care hospital. *Journal of Infection*. 2007;**54**(2):122-128
- [146] Gupta A, Gupta MM, Mankatala U, Khurana N. Primary tuberculosis of cervix mimicking carcinoma: A rare case. *Journal of Mid-life Health*. 2014;(2):96-97. DOI: 10.4103/0976-7800.133999

