

We are IntechOpen, the world's leading publisher of Open Access books Built by scientists, for scientists

6,900

Open access books available

186,000

International authors and editors

200M

Downloads

Our authors are among the

154

Countries delivered to

TOP 1%

most cited scientists

12.2%

Contributors from top 500 universities



WEB OF SCIENCE™

Selection of our books indexed in the Book Citation Index
in Web of Science™ Core Collection (BKCI)

Interested in publishing with us?
Contact book.department@intechopen.com

Numbers displayed above are based on latest data collected.
For more information visit www.intechopen.com



Pros and Cons of Myomectomy during Cesarean Section

Cengiz Tokgöz, Şafak Hatirnaz and Oğuz Güler

Additional information is available at the end of the chapter

<http://dx.doi.org/10.5772/intechopen.75365>

Abstract

Additional surgical interventions apart from emergencies during cesarean section are not recommended in the textbooks; thus, surgical procedures like myomectomy as an adjunct to cesarean section remains a hot topic of discussion. There are many publications supporting serosal myomectomy during cesarean section, but studies published so far are poor in quality of evidence. To clarify the efficacy and safety of cesarean myomectomy, large-scale randomized controlled studies and studies explaining the mid-term and long-term outcomes of the cesarean myomectomy are required. Traditionally, cesarean myomectomy is performed from the uterine serosa as in the usual abdominal myomectomy. Although the surgical technique is the same as intracapsular myomectomy, a novel cesarean myomectomy technique, endometrial myomectomy, introduced into the obstetrics practice for minimizing the risk of adhesion formation and diminishing the blood loss during surgery. Further, strong studies are needed to overcome the controversy on cesarean myomectomy.

Keywords: endometrial myomectomy, cesarean section, serosal myomectomy, complications

1. Introduction

Among the benign uterine diseases, leiomyoma of the uterus seems to be the most common pathology. Though the endometrium is accepted as a dynamic tissue and myometrium is accepted as a silent muscular tissue, the reality is not that and it was understood from the studies that both endometrial processes and myometrial processes play a role in abnormal uterine bleeding.

Uterine leiomyomas, also known as fibroids, are smooth muscle-derived benign masses ranging from millimeters to many centimeters. The investigation of pathological specimens of the uterus revealed that almost 80% of African Americans women and 70% of Caucasian women have detectable leiomyomas [1, 2]. The well-known risk factors for leiomyoma do not explain why racial difference is this much but genetic polymorphisms including increased aromatase activity and signal transducing genes showed that more severe phenotypic pattern may be seen in African Americans [3, 4].

Inadequacy of medical treatment and lack of understanding of molecular physiology and pathophysiological processes make the surgical treatment as the main therapeutic option for leiomyomas [5].

Leiomyomas of the uterus are highly vascular benign tumors, and their volume may increase 9% in 6-month period. Growth rate of the myomas decreases after the age of 35 among Caucasian women and almost all myomas carried to menopausal period without any symptoms shrink in size together with the shrinkage of the uterus [6].

There are only limited options for the treatment of leiomyomas of the uterus, and most of the time leiomyomas are asymptomatic and no treatment is necessary. For asymptomatic patients, menopause itself is a cure factor [7].

There are numerous medical treatment options for the treatment of leiomyoma of the uterus like OCPs, progestins, NSAIDs, androgenic compounds, antifibrinolytics and progestin-loaded IUDs for symptom relief, and they are likely effective in at least a group of patients [8].

Other treatment options related to the use of GnRH agonists, GnRH antagonists and estrogen and progestin add back regimens may decrease the volume of the leiomyomas but after the cessation of medical treatment, leiomyomas resume their volume within 6 months of time [9–11].

Surgical therapy remains the definitive treatment option in symptomatic leiomyomas. Hysterectomy for the patients with no fertility problem increases the quality of the life of leiomyoma patients. Hysterectomy can be done by open surgery, laparoscopy or robotic-assisted surgery. Supracervical or subtotal hysterectomy is a controversial issue [12–14]. Abdominal myomectomy is the first surgical option for those who refuse to lose their uterus and who want to preserve their fertility for childbearing. Myomectomy can be done by open surgery, laparoscopic surgery and robotic-assisted surgery [15, 16]. For those who have submucous myomas, hysteroscopic resection is the gold standard treatment choice.

2. Cesarean myomectomy

One of the most controversial issues of obstetrics and gynecology is the presence of known or incidental leiomyomas during pregnancy and how to manage patients with myomas together with pregnancy. A total of 10–30% of the pregnancies develop some complications related to leiomyomas [17].

Cesarean section is the most commonly performed procedure globally [18]. Due to more advanced age, pregnancies are more prevalent in developed countries, naturally encountering leiomyoma during cesarean section getting more prevalent as well. The prevalence of the leiomyomas during pregnancy varies from 0.37–12% in the current literature [19–21].

Performing myomectomy during cesarean section is a controversial topic. The main concern is the potential risk of severe bleeding and increased morbidity when it is performed during cesarean section [22]. However, accumulating number of publications to support cesarean myomectomy in recent years is merging.

Potential indications of cesarean myomectomy are listed in **Table 1**.

Contraindications of cesarean myomectomy are listed in **Table 2**.

In contrary to common belief, Tinelli et al. presented that serosal myomectomy has a minuscule impact on blood loss in the light of no difference in blood product transfusion rates when it performed during cesarean section [23]. Ramesh et al. investigated 21 cases of cesarean myomectomy retrospectively and concluded that myomectomy during cesarean section is not associated with intraoperative and postoperative complications [24]. Leiomyomas located at the cornual region were not removed in their study. Mangala et al. compared the blood loss in single fibroid in abdominal and cesarean myomectomy cases and concluded that there is no significant difference between the groups, and it is safe to remove the single leiomyoma during cesarean section [25]. Machado et al. studied eight cases in Oman for the safety of cesarean myomectomy and concluded that in selected patients, cesarean myomectomy is safe and efficient in the hands of experienced surgeons and in the tertiary healthcare facilities [26]. Kwon et al. investigated 165 pregnant women having myomas, and they evaluated the patients whose myomas are over 5 cm in size and concluded that the size of the myoma has no greater impact on the increased rates of complications [27]. Sparic et al. assessed 350 papers on cesarean myomectomy and 38 studies found to be eligible for their evaluation for review of cesarean myomectomy in modern obstetrics. The major risk is intraoperative bleeding ranging

Symptomatic myomas (mild pelvic pain)
Myoma >5 cm
Single myoma
Anteriorly located myomas
Tumor previa
Pedunculated myomas
Avoiding extra surgical procedure
Degenerative myomas
Patient's desire

Table 1. Potential indications of cesarean myomectomy.

Age > 40 years
Multiple myomas
Cornual located myomas
Posteriorly located myomas
Asymptomatic myomas
Tendency to bleed
Previous history of uterine rupture

Table 2. Contraindications of cesarean myomectomy.

from 0 to 35.3%. A potential late complication is the scar quality after the surgery. This may increase the risk of uterine rupture during the next pregnancy, but the literature lacks studies related to scar quality. However, Sparic et al. noted the advantages of cesarean myomectomy as smaller incision on the serosal surface, easy to perform during cesarean section, effortless suture placement and two operations in one. Another important advantage of cesarean myomectomy is the improved quality of life in affected women. However, they concluded that the risk benefit of cesarean myomectomy should be re-evaluated and further research is necessary [28]. Song et al. reviewed myomectomy during cesarean section through the database search and among 2500 studies they found nine studies eligible for their review and concluded that cesarean myomectomy may be a reasonable option in some leiomyoma patients but data driven from the meta-analysis were low quality, and definitive conclusion on this issue cannot be drawn [29].

Synchronous uterine contractions are mandatory for a healthy delivery. The uterus has no triggering mechanism as pacemaker in the heart, instead, uterine muscles have self-oscillators triggered by the changing membrane potentials happening in the pregnancy period and their contractility increases toward the end of the gestation [31]. Myocyte contractility also increased by the facilitation of prostaglandins and myocyte to myocyte connectivity and activated intracellular contractile mechanism, which eventually increase the intrauterine pressure that effaces and dilates the cervix for the babies to be delivered. Any leiomyoma or other uterine pathologies may have negative effect on the uterine contractility and also any surgical procedure related to the uterine musculature might have negative impact on the uterine contractility and may increase the risk of uterine rupture during delivery. Decreasing the myocyte damage during myomectomy should be taken into consideration during any myomectomy cases.

Uterine pathologies including the leiomyoma have negative impact on the implantation and placentation [32]. Submucosal and intramural myomas deforming the endometrial surface reduce the implantation rates and increase the risk of abortion and mallocated placentation. The intramural leiomyoma not affecting the endometrial cavity is still a question. Number, size and locations of the myomas determine their impact. Small leiomyoma without endometrial

impact has no adverse effects [33]. Leiomyoma classified according to new myoma classification from type 0 (submucous myoma) to type 8 (Parasitic myomas) [34]. In this study, the leiomyomas were in the range of type 2 and type 5.

The human uterus may increase in volume and weight, 1000 times and 20 times respectively throughout pregnancy [35, 36]. However, myomas can only grow one in fourth size during pregnancy. Thus, myomectomy during cesarean section produces less tissue damage compared to removal of a symptomatic myoma in normal sized uterus. Serosal scarring and myocyte damage during myomectomy in nonpregnant uterus is more than that of cesarean myomectomy especially endometrial myomectomy. After all cumulated publications about the safety of cesarean myomectomies, severe bleeding and possibility of cesarean hysterectomy still remain controversial issue though these two complications are no common. Conforti et al. described techniques for reducing hemorrhagic blood loss in their study published in *European Journal of Obstetrics & Gynecology and Reproductive Biology* including tourniquet, uterine artery ligation, uterine artery embolization, vasopressin, tranexamic acid and uterotonic agents like oxytocin, misoprostol and dinoprostone, GnRH analogs before the operation, recycling of lost blood during surgery and gelatin matrix [31]. Desai et al. described a novel technique for reducing the blood loss during myomectomy, and they used selective uterine devascularization in nine pregnant patients before myomectomy at the time of cesarean section. The ovarian vessels were ligated on both sides, and the ascending and the descending uterine artery branches were ligated bilaterally after the removal of baby and placental materials. All cases were managed successfully after the selective devascularization, and they found this technique as a safe and effective method [32]. Uterine artery ligation is lifesaving procedure during cesarean myomectomy of big-sized myomas as in the case reported by Ma et al. in *Taiwanese Journal of Obstetrics and Gynecology* [33]. Blood loss due to myomectomy following cesarean section is calculated by the weighing the swabs used during the surgery and volumetric measurement of aspirated blood and recorded. Loss of blood in cesarean section was not recorded but before beginning myomectomy, the uterus and lower uterine segment incision site were stabilized for any major or minor bleeding. In a meta-analysis conducted by Song et al., they searched many databases without language restriction and included only nine studies eligible for investigation and they concluded that though cesarean myomectomy can be a reasonable option, cesarean myomectomy remains still controversial because the data are not satisfactory [29].

Literature search for cesarean myomectomies revealed many publications supporting the cesarean myomectomy. In the retrospective study conducted by Topcu et al., 76 cesarean myomectomy cases were compared with 60 cesarean only cases for blood loss, operation time, the need for transfusion and hospital stay and concluded that size of the myoma is not important and removal of corporal and subserous myomas is safe and feasible in some patients [36]. In a large group of cases in a university hospital setting, Li et al. investigated the efficacy of cesarean myomectomy of 1242 cases by comparing three groups of cases where 200 cases without myoma (group A), 145 cases with myoma but without myomectomy (group B) and 51 cases with myoma during pregnancy resulted in cesarean hysterectomy (group C), and they concluded that myomectomy during cesarean section is a safe and effective surgical method [37]. Sparic et al. analyzed the decision 289 making in cesarean myomectomy and concluded that

surgical skills, age of the patient and type of the myomas are the most important predictors of cesarean myomectomy [38].

Cesarean myomectomy has been consistently applied in our setting for 17 years. Beginning from 2013, endometrial myomectomy has been started and selected as the cesarean myomectomy of choice instead of classical serosal approach because in serosal myomectomy, the bleeding, operative time, myometrial damage and adhesion formation possibilities are higher as compared to endometrial myomectomy [30]. The rate of suturing the endometrium during surgery is very low and uterine involution itself shrinks the surgical site to a lesser size. The surgery raises the question whether the endometrial myomectomy increases the likelihood of intrauterine adhesions or Asherman syndrome. We performed ultrasound evaluation at seventh day postoperation and evaluated the myometrial defect and found totally normal appearance in 22 cases. Also we called all patients 40 days after the surgery for saline infusion sonohysterography (SIS) and SIS outcomes revealed that no single case experienced intrauterine adhesions at any level. SIS has been neglected for long time in infertility, but actually SIS is a simple and important investigation for intrauterine pathologies. Intrauterine adhesions can be verified by simple SIS as an adjunct to other diagnostic tools [39]. CS myomectomy from endometrial approach decreases loss of blood, total operation time and adhesion formation compared to classical cesarean myomectomy.

Hospital stay is no longer than classical myomectomies. Uterine serosa remains intact.

Endometrial myomectomy uses the principles of hysteroscopic myomectomy and supported by the physiological mechanism of uterine involution to decrease the blood loss and suturing during surgery. In this surgical method, unintentional opening of uterine serosa is accepted as complication because the main goal of this surgery is to remove all myomas from the endometrial layer without touching the serosal layer for preserving the uterus from dense adhesions and ease the future surgeries of the patient. All myomas located in anterior or posterior region and even the ones located close to cornual area can be safely removed by this surgical technique.

In the following section, we describe the techniques of serosal myomectomy and endometrial myomectomy in detail.

2.1. Techniques of cesarean myomectomy

There are two approaches for removing the leiomyomas during cesarean section; one is the well-known serosal myomectomy and second is the novel technique recently published endometrial myomectomy. Both techniques use the same principle of intracapsular myoma removal, but the only difference is the route of myoma removal. Removing myomas by endometrial route have some advantages over the serosal myomectomy and both techniques are explained in the following section in detail.

2.2. Technique of serosal myomectomy

Serosal myomectomy is the removal of the leiomyomas as in abdominal or laparoscopic myomectomy where incisions were made on the surface of the uterus. The only difference

is the enlarged and well-vascularized uterus during cesarean section. Uterine involution squeezes the big vessels in the endometrial cavity, but the surface blood supply is not affected from the involution thus the risk of bleeding during serosal myomectomy is increased. Besides, the incision on the surface remains large which may have greater impact on the adhesion formation. In cases where multiple myoma removal is necessary, the number of incisions increases and the risk of bleeding and formation of adhesions increases. In serosal myomectomy, removal of posterior myomas and myomas close to the cornual region are not recommended. Myomas close to each other may be removed from the same incision to diminish the adhesion formation.

Following removal of baby and the placenta, the uterine cavity is swept by a gauze and incision site is controlled for any bleeding and lower uterine segment incision is closed with a running nonlocked no. 1 Vicryl suture. Uterine surface is evaluated for the locations and the sizes of the myomas present. Leiomyoma close to the low uterine segment incision site was taken out as described in endometrial myomectomy technique. Closed proximity of the leiomyomas was removed from a single incision to diminish the adhesion formation. Leiomyoma located in different locations is removed by incising each leiomyoma surface thus sutures and scarring on the surface of the uterus are prominent in classical technique. While removing the myoma, if myoma base carries a vascular pedicle, then the pedicle is clamped and sutured. The muscular layer is closed by separate no. 1 Vicryl sutures. The serosal surface is closed in either continuous locked no. 1 Vicryl sutures or a baseball suturing technique. After suturing a very hot sponge is placed on the suture line for a short time and then removed to see any bleeding foci. Any resistant bleeding not controlled by electrocautery may be controlled by no. 2 Vicryl U sutures or by figure of eight sutures around the suture line. No antiadhesion material is used for protection. After removal and suturing of all myomas, uterus is placed in the abdominal cavity and the serosal surface of the uterus and the tubes and ovaries are checked for bleeding and following hemostasis and clot removal the abdominal layers are closed according to the general principles.

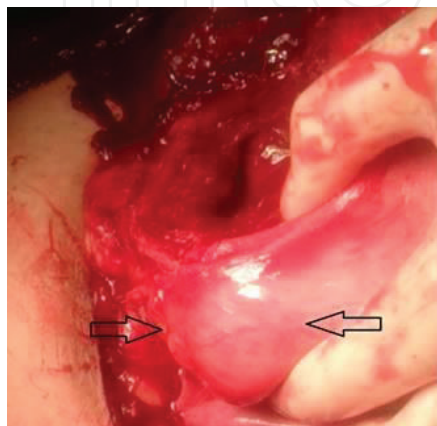
The long-term effect of this method is the adhesion formation, which makes the latter abdominal surgeries prone to complications. Hemostatic sutures for bleeding result in many suture nodes on the uterine surface and may prolong time of surgery.

In 2013, **Cengiz Tokgöz M.D.** developed a new cesarean myomectomy technique which was named as **endometrial myomectomy**. The main aim of this novel technique is to minimize the uterine scarring and eventual adhesion formation while using the uterine physiology as the main support for this surgical procedure. Until 2017, more than 30 cases were operated by this technique and 22 of the cases without posterior myomas were drilled into a retrospective study for publishing the preliminary outcomes of this novel technique. The technique was published in the *Journal of Maternal Fetal and Neonatal Medicine* as the first in the world and this study is the first and unique to compare one cesarean myomectomy technique(endometrial myomectomy) with another one (serosal myomectomy).

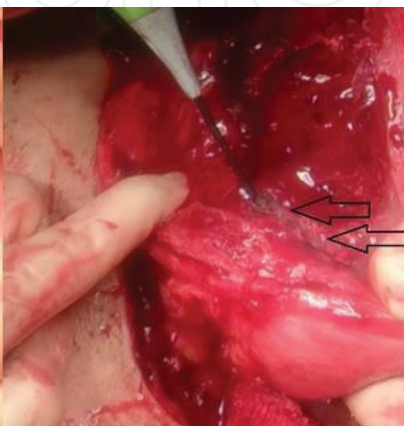2.3. Technique of endometrial myomectomy

All myomectomy cases were performed by the same team of surgeons and cesarean section technique and myomectomy techniques used in these surgeries were the same. After removal

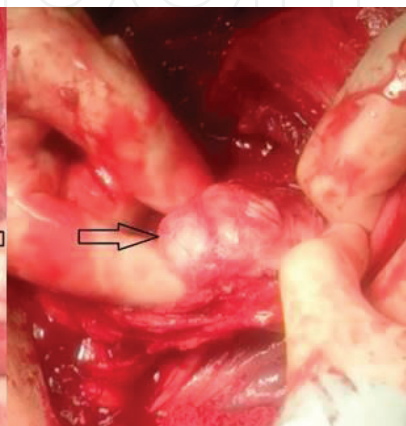
of the baby and the placenta, the uterus is taken out from the abdominal cavity. The uterine cavity is swept by a gauze and uterine incision is controlled for any bleeding. Uterine surface and cavity are evaluated thoroughly for leiomyomas and anatomical locations and sizes are evaluated quickly. Those leiomyomas located close to the low uterine incision site (**Picture 1**) are removed from the incision line, which is neither a serosal nor an endometrial myomectomy, and in fact, the myoma (**Picture 3**) is removed from subendometrial-intramyo-metrial area (**Picture 2**). The death space is closed together with the low uterine incision line suturing thus no extra suturing is necessary in such conditions.



Picture 1: Leiomyoma located close to the low uterine incision site



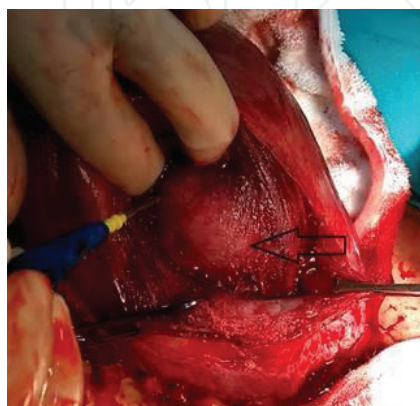
Picture 2: Incision to subendometrial - intramyometrial area



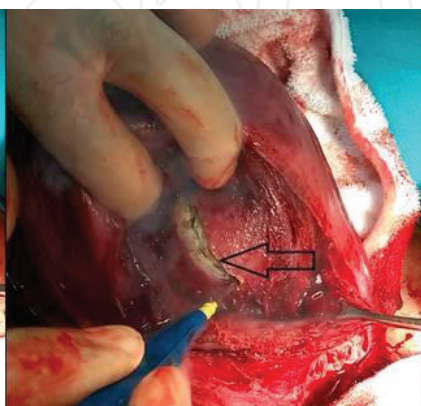
Picture 3: Removing the myoma

Courtesy of Oğuz Güler M.D. & Cengiz Tokgöz M.D.

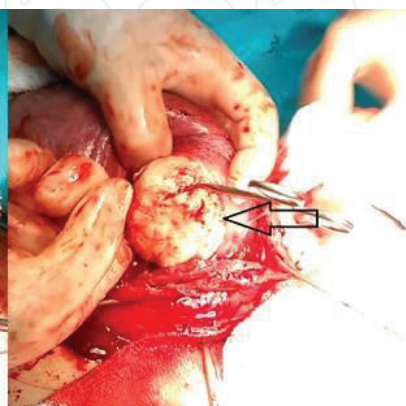
Following palpation and localization, leiomyomas (**Picture 4**) were pushed from the serosal site to be visible and palpable from endometrial site, then an endometrial-transmyometrial incision was made (**Picture 5**) to reach the leiomyoma by a scalpel or electrocautery knife and leiomyoma(**Picture 6**) was removed without its capsule (**Picture 7**) by blunt and sharp dissections.



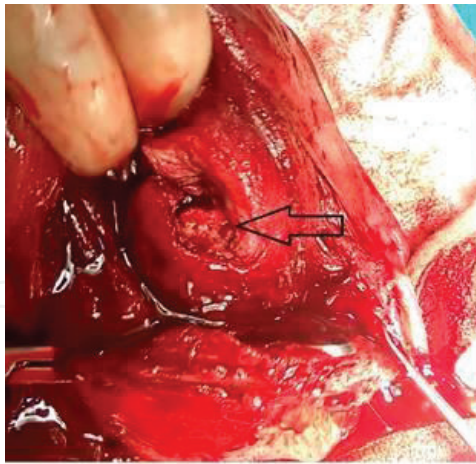
Picture 4: Palpation and localization of myoma



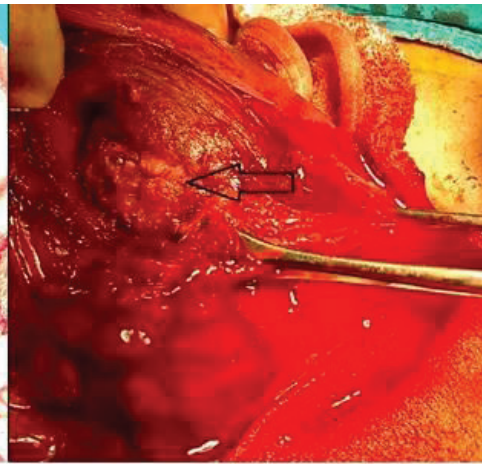
Picture 5: Endometrial-transmyometrial incision by electrocautery



Picture 6: Removing leiomyoma



Picture 7: Capsule remains it's place



Picture 8: Sutured endometrial incision

Courtesy of Şafak Hatırnaz M.D. & Oğuz Güler M.D.

Any vascular structures at the root of leiomyoma were clamped and sutured (**Picture 8**). If more than one leiomyoma are present and not close to each other, then all leiomyomas removed from one by one and endometrium is incised for each leiomyoma. However, the endometrium has the opportunity to involute rapidly and the endometria incisions diminish in size, which makes the endometrial scar smaller than the original incision. If the myoma removal site is not bleeding and the diameter of the incision on the endometrial layer <3 cm, no sutures are placed on the endometrial layer to minimize the adhesion formation within the endometrial cavity. This is what is done in hysteroscopic submucous or intramural myoma resection where suturing is impossible to do. If suturing is necessary for bigger incisions or bleeding, the no. 1 rapid Vicryl separate or continuous sutures are placed on the endometrial incision sites. By this technique, almost all myomas located on the uterus can be easily removed from the endometrium including subserous non pedunculated leiomyomas. Subserous myoma removal from the endometrium may seem to be unnecessary, but serosa of the uterus remains intact and the myometrial tissue damage diminishes while uterus is involuted. Thus, the death space in the myometrial layer is not observed, and myometrial integrity is not affected too much following this surgical procedure. Uterine physiology is the major supporter in this technique.

Following bleeding control, any bleeding sites were sutured if present and if no major bleeding, myoma bed or death spaces are sutured with no. 1 Vicryl in a separated manner. Endometrium is sutured with an absorbable suture in cases where the defect site is bigger than 3 cm. Any serosal opening during subendometrial myomectomy is accepted as complication because the main goal of this surgical method is to keep the uterine serosa intact apart from cesarean lower uterine segment incision scar and by this way to minimize the adhesion formation which is a matter of fact in myomectomies. In cases where reaching myoma is difficult, the team preferred to use bivalves to open the endometrial cavity for a safe surgical procedure. Uterus itself is the major supporter of this surgery since the rapid physiological involution of the uterus diminishes the death spaces and suture sites thus endometrial scarring

minimizes automatically. After inspection and hemostasis, lower uterine segment incision is closed and layers of the abdomen are closed carefully.

Postoperative care was not different from the cesarean section cases, and no additional treatment or follow-up was recommended for endometrial myomectomy cases.

Number of the leiomyomas, leiomyoma sizes, amount of blood lost during this procedure, serosal opening during surgery and operation time are all recorded. Leiomyomas are sent for pathological evaluation in all cases.

All patients are called 5 days after the hospital discharge for postoperative control and the uterus, the endometrium and the surgical sites of leiomyoma removal are evaluated carefully by

Intraoperative bleeding
Postoperative fever
Blood transfusion
Prolonged hospital stay
Adhesion formation
Asherman syndrome
Abnormal placental insertions
Uterine rupture

Table 3. Early and late complications of cesarean myomectomy.

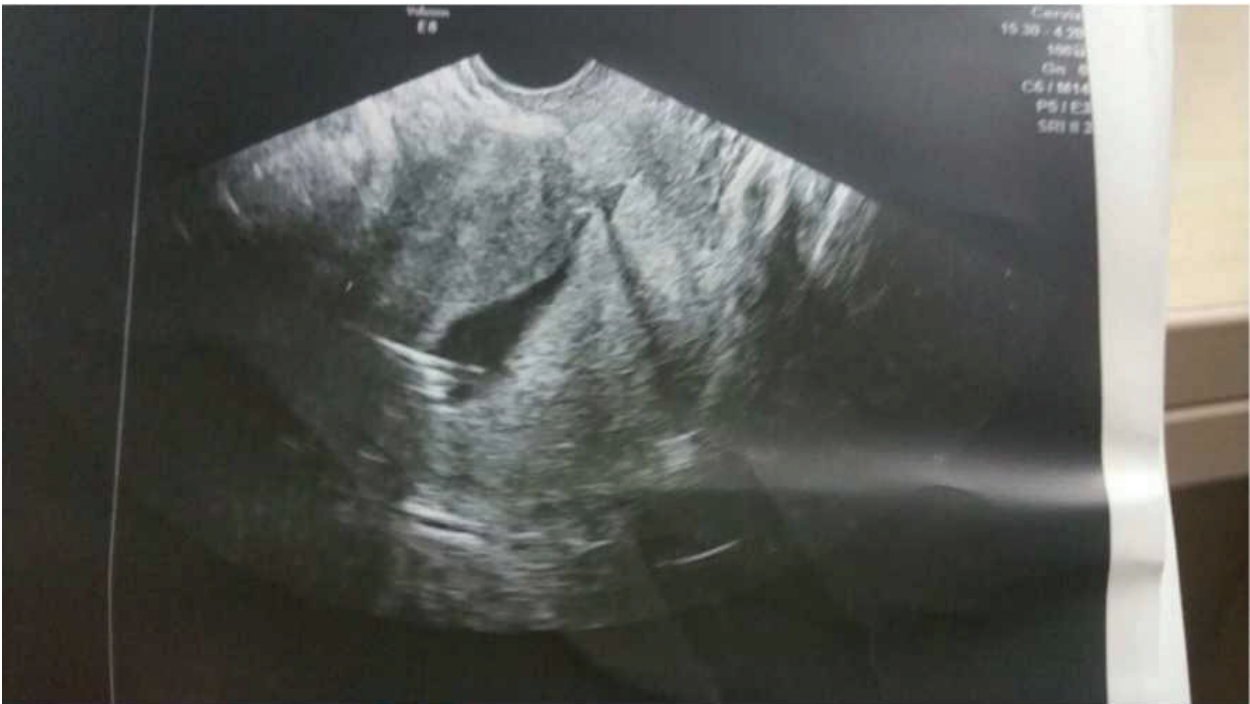

Figure 1. Saline infusion sonohysteroGRAPHY (SIS) 40 days after endometrial myomectomy. Courtesy of Oğuz Güler M.D.

transabdominal ultrasound and recorded. Every single patient is called for saline infusion sonography (SIS) 40 days after the surgery (when the uterine involution is ended and the uterus reaches the normal size) for the evaluation of endometrial damage or adhesion formation routinely and SIS findings are also recorded. Asherman syndrome at any level was not recorded in studied cases.

Among the studied 22 cases, four of them were operated for next cesarean section, and no leiomyoma formation or adhesion formation was observed during their next surgeries.

Both techniques carry some risks and complications during and after surgery. The complications related to cesarean myomectomy are listed in **Table 3**.

A picture of SIS 40 days after the operation is depicted in **Figure 1**.

3. Conclusions

Cesarean myomectomy still remains a controversial issue in obstetrics practice and seems to continue to be debated in the future. Because none of the studies were performed as randomized controlled trials so far, and meta-analyses derived from those studies have weak outcomes to say that cesarean myomectomy is a safe and reliable procedure. The accumulating data, however, diminished the fear of performing cesarean myomectomy.

Though this novel method of cesarean myomectomy, endometrial myomectomy, decreases the adhesion formation by keeping the uterine serosa intact, diminishes blood loss and reduce the operation time compared to serosal myomectomy, large-scale randomized controlled trials need to show mid-term and long-term outcomes of this novel approach. Much safer and technically easier methods may change the steady thoughts on the risks of cesarean myomectomy in future.

Author details

Cengiz Tokgöz¹, Şafak Hatirnaz^{2*} and Oğuz Güler¹

*Address all correspondence to: safakhatirnaz@gmail.com

¹ Department of Obstetrics and Gynecology, Private Bilge Hospital, Istanbul, Turkey

² IVF Center, Department of Obstetrics and Gynecology, Medicana International Hospital, Samsun, Turkey

References

- [1] Day Baird D, Dunson DB, Hill MC, Cousins D, Schectman JM. High cumulative incidence of uterine leiomyoma in black and white women: Ultrasound evidence. *American Journal of Obstetrics and Gynecology*. 2003;**188**(1):100-107

- [2] Cramer SF, Patel A. The frequency of uterine leiomyomas. *American Journal of Clinical Pathology*. 1990;**94**(4):435-438
- [3] Ishikawa H, Reierstad S, Demura M, Rademaker AW, Kasai T, Inoue M, et al. High aromatase expression in uterine leiomyoma tissues of African-American women. *The Journal of Clinical Endocrinology and Metabolism*. 2009;**94**(5):1752-1756
- [4] Pan Q, Luo X, Chegini N. Genomic and proteomic profiling I: Leiomyomas in African Americans and Caucasians. *Reproductive Biology and Endocrinology*. 2007;**5**:34
- [5] Stewart EA, Nowak RA. Leiomyoma-related bleeding: A classic hypothesis updated for the molecular era. *Human Reproduction Update*. 1996;**2**(4):295-306
- [6] Peddala SD, Laughlin SK, Miner K, Guyon JP, Haneke K, Vahdat HL, et al. Growth of uterine leiomyomata among premenopausal black and White women. *Proceedings of the National Academy of Sciences of the United States of America*. 2008;**105**(50):19887-19892
- [7] Şener AB, Seçkin NC, Ozmen S, Gokmen O, Doğu N, Ekici E. The effects of hormone replacement therapy on uterine fibroids in postmenopausal women. *Fertility and Sterility*. 1996;**65**(2):354-357
- [8] Marjoribanks J, Lethaby A, Farquhar C. Surgery versus medical therapy for heavy menstrual bleeding. *The Cochrane Database of Systematic Reviews*. 2006 Apr 19;**2**:CD003855. Review. Update in: *The Cochrane Database of Systematic Reviews*. 2016;**1**:CD003855
- [9] Friedman AJ, Daly M, Juneau-Norcross M, Rein MS. Predictors of uterine volume reduction in women with myomas treated with a gonadotropin-releasing hormone agonist. *Fertility and Sterility*. 1992;**58**(2):413-415
- [10] Friedman AJ. Treatment of leiomyomata uteri with short-term leupro-lide followed by leuprolide plus estrogen-progestin hormone replacement therapy for 2 years: A pilot study. *Fertility and Sterility*. 1989;**51**(3):526-528
- [11] Fellerbaum RE, Germer U, Ludwig M, Riethmuller-Winzen H, Hiese S, Buttge I, et al. Treatment of uterine fibroids with a slow release formulation of a gonadotropin releasing hormone antagonist Cetrorelix. *Human Reproduction*. 1998;**13**(6):1660-1668
- [12] Carlson KJ, Miller BA, Fowler FJ Jr. The Maine Women's Health Study: I. Outcomes of hysterectomy. *Obstetrics and Gynecology*. 1994;**83**(4):556-565
- [13] Kjerulff KH, Rhodes JC, Langenberg PW, Harvey LA. Patient satisfaction with results of hysterectomy. *American Journal of Obstetrics and Gynecology*. 2000;**183**(6):1440-1447
- [14] Owusu-Ansah R, Gatongi D, Chien PF. Health technology assessment of surgical therapies for benign gynecological disease, Best Practice & Research. *Clinical Obstetrics & Gynaecology*. 2006;**20**(6):841-879

- [15] Mansour FW, Kives S, Urbach DR, Lefebvre G. Robotically assisted laparoscopic myomectomy: A canadian experience. *Journal of Obstetrics and Gynaecology Canada*. 2012;**34**(4):353-358
- [16] Advincula AP, Xu X, Goudeau ST, Ransom SB. Robot-assisted laparoscopic myomectomy versus abdominal myomectomy: A comparison of short-term surgical outcomes and immediate costs. *Journal of Minimally Invasive Gynecology*. 2007;**14**(6):698-705
- [17] Klatsky PC, Tran ND, Caughey AB, Fibroids FVY. reproductive outcomes: A systematic literature review from conception to delivery. *American Journal of Obstetrics and Gynecology*. 2008 Apr;**198**(4):357-366. DOI: 10.1016/j.ajog.2007.12.039. Review
- [18] Ma PC, Juan YC, Wang ID, Chen CH, Liu WM, Jeng CJ. A huge leiomyoma subjected to a myomectomy during a cesarean section. *Taiwanese Journal of Obstetrics and Gynecology*. 2010;**49**:220-222
- [19] Laughlin SK, Baird DD, Savitz DA, Herring AH, Hartmann KE. Prevalence of uterine leiomyomas in the first trimester of pregnancy: An ultrasound-screening study. *Obstetrics and Gynecology*. 2009;**113**(3):630-635
- [20] Exacoustos C, Rosati P. Ultrasound diagnosis of uterine myomas and complications in pregnancy. *Obstetrics and Gynecology*. 1993;**82**(1):97-101
- [21] Kwawukume EY. Myomectomy during cesarean section. *International Journal of Gynecology & Obstetrics*. 2002;**76**:183-184
- [22] Park BJ, Kim YW. Safety of cesarean myomectomy. *The Journal of Obstetrics and Gynaecology Research*. 2009;**35**(5):906-911
- [23] Tinelli A, Malvasi A, Mynbaev OA, et al. The surgical outcome of intracapsular cesarean myomectomy: A match control study. *The Journal of Maternal-Fetal & Neonatal Medicine*. 2014;**27**:66-71
- [24] Ramesh Kumar R, Patil M, Sa S. The utility of cesarean myomectomy as a safe procedure. *Journal of Clinical and Diagnostic Research*. 2014 sep;**8**(9):0005-0008
- [25] Mangala KJ, Sudha S, Sarala S, Rajambal B, Usha MG, Sheejamol VS. Comparative study of cesarean myomectomy with abdominal myomectomy in terms of blood loss in single fibroid. *The Journal of Obstetrics and Gynecology Of India*. July-August 2016;**66**(4):287-291
- [26] Lovina SM Machado, Gowri V, Al-Riyami N, Al-Khurasani L. Cesarean myomectomy feasibility and safety *SQU MED J*. May 2012;**12**(2):190-196
- [27] Kwon DH, Song JE, Yoon KR, Lee KY. The safety of cesarean myomectomy in woman with large myomas. *Obstetrics & Gynecology Science*. 2014;**57**(5):367-372

- [28] Sparic R, Kadija S, Stefanovic A, et al. Cesarean myomectomy in modern obstetrics: More light and fewer shadows *The Journal of Obstetrics and Gynecology Research*. May 2017;**43**(5):798-804
- [29] Song D, Zhang W, Chames MC, Guo J. Myomectomy during cesarean delivery. *International Journal of Gynecology & Obstetrics*. 2013 Jun;**121**(3):208-213. DOI: 10.1016/j.ijgo.2013.01.021. Epub 2013 Mar 15. Review
- [30] Hatırnaz Ş, Güler O, Başaranoglu S, Tokgöz C, Kılıç GS. Endometrial myomectomy: A novel surgical method during cesarean section. *The Journal of Maternal-Fetal & Neonatal Medicine*. 2018 Feb;**31**(4):433-438. DOI: 10.1080/14767058.2017.1286320. Epub 2017 Feb 9
- [31] Alessandro C, Antonio M, Carlo A, 354 Ioannis T, Ida S, Adam M, Giuseppe DP. Techniques to reduce the blood loss during open myomectomy: A qualitative review of literature. *European Journal of Obstetrics & Gynecology and Reproductive Biology*. September 1, 2015;**192**:90-95. ©2015
- [32] Desai BR, Patted SS, Pujar YV, Sherigar BY, Das SR, Ruge JC. DGOA novel technique of selective uterine devascularization before myomectomy at the time of cesarean section: A pilot study. *Fertility and Sterility*. June 1, 2010;**94**(1):362-364. © 2010
- [33] Pei-Chun M, Yin-Chen J, I-De W, Chien-Han C, Wei-Min L, Cherng-Jye J. A huge leiomyoma subjected to a myomectomy during a cesarean section. *Taiwanese Journal of Obstetrics and Gynecology*. June 1, 2010;**49**(2):220-222. © 2010
- [34] Munro MG, Critchley HO, Fraser IS. The FIGO systems for nomenclature and classification of causes of abnormal uterine bleeding in the reproductive years: Who needs them? *American Journal of Obstetrics & Gynecology*. 2012 Oct;**207**(4):259-265. DOI: 10.1016/j.ajog.2012.01.046. Epub 2012 Feb 8
- [35] Shavell VI, Thakur M, Sawant A, Kruger ML, Jones TB, Singh M, et al. Adverse obstetric outcomes associated with sonographically identified large uterine fibroids. *Fertility and Sterility*. 2012;**97**:107-110
- [36] Topcu Hasan O, İskender Can T, Hakan T, Oktay K, Tuba M, Nuri D. Outcomes after cesarean myomectomy versus cesarean alone among pregnant women with uterine leiomyomas. *International Journal of Gynecology and Obstetrics*. September 1, 2015;**130**(3):244-246. © 2015
- [37] Li H, Du J, Jin L, Shi Z, Liu M. Myomectomy during cesarean section. *Acta Obstetrica et Gynecologica Scandinavica*. 2009;**88**:183-186
- [38] Sparic R, Malvasi A, Tinelli A. Analysis of clinical, biological and obstetric factors influencing the decision to perform cesarean myomectomy. *Ginekologia Polska*. January 1, 2015;**86**(1):40-45
- [39] Seshadri S, Khalil M, Osman A, Clough A, Jayaprakasan K, Khalaf Y. The evolving role of saline infusion sonography (SIS) in infertility. Eu Published. *European Journal of Obstetrics & Gynecology and Reproductive Medicine*. February 1, 2015;**185**:66-73. © 2014